

Foreign body

- Foreign bodies in the aerodigestive tract are the most common cause of accidental death in children **under 6 years**.
- Types of foreign bodies.... → Animate : insects, worms
→ In animate : Organic (fruits) or Inorganic (batteries, stones)

▶ Foreign bodies in EAR / Aural

1) In the helix / Pinna

- **Pierced earrings** ... in ear lobe or cartilaginous portions → in girls < 10 , adolescents with ✕ hygiene.
- ear pain, swelling, redness, constant pressure /due to swelling → ischemia and inflammation and even ULCER & purulent drainage from the piercing site.

→ Removal of embedded earrings -> local care & topical antibiotics.

2) In the external auditory canal

- Asymptomatic or complains of ear pain, hearing loss, tinnitus, itching , Purulent or bloody ear drainage.
- Can be **complicated** -> Infections (otitis media or externa) Bleeding, TM perforation, Stenosis in the ear canal, Damage to the inner ear.

→ Remove it by

- Hooks ▶ Animateshould be killed first by mineral oil, ethanol or lidocaine
- Magnetize Forceps ▶ Metal
- Suction ▶ very load / young pt can't tolerate it
- Syringing ▶ warmed saline Shouldn't be used in history of TM perforation , or for Organic FB

▶ Foreign bodies in NOSE

- Impacted between the septum and inferior turbinate and often visible on **anterior rhinoscopy**.
- Organic materials such as tissue paper provoke a inflammatory reaction from the nasal mucosa.
→ secondary inflammatory response of the nasal vestibular skin (**vestibulitis**) -> due to constant discharge.
- **Symptoms & Signs**
 - Sneezing, itching, bleeding, pain,
 - History of nasal FB insertion without symptoms
 - Mucopurulent nasal discharge
 - Foul odor - **unilateral** nasal discharge in a child
 - Epistaxis
 - Nasal obstruction
 - Mouth breathing
- **Complications**
 - Aspiration, bleeding, infections, adhesions, septal perforation.
- **Retrieval**
 - Bag valve Mask : by +ive pressure
 - Crocodile Forceps 🦎
 - Suction
 - Hooks 🗝

▶ Foreign bodies in Throat

- **medical emergencies** -> Airway Protection/ emergency intervention
- It should be suspected in patients with undiagnosed cough or stridor.

▶ Foreign bodies in Pharynx

- Nasopharynx -> **Rare/ gravity.... Or by leeches**
- Oropharynx -> **Fish bone**

▶ Foreign bodies in Hypopharynx

- Coins, bones, large bullous of food / meat, denture..
- Pain, choking, stridor, dysphagia, asphyxia ▶ the FB should be removed ASAP

Notes

→ **Both** are considered the most dangerous FBs :


Button batteries :

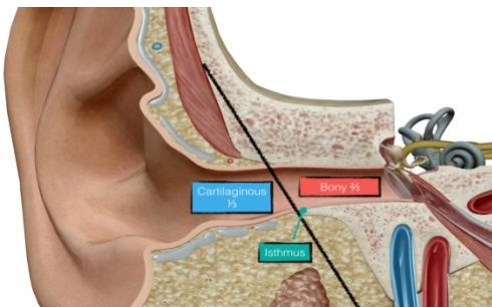
negative pole → directed toward the nasal septum → electrolysis generates hydroxide ions → alkaline tissue necrosis → septal perforation in less than 4 hr.

Paired disc magnets :

Strong, round disc magnets → one in each nostril → in the nasal septum → Prolonged attachment can cause perforation / chronic compression ▶ occurs over a period of weeks

→ Narrowest part in the external Ear  → Isthmus

→ Narrowest part in the Nose  → Internal nasal valve



Internal valve

The junction of the upper lateral cartilages with the nasal septum forms the internal nasal valve. This valve angle should be between 10 and 15° for adequate nasal airflow

