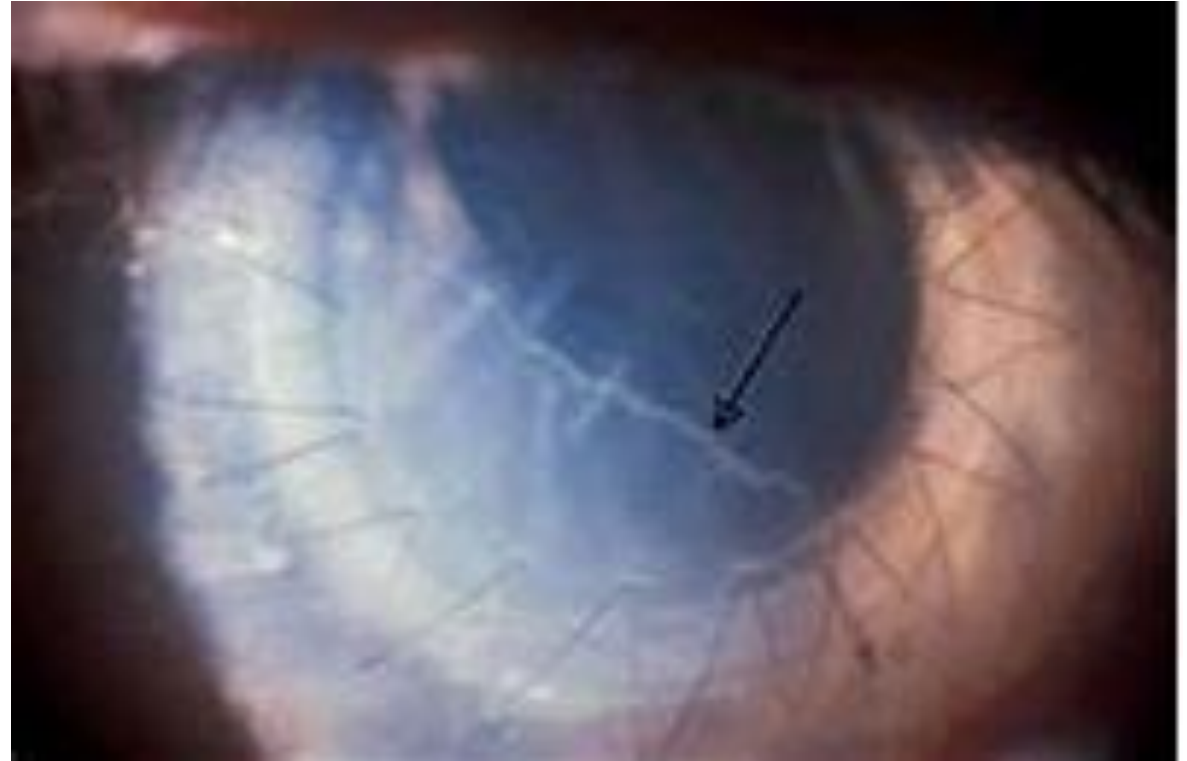

Clinical session

A 43 –year- old male patient  
had a history of pain redness  
and loss of vision

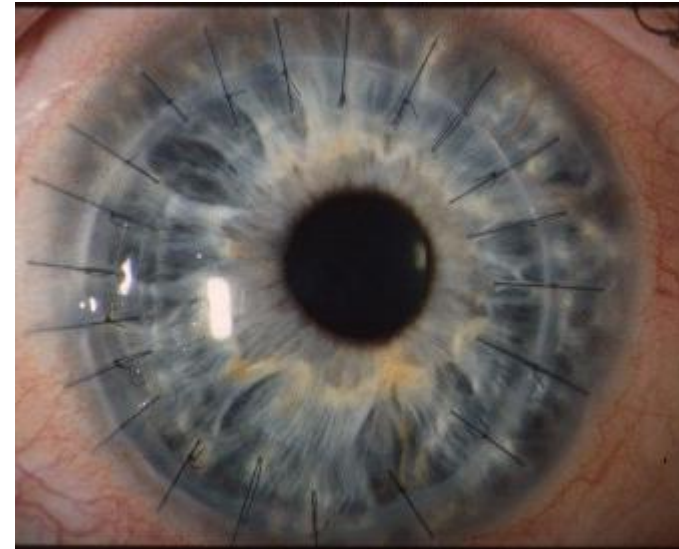
Had a corneal graft 6 months  
ago

Off eye drops



- signs of rejection which may be epithelial, stromal or endothelium. Rejection lines on the endothelium is called

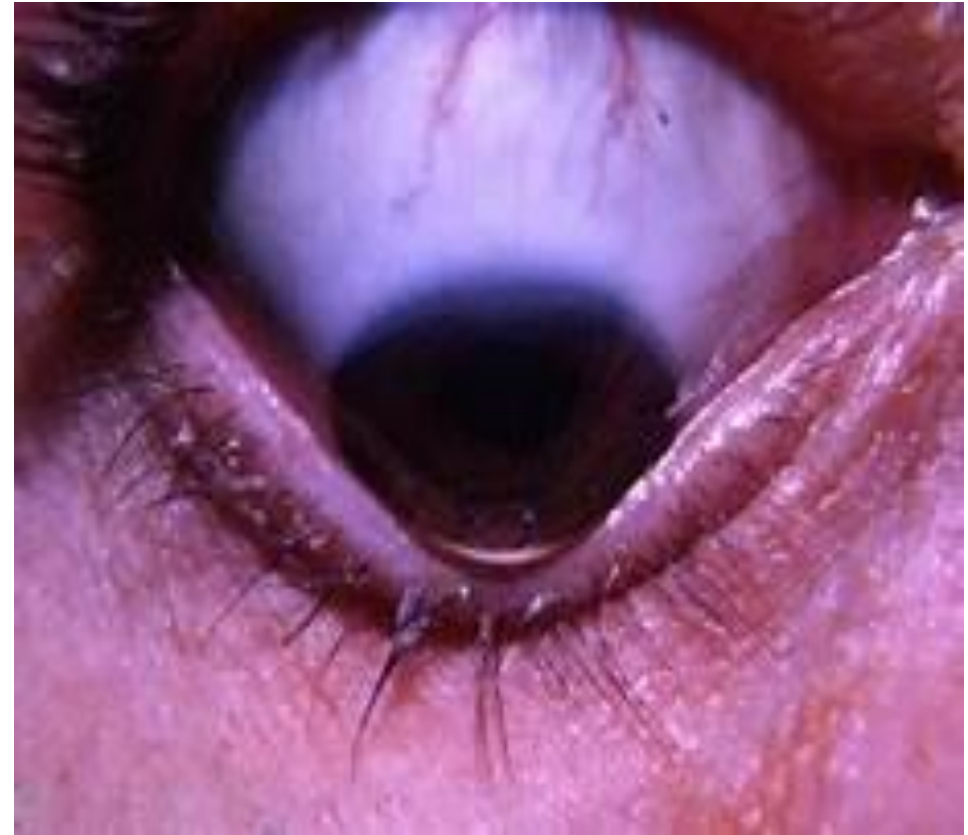
- Khodahoust's line. Do not forget to look for keratic precipitates as well as cells or flare in the anterior chamber. security of the suture and any pannus around the suture(s)



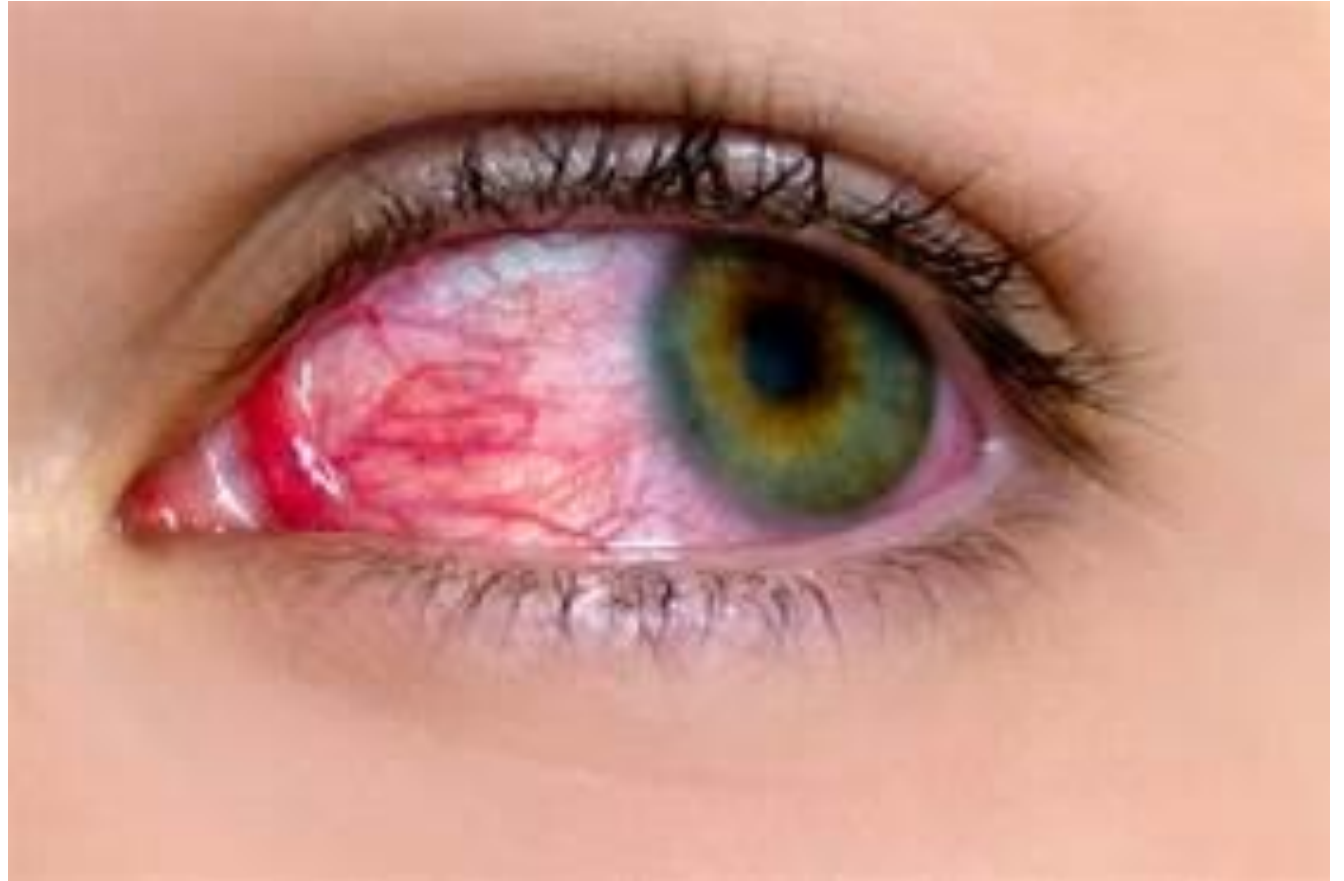## The indication for corneal graft

- presence of intraocular lens especially anterior chamber lens suggest pseudophakic bullous keratopathy
- look at the recipient cornea for signs for corneal dystrophy (this is especially obvious with macular dystrophy
- which extend to the peripheral cornea) examine the other eye for signs of dystrophies or keratoconus.
- in tetonic graft observe the patient's hands for rheumatoid arthritis which may be the cause of peripheral

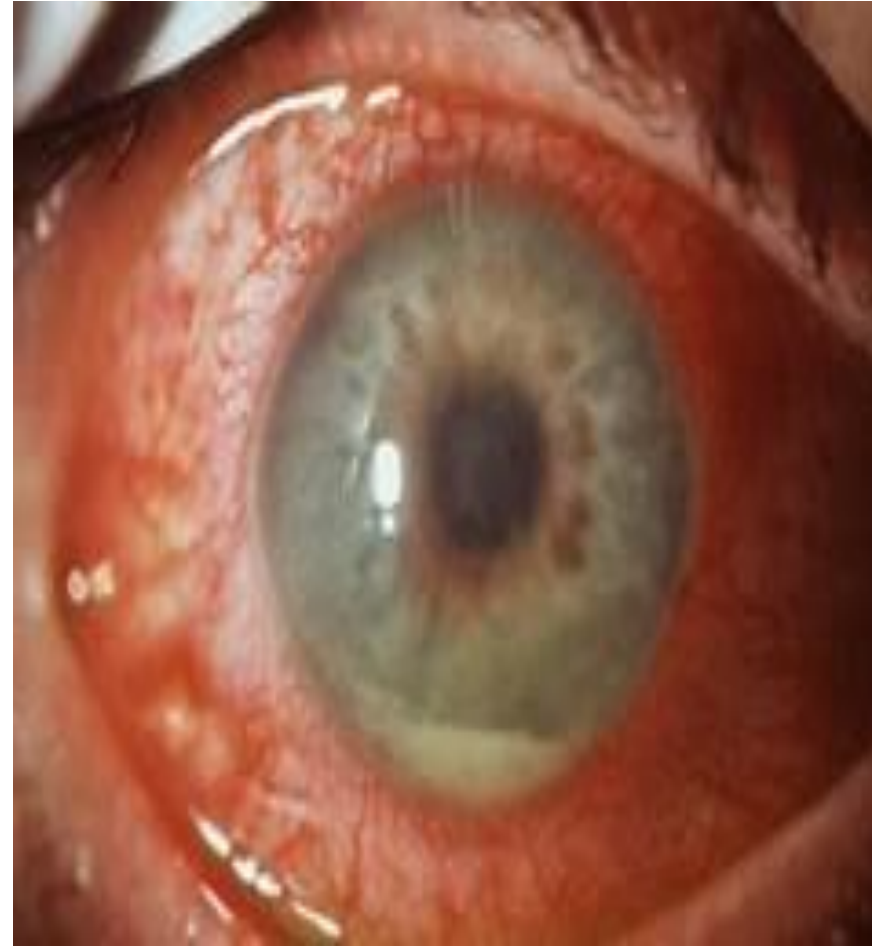corneal melt



What are the red flags  
in red eye

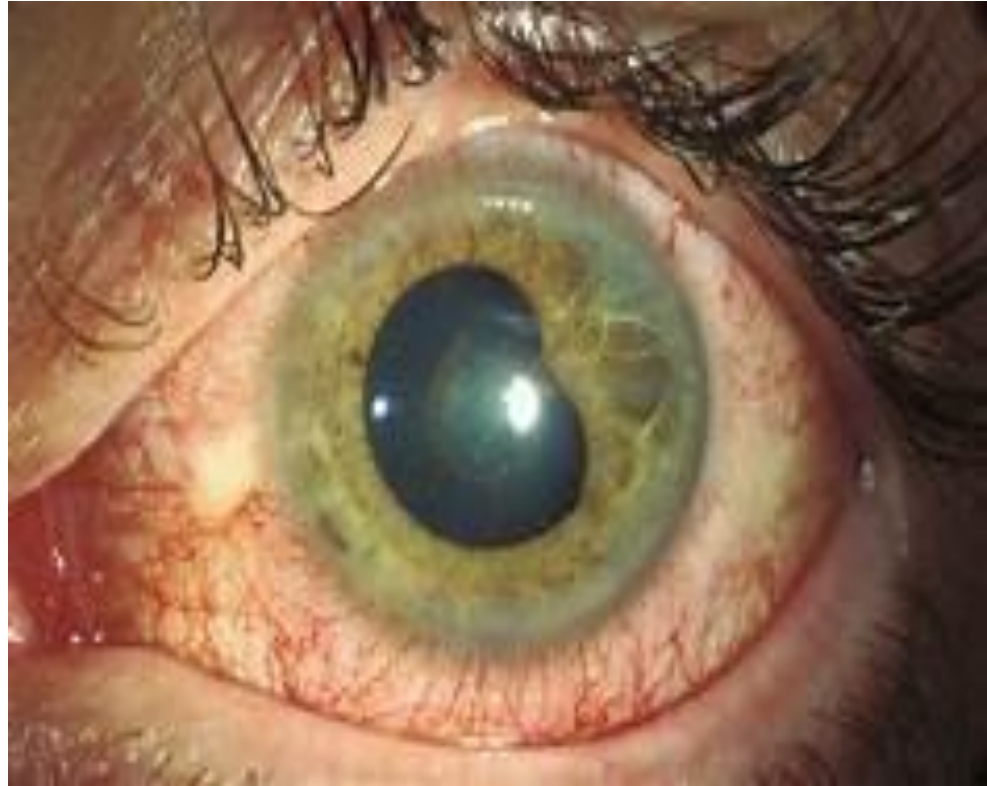

65 –year- old female  
presented with red eye  
and pain 5 days after  
cataract surgery



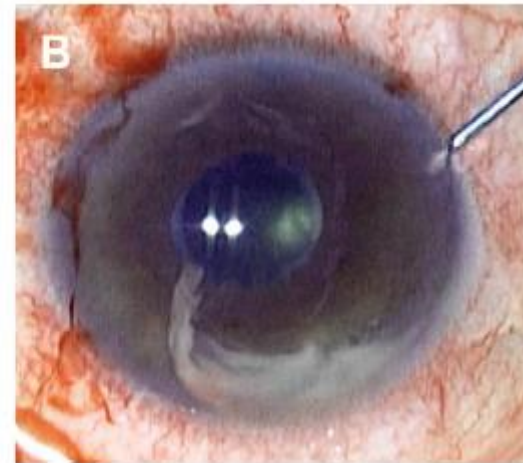
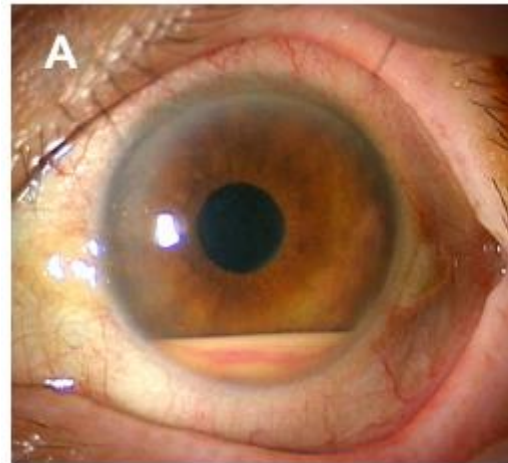
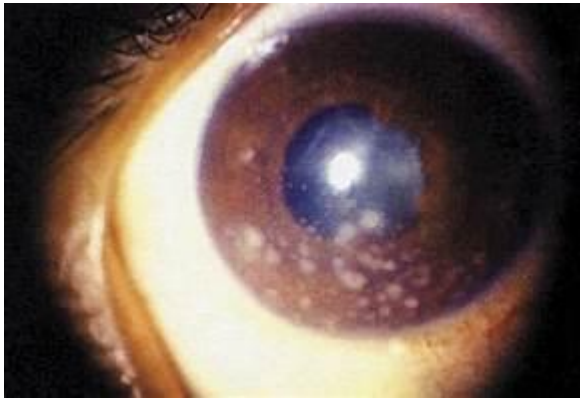
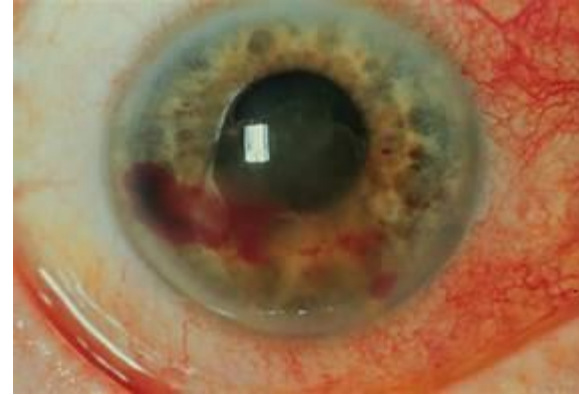
A 45 –year- old male with history of low back pain presented with eye redness

Had similar attack 2 months ago and reported no history of trauma





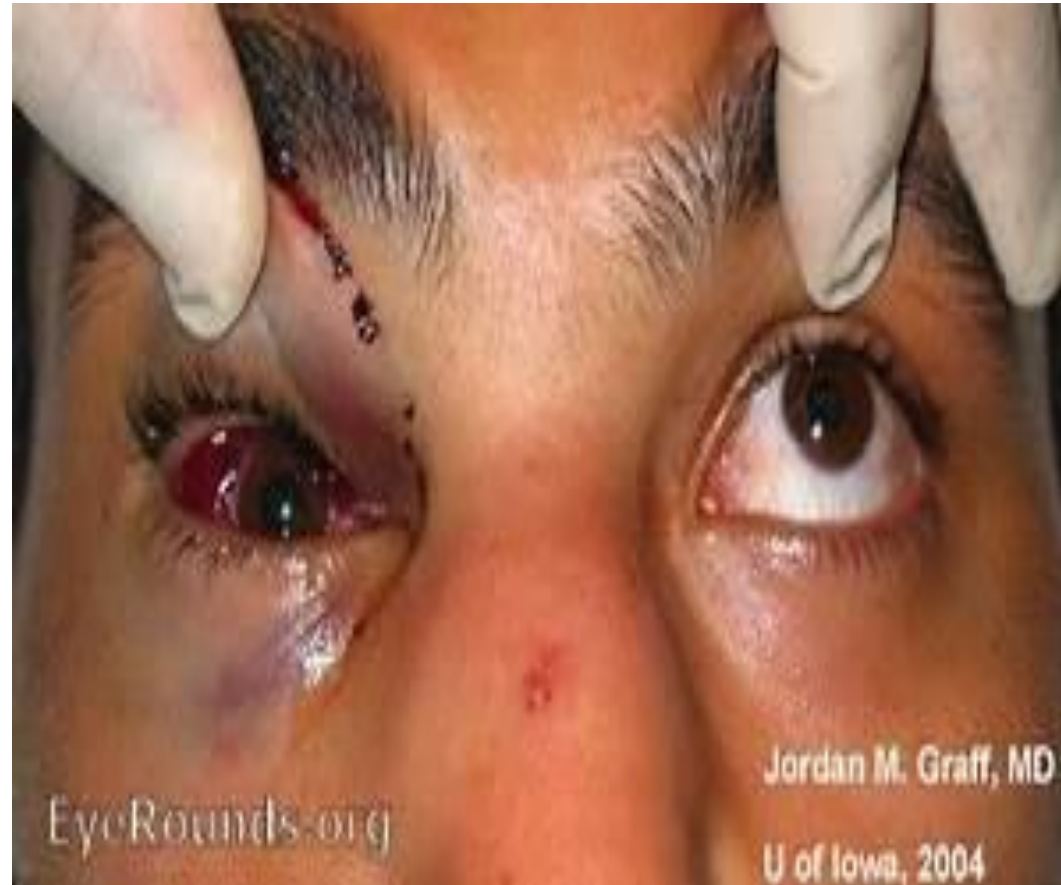## Other clinical signs



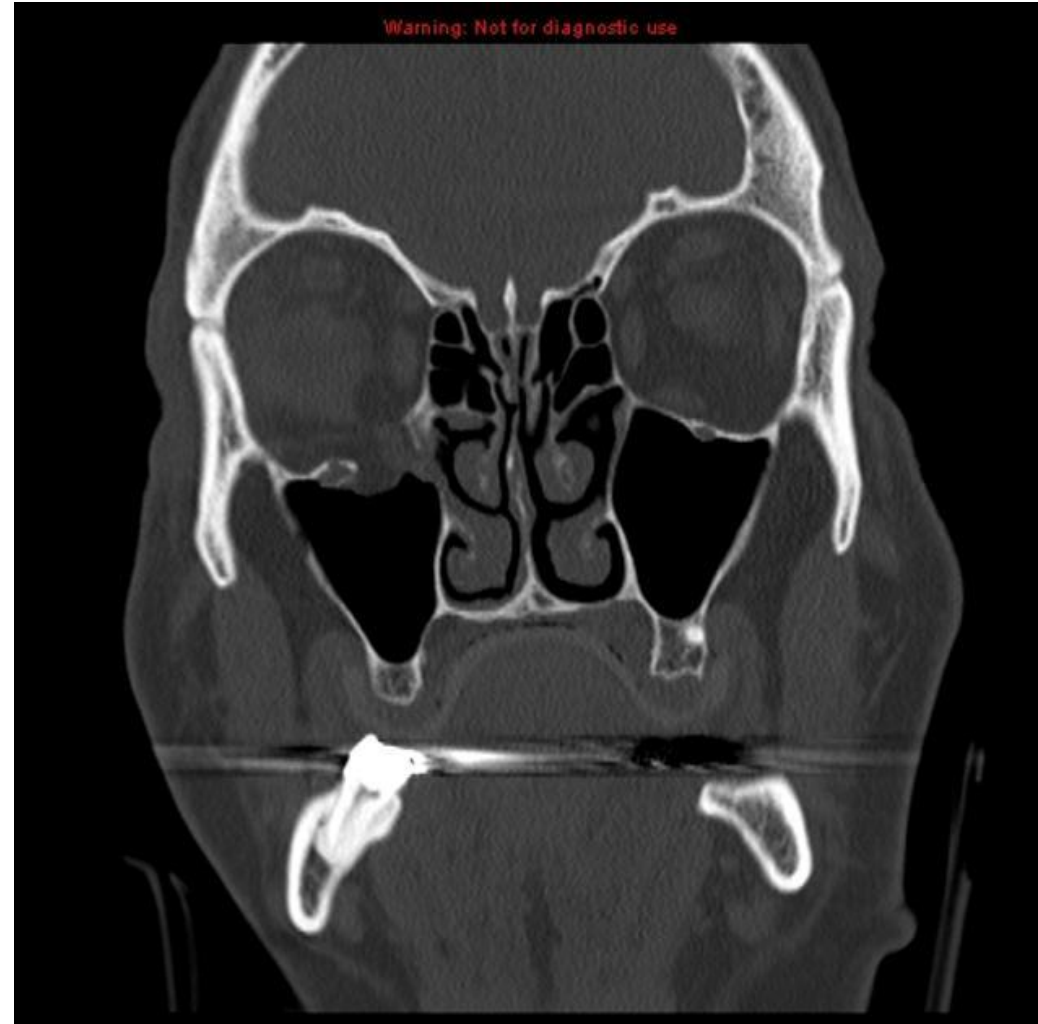


A 35 –year- old male with  
history of trauma by a  
tennis ball

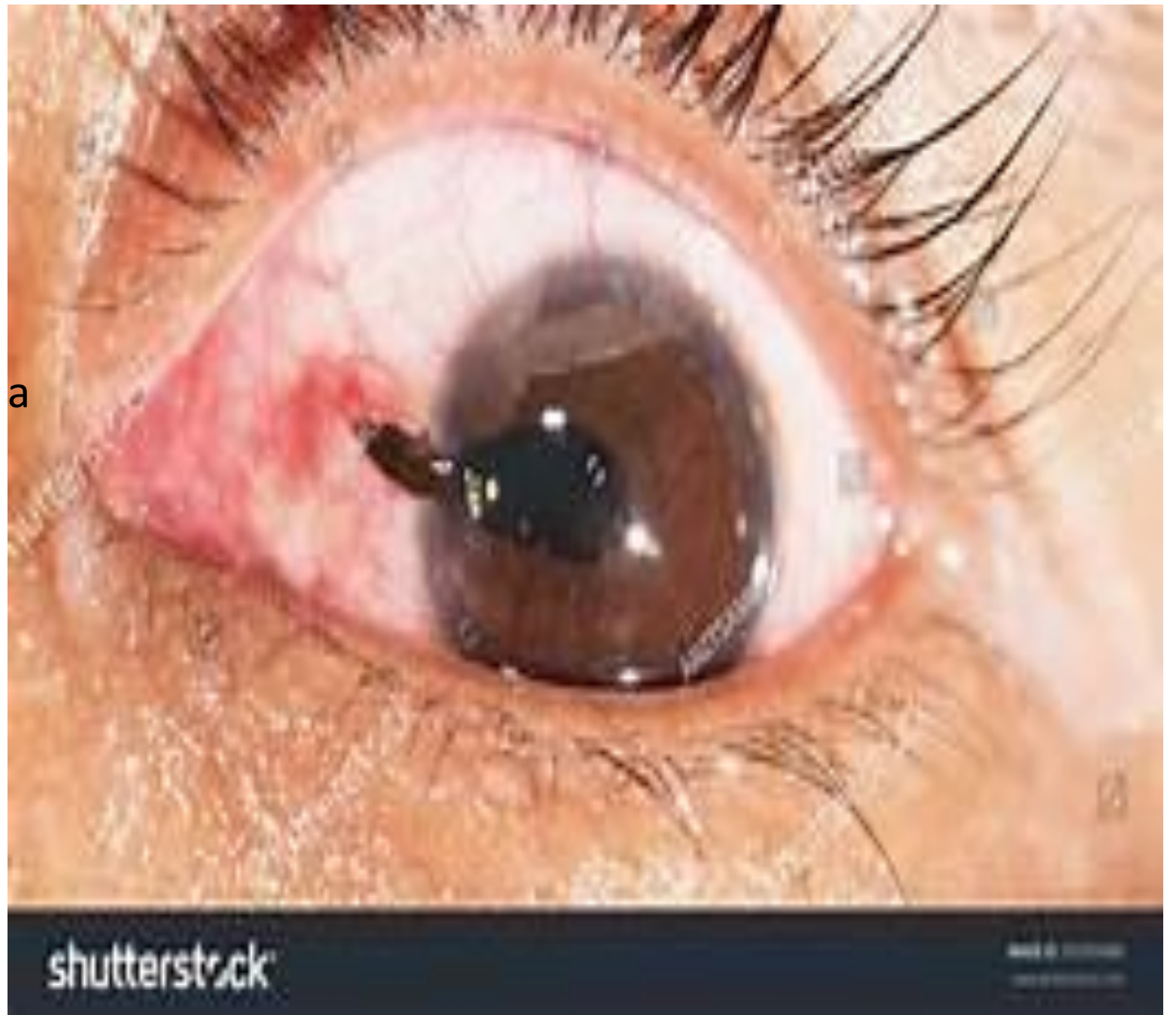How to approach



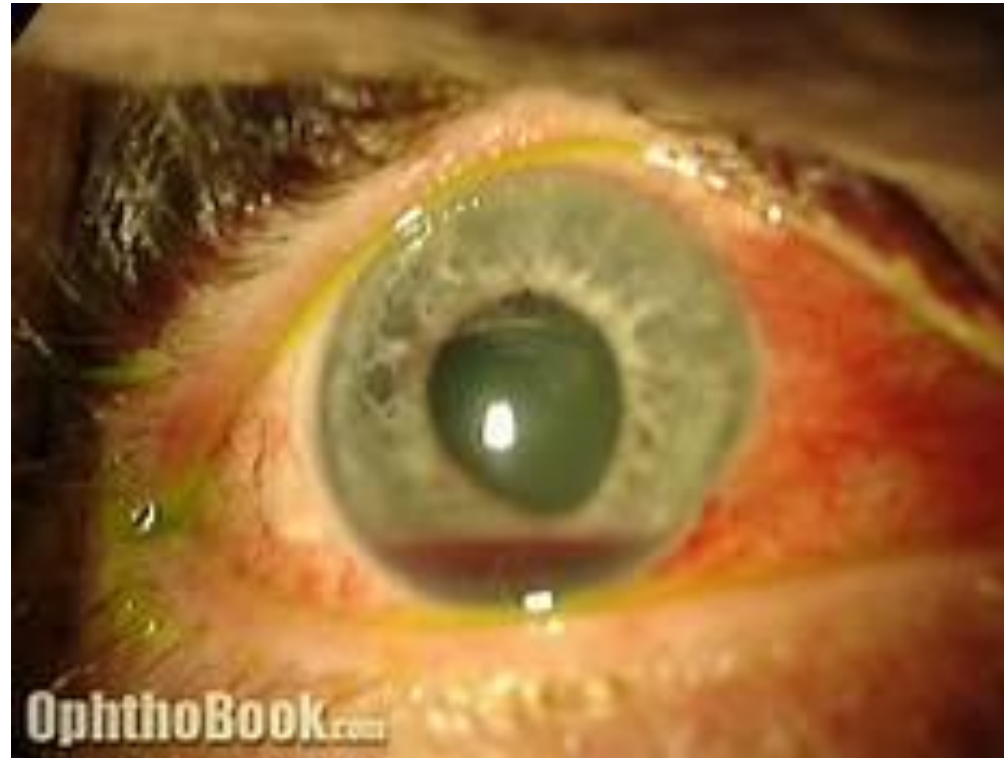What to look for in  
this imaging tool



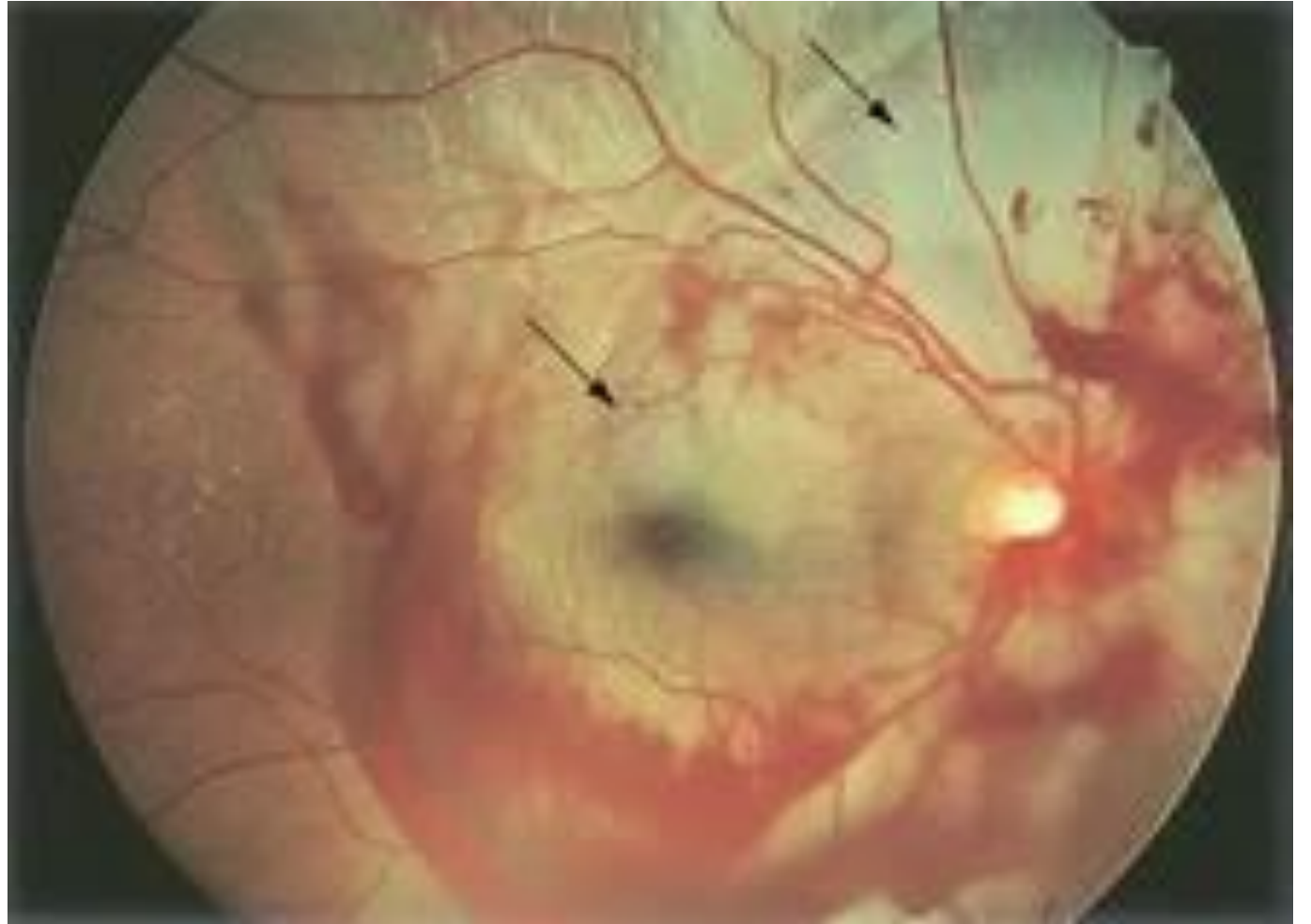A 10 year old boy with  
history of loss of vision after a  
quarrel



A 55 year old diabetic man with a complaint of loss of vision after being hit by a football

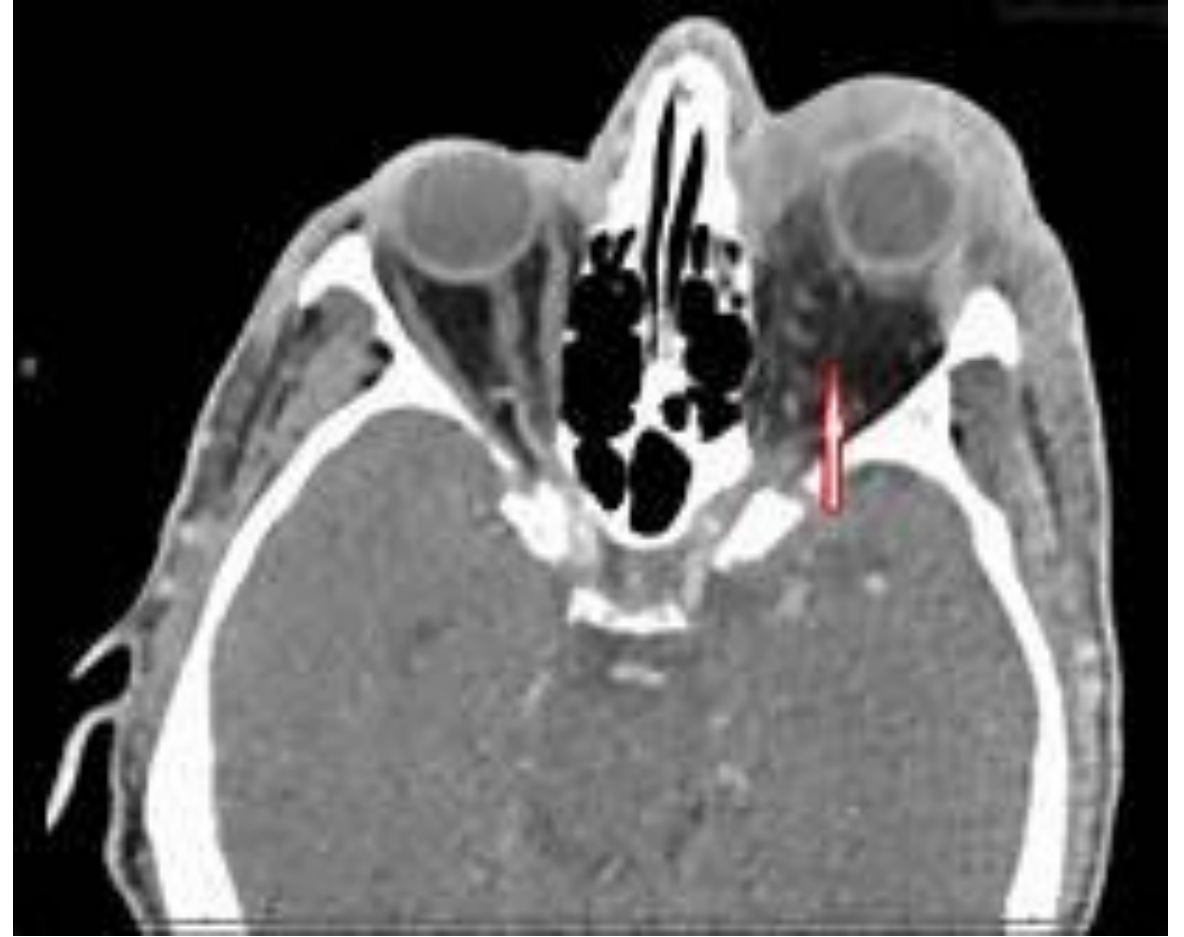


when it is safe to do  
dilated fundus exam

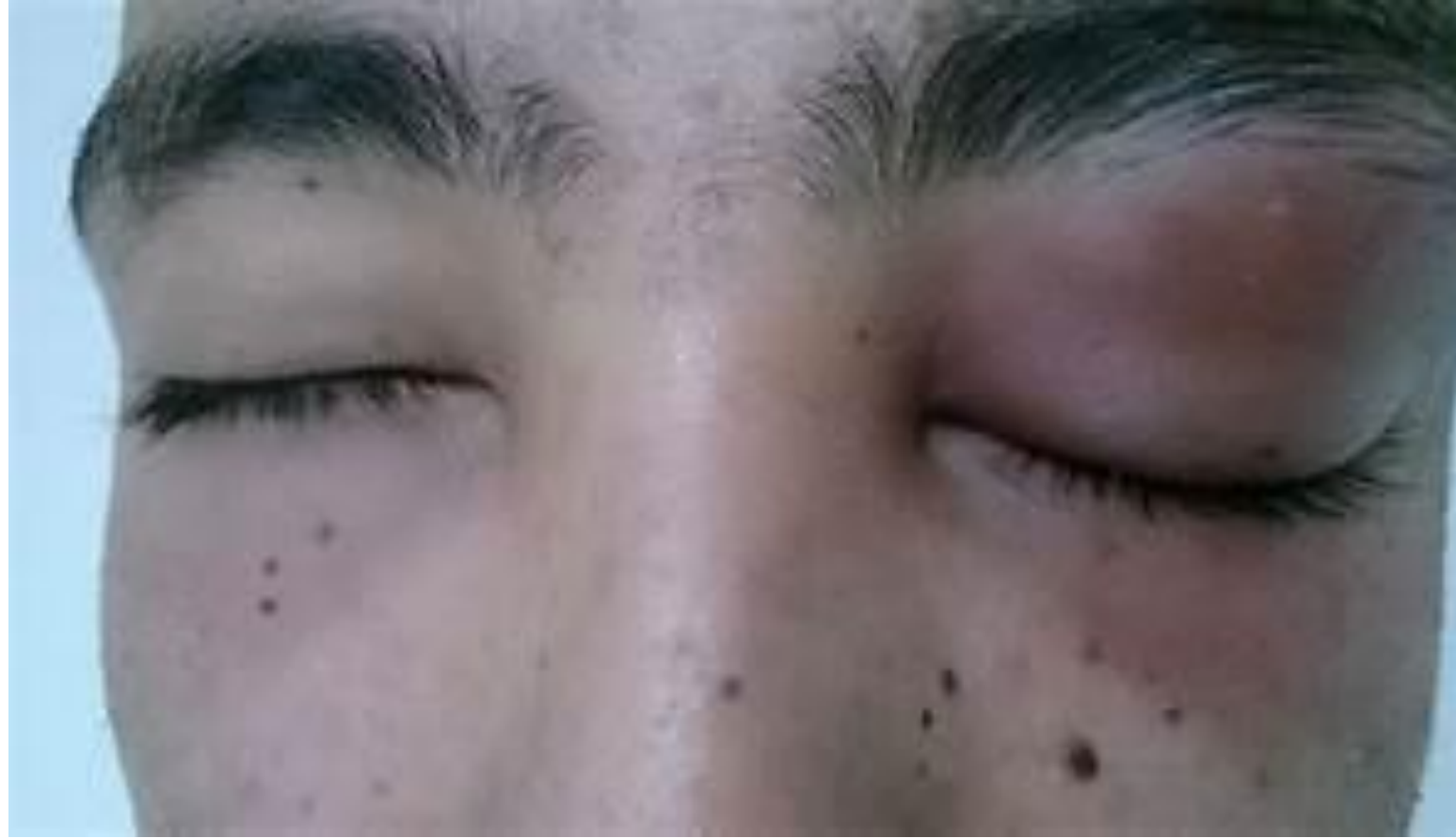



How can the CT scan help  
in differentiating  
preseptal from orbital  
cellulitis

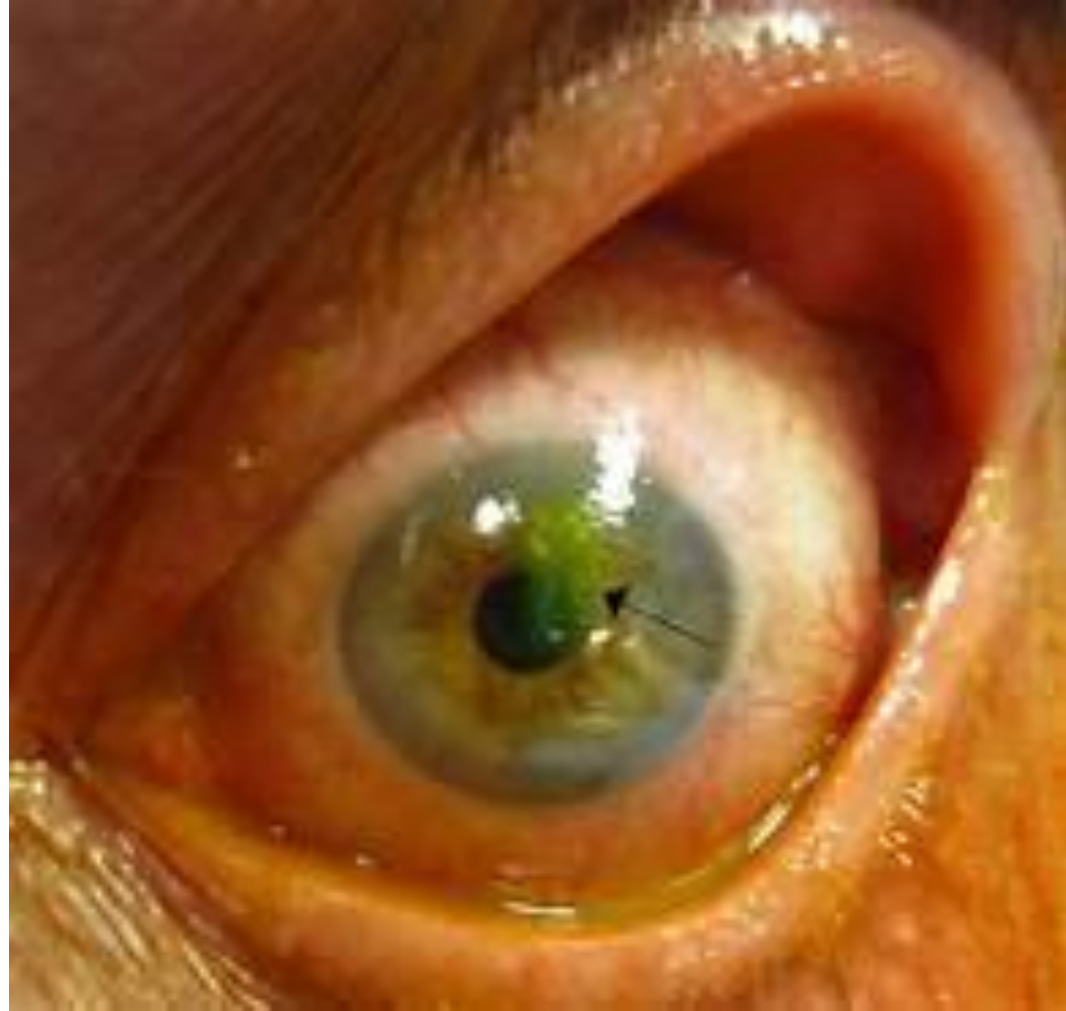

A 16 year old boy with  
complaint of fever , loss  
of appetite and It red eye



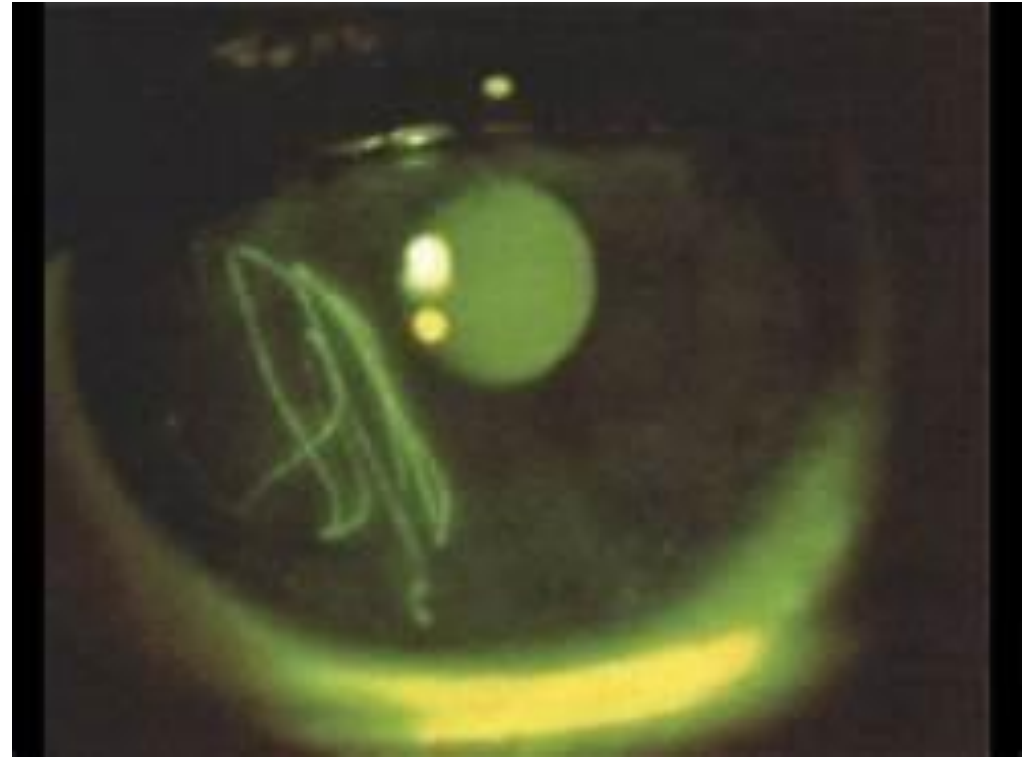


A 35 year old female with  
history of tearing ,  
forighn body sensation  
and photophobia

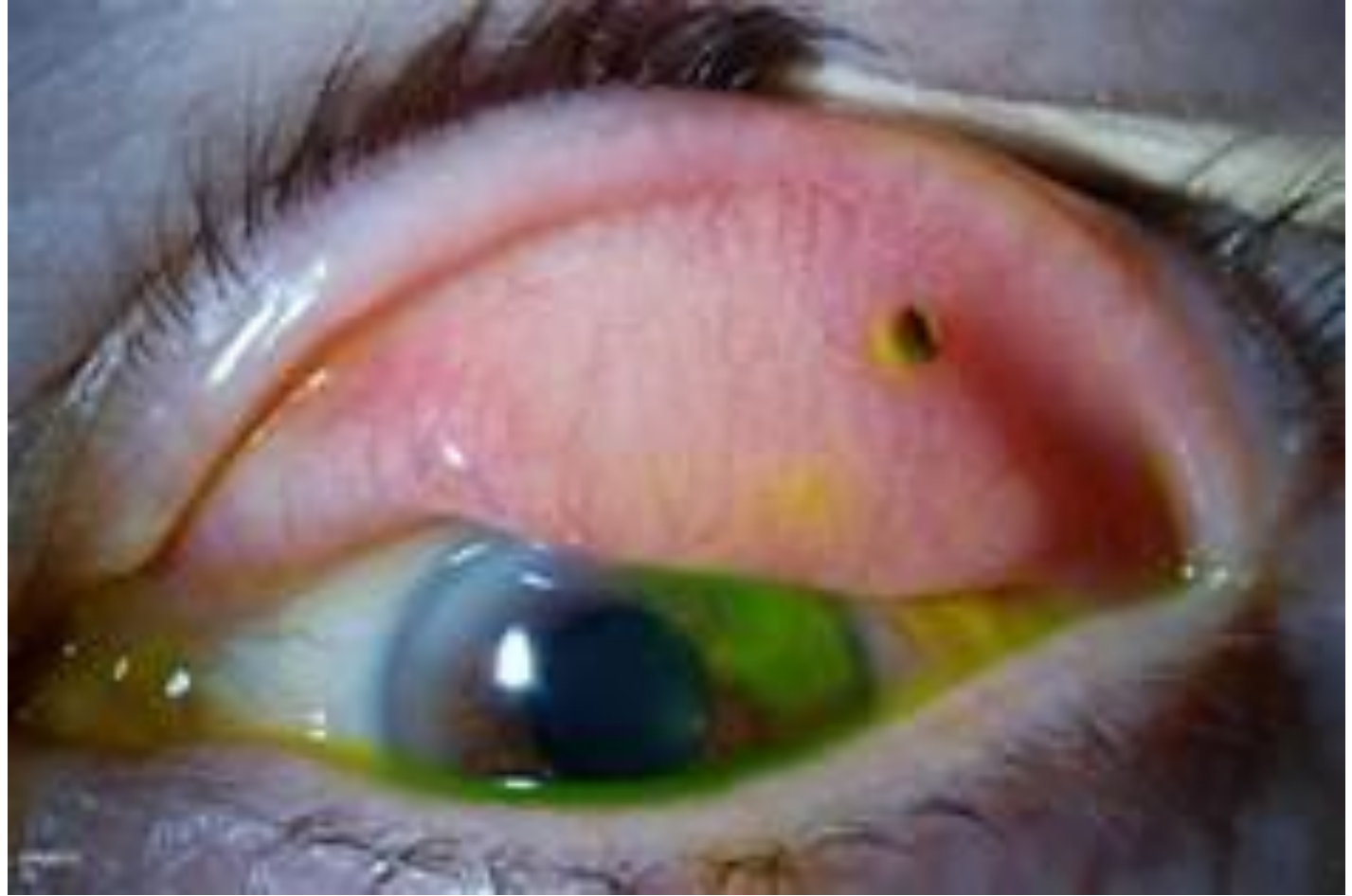

What is the name of  
the test

What is the important  
thing to look for



How do you manage?



What are possible complications of foreign bodies

How to manage this complication?

