Stones

RF → Previous stones, Family hx, DM, HTN, Obesity, gout, low fluid intake and diet, Malabsorption (Gastric bypass & short bowel syndrome)

Frequent upper UTI, Medications crystalize in urine (acyclovir, triamterene), Age (20-50), Male

Pathophysiology → Super saturation, Crystallization, Growth

Hx → severe Pain (Flank, suprapubic), Hematuria, N&V, Fever & Chills & rigors (Pyelonephritis), Recurrent UTI

→ Irritative S/S (Frequency, urgency, dysuria) (E.U.N), obstructive S/S (TPRIHU) → Testicular dropping, Poor stream, Retention, incontinence, urinary litter bag

Phx → Costovertebral angle tenderness

Invx → Basic labs (CBC, KFT, Urine analysis & culture), Metabolic workup (Ca, uric acid, creatinine, urea, Na, K, HCO3, Glucose)

CBC: WBC; Urine analysis: Urinalysis; Metabolic workup: BMP = Basic Metabolic Panel

Imaging

- KUB X-ray (initial for follow up, for knowing radio-appearance)
- US → indications → Pts X Radiation (Pregnant, Pediatric, recurrent stones) (Stones don't appear if they're in Ureter)
  - Findings → obstructive uropathy (hydronephrosis), stone (hyperechoic (bright) signal + acoustic shadowing)
- Non contrast CT → Gold standard (Abdomen & Pelvis) → Size, location, density, degree of obstruction, Hydroureter, Hydronephrosis
  - Indications → Single kidney, Severe N&V, AKI, leukocytosis, Pending sepsis (Pelvis ↑HR, ↓BP), Intractable Pain

Management

- **Acute** → Symptomatic management → Analgesia, Antiemetic, IV Fluids, IV Antibiotics
  - urgent active intervention: Decompression by Nephrostomy or Ureteric stent (JJ)
    - Indications (+ obstructive stone) → ① Single kidney ② Bil obstruction ③ Severe N&V ④ AKI ⑤ leukocytosis ⑥ Pending sepsis ⑦ Intractable Pain ⑧ Special scenarios
- **Chronic** → According to ① location ② Size

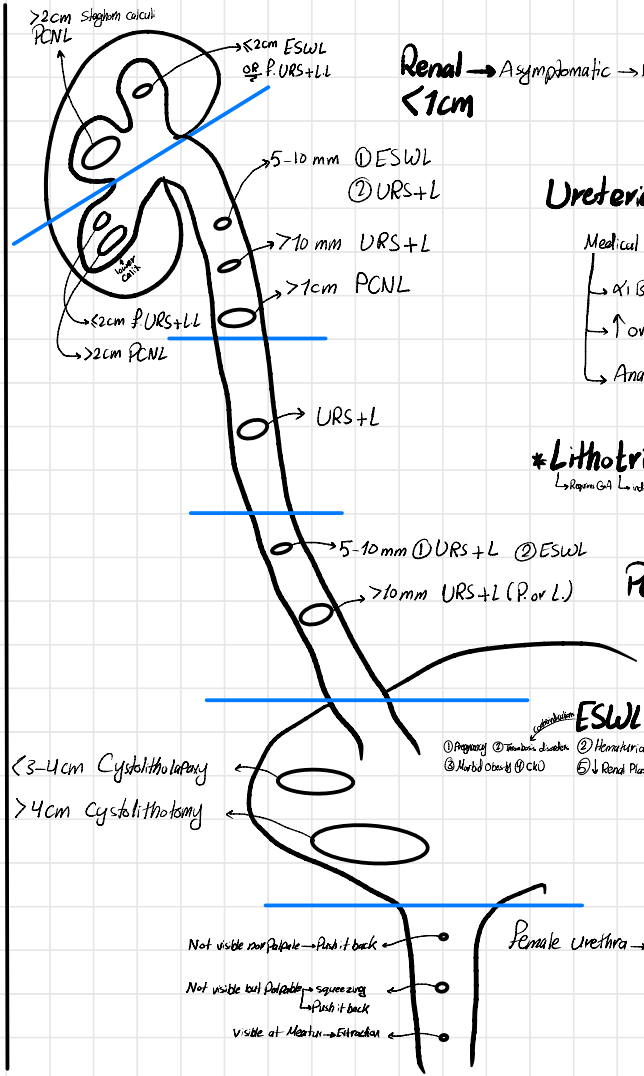

Renal <1cm → Asymptomatic → No need for intervention

Ureteric stones ≤5mm

Medical Expulsive Therapy (MET)
- α1 Blockers (Tamsulosin)
- ↑ oral Hydration
- Analgesia & Antibiotics

***Lithotripsy** → Laser, Pneumatic, ESWL
- Requires GA
- Indications: ① ESWL failure ② lower Pole stone ③ cystine stones ④ obesity ⑤ N&S deformities ⑥ Intractable kidney

PCNL Contraindications → UTI & bleeding tendency

ESWL Contraindications: ① Pregnancy ② Thrombosis disorders ③ Morbid obesity ④ CKD

SE → ① Structural & functional Renal damage ② Hematuria ③ Edema ④ Perirenal hematoma ⑤ ↓ Renal Plasma Flow ⑥ AKI

Stones

Overview of kidney stones

Types	Incidence	Etiology/associated findings	Urine pH	Crystal appearance	Radiopacity	Prophylaxis

Calcium oxalate stones	• ~ 75%	• Hypercalciuria
		• Hyperoxaluria
		• Hypocitraturia
		• Can result from increased intake of
		  ○ Ethylene glycol (antifreeze)
		  ○ Vitamin C
		• Associated with inflammatory bowel disease, i.e., ulcerative colitis and Crohn disease due to malabsorption
			• ↓ Urine pH (acidic)	• **Biconcave dumbbells** or **bipyramidal envelopes**	• Radiopaque	Rise Ph to 6.5-7.5
						• Urine alkalinization
						→ K citrate + Potassium
						→ Na HCO3 → Na + Bicarb /Bicarbonate

Uric acid stones	• ~ 10%	• Gout, hyperuricemia, and hyperuricosuria • High cell turnover (e.g., leukemia, chemotherapy)	• ↓ Urine pH (acidic) and volume (often seen in desert climates)	• Rounded rhomboids, rosettes, or **needle-shaped**	• Radiolucent	• Urine alkalinization
Struvite stones	• ~ 5–10%	• UTI with urease-producing bacteria (e.g., Proteus mirabilis, S. saprophyticus, Klebsiella)	• ↑ Urine pH (alkalic)	• Rectangular prisms (**coffin lid-appearance**)	• Weakly radiopaque	lower Ph < 7 (Bad) (Good) Urine acidification • Urine acidification @ IV NH4Cl (NPO)
Calcium phosphate stones		• Hyperparathyroidism • Type 1 renal tubular acidosis	• ↑ Urine pH (alkalic)	• **Wedge-shaped prisms**	• Radiopaque	• Urine acidification
Cystine stones	• < 5%	• Cystinuria (hereditary)	• ↓ Urine pH (acidic)	• **Hexagon-shaped**	• Weakly radiopaque	• Urine alkalinization
Xanthine stones		• Xanthinuria (hereditary)	• Generally independent of urine pH	• Amorphous	• Radiolucent	• N/A

DDx
- → Acute Abdomen → Biliary colic, Acute cholecystitis, Acute Appendicitis, IBD, Diverticulitis
- → Scrotal Pain → Testicular torsion, Epididymitis
- → Upper UT obstruction (Hydronephrosis), UTI (cystitis, Pyelonephritis)

Urodynamic Studies

Evaluating Pressure – Flow relationship between bladder and urethra → Functional & anatomical abnormalities of lower UT (Urinary incontinence)

2 Phases → Filling (storage) & Voiding

Filling
- → 2 catheter → ① Urethral (Intravesical P) ② Rectal, Vaginal, Stoma (Intra-abdominal P)
  - Detrusor P = IV – IA (normal = 40–60 mmHg)
- → Indications → ① Differentiate between Detrusor overactivity & stress incontinence ② Determine Neurological Abnormalities (Hypotonic bladder)
- → 5 → ① capacity → 450–550 ml (Adults) (Age + 2) × 30 (Children < 18)

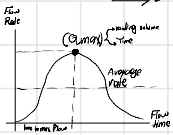

- ② Contraction → DVP, Should be Zero (no contraction), in Detrusor overactivity (uninhibited bladder) → DVP ↑↑↑ (mmHg/cm)
- ③ Compliance → for detrusor muscle, ΔV/ΔP = ↑V → P (same), DVP = 60 ml/20 → 12–14 (Sg), Determined by (viscoelastic Properties)
- ④ Cough test → look for Stress incontinence
- ⑤ Bladder sensation → urge to urinate during filling → 1st urge 100–150 ml, 2nd urge 150–200 ml, Max 350–550 ml
  - → ① intact sensation ② Hypersensitivity (sensory urgency) ③ Hypo sensitive

Voiding
- → Urine Flowmetry → ① Flow curve → continuous, single bell-shaped curve & urine volume > 200 ml over 15–30 sec
  - ② Qumax → 20–25 ml/sec (male), 25–35 ml/sec (Female)
- → Detrusor voiding Pressure → DVP 30–60 (male), 20–40 (Female) Obstruction → ↑DVP Hypo contractile → ↓DVP
- → Indications → ① obstruction (BPH, Urethral overactivity, Urethral stricture)
  - ② Weak detrusor (Hypotonic bladder) ③ ↑ Valsalva during voiding

Done by: Abdelrahman Sulieman