



Mohammad Z. Abo Shaban

Lejan Aldofaat female presented with infertility, visual defect and galactorrhea:

A- what's the best neuroimage? **MRI**

B- which hormone should be measured?

Prolactine.

C- on visual examination which finding you will find and explain why. ~~Hemianopsia~~ *Bitemporal*

hemianopsia due to mass effect of **prolactinoma** compressing the optic **chiasm.**

D- mention two lines of treatment?

- 1 **Resection of the adenoma.**
- 2 **Medical therapy (bromocriptine)**

→ D2 agonist

Bromocriptine

27w

Like

Reply



Mohammad Z. Abo Shaban

Lejan Aldofaat MRI or CT scan i don't remember with case scenario of a male falling from 3rd floor:

A- mention the radiological findings?

Hyperdense left subdural lesion with midline shift

B- name the neuroimage type (i guess)

C- approach to treatment in ICU

27w


Like

Reply

ABC / Ventralator / ICP monitor

MRI

CT



Mohammad Z. Abo Shaban

Lejan Aldofaat lumbosacral and thoracic MRI T2 lesion besides T9 vertebra (not the disc) with a scenario of a heavy smoker and a mass on chest x-ray:

A- what's the most probable diagnosis?

Metastatic tumor.

B- describe what you see? Osteolytic lesion
extradural compressing the spinal cord.

C- mention other differential diagnosis that cause myelopathy?


Meningioma i guess.

Disc herniation.

D- Lipoma - Neurofibroma

E- Schwannoma - Hemangioma

meningioma
Lipoma
Schwannoma
Neurofibroma
hemangioma
Disc herniation



Mohammad Z. Abo Shaban

Lejan Aldofaat patient open eyes on painful stimuli, incomprehensible words, flexes his left elbow on pain stimulus:

A- calculate the Glasgow coma scale? ~~3~~ 9

B- determine which type of head injury according to Glasgow coma scale? ~~Severe~~
~~moderate~~

C- management in ICU i guess..

D- - ABC approach / management his airway

27w

Like

Reply



Mohammad Z. Abo Shaban

Lejan Aldofaat a picture of a baby with macrocephaly and hydrocephalus:

A- what's the name of his eye's sign?

Sunset eyes.

B- mention three physical findings when examining the head?

- 1- dilated veins - upward gaze palsy
- 2- fontanelle bulge
- 3- Shin skin

C- the most common type of hydrocephalus in pediatrics? congenital aqueduct stenosis

D- mention two surgical treatments?

- 1- VP shunt
- 2- Endoscopic third ventricostomy

27w Like Reply



Fahed Zakout
Lejan Aldofaat

- 1- Ventricular catheter
- 2- Valve
- 3- peritoneal catheter
- 4- reservoir

Q1/ picture of VP shunt

Ventricles pretonical Shunt

- what is the name of this device
- what is the name of its component
- mention one indication (name of the disease) → hydrocephalus
- 3 complication →
 - 1- Bleeding
 - 2- infection
 - 3- Block

- 1- headache
- 2- ↓ cos
- 3- Meningism

Q2 /

Picture of subarachnoid hemorrhage

- what is the name of the image (angiogram and CT scan)
- what is the cause of this pathology (according to the picture) → aneurysm → AVM + Trauma
- management →
 - S + A, AVM → clipping + Endovascular coiling
 - T → conservative / BP monitoring

Hunt-hess
WFNS
Grossing system

Q3 / picture of meningioma

- describe the image And what you see in each picture → circular, hyperdense mass that locate intracranial, extramedullary
- management → Surgery excision craniotomy

Q4 (picture of lumbar canal stenosis)

- 1- weakness
- 2- saddle numbness
- 3- Pain

- what is the dermatome affected → cauda equina Syndrome
- what are the clinical sign you will see
- management → Decompression (Laminectomy)
- one more question

Q5 /

Picture of cervical canal herniation +

Hoffman → C8

- describe the picture

- what you will see in physical examination

- what questions you will ask to the patient

- what is the name of the test and how you

do this test *ex, make flexion on the middle finger of the examinee*
it will be +ve if thumb + index flexion

- what is the name of the surgery you will

do → *ACDF*

- complication of the surgery →

1. hoarse voice

2. Dysphagia

3. hematoma collection

1. hyperreflexia

2. hoffman +ve

3. clonus

4. spasticity

5. Babinski

1. weakness

2. paraesthesia

3. urinary incontinence

4. rigidity



دانة زياد المنزلي

Lejan Aldofaat

What is the name of the test?

Straight leg raise test

Is it passive or active? *active*

When we call it positive test?

when it evokes radiation of pain along the course of the Sciatic nerve, and below the knee between 30-70° of hip flexion

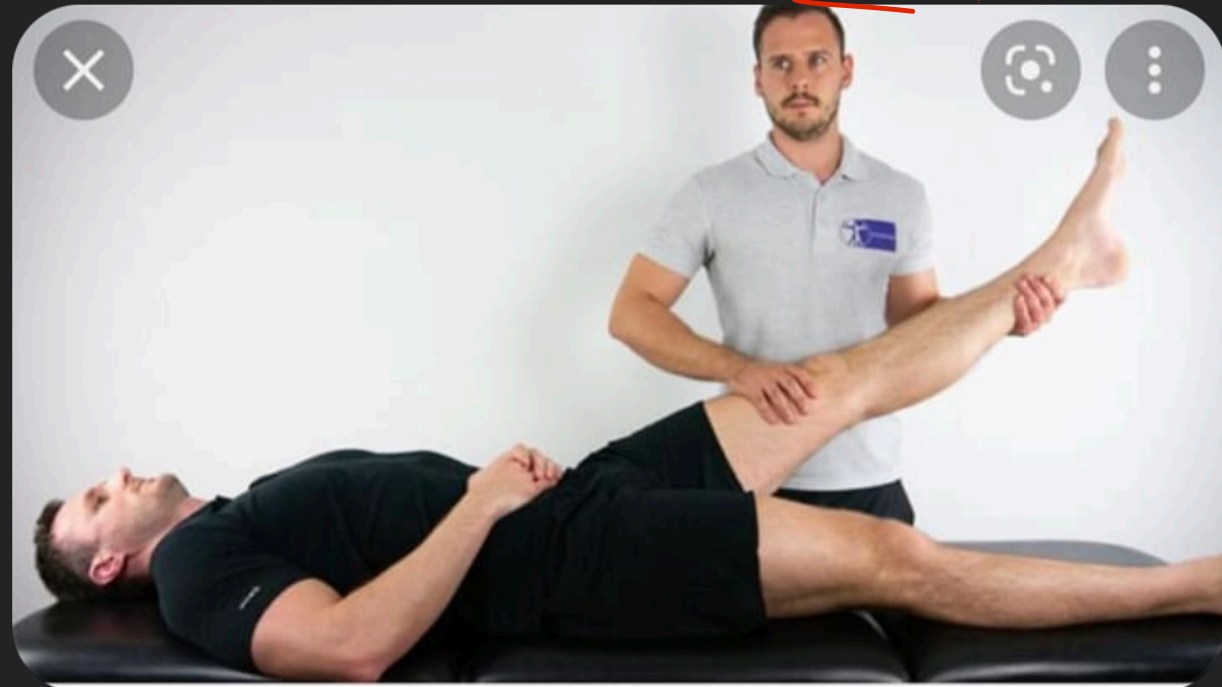If positive what is that mean?

*Sciatica
nerve root
compression*


What is the best image to do?

MR I

*[L5, S1]
prolapse
herniation*



23w Like Reply



دانة زياد المنزلي

Lejan Aldofaat

صورة لمريضة عندها cervical disc herniation

Describe the findings in the image

What is the name of the surgery? **ACDF**

name 2 complications -> **dysphagia**,

hoarseness

What you need to ask the patient?

What is the provocative sign that you may

find? **Pain in the back upon spurling's test**

هيك الجواب أعتقد

Bowstring

*Anterior cervical
discectomy and
fusion*

- 1- weakness*
- 2- Rigidity*
- 3- Parasthesia*
- 4- Urinary incontinence*

23w

Like

Reply



دانة زياد المنزلي

Lejan Aldofaat

Describe what you see? **dilated pupil**
directed outward and downward

What is the diagnosis? **Uncal herniation**


3rd CN palsy

How to treat the pt? **Craniotomy** (مش متأكدة)

What is the best image to do to confirm the diagnosis? **MRI**

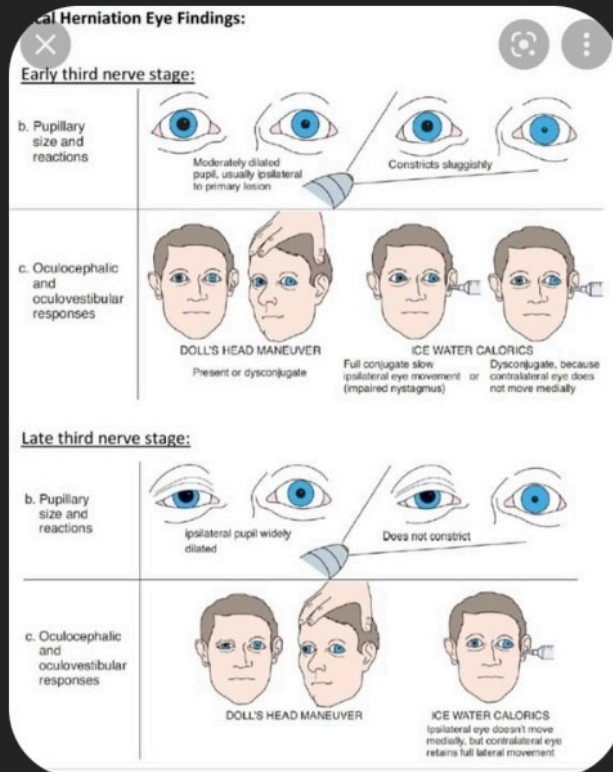
23w Like Reply

ACA
1. Cingulate
2. Uncal
3. Tonsillar
Brain stem
3CN
PCA




دانة زياد المنزلي

شيء مشابه قدر الإمكان



23w Like Reply



دانة زياد المنزلي

صورة ل parietal lobe tumor بال

Describe the findings in the image?

What is diagnosis? **Glioblastoma**

BM

How to treat the patient?

(w)

What is the possible grade? **High grade**

the patient will complain of? اشئ متل


هئك السؤال انه شو الاعراض الئ رح تطلع على

ICP

lobe المرضئ بناءً على وجود الورم بهاد ال

Symptoms

23w Like Reply



دانة زياد المنزلي

صورة لمريض كان راسه مشقوق والجمجمة

skull مبيئة وكانوا معطين معلومات عشان

نحسب ال **GCS**

Describe what you see? ✓

GCS? ✓

What is the classification according to


GCS? ✓

What is the management? **ABC**

What is the best image to do? **MRI**

23w Like Reply

Craniotomy
surgical exision
+
radiotherapy
Chemotherapy



دانة زياد المنزلي

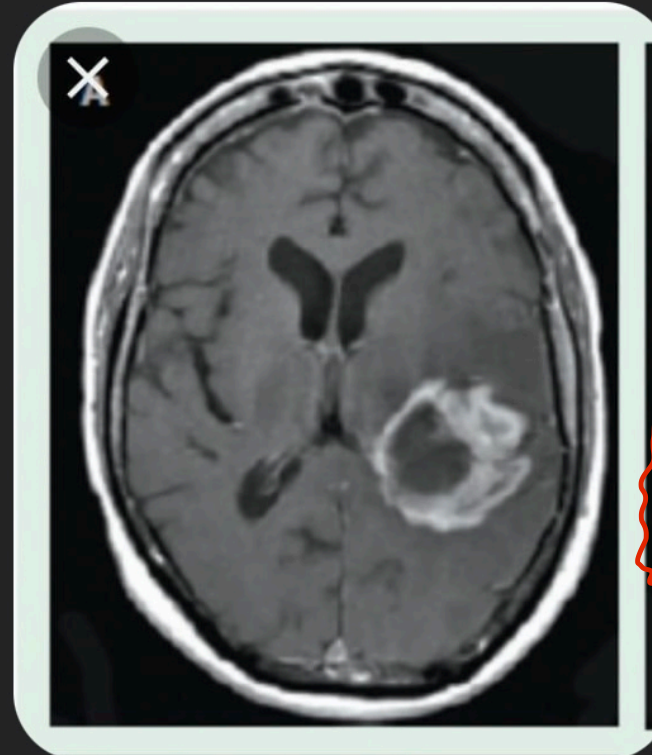بتشبه هي شوي

Heterogeneous يعني المهم فيها

enhancement و vasogenic edema وكانت

بالright parietal lobe ومعيطنا السؤال انه

المريض right handed



ring enhancement
vasogenic edema
Rt. Parietal lobe

hypointens mass

GBM
abscess
met

retracted hematoma

23w Like Reply



Sciatic L5/S1

peroneal n. injury

Mohammad Alsayed
Lejan Aldofaat

Q1) picture of right foot drop

1- Name the sign that the patient has ? Foot drop

1- Drag /slap test

2- Heel walk test

3- Manual muscle test

4- Step up and Down test

5- Jump test

2- Name four useful physical exam you can do for this patient ?

3- Which nerve root that is affected ?

L5

4- What is the best investigation ?

Lumbosacral spine MRI

Q2) patient comes to ER after RTA , open eyes on painful stimuli, incomprehensible words, flexes his left elbow on pain stimulus . CT scan shows Acute epidural hematoma

1- What is the diagnosis ? Acute epidural hematoma

2- Calculate the Glasgow coma scale? 3+4

3- Determine which type of head injury according to Glasgow coma scale? ~~Severe~~ head injury moderate

4- What is treatment ? Craniotomy to evacuate clot

1- Admission

2- ABCD

3- intubation

4- CT

← Mention also three measures you do in the ER: intubation and ABCs and then CT and admission ① ② ③ ④

①

Q3) This a few hours old newborn who was delivered by C/S , he was diagnosed antinatally to have this congenital anomaly (pic of spina bifida)

He is unable to move his lower limbs spontaneously

His head circumference is 40

السؤال ما كان بالصيغة هاي بالزبط لكن بنفس السيناريو

1- What is the diagnosis ?

Myelomeningocele / *meningiocele*

2- Mention 2 risk factors associated with this anomaly ? *Anticonvulsion*

Folic acid deficiency , family history

3- What will happen to neurological function after doing surgical repair to this baby? It will not improve but decrease risk

of infection

Q4) Patient has cervical disc herniation at level C5/C6 , and picture (A) sagittal MRI
Picture (B) Axial MRI .

1- Describe the image A and image B ?

A: T2 Sagittal MRI to cervicothoracic area

B: T2 axial MRI

And name the findings in each picture ?

A: Canal stenosis at C5/6

B: Disc herniation at C5/C6

2- What you need to ask the patient ?

3- Mention two provocative signs that you may find ? Pain in the back upon spurling's

test , Lhermitte's sign

4- What is the name of the surgery ?

Anterior cervical discectomy with fusion

name 2 complications ? dysphagia , ✓

hoarseness of voice ✓

Q5) picture of brain tumor in the left frontal or " frontoparietal "

1- describe the findings in the picture?

T2 Brain MRI that shows intraxial mass with heterogenous enhancement in the left frontoparietal lobe with midline shift

2- The patient will complain of ?

① Right sided weakness , personality and behavioural problems , Broca's aphasia ② ③

④ Symptoms of raised ICP especially in morning ✓

3- What is the diagnosis? Glioblastoma multiform

4- What is the treatment ? Surgical

resection of tumor and post op chemotherapy and radiotherapy

1- weakness
2- paraesthesia
3- rigidity
4- urinary incontinence

Glioblastoma multiform
GBM



Ahmad Adel

A 44-year-old patient presented with progressive lower back pain of 1 year duration radiating to his right lower limb. This is his picture (in the original picture, the mass was more white)

- .
- .
- .

1. Describe what you see in the picture.

A sagittal cut lumbosacral MRI T1 sequence
.. it shows a hyperintense, oval-shaped, intradural, extramedullary mass at the level of L5.

2. Mention other symptoms that this patient might complain of.

1
2
3
Right lower limb weakness & paraesthesia,
urinary incontinence, cauda equina
syndrome

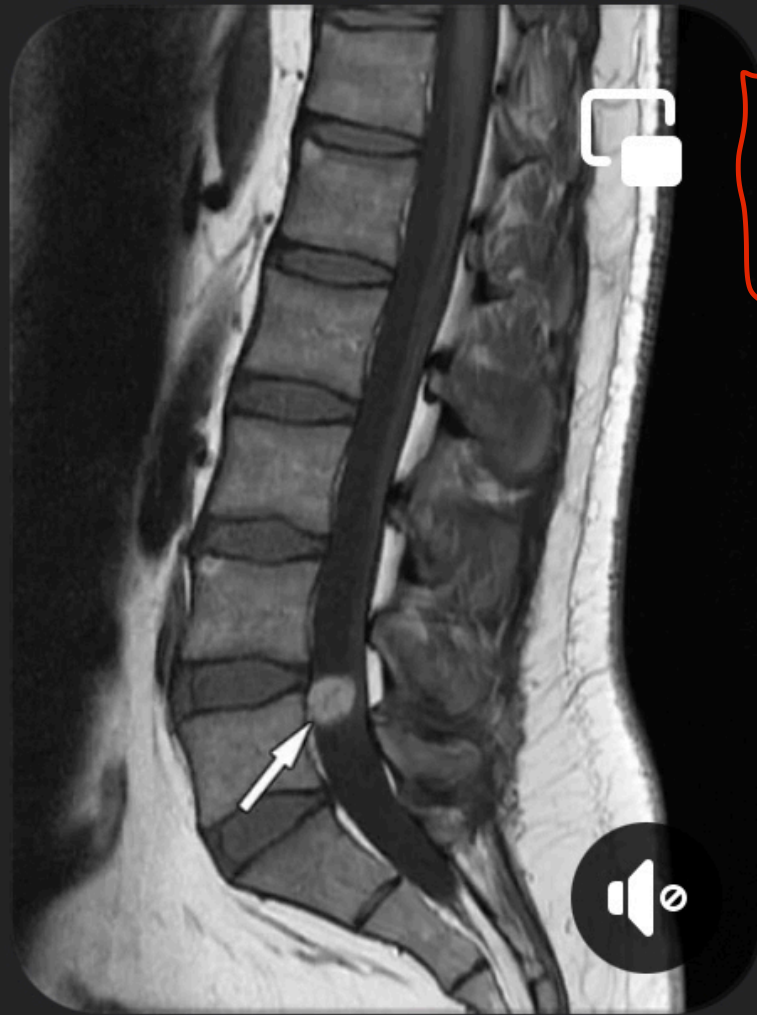
3. Give 2 possible diagnoses for this patient.

Meningioma, neurofibroma, schwannoma

4. How would you treat this patient?

Surgical excision via laminectomy


Laminectomy



Intradural
Extramedullary

- 1- meningioma
- 2- neurofibroma
- 3- Schwannoma

18w Like Reply



Hashem Mehdi

Lejan Aldofaat • Question 1

• A 65 year old pnt came to hospital after he fell from stairs, on examination , he was flexing his hands and produce inappropriate words and open eyes to pain: his ct scan is shown

A- Calculate his GCS? **8**

B- Mention 4 Acute complications of his condition? Hydrocephalus, herniation.....

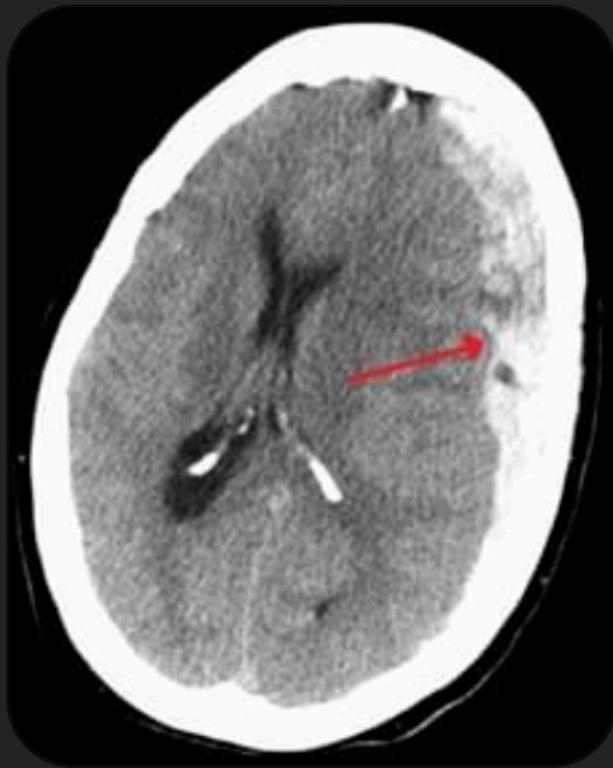C- Describe what you see on his CT scan.?

D- What is the best surgery for this pnt?

left side frontal
precentral, occipital
acute subdural
hematoma

Craniotomy and
evacuation

- 1- Hemorrhage
- 2- herniation
- 3- Parancymal clung
- 4 - ↑ ICP



16w Like Reply



Hashem Mehdi

Question 2

a 56 year old lady present with low back pain ,examination shows she has myelopathy. Question contained 2 pictures shown **babinski sign** picture and MRI

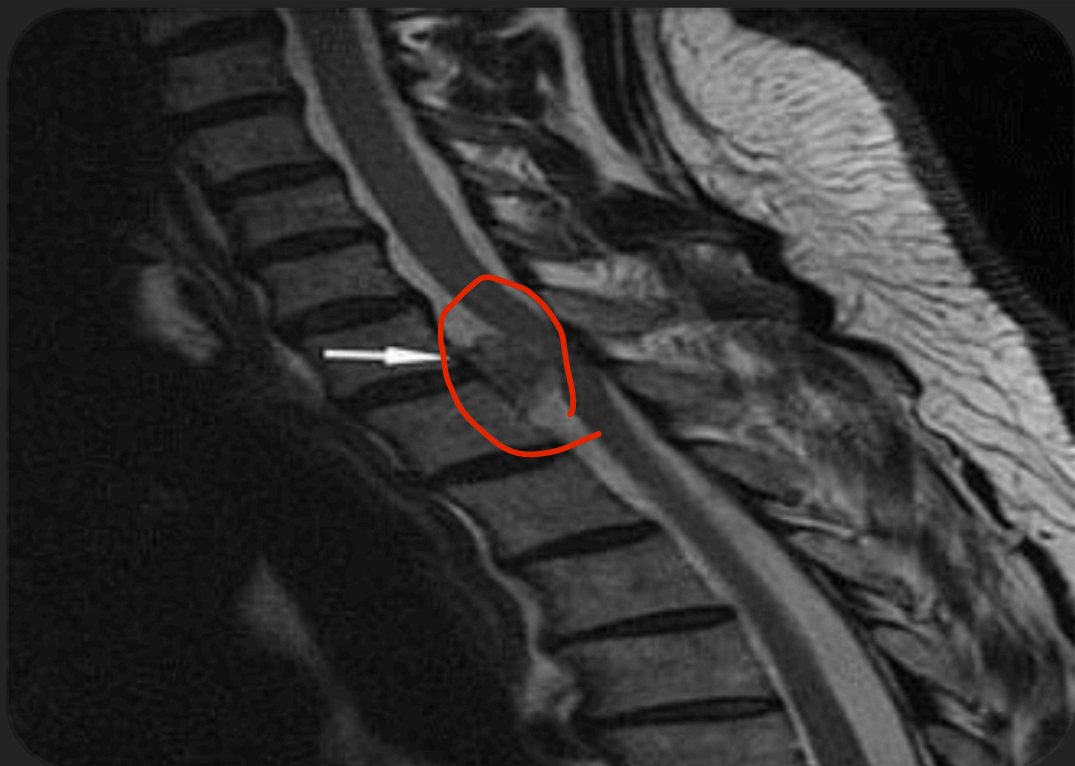A- Describe? **Intraspinal intradural extramedullary mass compressing spinal cord.**

B-Most likely diagnosis? **Meningioma.** ✓


C-Other 3 myelopathy signs of lower limb?

✓ **Hyperreflexia** , **clonus** , **spasticity** ✓

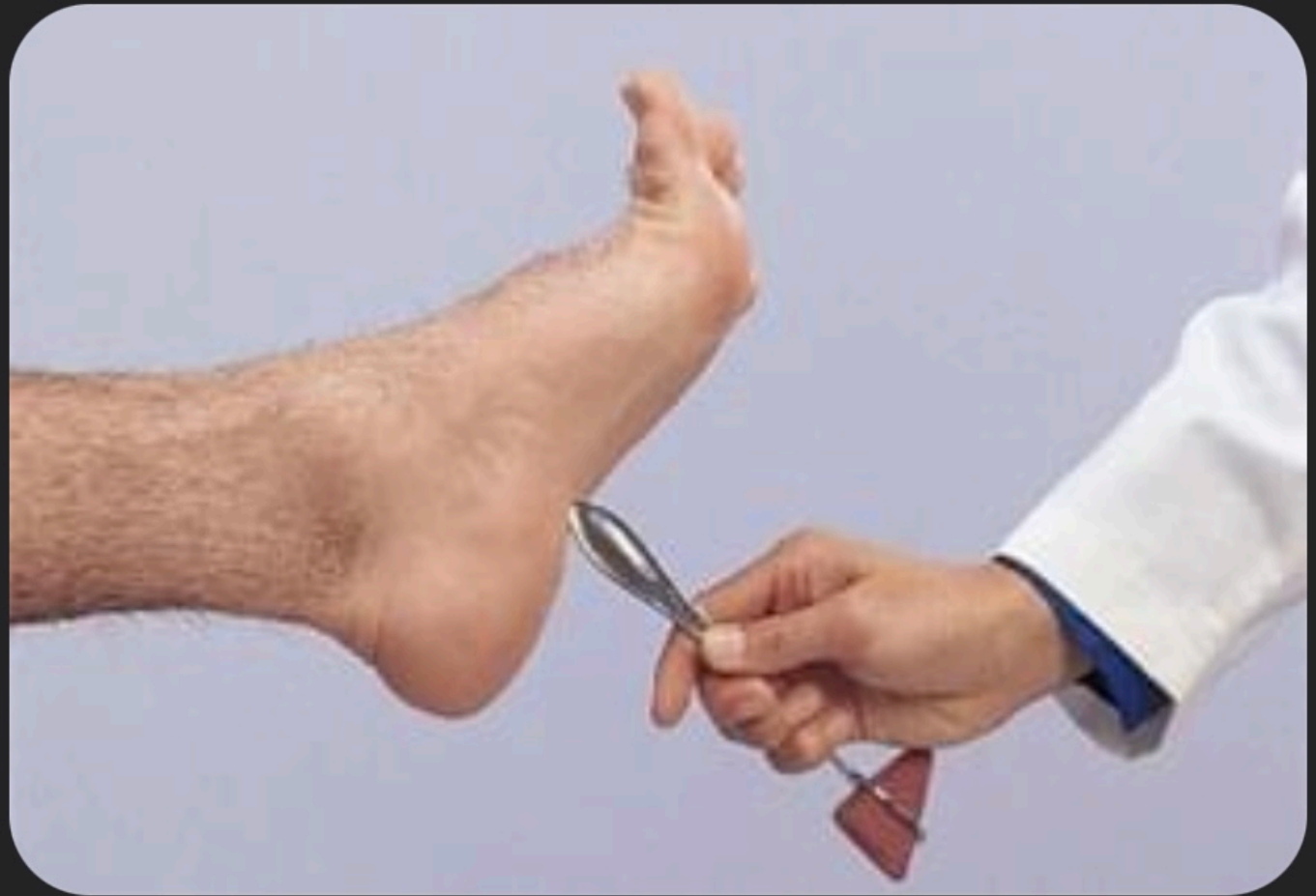D_ what does this sign indicate (babinski sign) ? **UMNL.**



16w Like Reply



Hashem Mehdi



16w Like Reply



Write a reply...



Hashem Mehdi

• Question 3:

A pnt came with low back pain. Five days later he had urinary incontinence. MRI picture were shown.

A-Describe MRI pic? **There was disk herniation in L5 S1**

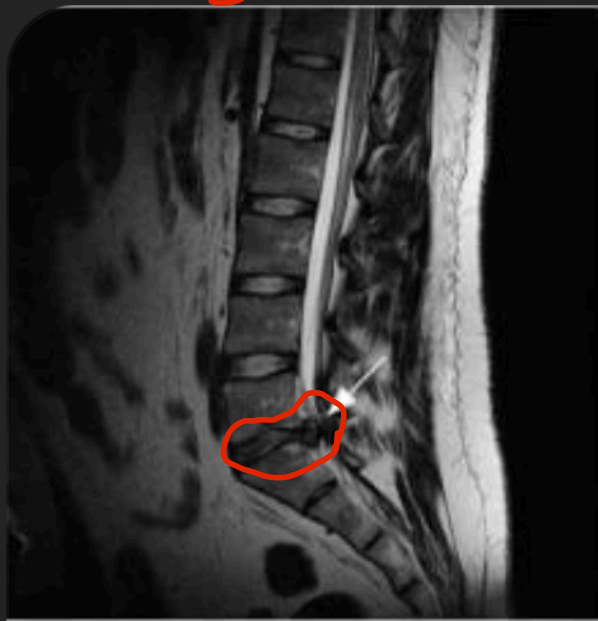B-mention 5 specific questions for his case? **Saddle anesthesia**, **impotence**, **weakness**, *Laminectomy*

C-What's the best surgical intervention? *Discectomy!*

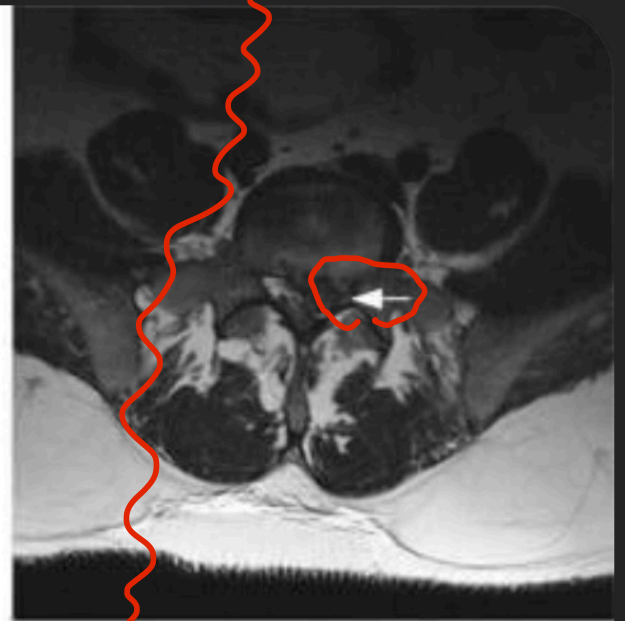
D- mention two signs seen on examination? *+ve straight leg raise test*, *jump test*

E- which dermatome, reflex are affected? *L5*

1- weakness
2- Parasthesia
3- urinary in
4- rigid
5- quad equina symet



A



B

16w Like Reply

ankle jerk ✓



Hashem Mehdi

Question 4:

A 68 year old pnt. has a history of lung cancer had a seizure recently , his MRI was shown (pnt is right handed).

A- Describe MRI findings ? There was mass irregular border in the frontoparietal area.

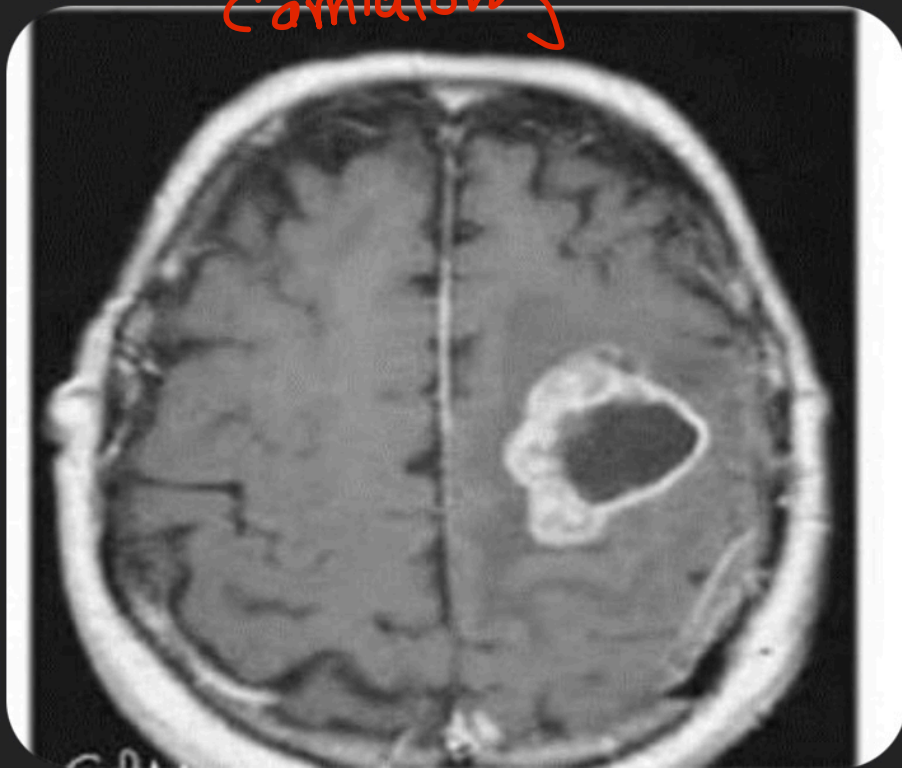
B- Diagnosis? brain metastasis

C-Other finding on p/e? agraphia, acalculia,.....

C- What are the lines of treatment for this pnt? Surgical excision + radiotherapy

Craniotomy

Chemotherapy




16w

Like

Reply

agrapia
acalculia



Hashem Mehdi

Question 5

hyperdense lesion
on the left
temporal area
circular in
shape
and there's
acute
subarachnoid
hematoma

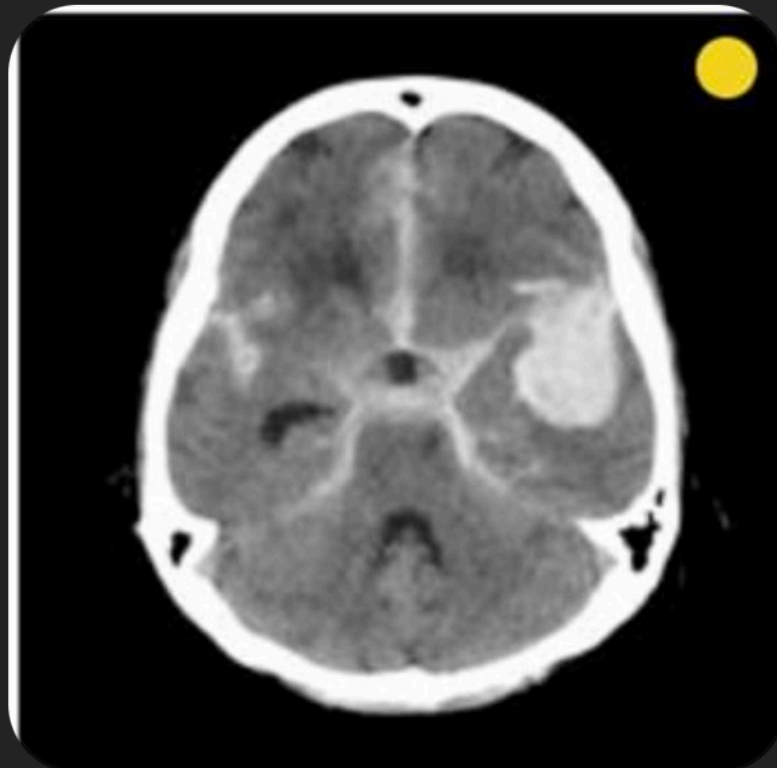A patient came to hospital due to severe headache. Her vitals were significant for BP of 180/110. Her labs show Na levels of 122.

A-Describe changes on CT?

B-What is the most common cause in her case? ^{RuDer} Aneurysm / AVM → Arteriovenous malformation

C-What is the next step in confirming diagnosis? Angiogram / LP

D-What are the explanations of her vitals and labs?



To maintain the cerebral perfusion pressure in normal range, by elevating the peripheral BP

16w Like Reply



Laith Alatawneh

Myelomeningocele and myelocele

no impfoumt+
but we do the surg
to prevent from
infection

1- name

2- which picture is Myelomeningocele

3 - prognosis after surgery? Same

4- associated with? Hydrocephalus

Percentage? 85% - 90%

5- which syndrome is this? Chiari Syndrome (2)

14w Like Reply



Laith Alatawneh

Basal skull fracture scenario causing facial nerve palsy?

when the basal fracture
cross the stилоmastoid for
cause injury to zth

1- whats pathology?

2- mention sign? Battle Sign

3 - tests to confirm that the leak is csf

4 - management?? → Surgical repair

+
conservative

14w Like Reply



Laith Alatawneh

Brain tumor /

1- describe finding in the image?

2- Most likely diagnoses?

3- signs and symptoms will happen?

4- treatment?

5-

14w Like Reply

1- B2-Transferrin

2- Surge

3- Test Salt

4- Halo Sign



Laith Alatawneh

Head trauma case with ct showing
epidural hemorrhage

1- findings in ct?

2- gcs? ✓

3 - type? ✓

4- management?

craniotomy + evacuation

14w Like Reply



Laith Alatawneh

Cervical disk i think

1- image findings?

cervical disc prolapse

2- signs and symptoms?

3 - management and complications?

Acdf... Infection? Hematoma?

infection
Dysphagia
hoarseness of voice

14w Like Reply

1- numbness
2- weakness
3- rigidity
4- Urin incontinence



Leen Hajeer

Q1) a case of RTA presented with the sign shown in the image. Open eyes⁴ spontaneously, not oriented to place⁴, obeys commands.⁶

1. What is the GCS? Explain. **14/15**
2. What is the type of head injury according to GCS? Why? **mild head injury**

3. What is the name of the sign shown? **Battle**

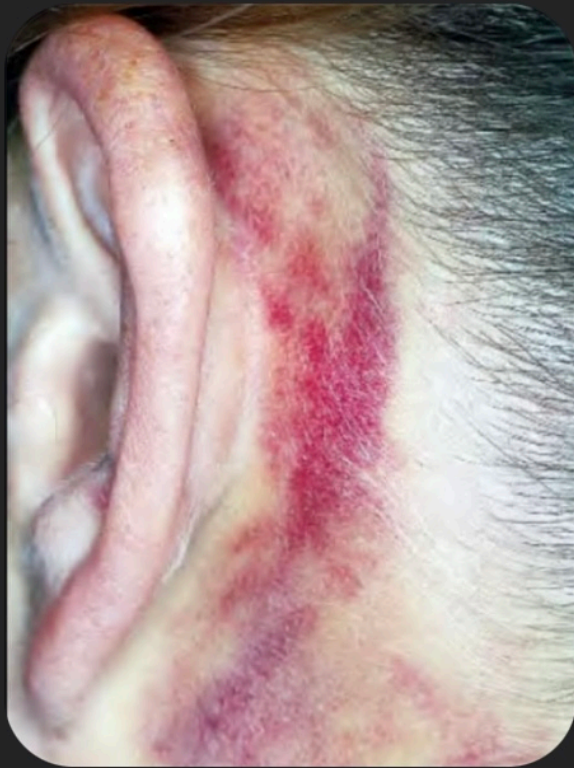4. Mention three other signs associated with basilar skull fractures

5. Mention two tests to differentiate CSF leak
1- B2 Transferrin 2- Surge

1- subconjunctival hemorrhage

2- Raccoon eye

3- Rhinorrhea



12w Like Reply



Leen Hajeer

Q2) Newborn with defect shown in the image. head circumference is 39, with paraparesis.

1. What is the diagnosis? *myelomeningocele*

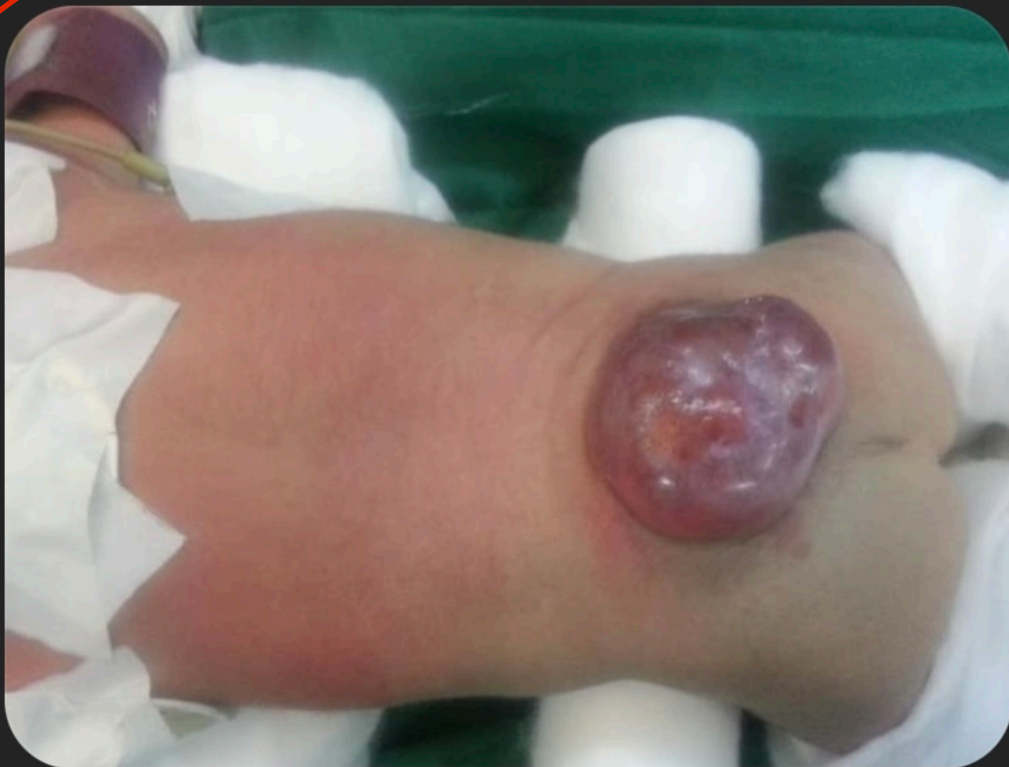2. Describe the head circumference and explain why

3. Mention two risk factors

4. What is the name of surgical procedure? mention 2 indications

herniation that make obstruction of CSF circulation that cause hydrocephalus

*1- folic acid
2- family hx
↓ surgical repair*



*1- To prevent infection
2- cosmetic*

12w Like Reply



Leen Hajeer

Q3) patient presented with severe back pain of 1 week duration radiating to the left leg.

1. Mention 5 specific questions you would ask the patient.

2. Mention two signs you expect to see in physical exam. → 1. Straight leg raise test
2. Heel + St

3. Describe what you see in image a and b. ✓

4. What is the dermatome affected? (L5)

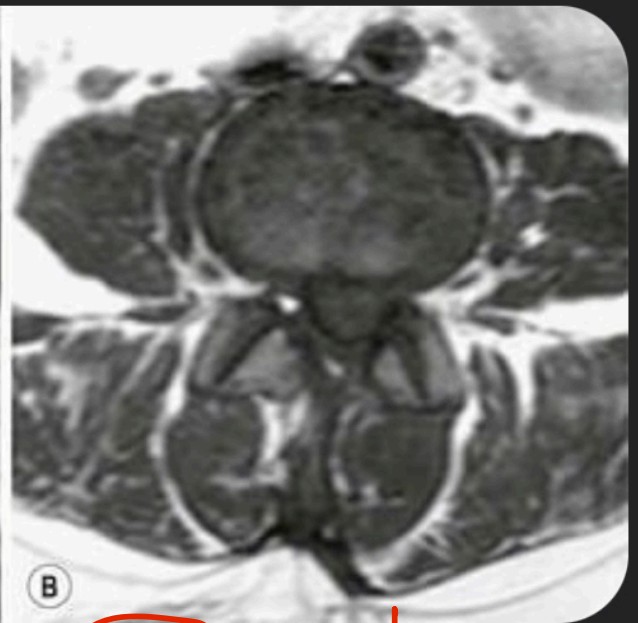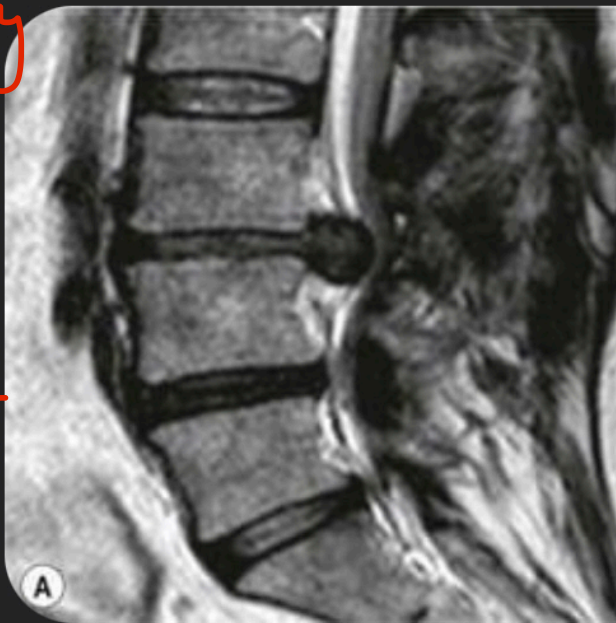
5. What is the management?

- 1- weakness
- 2- Rigidity ←
- 3- paraesthesia
- 4- Urin incont ML
- 5 - Cauda equina Syndrome

L4/L5 ←

Discectomy +
Laminectomy

Prokaps
C1



12w Like Reply

(T2)

↓
herniation

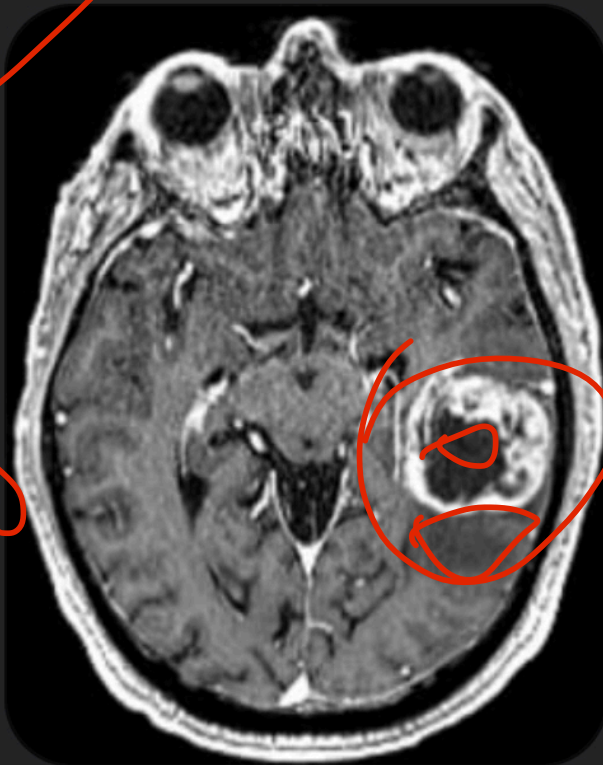


Leen Hajeer

Q4) Patient presented with headache and seizures, he is smoker, diagnosed with lung cancer 4 years ago.

1. What is the most likely diagnosis? *metastasis*
2. Describe what you see. ✓
3. Mention neurologic abnormalities the patient may have according to his lesion ✓
4. Mention the lines of management ✓

*agraphy
acalculia
Aphasia*



*Surgical
excision
craniotomy
with
chemotherapy
radiation*

*MRI
T1 with contrast*

12w Like Reply



Leen Hajeer

Q5) female patient presented with headache and galactorrhea. MRI is shown

1. What is the diagnosis? *Prolactinoma*

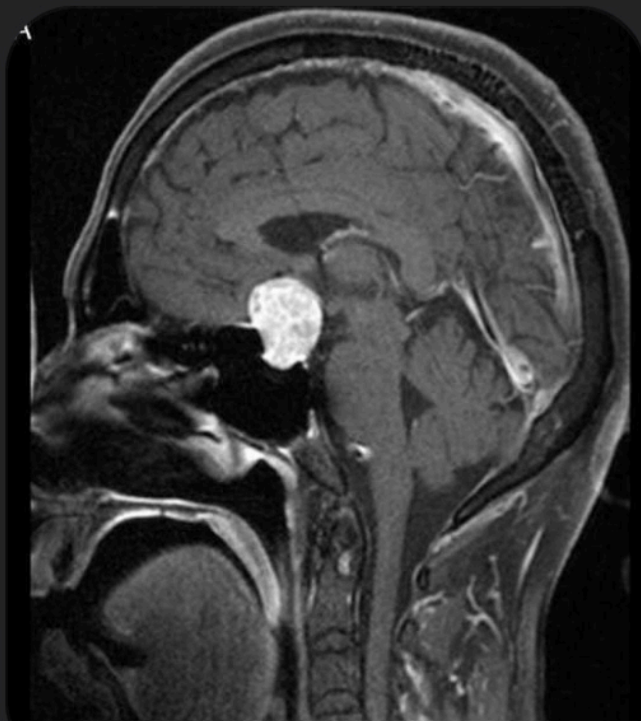2. What is visual defect you expect to be present in this patient? Why? *Bi-temporal hemianopia*

3. Mention laboratory investigations you would order for diagnosis. *Prolactine*

4. What is the first line treatment? *Bromocriptine*

5. What is the surgical management approach? *Trans sphenoid*

bc the mass compress on the optic chiasm



crinotomy

12w

Like

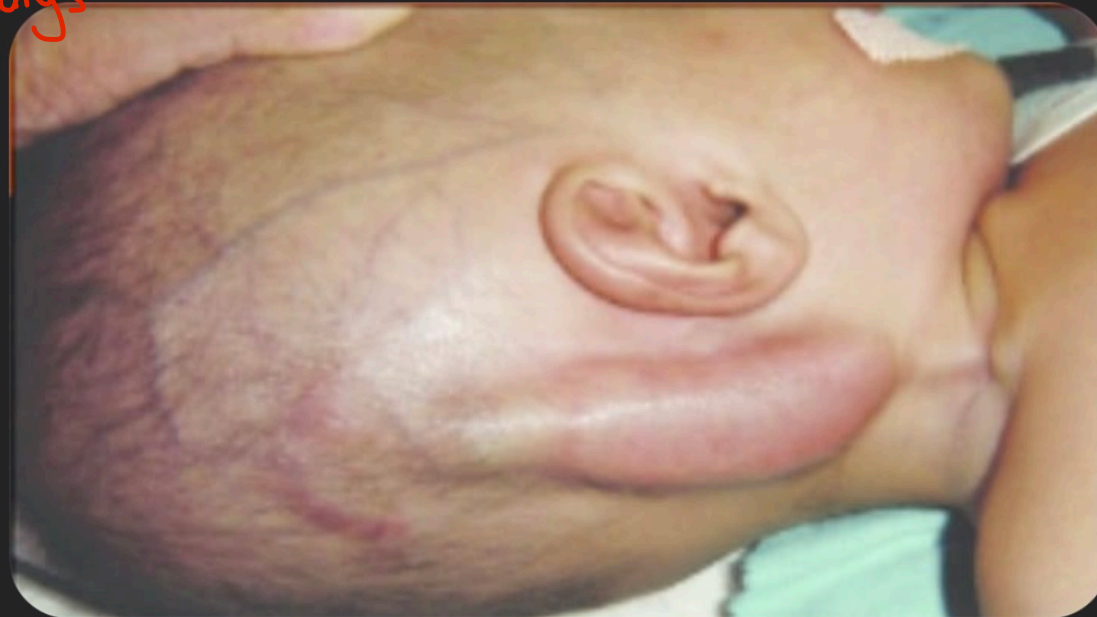Reply



Mona AlMoubarak

infant with head circumflex ~40 i think , had vp shunt before and now this is the presentation:

1. sunset appearance
 2. shiny skin
 3. dilated superficial vein
 4. ↑ circumference of the head
 5. macrocephaly
- 1) dx? obstructed VP shunt in hydrocephalus
 - 2) investigation? MRI, LP
 - 3) mention 5 signs of hydrocephalus
 - 4) most common cause of hydrocephalus in peds? Congenital aqueduct stenosis



10w Like Reply



Ghina Ali Alsawad

Lejan Aldofaat Q1.

A case of a patient with hearing loss

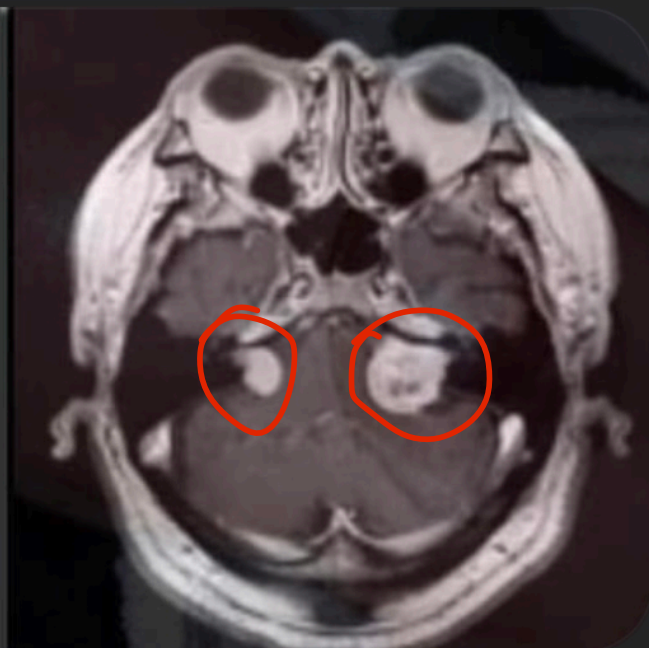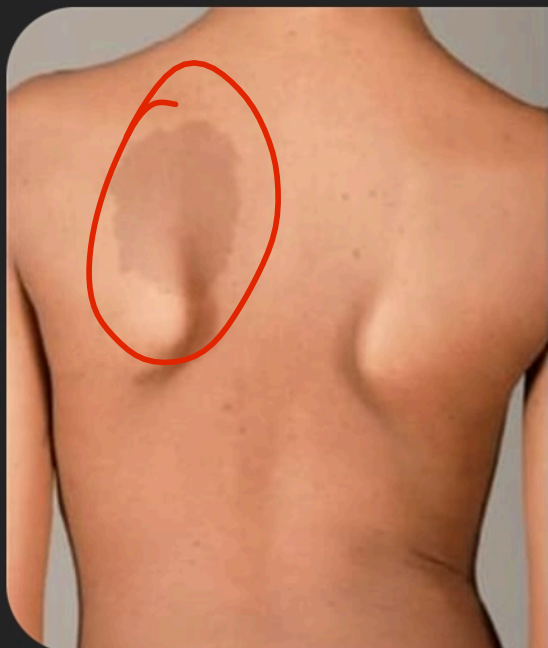1. Radiological image findings? **Bilateral temporal hypodense lesions and central hypodense lesion** (not sure)

2. Type of lesion? **Bilateral vestibular schwannomas**

3. Name of the sign? **Cafe au lait spot**

4. Name of the syndrome? **Neurofibromatosis 2**

5. Which cranial nerves should be tested? **CN8**



8w Like Reply



Ghina Ali Alsawad

Lejan Aldofaat Q2.

Newborn with lesion in his back

1. Diagnosis? **Myelomeningocele**

2. Which one represents the patient's findings A or B? **B** ✓

3. What is this associated with + percent?

Arnold chiari malformations 2
(Hydrocephalus), 85-90% association

4. The name of the syndrome?

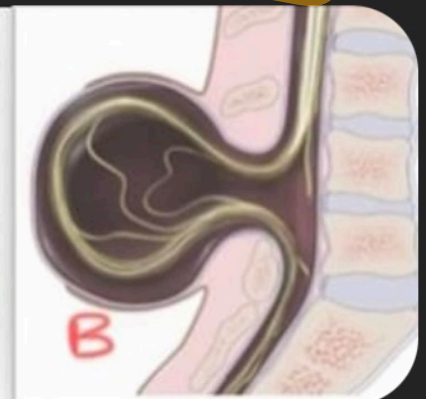
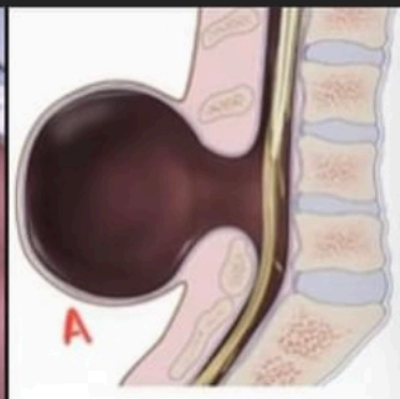
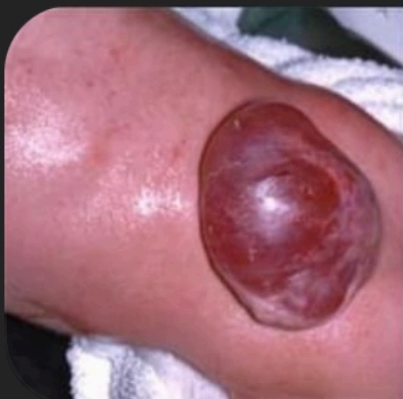Arnold chiari syndrome OR **chiari malformations type 2**

5. What can you do to help this lady while pregnant?

Intrauterine Myelomeningocele surgical repair ✓

6. What advice would you give to avoid this problem in the future?

Planned pregnancy with folic acid supplementation 3mo before pregnancy. ✓



8w

Like

Reply



Ghina Ali Alsawad

Lejan Aldofaat Q3. Old patient with frequent falls due to paralysis, with heart disease on aspirin, presented with headache.

1. Describe image findings? **Bilateral** (mention lobes it encompasses) **hypodense** **subdural lesion**

2. Diagnosis? **Chronic bilateral subdural hemorrhage**

3. Risks? **Drugs** (antiplatelets/ anticoagulants)

Liver disorder

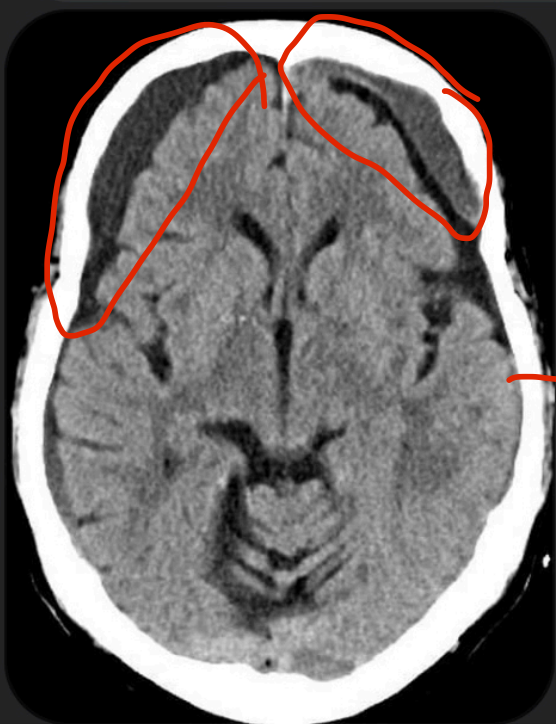
Falls (paralysis), **old age**

4. What other symptoms the patient may suffer from besides mentioned?

- 1** **Confusion**, **cognitive deficits** (impaired memory), **hemiparesis**, **seizures**,
- 5** **papilledema** (blurry vision)

5. Treatment? ~~Craniotomy~~ and **evacuation**

Burr hole



MRI T1

- 1- cognitive deficits*
- 2- confusion*
- 3- papilledema*
- 4- seizures*
- 5- hemiparesis*

Ghina Ali Alsawad

Lejan Aldofaat Q4. lady with neck pain radiating to the right upper limb, as well as difficulty walking that started a year ago.

1. Describe what you see in the picture.

A sagittal cervical spine MRI (T2) Showing C5-C6 disc prolapse

2. What are 4 questions that you should ask this specific patient?

Any Sensory, weakness, gait, urinary incontinence, muscle rigidity changes?

3. Mention 4 signs of myelopathy?

-Positive Hoffmann's test

-Clonus

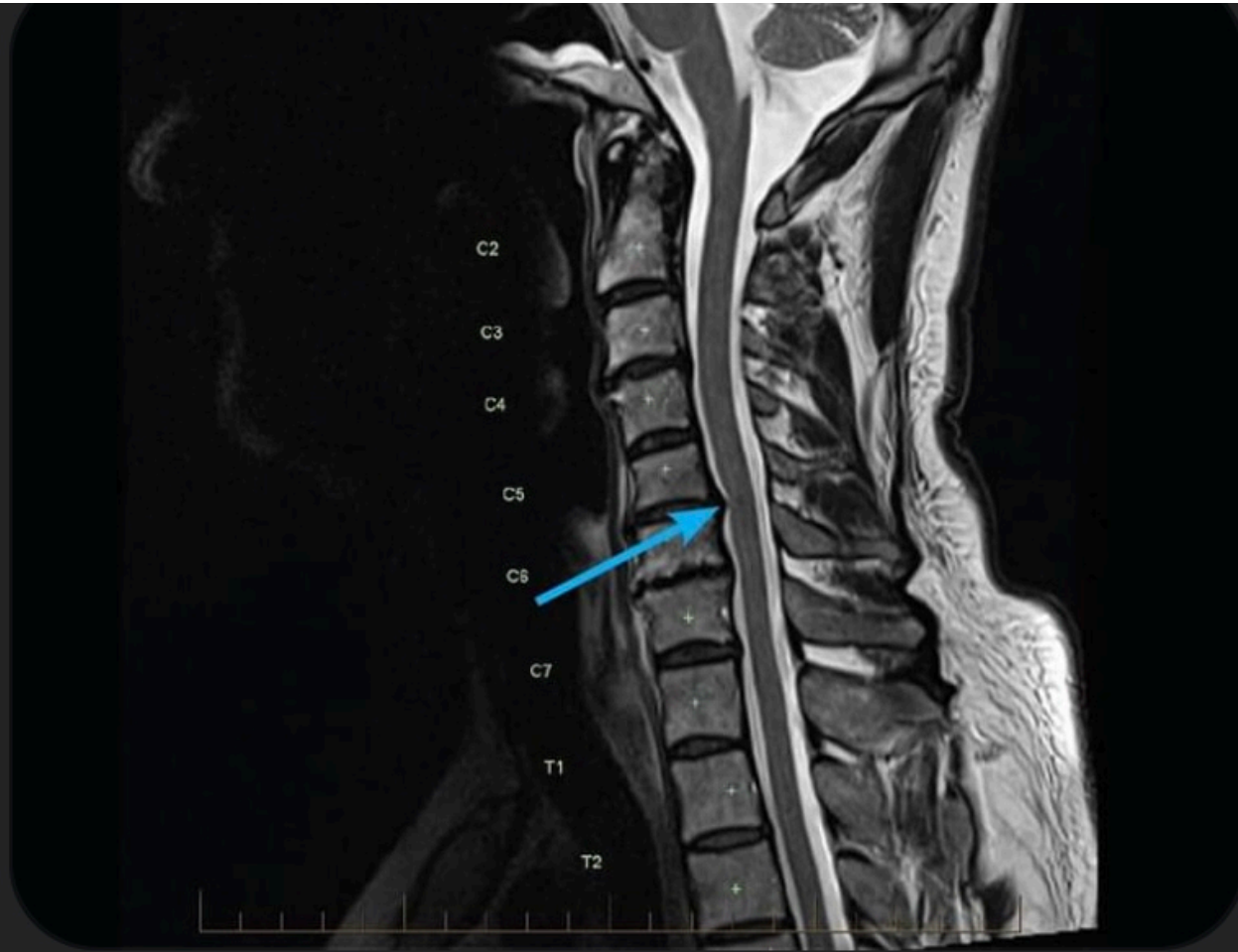
-Hyperreflexia

-Hypertonia (Spasticity)

4. At what level is the upper motor neuron affected in this patient? Below C6

5. Name the surgical approach used to treat this patient & mention 2 complications.

ACDF, hoarseness & dysphagia



8w Like Reply

Ghina Ali Alsawad

Lejan Aldofaat Q5. A patient with severe headache

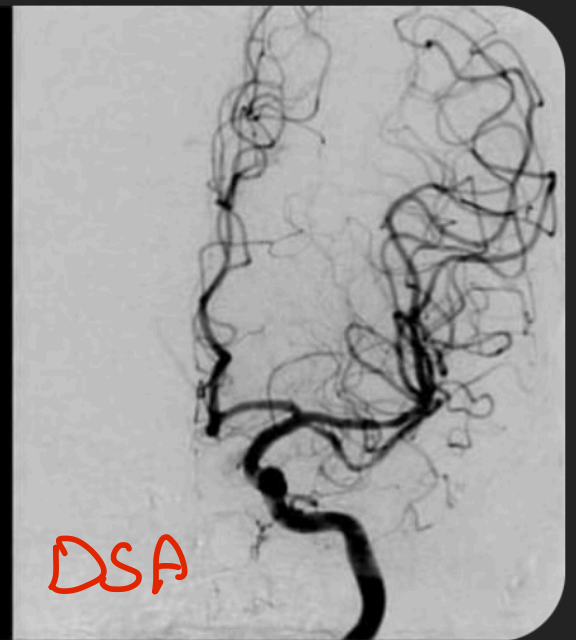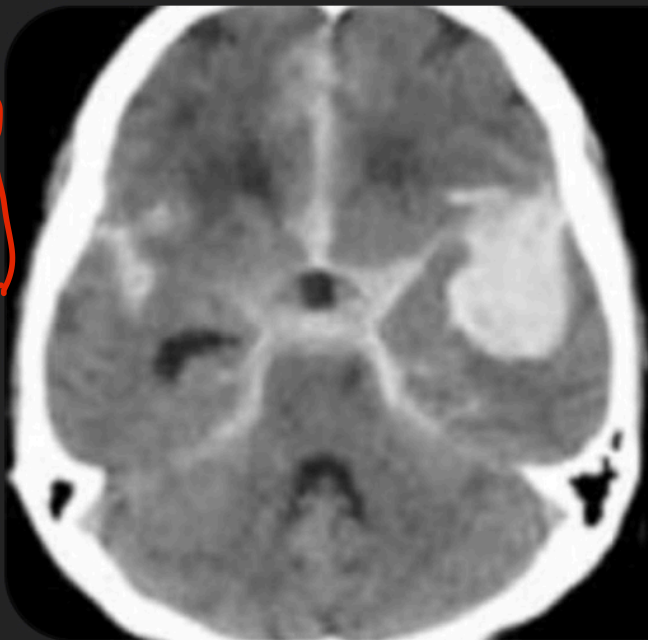1. Findings on CT? **Hyperdense subarachnoid hemorrhage in middle cerebral artery area**

2. Imaging modality? **Digital subtraction angiography (DSA)**

3. cause? **Ruptured aneurysm**

4. Treatment? **Clipping and coiling**

*hyperdense
Subarachnoid
hemorrhage
in the MMA*



DSA

8w Like Reply



Hala Alqudah
Lejan Aldofaat

1) What is this test? What does it indicate?

"Spurling's" Lhermitte / cervical cord compression

Which nerve root affected? C6 ✓

What dermatome affected? What myotome?

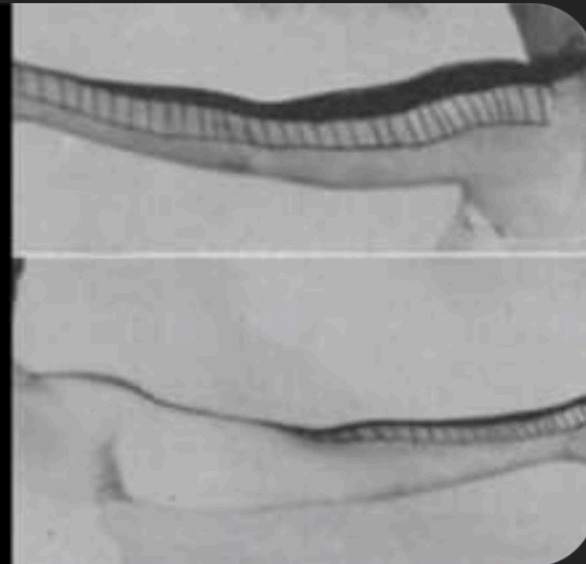
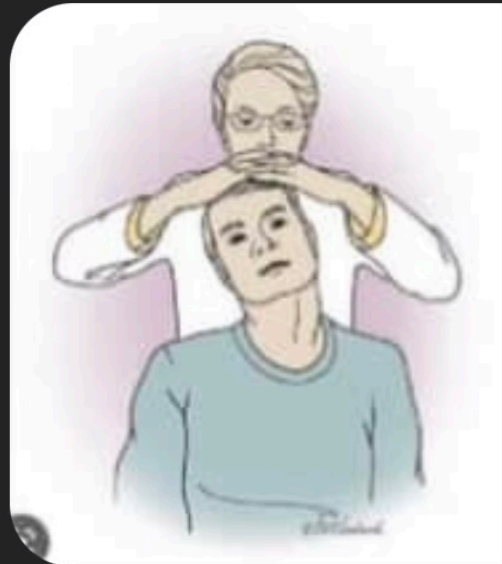
Bacovodilus →

C6

Reflex affected? Biceps ✓

Surgery? ACDF

Spurling's



6w Like Reply



Hala Alqudah

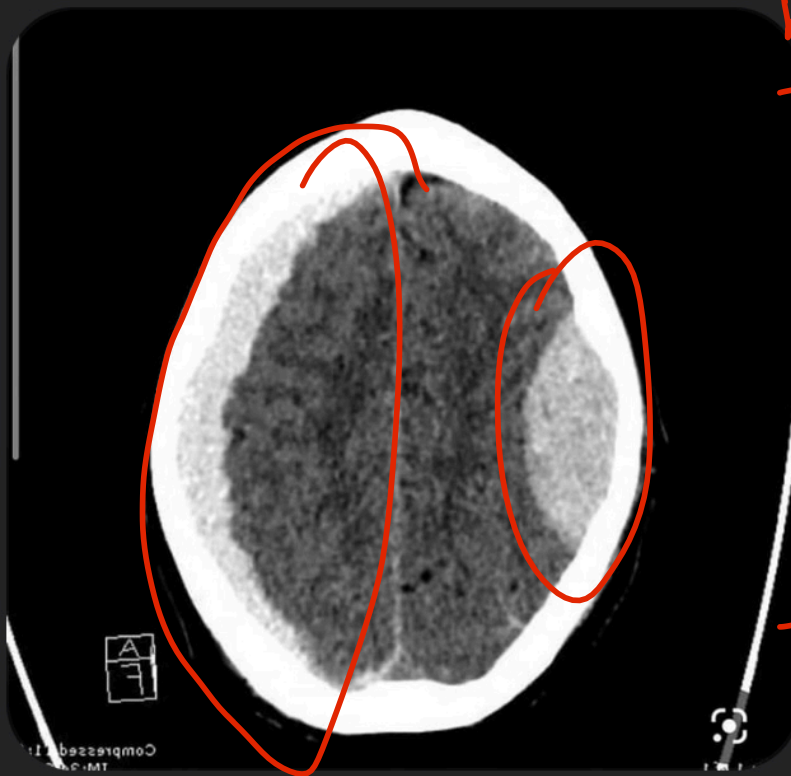
Lejan Aldofaat

2) The patient opens his eyes on painful stimulus, inappropriate words², extend both hands on painful stimulus (the CT was showing similar findings in this CT +midline shift)³

-GCS E2V3M2 : 7/15

-Type of head injury depending on GCS, why? **Severe head injury**

-Describe the CT findings *there's in the Rt. side*



hyperdense lesion that extend from frontal - parital - occipital that is crescent in shape that suggest acut subdural hematoma

in the Lt. side there's oval in shape hyperdense that's in priatal lobe that suggest epidural hematoma

6w Like Reply

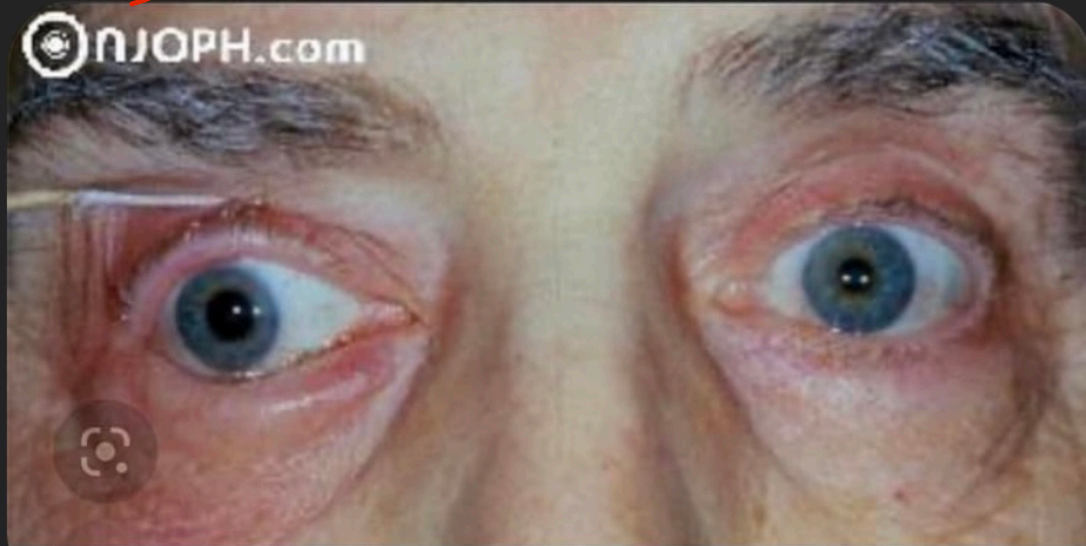

Hala Alqudah

+ with the same question they asked:
Describe what you see+What is the
cause of the underlying condition, o
explain why it happened?

injury

3rd nerve



6w Like Reply



Write a reply...

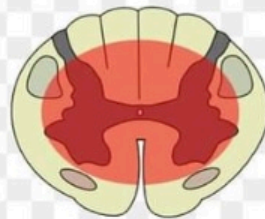


Hala Alqudah

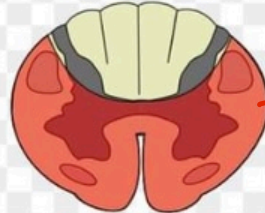
Lejan Aldofaat 3) Name the syndromes+ symptoms of each

Incomplete lesions of the spinal cord

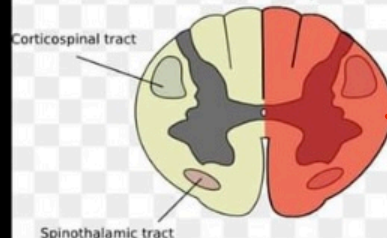
Central Cord Syndrome



Anterior Cord Syndrome



Brown-Séquard Syndrome



- 1- Bilateral weakness [ARM > Leg]
- 2- Sensory deficit mostly Pain, Temp
- 3- cap like distribution

* Paralysis → Bilateral, with loss of Pain and Temp senses, below the level of lesion

spared → dorsal column [proprioception, Touch, vibration]

- 1- ipsilateral motor loss, deep touch, light touch, position, vibration loss
- 2- contralateral temp, pain, loss

6w

Like

Reply



Hala Alqudah

Lejan Aldofaat 4) Female patientcame to the ER with nuchal rigidity, fully conscious, Na:122, Bp: 180/sth, PR 45/min....

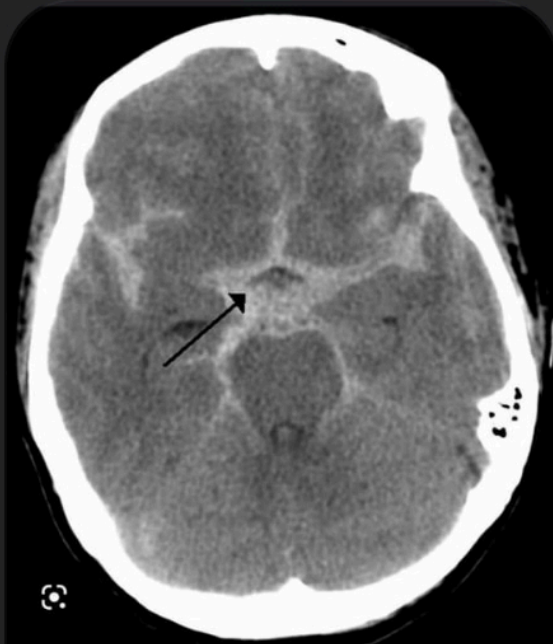Describe the findings? ✓

The cause? *Rupture Aneurysm*

Grade? (They meant **Fisher grade depending on history**) **grade 2**

Explain the vital signs and the

Hyponatremia? *inappropriate secretion of antidiuretic hormone*



Subarachnoid hemorrhage - Wikipedia

Visit

6w

Like

Reply



Hala Alqudah

Lejan Aldofaat

5) What visual findings associated, Why?

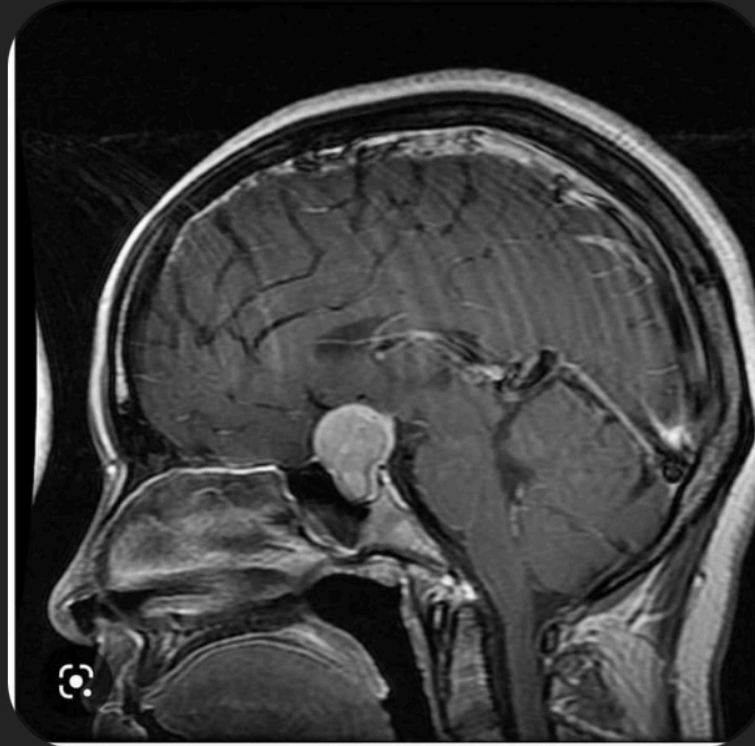Give 2 Differential diagnosis ?

What specific lab tests needed?

Surgical approach? → ACDf

functional
non functional
prolactin

→ Bitemporal
hemianopia
→ bc, the tumor is
compression on the
optic chiasm



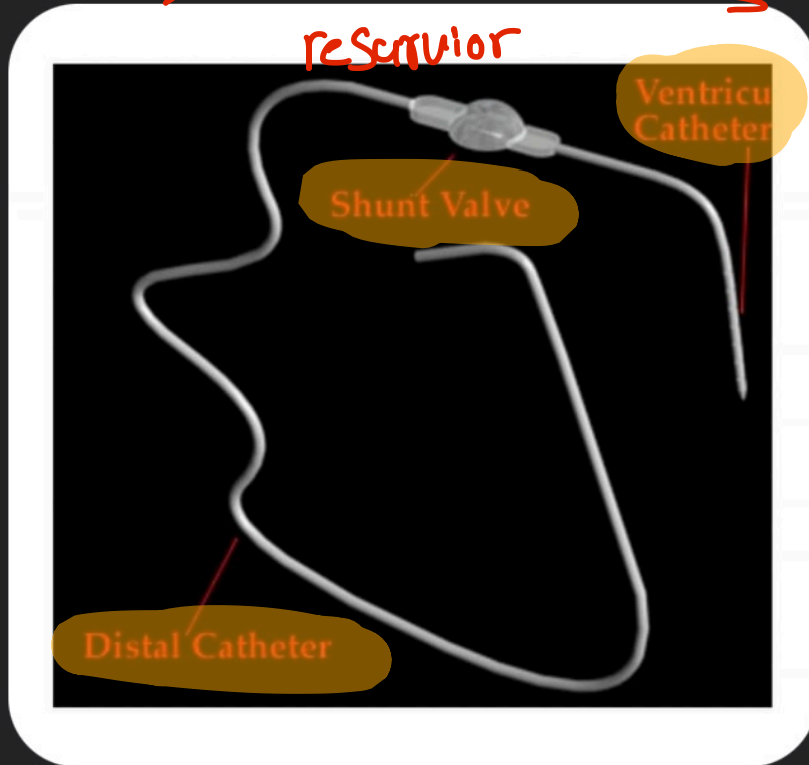
6w Like Reply



Batool Bassam

what is the name of the device (VP shunt), name each structure, complications (malfunctioning, intestinal obstruction, infections), other uses for the valve (CSF sampling, checking for obstruction)

bleeding +



4w Like Reply



Batool Bassam

Case of cervical canal stenosis

Describe the image & findings, 4 questions you have to ask about (gait, urinary symptoms, numbness), 4 signs of myelopathy (hyperreflexia, hoffman's, clonus, hypertonia, so basically UMNL signs), what nerve root it will compress, treatment (ACDF) complications of the surgery (dysphagia, hoarseness)

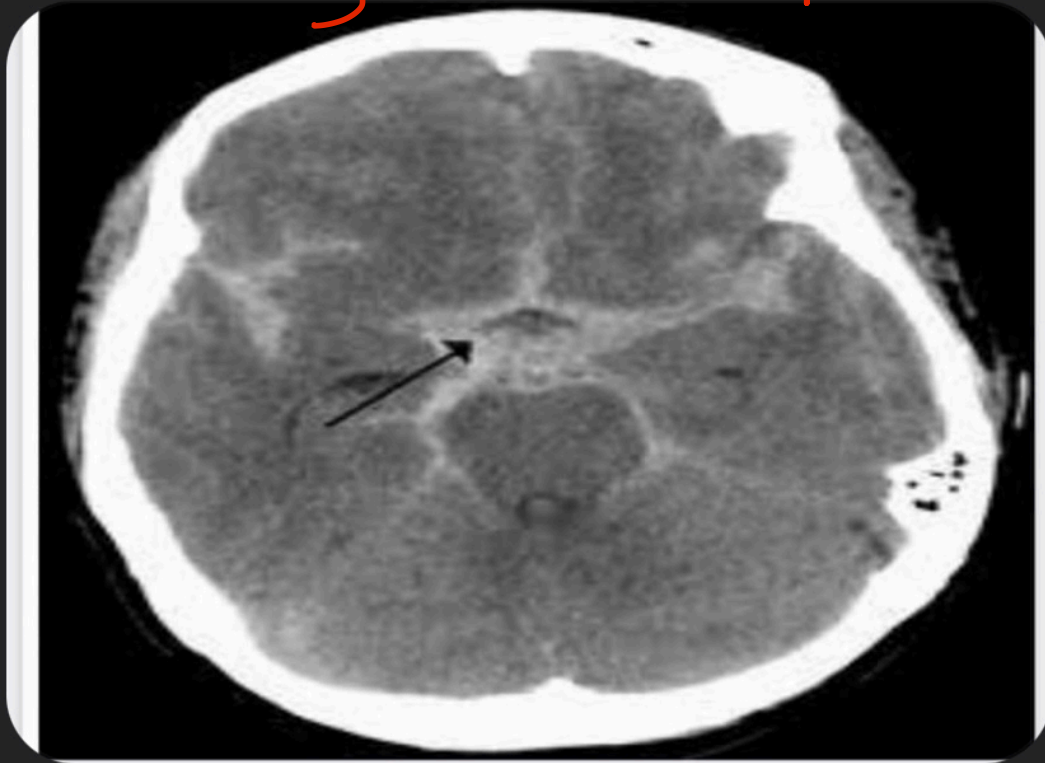4w Like Reply



Batool Bassam

Case of **SAH after trauma**

describe what you see ? , question about GCS , what is the classification ? 3 basic lines of management , (**admission , ABCDE , treating increase in ICP , Intubation**)



4w Like Reply



Batool Bassam

8years old child complaining of headache , case of **extra-axial tumor** (the dr said that **medulloblastoma & pilocytic astrocytomas** will be considered correct) , what questions you should ask about the "headache"? (**If it was associated with vomiting , occurs in the morning**) , if the pt suddenly deteriorates what is the next step ? **Brain ct to check for hemorrhage**

4w Like Reply



Batool Bassam

3 PM Fri 13 Jan

neurosurgery Mini-OSCE muta

Miniosce dr mahomoud

neurosurgery Mini-OSCE muta

GCS to patient One of his eyes fixed dilated not response to lightThe
other eye response to pain The patient was decerebrate and made
incomprehensive words

2

2

7/15

3

7/15

185 of 423

4w

Like

Reply



Ahmad Adel

This is the picture of a patient who fell from the third floor & suffered the following lesion.

- .
- .
- .

1. What is the name of this appearance?

Raccoon eye appearance ✓

2. What is the cause of this appearance?

Basal skull fracture ✓

3. Mention 3 other signs you expect to find in this patient?

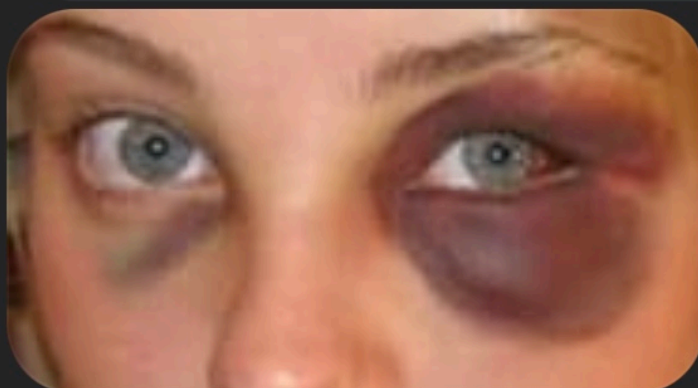
✓ Rhinorrhea, ✓ subconjunctival hemorrhage, ✓ cranial nerve deficit ✓

4. What is the best diagnostic tool for this patient?

CT scan ✓

5. What are possible complications in this patient?

✓ Epilepsy, ✓ hematomas, ✓ CSF leak, ✓ infections..



Amirad Adel

A ~40-year-old patient suffered a head injury & fell unconscious. In the ER, his vital signs were stable.

The patient doesn't open his eyes in response to pain, he responds with incomprehensible sounds² when you talk to him, & he flexes his elbow in response to pain. ⁴

This is his CT scan.

- .
- .
- .

1. Describe what you see in the pictures.

Axial (left) & coronal (right) brain CT .. they show crescent-shaped, subdural hyperdensity on the left side with midline shift to the right side.

2. What is the Glasgow coma score for this patient?

E1V2M3 (GCS) (7)

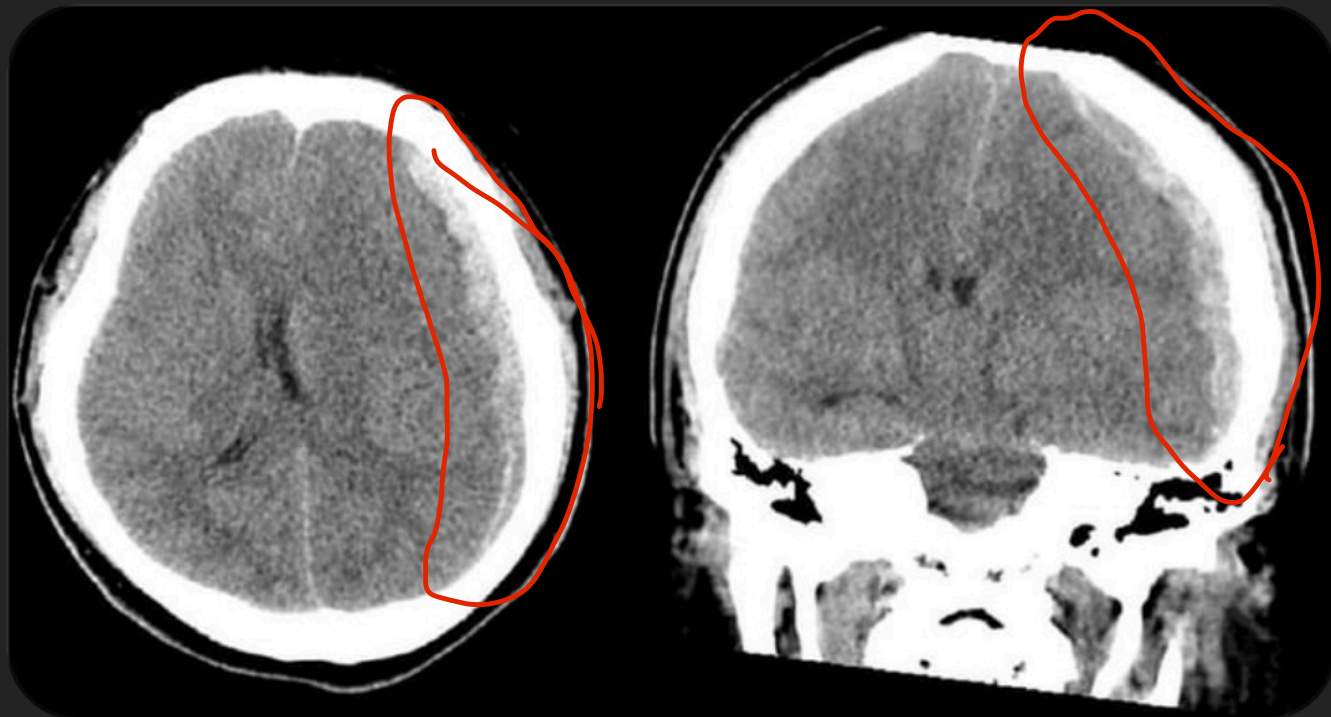
3. What is the type of injury depending on the GCS?

Severe brain injury

4. How would you manage this patient in the ER & after admission?

-In the ER: ABCDE then craniectomy & evacuate the hematoma

-After admission: monitor in the ICU & give IV fluids



18w Like Reply



Ahmad Adel

A 40-year-old lady presented with neck pain radiating to the right upper limb, as well as difficulty walking that started 1 year ago. This is her picture.

- .
- .
- .

1. Describe what you see in the picture.

A sagittal cut cervical spine MRI T2 sequence .. it shows C5-C6 disc prolapse

2. What are 4 questions that you should ask this specific patient?

-Does she have right upper limb weakness?

-Does she have right upper limb paraesthesia?

-Does she have urine incontinence?

-Does she have any muscle rigidity?

3. Mention 4 signs of myelopathy?

- 1 -Positive Hoffmann's test
- 2 -Clonus
- 3 -Hyperreflexia
- 4 -Spasticity

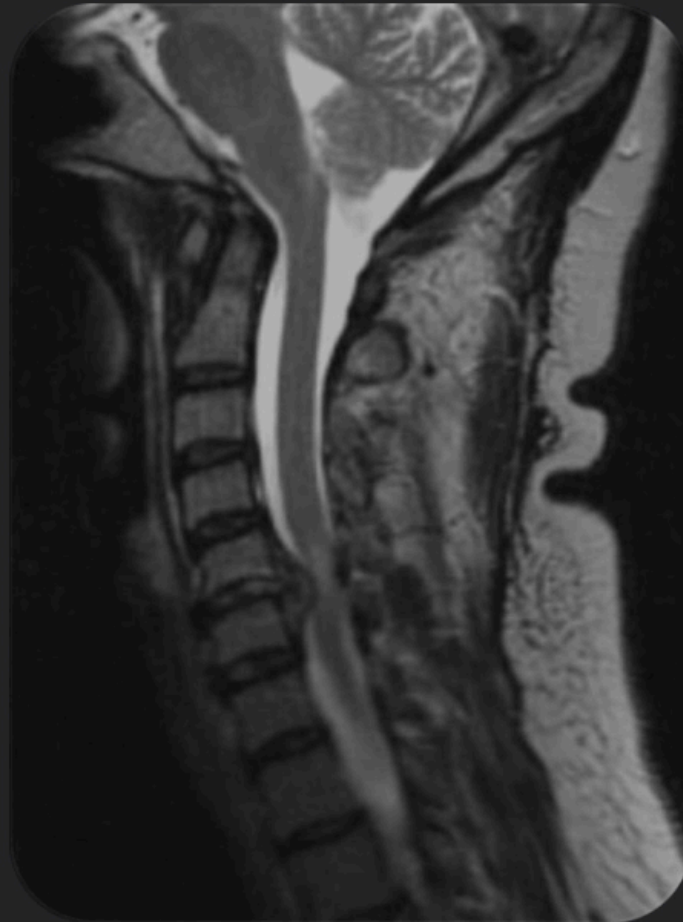4. At what level is the upper motor neuron affected in this patient?

Below C6

anterior cervical
discectomy with
fusion

5. Name the surgical approach used to treat this patient & mention 2 complications.

ACDF .. hoarseness & dysphagia



18w Like Reply



Ahmad Adel

A 2-year-old patient is brought by his parents to the hospital as a case of hydrocephalus. This is his picture.

- .
- .
- .

1. What's the name of this sign?

Sunset sign ✓

2. Mention 4 other findings you'll find when examining the head of the patient.

- Tense/bulged fontanelle ✓
- Increased head circumference ✓
- Tense, shiny skin ✓
- Distended scalp veins ✓

3. What's the most common cause of hydrocephalus in this patient?

Cerebral aqueduct stenosis

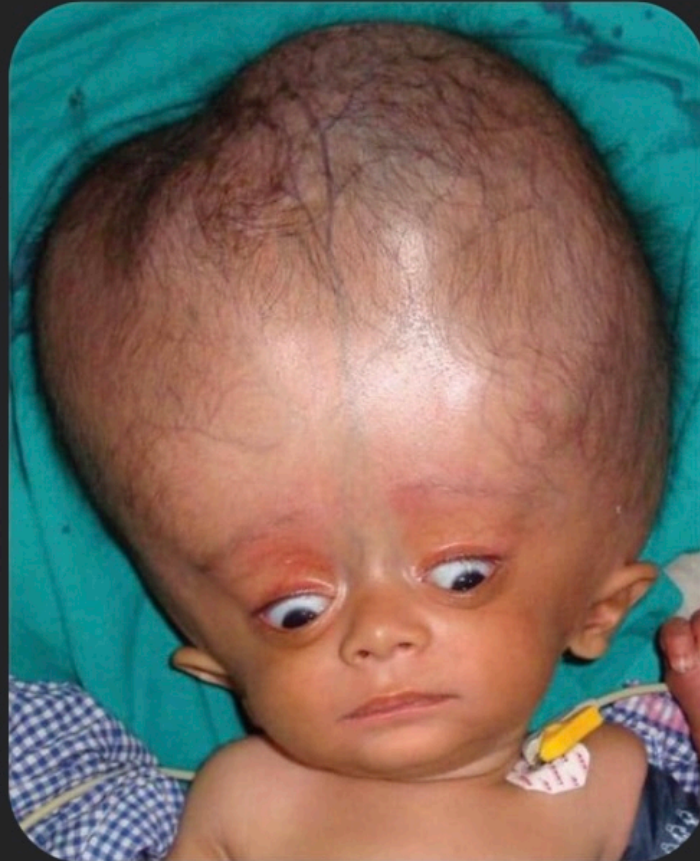4. What is the best diagnostic method for the diagnosis of hydrocephalus?

MRI ✓

5. What are 2 definite surgical treatments for this patient?

-VP shunt ✓

-Endoscopic third ventriculostomy ✓



18w

Like

Reply

1 