

Malignant Ovarian Tumors

- **JU/5th Year Medical Students**
- **Dr Amal Barakat**
- **December/2023**

Epidemiology of Malignant Ovarian Tumors

- The second most common gynecologic malignancy in developed countries.
- Incidence of 9.4 per 100,000 women and a mortality rate of 5.1 per 100,000.
- In the United States, it is more common in White and Hispanic women.
- Among women it ranks fifth in cancer-related deaths.
- Almost 50% of all cases occurring in women older than 65 years
- About 90% of ovarian cancers involve epithelial tumors.
- The overall five-year survival rate in the United States is 49%.
- 65% Epithelial, 35% Non- Epithelial

Risk Factors

- ✓ Older age
- ✓ Early menarche or late menopause
- ✓ Family history of ovarian and/or breast cancer, endometrial & colon.
 - A family history of ovarian cancer is known as the most important risk factor
- ✓ Genetic factors
- ✓ Nulliparity
- ✓ Endometriosis
- ✓ Asbestos
- ✓ Pelvic radiation
- ✓ Menopausal hormone therapy
- ✓ Obesity
- ✓ Race: Caucasian

Risk Factors

- Life time risk is 1%
- It is estimated that BRCA gene mutations and Lynch syndrome account for **10 -15%** of ovarian cancer cases.
- History of breast cancer increases risk by factor of 2
- History of ca ovary increases the risk by factor of 3
- One first degree relative affected: risk 2.7%
- 2 first degree relatives affected : risk is 13%
- If BRCA1 mutation carrier : risk is up to 50%

Genetic Factors

- Several ovarian cancer susceptibility genes have been identified, primarily **BRCA1** and **2** and the mismatch repair genes (associated with **Lynch syndrome**); other genes include RAD51C, RAD51D, and BRIP1.
- The age at diagnosis of ovarian cancer is *younger* among women with a **hereditary ovarian cancer syndrome**.
- The estimated lifetime risk of ovarian cancer is **35-46 % for BRCA1** mutation carriers and **13-23 % for BRCA2** mutation carriers.
- Some family cancer syndromes such as hereditary nonpolyposis colon cancer and Peutz-Jeghers syndrome also increase the risk of developing ovarian cancer.

Protective Factors

- **Tubal ligation**
- **Bilateral salpingo-oophorectomy**
- **Hysterectomy**
- **Oral contraceptives**
- **Intrauterine device**
- **Pregnancy/Breastfeeding**
- **Multiparity**

Clinical Features

- **Ovarian cancer is a type of tumor which rarely causes symptoms in its early stages, but as it progresses it may cause:**
 - **Abdominal or pelvic pain, swelling, or pressure**
 - **Pressure symptoms of bladder or rectum**
 - **Difficulty eating or feeling full quickly**
 - **Bloating or gas**
 - **Nausea and vomiting**
 - **Constipation**
 - **Ascites (fluid in the abdomen)**
 - **Indigestion and acid reflux**
 - **SOB**
 - **Fatigue**
 - **Vaginal bleeding**

Diagnosis

- History & Physical Exam
- Blood work: Tumor markers, CBC, LFT, KFT
- Occult blood per rectum, Endoscopy & Colonoscopy
- If abnormal vaginal bleeding: Endometrial biopsy& ECC
- Chest X-Ray
- Mammogram
- Ultrasonography (pelvic or transvaginal)
- Abdominal and pelvic computerized tomography (CT) or magnetic resonance imaging (MRI)
- Ascitic Tap
- Surgical Staging

Diagnosis

- **Imaging :**
- **Pelvic Ultrasound** is the single most effective way of evaluating an ovarian mass. With transvaginal ultrasonography being preferable due to its increased sensitivity over transabdominal ultrasound.
- **Abdominal and pelvic computerized tomography (CT) or magnetic resonance imaging (MRI)** can help to assess for the presence of ascites and the extent of disease in women with suspected intraabdominal spread.
- **Chest radiography** is performed in most patients to evaluate for pleural effusion, pulmonary metastases, and mediastinal lymphadenopathy.

Features of Malignant Ovarian Cyst on Ultrasound

- **Ultrasonographic finding that is most indicative of ovarian cancer is** cystic mass containing a **vascular papillary excrescence** (an outgrowth or enlargement), which is present in more than 50% of ovarian malignancies.
- Thick & Irregular contour.
- Poorly defined margins.
- Thick or irregular septations.
- Irregular multilocular solid mass > 10 cm in diameter.
- Absence of acoustic shadow.
- Presence of solid areas.
- Adherent bowel loops.
- Ascites.

Screening for ovarian cancer

- Routine screening in asymptomatic average-risk women is not recommended by any professional society.
- **A family history of ovarian cancer is known as the most important risk factor**
- **Potential screening tests for ovarian cancer include:**
 - 1) The bimanual pelvic examination
 - 2) Serum CA 125, HE4
 - 3) Ultrasound imaging.

Screening for ovarian cancer

- The new ovarian cancer pathogenesis model divides the known ovarian cancer subtypes into types I and II tumor.
- Type II ovarian cancer is the most aggressive subtype, which progresses very quickly (under one year) to stage III.
- Therefore, the diagnosis of low volume (stage IIIa/b) type II tumors should be the primary goal of screening.

CA-125 Marker

- The human cancer antigen 125 (CA 125), also known as mucin 16 (MUC16), is a cell-surface, glycoprotein antigen normally expressed in tissues **derived from coelomic epithelia**, such as ovary, fallopian tube, peritoneum, pleura, pericardium, colon, kidney, and stomach.
- CA 125 is detectable either through serological-based tests or tissue-based studies of malignant ovarian or endometrial tissue specimens.
- The reference range of CA 125 is 0-35 units/mL (0-35 kU/L).
- **CA 125 is the best-known tumor marker for ovarian carcinoma as it rises in more than 80% of non-mucinous epithelial ovarian carcinomas**
- Serum CA 125 >200 U/mL had been used as a criterion for referral to a gynecologic oncologist in premenopausal women with adnexal mass.

Limitations to using CA-125 as a biomarker

- **Low sensitivity during early disease (~50%)**
 - ✓ levels significantly elevated in only ~50% of women diagnosed with stage I or II ovarian cancer.
- **Normal levels in 20% of ovarian malignancies**
 - ✓ CA 125 is not consistently produced by some histologic types of epithelial ovarian cancer, including:
 1. Mucinous
 2. Clear cell
 3. Mixed müllerian ovarian tumors.
- **Elevations in other benign and malignant processes**

Elevated CA 125 Due to Benign Conditions

- **Normal patients (1%)**
- **Menstruation**
- **Pregnancy**
- **Endometriosis**
- **Adenomyosis**
- **Uterine fibroids.**
- **Benign ovarian cysts (Ovarian Fibroma)**
- **Acute PID**
- **Diverticulitis**
- **Lung Disease**
- **Liver cirrhosis**
- **Acute pancreatitis**
- **Acute peritonitis**
- **Peritoneal Tuberculosis**

Elevated CA 125 Due to Malignant Conditions

- **Ovarian Cancer**
- CA 125 is the best-known tumor marker for ovarian carcinoma as it rises in more than 80% of non-mucinous epithelial ovarian carcinomas
- **Endometrial Cancer**
- **Fallopian tube cancers.**
- **Breast cancer**
- **Lung cancer**
- **Pancreatic cancer**
- **Primary Peritoneal cancers.**
- **Elevated in up to 40% of advanced or metastatic non-ovarian abdominal malignancies. (Peritoneal implants of non-ovarian cancer)**

CA-125 Marker

- CA125 has played an important role in the screening, treatment, and follow-up phases of ovarian cancer management.
- Ovarian cancer recurs in 25% of early-stage and more than 80% of advanced-stage patients
- CA-125 is approved by the Food and Drug Administration to monitor the effectiveness of treatment for ovarian cancer and for detecting disease recurrence after treatment.
- CA-125 test alone is not an accurate diagnostic tool.

Question??

Which of the following is NOT typically associated with an elevated CA 125?

- Adenomyosis
- Endometrioma
- High grade serous cystadenocarcinoma
- Mucinous borderline tumor
- Tubo-ovarian abscess

Human Epididymis Protein 4 (HE4) biomarker

- Novel biomarkers could contribute to the accuracy of CA125 and prove their potential as an adjunct marker to CA125.
- Besides CA125, human epididymis protein 4 (HE4) is the most promising tumor biomarker for ovarian cancer.
- The laboratory reference range of HE4 is ≤ 150 pM.
- The search for more accurate ovarian cancer biomarkers is an ongoing process.
- Despite the identification of numerous new biomarkers, CA125 is still superior to the majority of novel biomarkers in postmenopausal women, including HE4.

Tumor serum biomarkers

❖ Carcinoembryonic Antigen (CEA) :

- CEA may be elevated in malignancies that produce the protein, particularly mucinous cancers associated with the gastrointestinal tract or ovary.
- CEA may also be elevated in the following malignancies: Breast, Pancreas, Thyroid & Lung.
- The typical upper limit of normal for CEA in non-smokers is 3.8 micrograms per liter (mcg/L).
- For smokers, the upper limit of normal is 5.5 mcg/L.

❖ Cancer antigen 19-9 (CA 19-9) :

- (CA 19-9) is a mucin protein that may be elevated in ovarian cancer.
- It commonly elevates in gastrointestinal and pancreatic malignancies.

Risk of Malignancy Index (RMI)

- The risk of malignancy index (RMI) was originally developed in 1990 and is a multimodality approach that combines serum CA 125, pelvic ultrasound, and menopausal status into an index score to predict the risk of ovarian cancer in women with an adnexal mass.
- **RMI combines three presurgical features:**
 - Serum CA-125 level (IU/ml)
 - Menopausal status (M) (Premenopausal, Postmenopausal)
 - Ultrasound score (U). (Multi locular, solid areas, bilateral, ascitis, intra abdominal mets)
- **$RMI = U \times M \times CA-125$**
- **RMI I score of >200 = high risk** (sensitivity 78%, specificity 87% for ovarian cancer)
- **RMI I score < 25 = low risk** (risk of cancer < 3%)

Risk of Ovarian Malignancy Algorithm (ROMA)

- The risk of ovarian malignancy algorithm (ROMA) incorporates: cancer antigen 125 (CA125), human epididymal protein 4 (HE4) and menopausal status to assign women that present with an adnexal mass into a high-risk or low-risk group for finding an ovarian malignancy.
- This test combines two serologic biomarkers (HE4 and CA 125) with menopausal status to produce a numerical score that identifies patients as having low or high risk.
- Two other multimarker serum tests (OVA1 and Overa), each of which checks for five serum markers, have also been approved by the U.S. Food and Drug Administration for the same indication.

Surgical Management & Staging

- **There are two goals for the surgical treatment of epithelial ovarian cancer:**
 - Staging
 - Debulking.
- Laparotomy is generally used, but laparoscopic or robot-assisted approaches are used by some surgeons for selected patients.
- Frozen section : The diagnosis of ovarian, tubal, or peritoneal cancer is usually made at time of surgery.

Managment

- **Surgery :**

- ❖ Primary
- ❖ Interval debulking
- ❖ Palliative
- ❖ Second look surgery

- **Chemotherapy**

Management of Ovarian Cancer

- **Surgery and chemotherapy** have been used as the main ovarian cancer treatments for many decades.
- **Primary debulking surgery (Cytoreduction)** is the preferred initial treatment option for patients with advanced-stage ovarian cancer.
- **Complete resection of tumors leading to no visible residual disease during primary cytoreductive surgery is one of the major prognostic factors for ovarian cancer patients.**

Surgical Management

➤ Choosing Appropriate Surgery

- The appropriate surgical approach varies, depending on whether disease is visible outside the ovaries.
- For patients with no disease visible outside the ovaries, adequate surgical staging is essential because the incidence of microscopic metastases is significant.
- If macroscopic disease is visible outside of the ovary, all visible tumor should be removed. This may require extensive surgery, including bowel resection, excision of peritoneal implants, liver resection, omentectomy, and splenectomy.

Surgical Staging

- **Adequate surgical staging procedures include:**
 - Exploration of abdomen/pelvis
 - Peritoneal washings & cytology
 - Bilateral salpingo-oophorectomy
 - Hysterectomy
 - Peritoneal biopsies of Cul-de-sac
 - Peritoneal biopsies of Pelvic walls
 - Peritoneal biopsies of Paracolic gutters
 - Peritoneal biopsies of Diaphragm
 - Biopsy of any areas where metastases are suspected
 - Omentectomy
 - Appendectomy
 - As well as pelvic and para-aortic node dissection up to the renal veins.

Stage I

- **The cancer is only in the ovaries.**

- **Stage IA:** The cancer is only inside 1 ovary. No cancer is found on the ovarian surface or in the abdomen.

- **Stage IB:** The cancer is in both ovaries. No cancer is found on the surface of the ovary or in the peritoneal fluid or washings.

- **Stage IC:** The cancer is in 1 or both ovaries, with any of the following:

- Stage IC1:** The tumor ruptures while it is being removed surgically, called intraoperative surgical spill.

- Stage IC2:** The tumor wall is ruptured before surgery, or there is cancer on the surface of the ovary.

- Stage IC3:** Cancer cells are found in fluid buildup in the abdominal cavity; ascites, or in the samples of fluid from the peritoneal cavity taken during surgery.

Stage II

- **Stage II:**

The cancer involves one or both of the ovaries and has spread below the pelvis, or it is peritoneal cancer.

- **Stage IIA:** The cancer has spread to the uterus and/or fallopian tubes and/or the ovaries.

- **Stage IIB:** The cancer has spread to other tissues within the pelvis.

Stage III

- **Stage III:**

The cancer involves one or both of the ovaries, or it is peritoneal cancer. It has spread to the peritoneum outside the pelvis and/or to lymph nodes in the retroperitoneum (lymph nodes along the major blood vessels, such as the aorta) behind the abdomen.

- **Stage IIIA1:** The cancer has spread to the retroperitoneal lymph nodes, which are found at the back of the abdomen, but not to the peritoneal surfaces.

- Stage IIIA1(i):** Metastases, or areas of spread, are 10 millimeters (mm) or smaller.

- Stage IIIA1(ii):** Metastases are larger than 10 mm.

- **Stage IIIA2:** The cancer has spread microscopically from the pelvis to the abdomen. Cancer may or may not have spread to lymph nodes in the back of the abdomen.

- **Stage IIIB:** The cancer has visibly spread past the pelvis to the abdomen and is 2 centimeters (cm) or smaller, with or without spread to the retroperitoneal lymph nodes. A centimeter is roughly equal to the width of a standard pen or pencil.

- **Stage IIIC:** The cancer has visibly spread past the pelvis to the abdomen and is larger than 2 cm, with or without spread to the retroperitoneal lymph nodes.

Stage IV

- **Stage IV:**

The cancer has spread to organs outside of the abdominal area.

- **Stage IVA:** The cancer has spread to fluid around the lungs.

- **Stage IVB:** The cancer has spread to the liver or spleen or to organs beyond the abdomen, including lymph nodes in the groin outside of the abdominal cavity.

Grading

- Most epithelial ovarian cancers are the serous type, and they are graded as **low-grade serous carcinoma (LGSC)** or **high-grade serous carcinoma (HGSC)**.
- These tumors have different genetic alterations and biology.
- Other types of ovarian cancer, such as endometrioid cancers, may be given these grades:
- **Grade 1:** The tissue is well differentiated. This means the cells look and are organized within the tumor like normal cells. These tumors tend to grow slowly.
- **Grade 2:** The tissue is moderately differentiated. It shares features between well and poorly differentiated. Grade 2 is not commonly used.
- **Grade 3:** The tissue is poorly differentiated or undifferentiated. All or most cells appear very abnormal and do not have any normal tissue structure. These tumors tend to grow fast and can spread rapidly.

Surgical Cytoreduction

- **One or more of the following procedures may be considered for optimal surgical cytoreduction:**
- Bowel resection and/or appendectomy
- Stripping of the diaphragm or other peritoneal surfaces
- Splenectomy
- Partial cystectomy and/or ureteroneocystostomy
- Partial hepatectomy
- Partial gastrectomy
- Cholecystectomy
- Distal pancreatectomy

Surgical Cytoreduction

- **The terminology regarding extent of cytoreduction is:**
 - ✓ **Complete cytoreduction:** Cytoreduction to no grossly visible disease.
 - ✓ **Optimal cytoreduction:** The Gynecologic Oncology Group (GOG) defines optimal cytoreduction as residual disease that is ≤ 1 cm in maximum tumor diameter.
 - ✓ **Suboptimal cytoreduction** – Cytoreduction with tumor nodules >1 cm remaining.

Surgical Cytoreduction

- Stage IA : In young women, conservative surgery (unilateral salpingo-oophorectomy) for fertility preservation is being considered. full surgical staging, including washings, omentectomy, appendectomy, and node biopsies, should be done and should be negative.
- Stage IIIa/b patients are also more likely to achieve optimal resection than stage IIIc/d. Optimal primary debulking surgery followed by chemotherapy reduces the number of residual cancer cells, leading to survival improvements.
- Advanced stage ovarian cancer patients (stages IIIc and IV) who have undergone optimal primary debulking surgery (no visible residual disease) have a better seven-year survival than women with any residual disease remaining after surgery (73.6% vs 21%; $p < 0.0001$)

Management of Ovarian Cancer

- Median survival for patients with recurrent ovarian cancer is 12–24 months, while the disease is considered incurable.
- Ovarian cancer recurs in 25% of early-stage and more than 80% of advanced-stage patients.
- The chance of recurrence is much higher in patients with any residual disease remaining after primary debulking surgery than those with no residual disease after surgery.
- The volume of residual disease at the completion of surgery represents one of the most powerful prognostic factors.

Neoadjuvant Therapy

- **Neoadjuvant therapy:** Neoadjuvant chemotherapy (NACT) refers to the administration of systemic chemotherapy **before** definitive surgery.
- The goal of NACT is to **reduce perioperative morbidity and mortality and increase the likelihood of a complete resection of disease at the time of cytoreductive surgery.**
- In most cases of women treated with NACT, further chemotherapy is administered following surgery (ie, adjuvant chemotherapy).

Adjuvant Chemotherapy

- Only a small percentage of women with epithelial ovarian cancer can be treated with surgery alone.
- These include patients with stage IA grade 1 and stage IB grade 1 serous, mucinous, and endometrioid tumors.
- Patients not treated with chemotherapy should be monitored closely at regular intervals with clinical examination, serum CA-125 estimation, and ultrasonography if an ovary is still present. Surgery to remove the uterus and residual ovary should be considered when the patient no longer desires to remain fertile.
- While a number of chemotherapeutic agents are active in the treatment of EOC, numerous studies have shown the superiority of **the combination of a platinum agent and a taxane**, usually paclitaxel, following initial surgical cytoreduction, and this has become the standard of care for the treatment of EOC.
- The stage at diagnosis and extent of surgical cytoreduction determine the treatment duration and route.

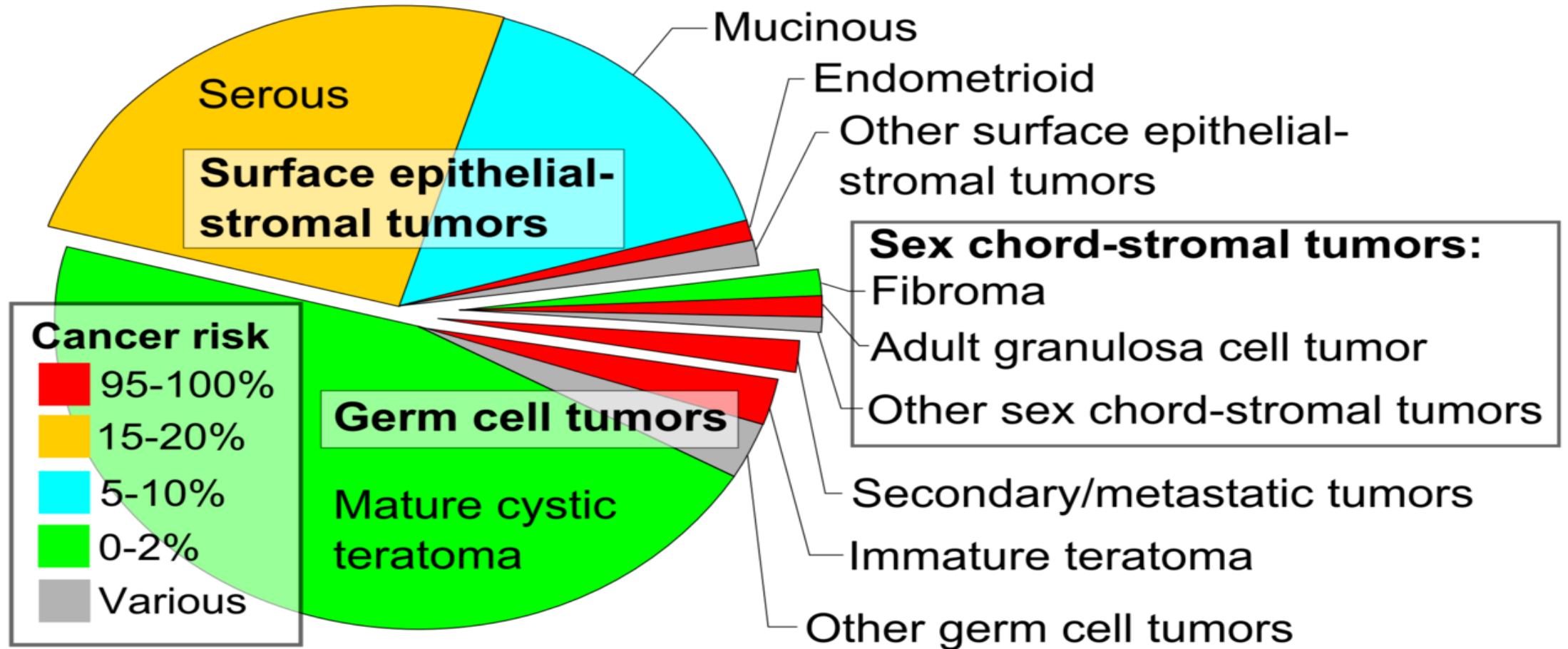
POSTTREATMENT SURVEILLANCE

- 1) **Office visits** (including physical and pelvic exams) every three to six months up to five years post-treatment, then annually.
 - 2) **CA-125 or other tumor markers (eg, HE4)** every visit if initially elevated, if indicated
 - 3) **Other testing** (ie, chemistry profile or complete blood count, CT scan, or transvaginal ultrasound in women who underwent fertility-sparing surgery) only as clinically indicated.
- ❖ Standard imaging techniques, including ultrasound, computerized tomography (CT), magnetic resonance imaging (MRI), and positron emission tomography (PET), have limited sensitivity to detect recurrent EOC.

SPECIFIC LONG TERM EFFECTS IN OVARIAN CANCER SURVIVORS

- In general, ovarian cancer survivorship can be characterized as issues involving one of the four domains of quality of life (QOL) : the physical, emotional (psychological), spiritual, and social.
- 1) **Neurotoxicity** : Muscle cramps, Ringing in ears or trouble hearing, Discomfort in feet, Trouble walking, Numbness and weakness in the hands.
- 2) **Cognitive dysfunction**
- 3) **Fatigue**
- 4) **Gastrointestinal toxicity**
- 5) **Surgical complications** : e.g, bowel obstruction, which can be caused by intra-abdominal adhesions secondary to prior surgery.
- 6) **Loss of fertility**
- 7) **Sexual dysfunction**
- 8) **Menopause** : Menopausal hormonal therapy does not appear to increase the risk of either recurrence or mortality.
- 9) **Psychological effects** (Depression, Anxiety , Guilt , Poor body image).

Ovarian Carcinoma



Ovarian Carcinoma

- **Epithelial Ovarian Tumors**
- **Germ Cell Tumors**
- **Sex Cord- Stromal Ovarian Tumors**

Epithelial ovarian, Fallopian Tubal, and Peritoneal carcinomas

- Epithelial ovarian carcinoma is the most common type of ovarian cancer, comprising more than 95% of cases.
- Based upon histopathology, immunohistochemistry, and molecular genetic analysis, the five main subtypes of epithelial ovarian, fallopian tubal, and peritoneal carcinomas and their relative proportions are :
 - 1- High-grade serous carcinoma (70-80 %)
 - 2- Endometrioid carcinoma (10 %)
 - 3- Clear cell carcinomas (10 %)
 - 4- Mucinous carcinoma (3 %)
 - 5- Low-grade serous carcinoma (<5 %)

Clinicopathological classification

- **Type I ovarian tumors**: low-grade, indolent tumors that typically manifest as large, unilateral, cystic neoplasms
- Histologic subtypes include: low-grade serous, endometrioid, clear cell, mucinous carcinomas, and malignant Brenner tumors
- Account for ~ 10% of ovarian cancer deaths
- Associated with low levels of chromosomal instability
- **p53 mutations** are uncommon

Clinicopathological classification

- **Type II ovarian tumors**: high-grade, aggressive tumors that typically involve both ovaries
- and are diagnosed at an advanced stage
 - Histologic subtypes include high-grade serous, carcinosarcoma, and undifferentiated carcinoma
 - Account for ~ 90% of ovarian cancer deaths
 - Associated with high levels of chromosomal instability
 - **P53 mutations** are common

Prognostic Factors

- The major prognostic factors associated with improved outcome were :

1) younger age :

Younger patients are more likely to have a favorable prognosis because they are more likely to have tumors of less aggressive histology and lower grade, and better baseline performance status.

2) Low volume of residual disease.

3) Good performance status.

4) Serous histology.

Low Volume of Residual Disease

- Early detection of ovarian cancer (stages I and II) has failed to provide a considerable reduction in mortality.
- The volume of residual disease after cytoreductive surgery is the most powerful prognostic factor for ovarian cancer patients.
- Therefore, the focus of screening should be shifted towards the diagnosis of low volume disease irrespective of stage.
- New cost-effective and accurate screening techniques that can detect type II ovarian carcinomas early in their evolution may substantially impact survival for ovarian cancer patients.

HIGH-GRADE SEROUS CARCINOMA (HGSC)

- Accounts for approximately **70-80 %** of all malignant ovarian neoplasms.
- The peak age range is 45 to 65 years with a mean of **57 years**.
- Most HGSC is diagnosed at an **advanced stage** (stage III or IV) and has a poor overall prognosis.
- Relatively **chemosensitive**.
- HGSC can range in size from microscopic to greater than 20 cm in diameter.
- The mass is typically cystic and multilocular.
- **Psammoma bodies may be present**, but are rarely as numerous as in low grade serous carcinoma (LGSC).
- **The key feature of HGSC, regardless of the overall architectural pattern, is the marked cytologic atypia with prominent mitotic activity.** The atypical nuclei are hyperchromatic with a threefold or greater variation in nuclear size, and tumor giant cells are common.

LOW-GRADE SEROUS CARCINOMA (LGSC)

- LGSC is uncommon and accounts for fewer than **5 %** of all cases of ovarian carcinoma.
- Like HGSC, LGSC is typically **diagnosed at an advanced stage**, and consequently, the long-term prognosis is poor.
- **Relative insensitivity to platinum-based chemotherapy.**
- Gross pathology : LGSC is often grossly indistinguishable from HGSC or serous borderline neoplasms.
- It has a **much lower mitotic activity than that observed in HGSC.**
- Another distinct feature that may be found in LGSC is a hyalinized stroma with **numerous psammoma bodies.**

ENDOMETRIOID CARCINOMA

- Accounts for approximately **10 %** of all ovarian carcinomas.
- Presents most frequently in women in their 40s and 50s, with a mean patient age of 56 years.
- Endometrioid carcinomas are **most often identified at an early stage** (unlike serous carcinomas), **consequently these patients have a much better prognosis.**
- Relatively **chemosensitive.**
- Ovarian endometrioid carcinoma is often associated with and believed to arise from **endometriosis** (up to **42 %** of patients have evidence of ovarian or pelvic endometriosis).
- Endometrioid ovarian carcinoma is associated with **carcinoma of the endometrium** in **15-20 %** of cases.

CLEAR CELL CARCINOMA

- Accounts for approximately **5 - 10 %** of all ovarian carcinomas.
- Presents most commonly in perimenopausal women in their late 40s or 50s.
- **Often presents at an early stage** (stage I or II) and has a relatively good prognosis due to the absence of distant metastases.
- **Insensitive to platinum-based chemotherapy.**
- Associated with an increased risk of **vascular thrombotic events** and **paraneoplastic hypercalcemia**.
- Similar to endometrioid carcinoma, clear cell ovarian carcinoma is often associated with, and likely arises from, **endometriosis**.

Mucinous Carcinoma

- Accounts for 3 - 4 % of primary ovarian cancers.
- Present in perimenopausal women in their late 40s to early 50s.
- Nearly all mucinous carcinomas of the ovary present with **early stage disease**, usually stage I.

MUCINOUS CARCINOMA

- **Gross pathology :**
- Primary ovarian mucinous carcinoma range size from 8 to 20 cm, but can be much larger. It is typically cystic or solid, unilateral, and confined to the ovary. The external surface is usually smooth without surface involvement.
- **Microscopic pathology :** The cells of ovarian mucinous carcinomas can resemble those of the intestine, endocervix, or gastric pylorus, although the vast majority of these neoplasms have gastrointestinal differentiation.

Pseudomyxoma Peritonei

- Pseudomyxoma peritonei (PMP) is a rare clinical entity, characterized by diffuse intra-abdominal gelatinous ascites, the so-called “jelly belly,” with mucinous implants on peritoneal surfaces.
- Although pseudomyxoma peritonei historically was believed to result from rupture of primary ovarian mucinous neoplasm, it is now accepted that pseudomyxoma peritonei almost always results from metastasis to the ovary, often from an appendiceal primary.
- Currently, it has been more widely used to describe peritoneal dissemination of mucus-producing neoplasm most frequently from the appendix, but also small and large bowel, stomach, pancreas, lung, breast, gallbladder, fallopian tubes, and ovaries.
- The primary site is identified predominantly as mucinous appendiceal adenocarcinoma.

Ovarian Germ Cell Neoplasms

- **Histological types :**
- 1) Teratoma :
 - - Mature teratoma : 1) Mature cystic teratoma (Dermoid cyst)
 - 2) Mature solid teratoma
 - - Immature teratoma
- 2) Dysgerminomas
- 3) Endodermal sinus (yolk sac) tumors
- 4) Rare OGCMs : Pure embryonal carcinomas, nongestational choriocarcinomas, and pure polyembryoma
- 5) Mixed germ cell tumors

Malignant Ovarian Germ Cell Neoplasms (OGCNs)

- **Malignant ovarian germ cell neoplasms** grow rapidly, unlike the more common epithelial ovarian neoplasms.
- Most patients present with stage IA disease .
- The majority are present as unilateral ovarian mass.

- **Immature teratoma** : account for 35.6 % of all malignant OGCNs
- **Dysgerminomas** : account for 32.8 % of malignant OGCNs
- **Endodermal sinus tumors** : account for 14 to 20 percent of all malignant OGCNs
- **Embryonal carcinoma** : accounts for 4 % of malignant OGCNs
- **Mixed germ cell neoplasms** : account for 5.3 % of all malignant OGCNs
- **Non-gestational choriocarcinoma** : account for 2.1 % of all malignant OGCNs

Clinical manifestations of Malignant Ovarian Germ Cell Neoplasms

- OGCNs often produce hormones, particularly the beta subunit of human chorionic gonadotropin (hCG).
- **Patients typically present with one or more of the following signs and symptoms:**
 - 1) Abdominal enlargement: from the mass itself, ascites, or both.
 - 2) Abdominal pain: from rupture or torsion.
 - 3) Precocious puberty, abnormal vaginal bleeding: presumably from hCG production.
 - 4) Symptoms of pregnancy: from hCG production.
- OGCNs tend to be large (median size 16 cm).
- Ascites (20%), rupture (pre- or intraoperative) (20%), and torsion (5%)

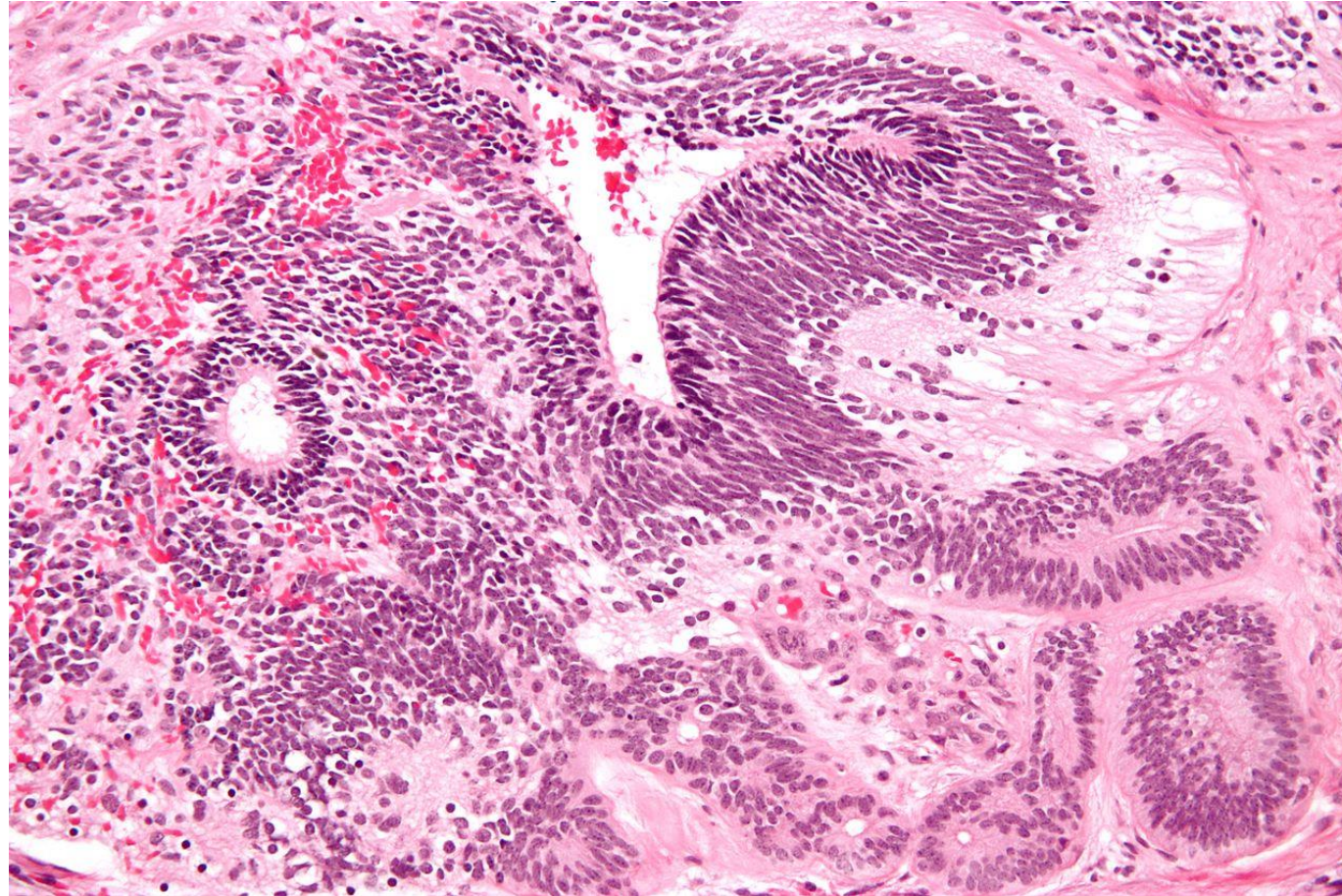
DIAGNOSIS OF (OGCNs)

- The diagnosis is made by histology at time of surgical excision.
- The diagnosis is strongly suggested preoperatively by the presence of an adnexal mass on pelvic imaging and an elevated level of an associated tumor marker (eg, [hCG], alpha fetoprotein [AFP]).
- **Tumor markers**
- **OGCNs are often associated with hormonal or enzymatic activity.**
- 1) **hCG**: embryonal cell carcinomas, ovarian choriocarcinomas, mixed germ cell tumors, and some dysgerminomas.
- 2) **AFP**: endodermal sinus tumors, embryonal cell carcinomas and polyembryoma carcinomas, mixed germ cell tumors, and some immature teratomas.
- **Most dysgerminomas are associated with a normal AFP.**
- 3) **Lactate dehydrogenase (LDH)**: dysgerminomas.

Immature teratoma

- It displays a specific age of incidence, occurring most frequently in the first two decades of life and almost never after [menopause](#).
- Unlike a mature cystic teratoma, an immature teratoma contains immature or embryonic structures.
- The most common embryonic component identified in immature teratomas is the [neuroectoderm](#).
- Compared with [mature teratomas](#), immature teratomas on average are larger (12–25 cm), occur in younger women (in the first three decades of life), and show more solid components on imaging
- It is typically large and has prominent solid components with cystic elements. It is usually filled with [lipid](#) constituents and therefore demonstrates [fat density](#) at [CT](#) and [MRI](#).

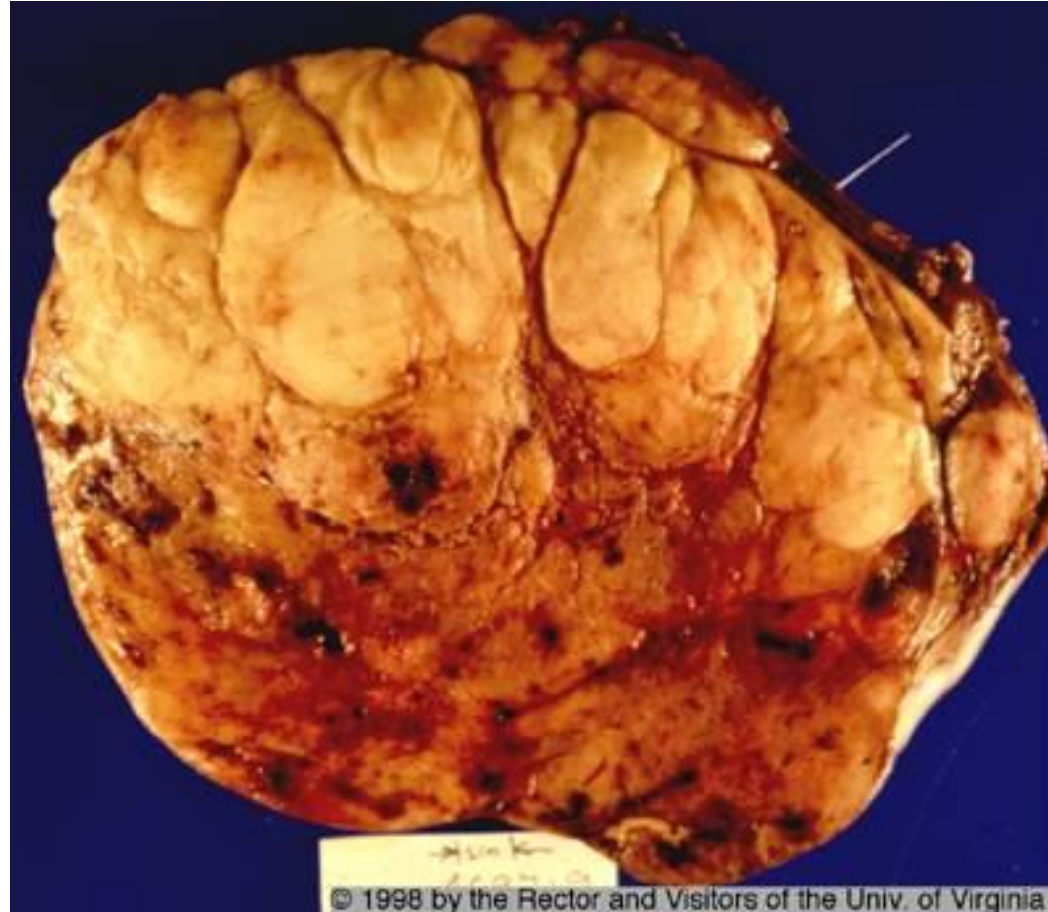the *primitive neuroepithelium* of an
immature teratoma



Dysgerminoma

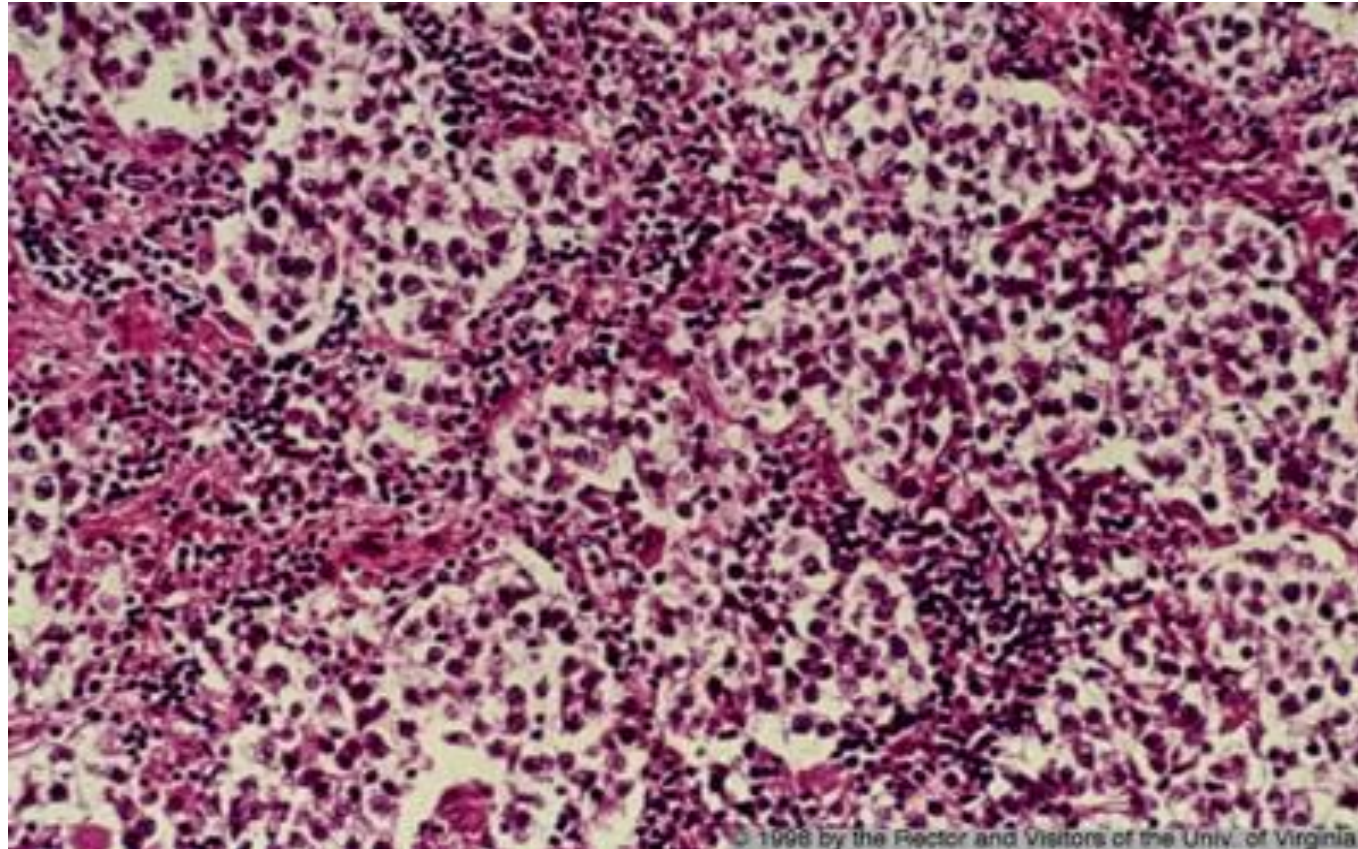
- The ovarian counterpart of the **testicular seminoma**
- 2% of all ovarian malignancies
- Most common malignant ovarian germ cell tumor in adolescents and young women
- Affects primarily younger females with the majority in the second and third decades.
- It is the most frequently encountered ovarian malignancy in pregnancy
- An excellent prognosis.
- Highly radiosensitive .

Solid/ lobulated mass with foci of hemorrhage



© 1998 by the Rector and Visitors of the Univ. of Virginia

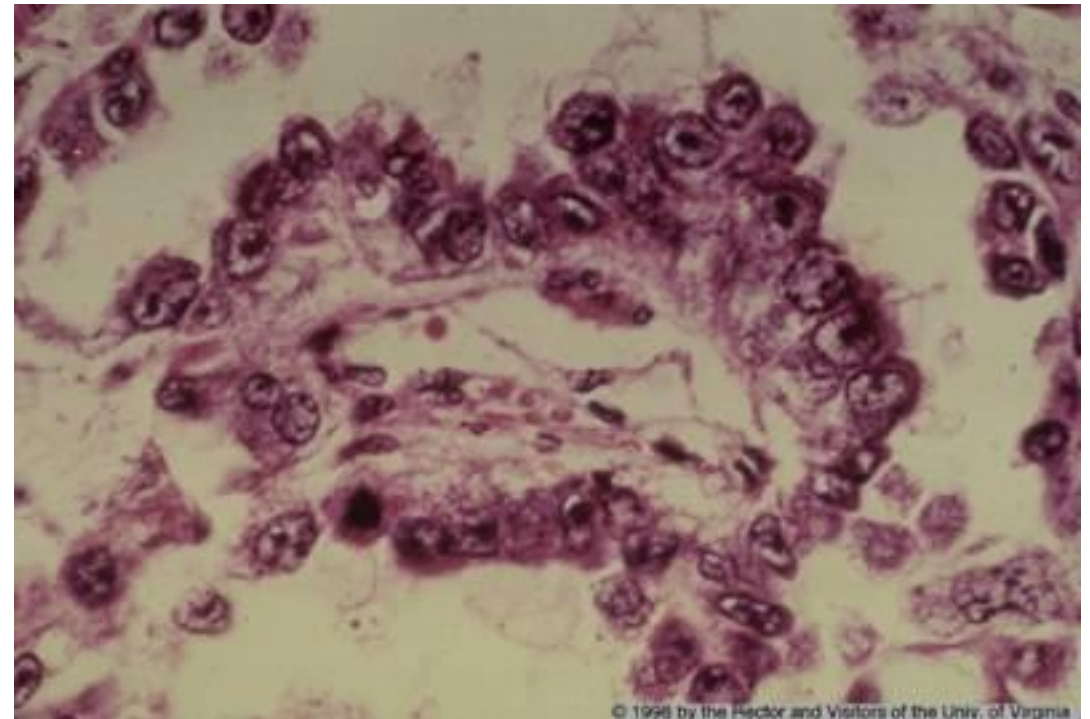
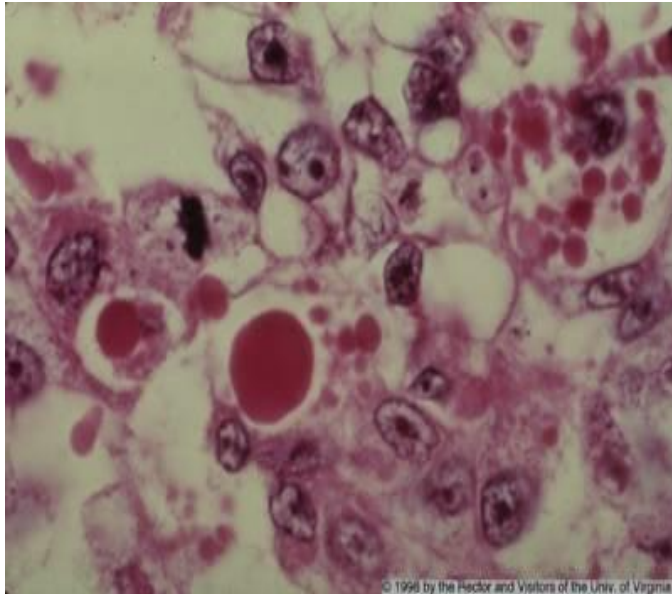
**Sheets of monotonous rounded cells with
pale cytoplasm and central nuclei**



Endodermal sinus tumor (Yolk sac carcinoma)

- Tumor is a highly malignant and clinically aggressive neoplasm
- Most frequently in **children and young females**
- 20% of malignant germ cell tumors.
- A diagnosis of endodermal sinus tumor can be confirmed prior to surgery by detecting elevated levels of serum AFP
- Fatal within 2 years of diagnosis

Schiller-Duval body is the defining morphologic feature of yolk sac tumor



Schiller-Duval body

- Schiller Duval body is a cellular structure that is characterized by the presence of a central blood vessel surrounded by layers of tumor cells. Schiller Duval bodies are most commonly found in testicular yolk sac tumors.

Treatment of (OGCNs)

- **Treatment:**

- 1) Surgery : unilateral salpingo-oophorectomy / cytoreduction.
- 2) Chemotherapy : usually very sensitive to chemotherapy.
- 3) Radiation therapy

Sex Cord-Stromal Tumors

- < 5% of all ovarian tumors
- **Types of sex cord-stromal tumors of the ovary:**
- Ovarian fibroma (Benign)
- Theca cell tumor (thecoma) (Benign)
- Sertoli-Leydig cell tumor (Well differentiated Sertoli-Leydig cell tumors are essentially benign)
- Granulosa cell tumor (Malignant)

Sex Cord-Stromal Tumors

- In contrast with epithelial ovarian cancer, most patients with malignant sex cord- stromal neoplasms are diagnosed with **early-stage disease**; even malignant neoplasms are generally considered to be low-grade.
- **Lymph node metastases are rare** from these neoplasms.
- The age distribution of sex cord-stromal neoplasms is somewhat younger than that of epithelial neoplasms, The average age at diagnosis of sex cord-stromal neoplasms was **50 years** (compared with 61 years for epithelial cancer).

Sex Cord-Stromal Neoplasms (SCS Neoplasms)

- **Clinical presentation:**

- Women with sex cord-stromal neoplasms generally present in the same manner as women with epithelial ovarian neoplasms (eg, abdominal or pelvic symptoms, finding of adnexal mass on examination or imaging).
- In addition, sex cord-stromal neoplasms that secrete estrogens or androgens result in endocrine-dependent clinical manifestations.
- The diagnosis should therefore be suspected in patients who present with signs of estrogen excess (eg, precocious puberty in a child, abnormal uterine bleeding, endometrial hyperplasia or carcinoma) or androgen excess (virilization), especially if an adnexal mass is present.

- **Tumor markers:**

- Some sex cord-stromal neoplasms secrete proteins (eg, inhibin, estrogen, androgens), which can serve as diagnostic markers.
- For women with sex cord-stromal neoplasm, endometrial sampling should be performed.

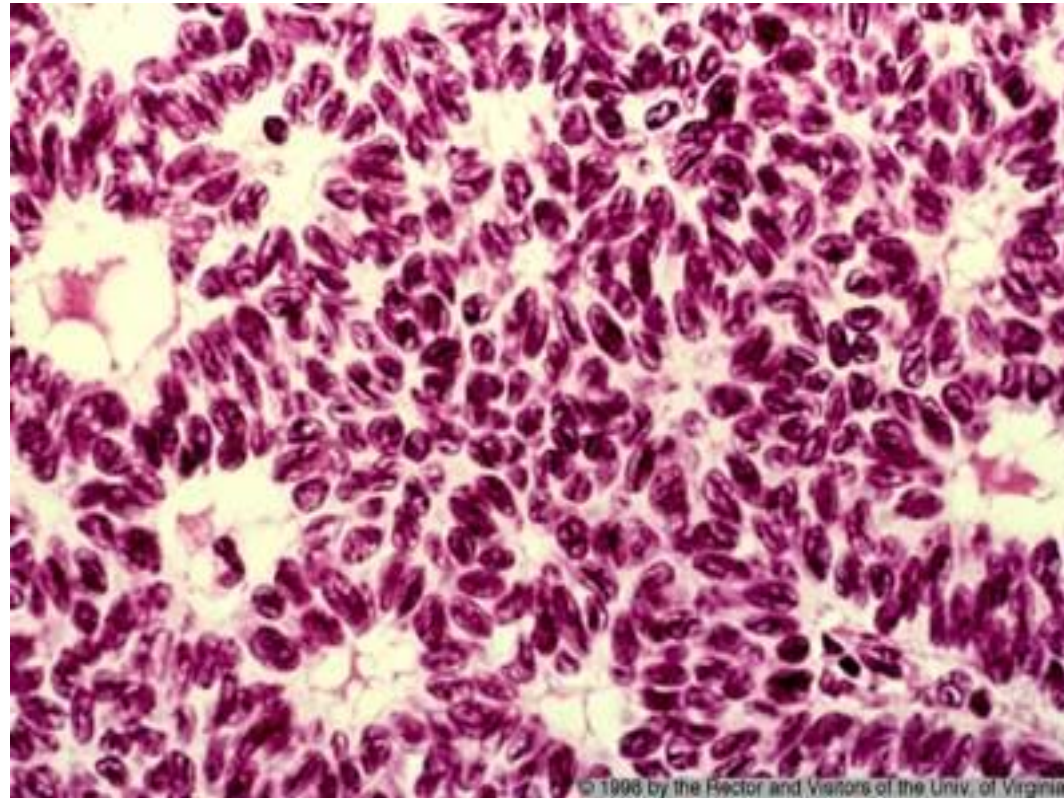
Granulosa cell tumor

- Most common type of sex cord-stromal malignancy (~ 90%)
- Peak age: 50–55 years
- The most common **estrogenic ovarian neoplasm.**
- Symptoms caused by estrogen and/or progesterone secretion
- ❖ Adult Subtype: **menstrual irregularities** (e.g., postmenopausal bleeding endometrial hyperplasia with metrorrhagia)
- Associated with increased risk of **endometrial hyperplasia & endometrial cancer**
- ❖ Juvenile subtype: Precocious puberty

Granulosa cell tumor

- **U/S Appearance:**
 - Typically, large tumor with multilocular solid appearance with > 10 small locules
 - Typically mixed or low level echogenicity
- **Histology:** **Call-Exner bodies:** granulosa cells arranged in clusters surrounding a central cavity with eosinophilic secretions, resembling primordial follicle.
- **Tumor Marker:** Inhibin

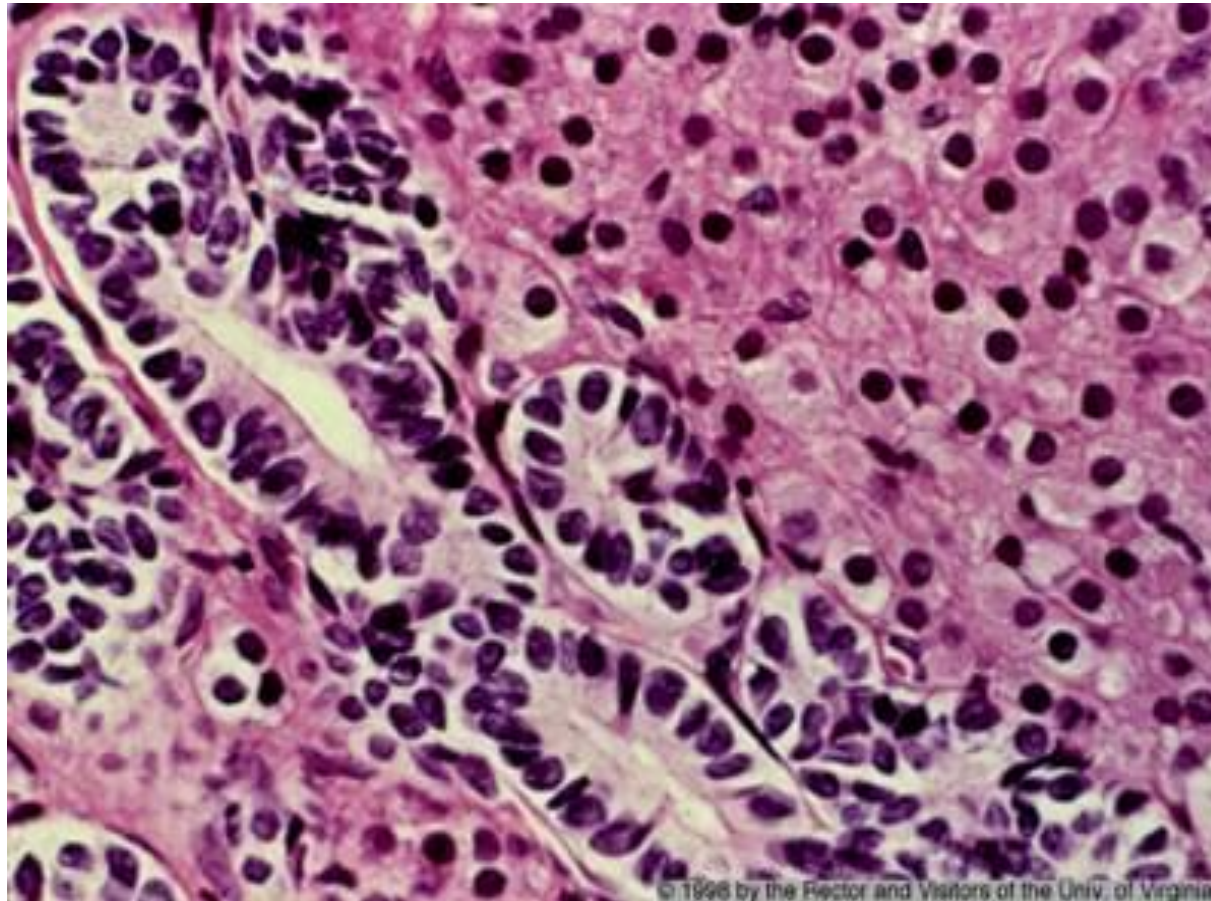
Sheets of granulosa cells containing spaces lined by the cells to give a follicle-like appearance (Call-Exner bodies).



Sertoli-Leydig cell tumors

- Rare. <1% of ovarian neoplasms
- Rare ovarian tumor composed of sex cord (Sertoli cells) and stromal (Leydig cells) element
- It occurs predominantly in young women.
- Commonly **androgenic**, cause defeminization of women manifested as hirsutism, clitoromegaly, breast atrophy and menstrual irregularity or amenorrhea
- Sertoli-Leydig cell tumor:
 - ✓ Well differentiated (Benign)
 - ✓ Moderately differentiated / intermediate grade
 - ✓ Poorly differentiated
- Approximately 10% of moderately differentiated and 13 - 59% of poorly differentiated tumors have malignant behavior

Tubules lined by Sertoli cells and sheet of Leydig cells



© 1996 by the Rector and Visitors of the Univ. of Virginia

Ovarian tumors of low malignant potential (Borderline Tumors)

- Tumors of low malignant potential (also called borderline tumors) are a heterogeneous group of lesions defined histologically by atypical epithelial proliferation **without stromal invasion**.
- Account for 10-20 % of ovarian epithelial tumors.
- The average age at diagnosis is 40 to 60 years old, but the highest frequency relative to invasive ovarian cancer of these tumors occurs in the 15 to 29 year-old age group.
- The disease frequently affects women with a desire to preserve childbearing potential.
- **HISTOLOGIC TYPES:**
 - Serous borderline tumors, Mucinous borderline tumors, Endometrioid, clear-cell, and transitional cell (Brenner) borderline tumors.
 - The majority of borderline tumors are serous, Approximately 75 % of patients are diagnosed with stage I disease; 25-50 % of tumors are bilateral.
 - Mucinous tumors are the other common cellular type; 90 % are stage I and fewer than 10 % are bilateral

Ovarian tumors of low malignant potential

- Borderline tumors are staged using the same criteria as other ovarian tumors. Most women present with stage I disease (approximately 70 percent); stage II and III disease are relatively infrequent.
- **TREATMENT:**
 - **(1) Fertility preserving surgery** — Borderline tumors generally have an excellent prognosis and can be treated conservatively in women who wish to preserve their fertility or are pregnant at the time of diagnosis.
 - Unilateral salpingo-oophorectomy, or, in some instances, ovarian cystectomy may be performed.
 - The overall risk of recurrence after conservative surgery ranges from 7-30 %, and recurrences typically show borderline histology, not invasive cancer.
 - **(2) Hysterectomy and bilateral salpingo-oophorectomy**
 - Total abdominal hysterectomy plus bilateral salpingo-oophorectomy (TAH-BSO) is recommended for women who are not planning pregnancy or have advanced stage disease.
 - The use of adjuvant chemotherapy is controversial: most physicians recommend chemotherapy after aggressive surgical debulking only if invasive implants are identified.

Ovarian tumors of low malignant potential

- **PROGNOSIS**

- The prognosis depends upon the stage and histologic features of the tumor, but is generally good. 5 years survival rate :
 - ●Stage I – 99%
 - ●Stage II – 98%
 - ●Stage III – 96%
 - ●Stage IV – 77%

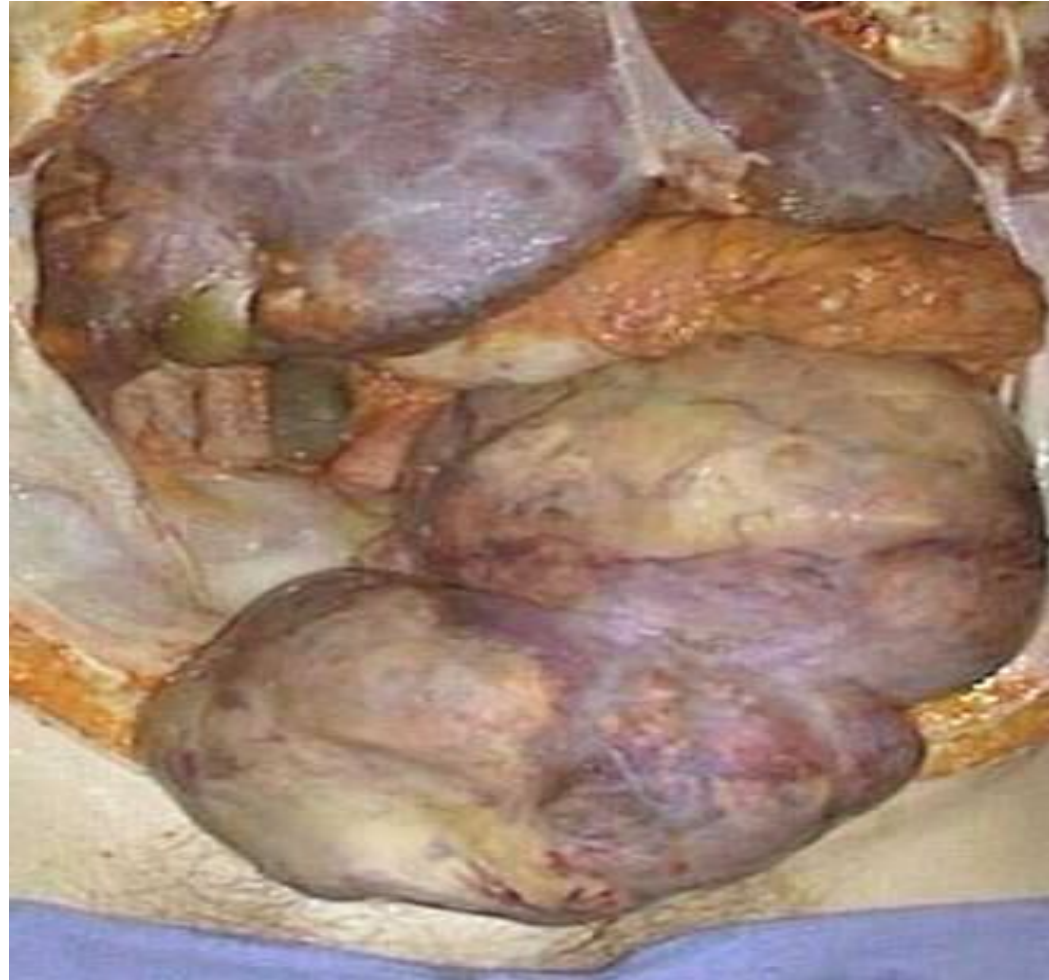Metastases to ovary

- **About 3% of malignant tumors in the ovary are metastatic.**
- **The most common primary site is the breast followed by the large intestine, stomach, and other genital tract organs.**

Krukenberg tumor

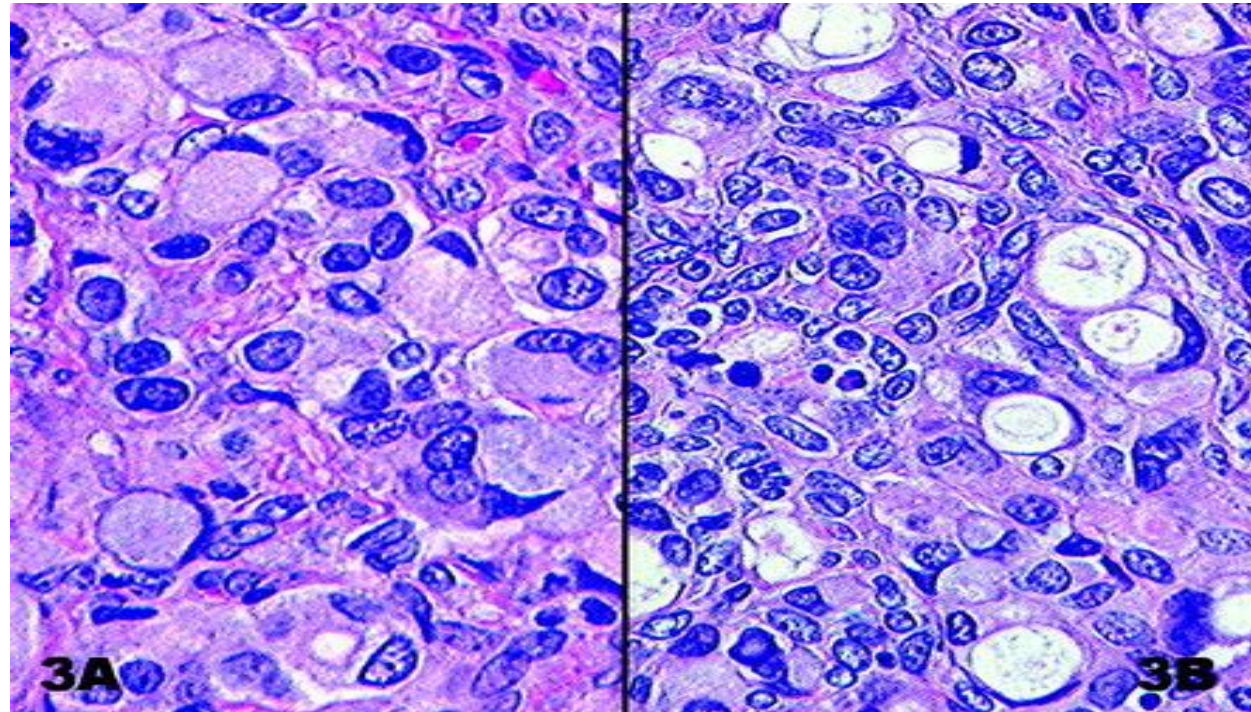
- It is applied to the uniform enlargement of the ovaries (usually bilaterally) due to diffuse infiltration of the ovarian stroma by **metastatic signet-ring cell carcinoma** .
- The commonest primary site is the **stomach** followed by the **colon**.

Krukenberg Tumor



Ovarian infiltration with signet ring cell

In histology, a **signet ring cell** is a cell with a large vacuole



The End of the Second Part

Thank you

Dr Amal Barakat