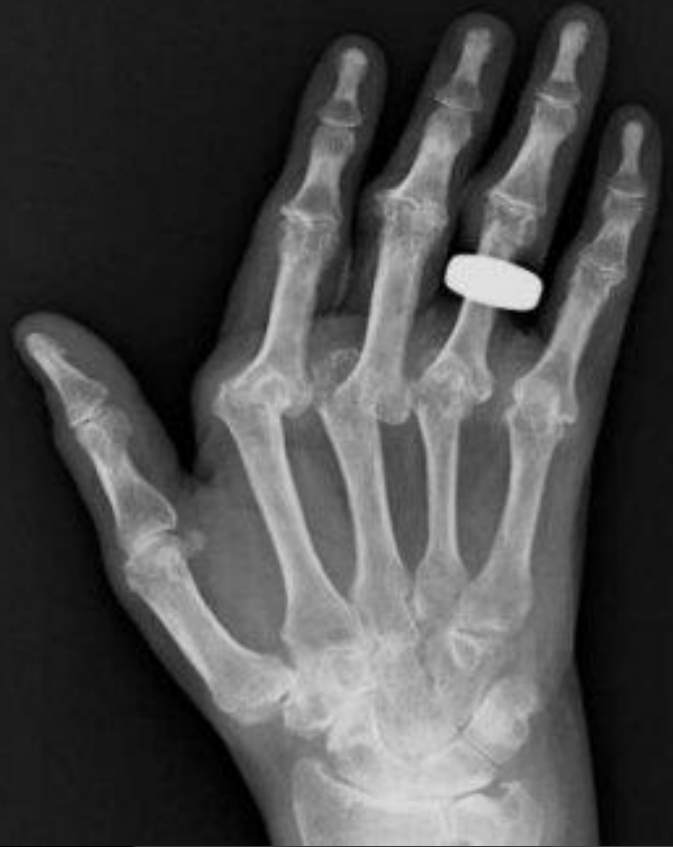
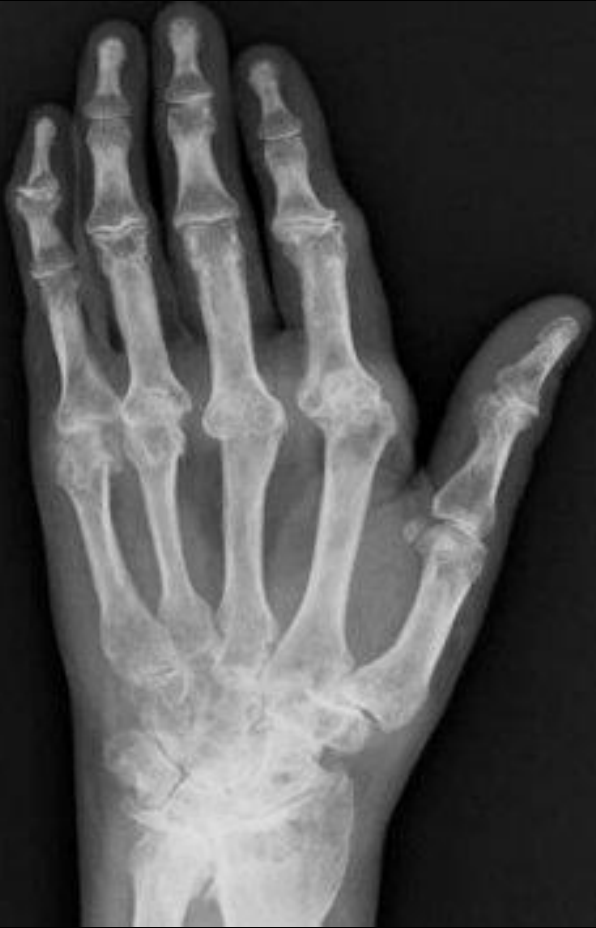
MSK Tutorial

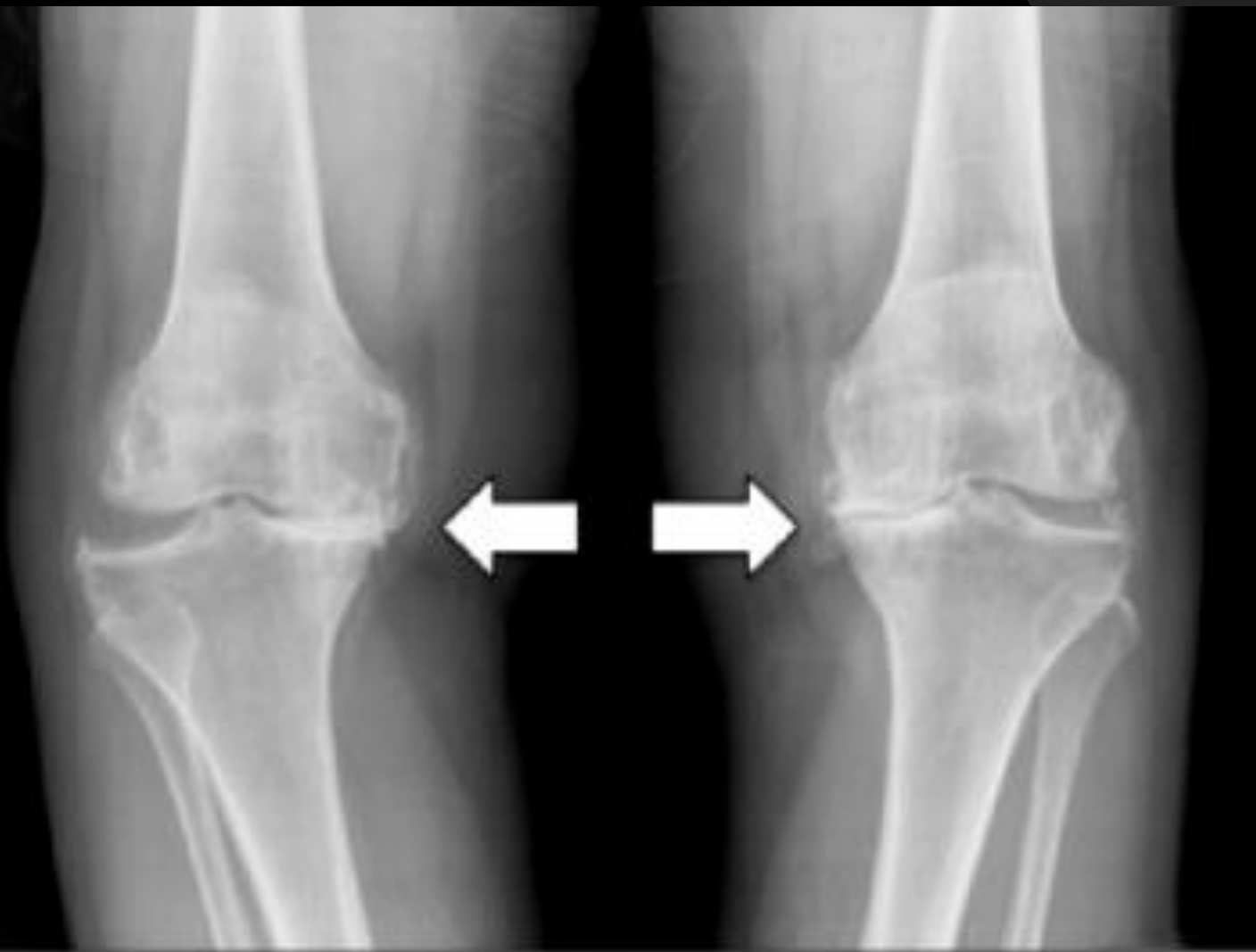Supervised by : Dr. Omar Al - btoush

1

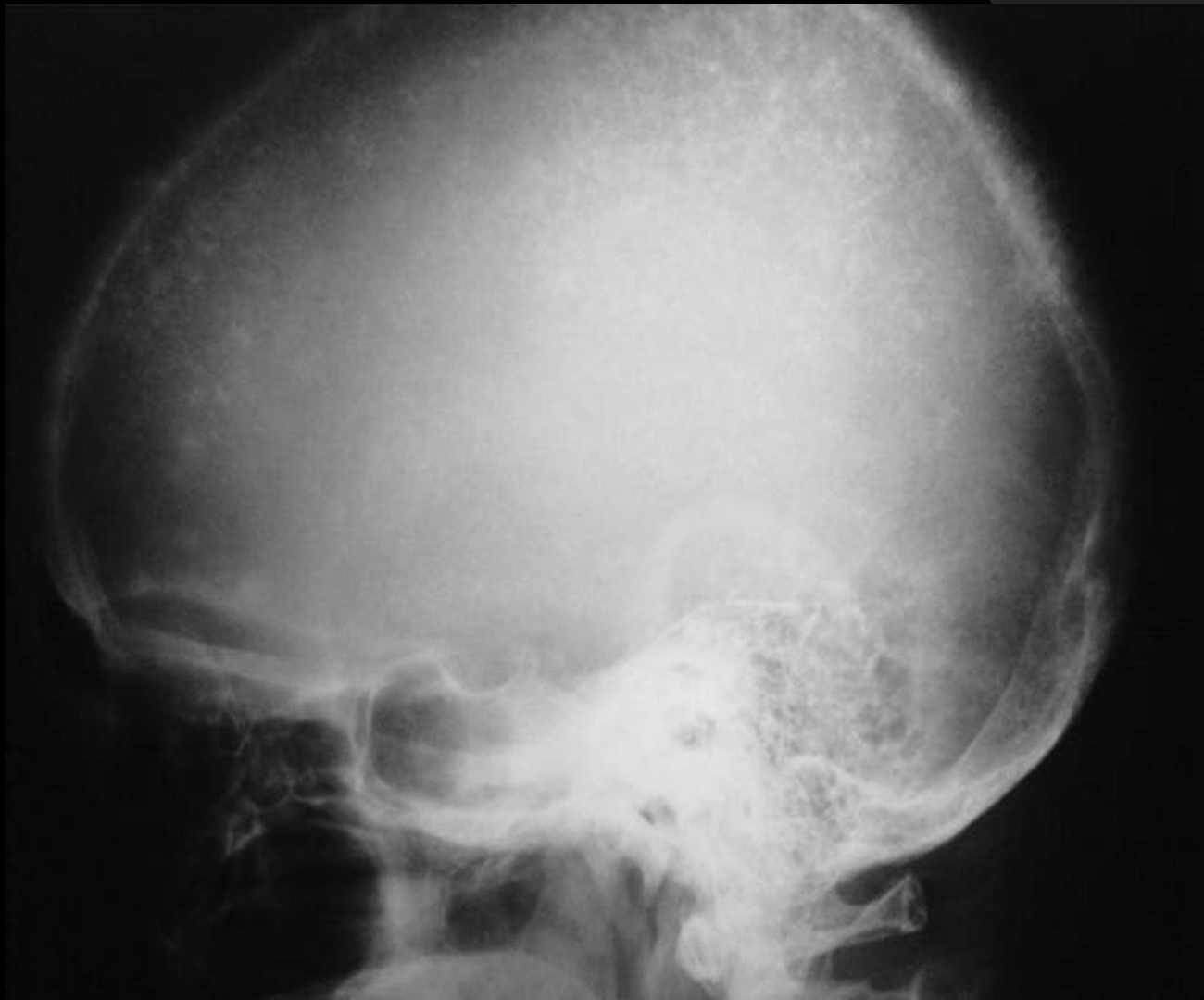D



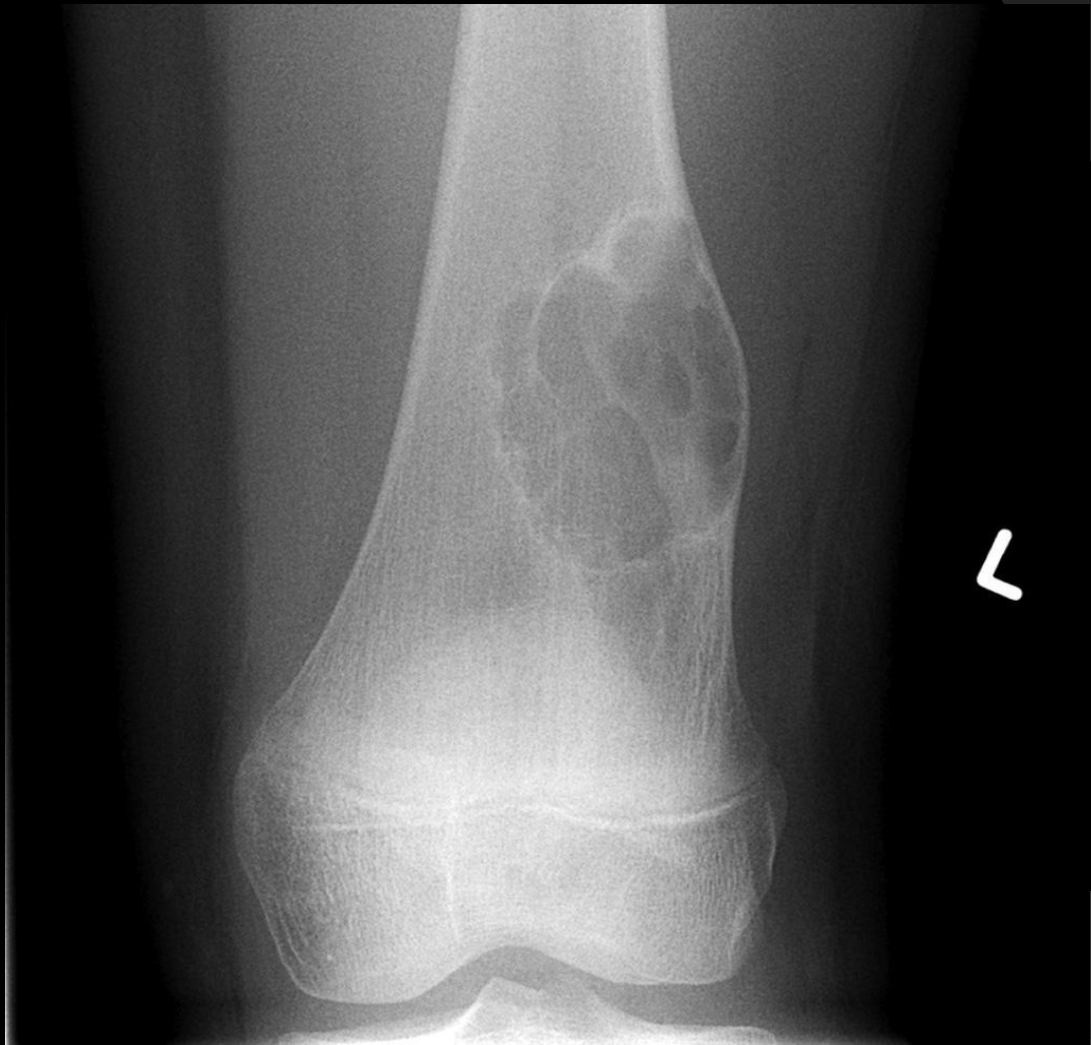
2



3



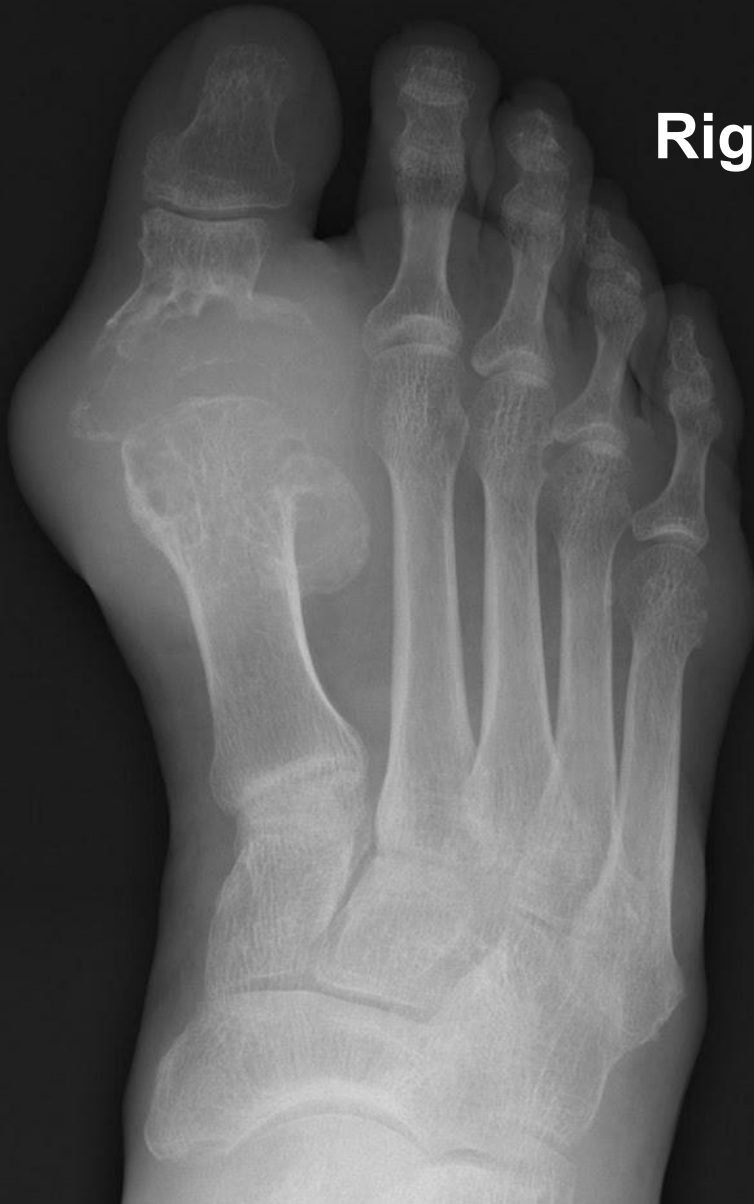4



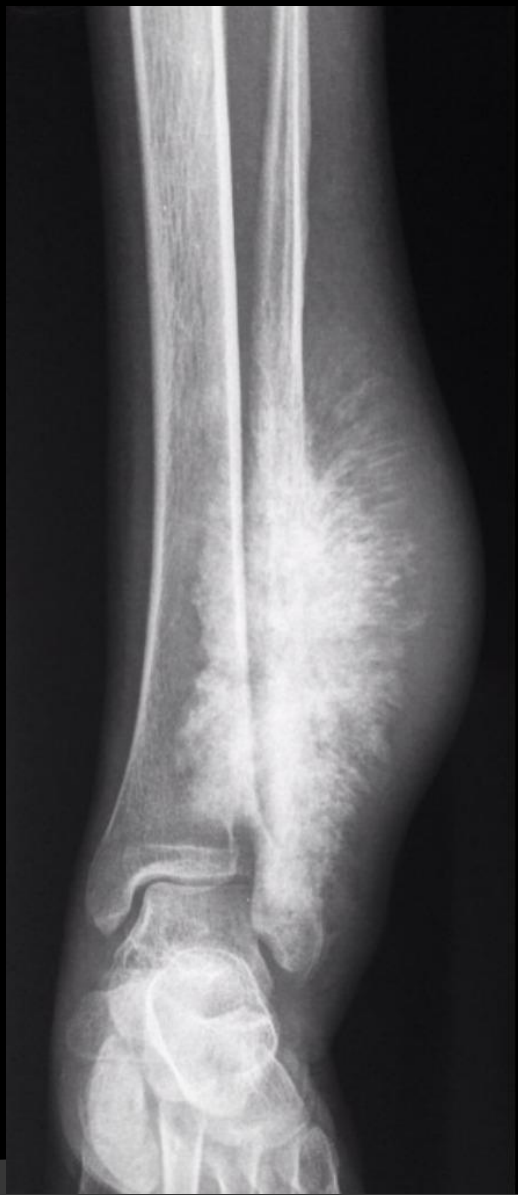L

5

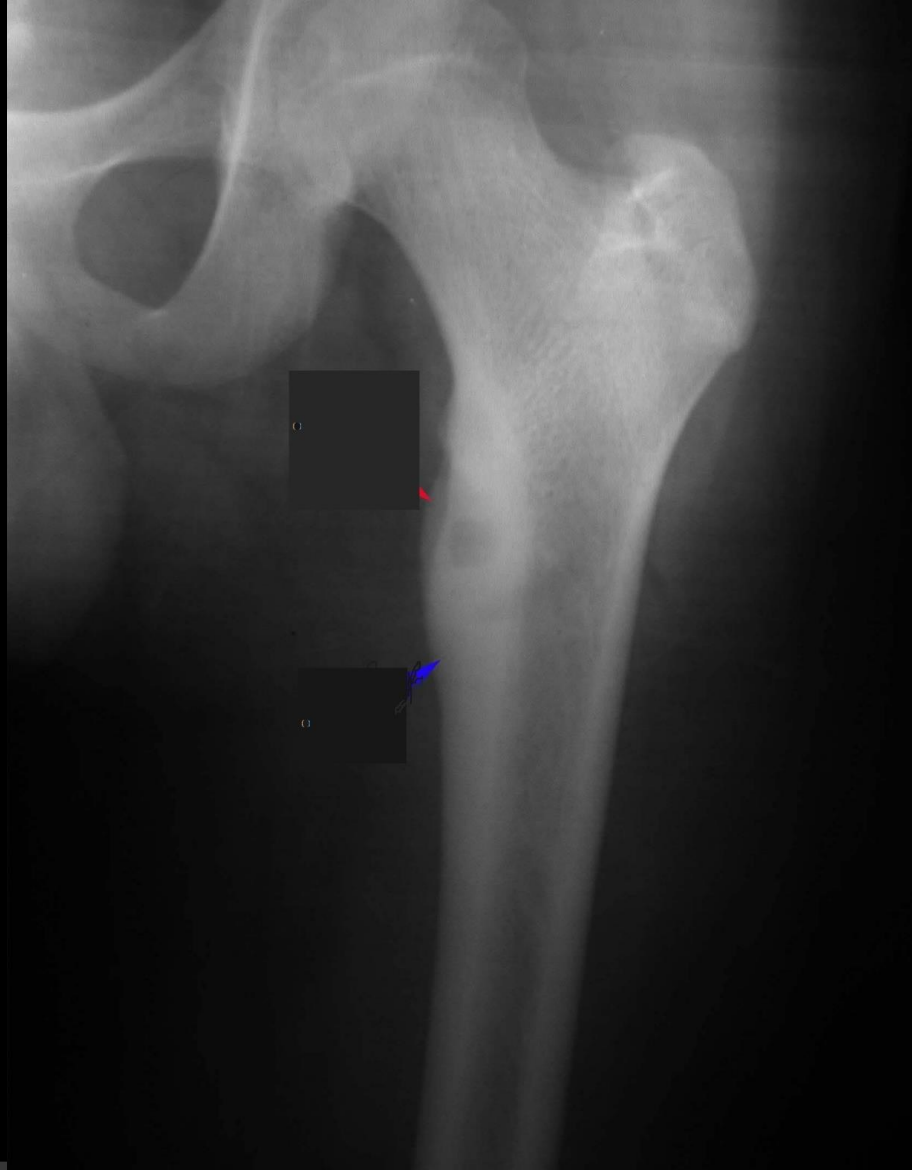
Right



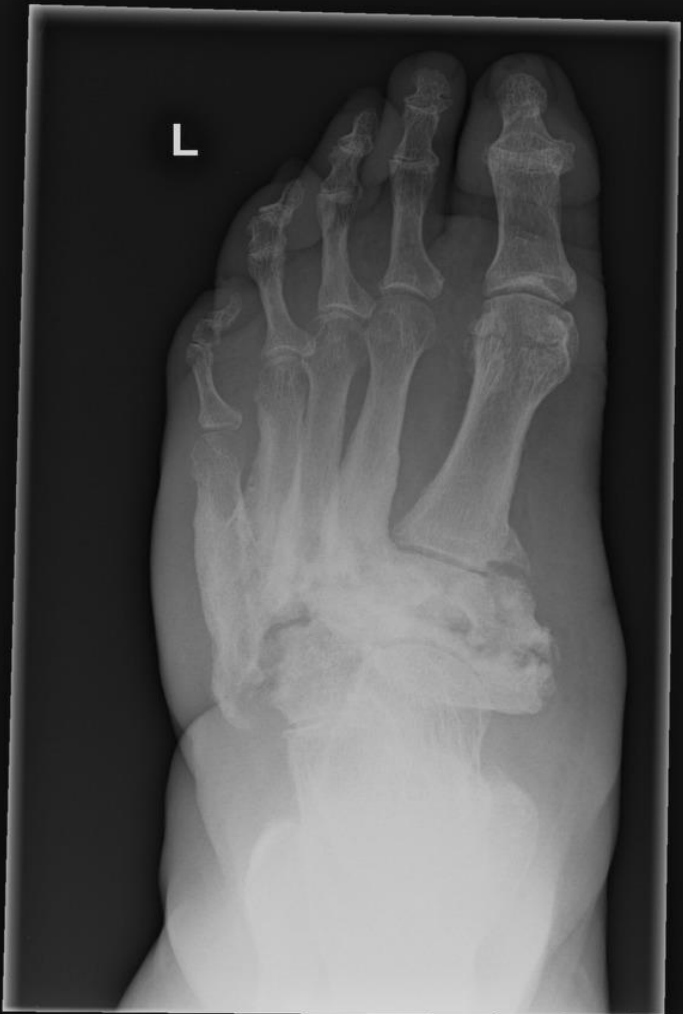6

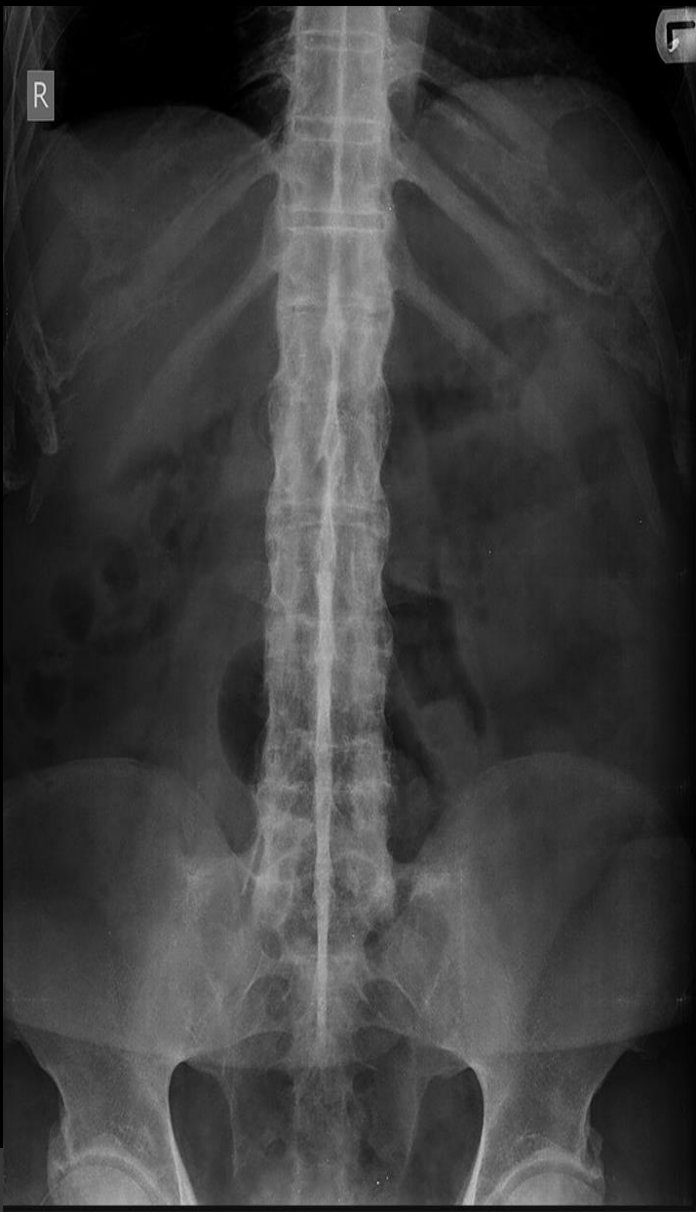

7

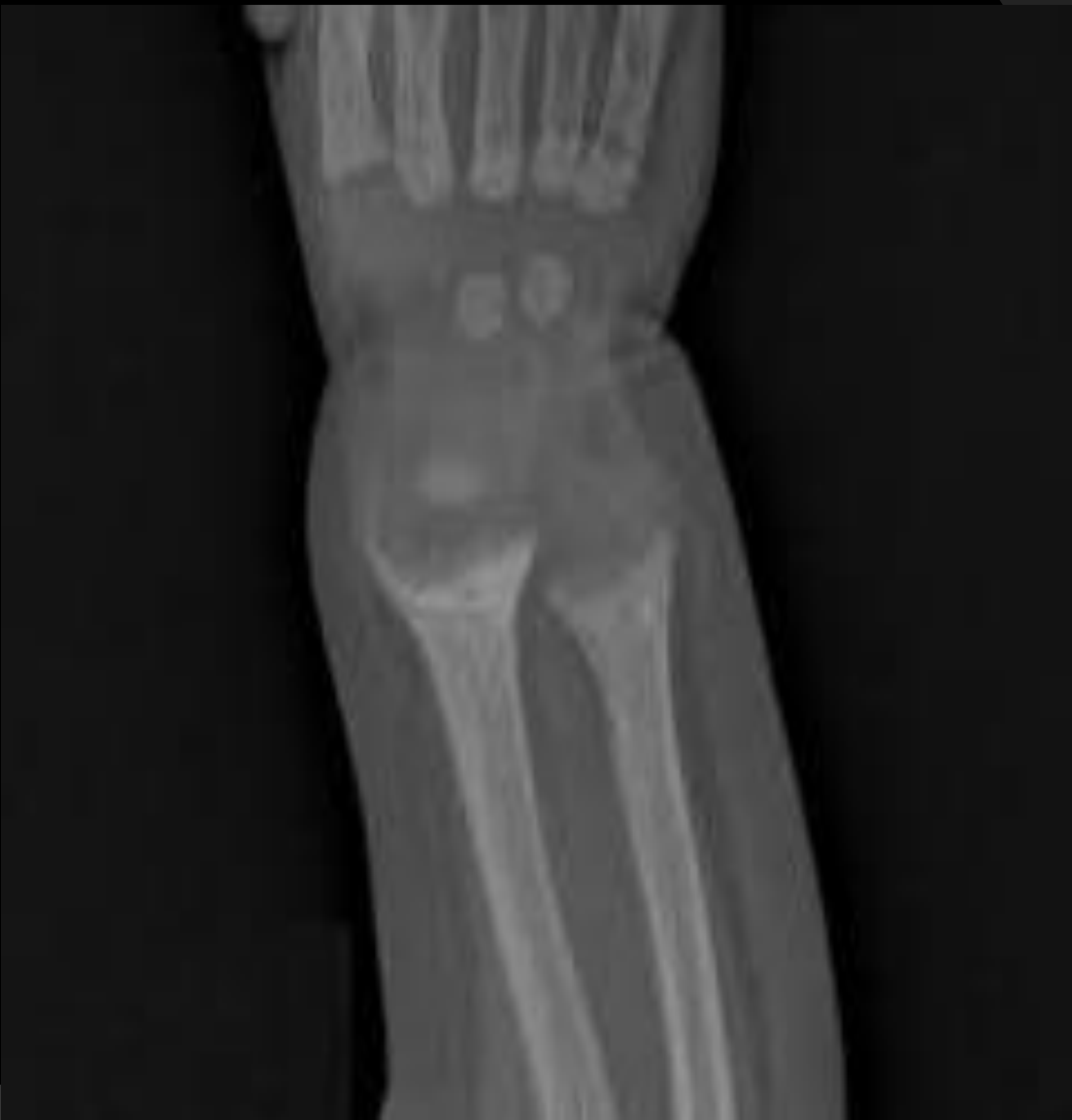

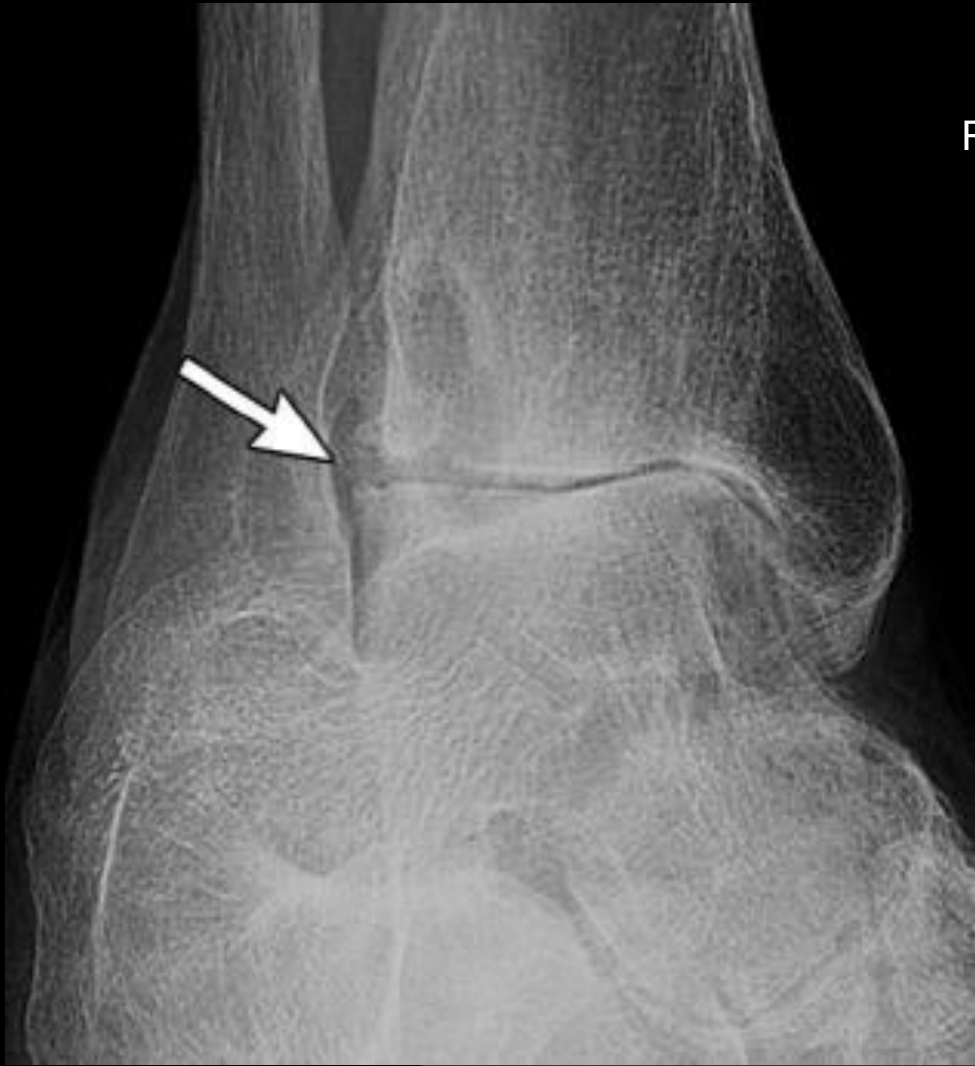8



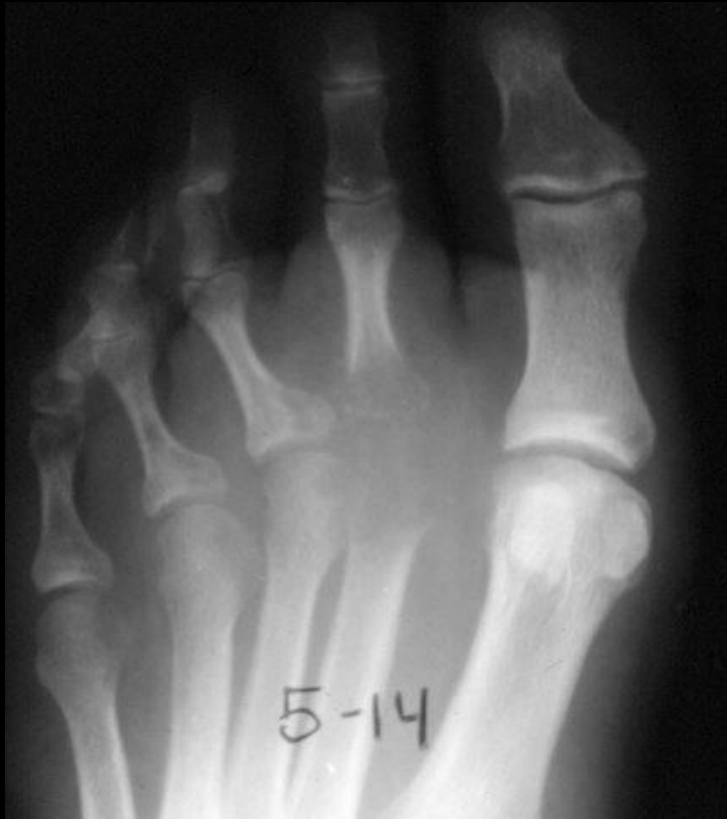

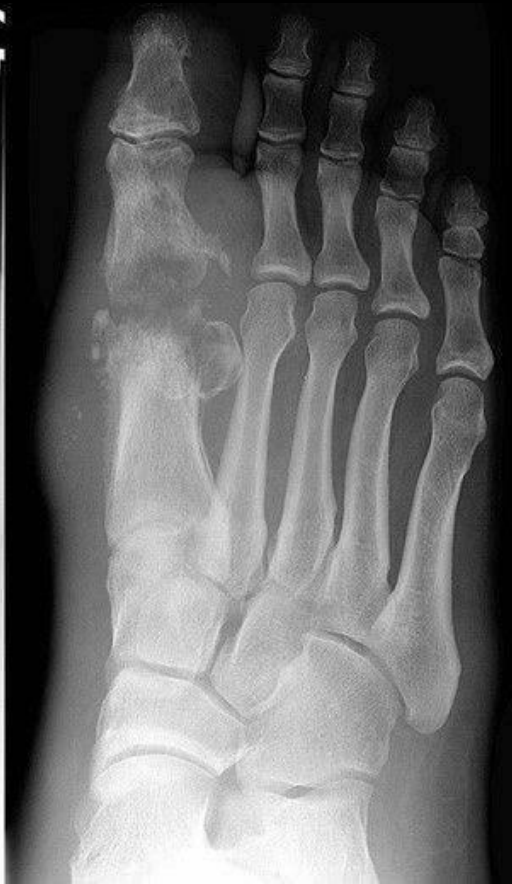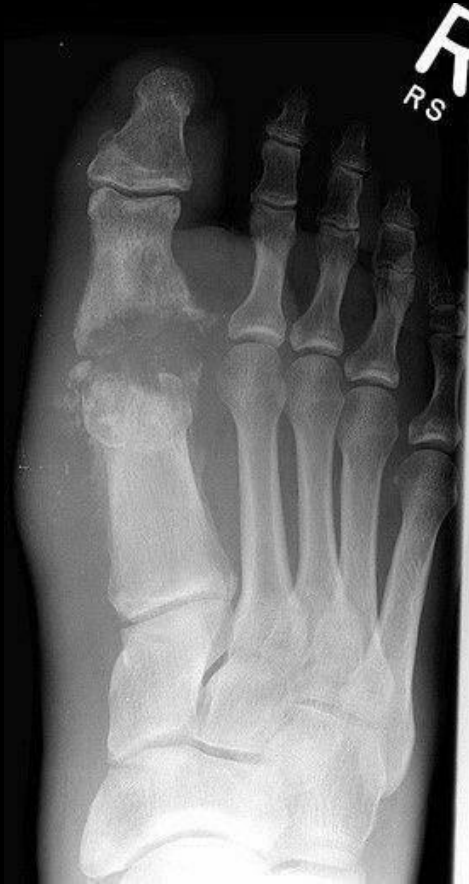Y

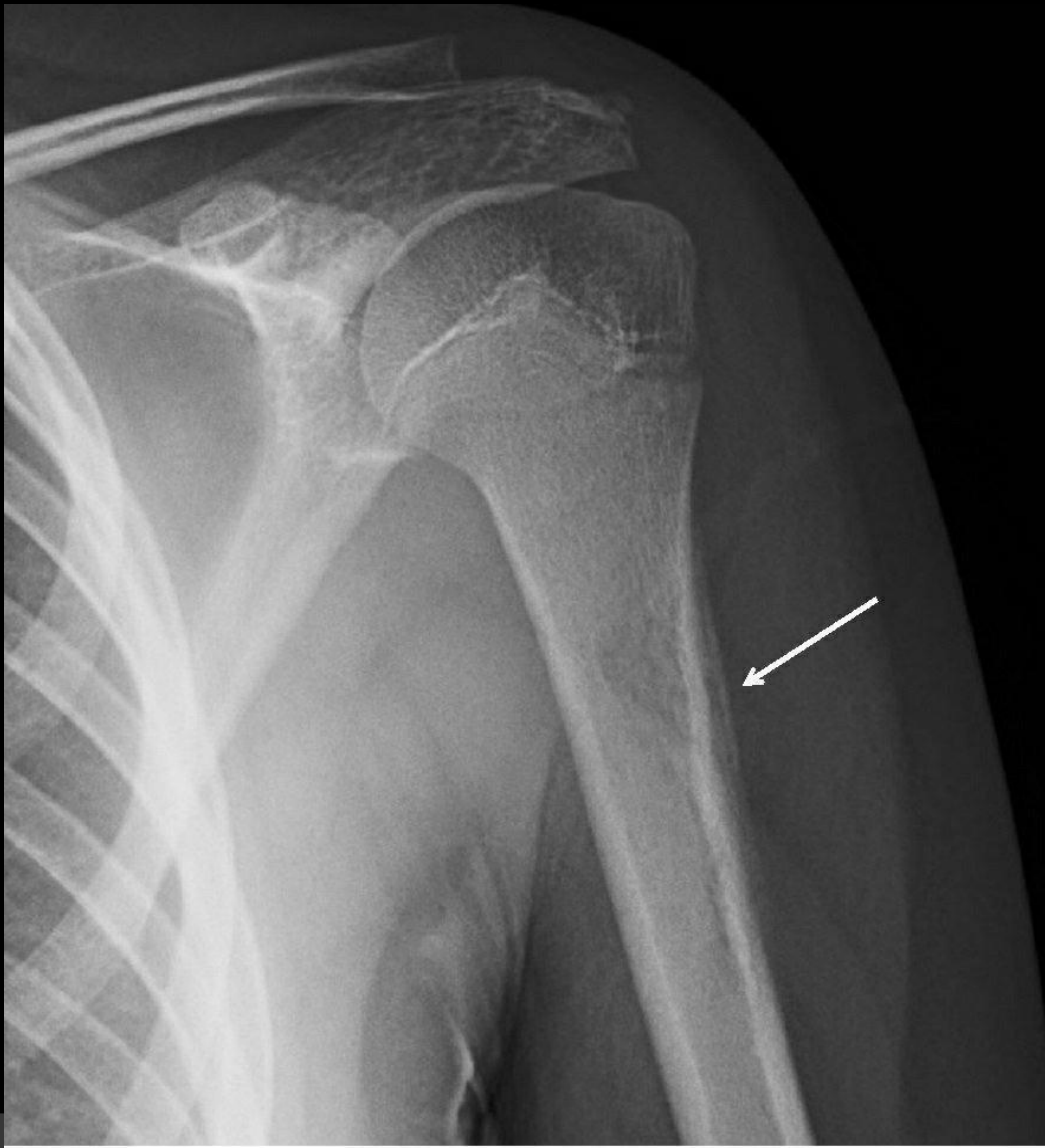


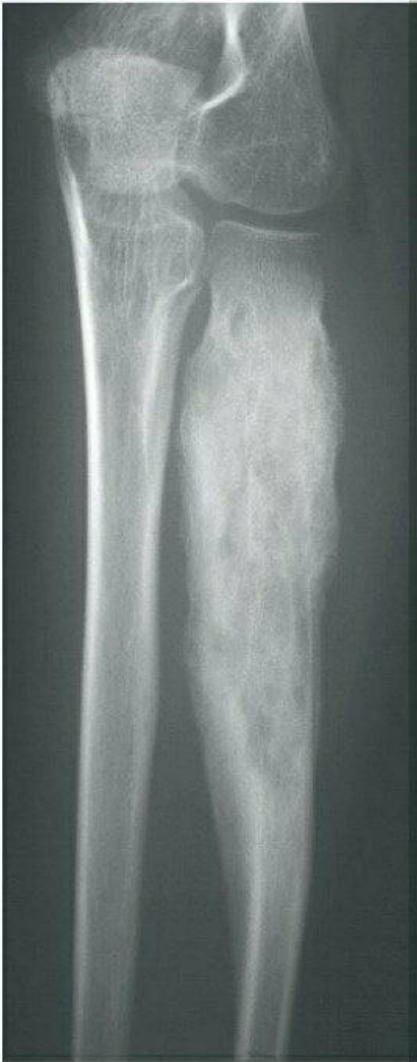

RT









Garre sclerosing osteomyelitis

