Loss of Vision

Laith AlGhazawi

Sudden visual loss

- Acute **transient** visual loss (TVL):
  sudden deficit in visual function in one or both eyes lasting **less than 24 hours**.
- Acute **persistent** visual loss (PVL):
  sudden deficit in visual function in one or both eyes lasting **at least 24 hours.**

Chief complaint

- Loss of vision …
  - uniocular or biocular ?
  - onset? Sudden vs. gradual
  - duration ?
  - any progression?
  - periods of recovery? Intermittent or persistent
  - associated features; visual Sx? Pain? Redness? Neurological Sx? N&V?

Afferent pupillary reflex

- demonstrated by shining a light alternately in one eye and then the other and finding that the direct response to light is more sluggish in the affected eye. The room should be dark, and the patient should fixate on a distant target to prevent miosis due to accommodation.

- The presence of an afferent pupillary defect is fairly **specific for unilateral optic nerve pathology**.

No Light

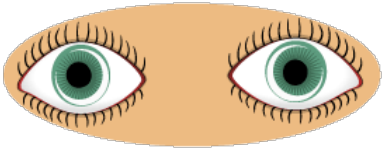

Normal Response to Light

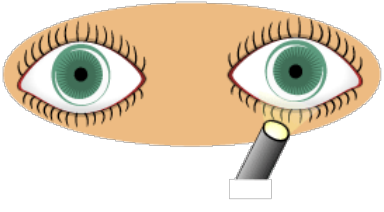

Positive RAPD of Right Eye



Pathology can be broadly divided into three major anatomic categories

1. Media problems
2. Retinal problems
3. Neural visual pathway problems

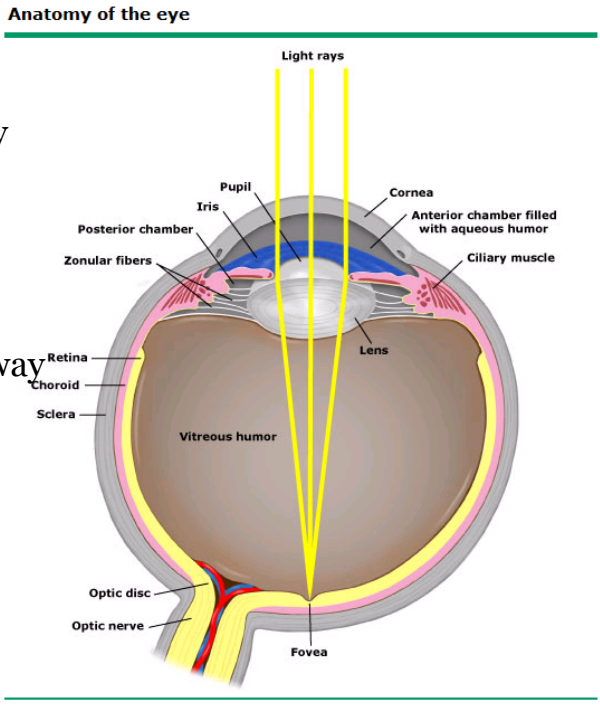

Considerations in diagnosing acute persistent visual loss*

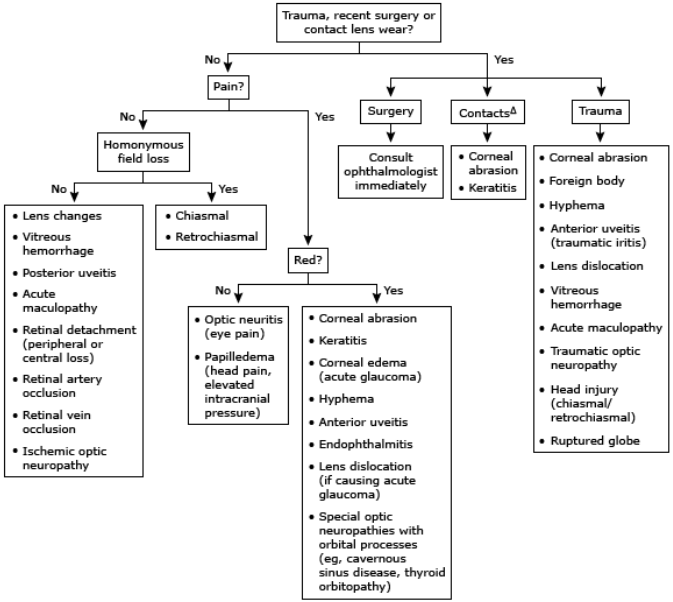

* These are considerations only. Clinical picture must otherwise fit.
∆ While corneal abrasion and keratitis are most common in patients who wear contact lenses, other sources of acute persistent visual loss should be considered if findings do not confirm abrasion or keratitis.

- Fluorescein staining is seen in keratitis, corneal abrasion, and corneal edema.
- Alterations in the red reflex are seen in most media opacities and in retinal detachment.
- Abnormalities in the visual pathways posterior to the optic chiasm can be distinguished by the presence of a homonymous visual field defect, often detectable with confrontation field testing.
- Retrochiasmal tumors may also cause palsy of the sixth cranial nerve.

Media problems:

1. Keratitis.
2. Corneal edema.
3. Hyphema.
4. Lens problems.
5. Vitreous hemorrhage.
6. Uveitis.

- **Keratitis** — Keratitis is inflammation of the cornea due to trauma, abrasive exposure, allergy, or infection. It is marked by cloudiness, irregularity, or loss of epithelial or sub-epithelial corneal tissues. Typically **the eye is tearing, red, and painful or irritated.**
- Loss of epithelial cells is demonstrated by corneal uptake of fluorescein dye, creating a focal or diffuse green glow under a cobalt blue light. Deeper corneal disease may be visible as a focal or diffuse white opacity, or by dulling of the usually distinct reflection of light off of the cornea (corneal light reflex). The most common causes of keratitis are infection (viral, bacterial,

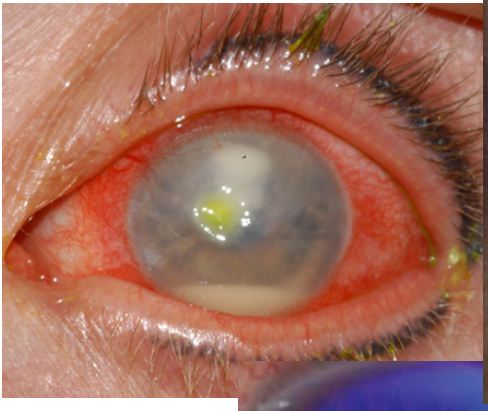

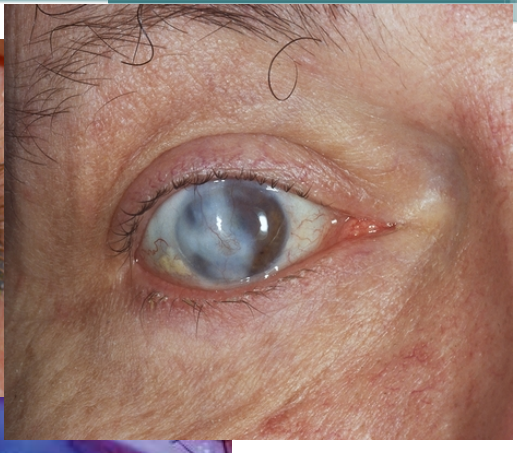

- **Corneal edema** — Corneal swelling results in loss of corneal clarity. Examination may reveal dulling of the corneal light reflex or a frank grey or white color to the substance of the cornea.
- A serious cause of sudden corneal edema is acute angle-closure glaucoma. The patient with severely elevated intraocular pressure (IOP) typically has nausea, vomiting, and may see colored halos around lights. The eye is tearing, red, and extremely painful, often with ipsilateral brow ache. In angle closure, the pupil may be fixed in a mid-dilated position, and biomicroscopic (slit lamp) examination may reveal a shallow anterior chamber. IOP is often

Corneal edema

- **Hyphema** — A hyphema is blood in the anterior chamber. It may result from blunt trauma or may occur spontaneously in a handful of conditions marked by abnormal growth or fragility of iris blood vessels (often in chronic poorly controlled diabetes). Biomicroscopic examination reveals red blood cells circulating and/or layered in the anterior chamber. Intraocular pressure may become dangerously elevated.

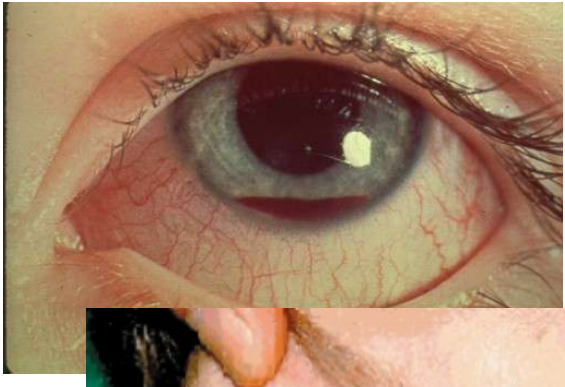

Hyphema

Figure 2: Total hyphema of left eye

- **Lens changes** — Changes in the size, clarity, or positioning of the crystalline lens may alter the focus of light onto the retina, resulting in visual disturbance. Trauma or a variety of congenital conditions can lead to lens dislocation and resultant vision loss. Lens clouding (cataract) does not typically occur acutely, except in the setting of trauma.
- Elevated blood glucose can cause lens swelling, altering the refractive error. If the change is great enough, patients may perceive vision loss. Vision impairment typically resolves within days to weeks of normalization of blood glucose.

- **Vitreous hemorrhage** — Bleeding into the vitreous humor can occur in the setting of trauma, spontaneous retinal tear, spontaneous vitreous detachment, or in any condition with retinal neovascularization (as in poorly controlled diabetes).
- The reduction in vision is directly proportional to the amount of blood in the vitreous. If the hemorrhage is dense enough, there may be a decreased red reflex, or the retina may not be visible with ophthalmoscopy

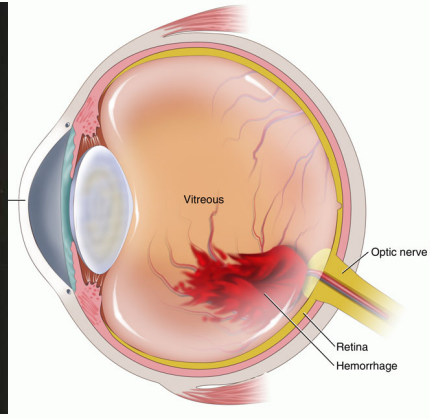

- **Uveitis** — Uveitis is the general term for inflammation inside the eye. Inflammation of the anterior structures of the eye typically are associated with red, painful light sensitivity, whereas isolated inflammation of intermediate and posterior structures may be associated with normal general appearance of the eye with decrease in the red reflex and/or patient complaint of new floaters
- The most important cause of acute persistent visual loss in this category is **endophthalmitis.** Endophthalmitis is a serious bacterial or fungal infection of all intraocular tissues, caused by surface pathogens (usually in the setting of

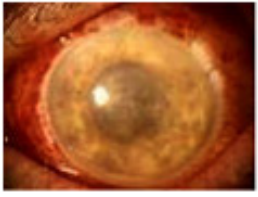

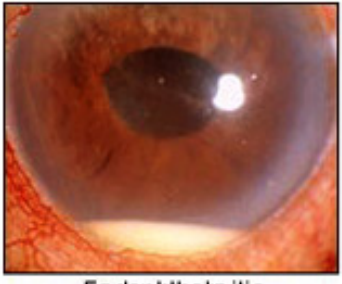

Endophthalmitis

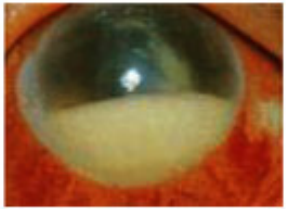

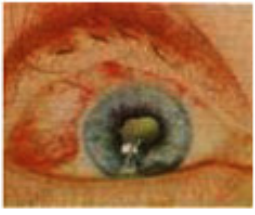

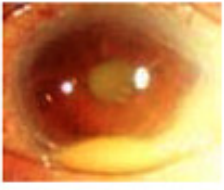

Retinal problems:

1. Retinal artery occlusion.
2. Retinal detachment.
3. Acute maculopathy.

- **Retinal artery occlusion** — Thrombosis, embolism, or arteritis of the central retinal artery results in retinal ganglion cell damage, leading to severe, sudden, painless, central or paracentral visual loss
- Within minutes to hours of the occlusion, the only abnormality noted on ophthalmoscopy may *be vascular narrowing*. An embolus is visible in about 20 percent of patients with central retinal artery occlusion (CRAO) After several hours, the inner layer of the retina becomes ischemic, turning milky white, except in the fovea, which appears as a cherry-red spot. An afferent

Branch Retinal Artery Occlusion

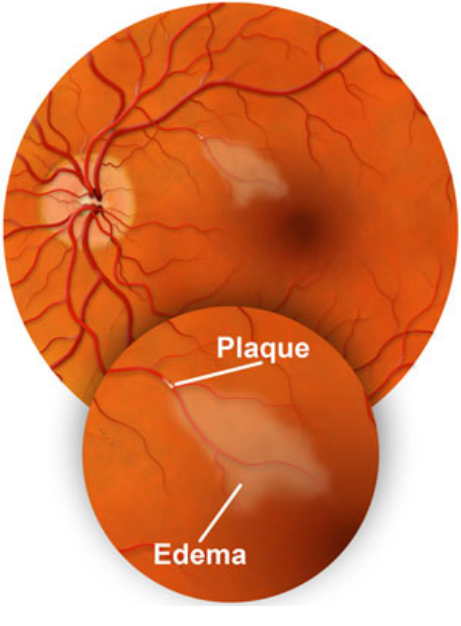

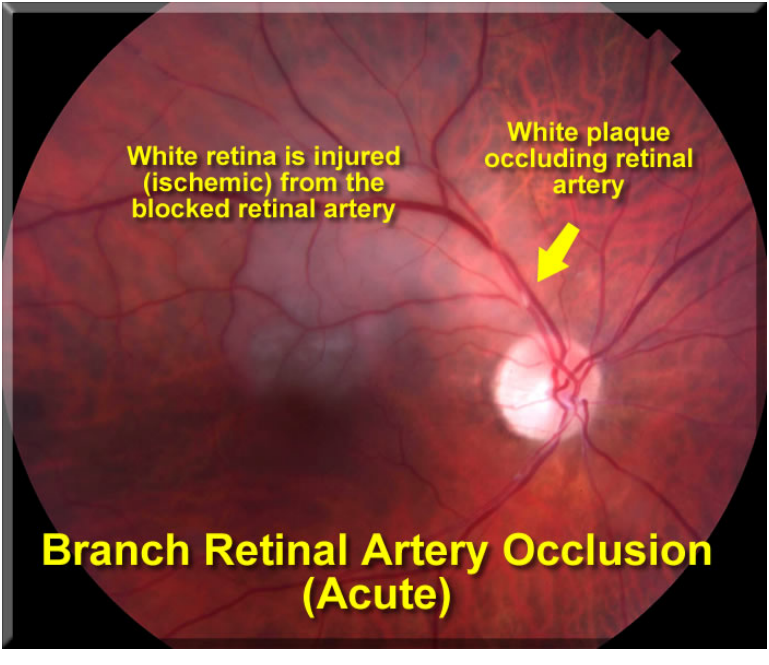
White retina is injured (ischemic) from the blocked retinal artery
White plaque occluding retinal artery
Branch Retinal Artery Occlusion (Acute)

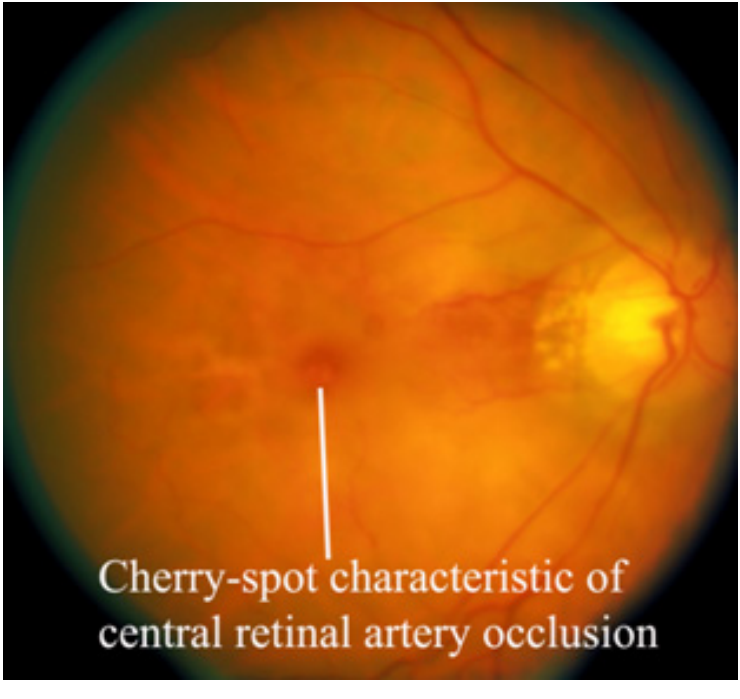
Cherry-spot characteristic of
central retinal artery occlusion

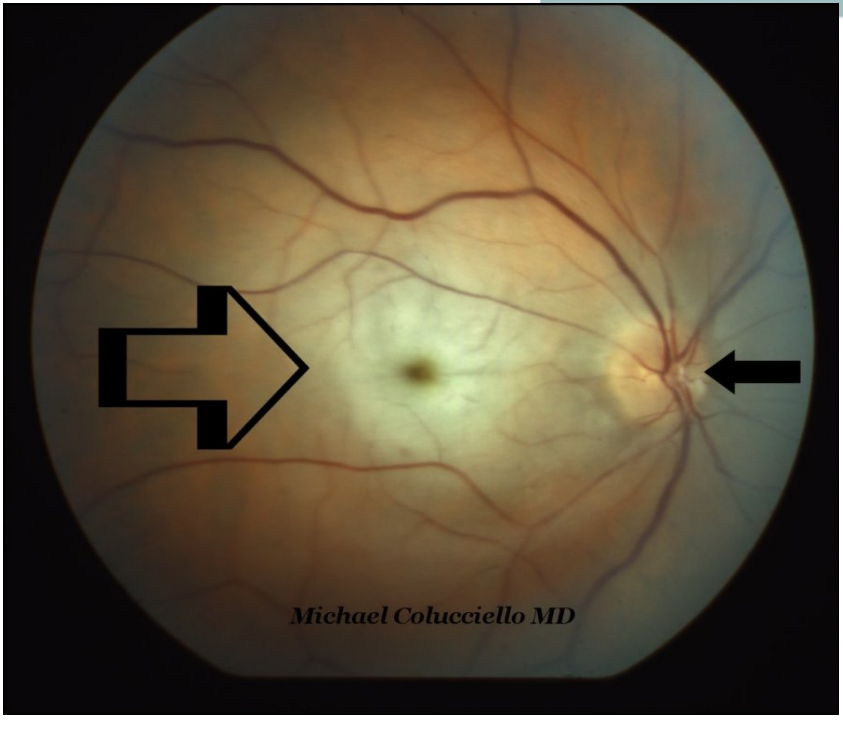
Michael Colucciello MD

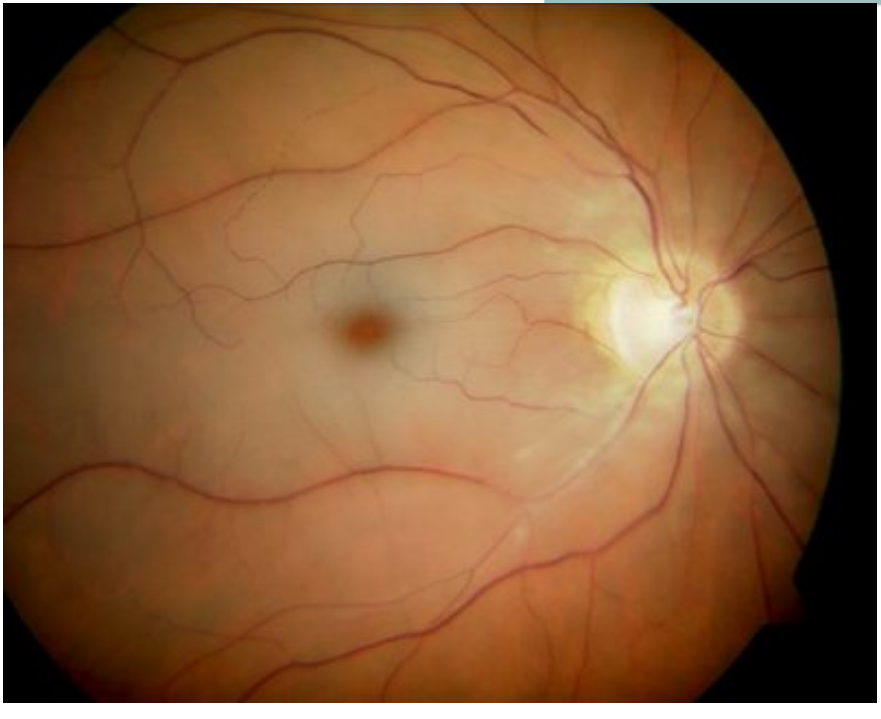

- **Retinal vein occlusion** — Thrombosis of the central retinal vein results in venous stasis, leading to disc swelling, diffuse nerve fiber layer and pre-retinal hemorrhage, and cotton wool spots that create a dramatic appearance, often called "the blood and thunder" fundus Depending upon the degree of ischemia or presence of macular edema, there may be need for retinal laser to prevent further vision loss or intravitreal injections of anti-VEGF agents or corticosteroids to recover vision
- While vision loss may be severe, the onset is typically subacute in contrast to the sudden

Retinal Vein Occlusion

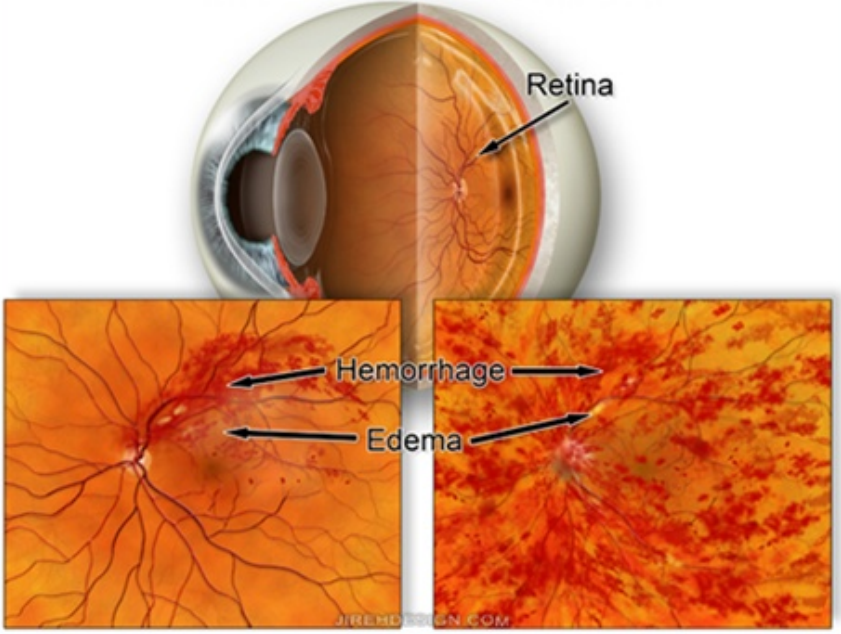

Branch Retinal Vein Occlusion Central Retinal Vein Occlusion

Retinal vein occlusion

"the blood and thunder"

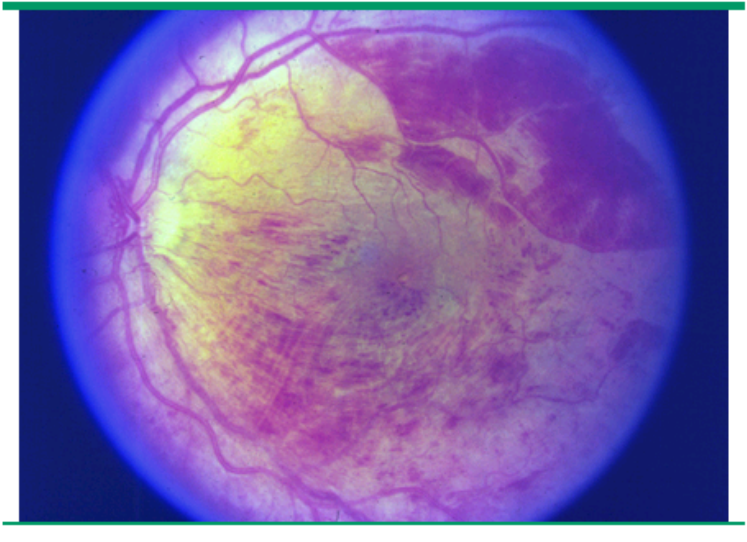

Courtesy of Don C Bienfang, MD.

UpToDate®

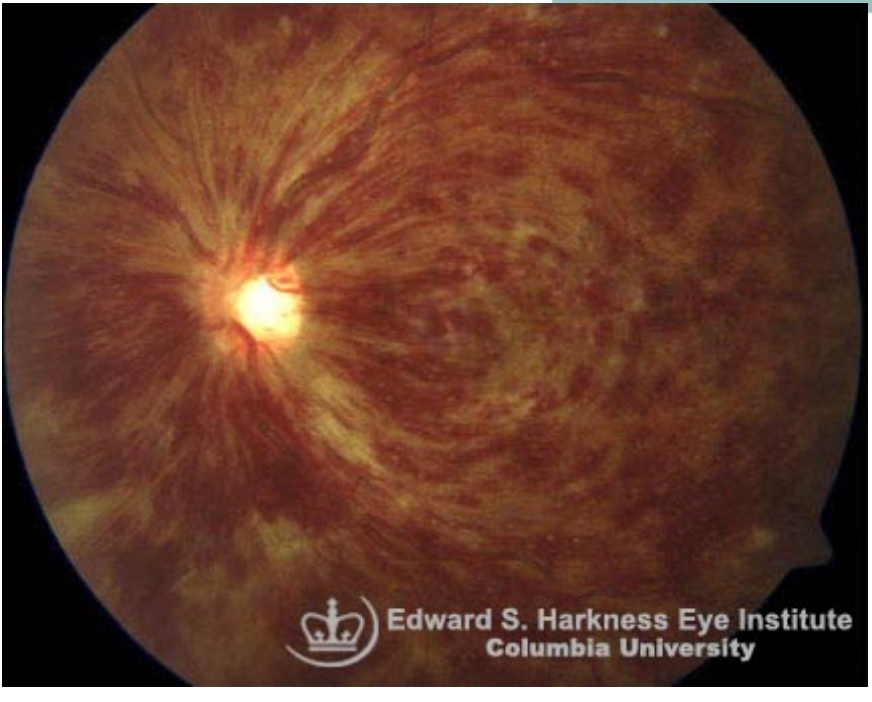
Edward S. Harkness Eye Institute
Columbia University

- **Retinal detachment** — Detachment of the neurosensory retina may occur spontaneously or in the setting of trauma. The most common form is due to a tear or break in the retina. Patients may describe sudden onset of new floaters or black dots in their vision, often accompanied by flashes of light (photopsias). In its early stages, a detachment may present as a persistent missing portion of the monocular visual field. Once the macula (central retina) has become involved, visual acuity will be severely compromised.
- Retinal detachment is ***not painful*** and does not cause a red eye. There may be a dulling of the red reflex, and ophthalmoscopic examination

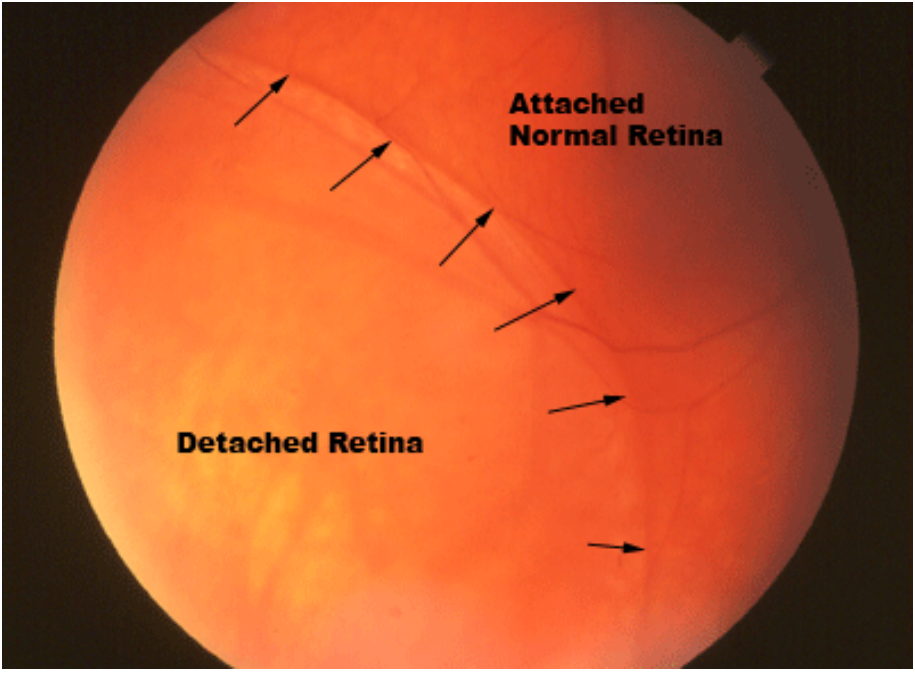
Attached
Normal Retina
Detached Retina

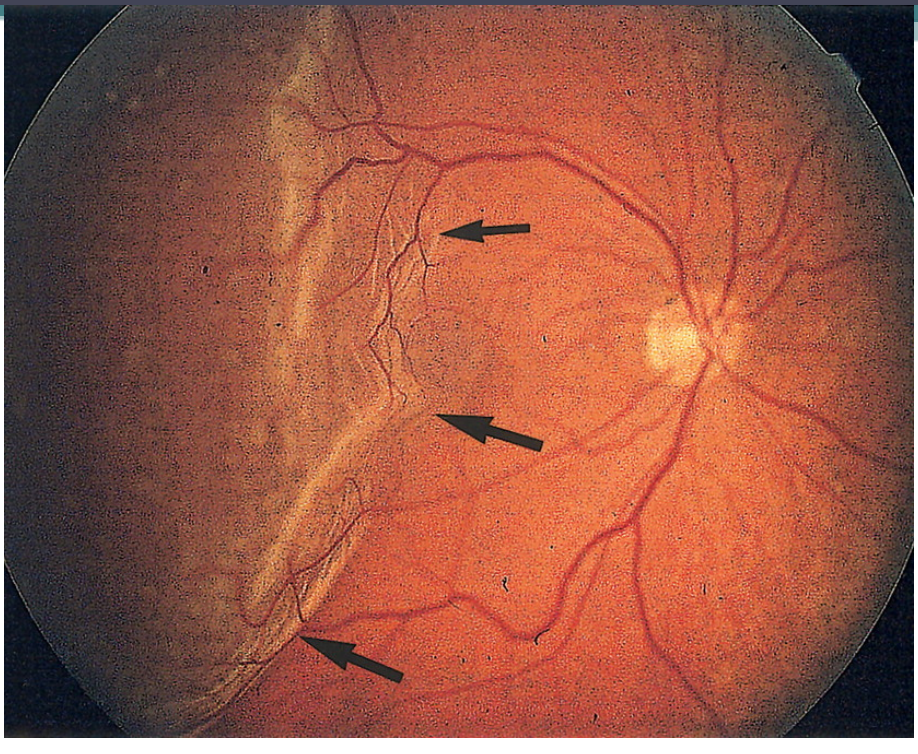

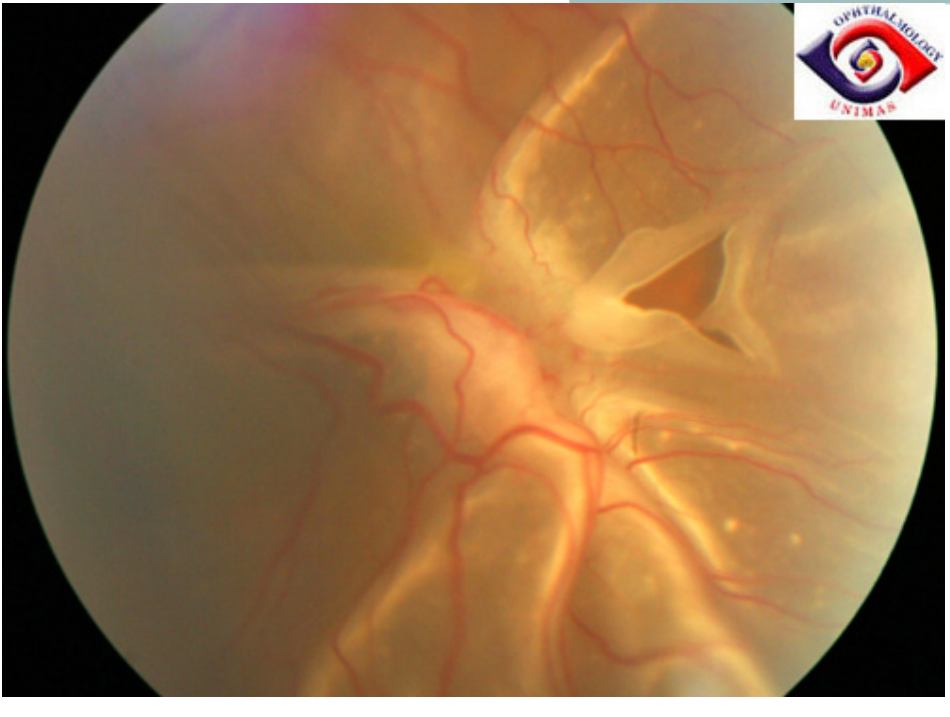

- **Acute maculopathy** — Conditions that affect the macula are associated with a central blind spot (scotoma), blurred vision, or visual distortion. Alteration of the macula due to fluid leakage, bleeding, infection, or other causes can occur de novo or as an acute worsening of a chronic disease (eg, new edema in previously dry diabetic retinopathy, or new bleeding in previously dry macular degeneration). Diagnosis usually requires detailed ophthalmoscopy with a high magnification lens through pharmacologically dilated pupils

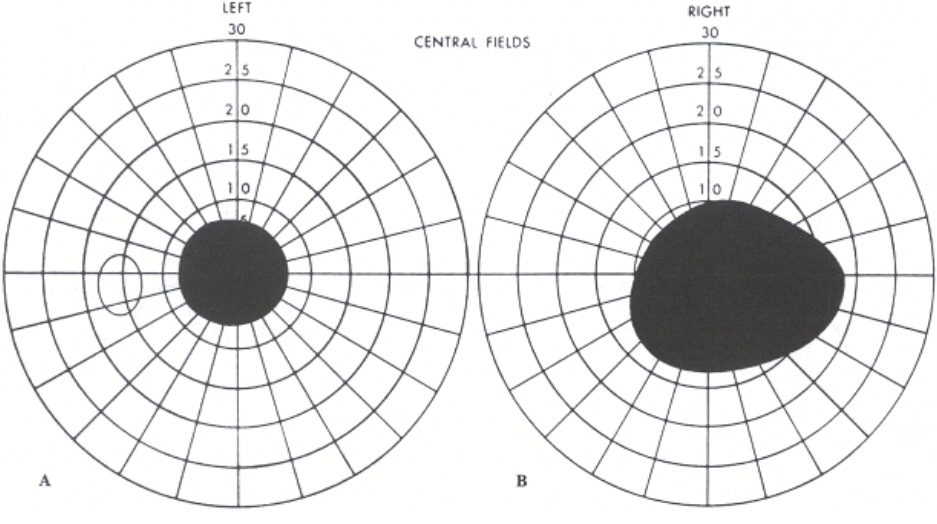
LEFT
30
25
20
15
10
5
CENTRAL FIELDS
RIGHT
30
25
20
15
10
A
B

Optic nerve problems:

1. Ischemic optic neuropathy.
2. Optic neuritis.
3. Papilledema.

Optic nerve problems

- Optic neuritis is the most common cause of optic nerve disease in younger adults.
- while ischemic optic neuropathy is the most common etiology in older patients.

- **Ischemic optic neuropathy** — Ischemic optic neuropathy is generally categorized as anterior (affecting the optic disc) or posterior (retrobulbar) and as arteritic or nonarteritic. Infarction at the optic nerve head due to thrombosis or transient hypotension leads to a superior or inferior altitudinal visual field defect, or diffusely reduced vision.
- An afferent pupillary defect is typically present. In anterior optic neuropathy, the optic disc is swollen, often accompanied by splinter hemorrhages. If nerve damage occurs posterior to the globe, no abnormalities may be seen on

All images: Neil R. Miller, MD

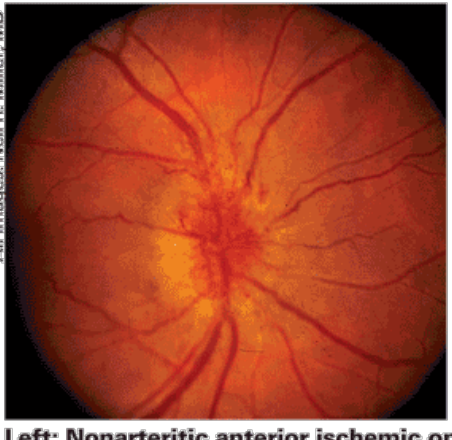

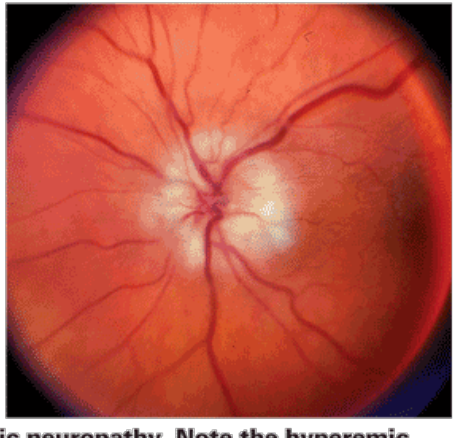

Left: Nonarteritic anterior ischemic optic neuropathy. Note the hyperemic swelling of the optic disc associated with the flame-shaped peripapillary hemorrhage. Right: Arteritic anterior ischemic optic neuropathy. Note the pallid swelling of the optic disc and a peripapillary cotton-wool spot.

- **Optic neuritis** — Inflammation of the optic nerve may be associated with a variety of conditions, most notably multiple sclerosis. Optic neuritis is the presenting feature in 15 to 20 percent of patients with multiple sclerosis, and it occurs at some time during the course of the disease in 50 percent of patients
- Affected patients note pain on eye movement, reduced visual acuity and washed out color vision. An afferent papillary defect is typically present, and the optic disc is either normal or swollen

Optic neuritis fundus

Papillitis: Note the absence of hemorrhages and exudates in the setting of optic neuritis.

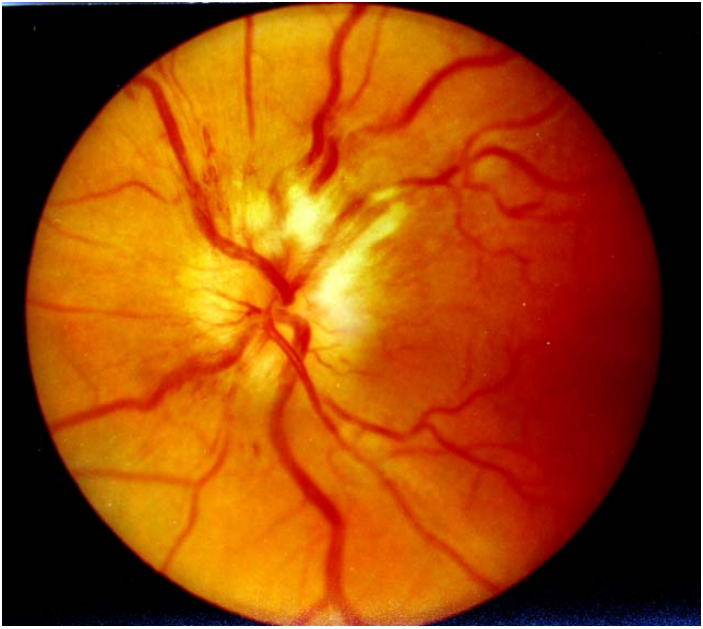

- **Papilledema** — Elevated intracranial pressure can lead to transient visual obscurations or mild persistent blurred vision. Examination reveals bilateral optic nerve swelling without relative afferent papillary defect.

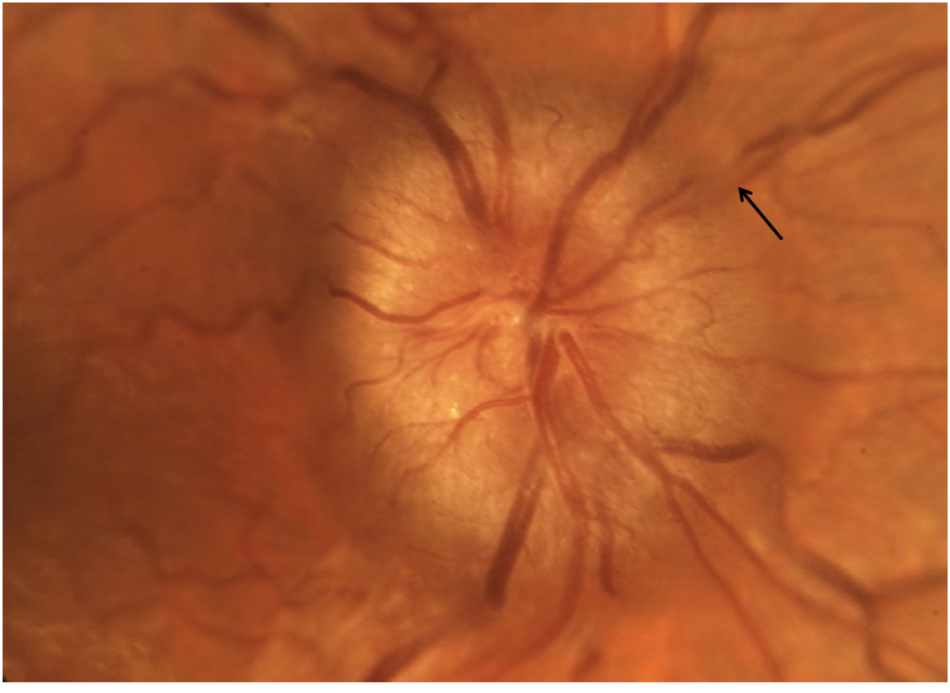

Figure 8. Grade III papilledema is characterized by Loss of major vessels as they *leave* the disc (arrow).

Chiasmal problems

- Involvement of the chiasm is suggested by visual loss of any type associated with pituitary dysfunction or by **a monocular or bitemporal hemianopia.**
- Compressive chiasmal lesions typically cause gradual decline in vision, as they impinge upon the chiasm, optic nerve, or optic tract. Peripheral vision loss is often asymptomatic until visual acuity is compromised; therefore, most visual complaints are of gradual blurring or dimming of vision. **Sudden chiasmal vision loss is**

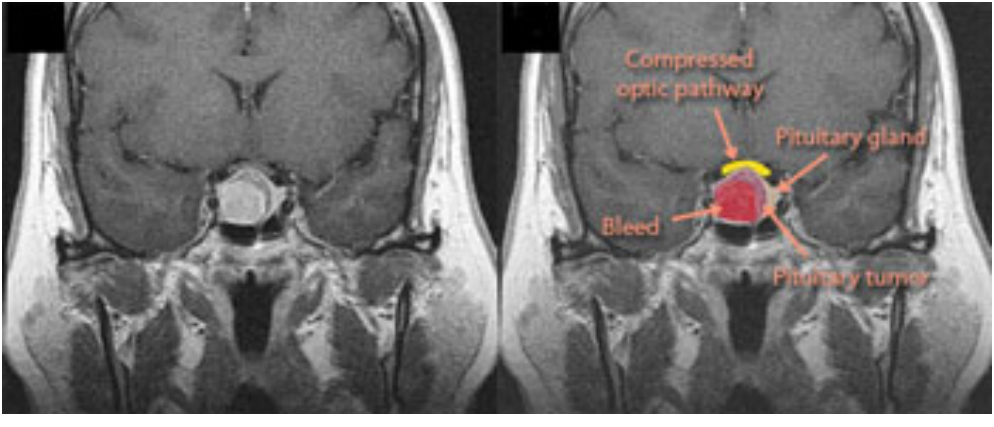
Compressed
optic pathway
Pituitary gland
Bleed
Pituitary tumor

Retrochiasmal disorders

- **Homonymous hemianopia** — Brain lesions in the region of the optic tract, the lateral geniculate body, the optic radiations, or the visual cortex produce a loss of vision on one side of both visual fields
- The visual field defect is relatively symmetric and respects the vertical midline. No other abnormalities are seen on ophthalmic examination. The most common cause is stroke or hemorrhage into a brain tumor.

Anatomy of the visual pathways and visual field correlation (view of underside of brain)

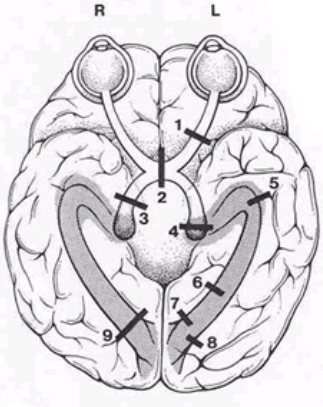

	Location	Field Defect: Left Eye	Field Defect: Right Eye	Comment
1	Left Optic Nerve			No light perception left eye
2	Chiasm			Bitemporal hemianopsia
3	Right Optic Tract			Incongruous left homonymous hemianopia
4	Left Lateral Geniculate Nucleus			Right homonymous sectoranopia (lateral choroidal artery) - or - Incongruous right homonymous hemianopia
5	Left Temporal Lobe			Right homonymous upper quadrant defect ("pie in the sky")
6	Left Parietal Lobe			Right homonymous defect, denser inferiorly
7	Left Occipital Lobe (upper bank)			Right homonymous lower quadrananopsia (macular sparing)
8	Left Occipital Lobe (lower bank)			Right homonymous upper quadrananopsia (macular sparing)
9	Right Occipital Lobe			Left homonymous hemianopia (macular sparing)

Retrochiasmal disorders

- **Cortical blindness** — Extensive bilateral damage to the cerebral visual pathways may result in complete loss of vision. Rarely, patients may confabulate and deny blindness, exhibiting a condition known as Anton syndrome. Other than blindness, no other abnormalities are seen on ophthalmic examination

Psychogenic problems

- Patients describing visual loss without an organic basis are said to have "functional" visual loss. Patients who are purposely feigning blindness are malingerers, whereas those who truly perceive blindness have a conversion disorder.
- The visual loss may be monocular or binocular, total or sub-total.
- Malingerers have been known to pharmacologically alter pupillary function.
- Once organic disease has been ruled out

Immediate treatment is required for

- Acute central retinal artery occlusion:
  within a window of 100 min, immediate attempt to lower the intraocular pressure with digital massage, paracentesis, or pharmacologic agents.
- Intraocular pressure greater than 40 mmHg with eye pain
- Vision loss in the setting of suspected giant cell arteritis
  started on methylprednisolone 1000 mg IV daily for one to three days, followed by prednisone 60 mg/d for two to four weeks

Emergent referral is required for

- Infectious keratitis
- Endophthalmitis
- Hyphema
- Retinal detachment

Urgent referral (within 24 to 48 hours) is appropriate for:

- Non-infectious uveitis
- Vitreous hemorrhage
- Acute maculopathy
- Central retinal vein occlusion
- Optic neuritis

- Visual manifestations of intracranial pathology (stroke, tumor, bleed, or elevated intracranial pressure) should be treated in the appropriate neurological or neurosurgical fashion

Thank you