▲ Reduction

→ Your target : **Anatomical** vs. **Functional**

- Anatomical → Anatomy is 100% restored → usually achieved by surgery → So risk of surgery + Compromise vascularity of the fracture] → that's why we don't do it always only when needed → intra-articular fractures + forearm in adults.
  - → to ↓↓ Risk of 2° OA
  - → in peds functional growth potential
- Functional
  - → we restore only the functional.
  - → Anatomy isn't 100% restored / rather we restore acceptable : Length , Alignment and Rotation (Angulation)
    - → "certain range" depending on the site and the age of the patient.
      - → called : The functional range.
    - → = Not affecting the function.

→ How it's done : open vs. closed , Direct vs. indirect

▲ Immobilization (= fixation) → Casts / splints / nails / screws / plates / wires .....

→ **Absolute** vs. **Relative** → Allows from some movement at the fracture site.

- → needed in intra-articular fractures → in order to mobilize early and avoid 2° joint stiffness
- → Doesn't allow any movement on the fracture site or movement less than 1mm

▲ Rehab.

→ when to start ? depending on the degree of fracture healing and stability

→ The Aim is to start as early as possible.

→ What's needed for any fracture to heel ?

Blood supply + Contact + Stability → (Absolute / relative / instability)

- Contact → No soft tissue or space in between
- Stability → The major factor that determines the type of healing → primary vs. secondary vs. none

---

* Secondary bone Healing / Healing by Calus formation / indirect bone healing :-

Fracture → bleeding and hematoma formation (first 24 hrs) → inflammation → fibrous tissue formation → Remove fibrous tissue and lay some cartilage (soft Calus / nth on x-ray) → Replaced by woven bone (hard Calus formation) → consolidation of the fracture (woven bone is converted into mature lamellar bone)

- bleeding → from small blood vessels of periosteum and endosteum ... and small arteries inside the bone cavities
- inflammation ← triggered by movement → Relative Stability.
- hard Calus formation → appears on X-ray
- Clinically: كيف نعرف انها تكونت ؟ - Pain resolves + - Fracture become relatively stable (moves as one piece) → يعني مو ضروري MRI

→ **Remodeling**

- → (Re-shaping of the calus / may takes years / Dependant on stress applied to bone [wolff's law])
  - → What you don't use you lose
- → (capacity of Remodeling is dependant on the age of the pt + site of the fracture)
  - → According to this the functional range is determined.
    - → the acceptable range of functional reduction
- → Best [younger] and closer to growth plate.

* Resembles endochondral ossification.

skeletally mature vs skeletally immature

both are skeletally mature ← 60 وواحد 30 لأنه ما بيزيد بيت واحد عمود

* Notes :

- if the pt has fracture and assigned for surgery it's either done within the first 24 hrs (hematoma stage) or after 7 - 10 days (after the end of the inflammatory stage), As you won't be able to close the wound of edematous tissue
- it's preferred not to give NSAIDs during the inflammatory phase → give paracetamol or narcotics.
- Orthopedic unit and it's derivatives ⇒ till hard calus formation (time till healing)
  - ↳ Time needed for Consolidation is double the time needed for healing
- Hematoma and necrotic tissue causes the release of cytokines that causes attraction of macrophages
  - ↳ fracture edges become necrotic

> • time needed for upper limb fracture to heal : 6 wks.
> • time needed for Consolidation (wt bearing) : 12 wks.

---

* Primary bone healing / Direct bone healing / healing by cutting bone formation :-

↳ (Absolute stability or fractures with gap less than 2 mm)

- No hematoma (خطا خلية وتخثرا طلعت), No minimal movement ⇒ Thus no inflammatory response
- necrotic fracture edges must be removed ⇒ This is done by osteoclast [cuts through the bone till reaching the fracture site] → And then osteoblas builds new bone ⇝ (Continous process of coupled bone resorption and bone formation)
- No Calus formation.
- So process is carried out by the Metabolizing unit →

> • Bone metabolizing units, at the frontal end, contain **cutting cones**
> • Lined by multicelluar osteoclasts.
> • Linear rate of bone resorption 50ṵm/ day.
>
> • Behind them, walls of osteons are lined by osteoblasts
> • Oppose new osteoid at 1ṵm/day

---

* Methods of absolute stabilization : (only these 3)

1- Lag Screw or Compression screw
2- Compression plate
3- tension band wiring.

Complications of fracture healing

1. Malunion:

Good healing but in an inappropriate position thus compromising function.

Treatment: osteotomy (surgically breaking the bone) and fixation in the correct position.

2. Nonunion:

2 types; hypertrophic where the problem lies in inadequate stability of the fracture site (gross mobility so the callus is formed but cannot hold the ends together),

And atrophic where the problem lies in inadequate vascularity at the fracture site causing necrosis at the fracture ends and minimal capacity fo r the fracture to heal.

→ compromized by : smoking / DM / open fractures / infections / Extensive surgical approaches .....

Hypertrophic Nonunion

Hepertrophic fracture ends on the radiographs (elephant foot or horse hoof appearance).

Treatment: surgical stabilization of the fracture. (مثلا لما)

كل جزء من الـ fracture اتعمله Calus (Pseudojoint) لحاله ولما ارتبطوا مع بعض

Fracture after 6 mo.

Atrophic Nonunion

No callus formation is seen, in long standing cases pencil like appearance of the fracture ends on the radiograhps could be seen.

Treatment: ① debridement of the necrotic bone ends, ② bone grafting, and ③ fixation.

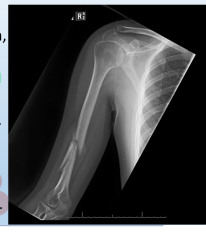

you keep removing dead bone (white bone) untill bone-bleeding → Paprika sign: (small red dots on the bone → = viable bone)

* Types of simple fractures according to shape : Transverse , oblique , spiral

The slowest.

fastest healling bcz of :

1- Higher surface area
2- mild soft tissue injury