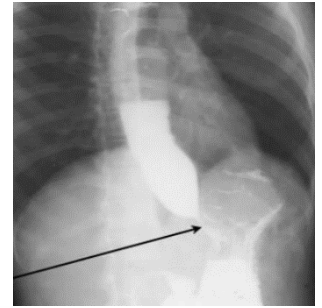


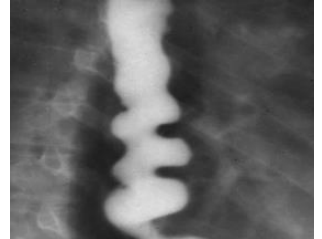Bird's beak sign

A finding in **barium swallow** test in the setting of **achalasia** (esophageal aperistalsis and failure of the lower esophageal sphincter to relax).



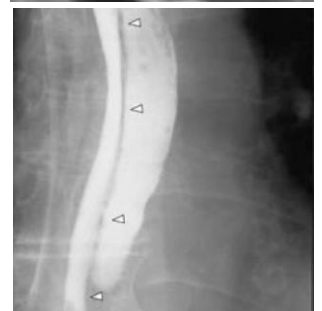Corkscrew sign

A finding in **barium swallow** test in the setting of **diffuse esophageal spasm** (simultaneous, **non**-peristaltic contractions of the esophagus).



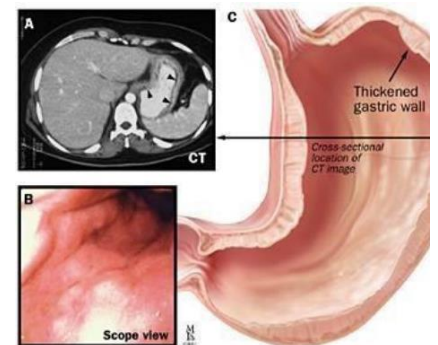
Double barrel esophagus

A finding in **barium swallow** test in the setting of **esophageal dissection**.



Leather bottle stomach (linitis plastica)

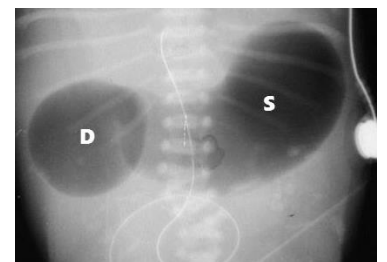
Diffuse subtype of adenocarcinoma invading throughout the stomach, resulting in the thickening and rigidity of the stomach wall (seen on CT), making the stomach indistensible like a bottle (seen in barium swallow tests).



A: a CT image of Linitis plastic (arrows denote a thickened gastric wall).

Double bubble sign

A finding on **abdominal -X-ray films** of infants and newborns in the setting of **duodenal obstruction** (e.g., duodenal webs, duodenal atresia, malrotation of the gut (because of Ladd bands and/or the presence of a midgut volvulus (with **whirlpool sign** on U/S)).



String of beads (or pearls)

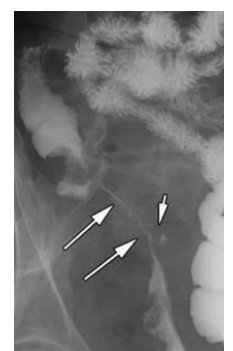
A finding on **abdominal -X-ray films** in the setting of a **small-bowel obstruction**.

Cobblestone sign

A finding in **fluoroscopic studies** in the setting of an acute exacerbation of **Crohn's disease**.

String sign

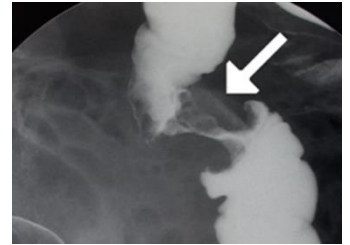
A finding on **abdominal -X-ray films** in the terminal ileum in the setting of **Crohn's disease**.



String sign

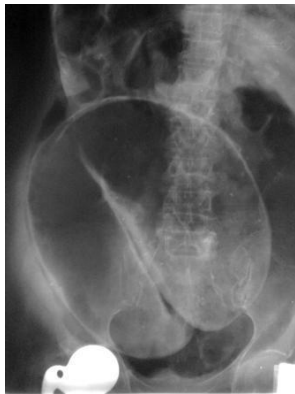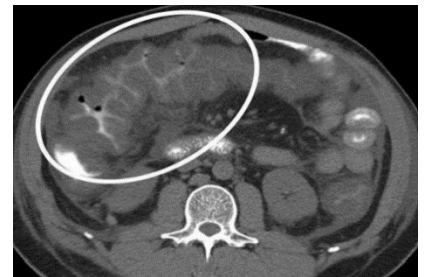Apple core sign

A finding in **barium studies** in the setting of **colon carcinoma**.



Accordion sign

A **CT** finding for *Clostridium difficile*-induced **pseudomembranous colitis**.

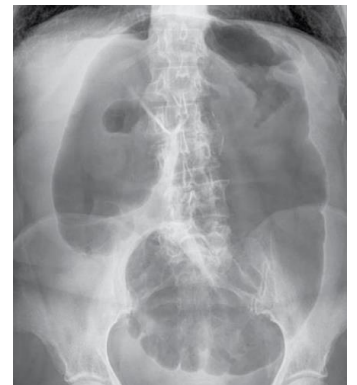


Coffee bean sign

A finding on supine **abdominal -X-ray films** in the setting of **sigmoid volvulus**.

Embryo sign (comma sign)

A finding on supine **abdominal -X-ray films** in the setting of **cecal volvulus**.

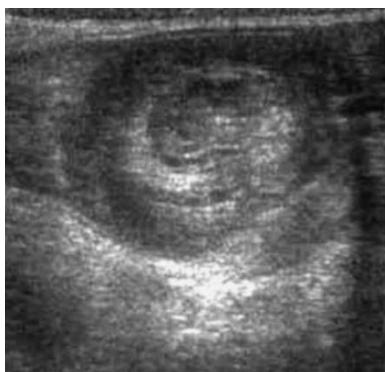

Doughnut sign, bull's eye sign, or target sign

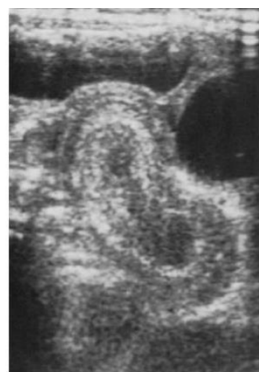An **ultrasound** finding in the setting of **intussusception**.

Pseudokidney

The longitudinal **ultrasound** finding of **intussusception**.



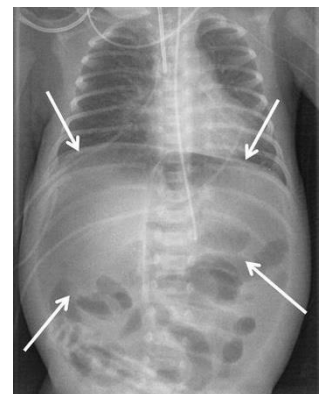
Target sign or donut sign (transverse)



Pseudo kidney sign (longitudinal)

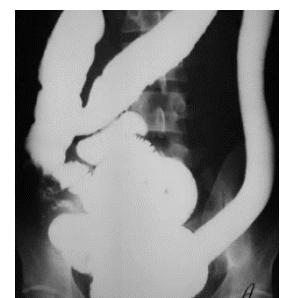Football sign

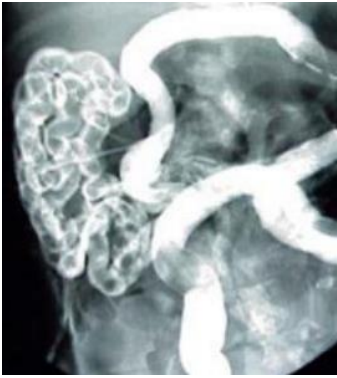A finding on **abdominal -X-ray films** in severe **pneumoperitoneum** (extra-visceral free air) most frequently in infants with perforation (e.g., as in complicated necrotizing enterocolitis).



Lead pipe sign

A finding in **barium studies** in the setting of **ulcerative colitis**.



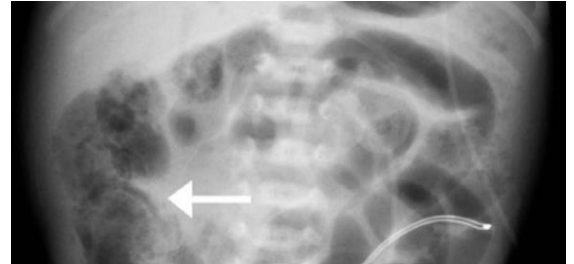


Neuhauser sign (soap bubble appearance of MI)

A finding on **abdominal -X-ray films** in the distal ileum in cases of meconium ileus (with **mottled** appearance of the meconium).

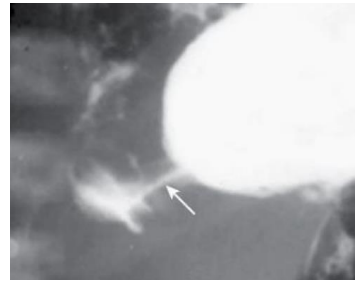
Soap bubble appearance

A finding on **abdominal -X-ray films** in the setting of **necrotizing enterocolitis**.



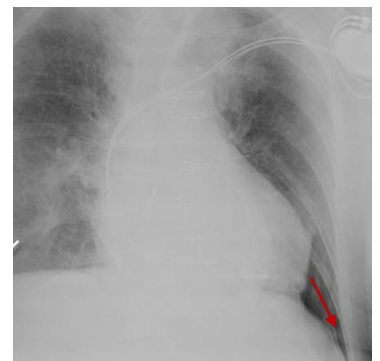
Double track sign

A finding in **barium studies** in the setting of **hypertrophic pyloric stenosis**.



Deep sulcus sign

A finding on supine **chest -X-ray films** in the setting of a pneumothorax.



Westermark sign

A finding on supine **chest -X-ray films** in the setting of a pulmonary embolus.

