

PRINCIPLES OF CANCER MANAGEMENT



720p will apply to your current video

Treatment

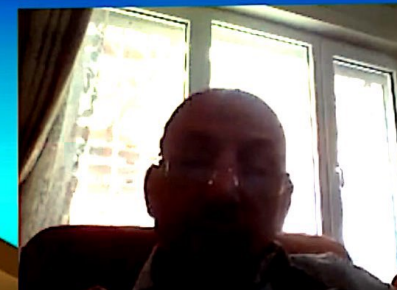
surgery

Radiotherapy

Chemotherapy

Hormonal Therapy

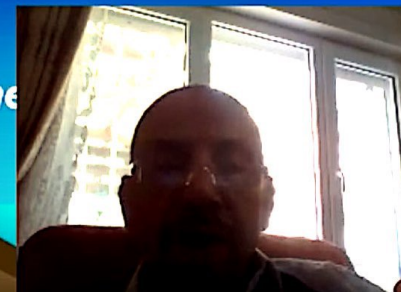
(single or multimodality)



Surgical Oncologist

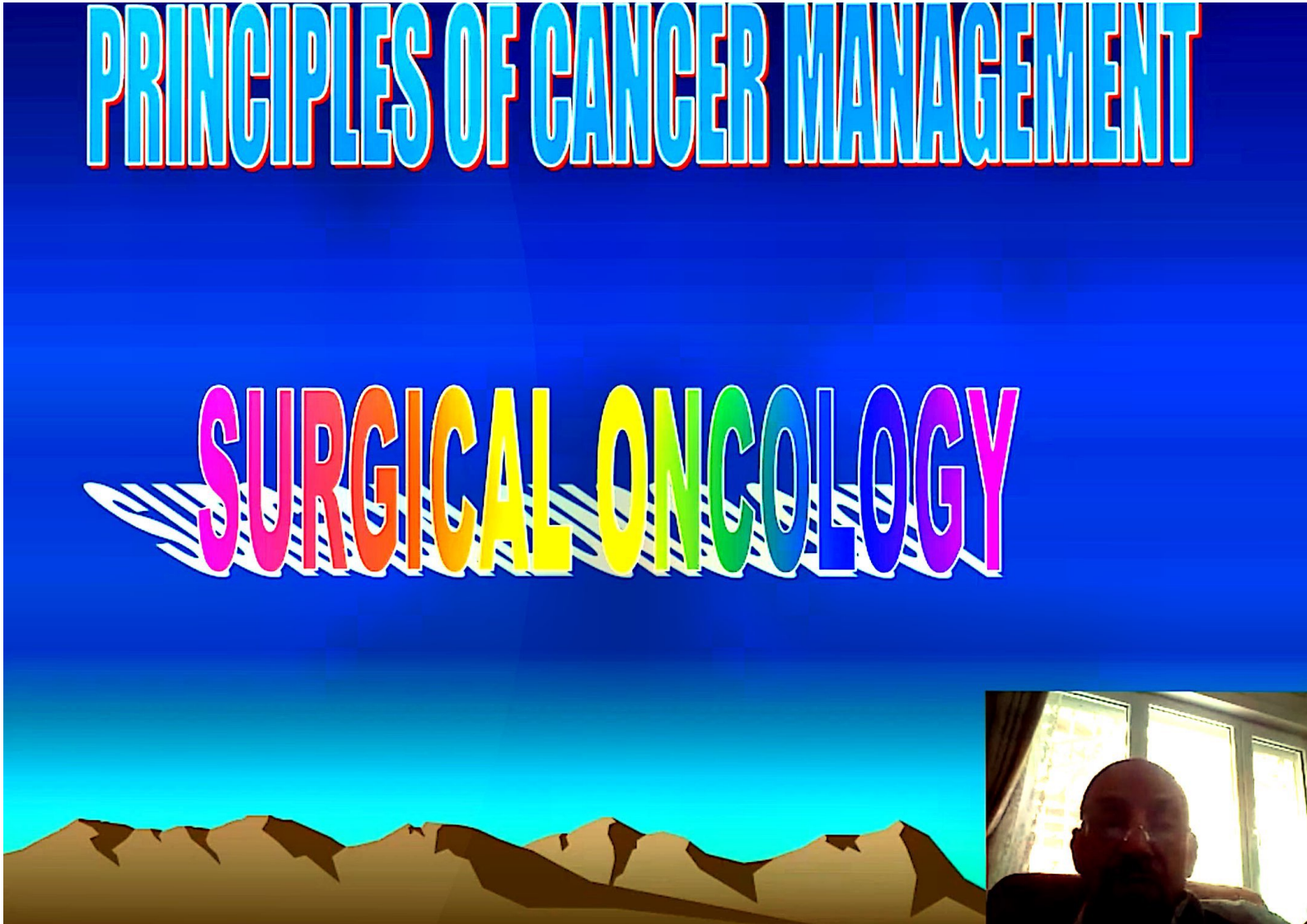
“A surgical oncologist is a well-qualified • surgeon who has obtained additional training and experience in the multidisciplinary approach to the prevention, diagnosis, treatment, and rehabilitation of cancer patients, and devotes a major portion of his or her professional practice to these activities and cancer research.

”Society of Surgical Oncology Training Program Guidelines



PRINCIPLES OF CANCER MANAGEMENT

SURGICAL ONCOLOGY



surgical Mangement of cancer

Prevention

Diagnosis

Treatment of primary tumor

Resection of metastasis


Managemēnt of oncological emergencies

Surgery for palliation

Surgery for residual disease Surgery for reconstruction

Cytoreduction

Regional chemotherapy




Surgery for Cancer Prevention



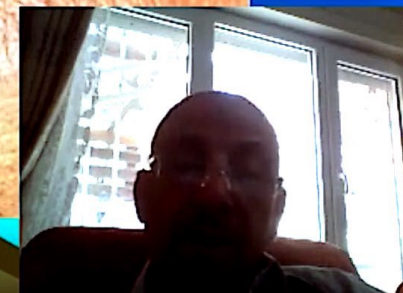
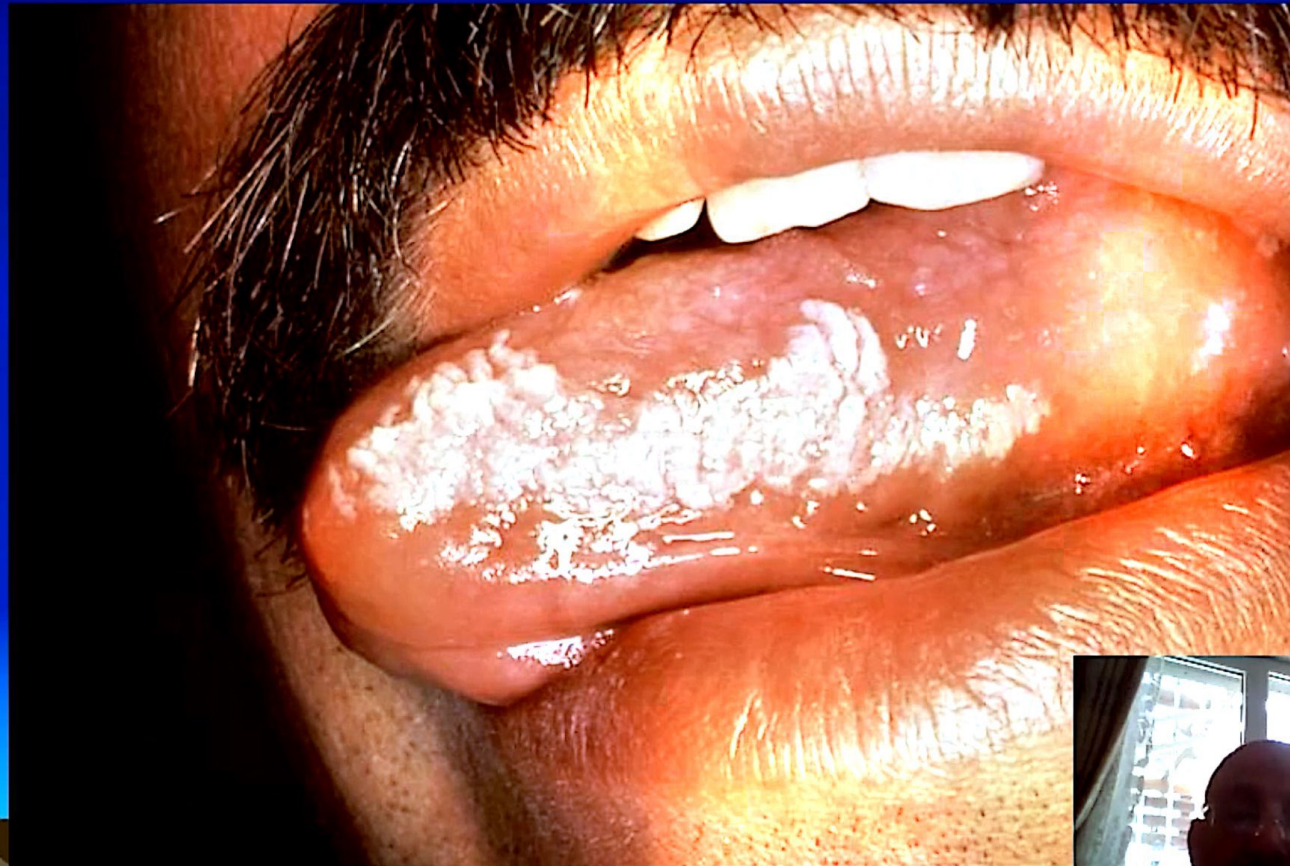Role of Surgery in primary Cancer Prevention

Pre-cancerous lesions

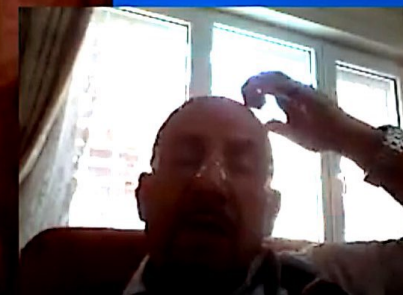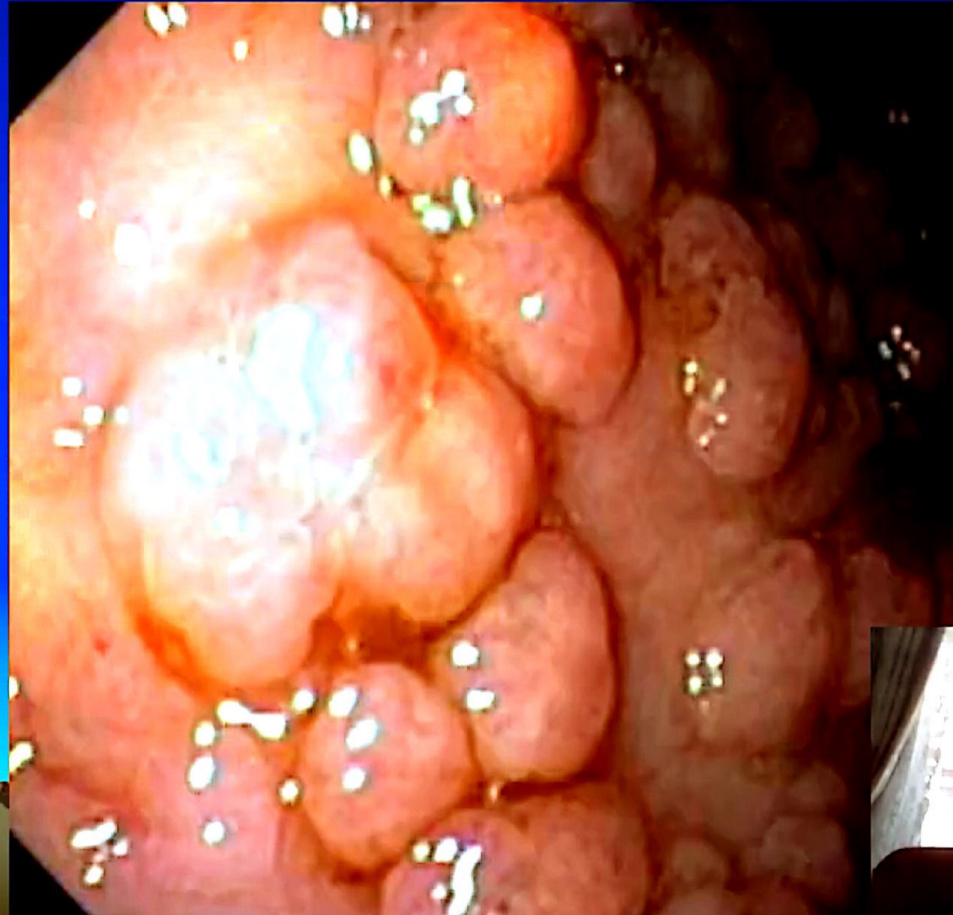
- Leukoplakia of the tongue
- Thyroid gland in MENS II
- Colon in FAP
- Colon in HNPCC
- Breast in BRCA mutations•

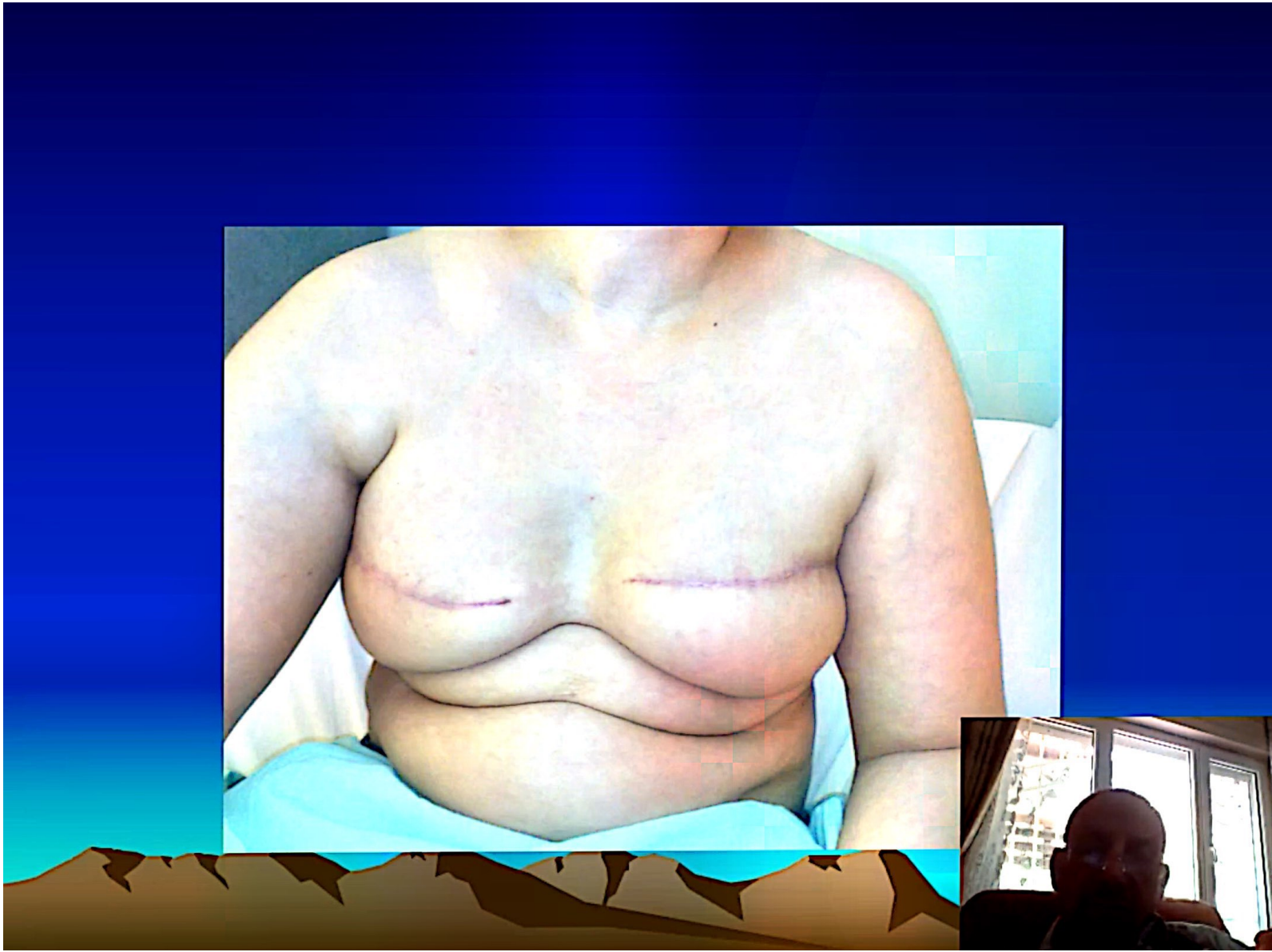

Leukoplakia of the tongue



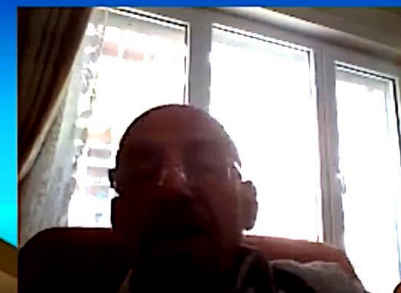
Colon in FAP





Role of Surgery in secondary Cancer Screening

- Colonoscopy in colon cancer**
- Digital rectal examination in prostate cancer**
- Clinical breast examination**



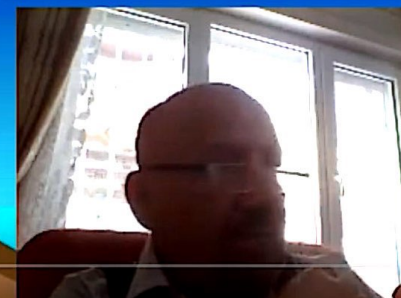
Clinical Diagnosis

History & Physical Examination

depends on involved system-late symptoms & signs

Investigation for fitness and staging

Histological Diagnosis



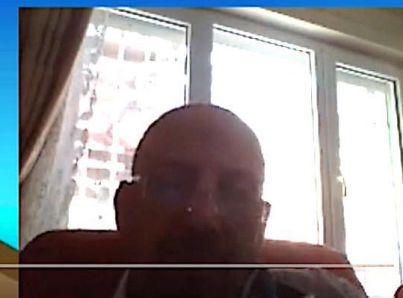
Histological Diagnosis

Needle Aspiration

Trucut Biopsy

Incisional biopsy

Excisional Biopsy



Fine Needle Aspiration Biopsy (FNAB)

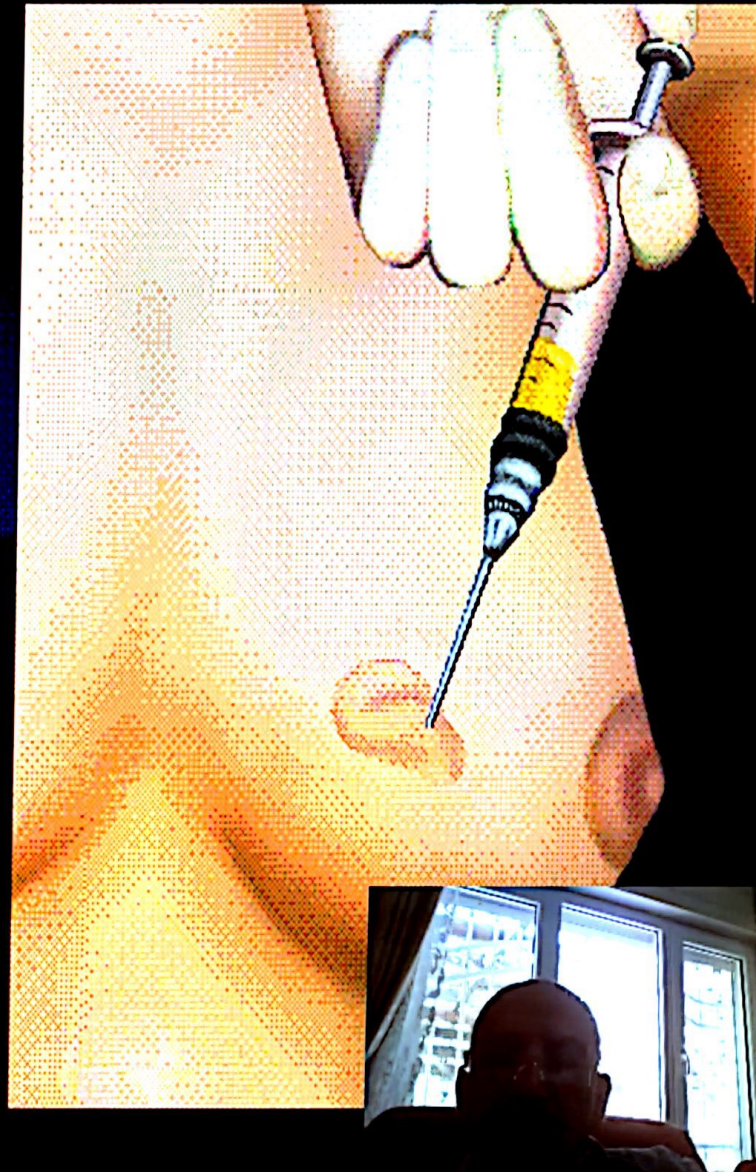
Fine needle **aspiration** biopsy is usually done in an office.

A small needle is inserted into the **tumor** and a sample of tissue is drawn up into the needle.

Material from the needle is put on a slide and examined for the presence of malignant cells.

It is a simple procedure done with minimal discomfort.

Disadvantage: May not always rule out **cancer** when it is negative.



Fine Needle Aspiration Biopsy (FNAB)

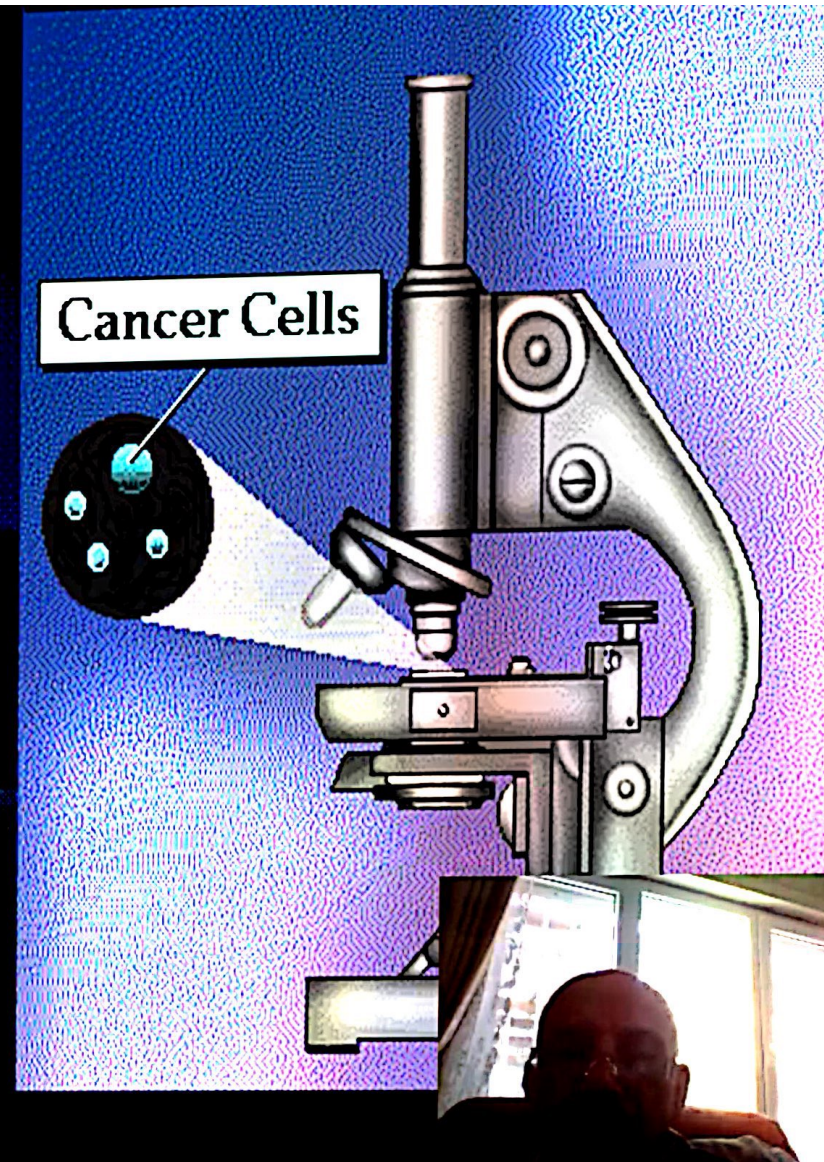
Fine needle **aspiration** biopsy is usually done in an office.

A small needle is inserted into the **tumor** and a sample of tissue is drawn up into the needle.

Material from the needle is put on a slide and examined for the presence of malignant cells.

It is a simple procedure done with minimal discomfort.

Disadvantage: May not always rule out **cancer** when it is negative.



Incisional biopsy

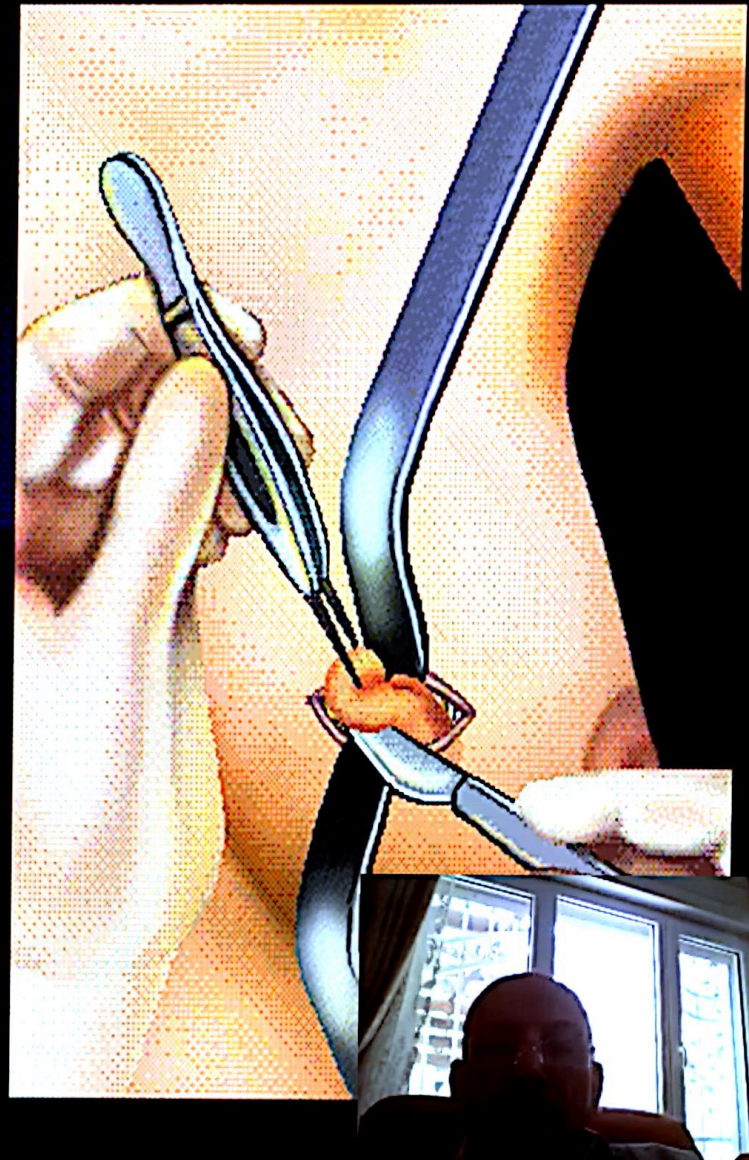
Incisional biopsy is done under local anesthesia, often with mild sedation.

It is an outpatient procedure.

Only part of the tumor is removed for diagnosis.

Incisional biopsy is usually done when the tumor is large.

It is rarely performed except in special circumstances.



Excisional biopsy

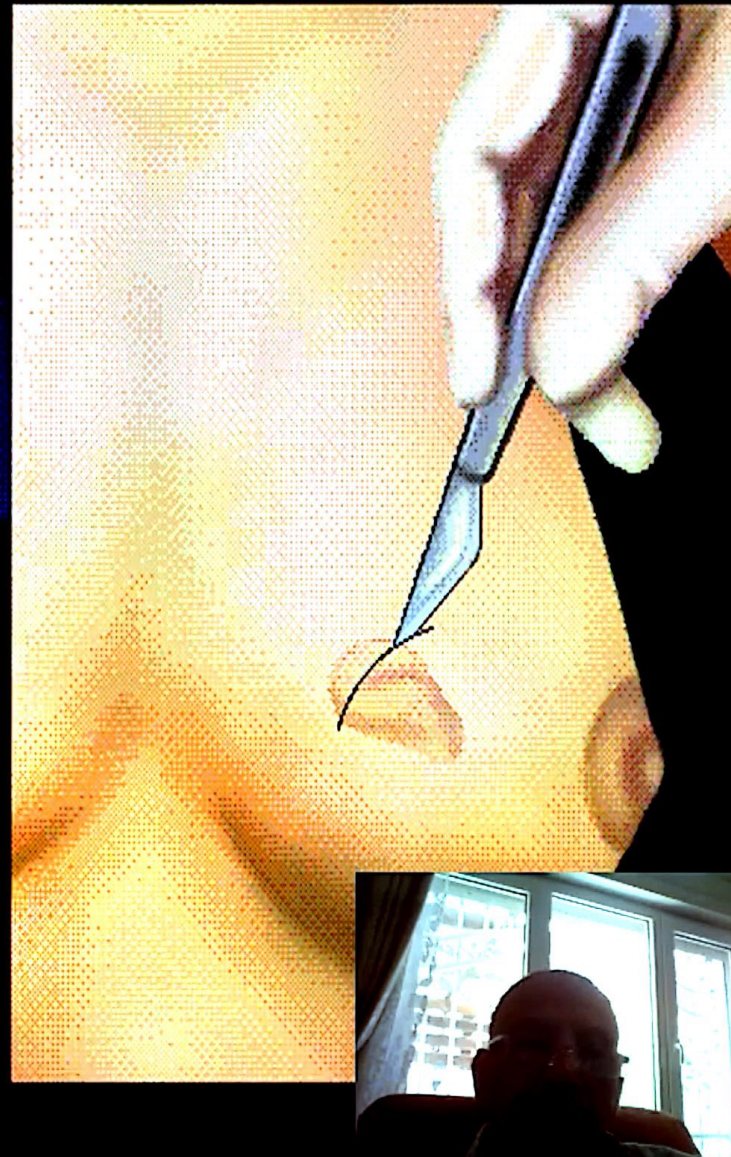
Excisional biopsy is the most common biopsy procedure.

It is an outpatient procedure.

It is usually done under local anesthesia, often with mild sedation.

The entire lump is taken out using a small incision on the breast.

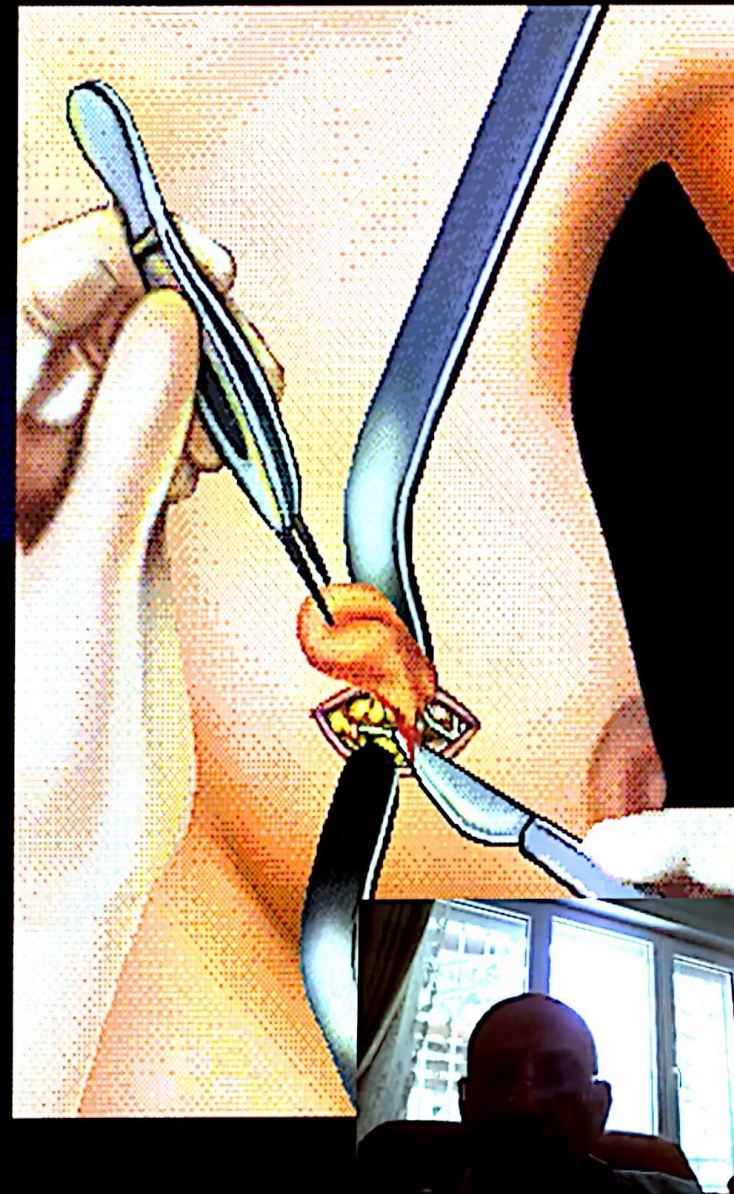
The pathologist examines the specimen for the presence of cancer.



Lumpectomy

Sometimes the **excisional biopsy** which was used to diagnose the cancer is sufficient for the lumpectomy, if the margins were negative.

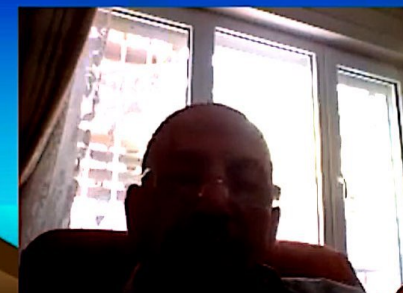
Lumpectomy with **radiation therapy** is as effective as **modified radical mastectomy**.



Biopsy

Surgeon's responsibilities:

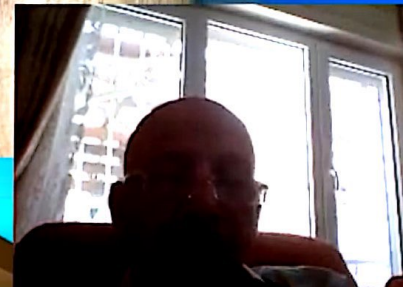
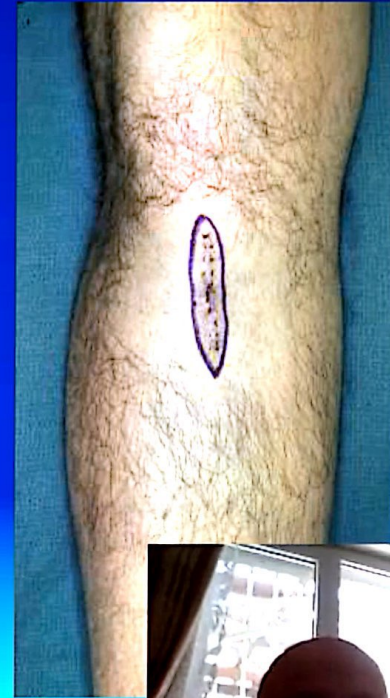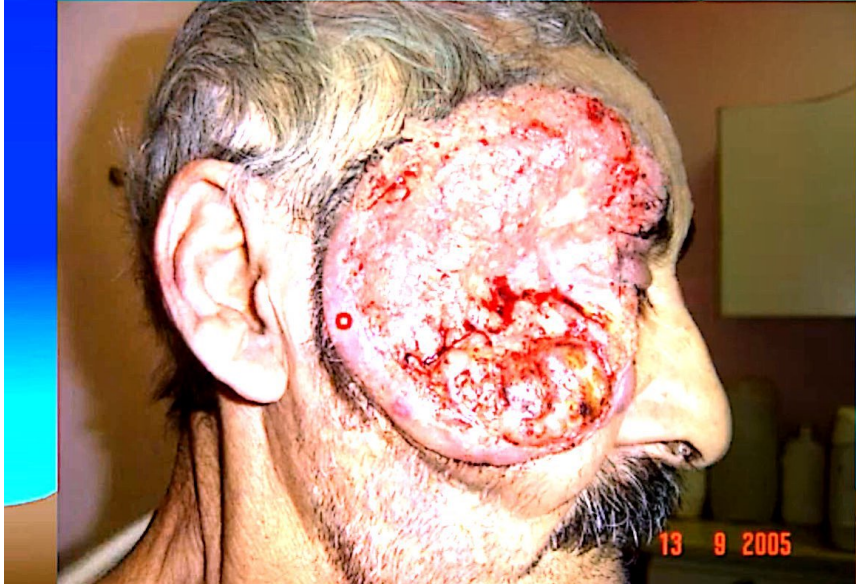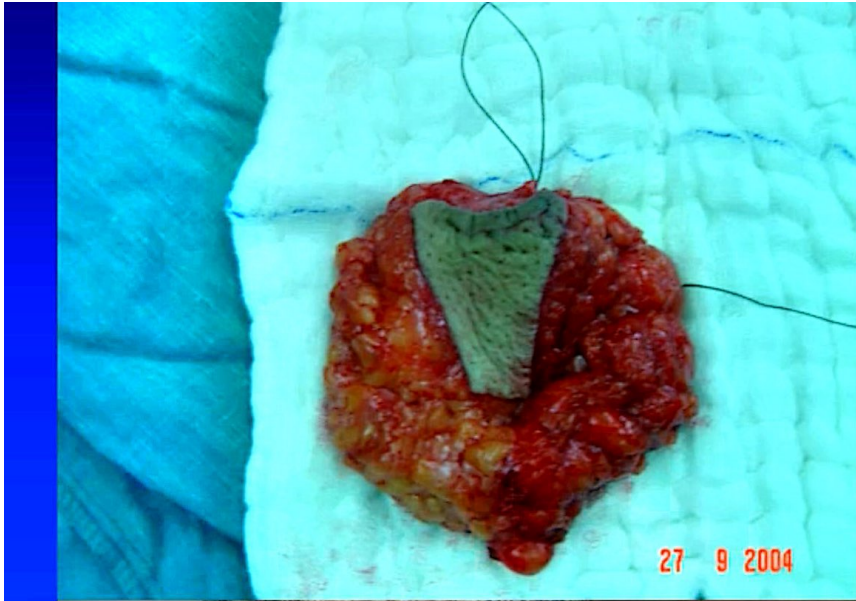
- Selection of appropriate biopsy method and site
- Responsible that the tissue reach the pathologist timely and properly .
- Communicate the results to the patient, family, other physicians
- Provide initial prognosis and information on follow-up care



Surgeon's Tasks in Performing Biopsy

- Orient the specimen
- Ensure the integrity of the tissue plane
- Ensure the adequacy of the tissue sample
- Be sure tissue reach the pathologist !





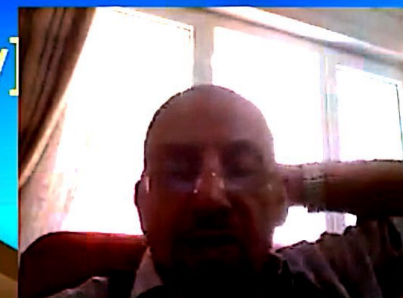
surgical Mangement of cancer

Objectives

cure

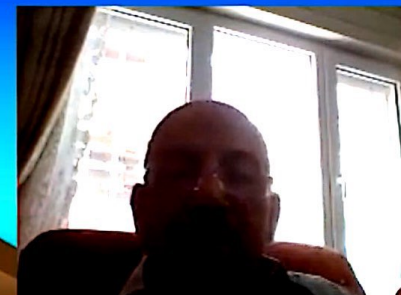
palliation

[single or part of multimodality]



The wide excision of primary melanomas in the skin that can be cured locally by surgery alone in about 90% of cases.

The resection of colon cancers with a 5-cm margin from the tumor results in anastomotic recurrences in less than 5% of cases



The magnitude of surgical resection is modified in the treatment of many cancers by the use adjuvant of treatment modalities



local resection

e.g. BCC

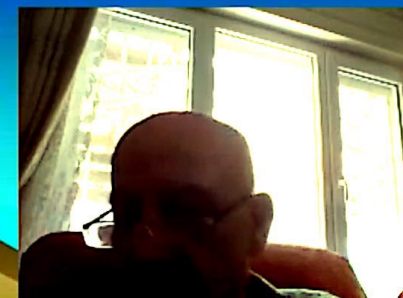wide local

e.g. breast ca

radical local excision

e.g. compartment

en block excision

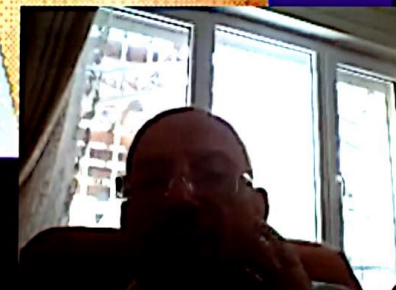
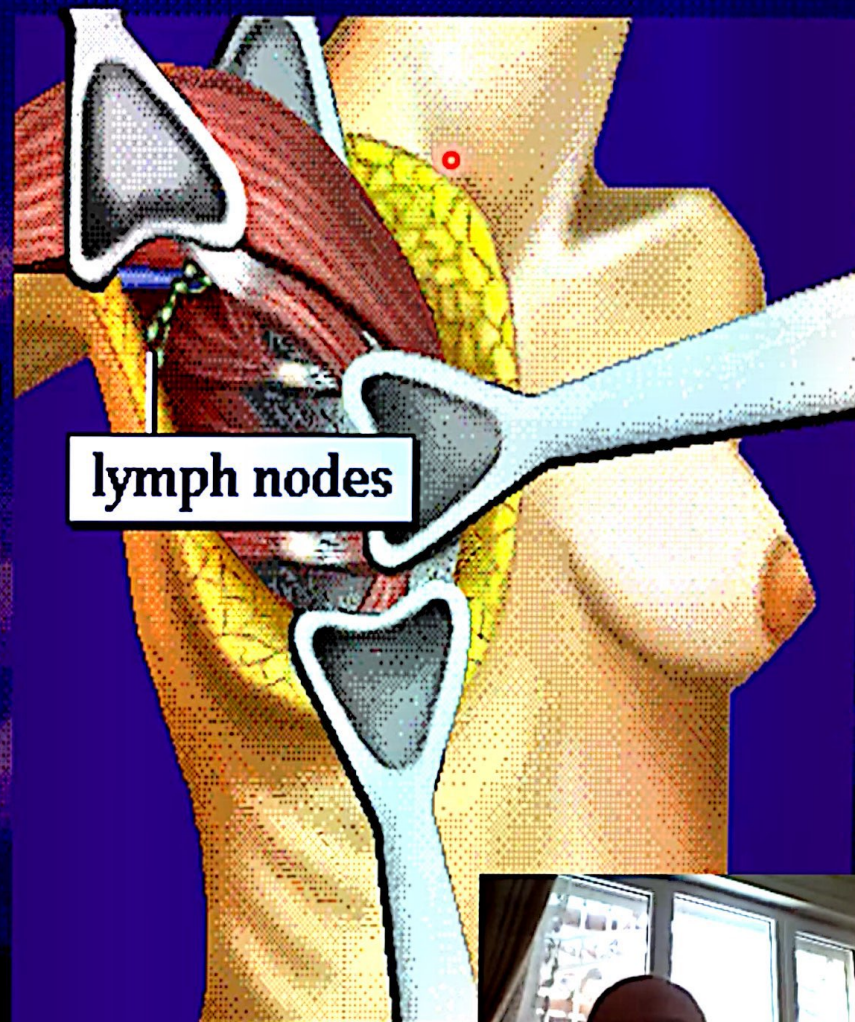


Total mastectomy (Simple mastectomy)

In total mastectomy the entire breast tissue is removed.

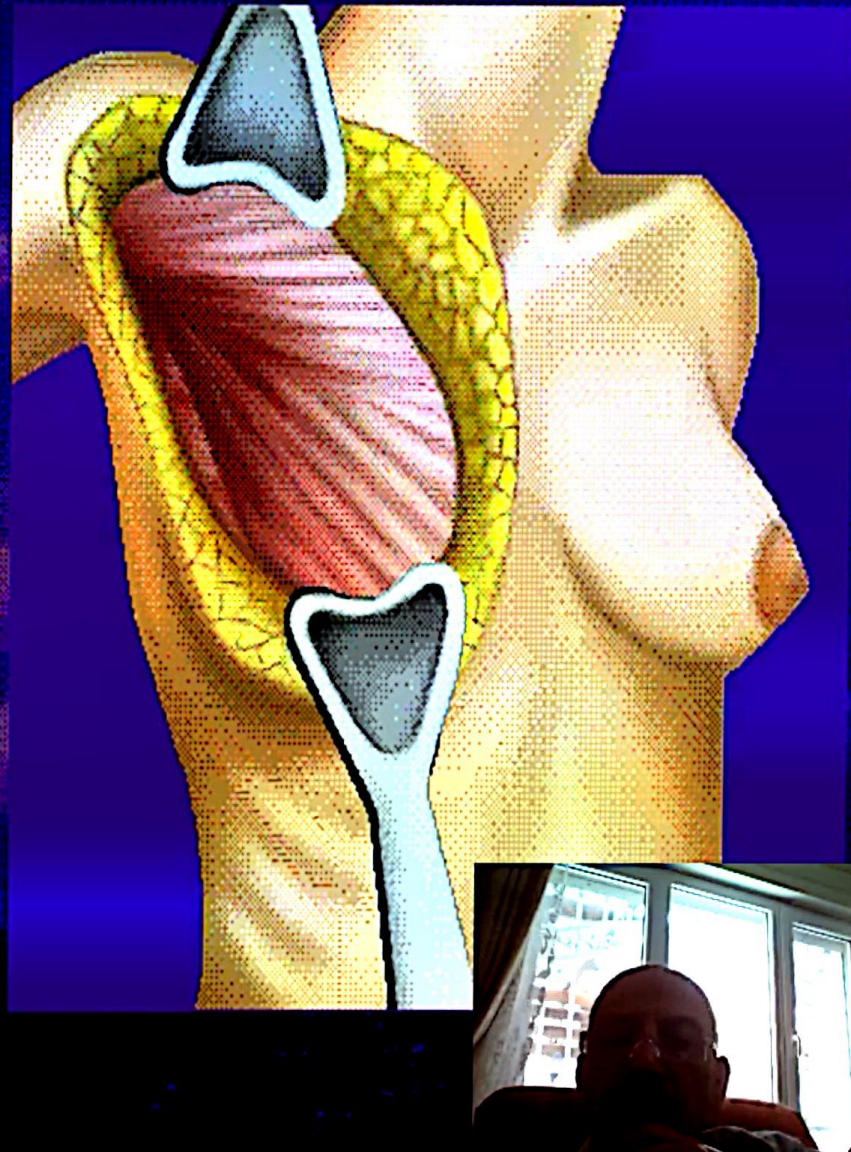
It is similar to modified radical mastectomy except that the **lymph nodes** in the armpit are not removed.

Total mastectomy is often recommended in early **noninvasive cancers** or when the mastectomy is being performed as a preventative measure.



Modified radical mastectomy

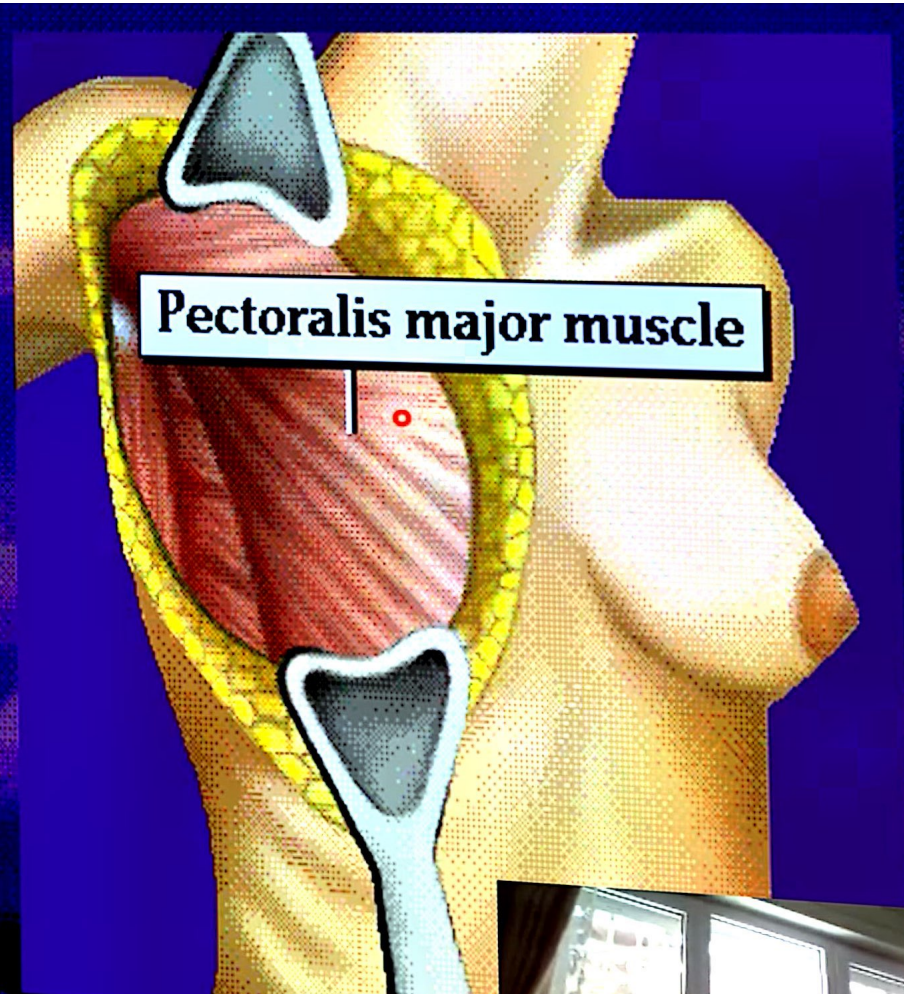
In modified radical mastectomy, the entire breast tissue is removed together with the **cancer** and some of the **lymph nodes** in the armpit. The muscles of the chest and arm are preserved.



Radical mastectomy

In radical mastectomy the muscles of the chest (e.g., **pectoralis major** and **pectoralis minor**) along with the breast and **lymph nodes** are all removed.

Radical mastectomy is now rarely performed. It is usually reserved for very large **cancers** that have grown into the muscle.



Principles of surgical resection of tumor

- Adequate margin of resection
- Prevention of tumor spillage
- Minimal manipulation
- Reconstruction

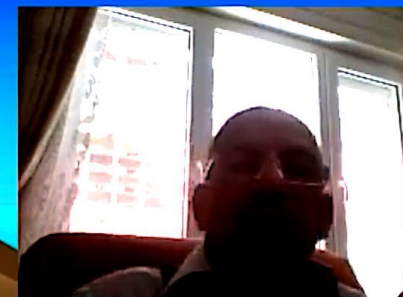


Surgery for palliation

Colostomy

Gastrostomy

Amputation



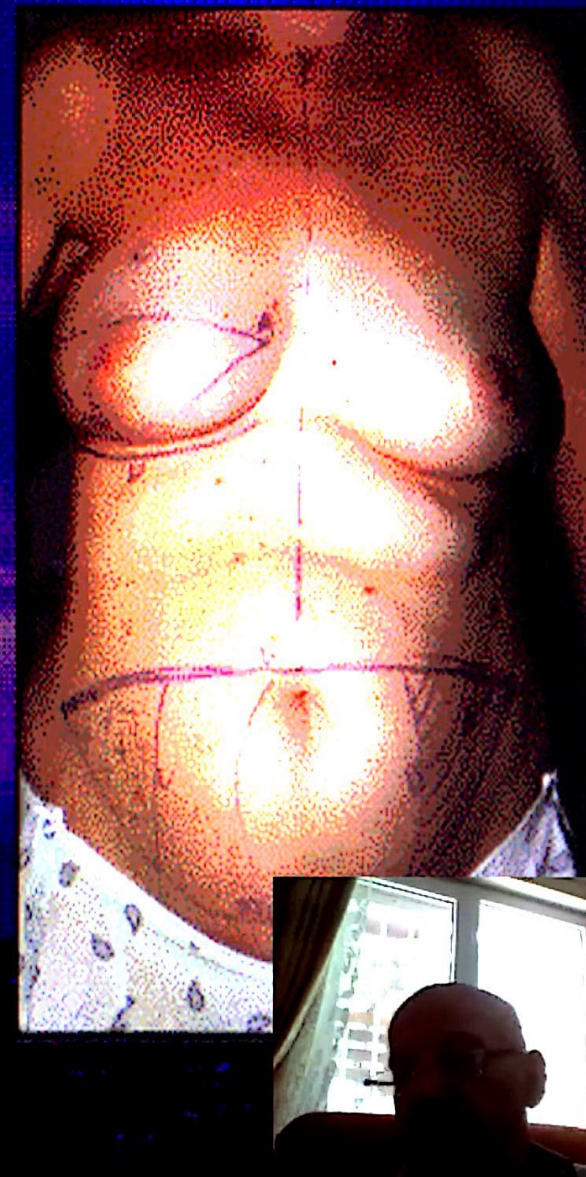
Surgery for reconstruction and rehabilitation



General Principles

Breast reconstructive surgery can be performed either at the same time that the breast is removed, or at a later date. More and more women are choosing to have their breast reconstruction begun at the same time their own natural breast is removed.

Most women who undergo **mastectomy** can have breast reconstruction.

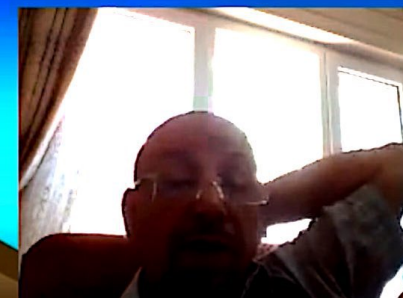

Surgery for Residual Disease

After Neoadjuvant chemotherapy

After radiotherapy

After inadequate surgery



Cytoreductive surgery

Ovarian cancer

Burkitt's lymphoma



Surgery for Metastatic Disease

metastases to:

-lung

-brain

-liver

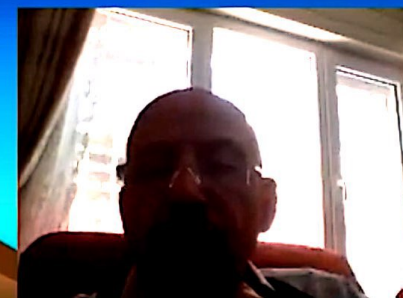
can be controlled by surgical resection



Metastasectomy

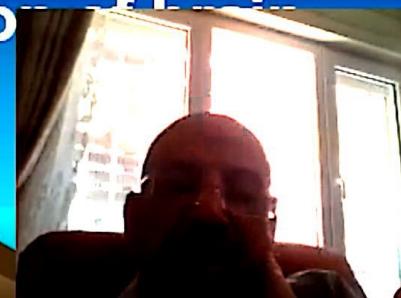
This is done when:

- **The primary tumor is controlled or can be controlled**
- **Metastasis is single or multiple**
- **Evidence that metastasectomy is associated clinical benefits**
- **Tumor doubling time is sufficiently long**
- **No significant co-morbid factor**



Metastasectomy

- Complete resection of distant metastases improves five-year overall survival rates
- 40% for colorectal cancer with resection of liver metastases
- 30% for sarcoma with resection of lung metastases
- 16% for breast cancer with resection of lung metastases

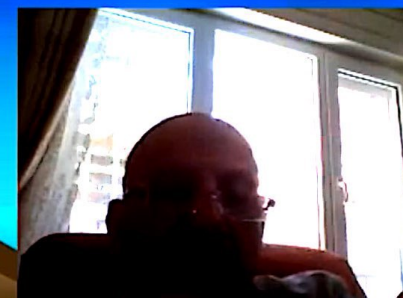
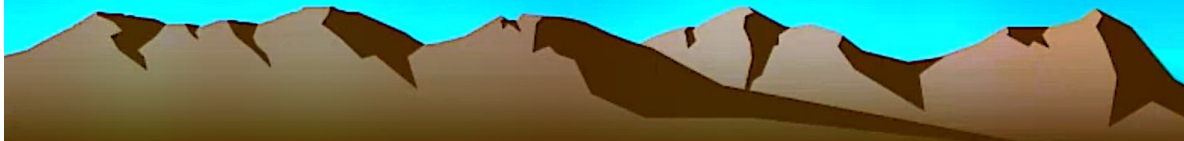

SURGERY FOR ONCOLOGIC EMERGENCIES

Hemorrhage

Abscesses

Perforation



Perforation of the gastrointestinal tract after effective treatment for lymphoma




**cancer invading central nervous
the system represents another
surgical emergency that can lead to
preservation of function.**



Venous access catheters

A venous access catheter is a small, flexible, hollow tube, which is surgically placed into a large vein where it can be left for several months. Venous access catheters are used for repeated infusions of **chemotherapy** drugs, antibiotics, and other intravenous fluids. They can also be used for blood-drawing. Venous access catheters are useful when veins are small or difficult to find.



Regional Chemotherapy

2009: Percutaneous Isolated Liver Perfusion

