

# Anatomy

- located at the **base** of the cecum, near the ileocecal valve .
- The appendix is a true diverticulum of the cecum.
- **blood supply**, the appendiceal artery, is a terminal branch of the ileocolic artery

# Epidemiology

- most frequently in the **second** and **third** decades of life.
- The **incidence** is approximately 233/100,000 population and is **highest** in the 10-to-19-year-old age group
- male to female ratio of **1.4:1**

# PATHOGENESIS

- Appendiceal **obstruction** has been proposed as the primary cause of appendicitis
- obstruction causes: **fecaliths** (hard fecal masses), **calculi**, **lymphoid hyperplasia**, **infectious** processes, and benign or malignant **tumors**.
- The **mechanism** of luminal **obstruction varies** depending upon the patient's **age**.
  1. In the **young**, **lymphoid** follicular **hyperplasia** due to **infection** is thought to be the main cause.
  2. In **older** patients, luminal obstruction is more likely to be caused by **fibrosis**, **fecaliths**, or **neoplasia** (carcinoid, adenocarcinoma, or mucocele).
  3. In **endemic** areas, **parasites** can cause obstruction in any age group

- The obstruction leads to an **increase** in luminal and intramural pressure, resulting in thrombosis and **occlusion** of the small vessels in the appendiceal wall, and **stasis** of lymphatic flow. As lymphatic and vascular compromise progresses, the wall of the appendix becomes ischemic and then necrotic.
- **Bacterial** overgrowth occurs within the diseased appendix. Aerobic organisms predominate early in the course, while mixed infection is more common in late appendicitis

- As the appendix becomes **engorged**, the **visceral** afferent nerve fibers entering the spinal cord at T8-T10 are stimulated, leading to vague central or **periumbilical** abdominal pain.
- **Well-localized** pain occurs later in the course when inflammation involves the adjacent parietal peritoneum.

# CLINICAL FEATURES

## ■ History

Classical symptoms:

- Right lower quadrant (right anterior iliac fossa) abdominal pain
- Anorexia
- Nausea and vomiting

In the **classic** presentation, the patient describes the onset of **abdominal** pain as the **first** symptom.

**periumbilical** in nature with subsequent **migration (50 to 60 %** of patients).

**Fever-related** symptoms generally occur **later** in the course of illness.

## Variation of symptoms

- many patients, initial features are **atypical** or nonspecific and can include:
  - Indigestion
  - Flatulence
  - Bowel irregularity
  - Diarrhea
  - Generalized malaise

The symptoms of appendicitis vary depending upon the **location** of the **tip** of the appendix,

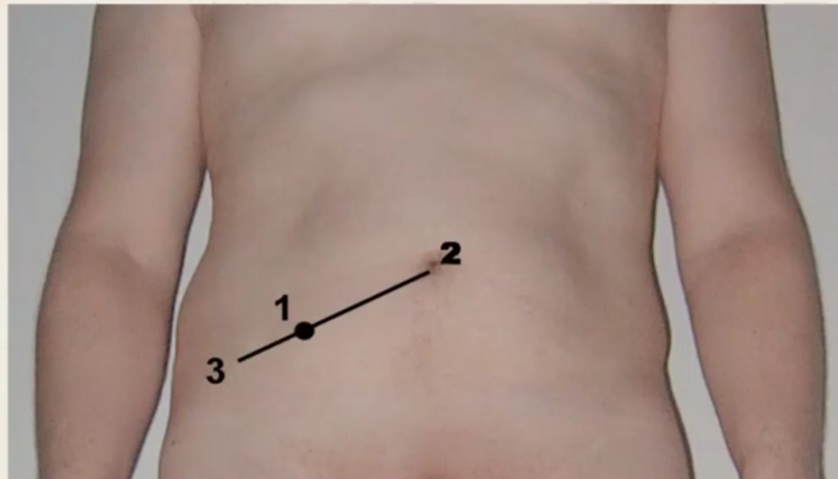
**anterior**

**retrocecal**

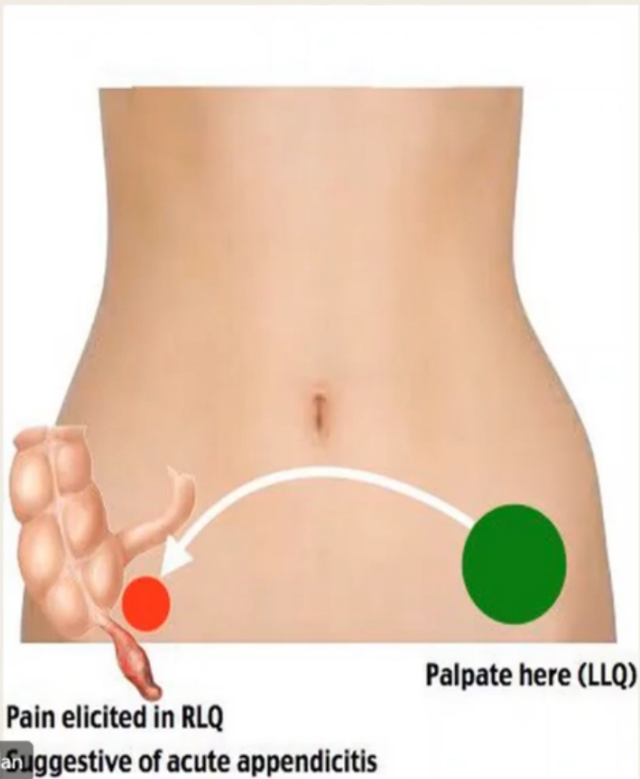
**pelvic**



- There are no physical findings, taken alone or in concert, that definitively confirm a diagnosis of appendicitis. ( sensitivity and specificity are variable )
- Commonly described physical signs include:
  - I. Rebound tenderness (also called blumberg sign ) *tenderness that occurs upon sudden release of pressure on the abdomen*
  - II. McBurney's point tenderness is described as maximal tenderness at the 2/3 of the way from the umbilicus to the anterior superior iliac spine (ASIS)



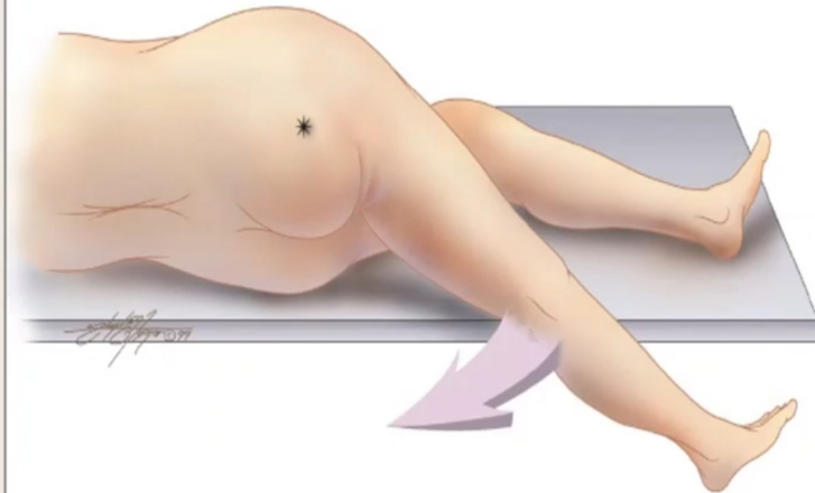
- **Rovsing's** sign refers to pain in the right lower quadrant with palpation of the left lower quadrant.



Mohammad Rashdan

The **psoas** sign( retrocecal appendix). This is manifested by right lower quadrant pain with passive right hip extension. The inflamed appendix may lie against the right psoas muscle

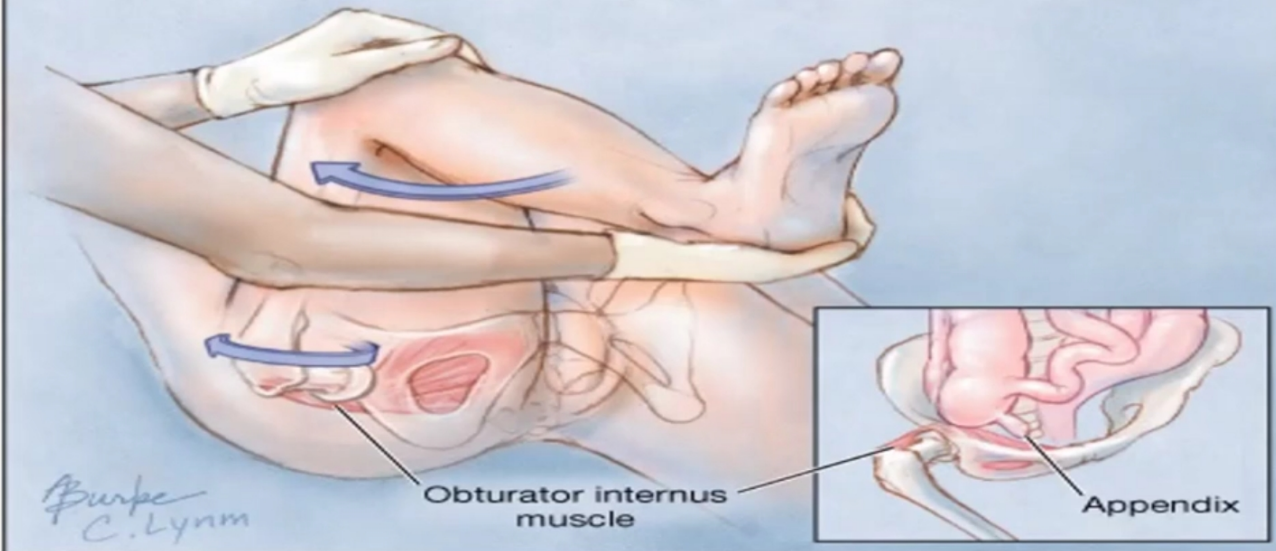
FIGURE 1



The psoas sign. Pain on passive extension of the right thigh. Patient lies on left side. Examiner extends patient's right thigh while applying counter resistance to the right hip (*asterisk*).

- The **obturator** sign is associated with a pelvic appendix. This test is based on the principle that the inflamed appendix may lie against the right obturator internus muscle. When the clinician flexes the patient's right hip and knee, followed by internal rotation of the right hip, this elicits right lower quadrant pain  
-The sensitivity is low enough that experienced clinicians no longer perform this assessment.

*With the patient in the supine position, the examiner passively flexes the right hip and knee. The leg is gently pulled laterally while maintaining position of the knee, causing internal rotation at the hip.*



# Laboratory findings

- A mild leukocytosis (white blood cell count  $>10,000$  cells/microL) is present in most patients with acute appendicitis
- Approximately 80 percent of patients have a leukocytosis and a left shift
- Serum C-reactive protein (CRP)

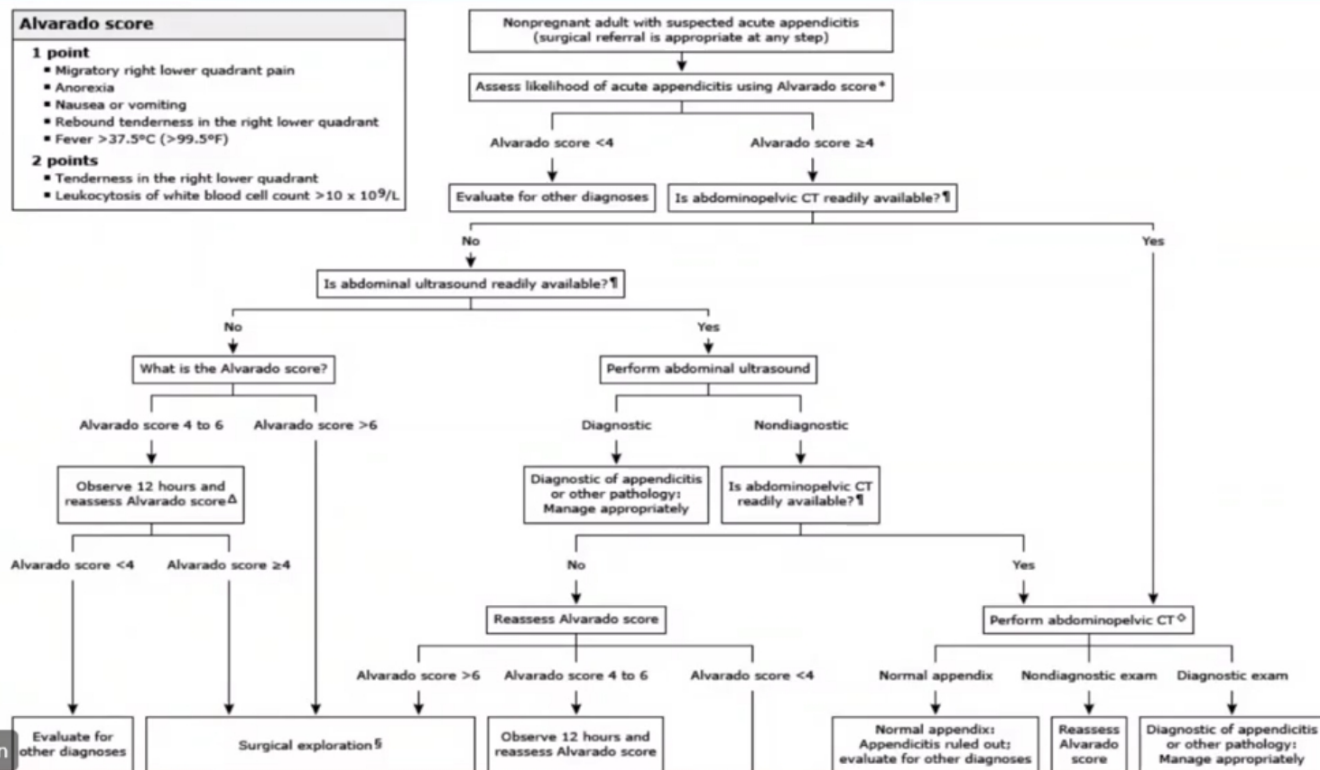
# Alvarado score

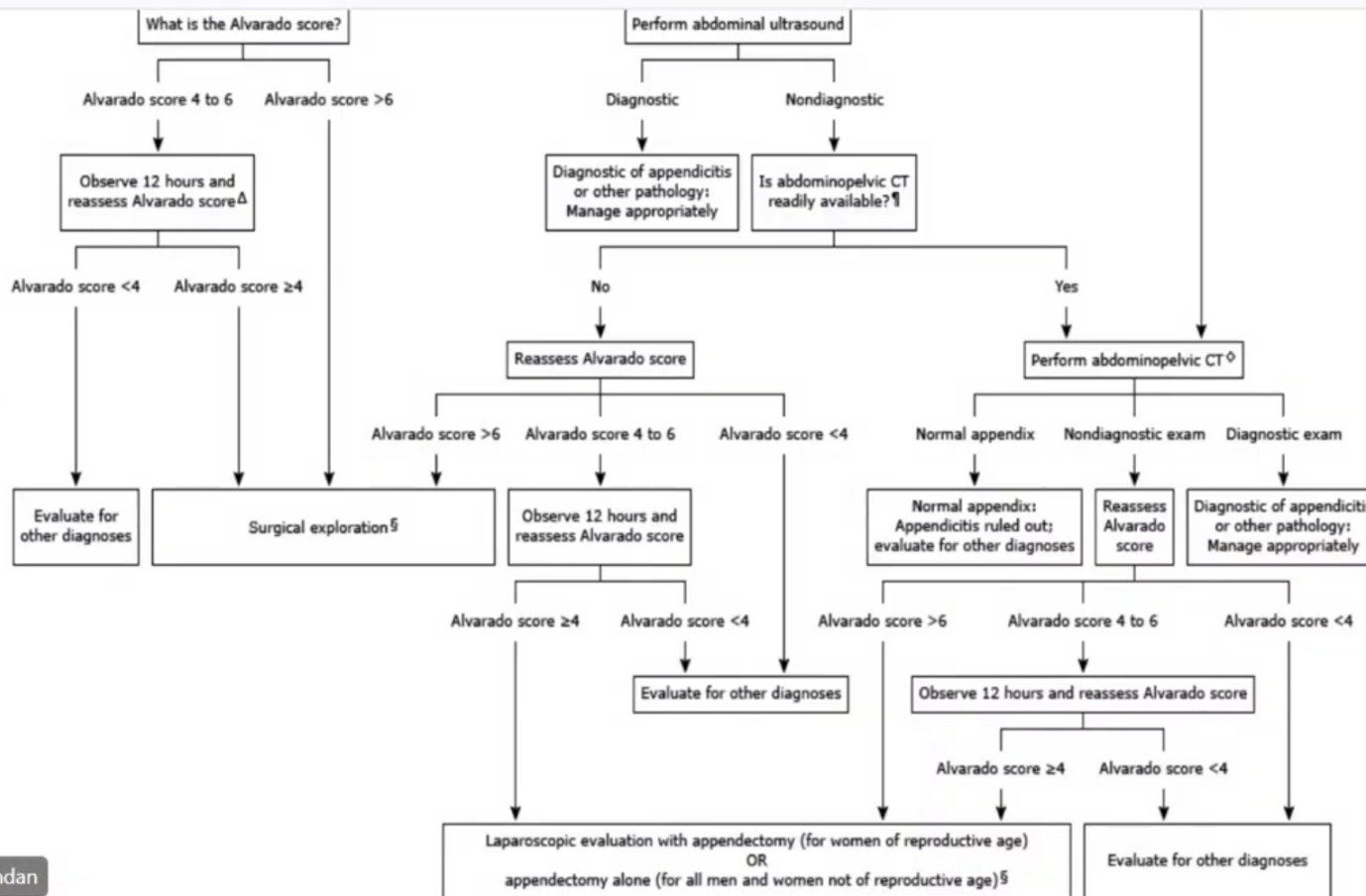
- Used only to rule in or to rule out appendicitis
- Patients with a score of 0 to 3 are unlikely to have appendicitis and should be evaluated for other possible diagnoses.
- Patients with a score of  $\geq 4$  should be evaluated further for appendicitis

# Alvarado score

## Algorithm: Diagnostic evaluation of suspected appendicitis

- Alvarado score**
- 1 point**
- Migratory right lower quadrant pain
  - Anorexia
  - Nausea or vomiting
  - Rebound tenderness in the right lower quadrant
  - Fever >37.5°C (>99.5°F)
- 2 points**
- Tenderness in the right lower quadrant
  - Leukocytosis of white blood cell count >10 x 10<sup>9</sup>/L





# Alvarado score

- Used only to rule in or to rule out appendicitis
- Patients with a score of 0 to 3 are unlikely to have appendicitis and should be evaluated for other possible diagnoses.
- Patients with a score of  $\geq 4$  should be evaluated further for appendicitis



# Imaging exam

- **Plain radiograph findings** — Plain radiographs are usually not helpful for establishing the diagnosis of appendicitis
- **Ultrasound findings** — The most accurate ultrasound finding for acute appendicitis is an appendiceal diameter of >6 mm
- **Computed tomography findings** — The following findings suggest acute appendicitis on standard abdominal computed tomography (CT) scanning with contrast including
  - Enlarged appendiceal diameter >6 mm with an occluded lumen
  - Appendiceal wall thickening (>2 mm)
  - Periappendiceal fat stranding
  - Appendiceal wall enhancement
  - Appendicolith (seen in approximately 25 percent of patients)

- In a minority of patients, surgical exploration may be warranted if clinical suspicion for appendicitis is high but imaging studies are either negative, nondiagnostic, or unavailable. In such patients, appendicitis can only be diagnosed intraoperatively

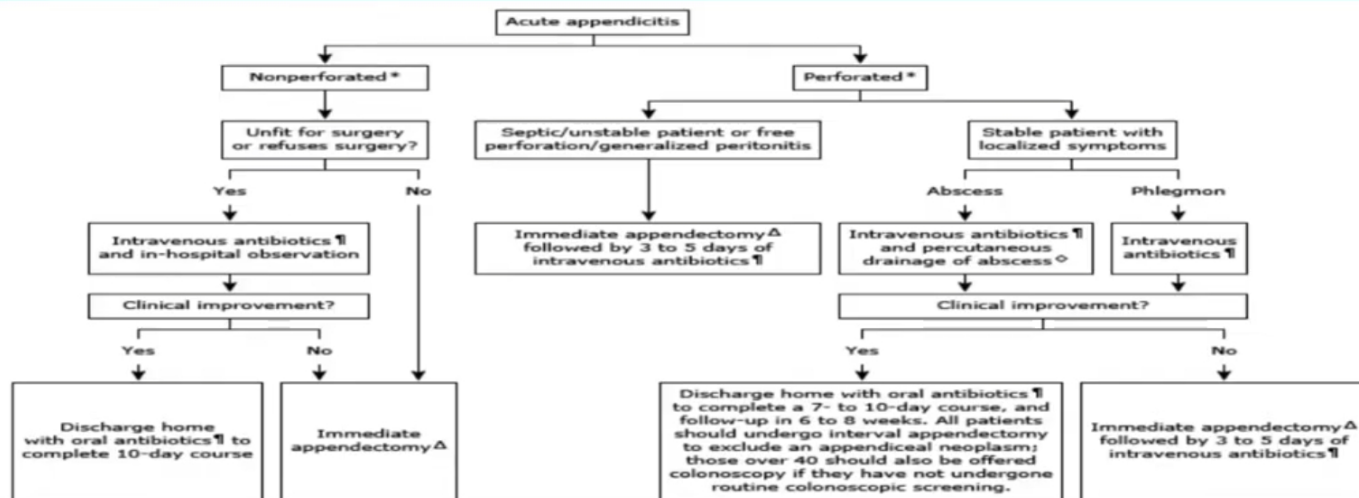
# DIFFERENTIAL DIAGNOSIS

- Perforated appendix
- Cecal diverticulitis
- Acute ileitis
- Crohn's disease
- Tubo-ovarian abscess
- Pelvic inflammatory disease
- Ruptured ovarian cyst
- Ovarian and fallopian tube torsion
- Ectopic pregnancy
- Renal colic

# Management

© 2019 UpToDate, Inc. and/or its affiliates. All Rights Reserved.

## Management of acute appendicitis in adults



\* Perforated appendicitis, also referred to as complicated appendicitis, is characterized by a palpable mass in the right lower quadrant on physical examination or by a phlegmon (inflammatory mass) or abscess on imaging studies. Nonperforated appendicitis, also referred to as simple or uncomplicated appendicitis, does not have any clinical or radiologic signs of perforation.

¶ The choice of antibiotics varies by clinical situations and is constantly evolving. Refer to related topics in UpToDate for information on antibiotic selection.

Δ Immediate appendectomy, as opposed to interval appendectomy, should be performed within 12 hours of decision to operate, except in the case of unstable/septic patient or the presence of free perforation or generalized perforation, where surgery should be performed emergently.

◊ Immediate appendectomy is an alternative option for patients with an appendiceal abscess, especially if the abscess is not amenable to percutaneous drainage.

# Non perforated appendicitis

- for acute nonperforated appendicitis in a stable patient
  1. **appendectomy within 12 hours**
  2. **Hydration**
  3. **pain** control
  4. intravenous **antibiotics** while awaiting surgery.

# PERFORATED APPENDICITIS

- **Unstable patients or patients with free perforation**
  - For patients who are septic or unstable, and for those who have a free perforation of the appendix or generalized peritonitis, emergency appendectomy is required, as well as drainage and irrigation of the peritoneal cavity. Emergency appendectomy in this setting can be accomplished open or laparoscopically; the choice is determined by surgeon preference with consideration of patient condition and local resource

# PERFORATED APPENDICITIS

- **Stable patients** : immediate appendectomy or initial nonoperative management. Both approaches are safe.
- Patients with an appendiceal abscess should be treated with intravenous antibiotics and percutaneous, image-guided drainage of the abscess. Immediate appendectomy is an alternative option for these patients, especially if the abscess is not amenable to percutaneous drainage
- Patients with a phlegmon of the right lower quadrant should be treated with intravenous antibiotics. Repeat imaging is often performed to follow the resolution (or progression) of the phlegmon, and to exclude other complications that could evolve over time (eg, abscess formation).
- Patients who fail initial antibiotic therapy clinically or radiographically require rescue appendectomy, whereas those who respond to initial antibiotic therapy can be discharged with oral antibiotics to complete a 7- to 10-day course (in total) and return for follow-up in six to eight weeks.

# Medical Management