Pericarditis

Hanna Al-Makhamreh, MD.FACC
Interventional Cardiologist
University of Jordan

- **Introduction:**
- The pericardium is a fibroelastic sac made up of visceral and parietal layers separated by a space, the pericardial cavity.
- In healthy individuals, the pericardial cavity contains 15-50 mL of an ultrafiltrate of plasma.

- Acute pericarditis refers to inflammation of the pericardial sac.
- The term myopericarditis, or perimyocarditis, is used for cases of acute pericarditis that also demonstrate myocardial inflammation.

- Most cases of acute pericarditis are considered of possible or confirmed viral origin, although the exact etiology of most cases remains undetermined following a traditional diagnostic approach.
- Acute pericarditis is a common disorder in several clinical settings, where it may be the first manifestation of an underlying systemic disease or may represent an isolated process.

Major causes of pericardial disease

Idiopathic
In most case series, the majority of patients are not found to have an identifiable cause of pericardial disease. Frequently such cases are presumed to have a viral or autoimmune etiology.
Infections
A. Viral - Coxsackievirus, echovirus, adenovirus, EBV, CMV, influenza, varicella, rubella, HIV, hepatitis B, mumps, parvovirus B19, vaccina (smallpox vaccination)
B. Bacterial - Staphylococcus, Streptococcus, pneumococcus, Haemophilus, Neisseria (gonorrhoeae or meningitidis), Chlamydia (psittaci or trachomatis), Legionella, tuberculosis, Salmonella, Lyme disease
C. Mycoplasma
D. Fungal - Histoplasmosis, aspergillosis, blastomycosis, coccidiodomycosis, actinomycosis, nocardia, candida
E. Parasitic - Echinococcus, amebiasis, toxoplasmosis
F. Infective endocarditis with valve ring abscess
Radiation
Neoplasm
A. Metastatic - Lung or breast cancer, Hodgkin's disease, leukemia, melanoma
B. Primary - Rhabdomyosarcoma, teratoma, fibroma, lipoma, leiomyoma, angioma
C. Paraneoplastic
Cardiac
A. Early infarction pericarditis
B. Late postcardiac injury syndrome (Dressler's syndrome), also seen in other settings (eg, post-myocardial infarction and post-cardiac surgery)
C. Myocarditis
D. Dissecting aortic aneurysm
Trauma
A. Blunt
B. Penetrating
C. Iatrogenic - Catheter and pacemaker perforations, cardiopulmonary resuscitation, post-thoracic surgery
Autoimmune
A. Rheumatic diseases - Including lupus, rheumatoid arthritis, vasculitis, scleroderma, mixed connective disease
B. Other - Wegener's granulomatosis, polyarteritis nodosa, sarcoidosis, inflammatory bowel disease (Crohn's, ulcerative colitis), Whipple's, giant cell arteritis, Behcet's disease, rheumatic fever
Drugs
A. Procainamide, isoniazid, or hydralazine as part of drug-induced lupus
B. Other - Cromolyn sodium, dantrolene, methysergide, anticoagulants, thrombolytics, phenytoin, penicillin, phenylbutazone, doxorubicin
Metabolic
A. Hypothyroidism - Primarily pericardial effusion
B. Uremia
C. Ovarian hyperstimulation syndrome

Adapted from: Shabetai R. Diseases of the pericardium. In: Hurst's The Heart, 8th ed, Schlant RC, Alexander RW, et al (Eds).

UpToDate

- **Clinical presentation:**
- Acute pericarditis can present in a variety of ways, depending on the underlying etiology.
- Patients with an infectious etiology may present with signs and symptoms of systemic infection such as fever and leukocytosis.
- Viral etiologies in particular may be preceded by “flu-like” respiratory or gastrointestinal symptoms.

- Patients with a known autoimmune disorder or malignancy may present with signs or symptoms specific to their underlying disorder.
- The major clinical manifestations of acute pericarditis include:

- Chest pain — typically sharp and pleuritic, improved by sitting up and leaning forward.
- Pericardial friction rub — a superficial scratchy or squeaking sound best heard with the diaphragm of the stethoscope over the left sternal border.
- Electrocardiogram (ECG) changes — new widespread ST elevation or PR depression
- Pericardial effusion.

- **I-Chest pain:**
- The vast majority of patients with acute pericarditis present with chest pain (>95% of cases).
- Chest pain that results from acute pericarditis is typically fairly sudden in onset and occurs over the anterior chest.
- Unlike pain from myocardial ischemia, chest pain due to pericarditis is most often sharp and pleuritic in nature, ***with exacerbation by inspiration or coughing.***

- One of the most distinct features is the **tendency for a decrease in intensity when the patient sits up and leans forward.**
- This position (seated, leaning forward) tends to reduce pressure on the parietal pericardium, particularly with inspiration, and may also allow for splinting of the diaphragm.

- **II-Pericardial friction rub:**
- The presence of a pericardial friction rub on physical examination is highly specific for acute pericarditis.
- Pericardial friction rubs, which occur during the maximal movement of the heart within its pericardial sac, are said to be generated by friction between the two inflamed layers of the pericardium.

- Pericardial rubs have a superficial scratchy or squeaking quality that is best heard with the **diaphragm** of the stethoscope.
- They may be localized or widespread, but are usually loudest over the left sternal border.

- **III-Electrocardiogram:**
- Changes in the electrocardiogram (ECG) in patients with acute pericarditis signify inflammation of the epicardium, since the parietal pericardium itself is electrically inert.

- The typical progression of ECG changes in patients with acute pericarditis is described below:
- Stage 1, seen in the **first hours to days,** is characterized by **diffuse ST elevation** (typically concave up) with **reciprocal ST depression in leads aVR and V1.**
- There is also an atrial current of injury, reflected by **elevation of the PR segment in lead aVR and depression of the PR segment in other leads.**

- Stage 2, typically seen in the first week, is characterized by normalization of the ST and PR segments.
- Stage 3, is characterized by the development of diffuse T wave inversions, generally **after** the ST segments have become isoelectric.
- Stage 4, is represented by normalization of the ECG or indefinite persistence of T wave inversions ("chronic" pericarditis).

Normal ECG

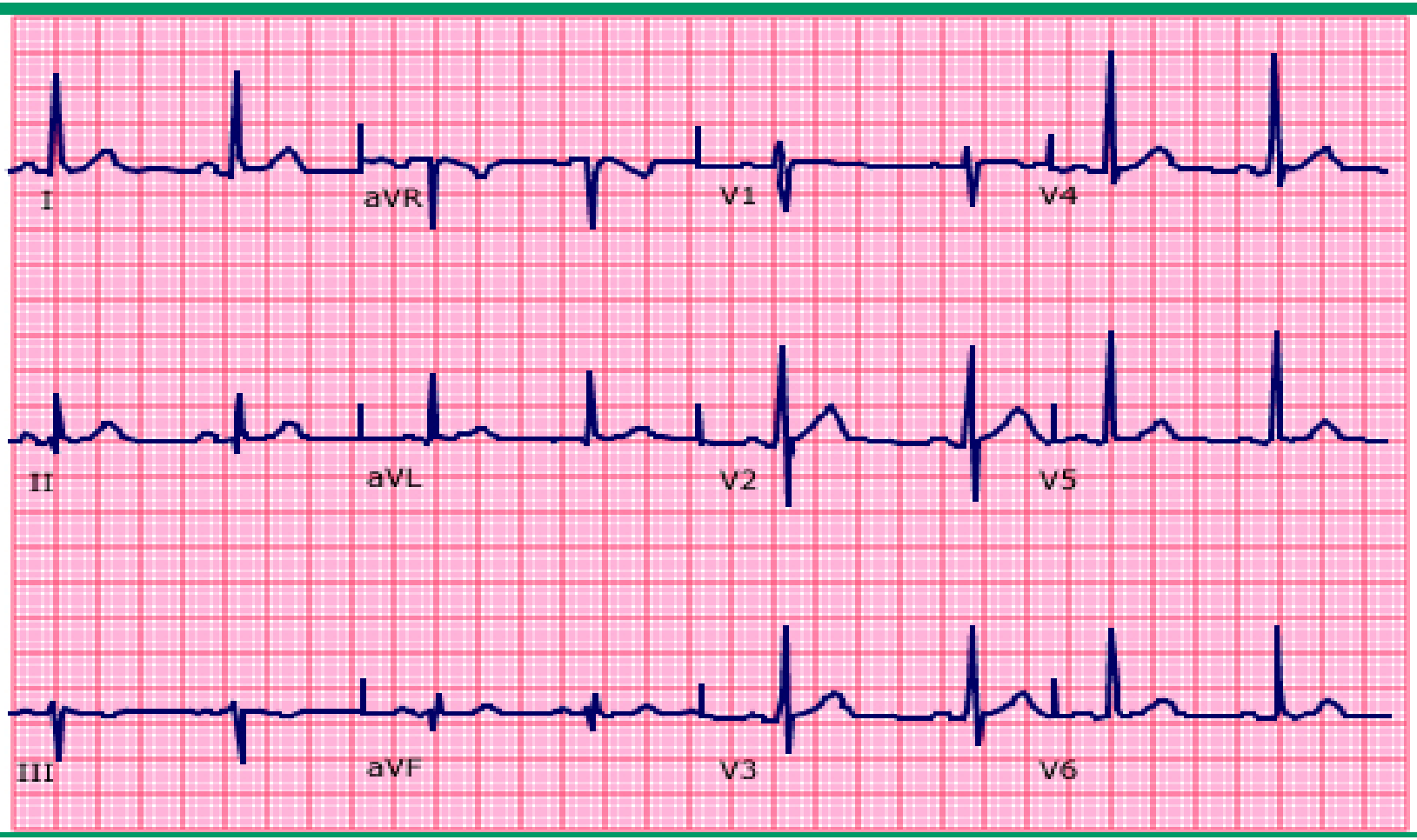

Normal sinus rhythm at a rate of 71 beats/min, a P wave axis of 45°, and a PR interval of 0.15 sec.

Courtesy of Morton Arnsdorf, MD.

UpToDate

Pericarditis

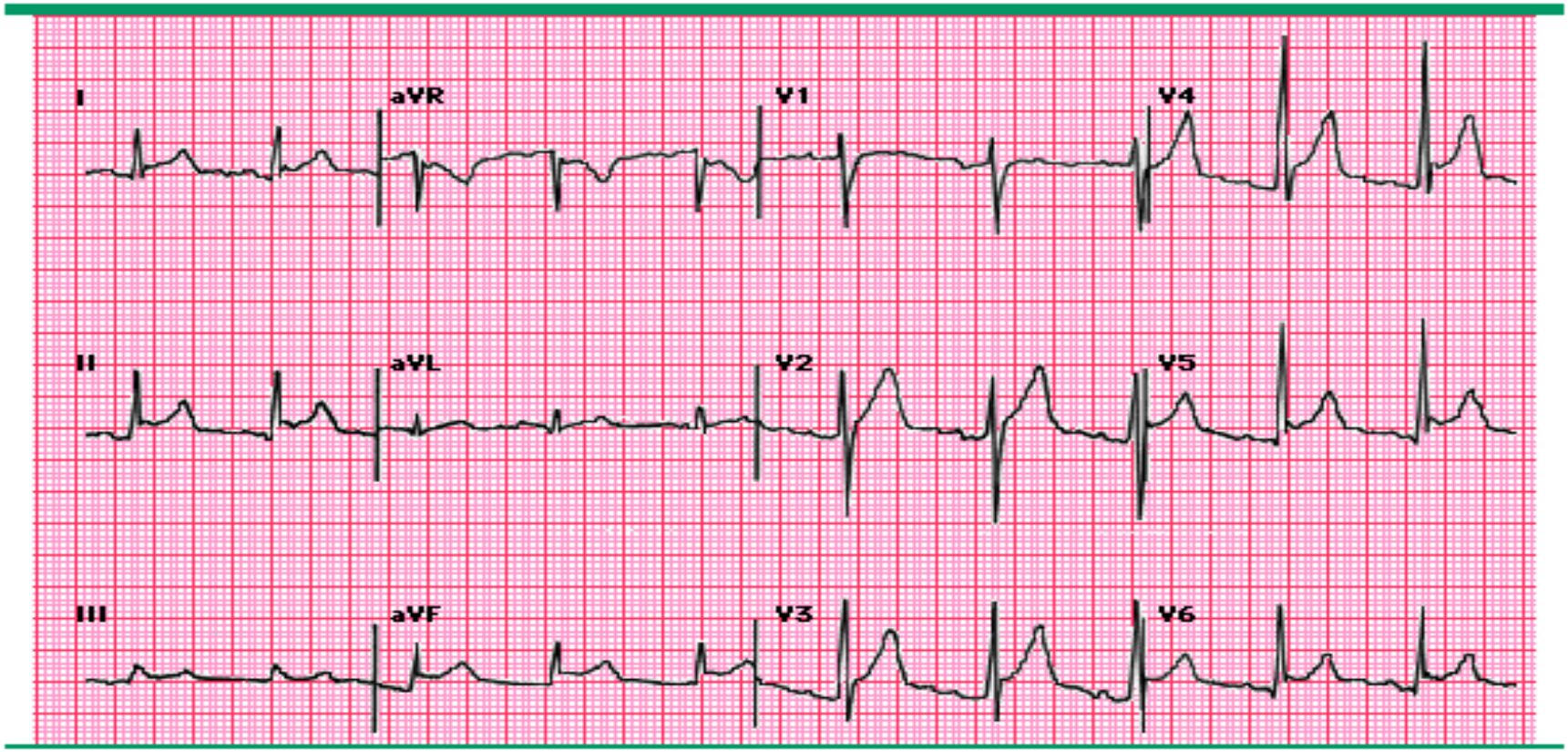

Electrocardiogram in acute pericarditis showing diffuse upsloping ST segment elevations seen best here in leads II, III, aVF, and V2 to V6. There is also subtle PR segment deviation (positive in aVR, negative in most other leads). ST segment elevation is due to a ventricular current of injury associated with epicardial inflammation; similarly, the PR segment changes are due to an atrial current of injury which, in pericarditis, typically displaces the PR segment upward in lead aVR and downward in most other leads.

Courtesy of Ary Goldberger, MD.

UpToDate

- Echocardiography is often normal in patients with the clinical syndrome of acute pericarditis unless there is an associated pericardial effusion.
- Chest radiography is typically normal in patients with acute pericarditis. Although patients with a substantial pericardial effusion may exhibit an enlarged cardiac silhouette with clear lung fields .

Chest x-ray of a pericardial effusion

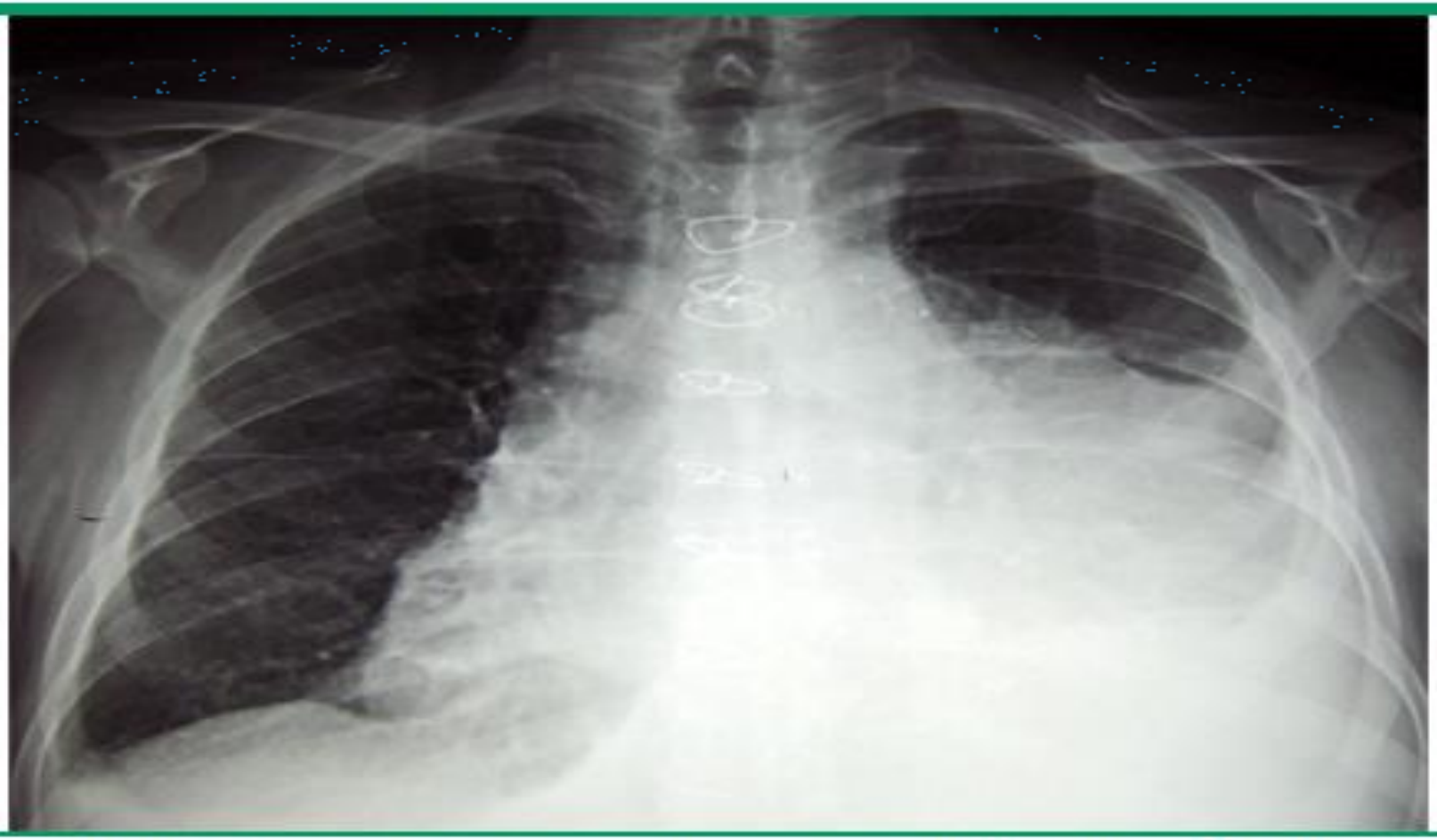

Cardiomegaly due to a massive pericardial effusion. At least 200 mL of pericardial fluid must accumulate before the cardiac silhouette enlarges.

Courtesy of Massimo Imazio, MD, FESC.

UpToDate

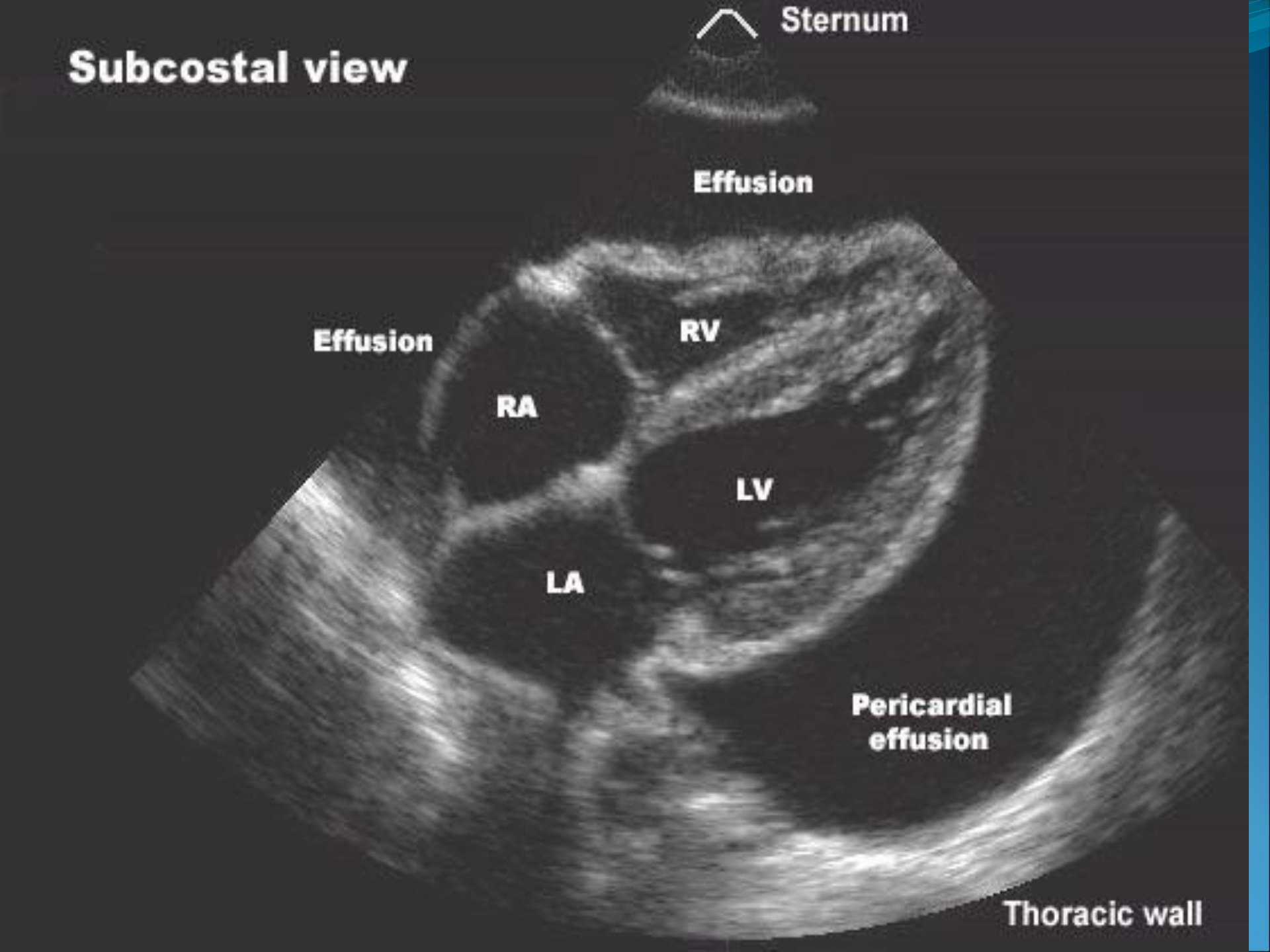
Subcostal view
Sternum
Effusion
Effusion
RV
RA
LV
LA
Pericardial effusion
Thoracic wall

Electrical alternans

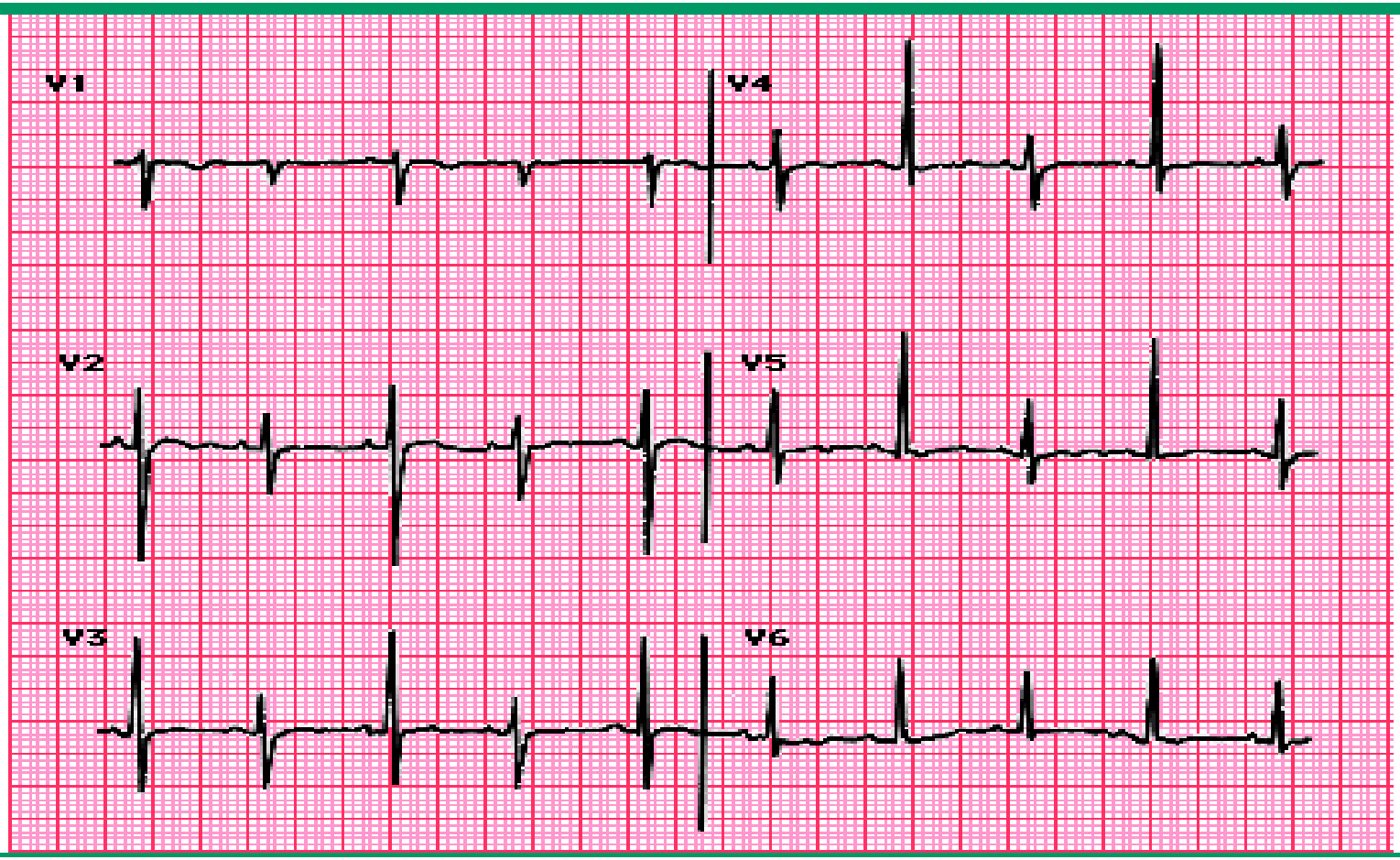

Sinus tachycardia with electrical alternans which is characterized by beat-to-beat alternation in the QRS appearance (best seen in leads V2 to V4). These findings are strongly suggestive of pericardial effusion, usually with cardiac tamponade. The alternating ECG pattern is related to back-and-forth swinging motion of the heart in the pericardial fluid.

Courtesy of Ary Goldberger, MD.

UpToDate®

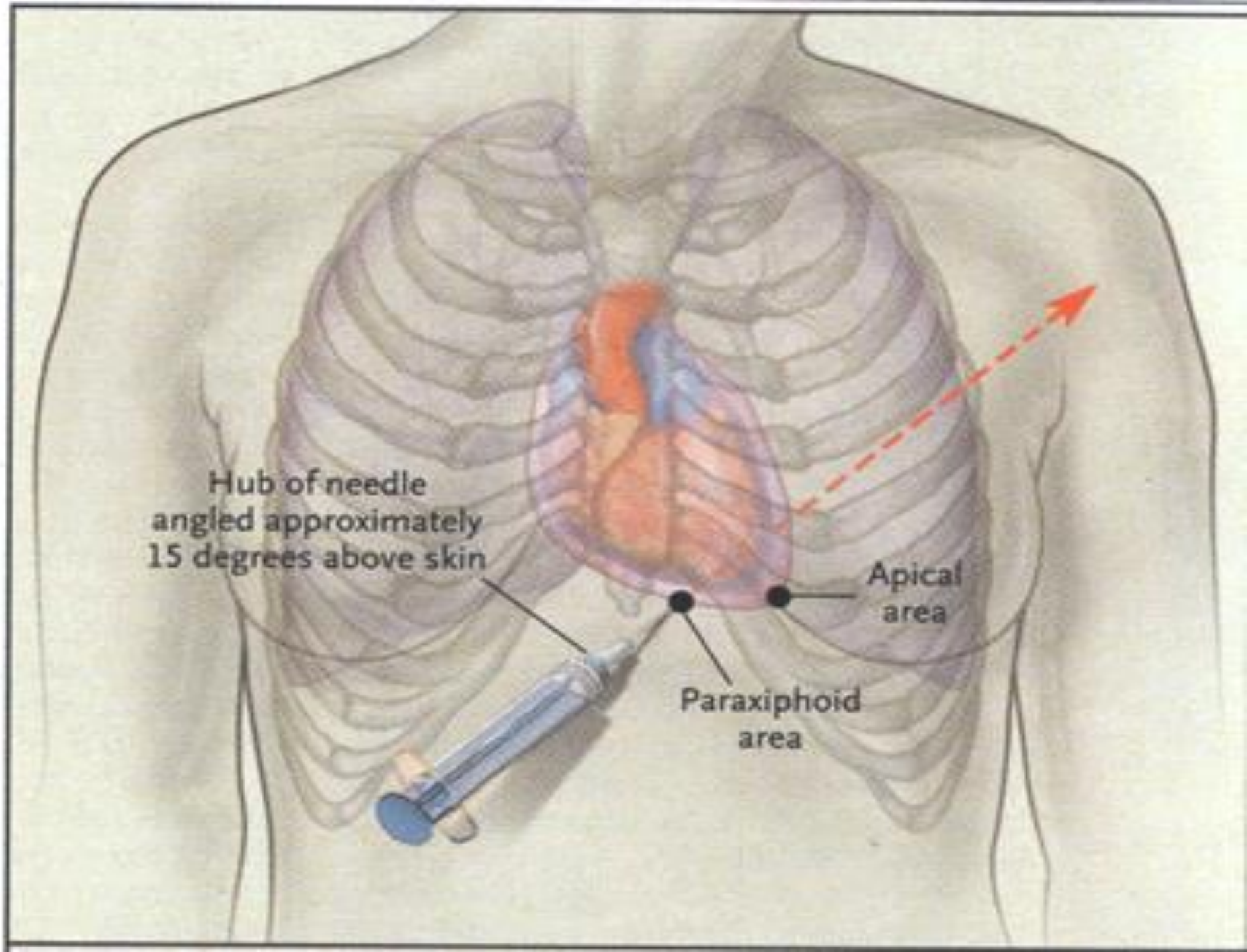
Hub of needle
angled approximately
15 degrees above skin
Apical
area
Paraxiphoid
area

- Acute pericarditis may be associated with increases in serum biomarkers of myocardial injury such as cardiac troponin or MB fraction of creatine kinase.
- Since pericarditis is an inflammatory disease, laboratory signs of inflammation are common in patients with acute pericarditis.
- These include elevations in the white blood cell count, erythrocyte sedimentation rate, and serum C-reactive protein concentration.

Diagnostic criteria for acute pericarditis and myopericarditis in the clinical setting

Acute pericarditis (at least 2 criteria of 4 should be present)*:
1. Typical chest pain
2. Pericardial friction rub
3. Suggestive ECG changes (typically widespread ST segment elevation)
4. New or worsening pericardial effusion
Myopericarditis:
1. Definite diagnosis of acute pericarditis, **PLUS**
2. Suggestive symptoms (dyspnea, palpitations, or chest pain) and ECG abnormalities beyond normal variants, not documented previously (ST/T abnormalities, supraventricular or ventricular tachycardia or frequent ectopy, atrioventricular block), **OR** focal or diffuse depressed LV function of uncertain age by an imaging study
3. Absence of evidence of any other cause
4. One of the following features: evidence of elevated cardiac enzymes (creatine kinase-MB fraction, or troponin I or T), **OR** new onset of focal or diffuse depressed LV function by an imaging study, **OR** abnormal imaging consistent with myocarditis (MRI with gadolinium, gallium-67 scanning, anti-myosin antibody scanning)
Case definitions for myopericarditis include:
Suspected myopericarditis: criteria 1 plus 2 and 3
Probable myopericarditis: criteria 1, 2, 3, and 4
Confirmed myopericarditis¶: histopathologic evidence of myocarditis by endomyocardial biopsy or on autopsy

* Pericardial effusion confirms the clinical diagnosis but its absence does not exclude it.
¶ In clinical practice a confirmed diagnosis would require an endomyocardial biopsy that is not warranted in self-limited cases with predominant pericarditis.

Reproduced with permission from: Imazio M, Trinchero R. Triage and management of acute pericarditis. Int J Cardiol 2006, doi:10.1016/j.ijcard.2006.07.100. Copyright © 2006 Elsevier.

UpToDate®

- **Treatment:**
- In cases of pericarditis due to an identifiable cause (eg, bacterial infection or malignancy), management is focused upon the underlying disorder and, if necessary, drainage of an associated pericardial effusion.

- For most patients with acute idiopathic or viral pericarditis, combination therapy with colchicine plus NSAIDs rather than NSAIDs alone.
- This is based upon a reduced rate of recurrent pericarditis and a low incidence of side effects with colchicine.

- In patients with acute pericarditis following an MI, aspirin plus colchicine rather than another NSAID plus colchicine
- This is principally due to the possibility that other NSAIDs may interfere with healing and scar formation.
- Although the evidence of potential harm from glucocorticoids and NSAIDs other than aspirin is modest, there is no evidence that these medications improve outcomes.

- ***For these reasons glucocorticoids and NSAIDs other than aspirin should generally be AVOIDED in patients with acute pericarditis following an acute MI.***

Steroids

- pericarditis due to connective tissue disease, autoreactive (immune-mediated) pericarditis, uremic pericarditis not responding to dialysis, and to patients who have contraindications to NSAID therapy.

- Glucocorticoid therapy is also used for patients with idiopathic or viral pericarditis that is refractory to combination therapy with NSAIDs and colchicine.

Drug therapy in acute pericarditis

Drug	Dose	Duration of therapy	Tapering
For initial combination treatment of most patients:			
Ibuprofen	400 to 800 mg three times daily	1 to 2 weeks	Decrease the dose weekly
OR			
Indomethacin	50 mg three times daily	1 to 2 weeks	Decrease the dose weekly
PLUS			
Colchicine	0.5 mg two times daily	3 months	Usually not tapered
For initial combination therapy of patients following myocardial infarction:			
Aspirin	650 to 1000 mg three times daily	1 to 2 weeks	Decrease the dose weekly
PLUS			
Colchicine	0.5 mg two times daily	3 months	Usually not tapered
For refractory cases or patients with a contraindication to NSAID therapy:			
Prednisone	0.2 to 0.5 mg/kg/day	2 weeks	Slow tapering, see text
PLUS			
Colchicine	0.5 mg two times daily	3 months	Usually not performed

UpToDate

Initial clinical and echocardiographic evaluation of patients with suspected acute pericarditis

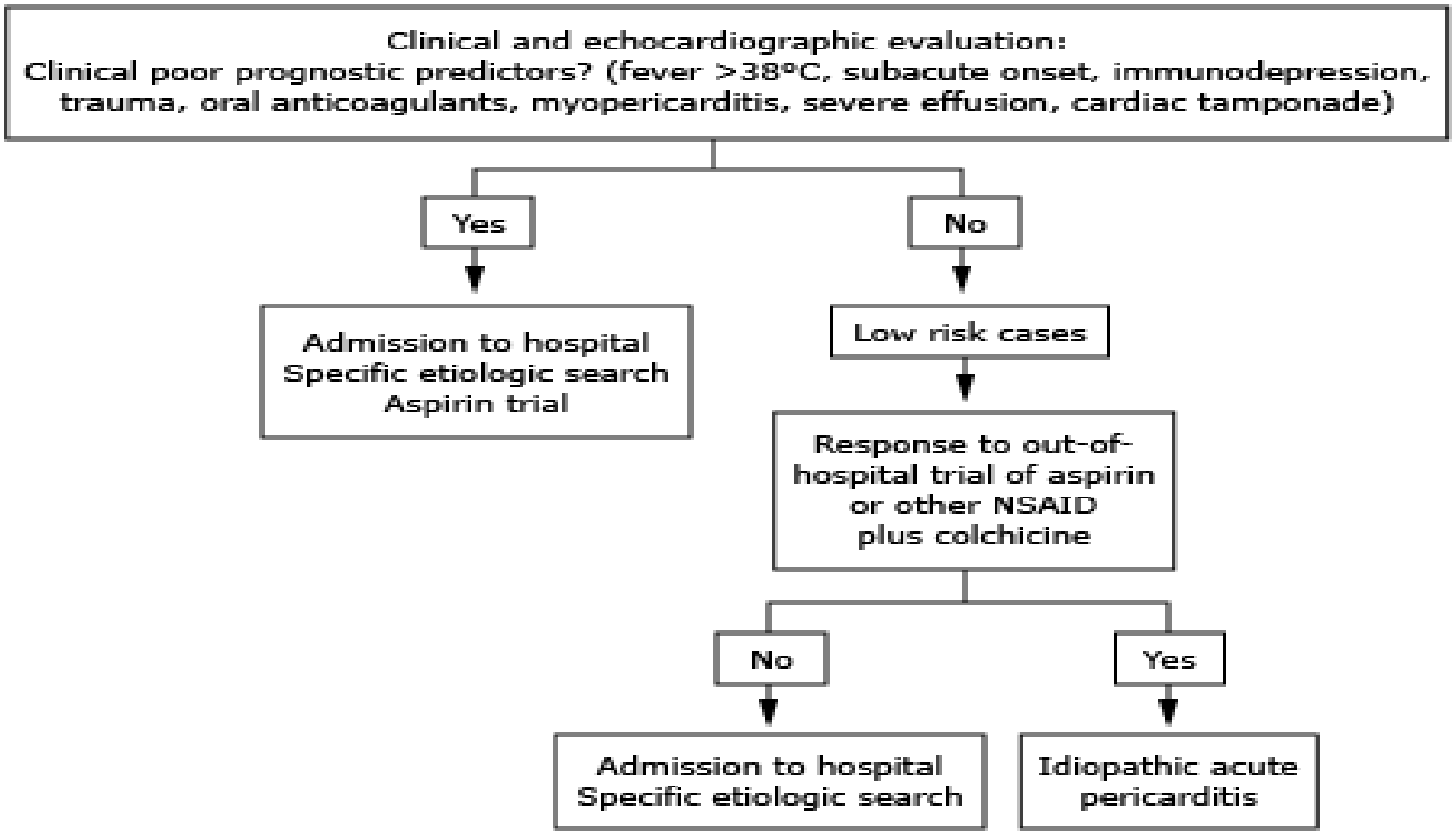

Reproduced with permission and modified from: Imazio, M, Demichelis, B, Parrini, I, et al. Day-hospital treatment of acute pericarditis: a management program for outpatient therapy. J Am Coll Cardiol 2004; 43:1042. Copyright © 2004 Elsevier.

UpToDate

Pericardial Tamponade

- Causes
  - Trauma, uremia, anticoagulation, neoplasm, infection
- Clinical signs (Beck's triad, 1935)
  - Hypotension, JVD, muffled heart sounds
  - pulsus paradoxus
- ECG
  - Electrical alternans (beat to beat alteration in the amplitude of the QRS complex)
  - low voltage
- ECHO findings
  - Effusion
  - RV diastolic collapse (specific for tamponade)

Pericardial Effusion

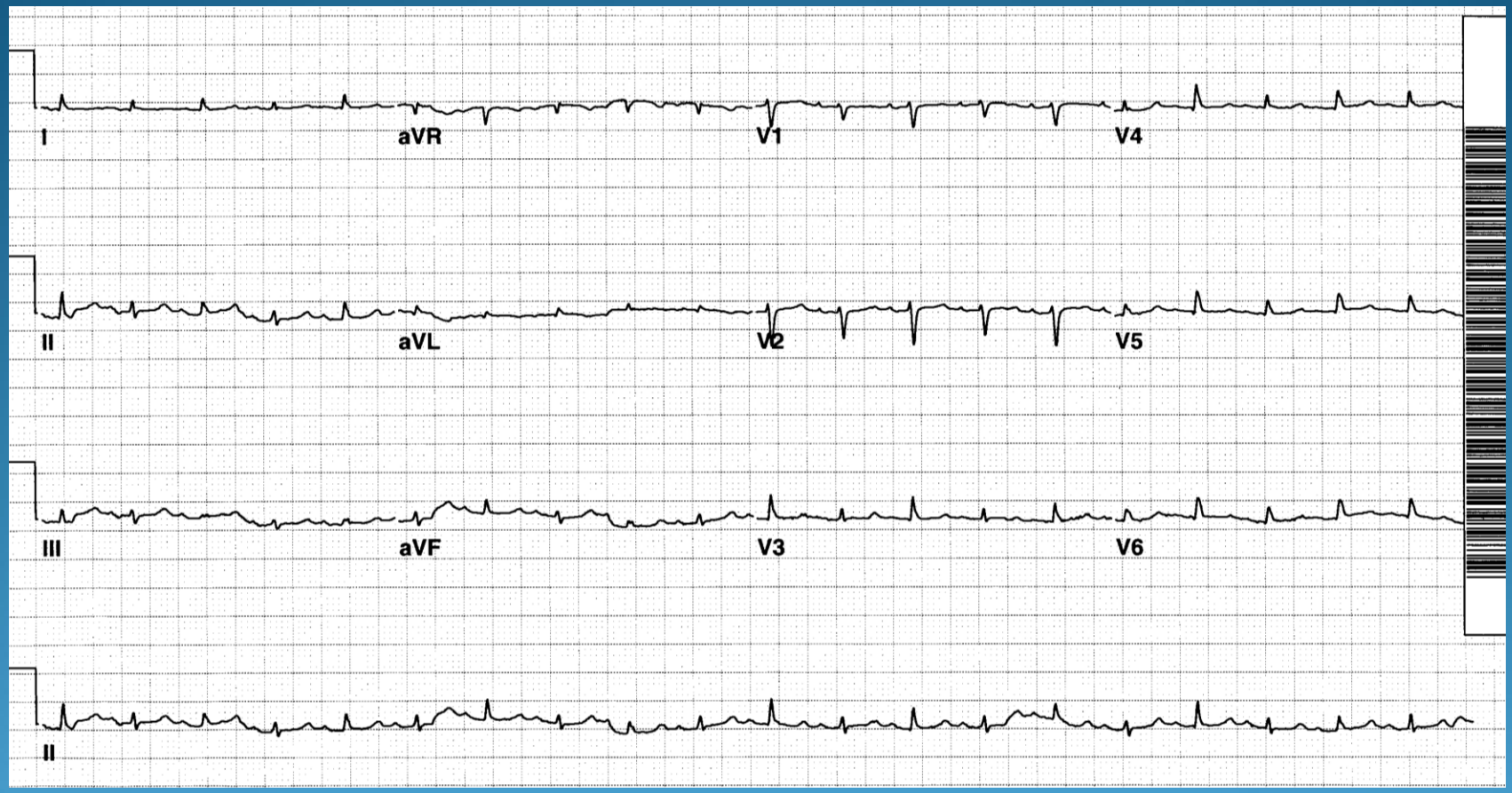

From *ECGs for the Emergency Physician Vol 1* (Mattu, Brady; Blackwell 2003)

Constrictive Pericarditis

- Thick dense fibrous obliteration with calcification of the pericardial sac encasing the heart
- limiting diastolic expansion and restricting cardiac output

Constrictive Pericarditis

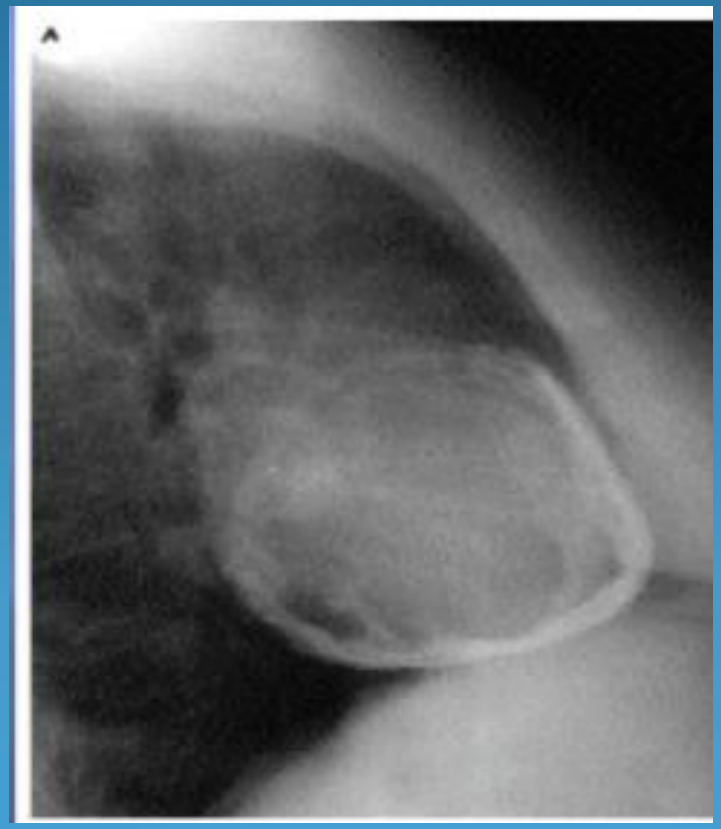

Absence of calcification does not r/o constrictive pericarditis

Constrictive Pericarditis

- Evidence of right heart failure
- Kussmaul sign: no fall or even elevation JVP with inspiration
- Abnormal echo

- A 32-year-old-male patient presented to your office for an ECG as ordered by his insurance company.

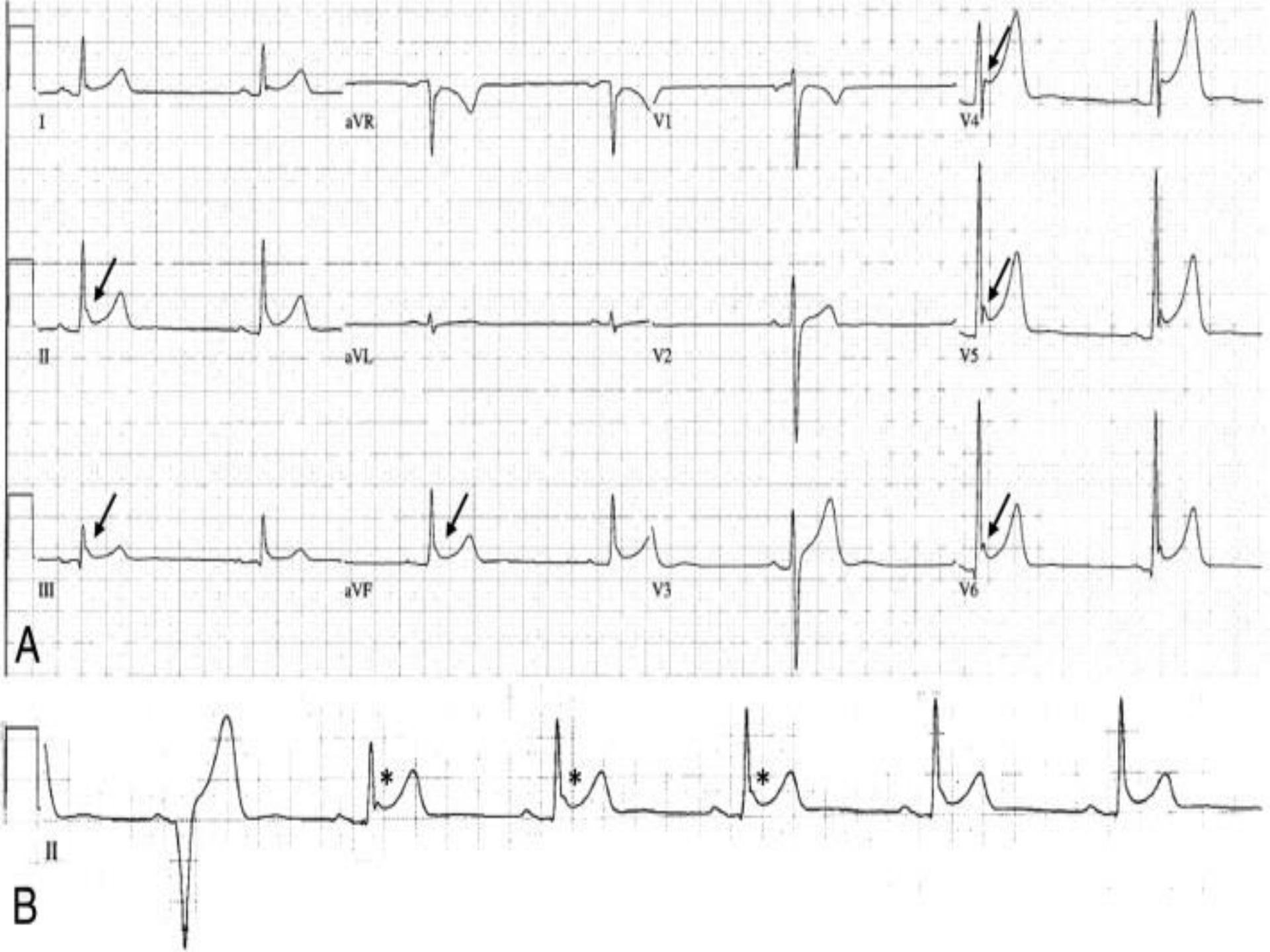
I
aVR
V1
V4
II
aVL
V2
V5
III
aVF
V3
V6
A
II
B

- A 46-year-old-male patient with a pmhs of hypertension and smoking presented to the ED with chest pain.

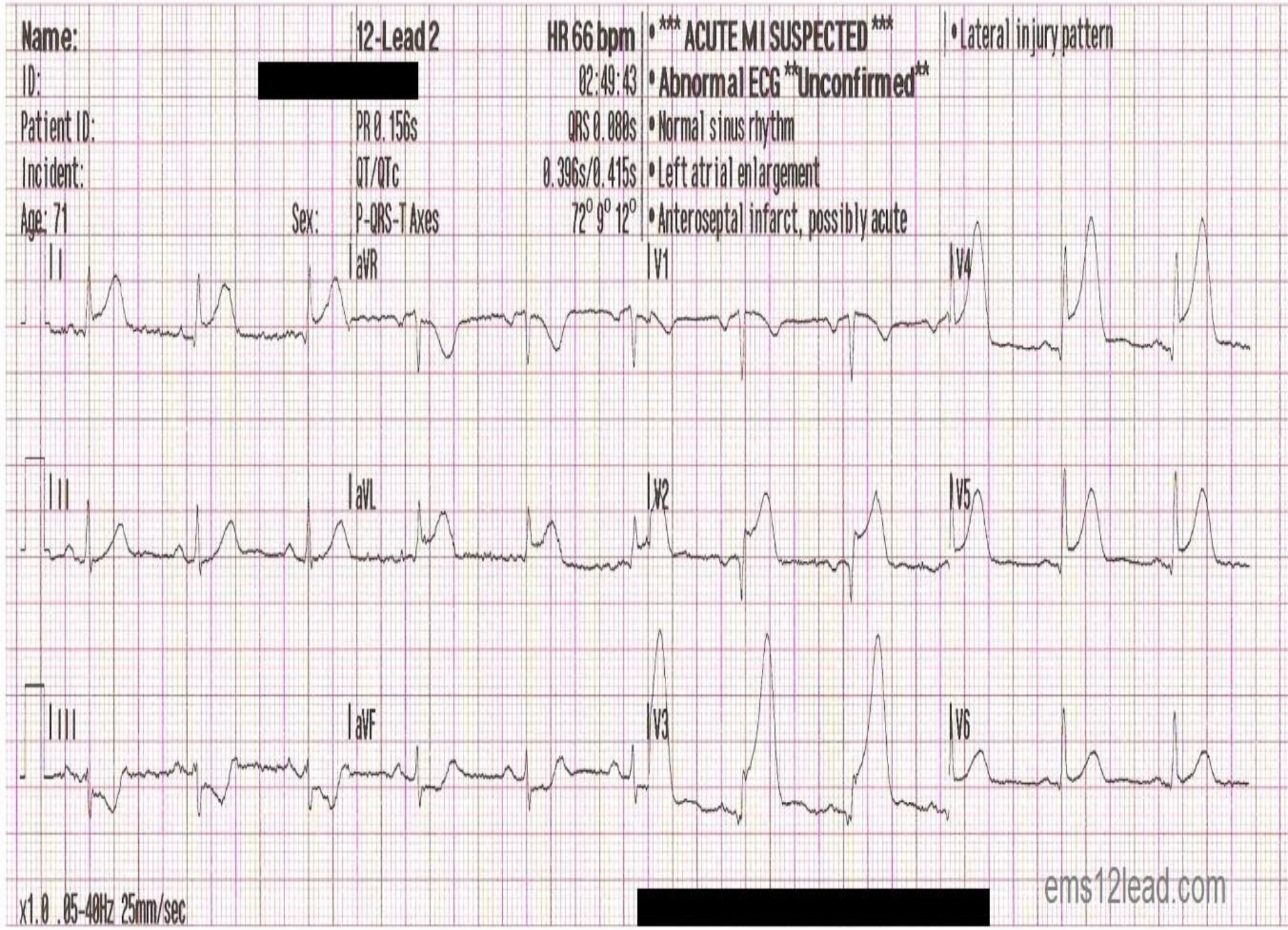
Name:
12-Lead 2
HR 66 bpm
*** ACUTE MI SUSPECTED ***
Lateral injury pattern
ID:
[redacted]
02:49:43
Abnormal ECG **Unconfirmed**
Patient ID:
PR 0.156s
QRS 0.080s
Normal sinus rhythm
Incident:
QT/QTc
0.396s/0.415s
Left atrial enlargement
Age: 71
Sex:
P-QRS-T Axes
72° 9° 12°
Anteroseptal infarct, possibly acute
I
aVR
V1
V4
II
aVL
V2
V5
III
aVF
V3
V6
x1.0 .05-40Hz 25mm/sec
[redacted]
ems12lead.com

- A 25-year old male pt. presented with worsening dyspnea to the ED. His heart rate was 140 bpm and BP 80/40 mm Hg.

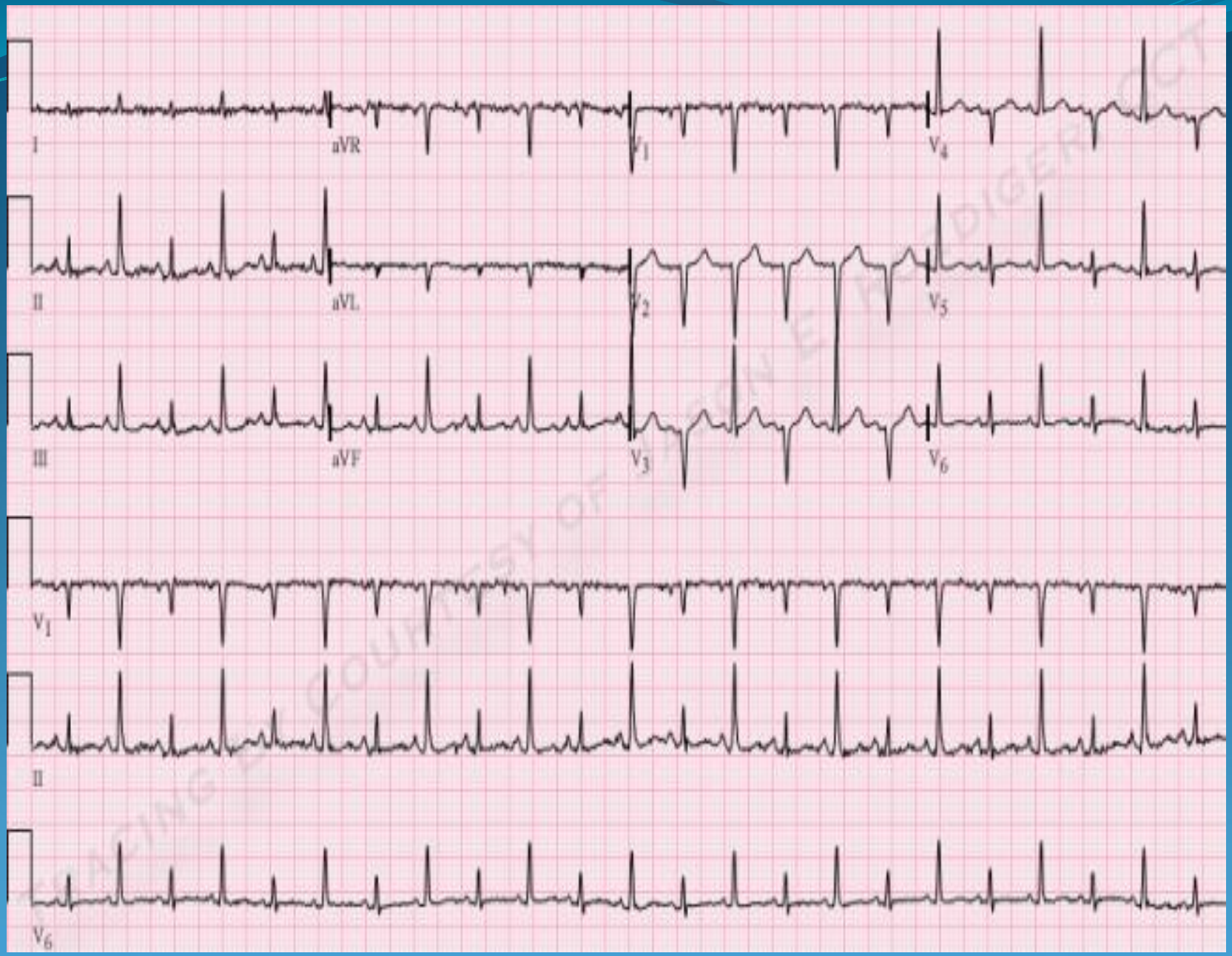
I
aVR
V1
V4
II
aVL
V2
V5
III
aVF
V3
V6
V1
II
V6

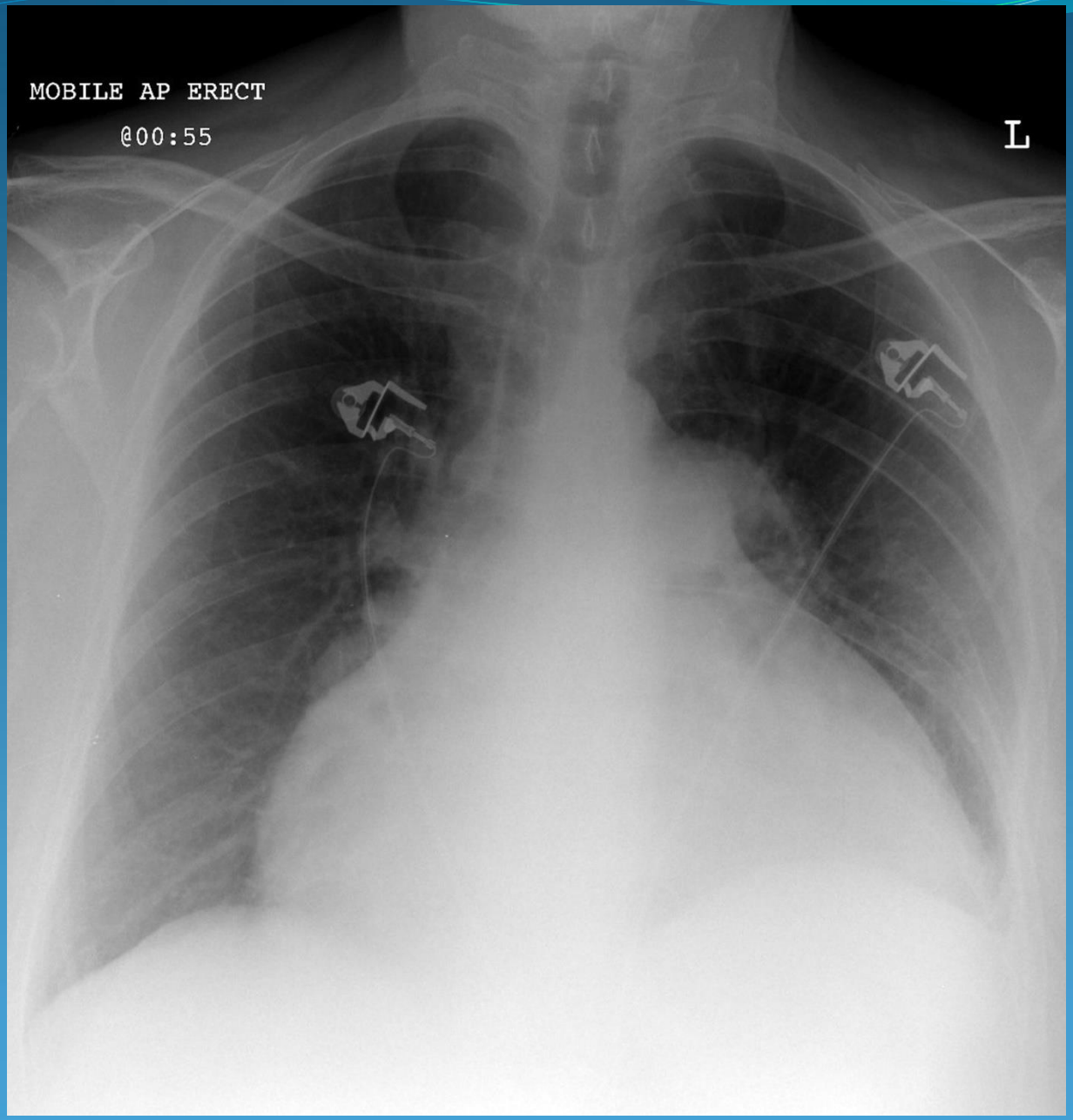
MOBILE AP ERECT
@00:55
L

Good Luck