Clinical Approach to Neurological History and Examination

Said S Dahbour.MD. FAAN
Professor of Medicine (Neurology)
Faculty of Medicine/ University of Jordan
September 2021

What Is The Purpose of Neurological History and Physical Examination?

- Is there a lesion in the nervous system?
- Where is that lesion in the nervous system?
- What caused that lesion ?

Understanding sings and symptoms of the Nervous System

Function	**DysFunction**
Consciousness	Coma
Cognitive function Mental processes	Dementia/ Delerium Psychiatric disorders
Special senses	Blindness
Motor control	Weakness
Sensory processing	Pain
Coordination	Ataxia
Endocrine	Endocrinopathy
Autonomic	Autonomic failure

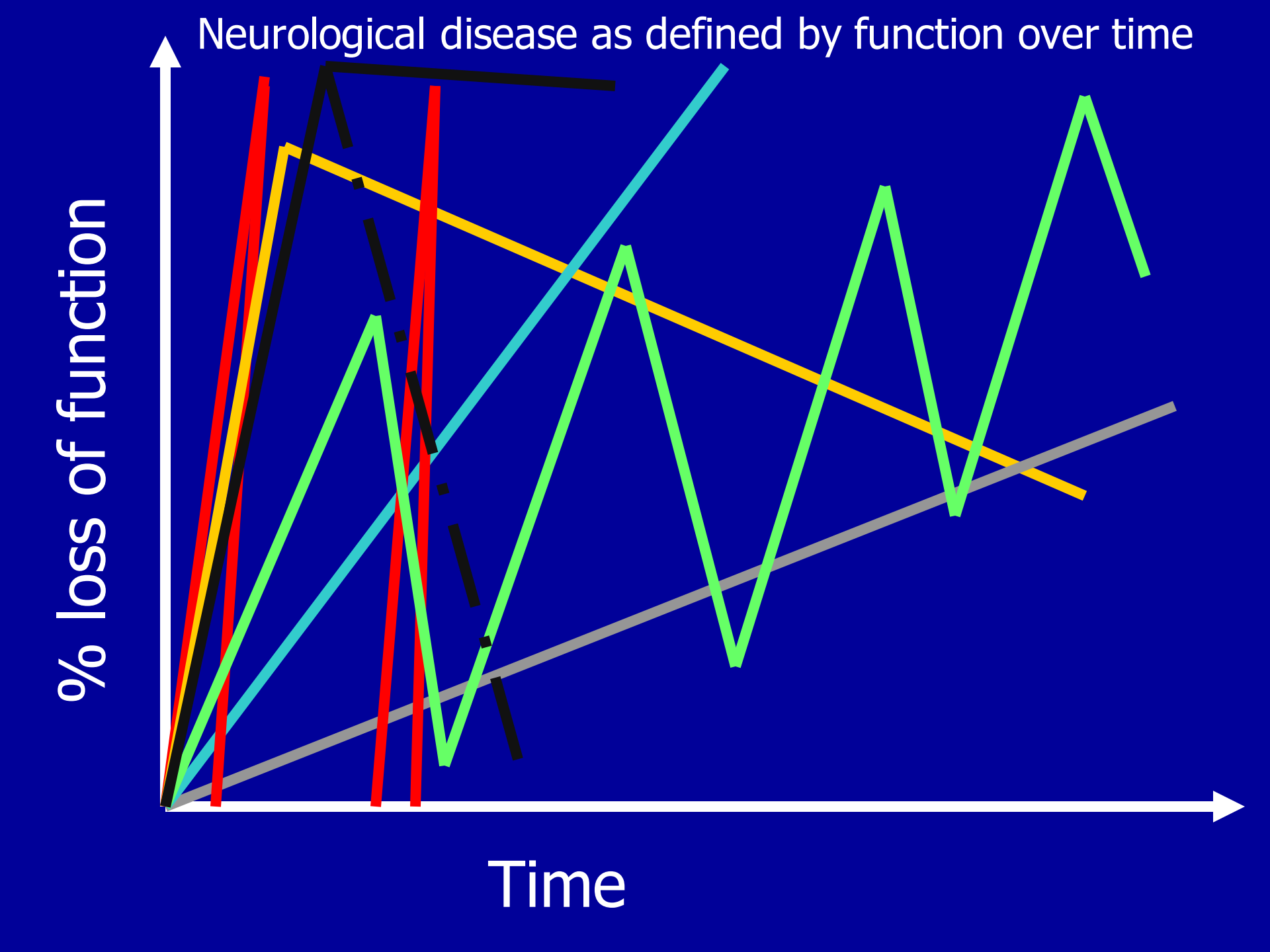
Neurological disease as defined by function over time
% loss of function
Time

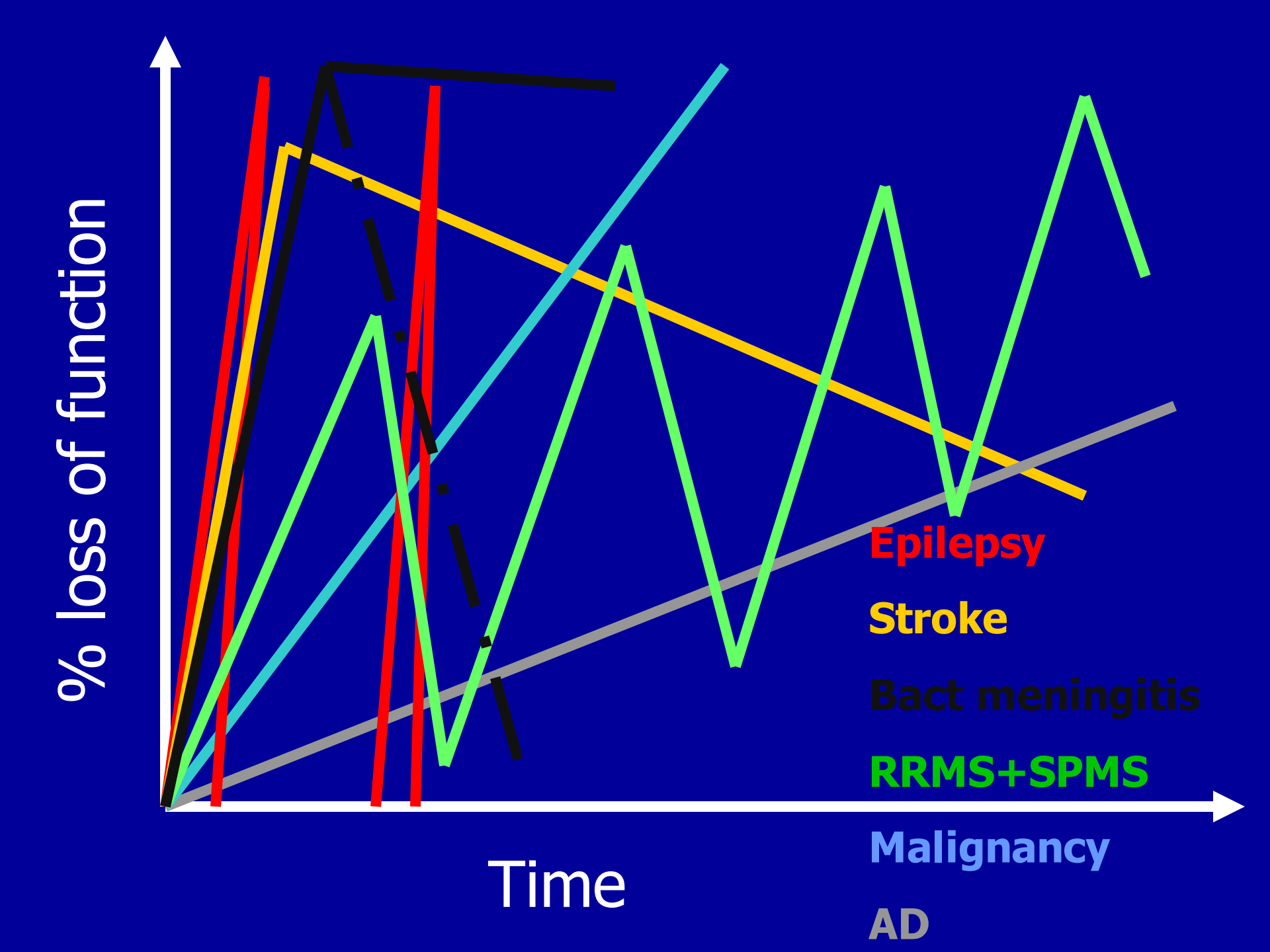
% loss of function
Time
Epilepsy
Stroke
Bact meningitis
RRMS+SPMS
Malignancy
AD

Physical examination

Some Tools Used For Neurological Examination



General Approach to Neurological Examination

- General look of patient
- Vital signs
- Level of consciousness
- High cognitive functions
- Cranial nerves 1-12
- Motor system: bulk, tone, power, reflexes
- Sensory system
- Coordination and cerebellum
- Stance and gait

RAS and the Thalamo-Cortical System

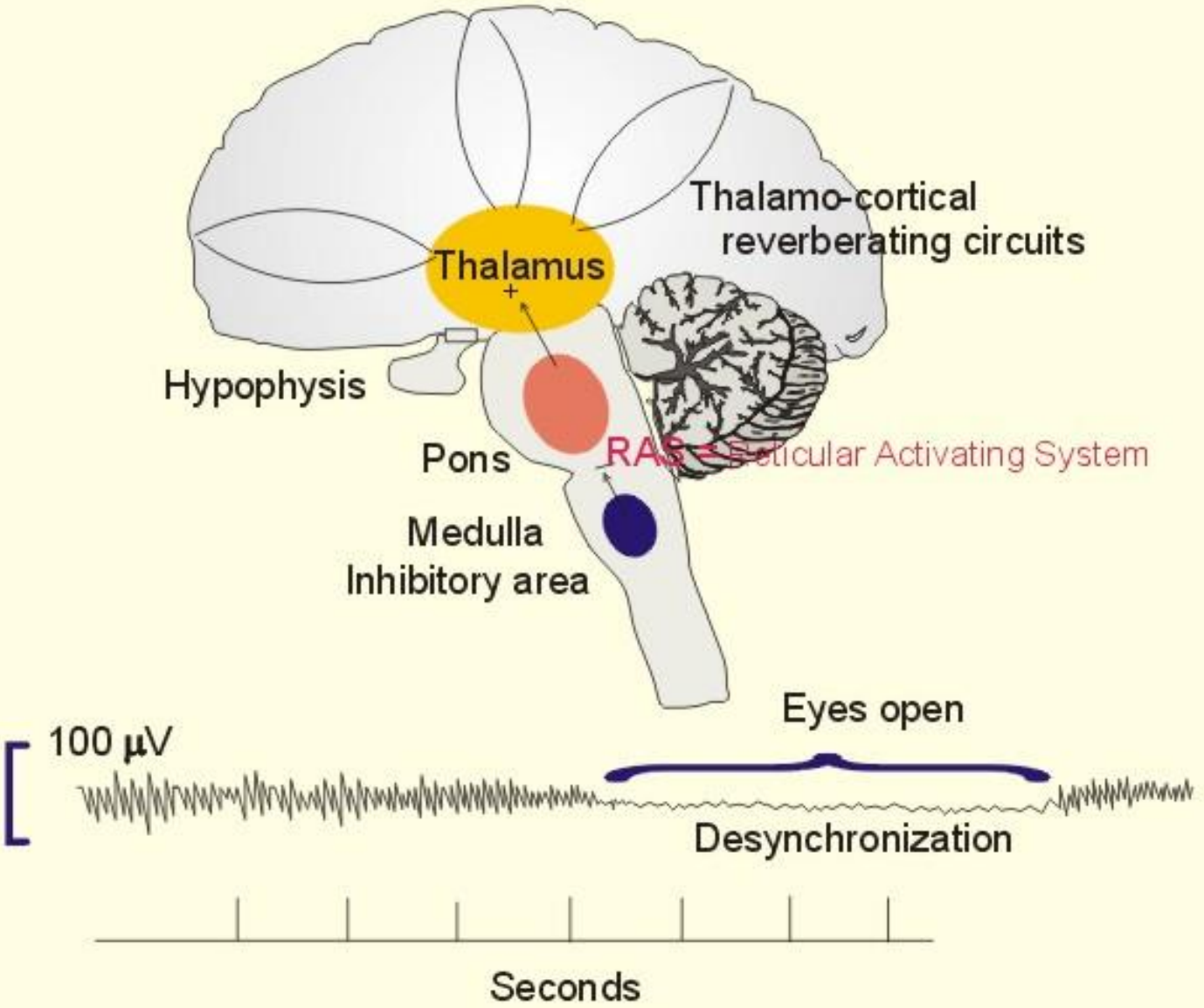

KMc

Level of Consciousness (Arousal): Technique and Patient Response

Level	Technique
Alertness	Speak in a normal tone and voice. An alert patient opens the eyes, looks at you, and responds fully and appropriately to stimuli (arousal intact)
Lethargy	Speak in a loud voice. For example call the patient name or ask :(How R U?)
Obtundation	Shake the patient gently as if awakening a sleeper
Stupor	Apply a painful stimulus e.g. Pinch a tendon, rub the sternum, or roll a pencil across a nail bed. (No stronger stimuli are needed)
Coma	Apply repeated painful stimuli

Glasgow Coma Scale

Eye opening (E)	
Nil	1
Pain	2
Verbal	3
Spontaneous	4

Verbal response (V)	
Nil	1
Incomprehensible	2
Inappropriate	3
Confused	4
Oriented fully	5

Motor response (M)	
Nil	1
Abnormal extension	2
Abnormal flexion	3
Weak flexion	4
Localizing	5
Obeys command	6

Coma= E2V2M4 or Less

Speech and articulation

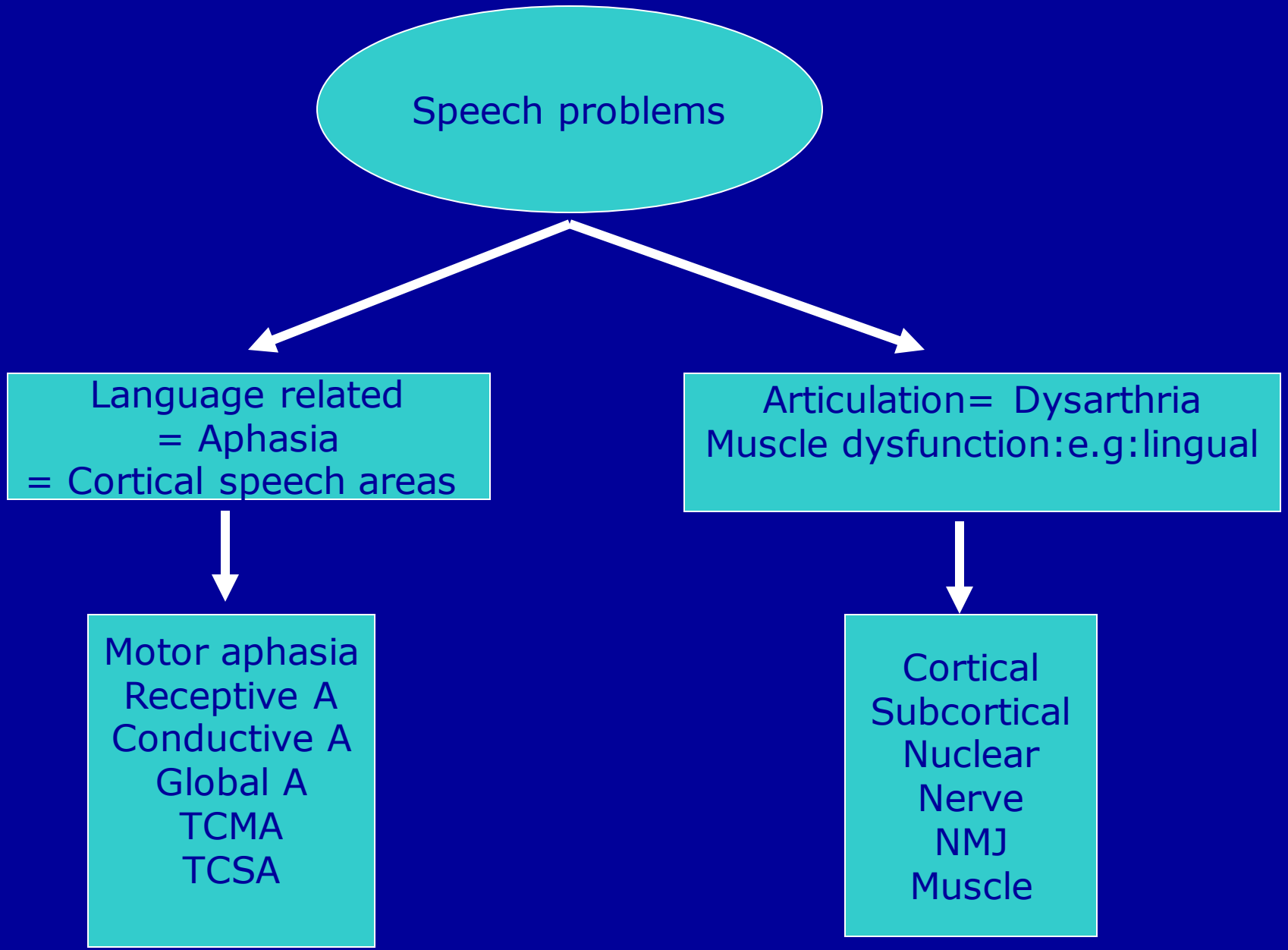
Speech problems
Language related
= Aphasia
= Cortical speech areas
Articulation= Dysarthria
Muscle dysfunction:e.g:lingual
Motor aphasia
Receptive A
Conductive A
Global A
TCMA
TCSA
Cortical
Subcortical
Nuclear
Nerve
NMJ
Muscle

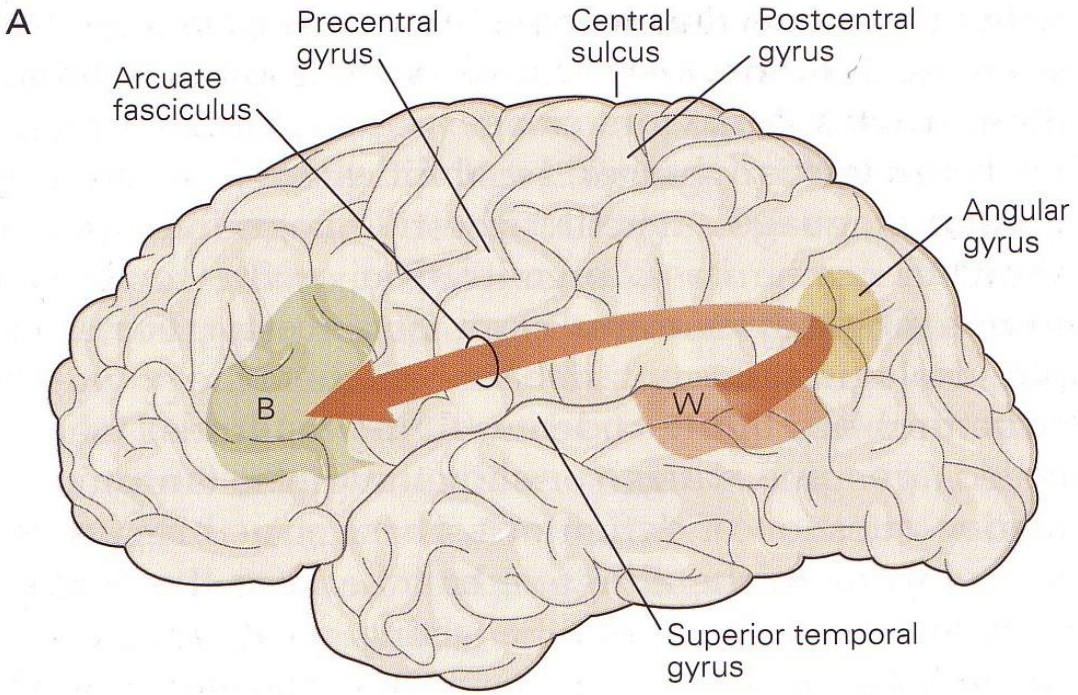

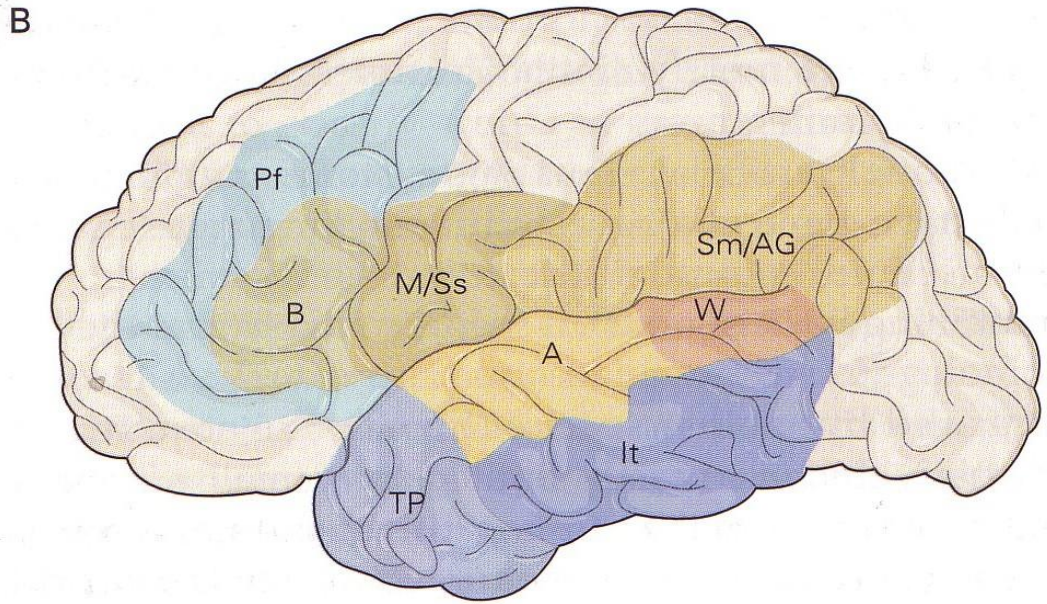

Old an New Concepts of Language Areas in the Brain

Implementation system

Mediational system

Conceptual system

Testing for Aphasia

- Fluency of speech
- Comprehension
- Naming
- Repetition
- Reading and its comprehension
- Writing

DDX of Aphasia

Type	Speech	Comprehension	Repetition	Lesion
BA	Non fluent	Normal	Impaired	Lt post frontal
WA	Fluent	Impaired	Impaired	Lt post & middle temp cortex
CA	Fluent	Normal	Impaired	Lt super temporal and supramarginal
GA	Non fluent	Impaired	Impaired	Massive lt perisylvian
MTC	Non fluent	Normal	Normal	Ant or sup to B area
STC	Fluent	Impaired	Normal	Post or infer to W area

BA= Broac's aphasia, WA=Wernicke's A, CA=conduction A, GA=Global A, MTC=motor transcortical A, STC=sensory transcortica A

Mini Mental Status Examination MMSE

Orientation
Month (1)
Day (1)
Date (1)
Year (1)
Season (1)
Where R U? (1)
What floor? (1)
City? (1)
Muhafaza ? (1)
Country ? (1)

REGISTRATION (immediate memory) State 3 items			
Ball (1)			
Flag (1)			
Tree (1)			
ATTENTION Spell the word عوالم Backwards or Subtract 7 from 100 to 65			
م	93	(1)	
ل	86	(1)	MMSE
ا	79	(1)	
و	72	(1)	
ع	65	(1)	

LANGUAGE

Naming

Watch (1)

Pen (1)

Repeat

لا شك و لا جدال و لا نقاش في ذلك (1)

Comprehension:

Take this paper in your right hand (1)

Fold it in half (1)

Put it on the floor (1)

Reading : read and obey

اغلق عينيك (1)

Writing : write a sentence (1)

Visuospatial : copy transecting pentagons (1)

RECALL (recent memory) can you recall the 3 words

Ball (1) Flag (1) Tree (1)

MMSE

Total score = 30

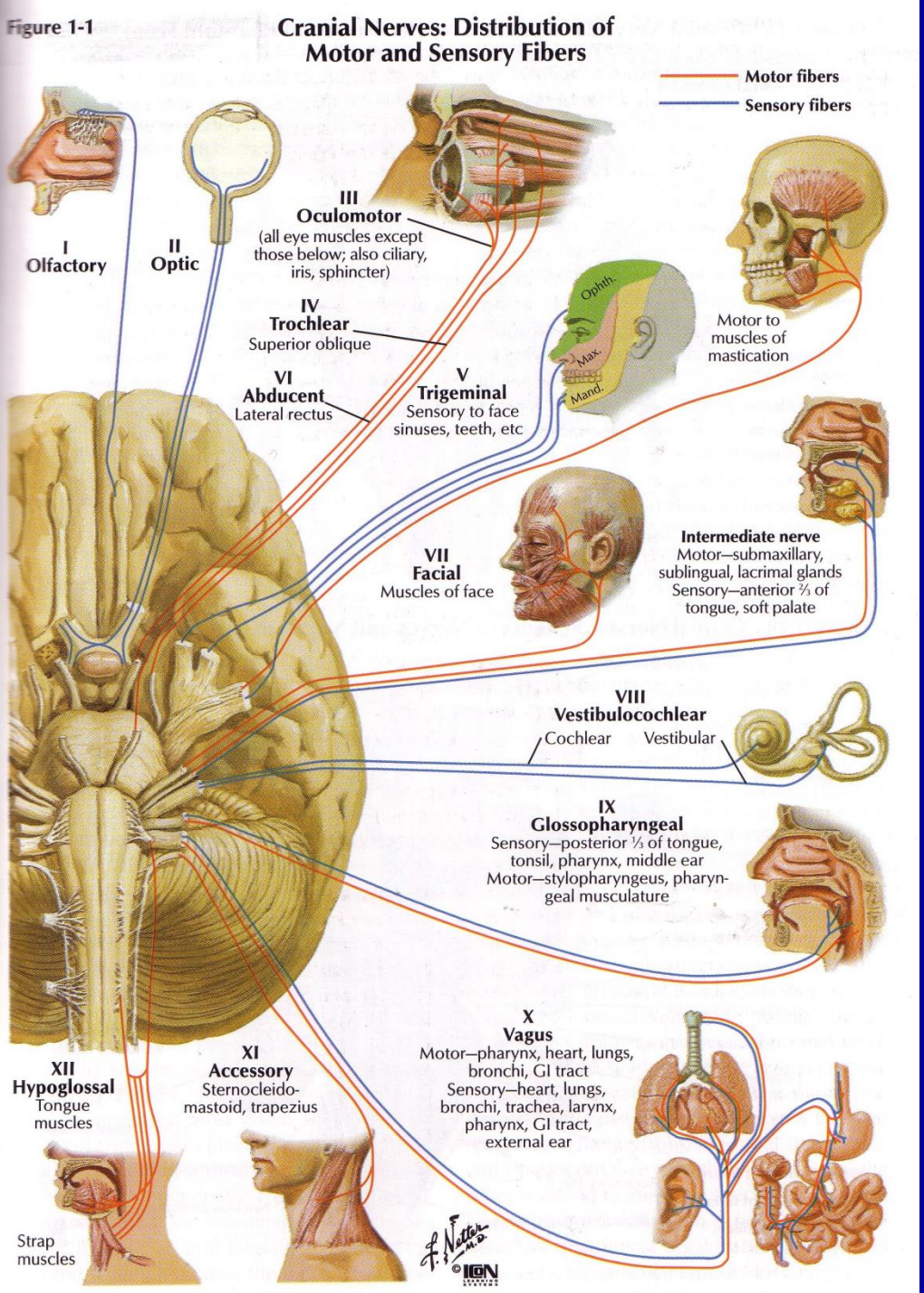

Cranial Nerves

Cranial nerves examination

Cranial N	Special	Motor	Sensory	Reflex
Olfactory	Smell	None	None	None
Optic	Visual acuity and fields, fundoscopy	None	None	Pupillary accomodation
Oculomotor	None	MR,SR,IR,IO, LPS,ciliary, pupillary constrictor muscles	None	Pupillary, accomodation
Trochlear	None	SOM	None	None
Trigeminal	None	Temporalis, masseters, ptyregoids	facial	Corneal, jaw
Abducens	None	LRM	None	None

CNII: Visual fields

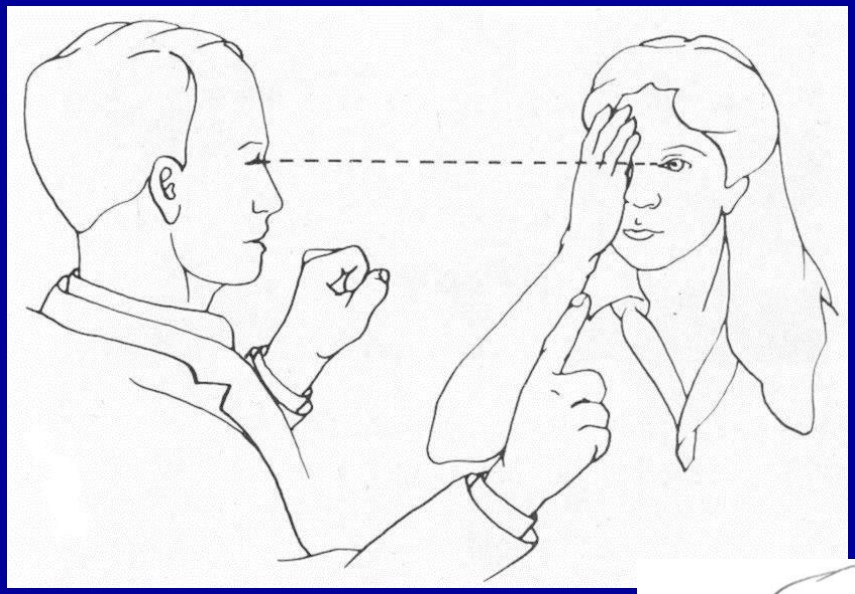

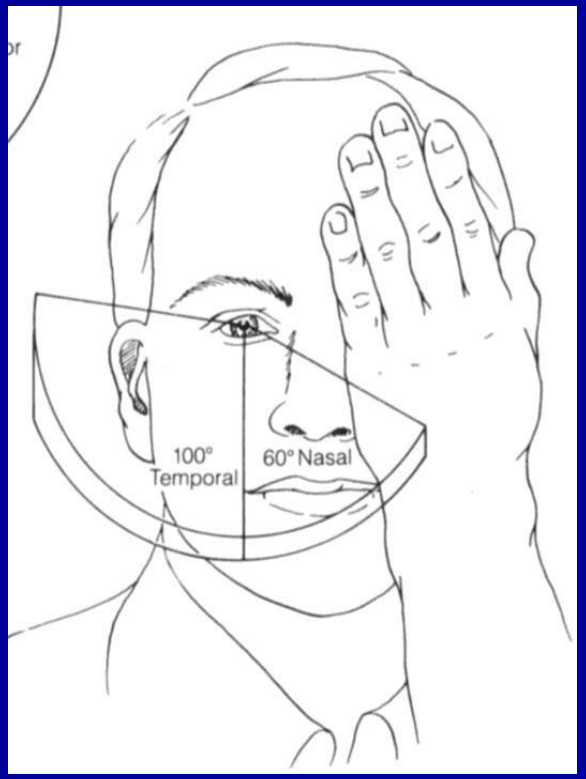

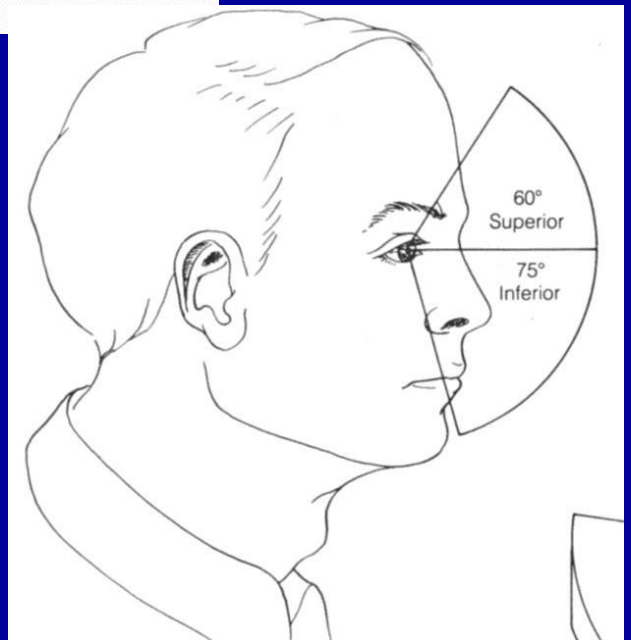

Pupil size

Myosis

mydriasis

Anisocorea

Extraocular Movements

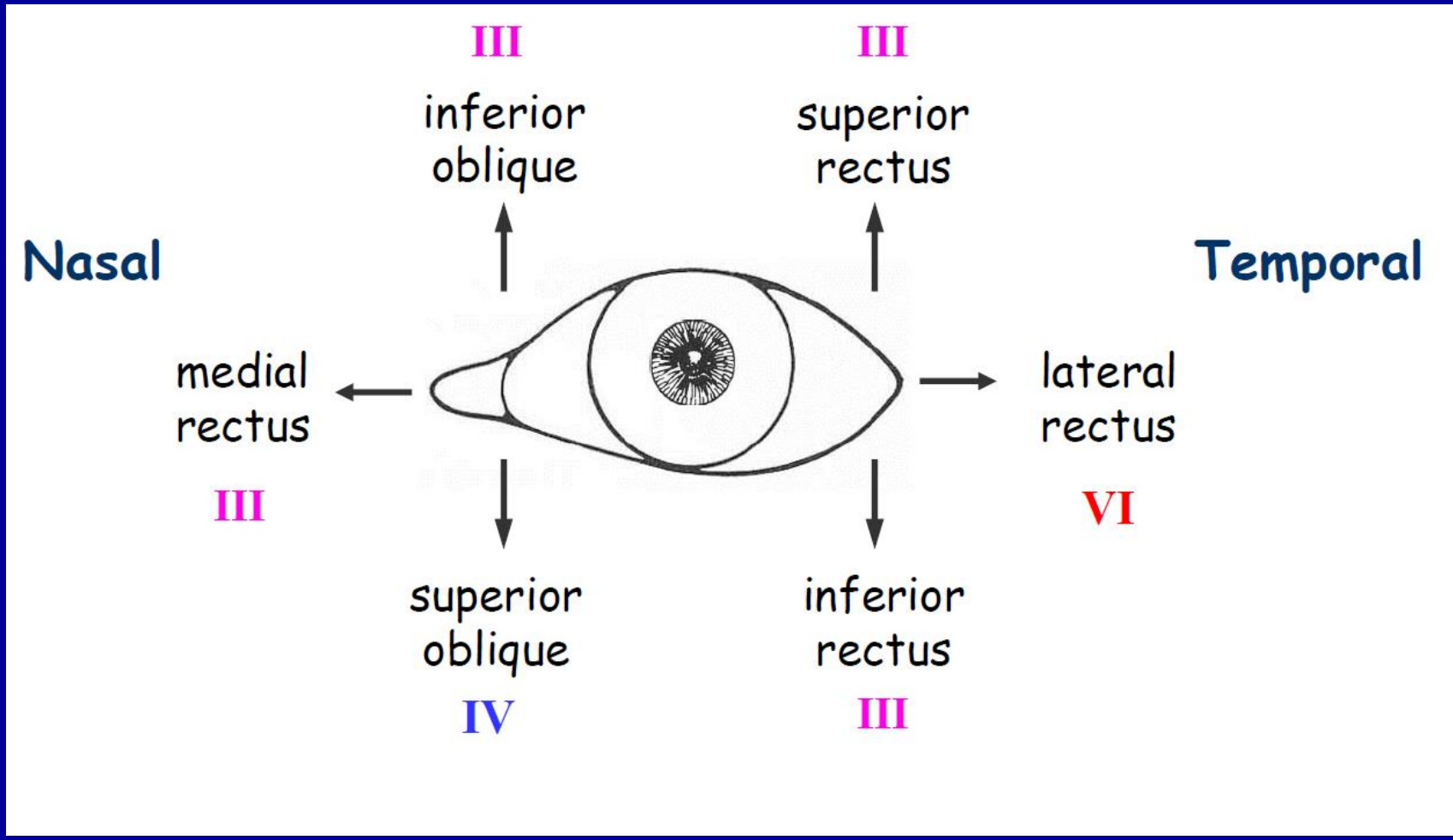

Cranial nerves examination

Cranial N	Special	Motor	Sensory	Reflex
Facial	Taste ant 2/3	Facial	EAM	Corneal
Vestibulococlear	Balance, Hearing,	None	None	Oculovestibular
Glossopharyngeal	Taste post 1/3	stylopharyngeus	pharyngeal	Gag
Vagus	None	Pharynx, Larynx	EOM	Gag
Accessory	None	SCM, TRZ	None	None
Hypoglossal	None	Tongue	None	None

Motor system examination

- Inspection and palpation of muscles
- Assessment of tone
- Examination of reflexes
- Testing movement and power
- Testing coordination

MRC Scale for muscle power

- 0 No muscle contraction visible
- 1 Flicker of contraction but no movement
- 2 Joint movement when effect of gravity eliminated
- 3 Movement against gravity but not against examiner's resistance
- 4 Movement against resistance but weaker than normal
- 5 Normal power

Definitions of paralysis

Paresis	Partial paralysis
Plegia	Complete paralysis
Monoplegia	Involvement of a single limb
Hemiplegia	Involvement of one-half of the body in the sagittal plane
Paraplegia	Paralysis of the legs
Tetraplegia	Paralysis of all four limbs

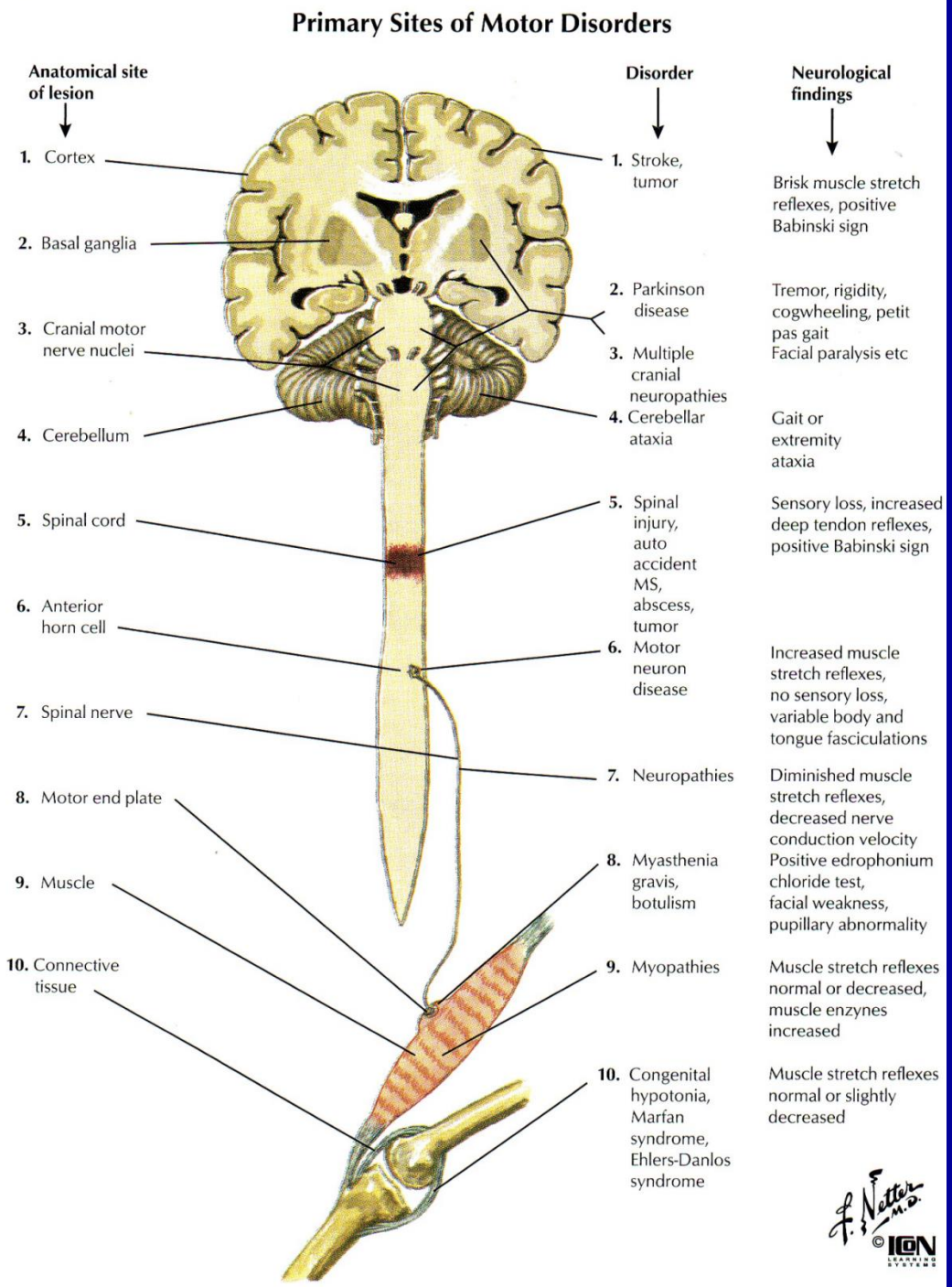

Motor Dysfunction Levels

Patterns of motor dysfunction

- Paralysis or weakness
- Impairment of coordination
- Changes in tone and posture (dystonia)
- Involuntary movements (dyskinesia)
- Changes in the rate at which movements are performed (hypokinesis and bradykinesis)
- Loss of learned movement patterns (dyspraxia)

Differential Features of Weakness

Feature	**Upper motor Neuron**	**Lower motor Neuron**
Power	Weak	Weak
Tone	Increased (spastic)	Decreased (flaccid)
Bulk	Normal	Atrophy
Reflexes	Increased (hypereflexia)	Decreased (hyporeflexia)
Fasciculations	Absent	May be present
Babinski sign	Present	Absent
Distribution	Proximal >distal	distal > proximal

Weakness patterns

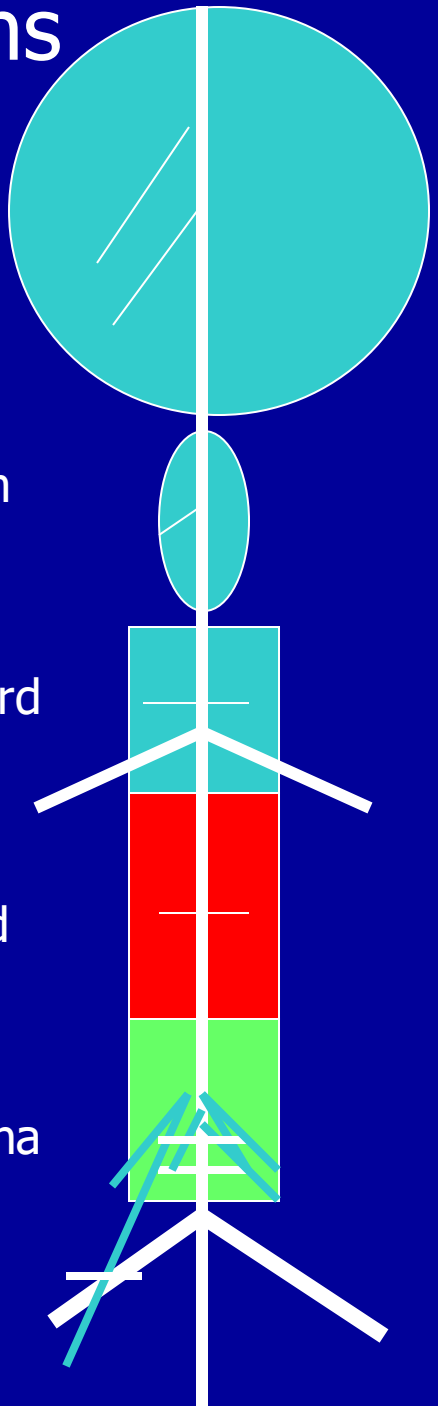

Cerebrum

Contralateral hemiplegia

Brainstem

Crossed hemiplegia

Cervical cord

Quadreplegia spastic

Dorsal cord

Paraplegia spastic

Cauda equina

Paraplegia flaccid

Roots/ plexus

Monoplegia

Reflexes

Commonly Tested Reflexes

Reflex	Segment / Nerve
Jaw jerk	Pons/ Trigeminal
Biceps	***C5*** , C6 / Musculocutaneous
Supinator	C5, ***C6*** / Radial
Triceps	C6, ***C7*** / Radial
Knee jerk	L2, ***L3, L4*** / Femoral
Ankle jerk	S1 / Sciatic
Abdominal upper	T8, T9, T10 / Intercostal
Abdominal lower	T10, T11, T12 / Intercostals
Cremasteric	L 1/ Ilioingual
Planter	L5, S1/ Sciatic

DTRs Grades

Grade	Description	comment
0	Absent	GBS
1+	Decreased	Neuropathy
2+	NORMAL	REFERENCE
3+	Increased	?anxiety
4+	Increased	Clonus



Reflex Hummer

Plantar reflex

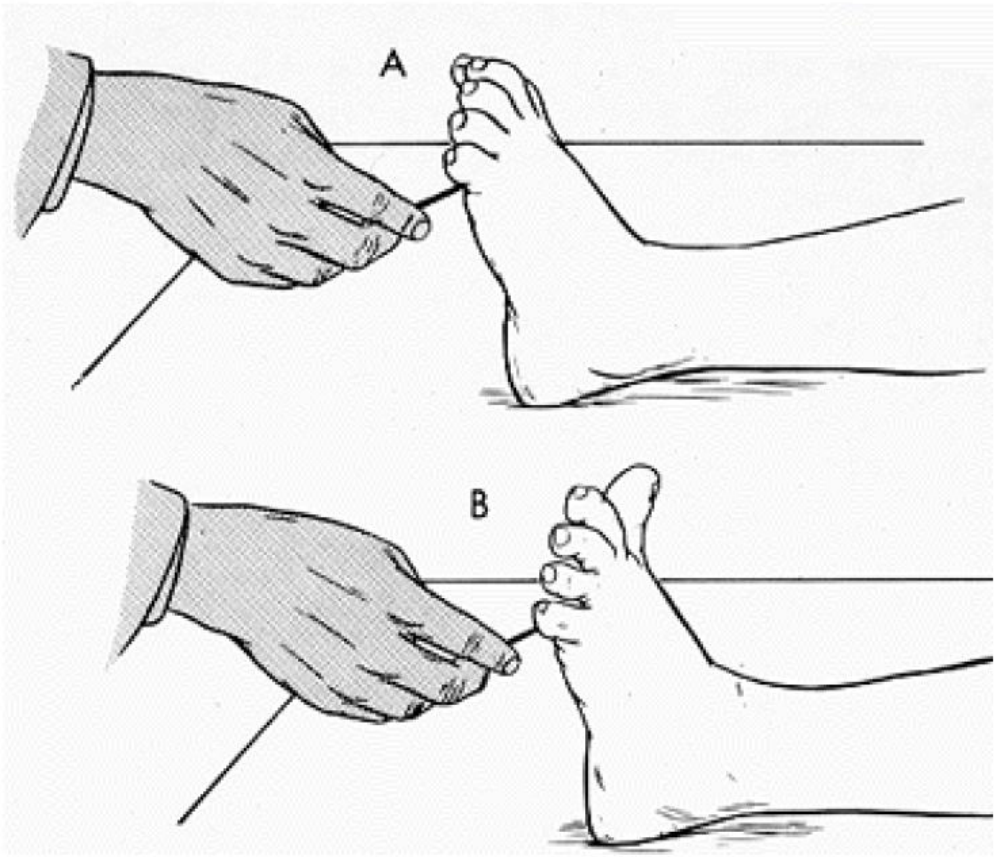

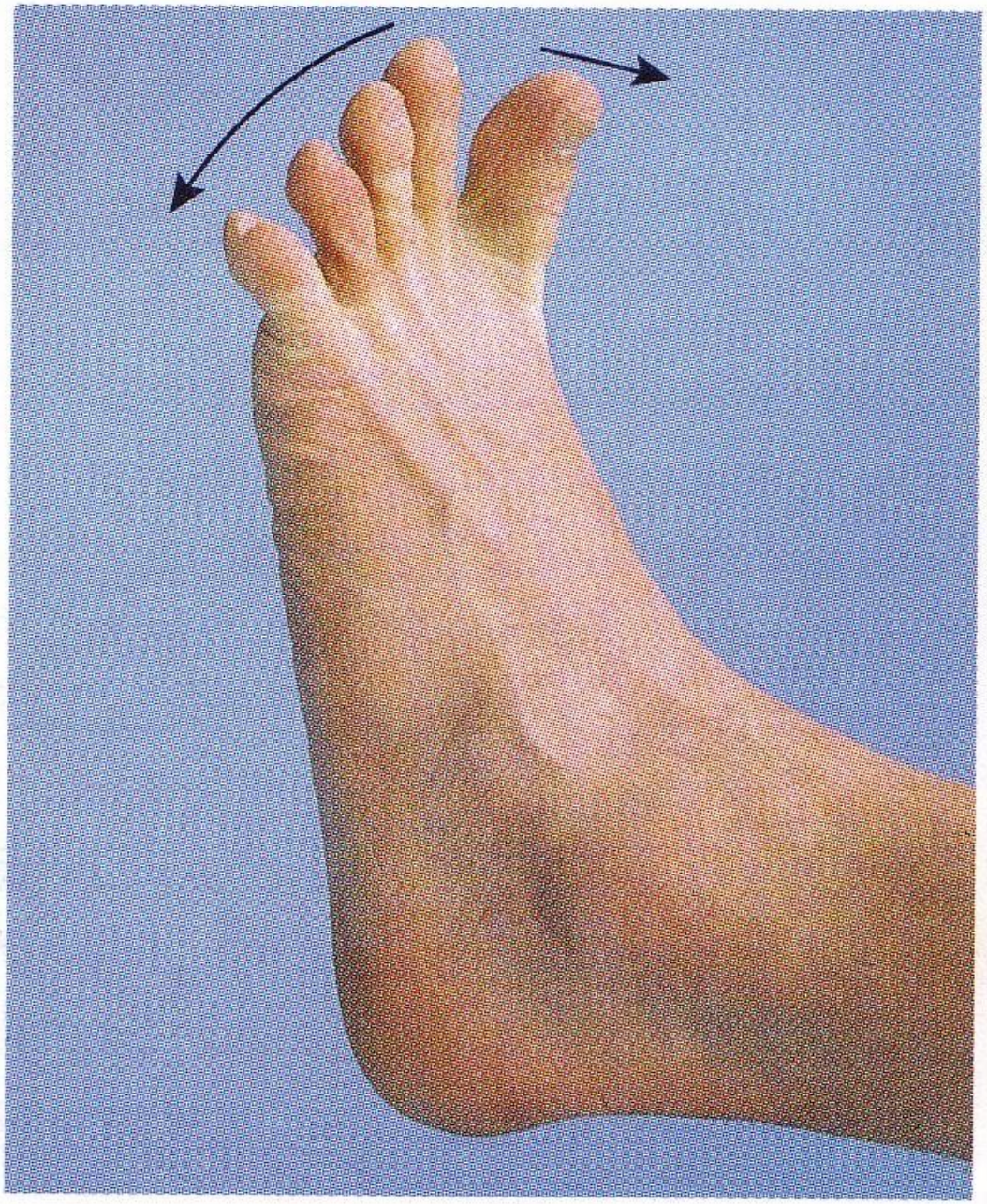

Babenski's sign is an Abnormal Response

Ankle clonus

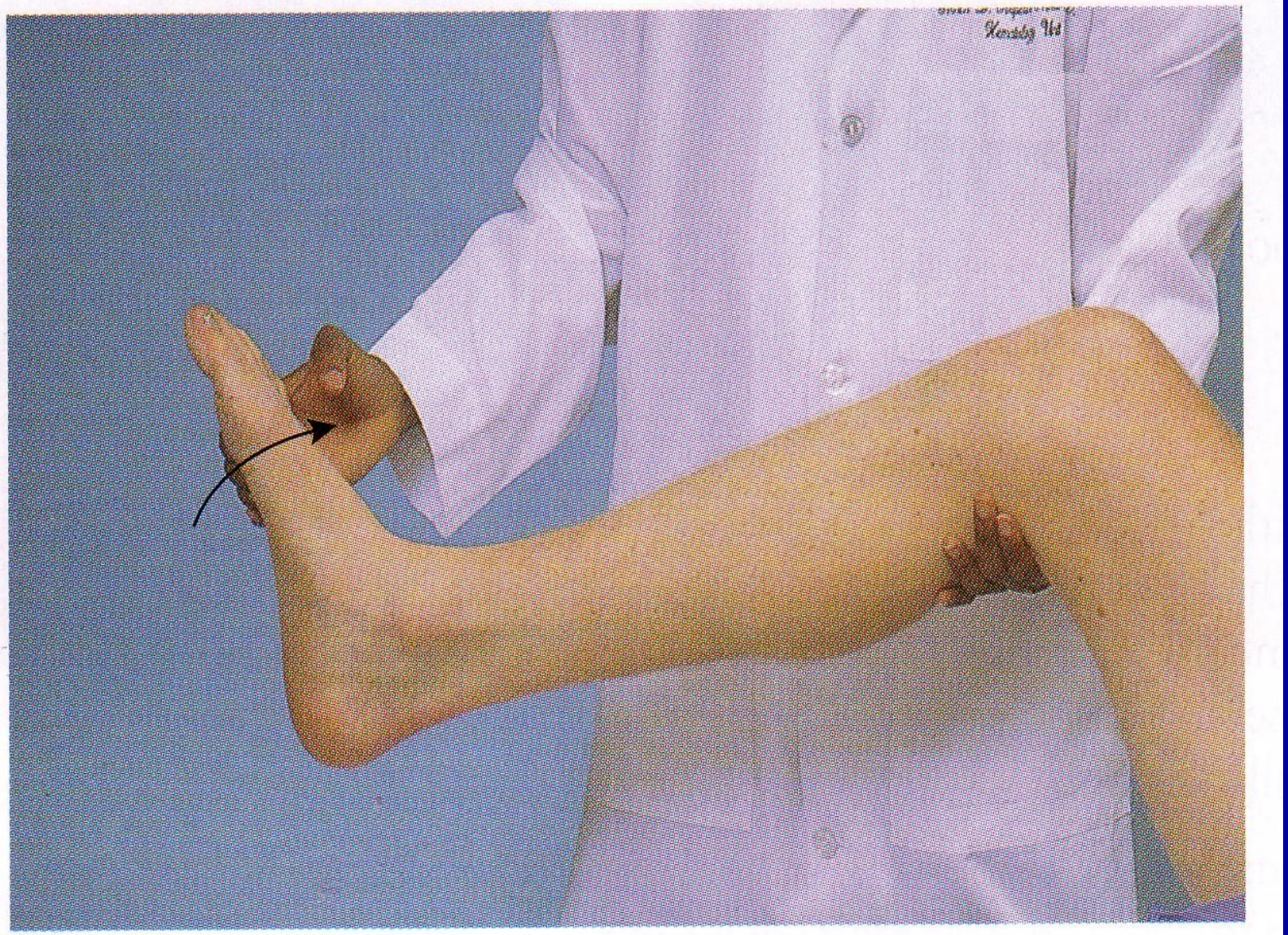

Ankle Clonus

Cerebellar function testing

- **Rebound phenomenon**
- **Finger-nose test**
- **Heel-shin test**
- **Rapid alternating movements**

Sensory examination

- **Light touch**
- **Superficial pain**
- **Deep pain**
- **Temperature**
- **Vibration**
- **Joint position sense**
- **Two-point discrimination**
- **Point localization**
- **Stereognosis and graphaesthesia**
- **Sensory inattention**

Vibration and JPS

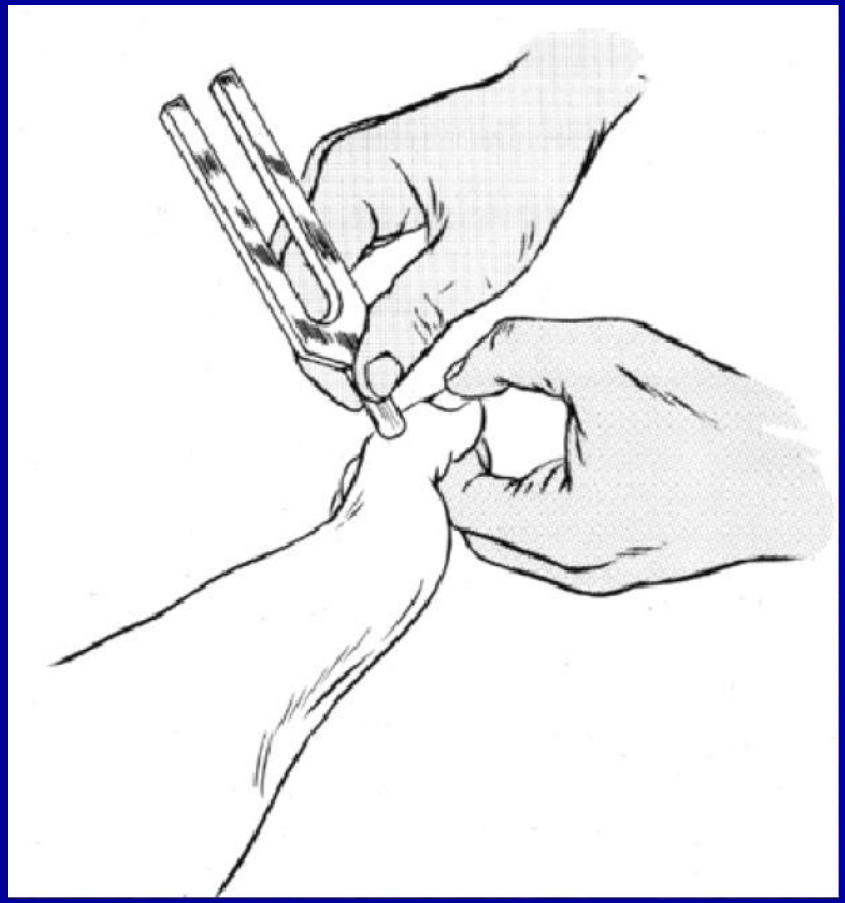

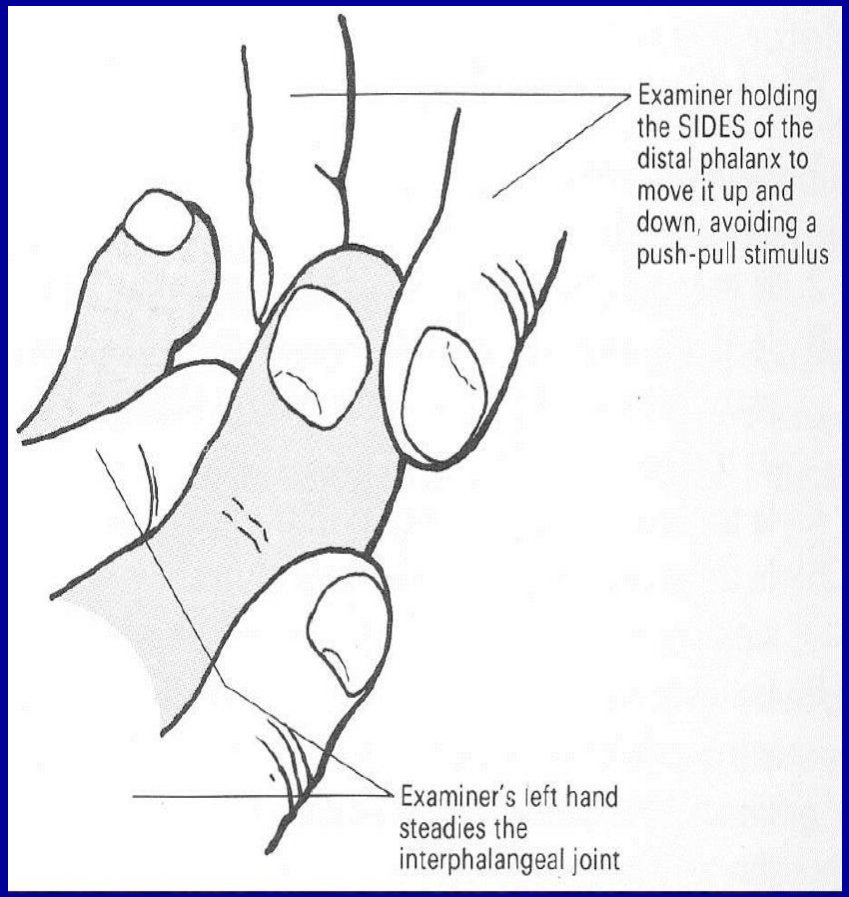

Stereognosis & Graphesthesia

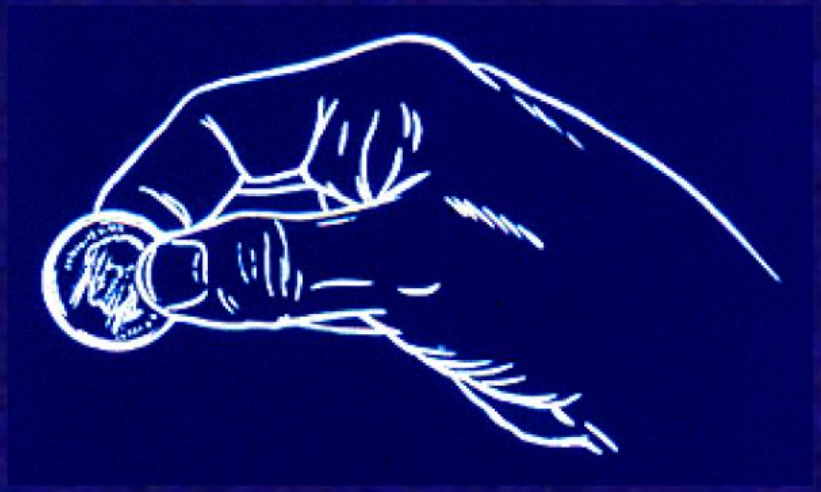

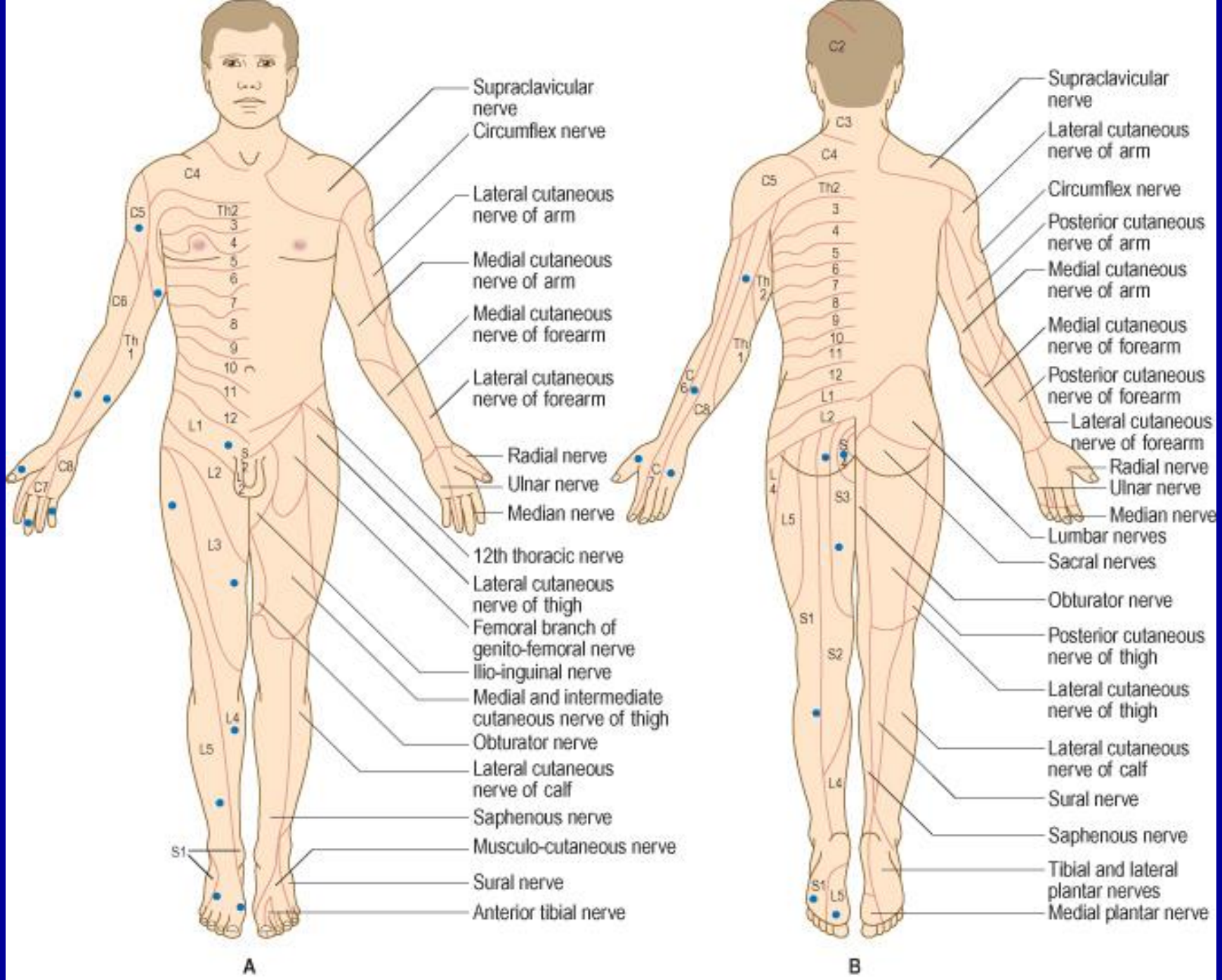

© Elsevier. Douglas et al.: MacLeod's Clinical Examination 11e - www.studentconsult.com

Stance and gait : Examination sequence

Stance : Romberg's test

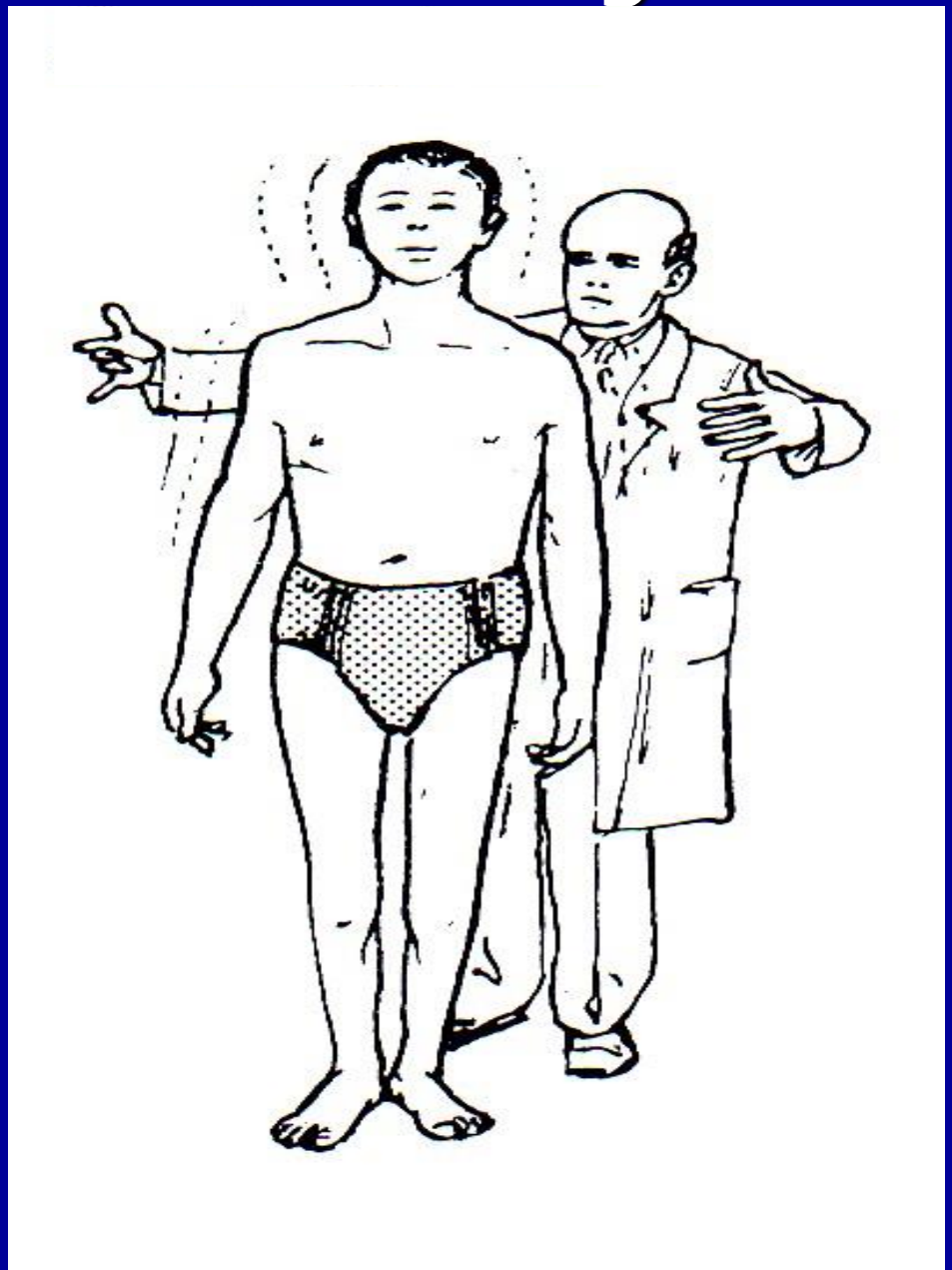

Gait testing

Tandem walking

Hopping

Gait types 1

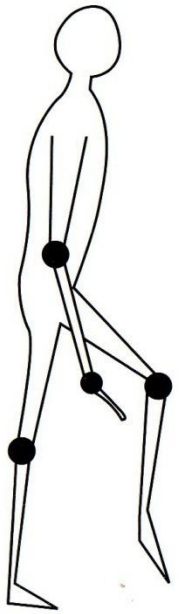

	Spastic Hemiparesis	Scissors Gait	Steppage Gait
Underlying Defect	Associated with lesion in corticospinal tract, as with stroke	Associated with bilateral spastic paresis of the legs	Associated with foot drop, usually secondary to lower motor neuron disease
Description	One arm is held immobile and close to the side, with elbow, wrist, and interphalangeal joints flexed. The leg is extended, with plantar flexion of the foot. On walking, the patient either drags the foot, often scraping the toe, or circles it stiffly outward and forward (*circumduction*)	The gait is stiff. Each leg is advanced slowly, and the thighs tend to cross forward on each other at each step. The steps are short. The patient appears to be walking through water.	These patients either drag their feet or lift them high, with knees flexed, and bring them down with a slap onto the floor, thus appearing to be walking up stairs. They are unable to walk on their heels. The steppage gait may involve one or both sides.

Gait types 2

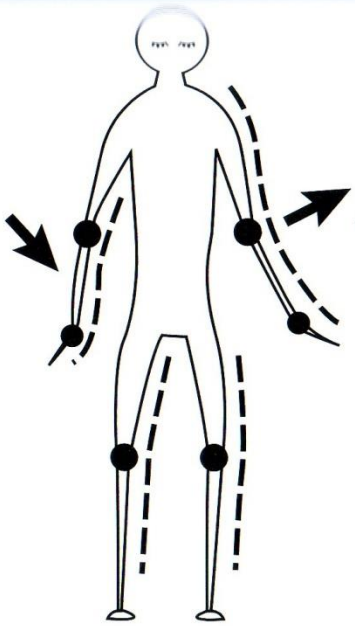

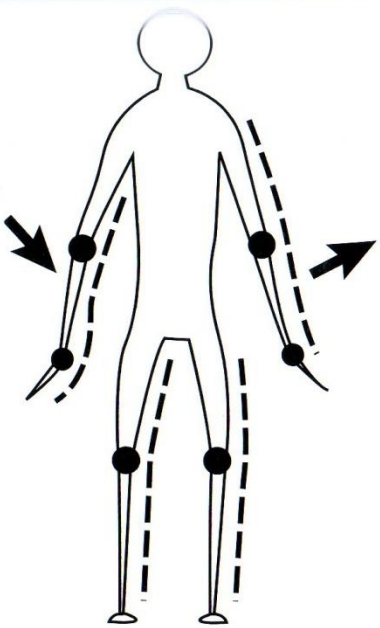

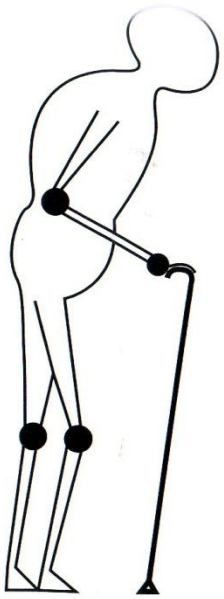

Underlying Defect	Sensory Ataxia	Cerebellar Ataxia	Parkinsonian Gait	Gait of Older Age
	Associated with loss of position sense in the legs, as from polyneuropathy or posterior column damage	Associated with disease of the cerebellum or associated tracts	Associated with the basal ganglia defects of Parkinson's disease	The aging process
Description	The gait is unsteady and wide based (with feet wide apart). These patients throw their feet forward and outward and bring them down, first on the heels and then on the toes, with a double tapping sound. They watch the ground for guidance while walking. With eyes closed, they cannot stand steadily with feet together (a positive Romberg sign) and the staggering gait worsens.	The gait is staggering, unsteady, and wide based, with exaggerated difficulty on the turns. These patients cannot stand steadily with feet together, whether their eyes are open or closed.	The posture is stooped, with head and neck forward and hips and knees slightly flexed. Arms are flexed at elbows and wrists. The patient is slow in getting started. Steps are short and often shuffling. Arm swings are decreased and the patient turns around stiffly—"all in one piece."	Speed, balance, and agility decrease with aging. Steps become short, uncertain, and even shuffling. The legs may be flexed at hips and knees. A cane may bolster lost confidence.

Summarizing your neurological examination

Summary of Neurological Examination

- MS: Conscious, alert oriented with normal speech, memory, attention and thought process
- CN: I-XII intact except for right upper motor facial weakness
- Motor and reflexes : see figure
- Cerebellar: normal F-N , H-Shin on the left and mildly impaired on the right but consistent with degree of weakness
- Sensation: normal light touch, pp, jp, vib, and cortical
- Gait and station: right spastic hemiparetic gait.

Motor Power and Reflexes Simple and Informative Diagram



3/5

5/5

A Patient with spastic right sided hemiparesis

Motor Power and Reflexes Simple and Informative Diagram



5/5

3/5

A Patient with spastic left sided hemiparesis

Common Tests Used to Diagnose Neurological Disorders

- Brain and spinal cord CT and MRI
- CSF studies
- Angiography of cerebral circulation
- NCS and EMG
- EEG and Evoked potentials
- Muscle and nerve biopsies
- Other genetic and immunologic tests

ICH Rapid extension

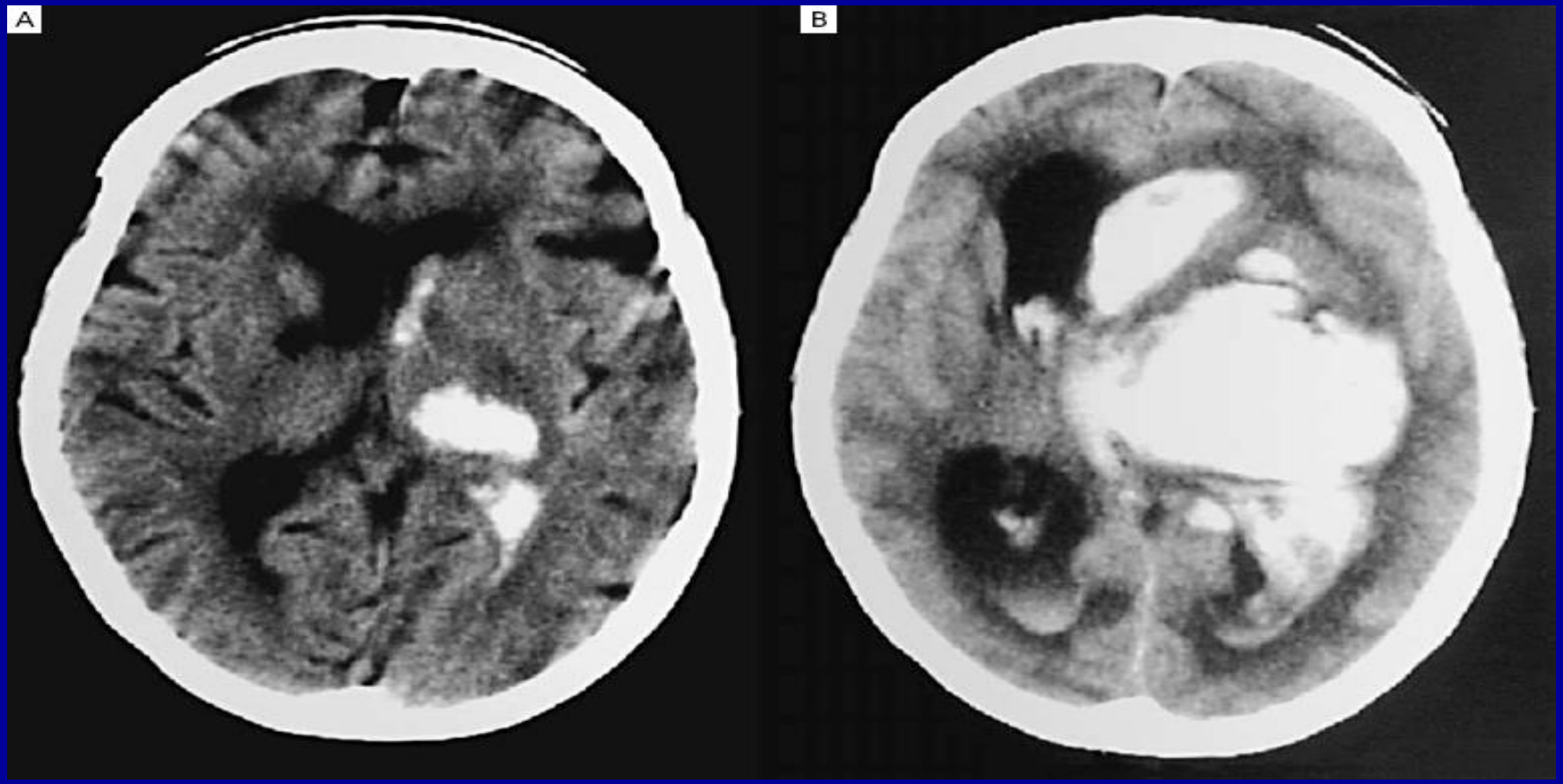

1HR

6HRS

Left MCA Infarction: 80 year old , AF case 2021093652

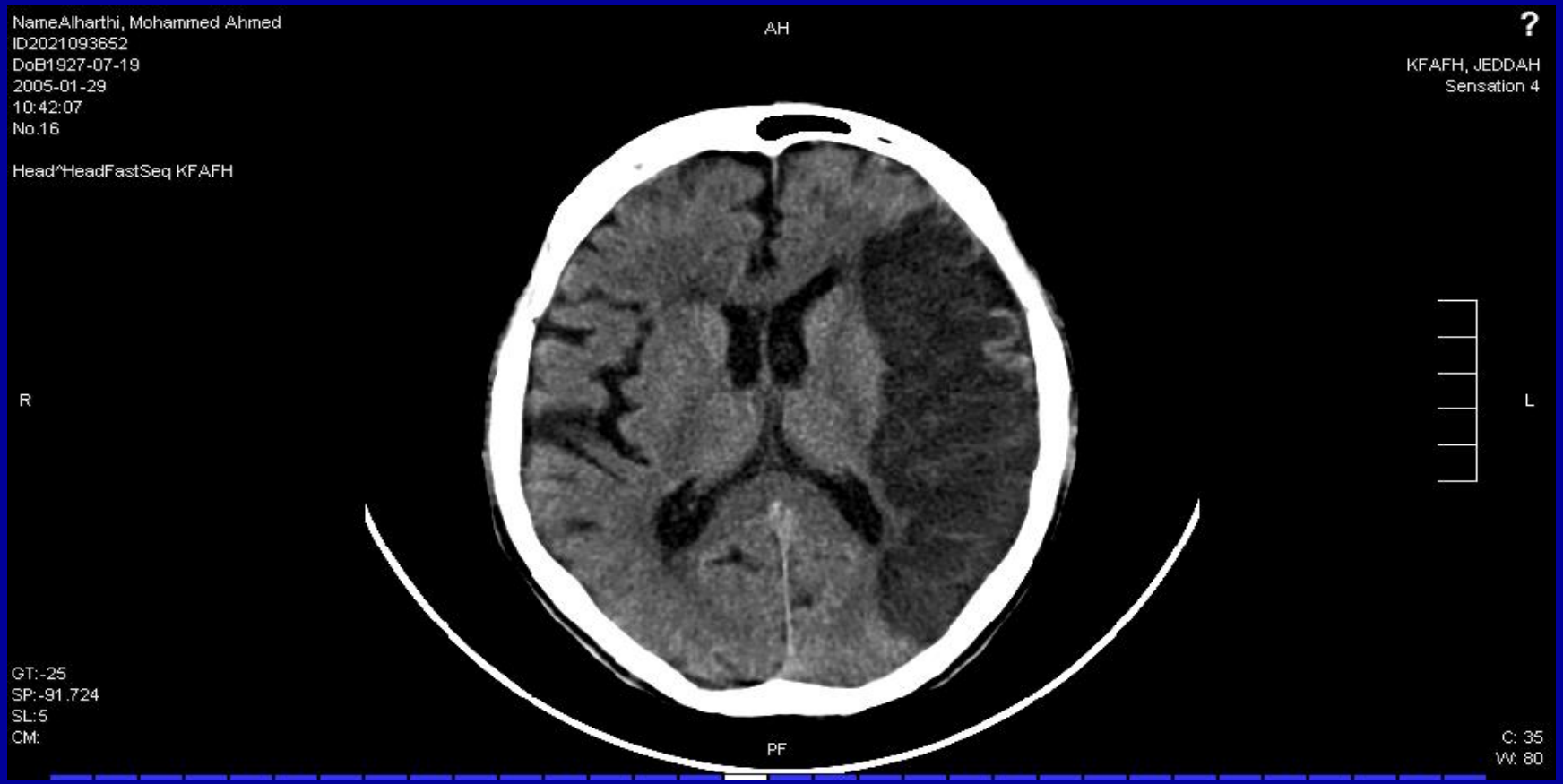

MRI Flair

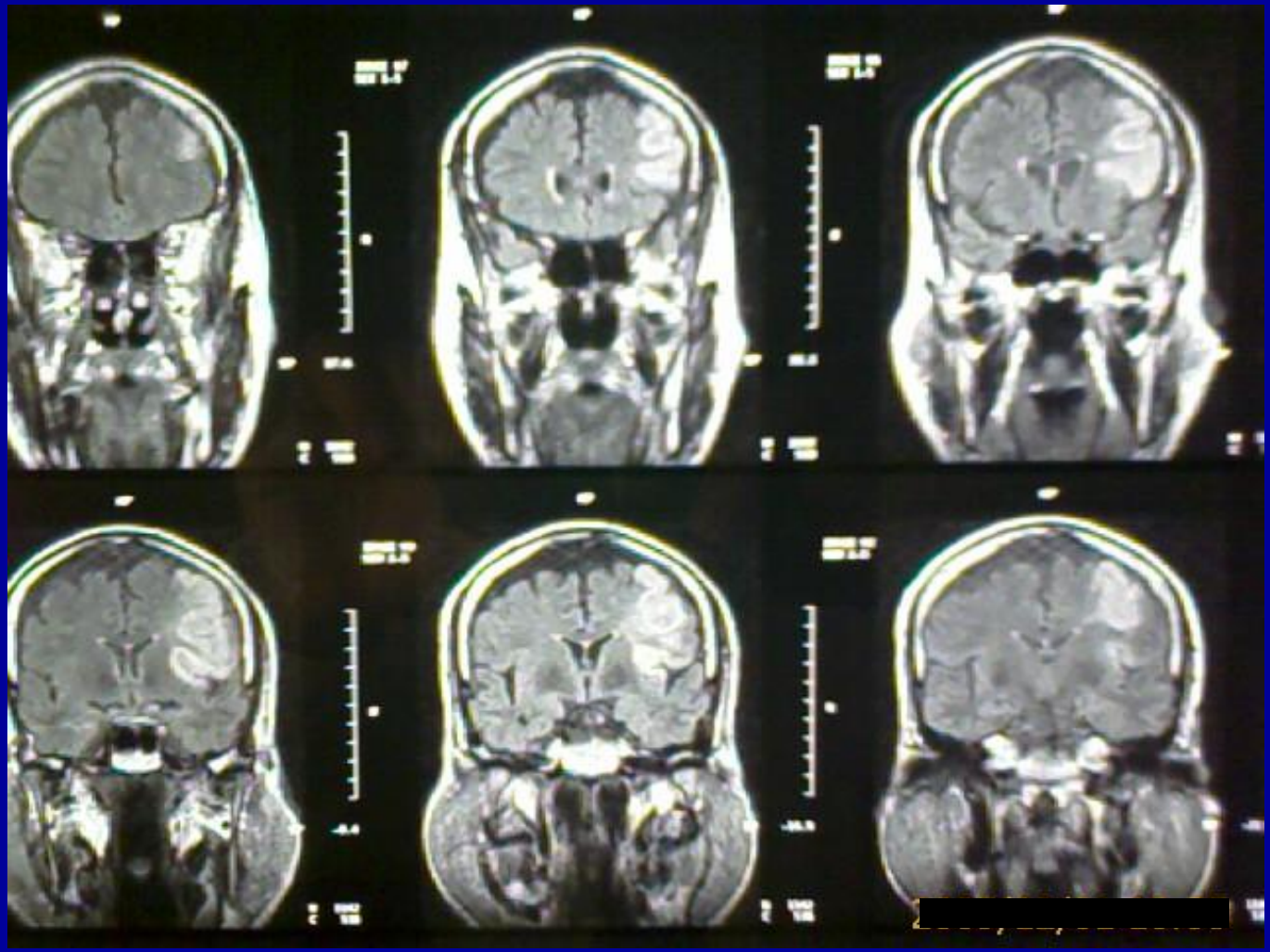

Right occipital infarction: DW MRI

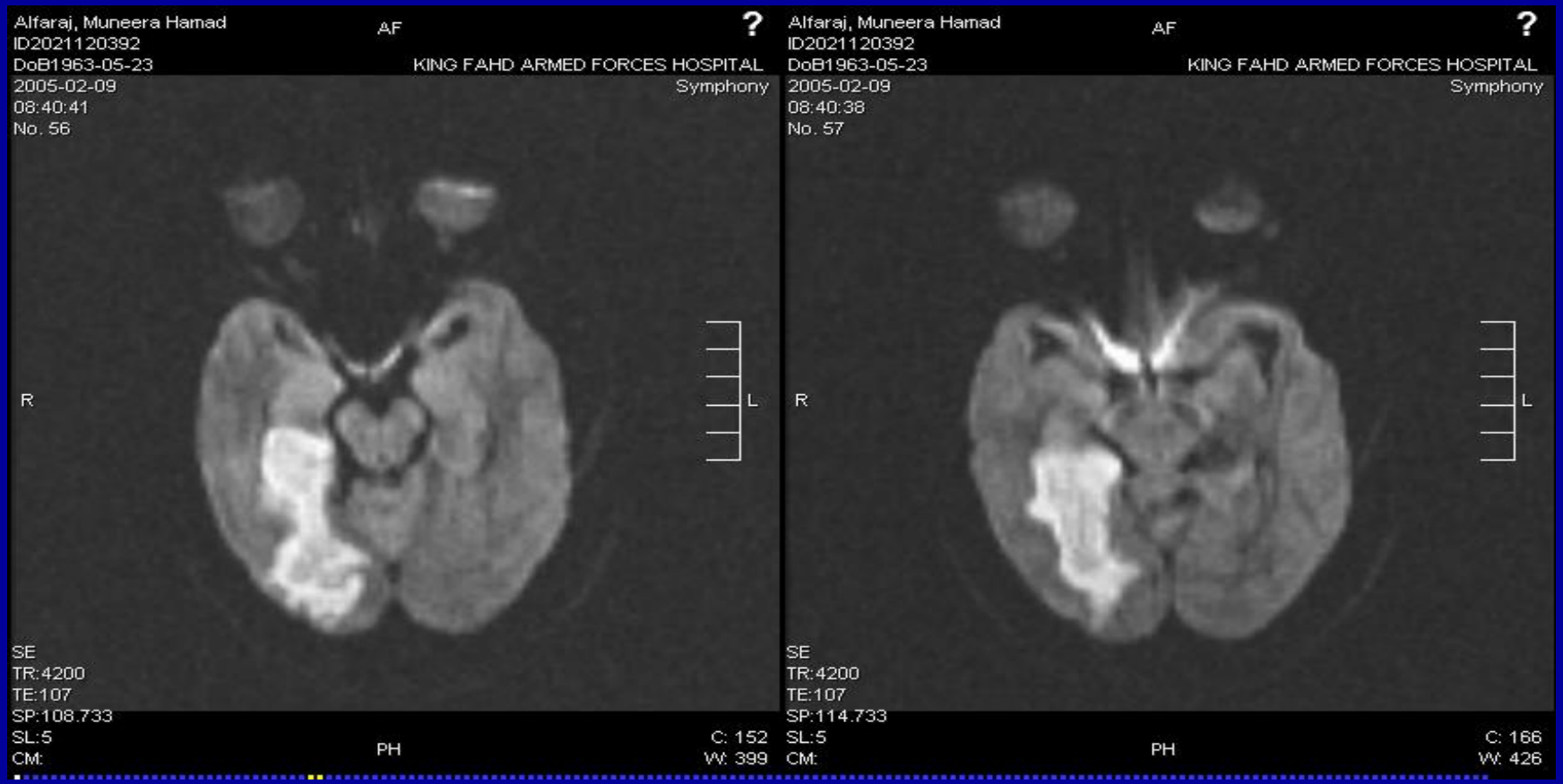

Rt frontal infracion MRA
Absent left carotid system , stenosed right ICA

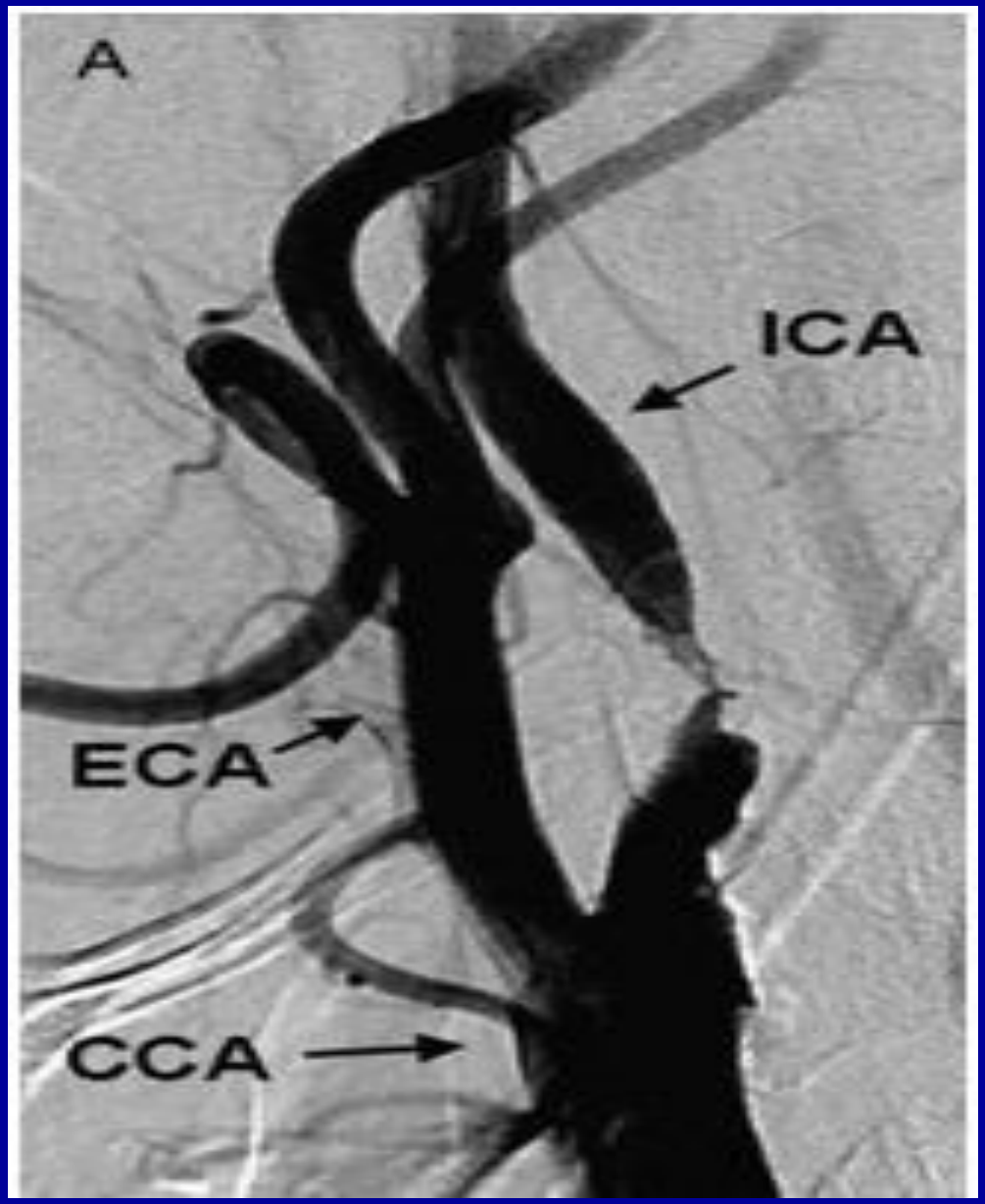

Carotid angiogram

Spine MRI: extensive myelitis

Electroencephalogram

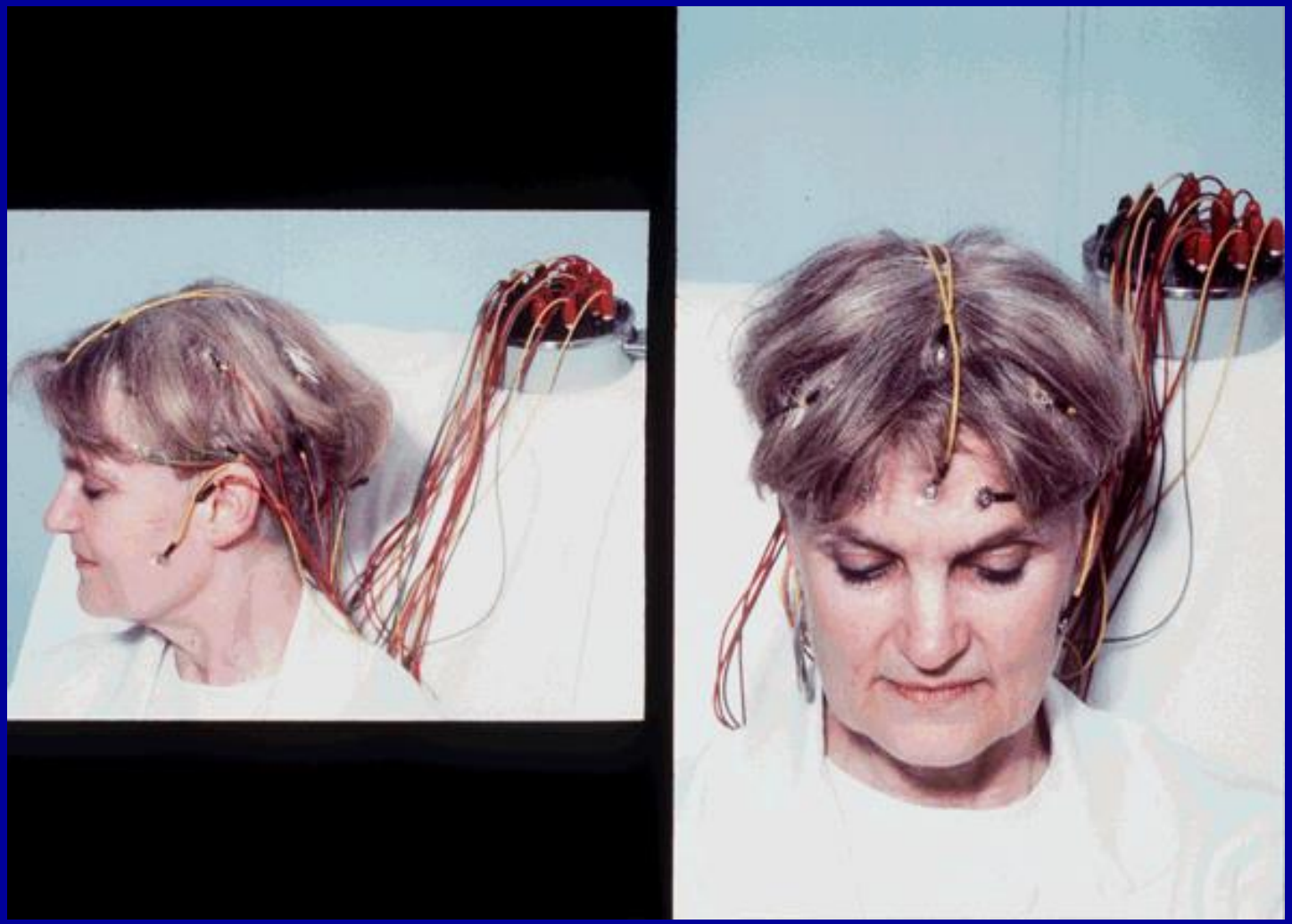

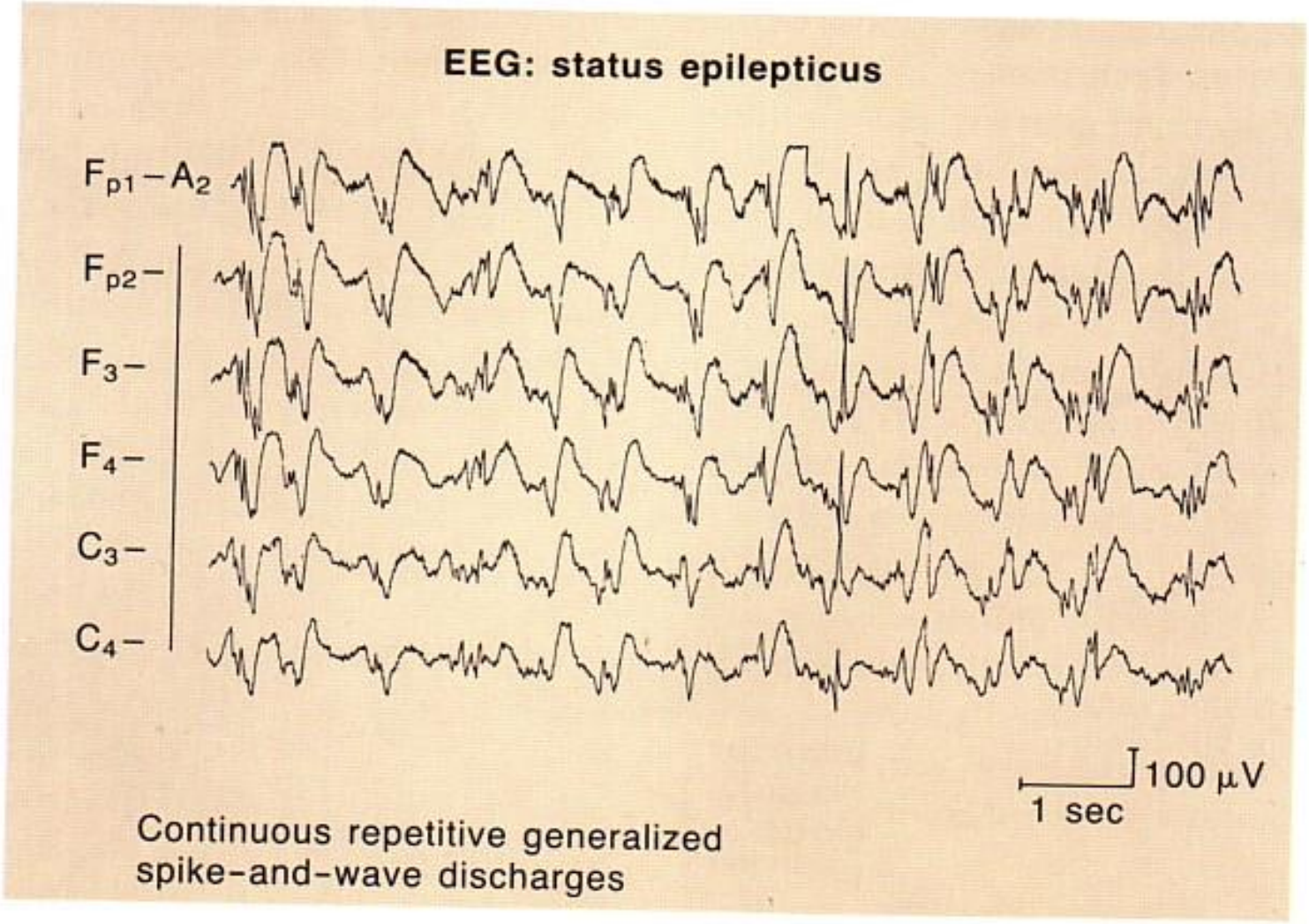
EEG: status epilepticus
$F_{p1}-A_2$
$F_{p2}-$
F_3-
F_4-
C_3-
C_4-
100 μV
1 sec
Continuous repetitive generalized
spike-and-wave discharges

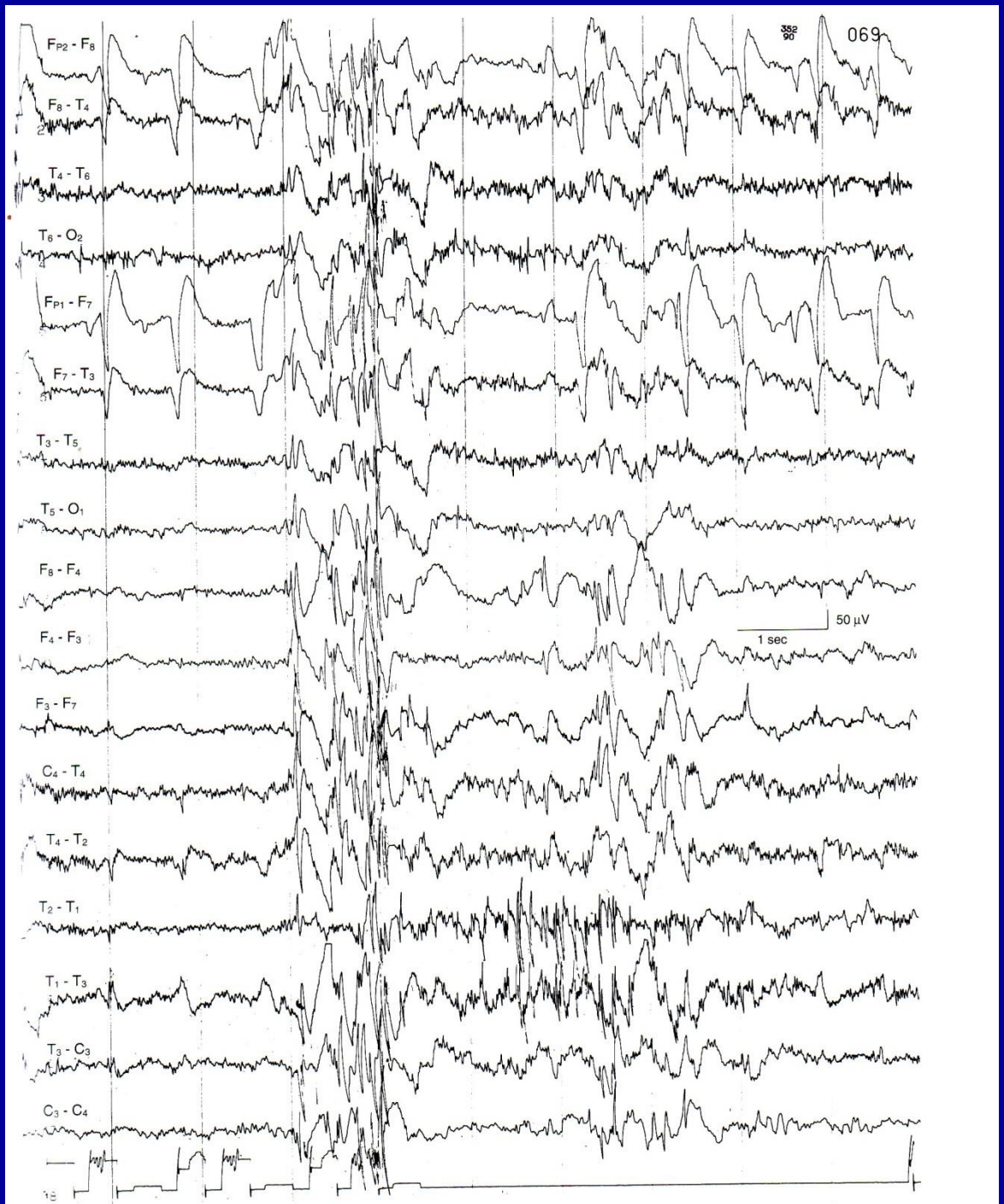

Diffuse 2-5 Hz multi-spike-wave complexes preceding a multi-spike discharge during a myoclonic jerk



NERVE CONDUCTION STUDY

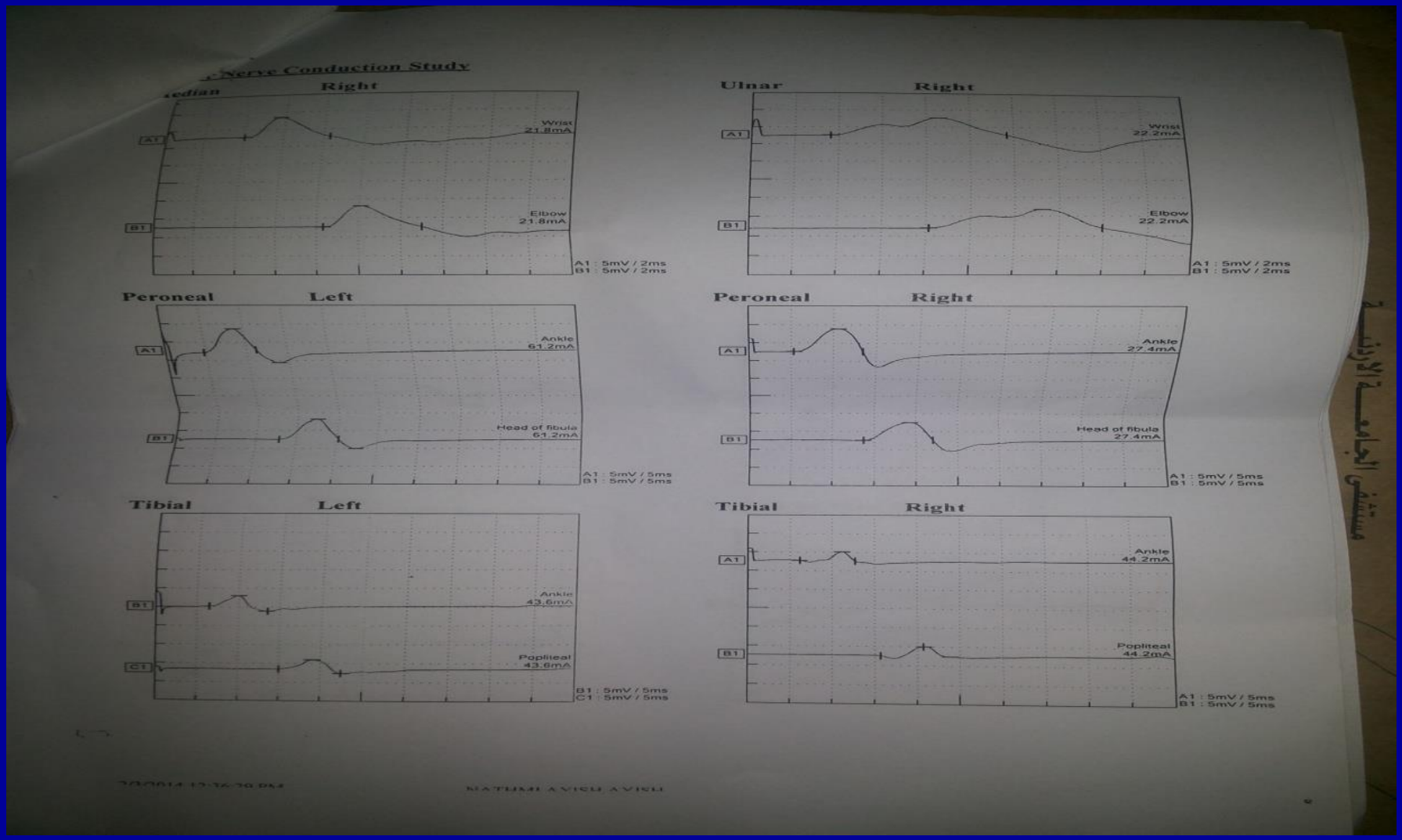

...y Nerve Conduction Study

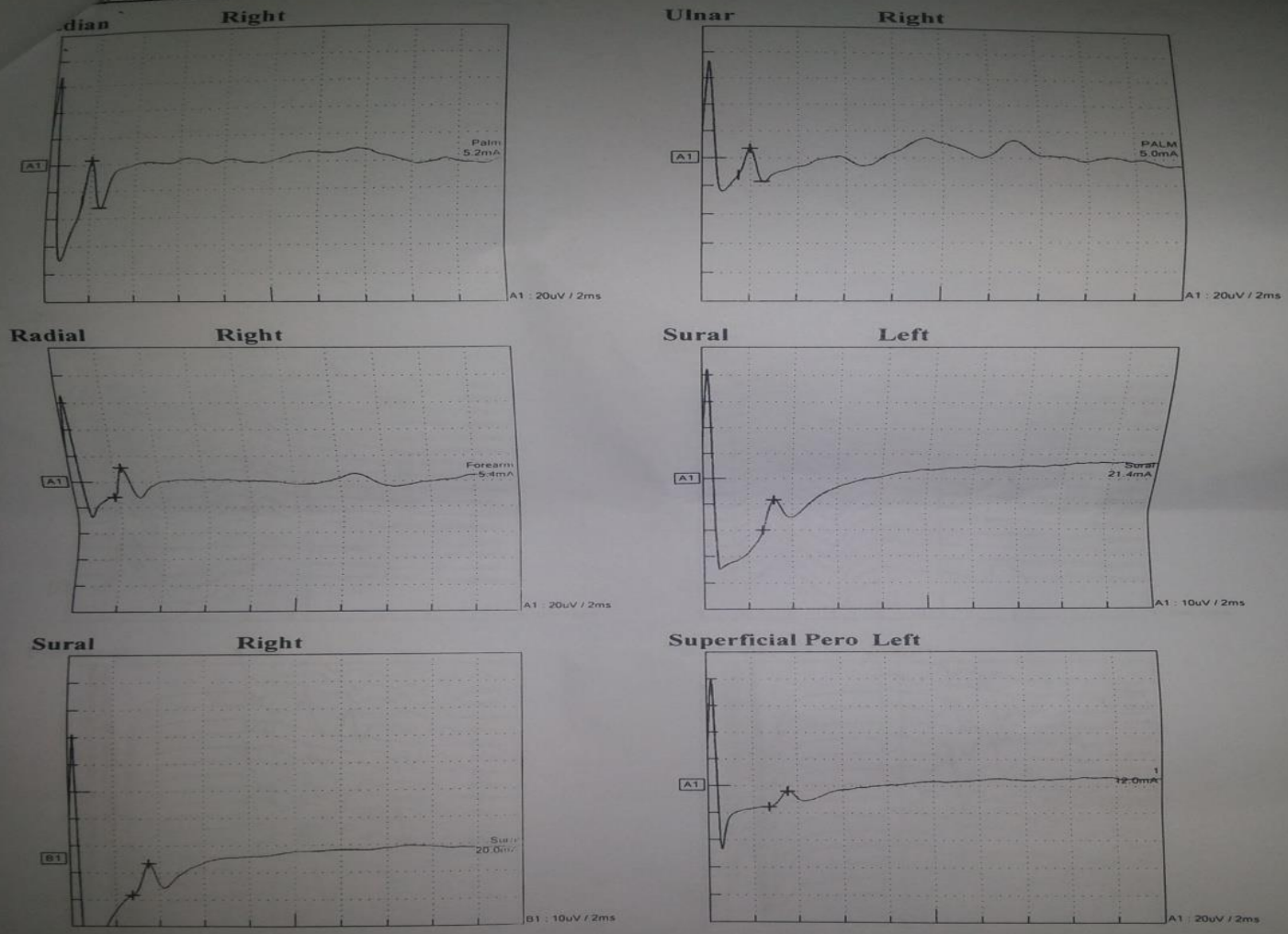

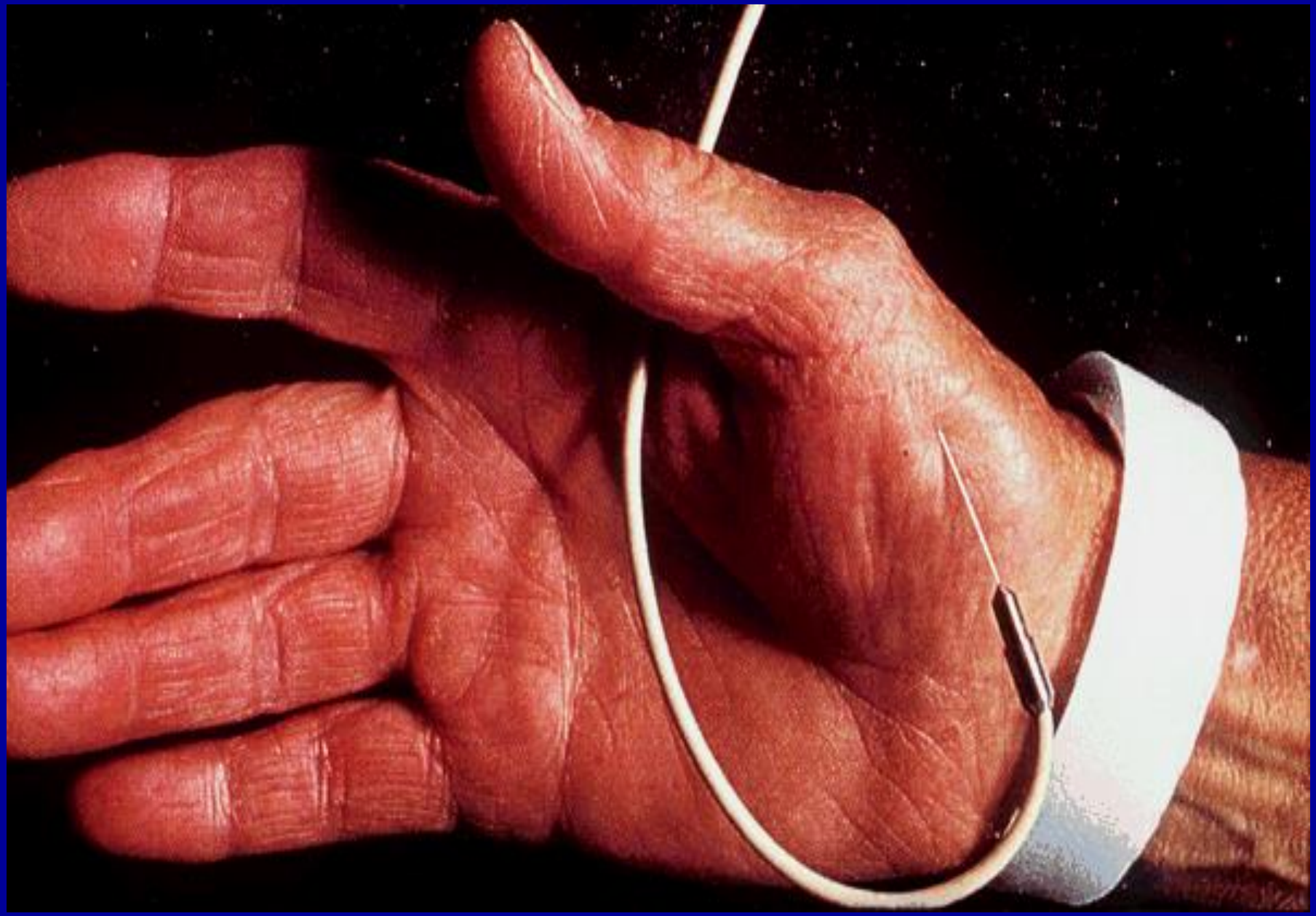

EMG (ELECTROMYOGRAPHY)

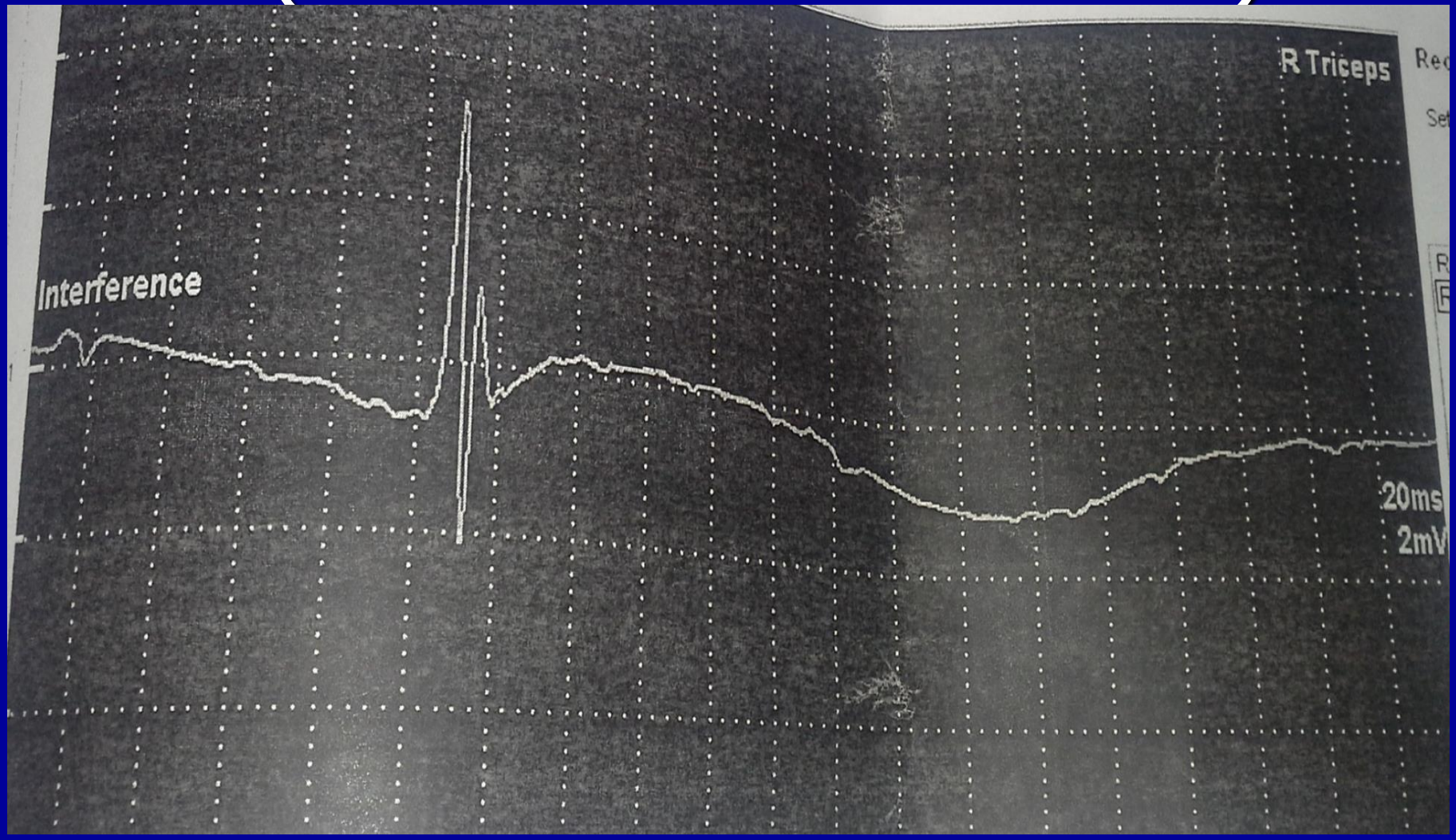

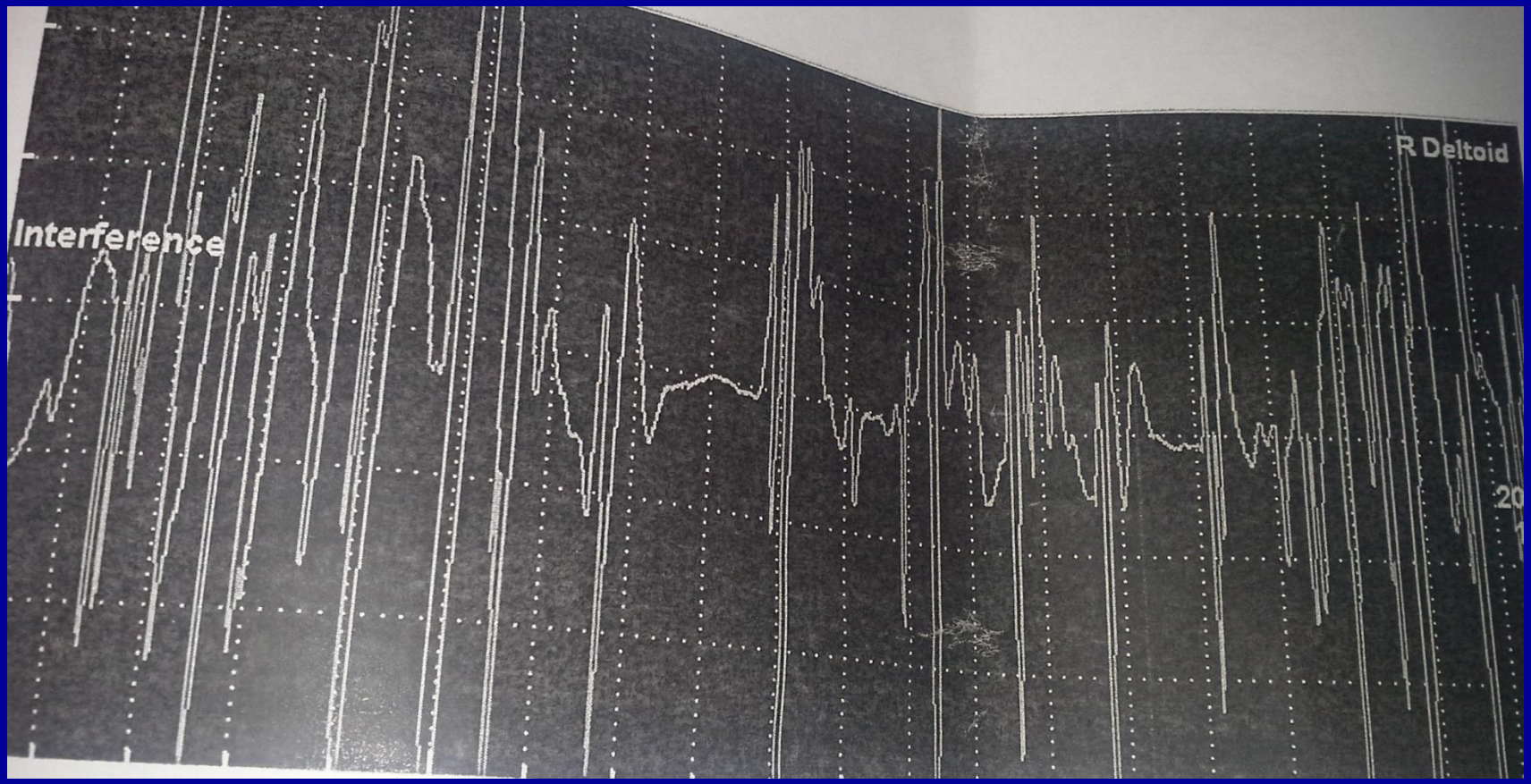
Interference
R Deltoid

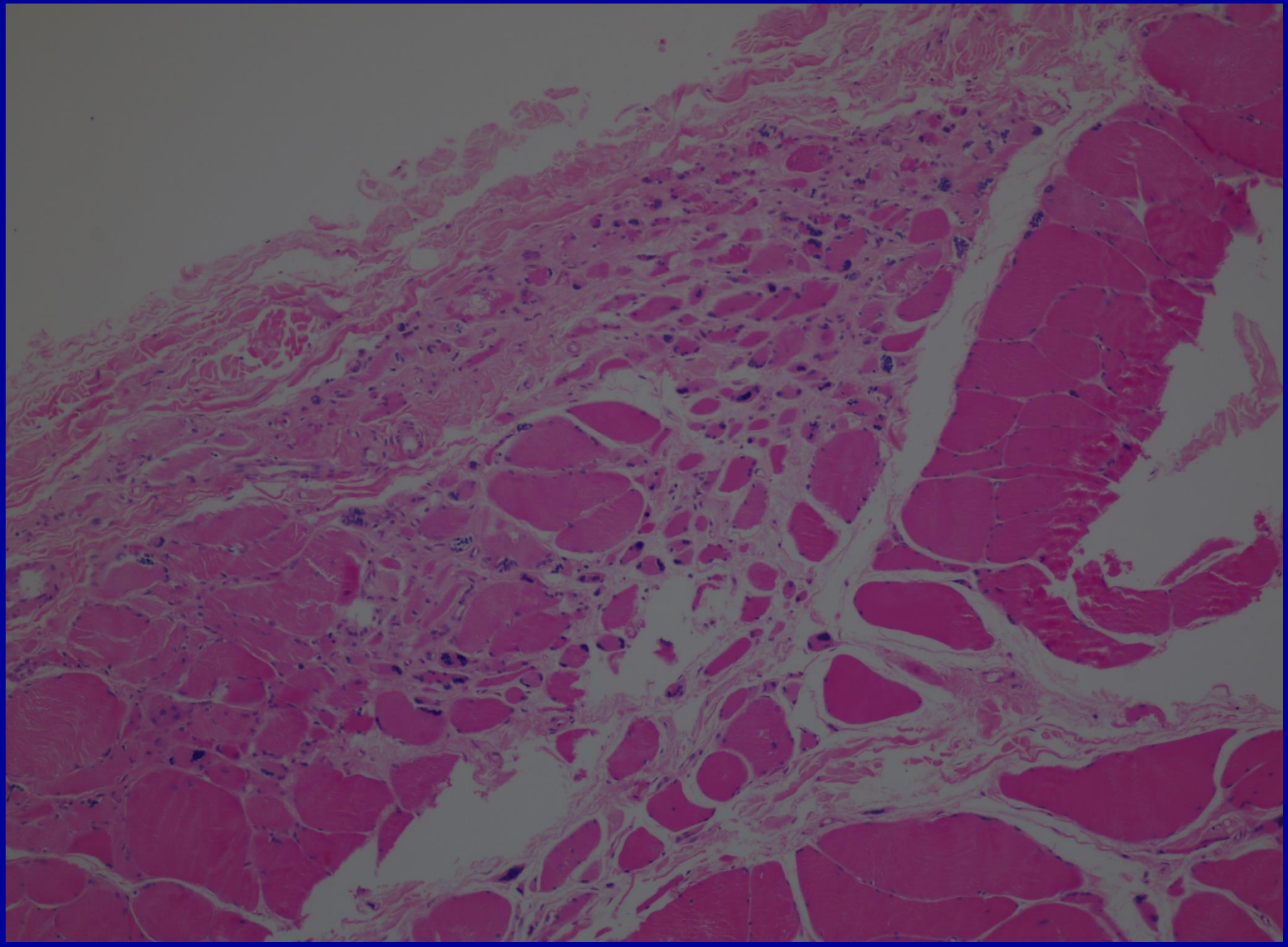

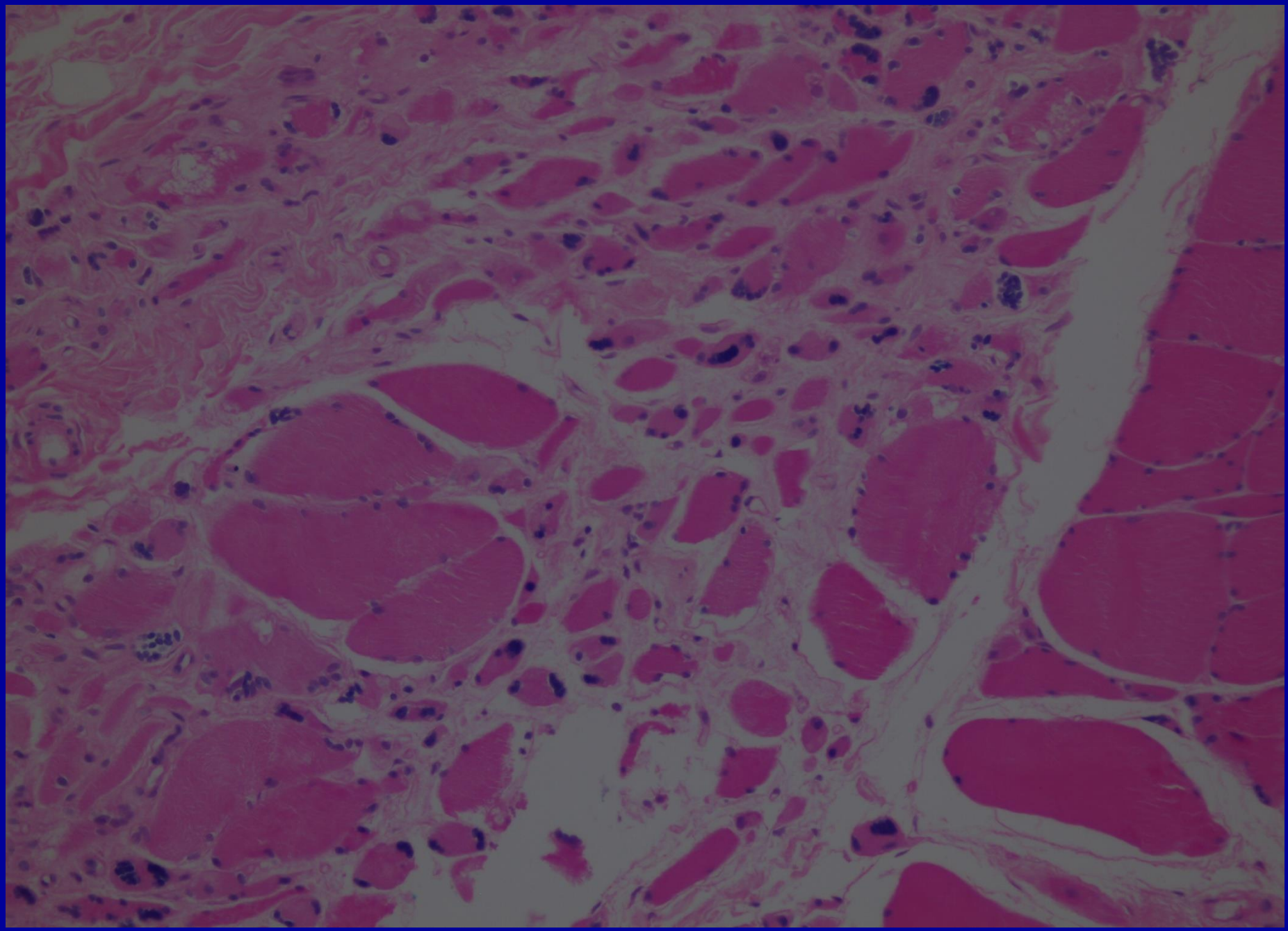

VEP Pattern VEP 1ch

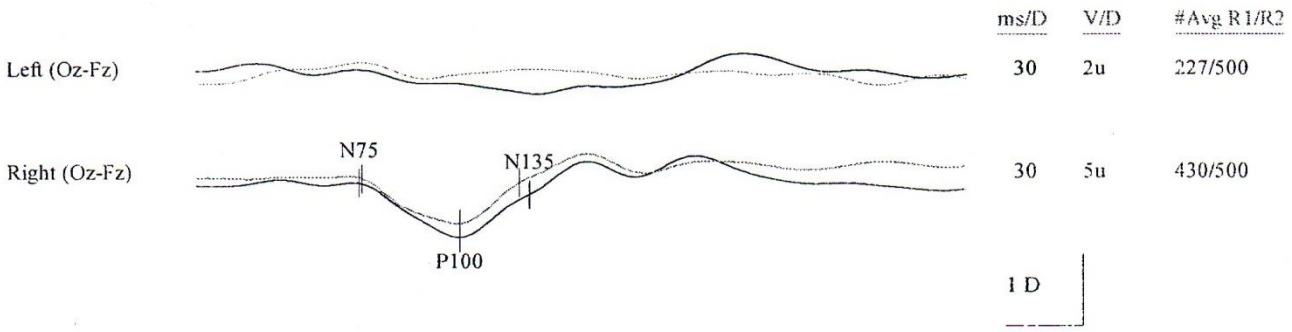

Display

Left : Run1 Run2 Superimposed
Right : Run1 Run2 Superimposed
Left Right Mixed
Left ——
Right ——

Stimulation

Left Run1 : Left ☐ 2Hz Reversal
Size : 12x16 Checkers Fix: +
Left Run2 : Left ☐ 2Hz Reversal
Size : 12x16 Checkers Fix: +
Right Run1 : Right ☐ 2Hz Reversal
Size : 12x16 Checkers Fix: +
Right Run2 : Right ☐ 2Hz Reversal
Size : 12x16 Checkers Fix: +

Channel	Montage/Marker	Latency [ms] Left	Latency [ms] Right	Latency [ms] Diff	Latency [ms] Diff%	Amplitude [uV] Left	Amplitude [uV] Right
Run 1							
1	Oz-Fz/ Oz-Fz						
	N75		63.25				-0.44
	P100		102.00				-4.27
	N135		129.25				-1.25
Run 2							
1	Oz-Fz/ Oz-Fz						
	N75		64.50				-0.11
	P100		102.00				-3.30
	N135		125.50				-0.38

-6SD 0 +6SD -3x 0 +3x -6SD 0 +6SD

Normal Area • Left + Right ⊗ Lat * Amp

VEP Study



CSF : Inspection

Conclusions 1

- The CNS is well organized system and its evaluation mandates an organized approach.
- The aim of neurological history and examination is to localize a lesion in the nervous system .
- The neurological examination starts with a general look and examination.

Conclusions 2

- The neurological examination involves :

  Mental status

  The 12 pairs of cranial nerves

  Motor system

  Sensory system

  Cerebellum and its connections

  Stance and gait

Conclusions 3

- Though neurological examination seems lengthy and difficult ,but an organized approach and repetition will make one easily master this important clinical tool.
- Appropriate choice of the various investigation is greatly helped by an appropriately conducted neurological history and examination.

THANK YOU