

Esophageal Cancer

Rami Addasi, MD, MRCS

General Surgery and Surgical Oncology Consultant

Assistant Professor Faculty of Medicine

The University of Jordan

Region:
World

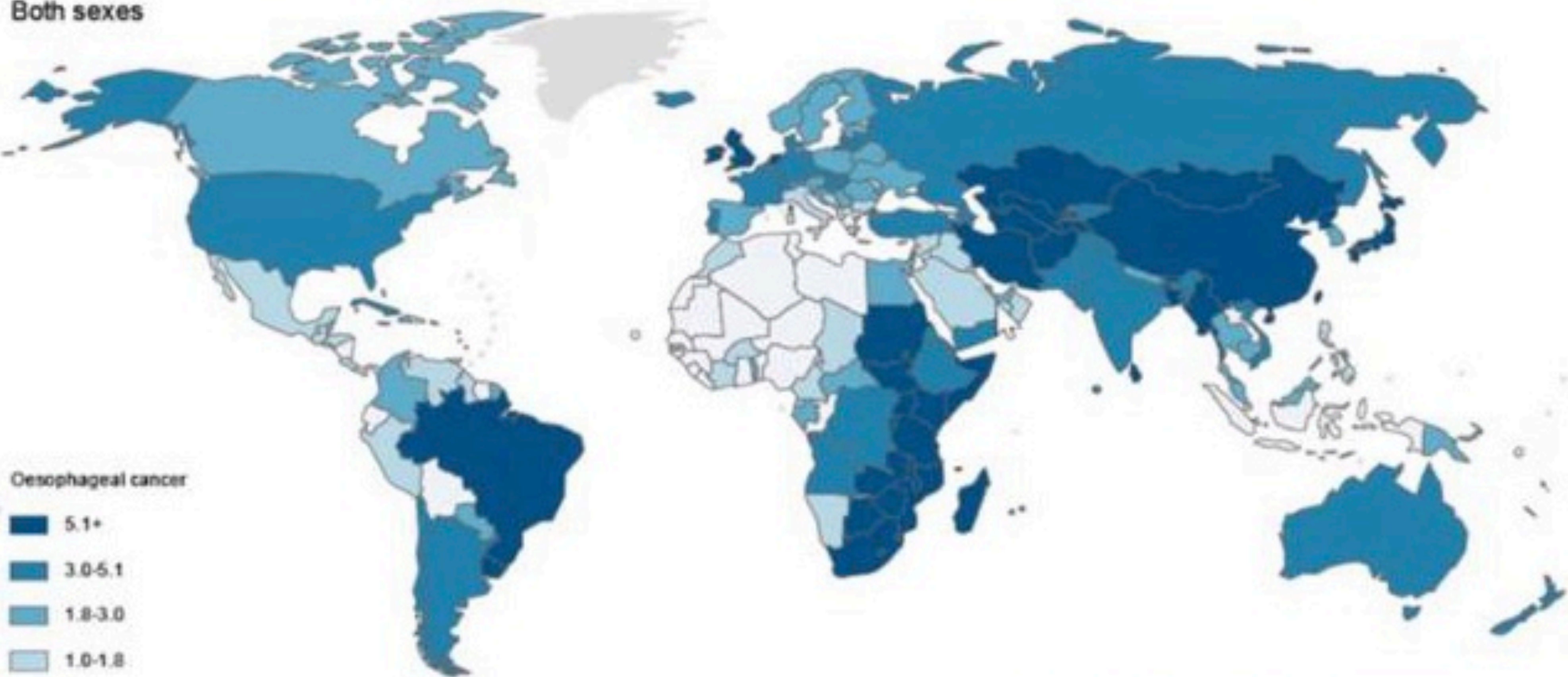
Type:
Incidence

Indicator:
ASR

Site:
Oesophagus

Sex:
Both sexes

Incidence ASR
Both sexes



Oesophageal cancer

5.1+

3.0-5.1

1.8-3.0

1.0-1.8

<1.0

No Data

International Agency for Research on Cancer



World Health
Organization

Epidemiology

- Major risk factors in these areas are not well understood, but are thought to include
 - poor nutritional status,
 - low intake of fruits and vegetables,
 - drinking beverages at high temperatures.
- Low-risk areas
 - smoking
 - excessive alcohol consumption in 90% of SCC
- Most common types are squamous cell carcinoma (SCC) and adenocarcinoma (ACA).
- The male to female ratio is 3:2 for SCC and 10:1 for ACA.

Epidemiology

Table (3) Number and percentage of cancer by primary site & gender- Jordan, 2015

Primary Site	Male		Female		Total	
	N	%	N	%	N	%
All Sites	2668	100.0	2888	100.0	5556	100.0
Lip	7	0.3	3	0.1	10	0.2
Tongue	12	0.4	9	0.3	21	0.4
Mouth	11	0.4	6	0.2	17	0.3
Salivary glands	6	0.2	10	0.3	16	0.3
Pharynx	32	1.2	9	0.3	41	0.7
Esophagus	20	0.7	5	0.2	25	0.4
Stomach	101	3.8	56	1.9	157	2.8
Small intestine	13	0.5	15	0.5	28	0.5
Colon	250	9.4	196	6.8	446	8.0
Rectum	138	5.2	84	2.9	222	4.0
Liver, Biliary Passages	74	2.8	43	1.5	117	2.1
Pancreas	57	2.1	42	1.5	99	1.8
Other & Unspecified Digestive	4	0.1	11	0.4	15	0.3
Larynx	76	2.8	16	0.6	92	1.7

ETIOLOGIC FACTORS

- **Hereditary factors**

 - Familial aggregation

 - Uncertain

- **Squamous cell carcinoma**

 - Smoking and alcohol**

 - Dietary factors**

 - N-nitroso compounds

 - Certain types of pickled vegetables.

 - Toxin-producing fungi (eg, aflatoxin)

ETIOLOGIC FACTORS

- **Underlying esophageal disease**
 - achalasia
 - caustic strictures
- **Prior gastrectomy**
- **Atrophic gastritis**
- **Tylosis**
- **Upper aerodigestive tract cancer**
- **Poor oral hygiene**

ETIOLOGIC FACTORS

- High temperature beverages and foods
- Red meat intake
- Zinc deficiency
- low intake of dietary folate

ETIOLOGIC FACTORS

- **Adenocarcinoma**

Gastroesophageal reflux disease

Barrett's metaplasia

Smoking

Alcohol

Obesity

Helicobacter pylori infection

Pathobiology

- **Squamous cell carcinoma**
- midportion of the esophagus.
- SCC arises from small polypoid , denuded epithelium, or plaques .
- These early lesions are usually subtle, and can easily be missed on endoscopy.
- More advanced lesions are characterized by infiltrating and ulcerated masses, which may be circumferential

- SCC invades the submucosa at an early stage, and extends along the wall of the esophagus usually in a cephalad direction

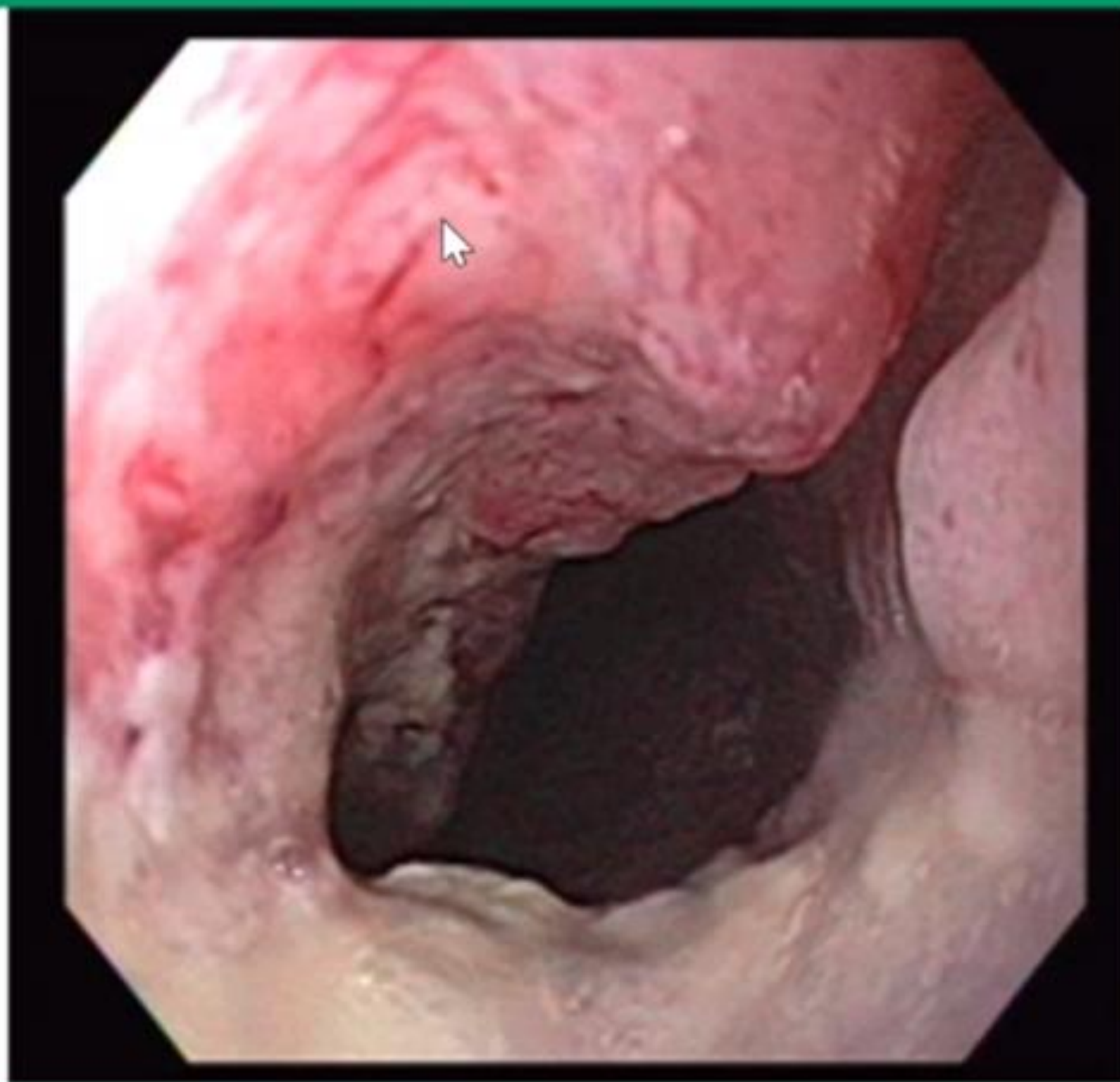
- Local lymph node invasion occurs early and quickly because the lymphatics in the esophagus are located in the lamina propria, in contrast to the rest of the gastrointestinal tract, in which they are located beneath the muscularis mucosa. The tumor spreads to regional lymph nodes along the esophagus, the celiac area, and adjacent to the aorta.

- Invasion of local structures may result in fistula formation (such as to the trachea).

- Erosion into the aorta can be associated with massive upper gastrointestinal hemorrhage.

- Distant metastases to the liver, bone, and lung are seen in nearly 30 percent of patients

Endoscopic appearance of a squamous cell carcinoma of the distal esophagus



Pathobiology

- **Adenocarcinoma**
- The majority of cases are located near the gastroesophageal junction and are associated with endoscopic evidence of Barrett's esophagus.
- Adenocarcinoma arising in Barrett's esophagus may present as an ulcer, a nodule, an altered mucosal pattern, or no visible endoscopic abnormality
- Early adenocarcinoma not associated with Barrett's esophagus arises from an ulcer, plaque, or nodule near the gastroesophageal junction
- Similar to SCC, lymph node metastases occur early to adjacent or regional lymph nodes.
- Involvement of celiac and perihepatic nodes is more common with adenocarcinoma because of the location of the tumor at the gastroesophageal junction

CLINICAL MANIFESTATIONS

- Early intramucosal cancers are not specifically symptomatic
- Early symptoms of esophageal cancer are subtle and nonspecific.
Transient "sticking" of apples, meat, hard-boiled eggs, or bread
Retrosternal discomfort or burning sensation.
- Progressive solid food dysphagia
- weight loss.
dysphagia
changes in diet
tumor-related anorexia.
- Regurgitation of saliva or food uncontaminated by gastric secretions
- Aspiration pneumonia
- Hoarseness
- Chronic gastrointestinal blood loss.
- Tracheobronchial fistulas Life expectancy is less than four weeks following the development of this complication.

DIAGNOSTIC TESTING

- **Barium studies**
- **Endoscopic biopsy .**
- Early esophageal cancers appear endoscopically as superficial plaques, nodules, or ulcerations
- Advanced lesions appear as strictures , ulcerated masses, circumferential masses , or large ulcerations.
- **Biopsy**
 - number of biopsies
- **Brush cytology**
- Seventeen percent of lesions thought to be benign endoscopically were subsequently proven to be malignant

Imaging for diagnosis and staging

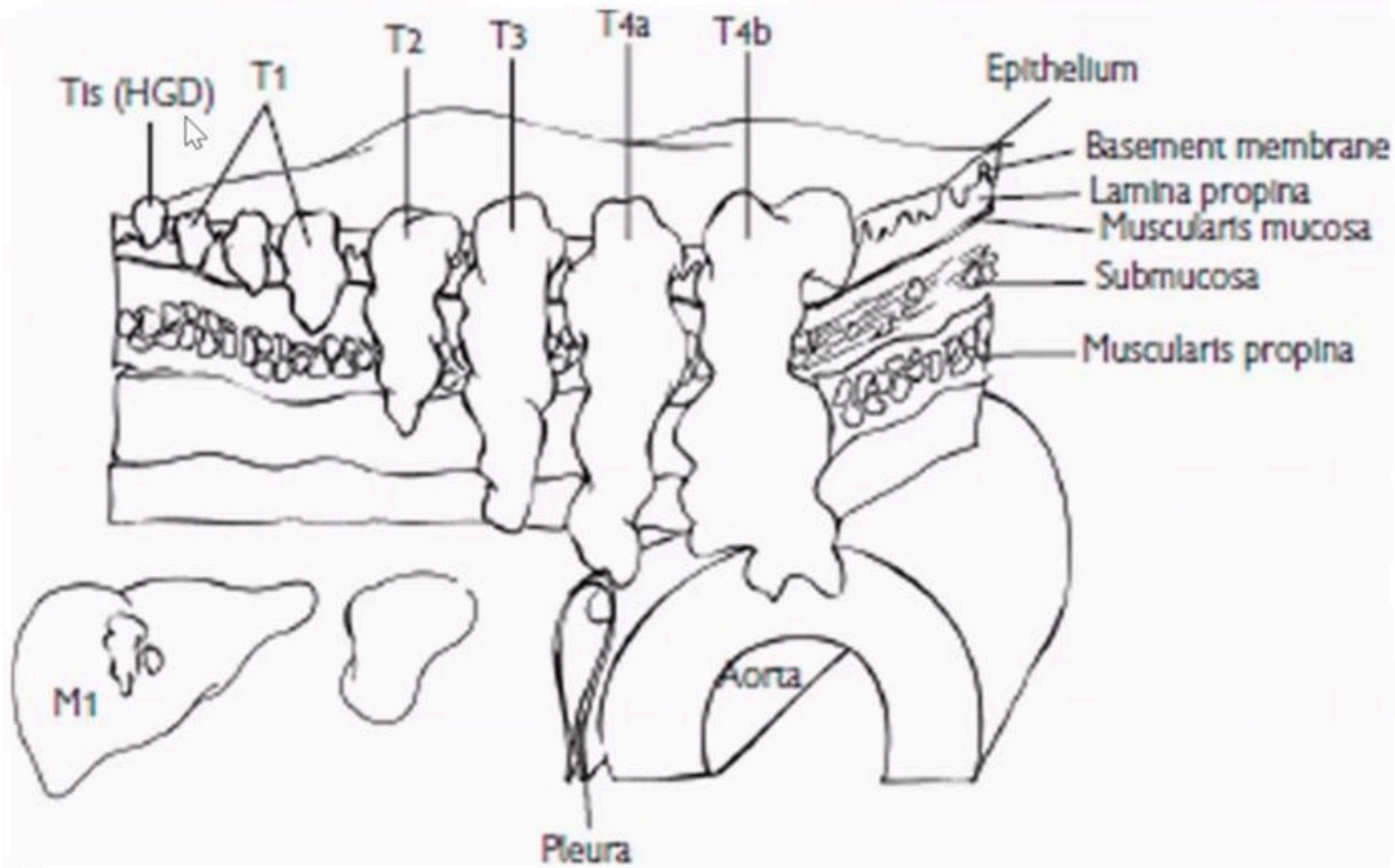
Accurate staging of esophageal cancer includes:

- (1) endoscopy
 - (2) chest and abdominal CT
 - (3) PET
 - (4) EUS
- EUS and CT together offer a 79% accuracy for T staging and 82% accuracy for N staging.
-

Endoscopic ultrasound

- • This is the gold standard for defining T stage: it allows detailed assessment of esophageal wall and surrounding structures.
- • Also allows fine needle aspiration (FNA) of suspicious lymph nodes.
- • EUS identifies five sonographic layers
 - • Layers 1–2: mucosa.
 - • Layer 3: submucosa.
 - • Layer 4: muscularis propria.
 - • Layer 5: adventitia.
- • EUS has several limitations: it is poor at assessing tracheobronchial invasion, may be unable to pass through very tight stenoses, and cannot detect distant metastases.

Layers of the esophageal wall, as they correspond to the five layers seen in an EUS image.



PET scan

- PET is most useful as a combination PET/CT fusion where it has a 78% sensitivity for identifying nodal disease and distant metastasis.

TNM staging scheme for esophageal cancer

- **Tis High-grade dysplasia**
- **T1 Tumour invading lamina propria or submucosa**
- **T2 Tumour invading muscularis propria**
- **T3 Tumour invading beyond muscularis propria**
- **T4a Tumour invading adjacent structures (pleura, pericardium, diaphragm)**
- **T4b Tumour invading adjacent structures (trachea, bone, aorta)**

- **N0 No lymph node metastases**
- **N1 Lymph node metastases in 1–2 nodes**
- **N2 Lymph nodes metastases in 3–6 nodes**
- **N3 Lymph node metastases in 7 or more lymph nodes**

- **M0 No distant metastases**
- **M1 All other distant metastases**

- Stage 1A: T1N0M0
- 1B: T2N0M0

- 2A: T3N0M0
- 2B: T1/2N1M0

- 3A: T4aN0M0, T3N1M0, T1/2N2M0;
- 3B: T3N2M0; 3C: T4aN1/2M0, T4bN0-3M0 T1-4N3M0;

- 4: T1-4N1-3M1

SELECTION OF OPERATIVE CANDIDATES

- A surgical resection was the standard treatment approach for patients with an early esophageal cancer, but its utility as a monotherapy has been challenged .
- **Criteria for resection**
- **Esophagectomy as first line of therapy**
 - T1N0M0
 - T2N0M0
- **Esophagectomy following neoadjuvant chemotherapy or chemoradiotherapy**
 - Patients with thoracic or esophagogastric junction tumors and full-thickness (T3) involvement of the esophagus with/without nodal disease
 - Selected patients with T4 disease with invasion of local structures (pericardium, pleura, and/or diaphragm only) that can be resected en bloc, and who are without evidence of metastatic disease to other organs (eg, liver, colon).

- **Relative contraindications**

 - Advanced age

 - Comorbid illness

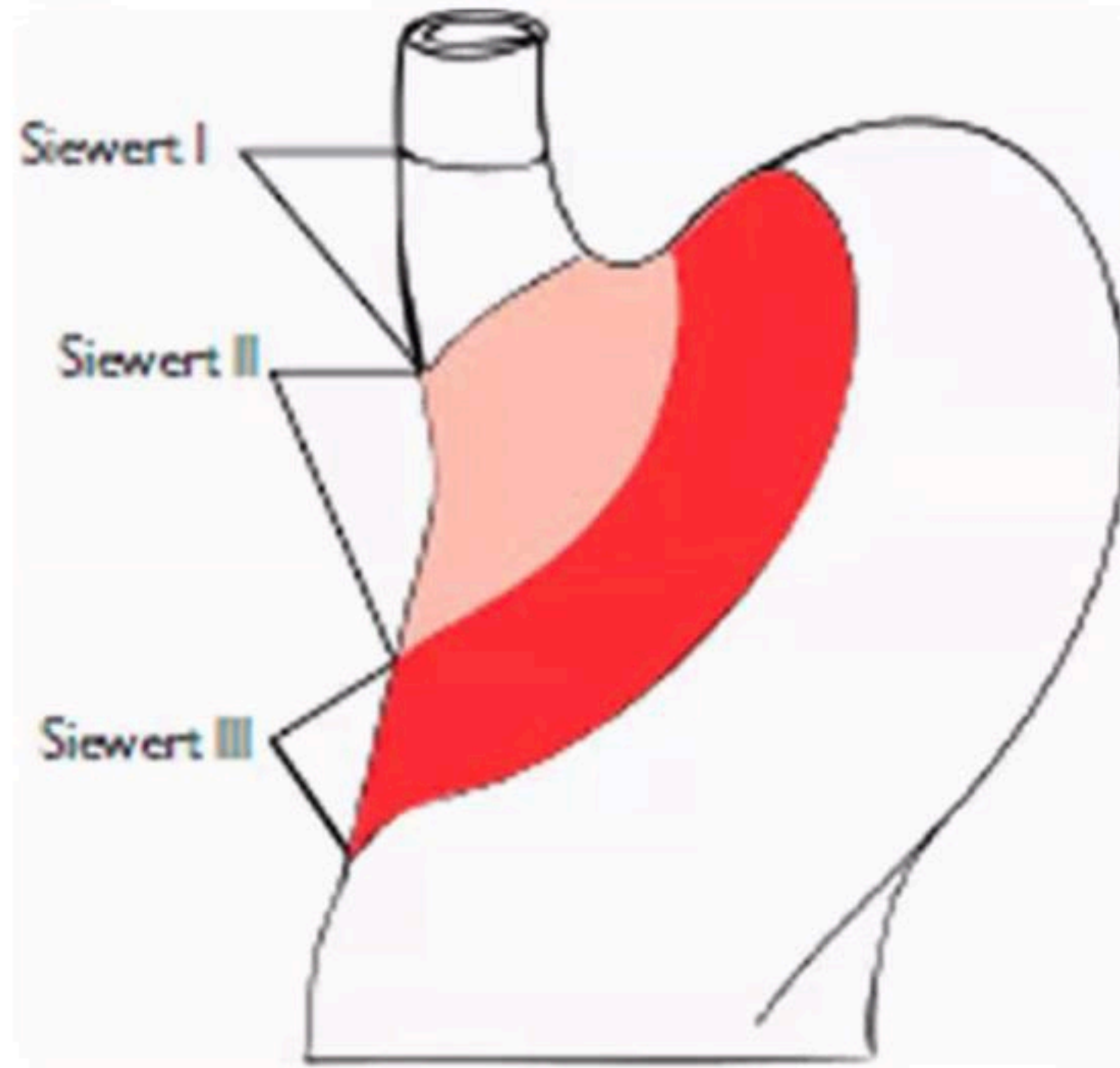
- **Indicators of unresectability** — The presence of **metastatic disease, such as** peritoneal, lung, bone, adrenal, brain, or liver metastases, or extraregional lymph node spread (eg, paraaortic or mesenteric lymphadenopathy), precludes an attempt at resection.

Esophagectomy: overview

- Numerous approaches to esophagectomy
 - esophagectomy *with thoracotomy*
 - esophagectomy *without thoracotomy*
 - no survival difference
- Conduits
 - Stomach: right gastric and right gastric epiploic artery pedicles.
 - Left colon: ascending branch of left colic artery pedicle.
 - Right colon: middle colic artery pedicle.
 - Jejunal free graft: microsurgery implantation of mesenteric arcade.
 - Myocutaneous tube flaps: radial forearm, pectoralis major, TRAM.
- • Route of enteric reconstruction
 - the posterior mediastinum.
 - substernally
 - subcutaneous (anterior to the sternum)
 - via the right or left pleural space.

- Distal adenocarcinomas are divided by *Siewert classification*
 - *Siewert I*: tumors confined to the distal esophagus, just above the gastroesophageal junction (GEJ), spread to mediastinal and celiac nodes: esophagectomy only required, with negative gastric margins.
 - *Siewert II*: tumors with epicenter in the GEJ, which may invade the proximal gastric cardia: generally esophagectomy only is required, with negative gastric margins. Spread is to abdominal lymph nodes.
 - *Siewert III*: tumors with epicenter within the cardia, and extensive gastric involvement: best treated with total gastrectomy, with possible esophagectomy. Spread is to abdominal lymph nodes.

Siewert classification of distal esophageal tumors.



Lymphadenectomy

- The optimal extent of lymph node dissection in esophageal cancer is controversial.
- The esophagus has an extensive lymphatic drainage, which is divided into three zones (fields): abdominal, intrathoracic, and cervical.
- Lymph node resection strategies at the time of esophagectomy range from standard regional and one-field lymphadenectomy, to radical approaches involving two- or three-field lymphadenectomy.

- **Neoadjuvant chemoradiotherapy followed by surgery** probably offers best survival in patients with locally advanced resectable tumor: cure rate is 50% due to a combination of inadequate pathologic response and distant metastases:
 - Stage 0, I, and IIa should be offered primary surgery.
 - Stage IIB and III tumors should be offered trimodality therapy.
 - Stage IV tumors are treated with primary chemoradiotherapy.
- Nutritional status should be optimized before treatment, possibly requiring either NG or jejunal tube feeds.
 - PEG should be avoided, if possible, if the stomach is planned as a conduit. PEG may injure the right gastroepiploic artery which is a necessary vascular pedicle for a gastric conduit.

Adjuvant therapy

- Patients with R1 or R2 resection or residual postoperative N1 disease should be considered for adjuvant chemotherapy 9 radiation, though there is no conclusive data that supports this regimen.



Primary chemoradiation

- Should be considered in patients who from a cardiopulmonary or anatomic standpoint are poor surgical candidates, or who refuse surgery, and for stage IV tumors.

Palliation

- • Attempts at palliation are generally directed to alleviating or minimizing dysphagia.
- • Photodynamic therapy (PDT):
 - • The patient is injected with a 2mg/kg photosensitizer such as sodium porfimer (Photofrin®)
 - • After 48h the tumor is exposed to 300–400J/cm of 630nm light.
 - • 5% perforation rate.
 - • Skin injury from light exposure is common.
- • Brachytherapy:
 - • Catheter-based administration of iridium-192.
 - • Risk of fistula formation.
- • Esophageal stents:
 - • Endoscopy-directed plastic or self-expanding metal stents (SEMS).
 - • Plastic stents are easily removed, but frequently migrate.
 - • Nickel/titanium (nitinol) stents are common. Covered stents (silicone or polyurethane) are beneficial in temporarily sealing tracheoesophageal fistulas. 95% effective in alleviating dysphagia.