Lana Mango

MULTIPLE SCLEROSIS

- AI disorder
- Demyelination of central neurons
- Affects CNS & spinal cord
- Mechanism:
- EPIDEMIOLOGY:
  - Women > men
  - ↑ risk w ↑ distance from the equator
  - ↑ risk w. ↓ vitamin D & sunlight exposure
  - Age 20-40
- COURSE OF THE DISEASE:
  - Relapsing Remitting (80-90%)

- Acute episodes / flares of symptoms
- Symptoms partially / completely resolve
- Followed by another relapse

  - Secondary Progressive

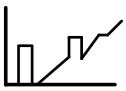

- Initially starts as relapsing rem.
- Next episode is followed by worsening symptoms (worsen gradually)

  - Primary Progressive

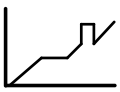

- Doesn't start as relapsing remitting.
- Starts progressing at onset
- May involve an acute flare along its course

- CLINICALLY ISOLATED SYNDROME:
  - First episode of MS symptoms
  - No Hx of previous MS symptoms
  - Classic Presentation:

1 OPTIC NEURITIS Optic N. is heavily myelinated

- * Unilateral (monocular)
- * Blurred vision
- * Central scotoma
- * Eye pain, esp on movement
- * Management: IV steroids (not oral)
  - Protects vision
  - Delays MS

2 INTERNUCLEAR OPHTHALMOPLEGIA

- * Caused by lesion in the medial longitudinal fasciculus (myelinated) which is responsible for coordinates adduction of one eye & abduction of the other (horizontal gaze)
- * Horizontal gaze disorder Affected side can't move medially
- * Affected eye (adducting eye): Can't adduct (weak medial rectus) / contralateral eye (abducting eye): Nystagmus
- * Diplopia (affected) & Nystagmus
- * Convergence is spared it has a diff. neural pathway

Balance my finger w. your eyes

- TRIGEMINAL NEURALGIA:
  - Sudden onset facial pain (lower facial)
  - Involved nerve root compression (usually) of CN V2 & V3 maxillary / mandibular
  - Pain triggered by: ① Touching face ② chewing
  - In MS:
    - * Bilateral
    - * 20 X more common
    - * Due to demyelination

- OTHER CLINICAL FEATURE
  - Lhermitte's sign
    - * electric shock / tingling down neck, spine → limbs
    - * On neck flexion
  - Uhthoff's sign
    - * Heat → ↓ nerve conduction → worsened symptoms
  - Charcot's Neurological Triad
    - * Scanning speech
    - * Nystagmus
    - * Intention Tremor
    - * All cerebellar symptoms

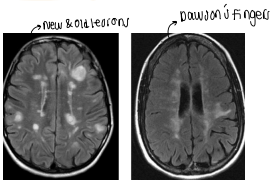

- DIAGNOSIS:
  - Clinical features + MRI
    - 1 * Old & new lesions (because lesions are separate in space & time)
      - Old: Dark, new: Bright (w. gadolinium contrast)
    - 2 * Dawson's fingers
      - White plaques extending from the corpus callosum (midline of the brain)
  - MRI nondiagnostic → VEPs & CSF analysis
  - VEPs Visual Evoked Potential
    - * evaluate optic N. conduction (optic N.)
    - * electrodes on the occipital → visual stimulus → detect time to P100 peak (time for signal to reach visual cortex)
    - * Delayed time to P100
  - CSF (spec)
    - * Oligoclonal (ABO) Bands
    - * Normal CSF: Protein bands
    - * CSF +ve → Oligoclonal Bands → High IgG level

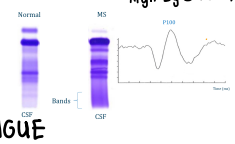

3 BRAINSTEM / CEREBELLAR SYNDROME

- * Ataxia
- * Vertigo
- * Nystagmus
- * Facial Numbness
- * Dysarthria:
  - Scanning speech
  - Words are broken up w. pauses in bw
  - Words are spoken with varying force.

4 PARTIAL TRANSVERSE MYELITIS

- * Spinal cord lesion (affects one level of the cord)
- * Motor & sensory symptoms below the lesion
- * Sensory: IPSILAT: vibration & proprioception CONTRALAT: Loss of pain & temp. sensation (similar to Brown-Sequard)
- * Autonomic: Bladder & bowel dysfunction

5 FATIGUE
extremely common

6 BLADDER DYSFUNCTION

- * urgency, frequency
- * URGE incontinence
- * due to overactive bladder & detrusor muscle
- * Management: Anti-cholinergic Oxybutynin or Antimuscarinic

- TREATMENT PML: Progressive Multifocal Leukoencephalopathy

→ Acute exacerbation:

- * IV corticosteroids (methylprednisolone)
- * Speedy recovery but doesn't alter prog.

→ Long term: (improve frequency)

- * IFN β (injection) → Inhibit T cell func. → Improve symptoms
- * Glatiramer (injection) → 4 AA polymer similar to myelin basic protein (MBP) which is target of T cell → T cells bind to the drug instead of neuronal MBS
- * Natalizumab (IV infusion) → monoclonal Ab targeting α4 subunit of integrin (integrin allows adhesion of lymphocytes to vasc. endoth. to migrate to the brain)
  - ↳ T cells don't enter the brain
  - • Risk of PML (check for anti JCV antibodies) (expensive by polymerase chain reaction)

DEMYELINATING DISEASES

Central: MS, ADEM, Neuromyelitis optica, PML
Peripheral: GBS, CIDP

CENTRAL DEMYELINATING DISORDERS

① ACUTE DISSEMINATED ENCEPHALOMELITIS
POSTINFECTIOUS ENCEPHALOMYELITIS

- Inflammatory central Demyelinating disorder
- Cause: Adverse effect of: (≈ 15 days later) ① Vaccine: Smallpox, Rabies ② Infection: Varicella, Measles
- Children
- Clinical Features:
  - * Confusion (encephalopathy)
  - * Motor / sensory deficits
    - Acute onset
    - Multifocal
  - * Rapid deterioration → Hospitalization

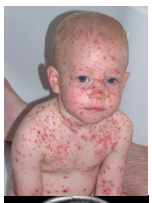

- MRI Findings:
  - * Multifocal: multiple lesions
  - * Asymmetric, Bilateral lesions

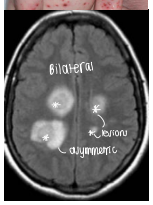

- Treatment
  - * Steroids: Methylprednisone

② NEUROMYELITIS OPTICA

- Involves Optic nerve & Spinal cord
- Caused by IgG antibodies against Aquaporin-4 (AQP4)
  - * Water channel protein in the CNS & Spinal cord.
  - * Distinguishes it from MS
- Diagnosis
  - * MRI
  - * AQP4 Ab Test
- Clinical Features:
  - * Similar to those of MS.
  - ① Optic neuritis
  - ② Transverse myelitis (sensory & motor loss)
  - ③ Brainstem syndromes (CN's)
  - ④ Area Postrema Clinical syndrome: → distinguishes it from MS
    - Area of the medulla that works as a chemoreceptor trigger zone.
    - Lesion in it:
      - ① Intractable nausea, vomiting
      - ② Intractable hiccups
- Treatment
  - * Acute: IV methylprednisolone (like MS)
  - * Recurrent attacks: Immunosuppressants (like MS)

③ PROGRESSIVE MULTIFOCAL LEUKOENCEPH. (PML)

- Cause: Reactivation of the dormant JC virus due to immune suppression.
  ① HIV ② Leukemia / Lymphoma ③ Natalizumab (MS treatment)
- Viral destruction of Oligodendrocytes.

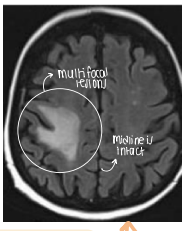

- PML Clinical Features:
  - * Subacute (slow onset) weeks - months
  - ① Motor or sensory deficit
  - ② Confusion (encephalopathy)
- Diagnosis:
  - ① MRI: multifocal lesions w. no mass effect / shifting the midline
  - ② CSF: JCV Ab's
  - ③ Gold standard: Biopsy (rarely done)
- Treatment:
  - * No effective Tx
  - * Resolve Immunosuppression

PERIPHERAL DEMYELINATING DISORDERS

① GUILLAIN-BARRE SYNDROME

- Acute inflammatory demyelinating radiculopathy.
- Destruction of Schwann cells by the immune system.
- Motor & sensory deficit.

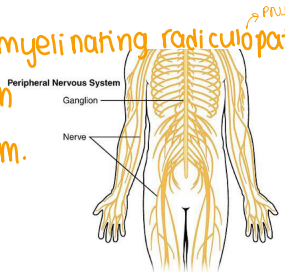

- Variants:
  - ① Acute Inflamm. Demyelinating Polyneuropathy
  - ② Acute Motor Axonal
  - ③ Acute motor & sensory Axonal
  - ④ Miller Fisher Syndrome
- Acute Inflamm. demyelin. Polyneuropathy
  - ① Ascending muscle weakness
    - 1/3: Resp. Failure
    - > 50%: Facial Muscle Weakness
  - ② Loss of Deep Tendon Reflexes
    - Deep reflexes have circuits in the PNS → Demyelination → Impairment
  - ③ Sensory Deficit (Paresthesia - mild)
    - Symptoms Resolve over months.
  - ④ Autonomic Dysfunction:
    1. Tachycardia
    2. HTN or Hypotention This, and Resp. Failure, are the causes of death in GBS pt's.
    3. Bed sweating
    4. Urinary Retention
    5. Ileus
    6. Arrhythmia
- Trigger: Infection or (rarely) immunization
  - ① Campylobacter Jejuni (Pt's present w. Bloody Diarrhea prior to neuropathy)
  - ② CMV
  - ③ EBV
  - ④ HIV
- Diagnosis
  - ① Clinical findings (3 A's)
    - Ascending Paralysis
    - Autonomic Neuropathy
    - Albuminocytologic Dissociation
  - ② CSF:
    - ↑ Protein
    - Normal cell count
      Albuminocytologic Dissociation
- TREATMENT: Steroids ARENT effective
  - ① Resp. monitor & support: Vital Capacity, Negative Inspforce
  - ② Plasmapheresis to wash out / remove harmful Ab's.
  - ③ IVIG to neutralize Ab's

② CIDP: CHRONIC INFLAMM DEMYELINATING POLYNEUROPATHY

- similar to Guillain Barre:
  ① motor weakness
  ② Loss of reflexes
  ③ Albuminocytologic Dissociation

- Distinguished from GBS:
  * Time course:
    - GBS: Max weakness ≤4 weeks since onset
    - CIDP: >8 weeks (chronic) to reach max (progressive) pain
  * corticosteroids:
    - GBS: No benefit
    - CIDP: effective