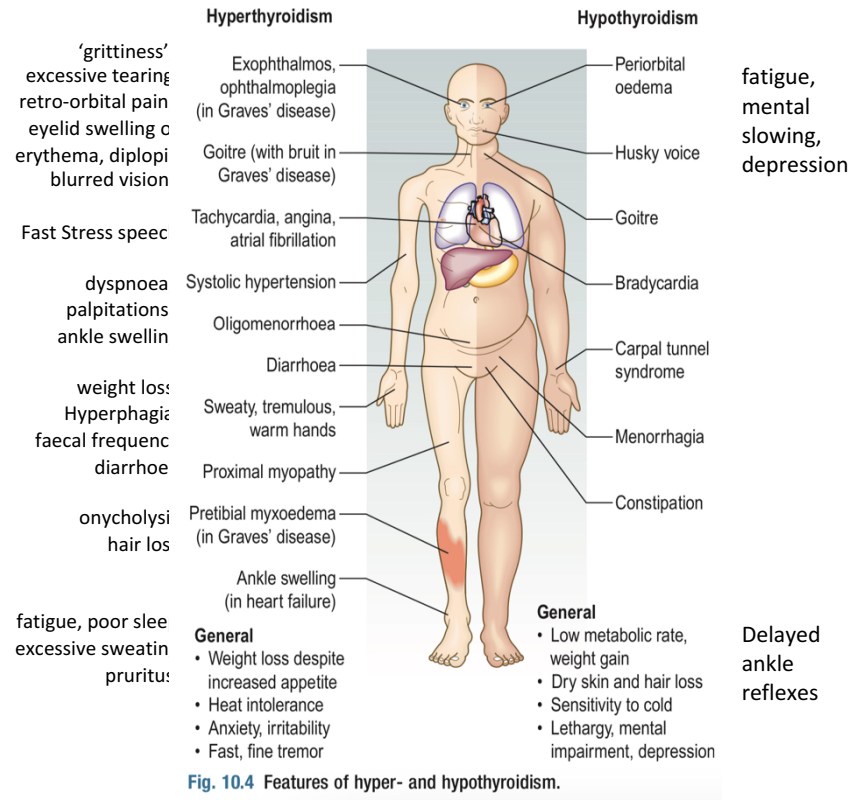




Thyroid diseases



Condition	Profile	Notes
Thyrotoxicosis	<p>Increased metabolism due to elevated thyroid hormone in the blood</p> <p>Hyperthyroidism symptoms</p> <p>P/E: warm, moist skin, proximal muscle weakness (due to a catabolic energy state), tremor and brisk deep tendon reflexes</p>	<p>Causes aside from graves' disease:</p> <ul style="list-style-type: none"> -Excessive TH ingestion -Toxic multinodular goitre -Solitary toxic nodule (nodules can be painful in case of bleeding) <p>-Amiodarone can result in hyperthyroidism</p>
Graves' disease	<p>Hyperthyroidism symptoms +</p> <p>P/E:</p> <ul style="list-style-type: none"> • Vitiligo • Acropachy • Pretibial myxedema • Lid retraction • Lid lag • Exophthalmus • Chemosis • Diffuse thyroid enlargement (can be nodular) • Thyroid bruit 	<p>Autoimmune disease</p> <p>With a Familial component</p> <p>More common in women ages 30-50</p> <p>sympathetic hyperactivity.</p> <p>Graves' ophthalmopathy</p> <p>Characteristically associated with restriction of upgaze. Caused by an inflammatory infiltration of the soft tissues and extraocular muscles</p>

	<ul style="list-style-type: none"> • Signs of Graves' ophthalmopathy (proptosis, redness, edema) • corneal ulceration, diplopia, ophthalmoplegia and compressive optic neuropathy 	<p>Inflammation of the orbital soft tissues may lead to other more severe features</p> <p>Smoking increases risk of graves ophthalmopathy</p>
Thyroiditis	<p>Significant history:</p> <ul style="list-style-type: none"> • Recent pregnancy – postpartum thyroiditis • Hyperthyroidism with diffuse neck pain followed by hypothyroidism - viral (de quervin's) thyroiditis 	
Goitre (large or retrosternal)	<p>Compressive symptoms: SOB, stridor and dysphagia</p>	Usually euthyroid
Thyroglossal cyst	<p>Neck cyst that moves with tongue protrusion</p>	Arises from remnant thyroglossal duct
Thyroid malignancy	<p>Fixation of the thyroid to surrounding structures (such that it does not move on swallowing) and associated cervical lymphadenopathy.</p>	
Hashimoto thyroiditis	<p>Hypothyroidism signs, Most common cause</p>	Autoimmune etiology
Hypothyroidism notes	<ul style="list-style-type: none"> • Antithyroid, radioiodine therapy, Lithium medication can cause hypothyroidism • Residence in an area of iodine deficiency, such as the Andes, Himalayas, Central Africa: can cause goitre and, rarely, hypothyroidism. • Graves disease surgery 	