

Thyroid gland

- Endocrine glands: 1. pituitary 2. thyroid 3. parathyroid 4. endocrine pancreas 5. adrenal 6. gonads (testis + ovaries)
- pituitary control All of them except: **pancreatic islet cells + para thyroid.**
- circulate in Blood → **systematic effect.**

- THYROID GLAND** - Butterfly shaped gland located inferior to cricoid cartilage, 4 cm below superior notch of thyroid cartilage.
- palpable in 50% women, 25% men. Central isthmus → 1.5 cm in width cover 2,3,4 tracheal rings. Bilateral lobes.
- extended to the superior mediastinum: partially or fully retrosternal.
- thyroglossal duct can form cyst. assist by tongue protrusion.
- attached to pretracheal fascia → Move Superiorly when swallowing → if tumor will not move

History

- **Neck swelling** ① Goitre: enlargement of thyroid gland ② thyroid nodules → Solitary
↳ euthyroid, stridor, dysphagia, SOB ↳ Multinodular
- **Neck pain** ① Sudden: bleeding of nodule after enlargement ② viral subacute (de Quervain's) thyroiditis.
- **Hyper- and hypo thyroidism** mention below
- **Medical Hx** - radiation (malignancy) - pregnancy (post-partum thyroiditis)
- **Drug Hx** Anti-thyroid drugs, radioiodine therapy → **amiodarone / lithium** → thyroid dysfunction.
- **Family Hx** endocrine disorders → Multiple endocrine neoplasia → Autosomal dominant inheritance.
- **Social Hx** - smoking → graves ophthalmopathy ② iodine deficiency areas → hypothyroidism.

Physical examination

- ① vital signs - LOC - BMI
- Inspection** Midline of Neck → scars, masses. Normal gland Not visible
- swallowing → mass, cyst, LN (more upward) malignancy (Not more)
- Tongue protrusion → cyst (more upward) mass, LN (Not more)
- palpation**
- From behind Pt → ① thyroid gland ② Adam's Apple ③ isthmus + lobes ④ Swallow water then palpate ⑤ protrude tongue for mass/cyst.
- LN palpation (Cervical LN)
- percussion** percuss sternum (from sternal notch to retrosternal dullness)
- Auscultation** Auscultate each lobe for bruit using Bell.

Hyperthyroidism

- ABOUT: ↑ thyroid hormone level → ↑ metabolism

- CAUSES: 1- Graves disease [M.C.C] Auto immune, Women > men [x 5-10], 20-50 yrs, causes ↑ production of TSI → ↑ production of T₃+T₄ from thyroid gland

2- Solitary toxic nodule 3- Multi nodular goitre

causes over production of thyroid hormones.

4- thyroiditis inf. of thyroid → 3 levels
 ↙ Hyper thyroidism 1
 ↘ eut thyroid 2
 ↘ Hypothyroidism 3 [Hashimoto]

5- exogenous thyroid types are

1- thyroid hormones intake 2- ectopic thyroid.

- Features: For all hyperthyroidism Causes:

* Fatigue - poor sleep - Tremor - Heat intolerance - sweating - pruritus (for both hypo + Hyper) - onycholysis - Hair loss - anxiety - emotional lability.

* Dyspnea - palpitation - ankle swelling cardiac symptoms because of ↑ demand on heart → heart failure.

* wt loss - Hyperphagia (↑ appetite) - diarrhoea

* proximal ms weakness (Shoulder + pelvic)

* oligo menorrhoea (↓ frequent period), amenorrhoea (absent period)

* HTN (systolic) - Tachycardia - atrial F.

* Face flushing due to vasodilation

For Hyperthyroidism that caused by graves disease:

* eye symptoms: grittiness (sand like in eyes), ↑ tearing, retro-orbital pain, eyelid swelling, erythema,

Blurred vision, diplopia, ophthalmoplegia

* Finger Clubbing [thyroid Acropachy], Vitiligo

* Goitre with bruit, pretibial myxoedema,

Hypothyroidism

- ABOUT: ↓ thyroid hormone level → ↓ metabolism

- CAUSES: 1- Hashimoto thyroiditis: MCC, women > men by 6x

2- radiation exposure

3- thyroidectomy

- Features: Fatigue and pruritis (Like Hyper)

* mental slowness (thick tongue → slow speech)

* cold intolerance

* wt gain (anorexia), constipation

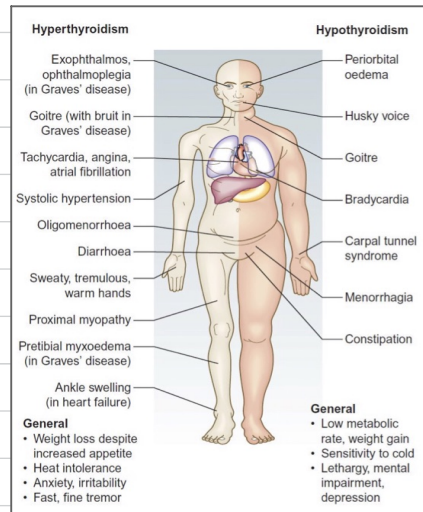
* Carpal tunnel syndrome (median nerve intrusion cause Numbness)

* Brittle hair and nails.

* HTN (diastolic) Brady cardia

* expression less face [dull-blank expression]

* Husky voice



Hyper-examination

HANDS

① Inspection * excessive sweating

- * Acropachy (phalangeal bone over growth)
- * onycholysis (detachment of nail from nail bed)
- * palmar erythema (+ pregnancy + liver disease)
- ② others * tremors (stretch arms) * vitiligo

RADIAL PULS

rate + rhythm

FACE

Excessive sweating

EYES

check for : Lid retraction (if sclera

visible btw upper lid margin and corneal limbus)

- * eye inflammation
- * exophthalmos (proptosis) (Bulging of the eye)

EYE MOVEMENTS

: ophthalmoplegia

(restricted eye move. + diplopia) , pain during eye move. (H shape)

- * Lid Lag (delay upper eyelid to eye ball move.)
- finger superior to inferior

CARDIAC EXAMINATION

Midsystolic murmurs → ↑ CO

REFLEXES

Nil

PRETIBIAL MYXOEDEMA

Mucinosis →

Accumulation of glycosaminoglycans in dermis .

↳ waxy - discolored induration of skin

PROXIMAL MYOPATHY

Multi nodular + Graves . Ask pt to stand from sitting

Position with crossed arms

Hypo-examination

HANDS

Dry skin - Carpal tunnel syndrome

RADIAL PULS

rate + rhythm

FACE

Dry skin , absence of the outer third of eyebrows

EYES

check for : lid retraction (if sclera

visible btw upper lid margin and corneal limbus)

EYE MOVEMENTS

Nil

CARDIAC EXAMINATION

Nil

REFLEXES

hypo reflexia → ① Biceps reflex

② Knee Jerk reflex

PRETIBIAL MYXOEDEMA

Nil

PROXIMAL MYOPATHY

Nil