

# Peripheral Vascular System

---

### **\*How common?**

- around 20% of population >60 YO
- only 1/4<sup>th</sup> are **symptomatic**.
- legs **8X more** commonly affected than arms

### **\* General cause?**

>> **atherosclerosis** of large & medium-sized vessels.

•



## 6.33 Classification of lower limb ischaemia

I	Asymptomatic
II	Intermittent claudication
III	Night/rest pain
IV	Tissue loss (ulceration/gangrene)

---

# Asymptomatic Ischemia

Significant LLI = ABPI <0.9 at rest.

Mostly asymptomatic

- choose not to walk very far, or
- exercise tolerance is limited by other co-morbidity.
  
- Even if the patient is symptomatic, they should be treated as if grade II (IC)

# Intermittent Claudication

---

## Most common symptom of PAD

\* Def.: Pain in a group of muscles on walking due to arterial insufficiency.

- typically; Calf (femoro-popliteal disease).
- also; Thigh &/or buttock (aorto-iliac obstruction).
- Tightness or '**cramp-like**' pain.
- Develops after relatively constant distance (**claudication distance**); often shorter if walking uphill, in the cold & after meals.
- Disappears **completely** within a few minutes of **rest** but recurs on walking.

---

>> Two other types of claudication:

- **Neurogenic**: due to neurological & musculo-skeletal disorders of lumbar spine.
  - **Venous**: due to venous outflow obstruction from the leg, following extensive DVT.
- >> Both are much less common than arterial claudication, & can be distinguished on Hx. & P/E.



### 6.34 The clinical features of arterial, neurogenic and venous claudication

	Arterial	Neurogenic	Venous
Pathology	Stenosis or occlusion of major lower limb arteries	Lumbar nerve root or cauda equina compression (spinal stenosis)	Obstruction to the venous outflow of the leg due to iliofemoral venous occlusion
Site of pain	Muscles, usually the calf but may involve thigh and buttocks	Ill defined. Whole leg. May be associated with numbness and tingling	Whole leg. 'Bursting' in nature
Laterality	Unilateral if femoropopliteal, and bilateral if aortoiliac disease	Often bilateral	Nearly always unilateral
Onset	Gradual after walking the 'claudication distance'	Often immediate on walking or standing up	Gradual, from the moment walking starts
Relieving features	On stopping walking, the pain disappears completely in 1–2 minutes	Bending forwards and stopping walking. May sit down for full relief	Leg elevation
Colour	<del>Normal or pale</del>	<del>Normal</del>	<del>Cyanosed</del> Often visible varicose veins
Temperature	Normal or cool	Normal	Normal or increased
Oedema	Absent	Absent	Always present
Pulses	Reduced or absent	Normal	Present but may be difficult to feel owing to oedema
Straight-leg raising	Normal	May be limited	Normal

# Night/Rest Pain

---

*‘ Pt. goes to bed, falls asleep, but is then woken 1–2 hrs later with severe pain in the foot, usually in the instep ’*



Lying down >> No gravity effects >> poor perfusion.



Dec. HR, BP & CO >> occurs when sleeping.

Relieved by hanging legs out of bed or by getting up & walking around.

However, on return to bed, pain recurs & pts often choose to sleep in a chair.



Dependent edema, ↑ interstitial tissue pressure.



Further reduction in tissue perfusion & ultimately a worsening of pain.

---

### ***Critical limb ischemia***

- Rest pain persisting for more than 2 weeks requiring opiate analgesia
- Tissue loss associated with ankle pressure of  $<50\text{mmhg}$  or toe pressure  $<30\text{ mmhg}$  , , ABI  $<0.4$  & a +ve Buerger's test

---

## A 'red flag' symptom

- \* Indicates severe, multilevel LL PAD.
- \* Mandates urgent referral to a vascular surgeon
  - >> As failure to re-vascularise >> critical LLI with tissue loss (gangrene, ulceration) & amputation.

## Rest Pain vs. Diabetic Neuropathy

- \* **Both** may be worse at night.
- \* **Neuropathic** pain: - usually *not confined* to the foot,
  - burning, tingling or numbness (*dysaesthesia*),
  - Not relieved by *dependency*,
  - Many pts cannot even bear bedclothes pressure on their feet.

---

## Tissue loss (ulceration &/or gangrene)

In severe LL PAD, even trivial injuries to feet fail to heal.



This allows bacteria to enter, leading to gangrene &/or ulceration.



Without re-vascularisation; leads **quickly** to amputation &/or death


\* critical limb ischaemia (rest pain, tissue loss) typically have an *ankle BP* <50 mmHg, *ABI* <0.4 & a *+ve Buerger's* test.

# Signs of lower limb PAD

---

- Absence of hair.
- Thin skin.
- Brittle nails.

# Acute LLI



6.35 Signs of acute limb ischaemia	
<b>Soft signs</b>	
<ul style="list-style-type: none"><li>• Pulseless</li><li>• Pallor</li></ul>	<ul style="list-style-type: none"><li>• Perishing cold</li></ul>
<b>Hard signs (indicating a threatened limb)</b>	
<ul style="list-style-type: none"><li>• Paraesthesia</li><li>• Paralysis</li></ul>	<ul style="list-style-type: none"><li>• Pain on squeezing muscle</li></ul>

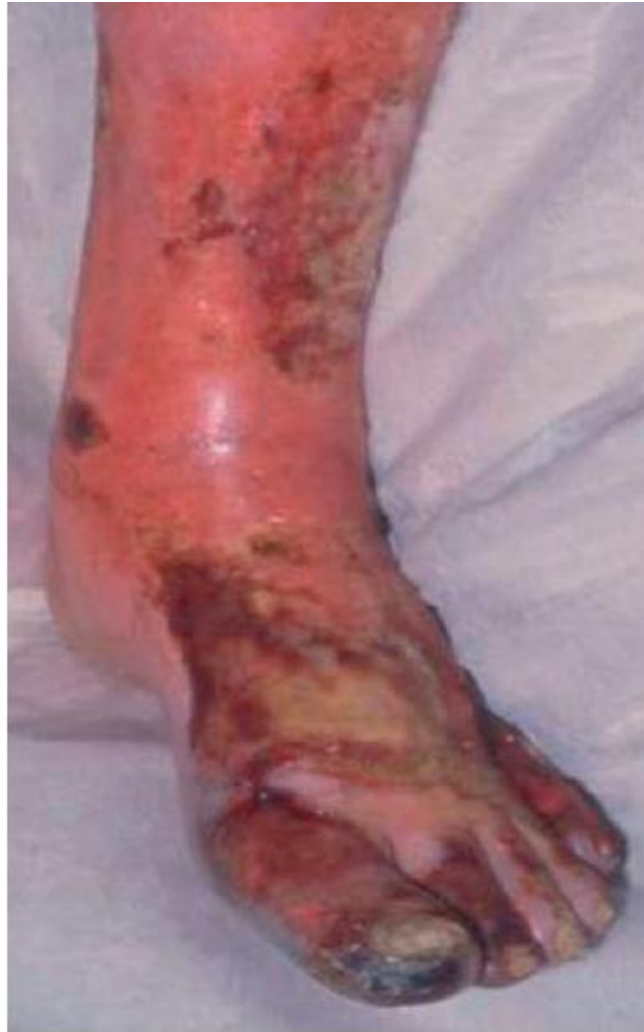

Irreversible damage **unless** circulation is restored within a ***few hours.***



## 6.36 Acute limb ischaemia: embolus versus thrombosis in situ

	<b>Embolus</b>	<b>Thrombosis</b>
Onset and severity	Acute (seconds or minutes), ischaemia profound (no pre-existing collaterals)	Insidious (hours or days), ischaemia less severe (pre-existing collaterals)
Embolic source	Present (usually atrial fibrillation)	Absent
Previous claudication	Absent	Present
Pulses in contralateral leg	Present	Often absent
Diagnosis	Clinical	Angiography
Treatment	Embolectomy and anticoagulation	Medical, bypass surgery, thrombolysis



**Fig. 6.36** Gangrene of the foot.

# Compartment Syndrome

---

- \* **Def.** >> increased pressure within the fascial compartments of the limb, most commonly the calf, which compromises perfusion & viability of muscle & nerves.
- \* **Causes: commonest** >> 1. lower trauma, (e.g. fractured tibia),  
2. reperfusion following tt of acute LLI.
- \* **Failure to recognize & treat** >> may require limb amputation!
- \* **The key symptom** >> severe pain often unrelieved by opioids & exacerbated by active or passive movement. Peripheral pulses are usually present.

# Mesenteric ischemia

---

The three major visceral arteries  
(celiac trunk, SMA & IMA).

## Chronic mesenteric arterial insufficiency:

- 2/3 must be critically stenosed or occluded as there is Rich collateral circulation.
  - **Severe central abdominal pain** typically develops 10–15 min post-prandial. “scared of eating” + significant wt. loss.
  - **Diarrhea** may occur.
- Confirmed by **Angiography**.

---

 **Acute mesenteric ischemia:**

***“surgical emergency”***

- Severe abdominal pain,
- Shock,
- Bloody diarrhea,
- Profound metabolic acidosis.
- **Rarely**, renal angle pain occurs from renal infarction or ischaemia, & is associated with microscopic or macroscopic hematuria.

# Abdominal Aortic Aneurysm

---

- ✿ **Def.** >> Abnormal focal dilatation of aorta.150%
- ✿ **How common?** 5% of men aged >65 yrs (**3X more in men**)
- ✿ **Risk factors** >> smoking, HTN, familial/genetic element.
- ✿ Mostly **asymptomatic** until rupture and usually Dx incidentally on CT scan or alternative imaging done for other reasons
- ✿ symptoms &/or back pain or awareness of abdominal pulsation, observation of ripples in the water when they are in the bath (wave sign)
- ✿ Confirm Dx. >> **US.**

\* Now, In UK, US-based AAA screening program for men as they reach their 65

# Ruptured AAA

---

## 💣 **Difficult to diagnose!**

>> many pts do not have the classical features which are: abdominal &/or back pain, pulsatile abdominal mass, syncope & shock (hypotension).

💣 **If** any suspicion >> call a vascular surgeon straight away >> **immediate** contrast-enhanced CT abdomen (**if pt is stable**).

💣 You should always have a low threshold of suspicion

💣 **'blue toe syndrome'**: purple discoloration of toes & forefoot of both feet. Due to athero-embolism from an AAA, popliteal aneurysm, atherosclerotic plaque. Usually full set of pedal pulses. Risk of major emboli. Herald the risk of a major embolus leading to acute limb ischemia and even limb loss

# Vasospastic Symptoms

---

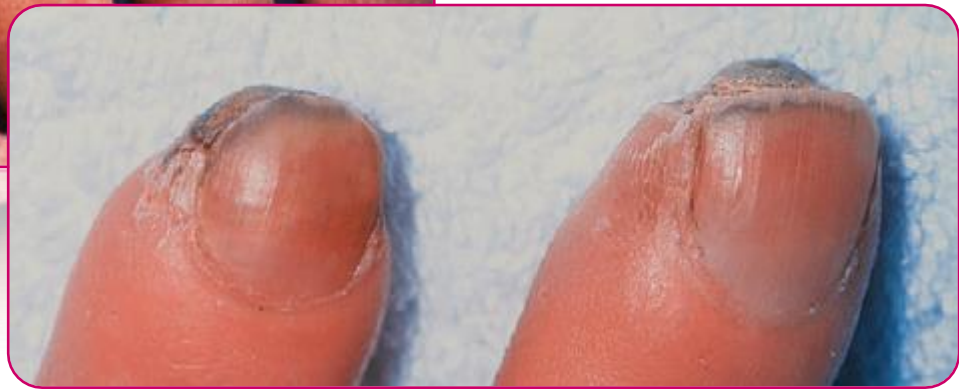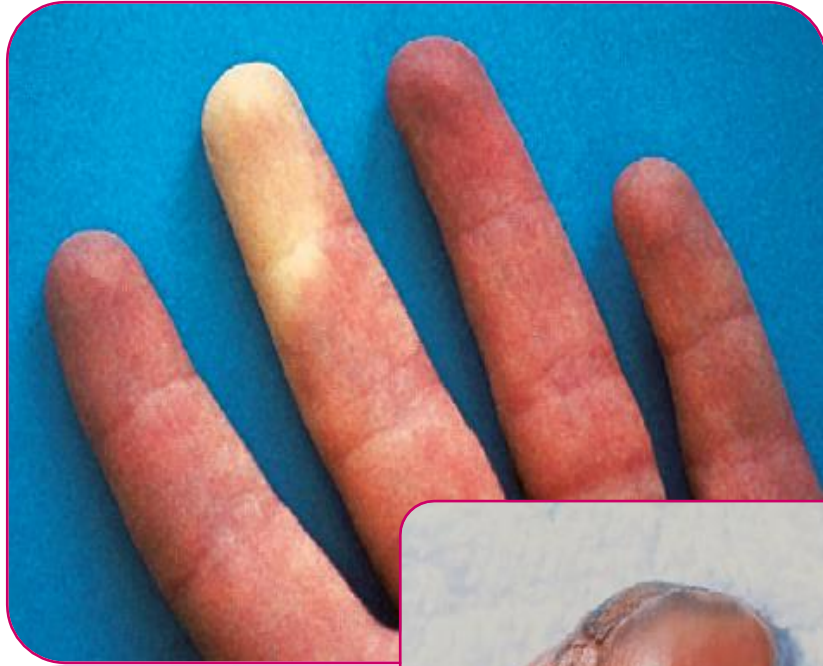## Reynaud's phenomenon

Digital ischaemia induced by cold.

### Three phases:

- **Pallor:** due to digital art. spasm &/or obstruction.
- **Cyanosis:** due to deoxygenation of static venous blood (this phase may be absent).
- **Redness:** due to reactive hyperemia.

***Pts >40YO with unilateral Raynaud's phenomenon have underlying PAD unless proven otherwise, especially if they have risk factors (smoking, diabetes).***



---

📖 **Primary**  
(Raynaud's **disease**)  
>> idiopathic digital  
artery vasospasm.

📖 **Secondary**  
(Raynaud's **syndrome**).

📖 Self limiting.. Tissue  
loss in minority



### 6.38 Diseases associated with secondary Raynaud's syndrome

- Connective tissue syndromes, e.g. systemic sclerosis, CREST (calcinosis, Raynaud's phenomenon, oesophageal dysfunction, sclerodactyly, telangiectasia) and systemic lupus erythematosus
- Atherosclerosis/embolism from proximal source, e.g. subclavian artery aneurysm
- Drug-related, e.g. nicotine, beta-blockers, ergot
- Thoracic outlet syndrome
- Malignancy
- Hyperviscosity syndromes, e.g. Waldenström's macroglobulinaemia, polycythaemia
- Vibration-induced disorders (power tools)
- Cold agglutinin disorders

---

# History



---

**Risk factors** for atheroma (smoking, hypercholesterolaemia, HTN, DM)?

**Family Hx.** premature arterial disease? Other vascular disease (AAA), CVA

Previous investigation , operation

**Impact of IC relates to pt's age & lifestyle, daily living .**

**Drugs : antiplatlet, lipid lowering .....**

---

# Physical Examination

Face and neck	
Corneal arcus and xanthelasma	Hypercholesterolaemia
Horner's syndrome	Carotid artery dissection or aneurysm
Hoarseness of the voice and 'bovine' cough	Recurrent laryngeal nerve palsy from a thoracic aortic aneurysm
Prominent veins in the neck, shoulder and anterior chest	Axillary/subclavian vein occlusion

\* + signs of anemia & cyanosis.

\* Abnormally prominent pulsation in neck of elderly significant >> normally caused by tortuous arteries rather than a carotid aneurysm or carotid body tumor.

Sign	Implication
<b>Hands and arms</b>	
Tobacco stains	Smoking
Purple discoloration of the fingertips	Atheroembolism from a proximal subclavian aneurysm
Pits and healed scars in the finger pulps	Secondary Raynaud's syndrome
Calcinosis and visible nailfold capillary loops	Systemic sclerosis and CREST (calcinosis, Raynaud's phenomenon, oesophageal dysfunction, sclerodactyly, telangiectasia)
Wasting of the small muscles of the hand	Thoracic outlet syndrome

- ⌘ Examine radial & brachial pulses.
- ⌘ Measure BP in both arms.

---

Abdomen	
Epigastric/umbilical pulsation	Aortoiliac aneurysm
Mottling of the abdomen	Ruptured abdominal aortic aneurysm or saddle embolism occluding aortic bifurcation
Evidence of weight loss	Visceral ischaemia

\* Aortic bifurcation >> at level of umbilicus.

⊗ **Palpate** over abdominal aorta – for **pulsatile mass** (*Below or above umbilicus = AAA vs. Iliac aneurysm*).

⊗ **Listen** over abdominal aorta.

---

# LL EXAMINATION





---

## Inspection:

- Position of pt.
  - >> Flat , elevate 45 degree, dependant position.
- Color changes / muscle wasting / hair distribution / scars form previous surgery / varicose vein / shiny skin / onycholysis / Venous guttering/ Fungal infection in between toes/ Swelling ...
- Look specifically **between toes** for ulcers [position, margin, depth & color] & **at heels** for ischemic changes (commonest site of 'pressure sores').



## Palpation:

- Muscle **tenderness**.
- Difference in **temperature**.
- Lower limb **pulses**.
- Capillary **Refill**.
- **Special** Tests (Burger's Test, ABPI).

## Femoral pulse:

---

Against head of femur.

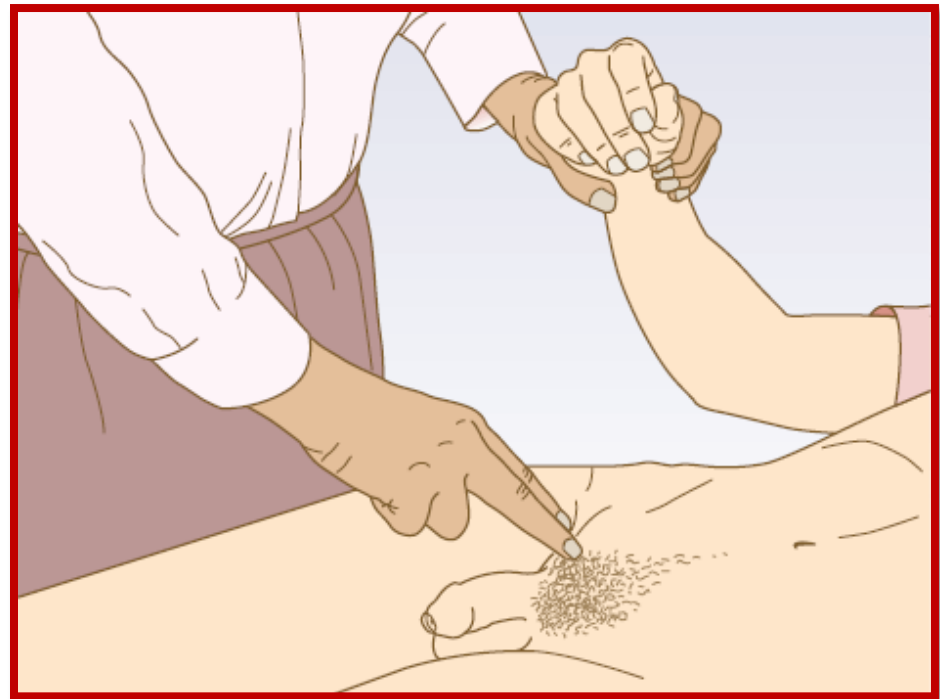Use 2 fingers pads (index & middle).

2.5\*2.5 cm inferior & lateral to pubic tubercle.

Difficult to feel in obese ppl.

Check for radio- femora delay.

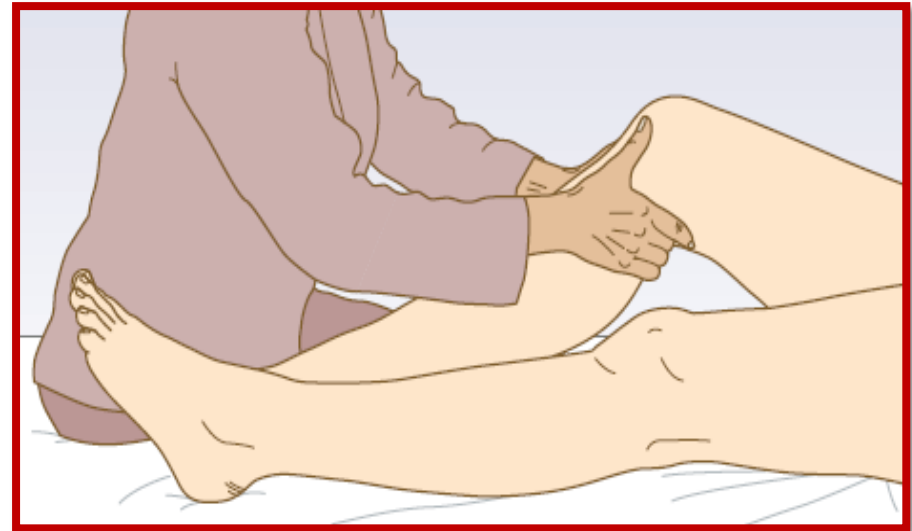
Bilateral auscultation (for bruit) using the **diaphragm**.



---

## Popliteal pulse:

**Lying flat** – knee flexion 30 degrees. Both thumbs in front of the knee, other fingers behind & press firmly.

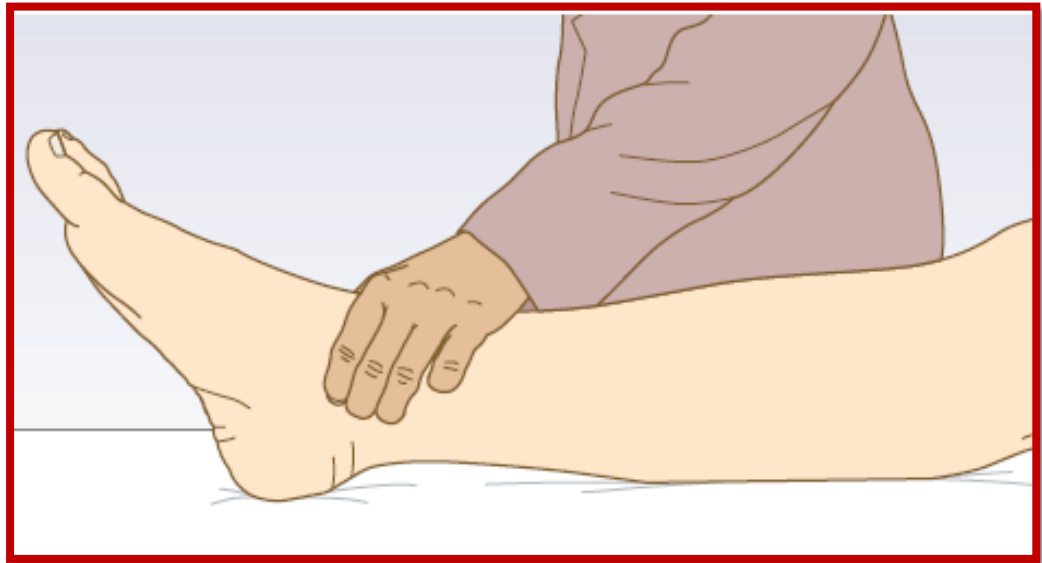


---

## Posterior tibial pulse:

2 cm below &  
2 cm behind  
medial malleolus.

Pads of middle three  
fingers.

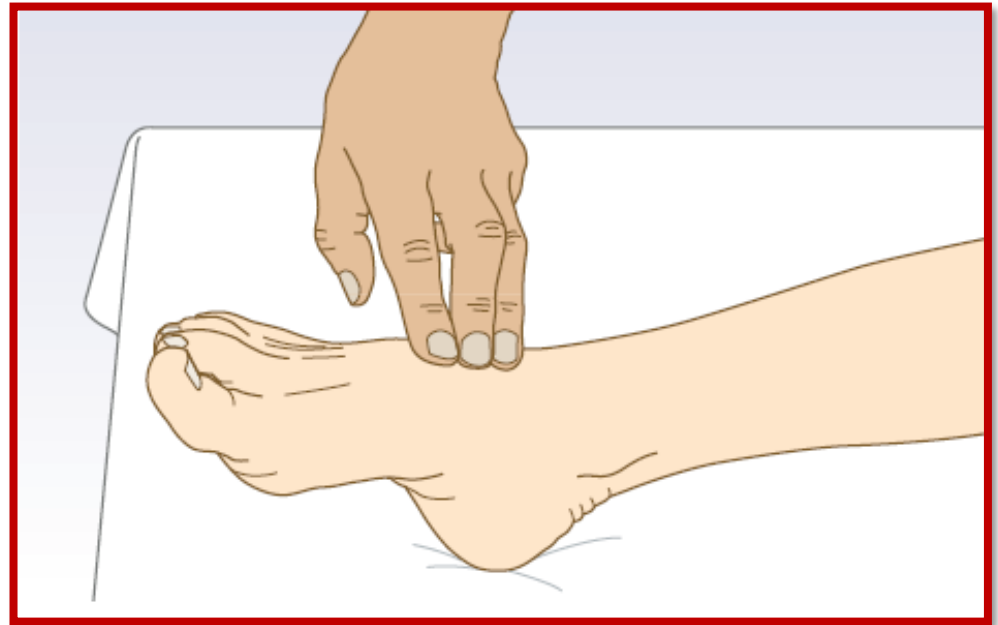


---

## Dorsalis pedis pulse:

Pads of three middle fingers.

Middle of the dorsum of the foot Lateral to extensor hallucis longus tendon.



---

## ABPI

Routinely whenever difficulty palpating lower pulses

PAD is suspected

Ratio of highest pedal artery pressure to highest brachial artery pressure



---

ABPI > 1 in supine

<0.9 intermittent claudication

<0.4 critical limb ischemia

ABPI in diabetic patient falsely reassuring due to noncompressibility and calcified vessels

# Burger's Test

Pt lying supine.

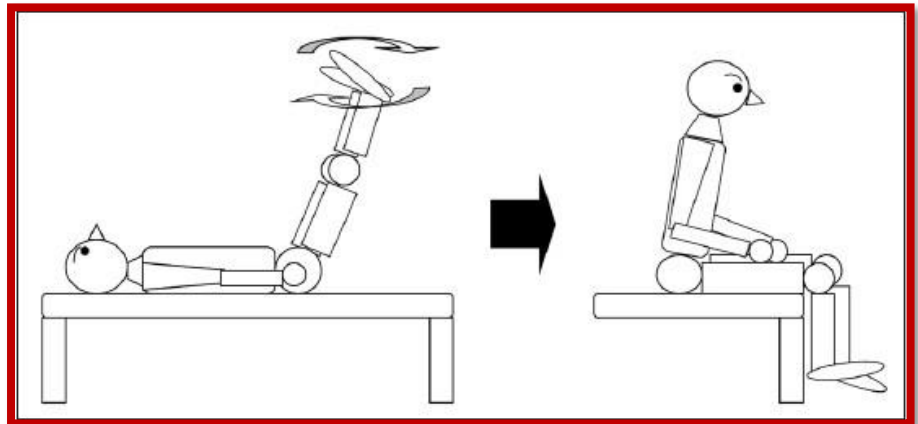
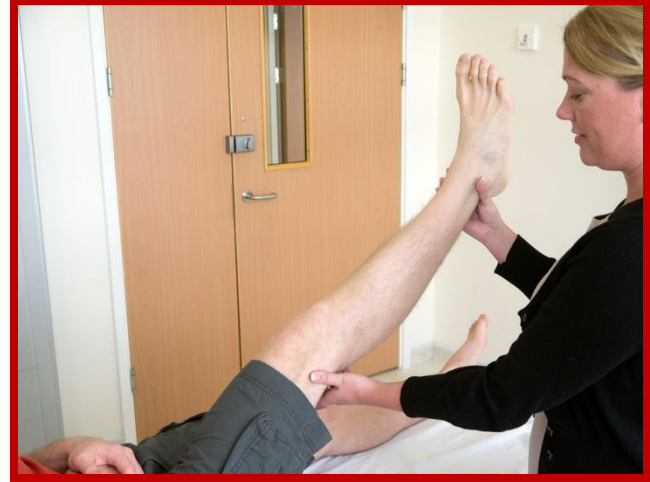Raise pt's feet & support legs at 45° for 2–3 minutes.

Watch for **pallor with emptying** or 'guttering' of superficial veins.

Ask pt to sit up & hang legs over bed's edge.

Watch for **reactive hyperemia on dependency**.

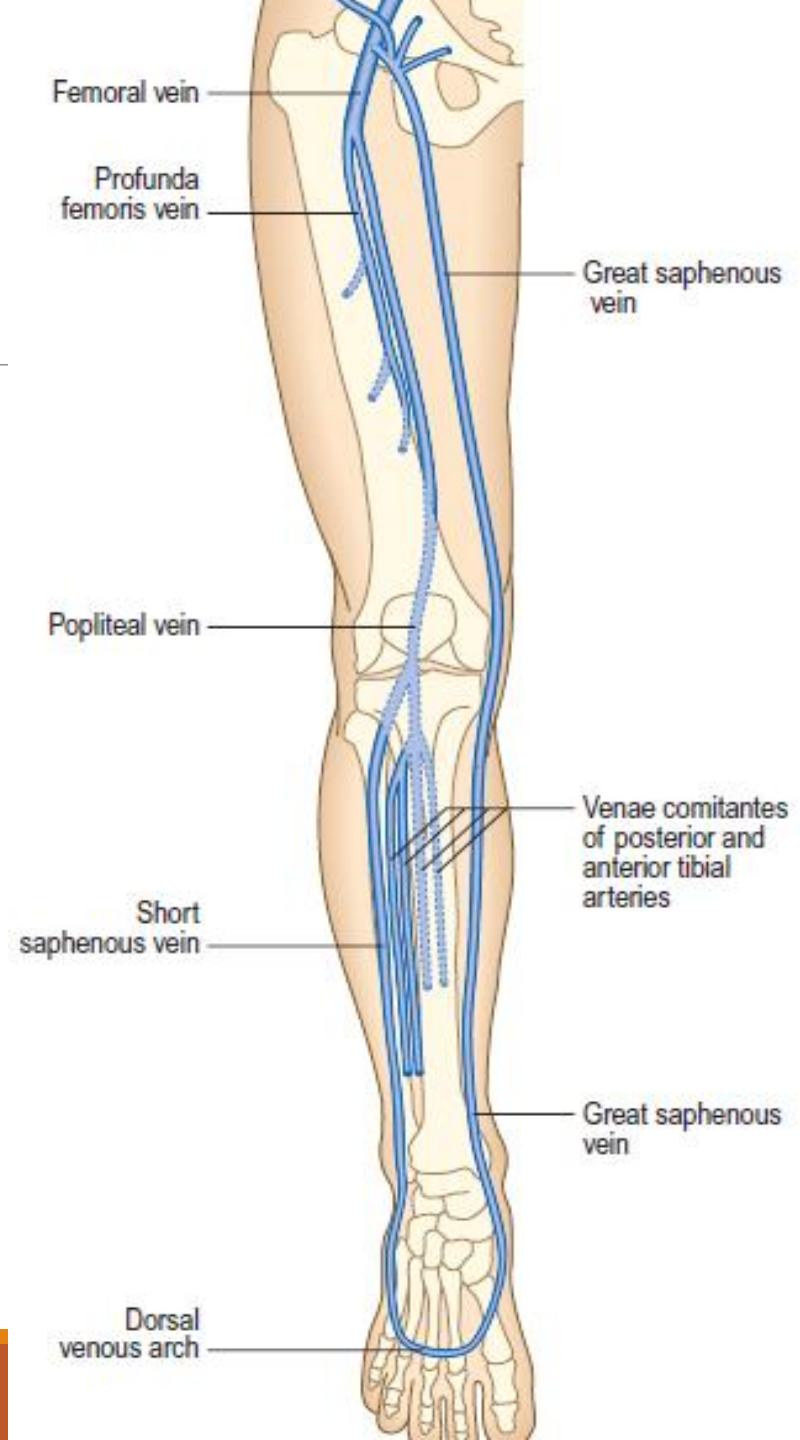
Loss of pallor & spreading redness is a positive test.



---

# Peripheral Venous System

**\* Anatomy \***



---

# Venous Return

Passive from head & neck

Active from lower limb

**( pressure on the sole of the foot + contraction of muscle ( calf , and to a lesser extent in the thighs ., buttock)**

90% through deep venous system

10% through superficial system

valves --- prevent backward flow (reflux)

The usual ambulatory venous pressure is <20 mmHg

---

**Muscle  
pump  
failure**



**Venous Diseases**

**Failure of  
valves  
function**

Primary or post  
thrombotic

**Venous HTN**



---

**Clinically the patient usually present with following**

**Varicose vein**

**Superficial thrombophlebitis**

**DVT**

**Chronic venous insufficiency & ulceration**

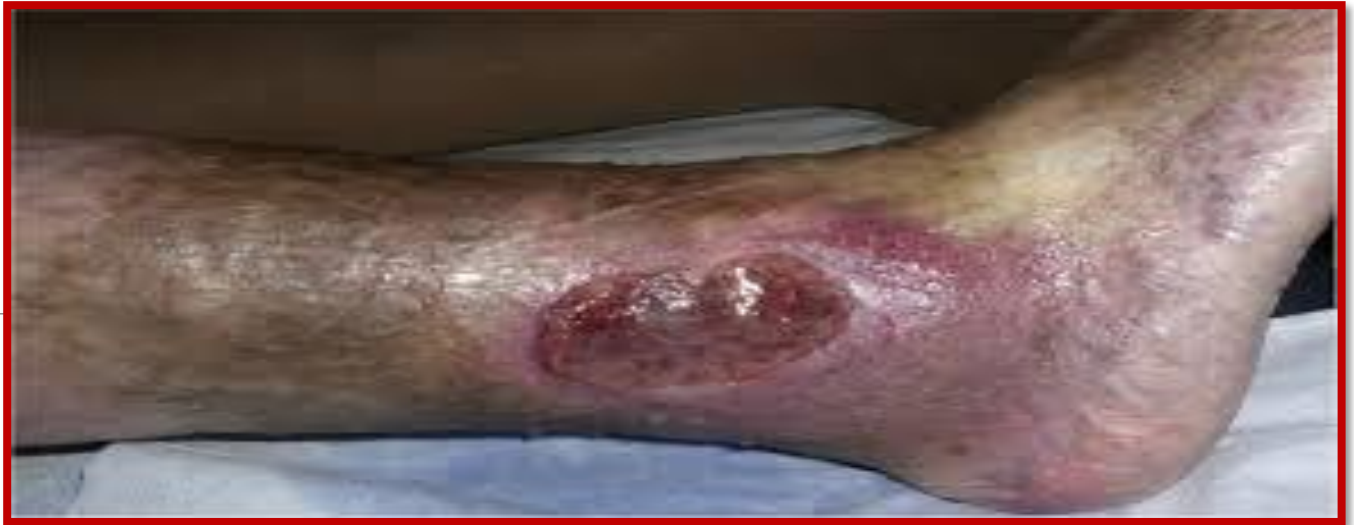---

*Pain*

*Swelling*

*Skin changes*

**varicoes eczema, hemosedrine deposition  
secondary to venous HTN, lipodrematosclerosis**



*Chronic venous ulcer*

**70-80% of lower limb ulceration**

**other causes of LL ulceration: syphilis ,TB, pyoderma gangrenosum , leprosy (Hansen's dis), sickle cell and tropical conditions**

**Medial aspect of the leg , shallow , pink(granulation tissue) or yellow/green (slough) in color ,irregular margin with surrounding skin changes of eczema and lipodermatosclerosis**

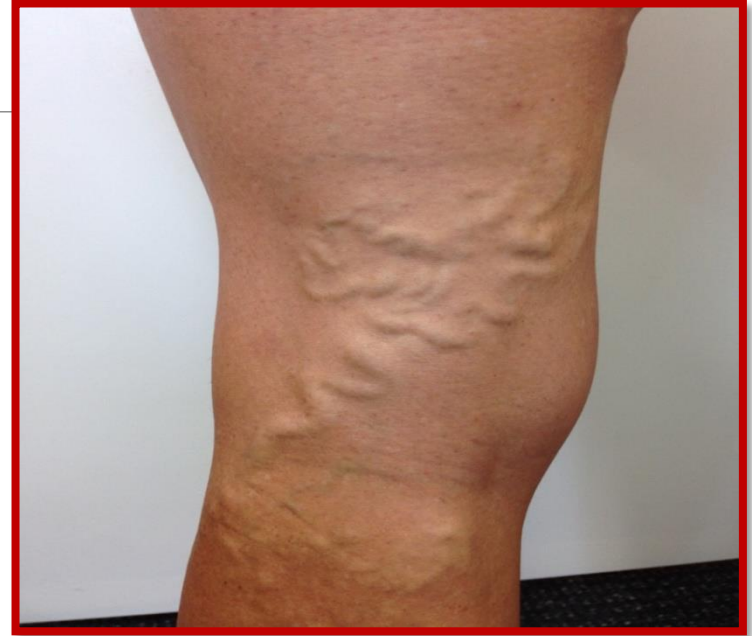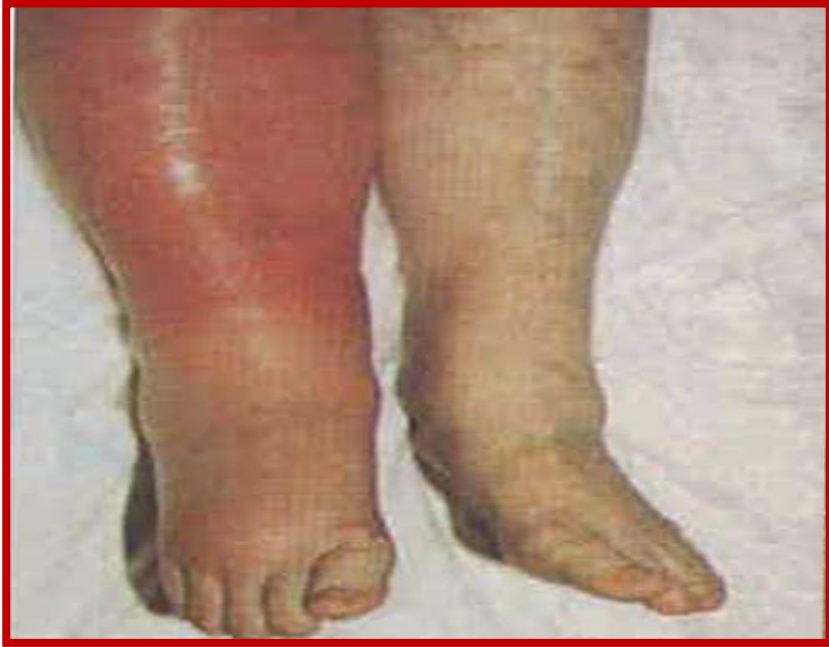---

## **superficial thrombophlebitis**

10% of sever varicoes vein , common during pregnancy

Recurrent , different area is usually associated with underlying malignancy

Risk of DVT, PE (propagation)



---

# DVT

## Upper limb

- Axillary , subclavian vein
- repetitive trauma , indwelling venous catheter , repetitive trauma at the thoracic outlet.
- pain / swelling exacerbated with exercise , skin is cyanosed and mottled

## lower limb

Risk factor .



## 6.42 Features of deep vein thrombosis of the lower limb

Clinical feature	Non-occlusive thrombus	Occlusive thrombus
Pain	Often absent	Usually present
Calf tenderness	Often absent	Usually present
Swelling	Absent	Present
Temperature	Normal or slightly increased	Increased
Superficial veins	Normal	Distended
Pulmonary embolism	High risk	Low risk



## 6.41 Clinical features of venous and arterial ulceration

Clinical feature	Venous ulceration	Arterial ulceration
Age	Develops at age 40–45 but may not present for years; multiple recurrences common	First presents in over-60s
Sex	More common in women	More common in men
Past medical history	Deep vein thrombosis (DVT) or suggestive of occult DVT, i.e. leg swelling after childbirth, hip/knee replacement or long bone fracture	Peripheral arterial disease, cardio- and cerebrovascular disease
Risk factors	Thrombophilia, family history, previous DVT	Smoking, diabetes, hypercholesterolaemia and hypertension
Pain	One-third have pain (not usually severe) that improves with elevating the leg	Severe pain, except in diabetics with neuropathy; improves on dependency
Site	Gaiter areas; usually medial to long saphenous vein; 20% are lateral to short saphenous vein	Pressure areas (malleoli, heel, fifth metatarsal base, metatarsal heads and toes)
Margin	Irregular, often with neopithelium (appears whiter than mature skin)	Regular, indolent, 'punched out'
Base	Often pink and granulating under green slough	Sloughy (green) or necrotic (black), with no granulation
Surrounding skin	Lipodermatosclerosis always present	No venous skin changes
Veins	Full and usually varicose	Empty with 'guttering' on elevation
Swelling (oedema)	Usually present	Absent
Temperature	Warm	Cold
Pulses	Present, but may be difficult to feel	Absent

# examination

---

**General inspection for patient condition + risk factor**

**While the patient standing , lying supine**

**Leg inspection**

**For skin color changes / swelling / dilated vein**

**Palpation : temperature / tenderness/ pitting edema/ leg circumference ( 10 cm below tibial tuberosity ).**

**Edema → check the JVP( bilateral edema with raised JVP suggest cardiac disease or pulmonary HTN)**