

Musculoskeletal System



General Principles

To know about :

- **Gross anatomy**
- **Common presenting symptoms**
- **Extra-articular symptoms**
- **Completing the History** “Past Medical, Surgical, Drug, Family, Social , environmental and occupational histories”.
- **Physical examination.**

- LOOK, FEEL, MOVE, SPECIAL TESTS.
- Observe the general appearance.
- Do NOT cause additional pain.
- Compare both sides.
- Active before passive movements.
- Use the standard terminology.

The Human Skeleton

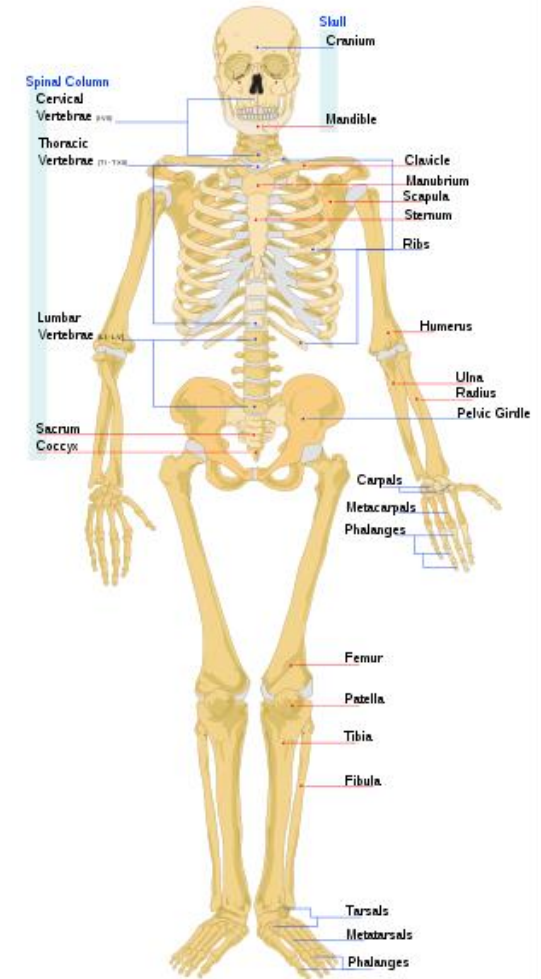
How many bones?



The Human Skeleton

How many bones?

206 Bones: 126 Appendicular
 80 Axial



Gross Anatomy

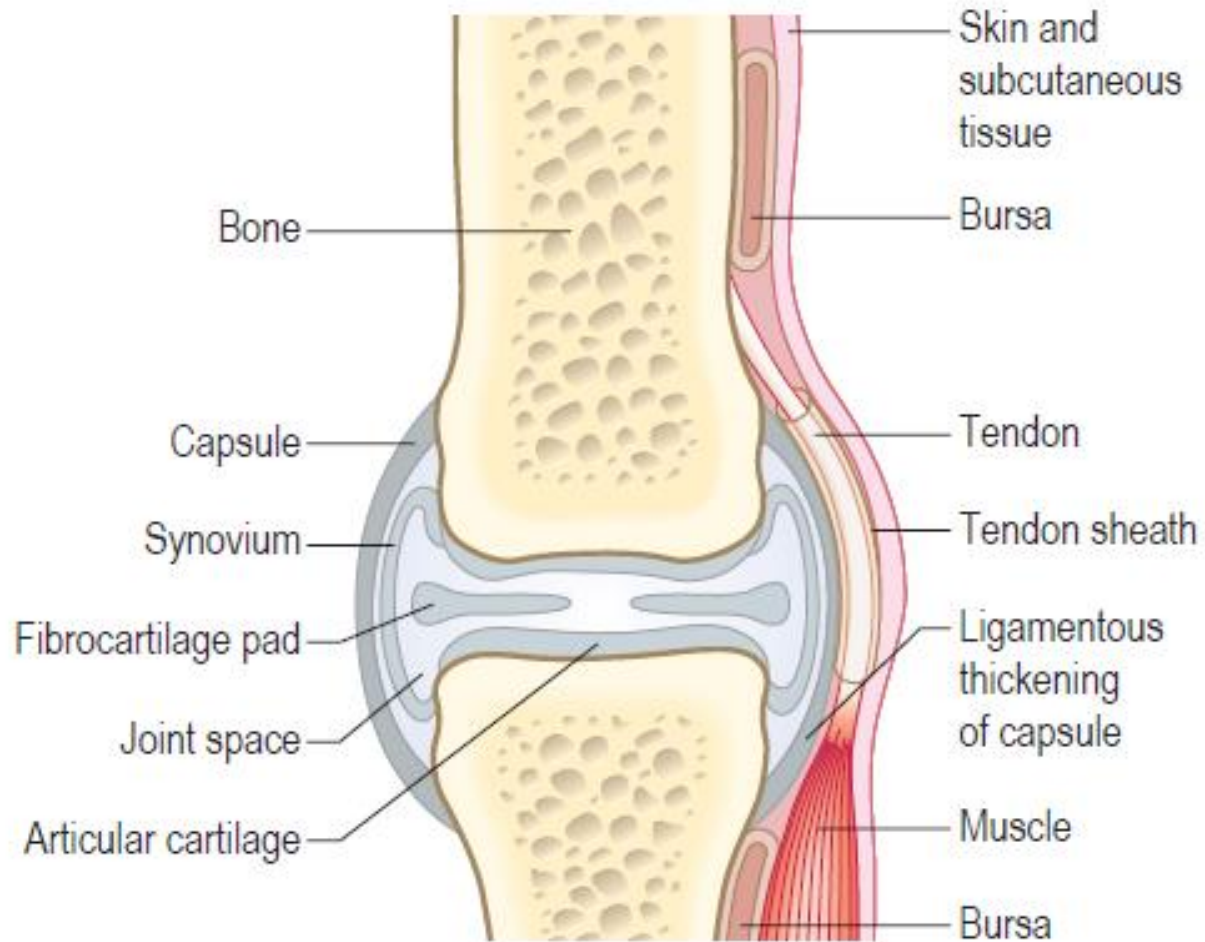


Fig. 13.1 Structure of a joint and surrounding tissues.

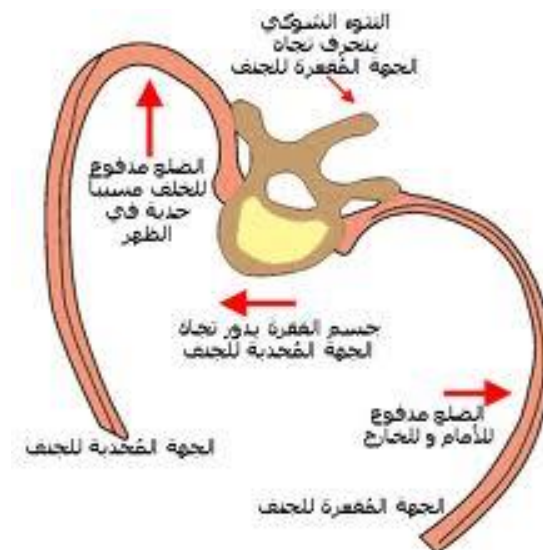
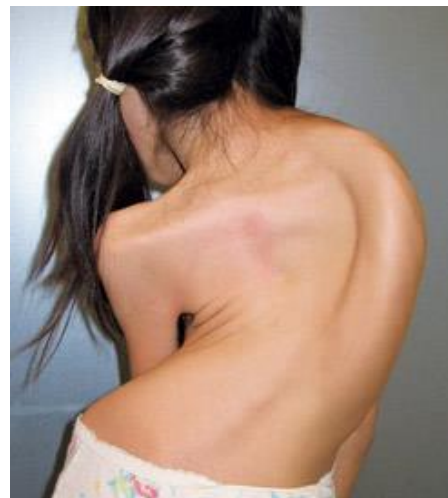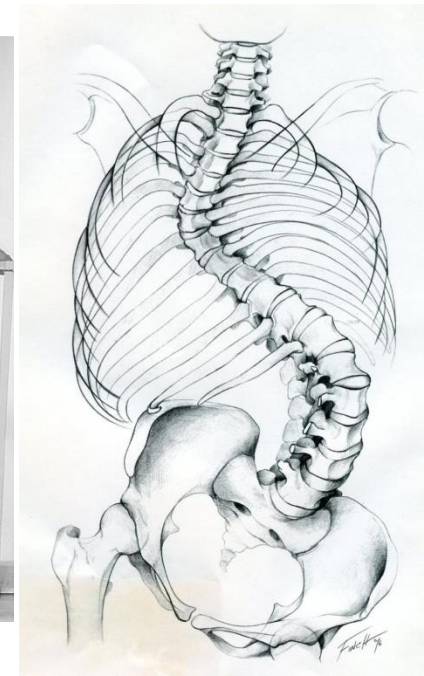
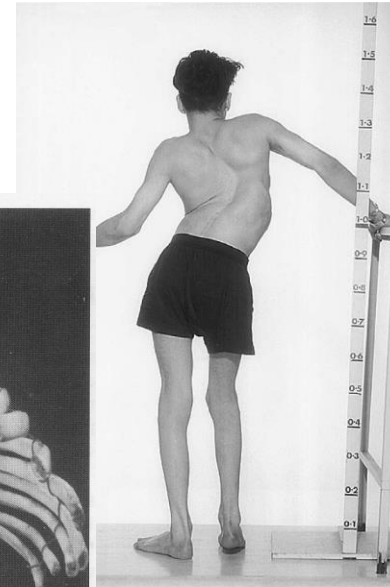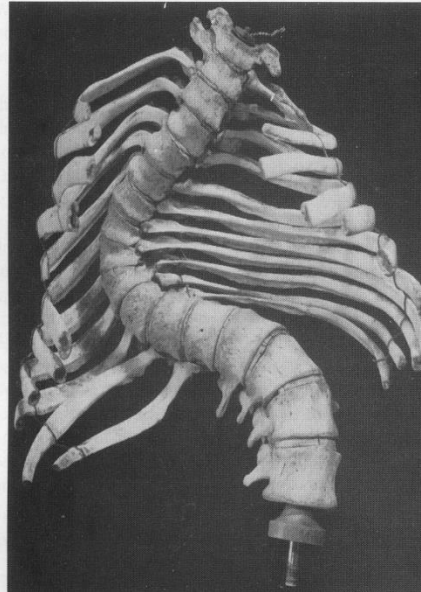
Nomenclature

Scoliosis

Kyphosis

Lordosis

Gibbus



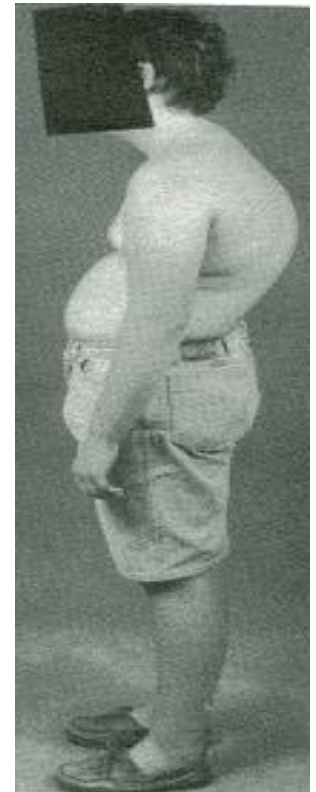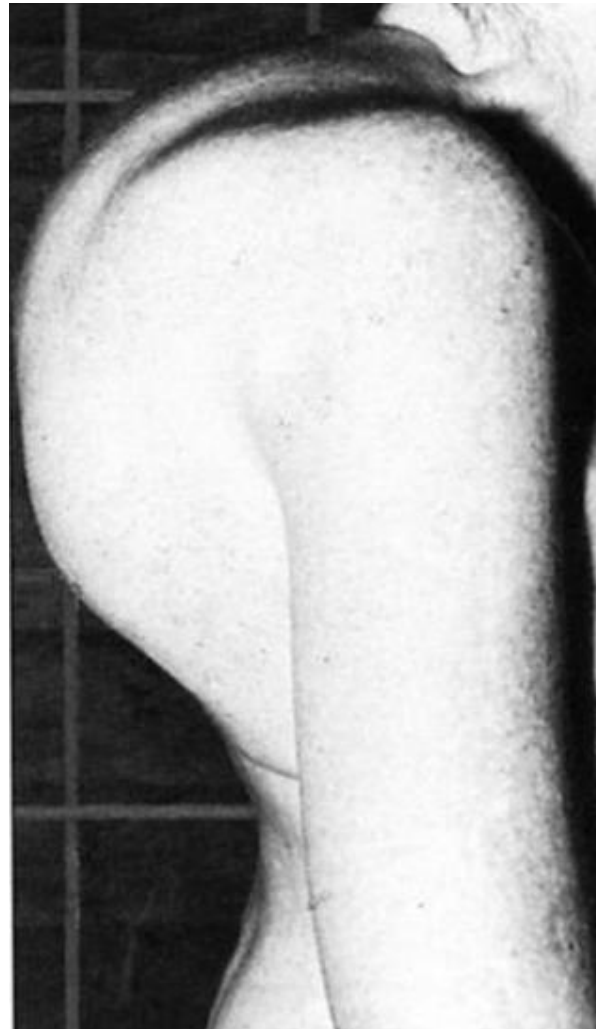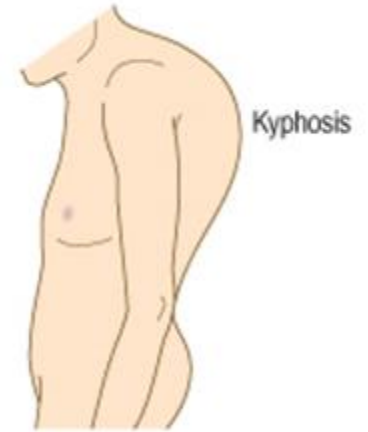
Nomenclature

Scoliosis

Kyphosis

Lordosis

Gibbus



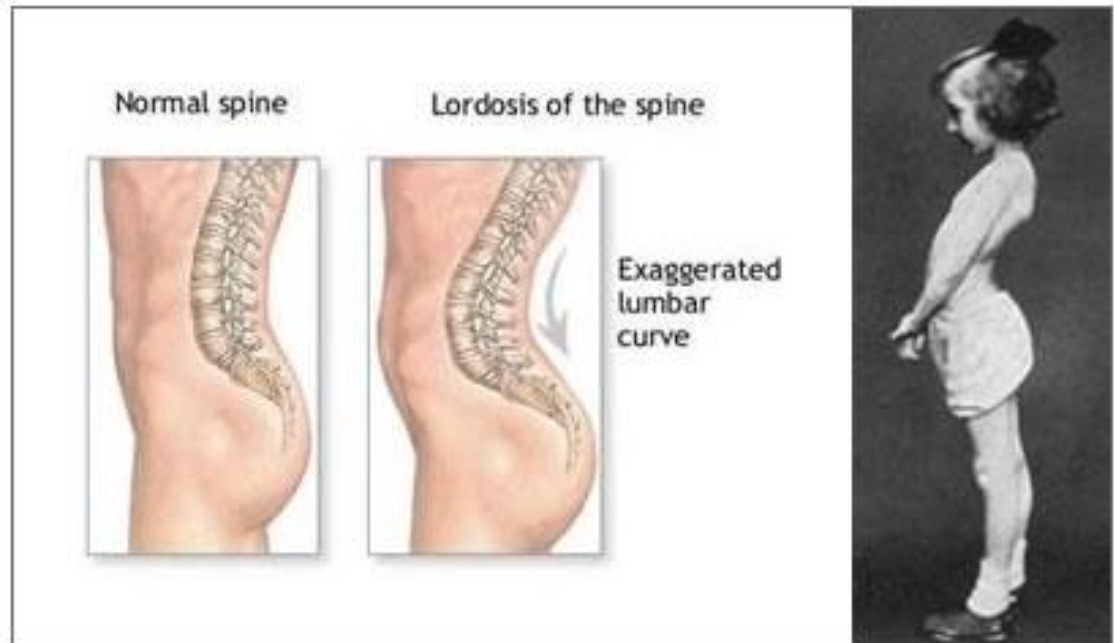
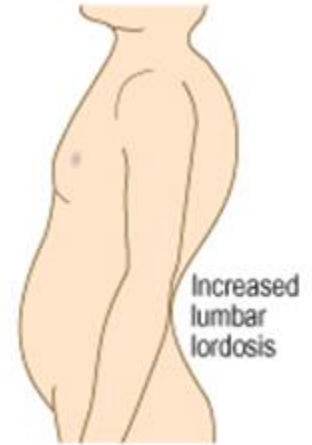
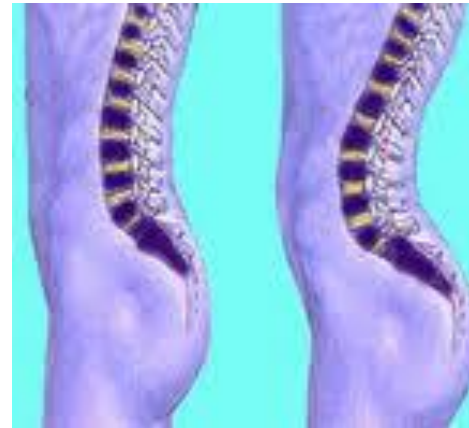
Nomenclature

Scoliosis

Kyphosis

Lordosis

Gibbus



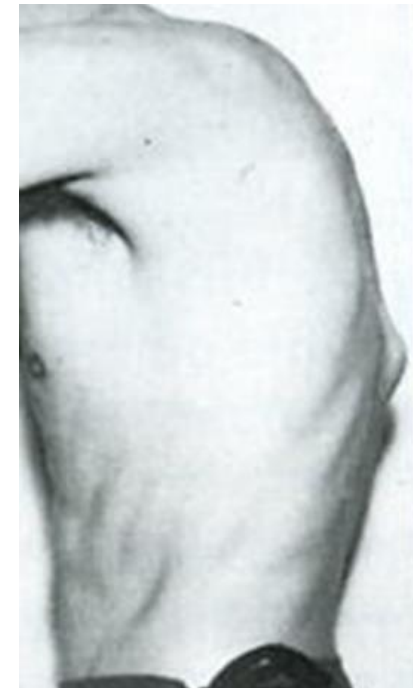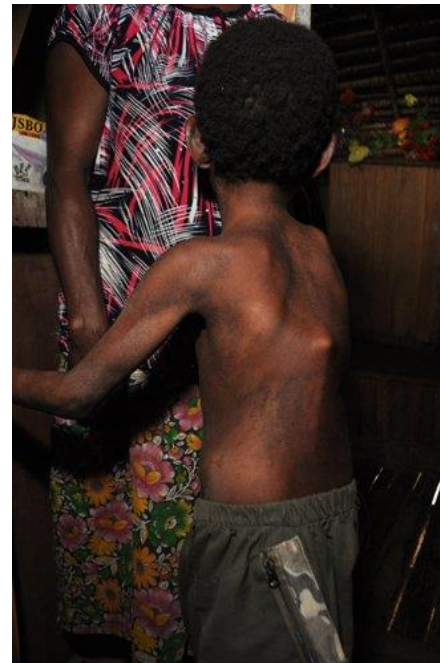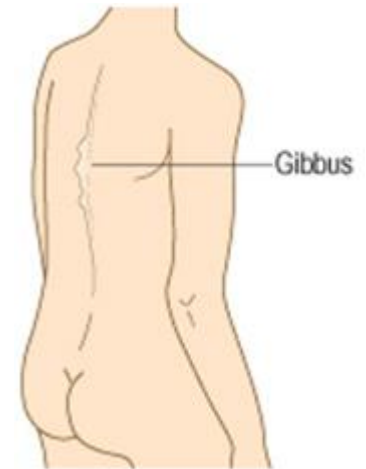
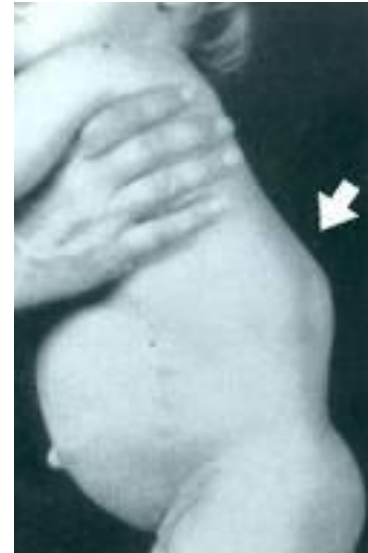Nomenclature

Scoliosis

Kyphosis

Lordosis

Gibbus



History Taking

Common presenting symptoms

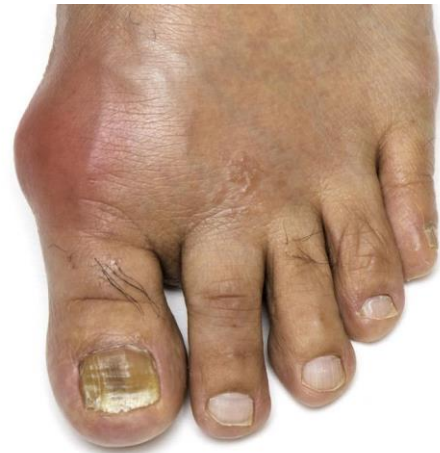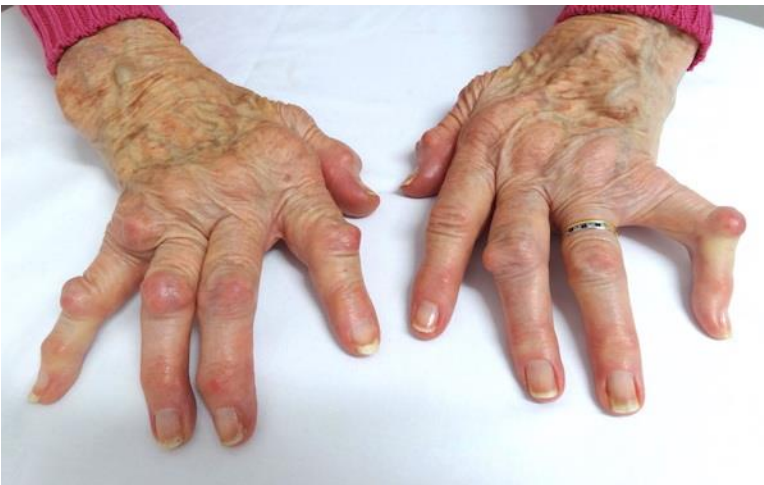- **Pain**
- **Stiffness**
- **Swelling**
- **Erythema and warmth**
- **Locking and triggering**
- **Extra-articular symptoms**

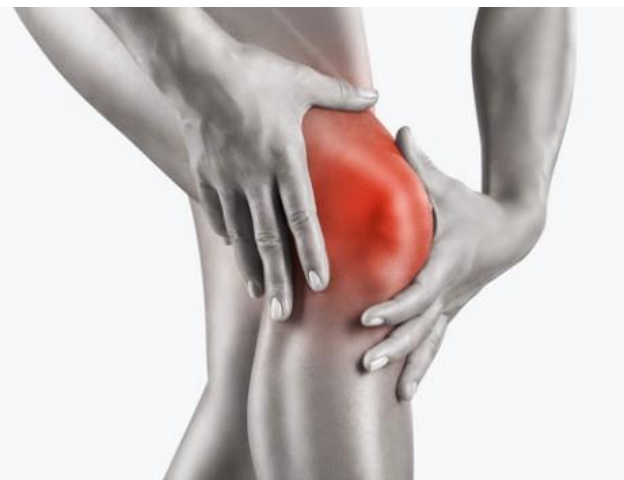Pain

- Site
- Onset
- Character
- Radiation
- Associated symptoms
- Timing
- Exacerbating and relieving factors
- Severity

Site

- The involved Component :
Joint , Muscles ,Bone, Tendons and Ligaments
- Local or multiple involvement





13.1 Common causes of arthralgia (joint pain)

Infective

- Viral, e.g. rubella, parvovirus B19, mumps, hepatitis B, chikungunya
- Bacterial, e.g. staphylococci, *Mycobacterium tuberculosis*, *Borrelia*
- Fungal

Postinfective

- Rheumatic fever
- Reactive arthritis

Inflammatory

- Rheumatoid arthritis
- Systemic lupus erythematosus
- Ankylosing spondylitis
- Systemic sclerosis

Degenerative

- Osteoarthritis

Tumour

- Primary, e.g. osteosarcoma, chondrosarcoma
- Metastatic, e.g. from lung, breast, prostate
- Systemic tumour effects, e.g. hypertrophic pulmonary osteoarthropathy

Crystal formation

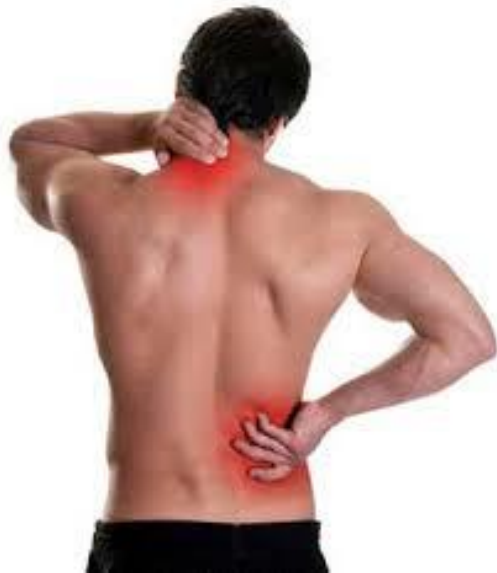- Gout, pseudogout

Trauma

- e.g. Road traffic accidents

Others

- Chronic pain disorders, e.g. fibromyalgia (usually diffuse pain)
- Benign joint hypermobility syndrome



13.2 Causes of muscle pain (myalgia)

Infective

- Viral: Coxsackie, cytomegalovirus, echovirus, dengue
- Bacterial: *Streptococcus pneumoniae*, *Mycoplasma*
- Parasitic: schistosomiasis, toxoplasmosis

Traumatic

- Tears
- Haematoma
- Rhabdomyolysis

Inflammatory

- Polymyalgia rheumatic
- Myositis
- Dermatomyositis

Drugs

- Alcohol withdrawal
- Statins
- Triptans

Metabolic

- Hypothyroidism
- Hyperthyroidism
- Addison's disease
- Vitamin D deficiency

Neuropathic

Onset



- Immediate : traumatic type
- Quickly and overnight : crystal type
- Within 24 hours : Inflammatory type
- More than 24 hours : septic type

Character :

- Localized pain : tumor ,osteomyelitis , osteonecrosis
- Diffuse pain: eg: osteomalacia
- Bone pain: penetrating, deep and boring mainly at night
- Muscle pain: stiffness and aching mainly with movement
- Nerve pain : shooting caused by peripheral nerve or nerve root impingement
- Fracture pain: sharp and stabbing ,↑ by movement and relieved by rest
- Progressive pain: eg: degenerative type
- Constant with diurnal variation : eg: Fibromyalgia (chronic pain syndrome)

Radiation :

Pain from nerve compression radiates to the distribution of that nerve or nerve root such as :

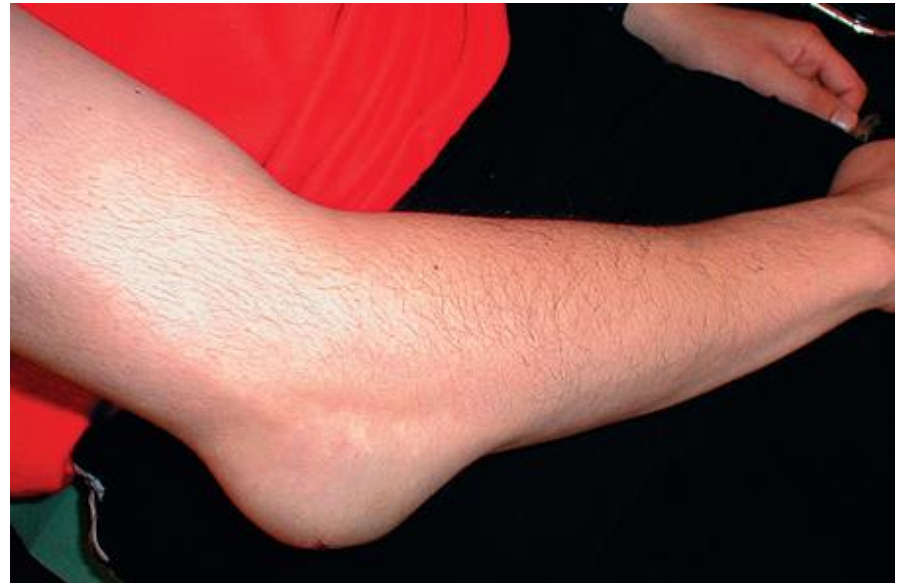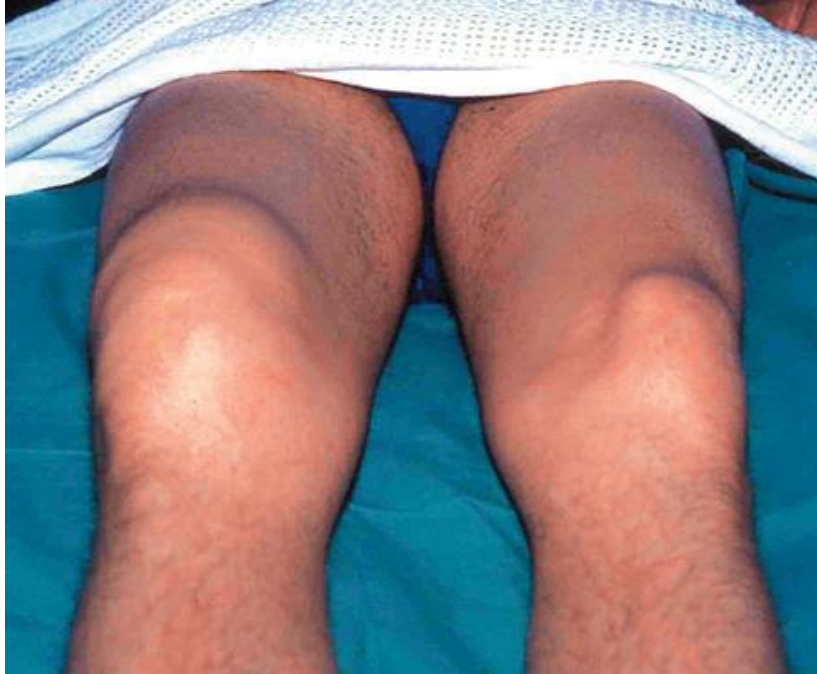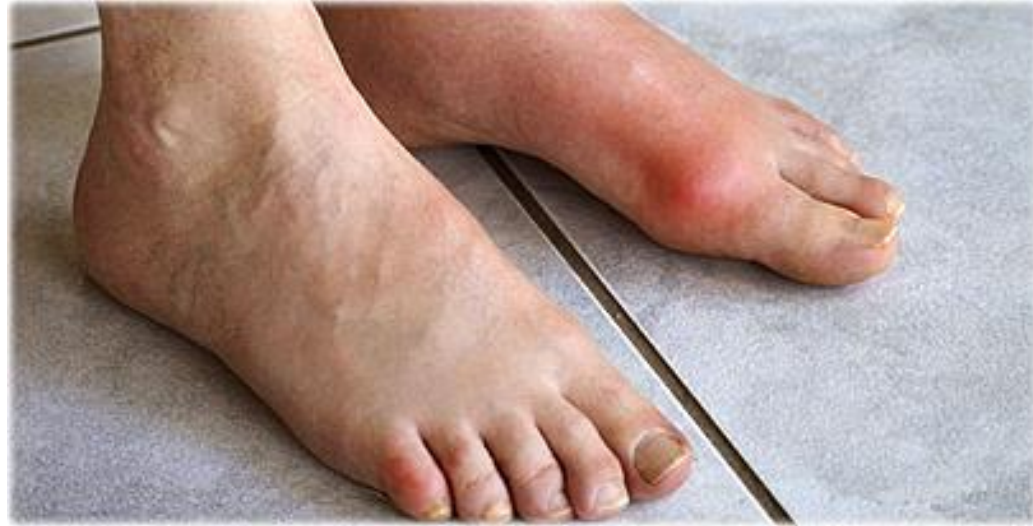- **Lower leg pain** in inter-vertebral disc prolapse.
- **Hand pain** in carpal tunnel syndrome.
- **Neck pain** radiates to the shoulder or scalp.
- **Hip pain** is usually felt in the groin but may radiate to the thigh or knee.

Radiation

13.3 Common patterns of referred and radicular musculoskeletal pain	
Site where pain is perceived	Site of pathology
Occiput	C1, 2
Interscapular region	C3, 4
Tip of shoulder, upper outer aspect of arm	C5
Interscapular region or radial fingers and thumb	C6, 7
Ulnar side of forearm, ring and little fingers	C8
Medial aspect of upper arm	T1
Chest	Thoracic spine
Buttocks, knees, legs	Lumbar spine
Lateral aspect of upper arm	Shoulder
Forearm	Elbow
Anterior thigh, knee	Hip
Thigh, hip	Knee

Associated Symptoms:

- Swelling
- Redness



Timing : Frequency ,duration and periodicity of symptoms

- Intermittent with resolution between episodes
→ palindromic rheumatism.
- Flitting pain over a period of days → rheumatic fever and gonococcal arthritis
- Several weeks of early-morning stiffness → inflammatory arthritis.
- Several years of pain with normal examination → Fibromyalgia.

Exacerbating /Relieving factor :

Worsen at rest → inflammatory arthritis

Worsen with exercise → osteoarthritic derangement

Both → Septic joint

Severity :

- Severe pain → Trauma , Crystal and septic arthritis

- Disproportionate pain to examination :

{ Acute : Compartment syndrome

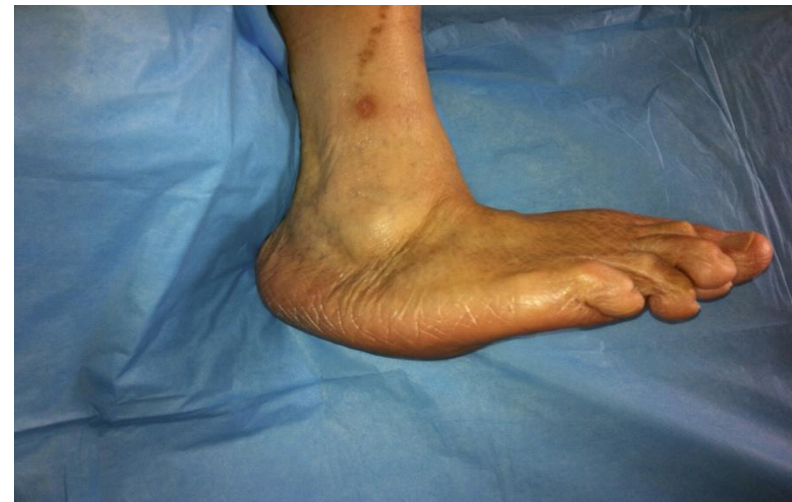{ Chronic : complex regional pain syndrome

- Pain free but severe deformity:

(neurological involvement)

eg: DM, Syphillis

Charcot joint (severe form)



Patterns of joint involvement

Definitions :

Monoarthritis : one Joint

Oligoarthritis : 2-4 Joints

Polyarthritis : > 4 Joints

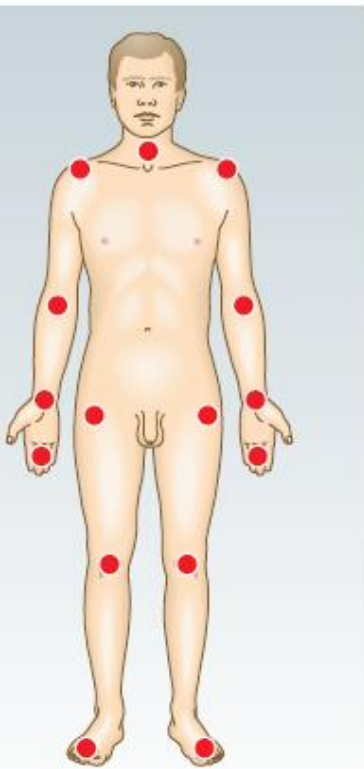
Notes :

Hand and feet small joint → Inflammatory arthritis

Medium or large joint → Degenerative and
seronegative arthritis

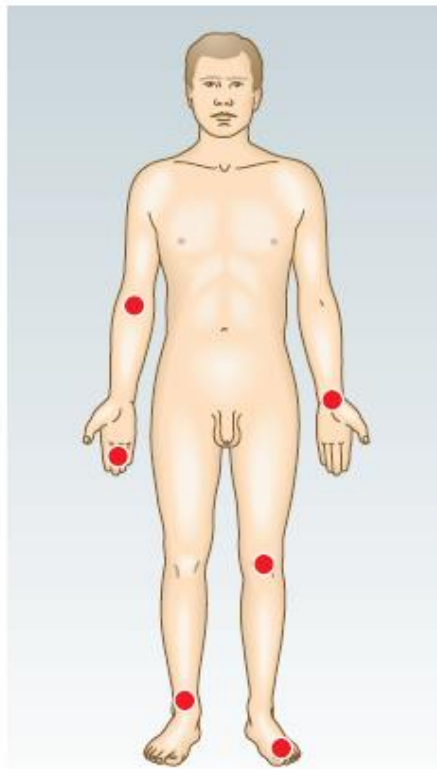
DIP and CMC joint of the thumb → Nodal arthritis

Contrasting patterns of joint involvement in polyarthritis.



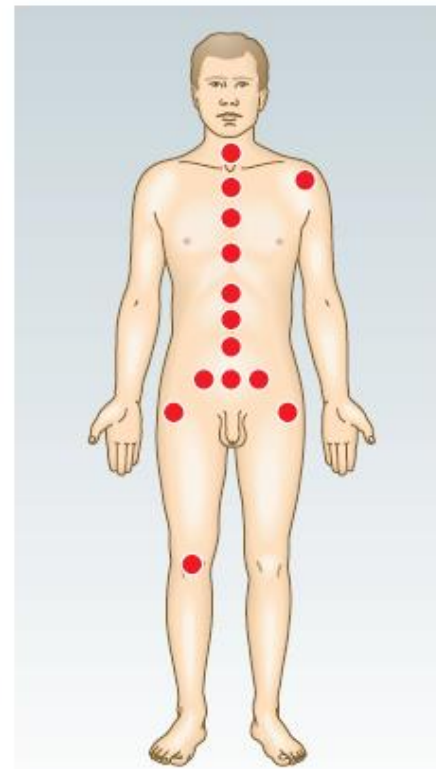
Rheumatoid arthritis

A



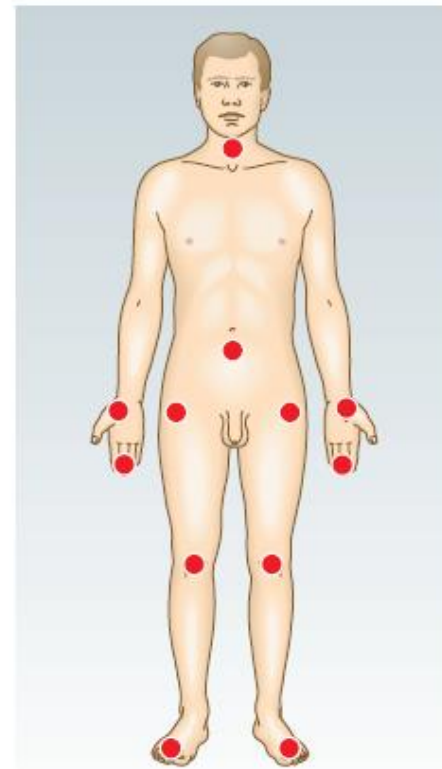
Psoriatic arthritis

B



Axial spondyloarthritis

C



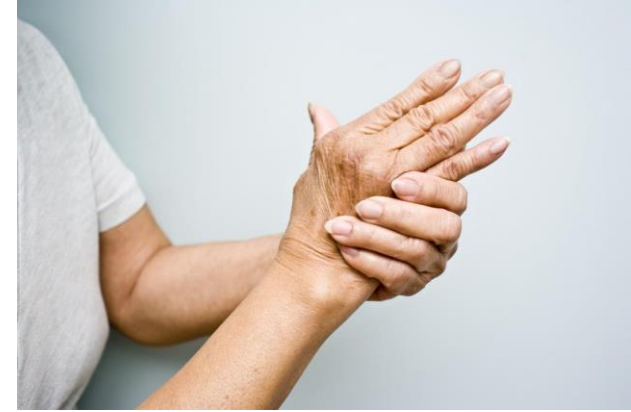Osteoarthritis

D

Stiffness :

Ask if is it:

- Restricted range of movement?
- Difficulty moving, but with a normal range?
- Painful movement?
- Localized to a particular joint or more generalized?



Inflammatory type: early morning stiffness for 30 minutes which wears off with activity

Mechanical type : stiffness after rest

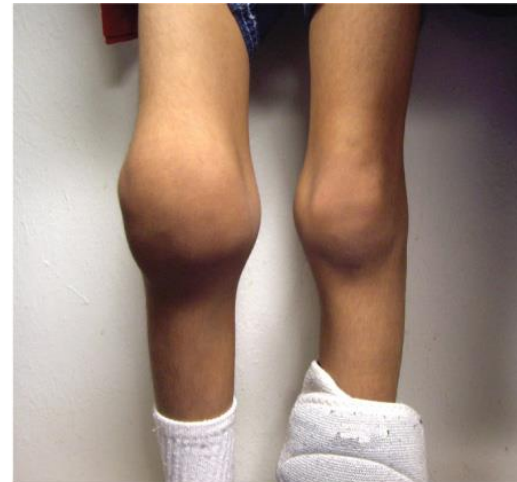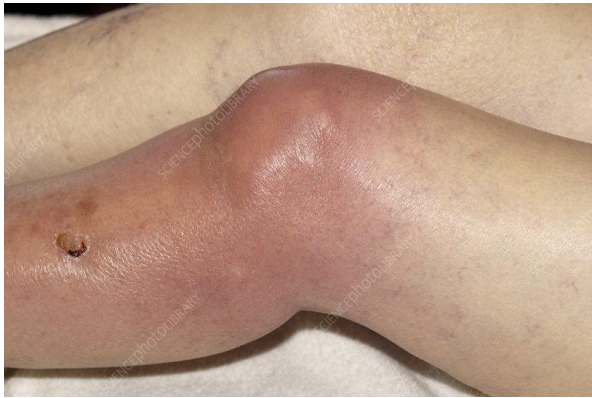Polymyalgia rheumatica : mainly shoulder and pelvic stiffness.

Swelling :

Rapid over 30min → haemarthrosis

Over few hours (marked swelling) → Septic joint

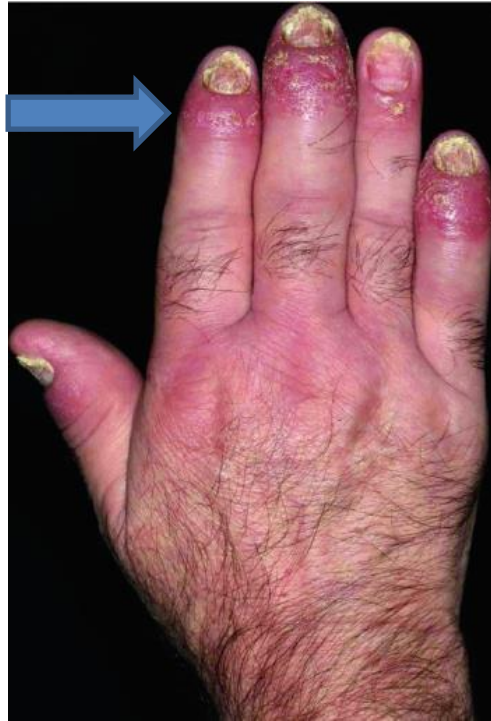
Over hours to days → traumatic effusion (meniscus and cartilaginous)



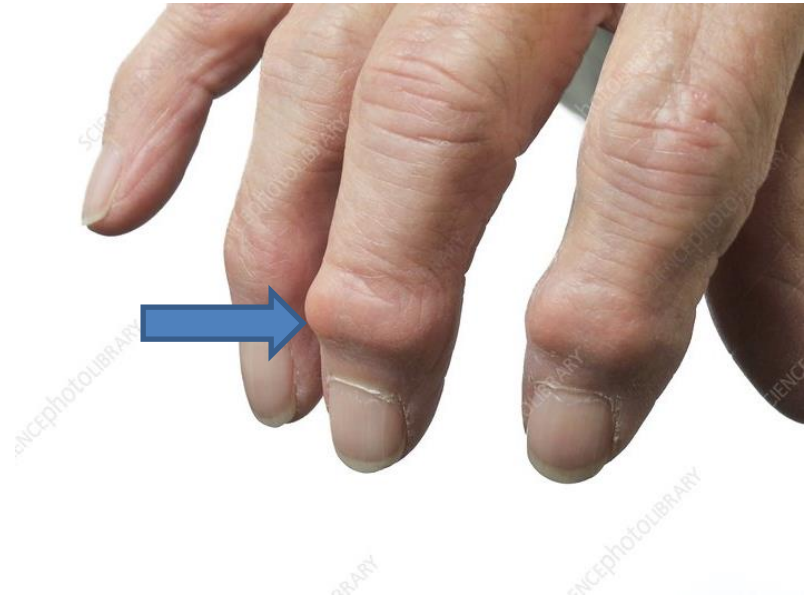
N.B : - Corticosteroids and NSAID modify these features

- Crystal- induced arthritis starts overnight and on early morning

Erythema and warmth : almost in all types of arthritis



Psoritic arthritis



Heberden's nodes of Osteoarthritis

Weakness:

Joint disorder → Pain or structure disruption

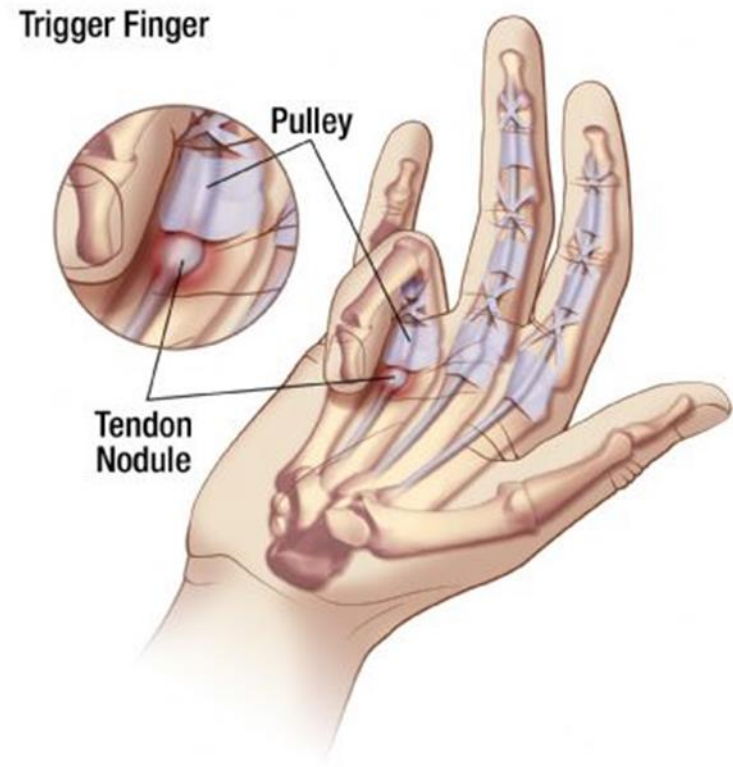
Nerve disorder → entrapment eg : CTS

Muscle disorder → widespread with pain and fatigue

N.B : proximal muscle weakness can be caused by endocrine disorders

Locking and triggering :

- **True locking** (incomplete range of motion) : mechanical causes
- **Pseudo-locking**: due to pain
- **Triggering** (block to extension of finger which gives suddenly forced extension)



13.5 Extra-articular signs in rheumatic conditions

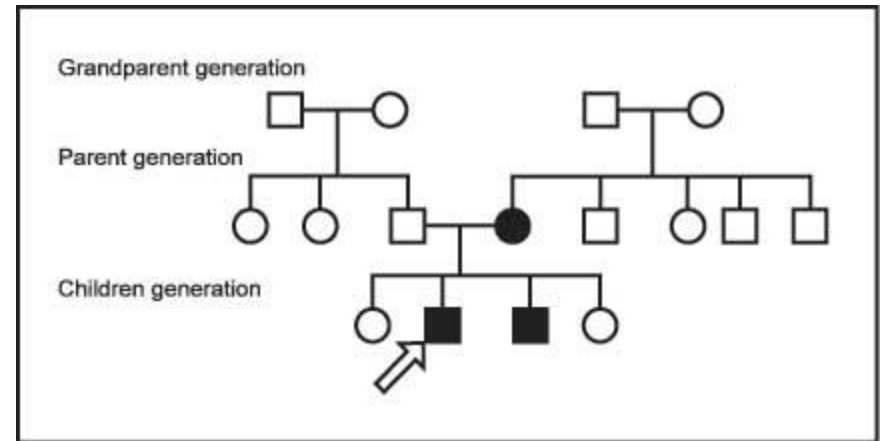
Condition	Extra-articular signs
Rheumatoid arthritis	Rheumatoid nodules, palmar erythema, episcleritis, dry eyes, interstitial lung disease, pleural ± pericardial effusion, small-vessel vasculitis, Raynaud's phenomenon, low-grade fever, weight loss, lymphadenopathy, splenomegaly, leg ulcers
Psoriatic arthritis	Psoriasis, nail pitting, onycholysis, enthesitis, dactylitis
Reactive arthritis	Urethritis, mouth and/or genital ulcers, conjunctivitis, iritis, enthesitis (inflammation of tendon or ligament attachments), e.g. Achilles enthesitis/plantar fasciitis, rash (keratoderma blenorrhagica)
Axial spondyloarthritis	Inflammatory bowel disease, psoriasis, enthesitis, iritis, aortic regurgitation, apical interstitial fibrosis
Septic arthritis	Fever, malaise, source of sepsis, e.g. skin, throat, gut
Gout	Tophi, signs of renal failure or alcoholic liver disease
Sjögren's syndrome	'Dry eyes' (keratoconjunctivitis sicca), xerostomia (reduced or absent saliva production), salivary gland enlargement, Raynaud's phenomenon, neuropathy
Systemic lupus erythematosus	Photosensitive rash, especially on face, mucocutaneous ulcers, alopecia, fever, pleural ± pericardial effusion, diaphragmatic paralysis, pulmonary fibrosis (rare), Raynaud's phenomenon, lymphopenia
Systemic sclerosis	Skin tightening (scleroderma, see Fig. 3.30C), telangiectasia, Raynaud's phenomenon, calcific deposits in fingers, dilated nail-fold capillaries, pulmonary fibrosis
Adult-onset Still's disease	Rash, fever, hepatomegaly, splenomegaly
Other	Erythema nodosum of shins in sarcoidosis, viral rashes, drug rashes

- Past medical history : previous attacks , DM
- Drug history :

13.7 Drugs associated with adverse musculoskeletal effects

Drug	Possible adverse musculoskeletal effects
Glucocorticoids	Osteoporosis, myopathy, osteonecrosis, infection
Statins	Myalgia, myositis, myopathy
Angiotensin-converting enzyme inhibitors	Myalgia, arthralgia, positive antinuclear antibody
Antiepileptics	Osteomalacia, arthralgia
Immunosuppressants	Infections
Quinolones	Tendinopathy, tendon rupture

Family history :



- First degree relative : inflammatory type
- Variable polygenic fashion : osteoarthritis, osteoporosis and gout
- HLA B27: spondyloarthritis
- Single gene defect : Marfan's syndrome , Ehlers-Danlos syndrome

Social , environmental and occupational history :

- How does the condition affect the patient's activities of daily living, such as washing, dressing and toileting?
- Can they use the stairs and do they need walking aids? Ask about functional independence, especially cooking, shopping and housework.
- Ask about current and previous occupations. Is the patient working full- or part-time, on sick leave or receiving benefits?
- Has the patient had to take time off work because of the condition and is their job at risk?



Ask about :

- Smoking
- High alcohol intake
- Certain ethnic groups (SCD , osteomalacia,TB)
- A sexual history (STD)

SCD : sickle cell disease

STD: sexual transmitted diseases



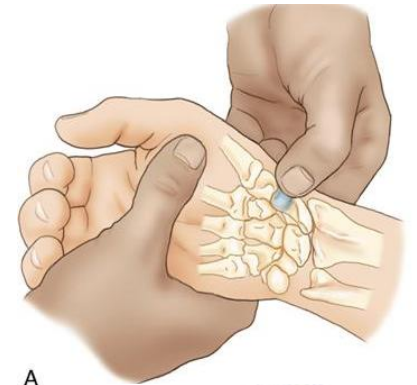
Physical examination

- 1) Examine the patient's overall appearance for features such :
 - Pallor, rash, skin tightening and hair changes.
 - Special postures
 - Weight loss ,muscle loss , fever and lymphadenopathy

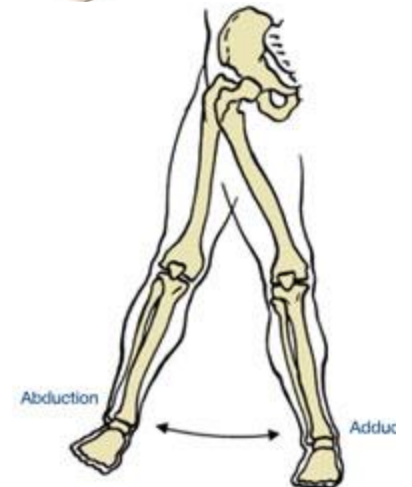
- 2) Use Look , Feel and move method

Physical examination

- Look (inspect for any deformity and abnormality)
- Feel (palpate each structure)
- Move (active and passive)

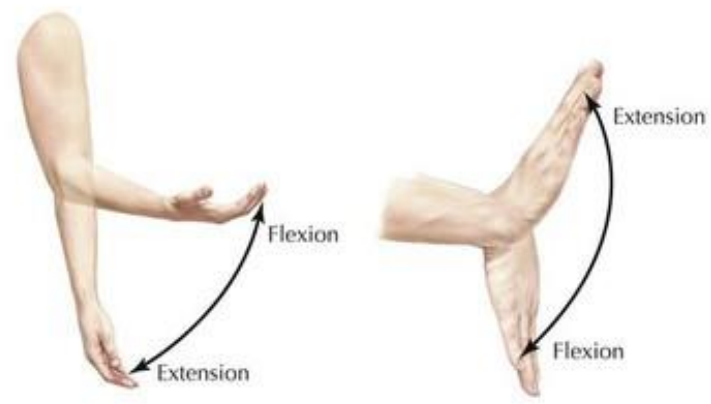
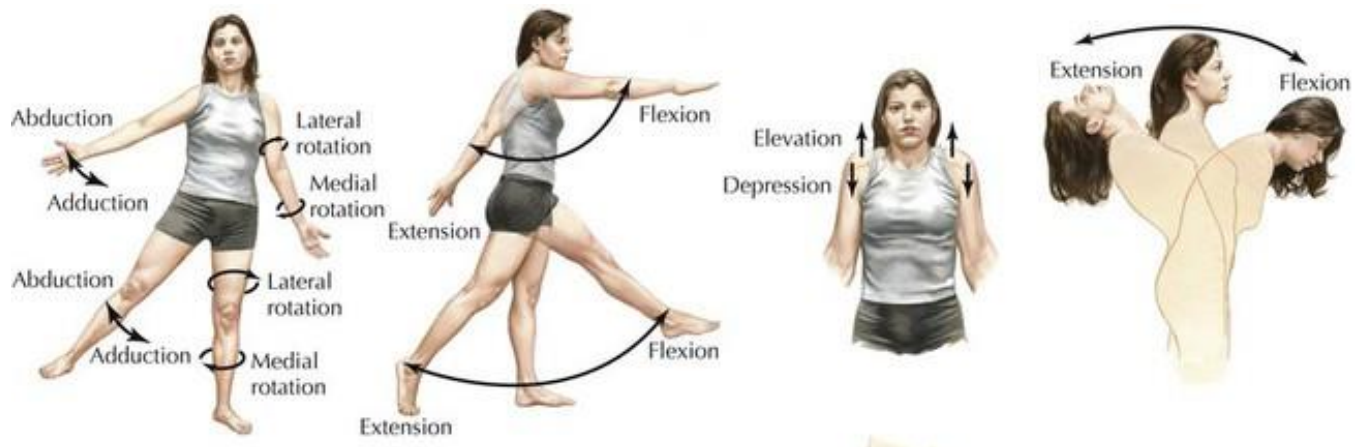


A

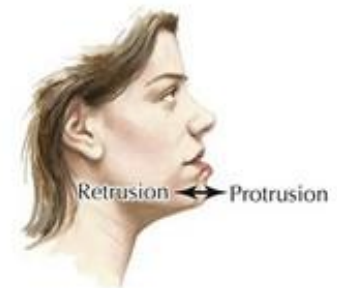


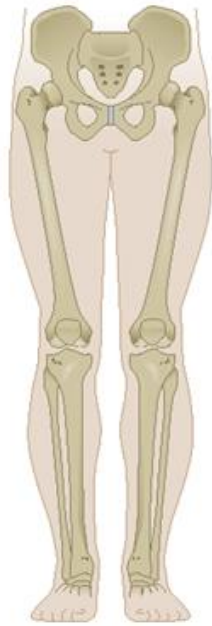- Look at the skin, subcutaneous tissues and bony outline of each area.
- **Before palpating**, ask the patient which area is painful or tender. Feel for warmth, swelling, stability and deformity. Assess if deformity is reducible or fixed
- Assess **active** before **passive** movement.
- **Compare** one limb with the opposite side.
- Always expose the joint **above and below** the affected one



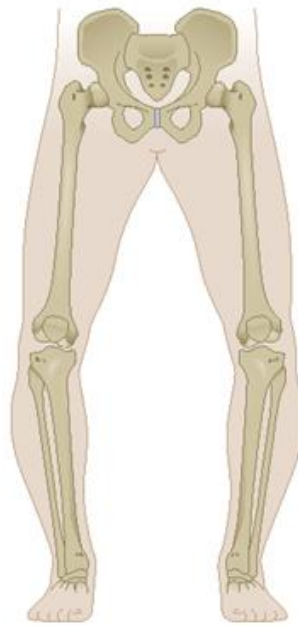


C. Machado
— M.D.

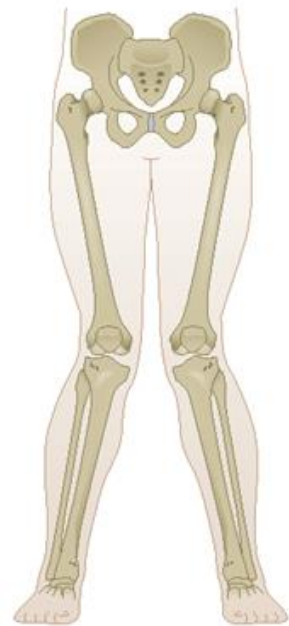



Normal

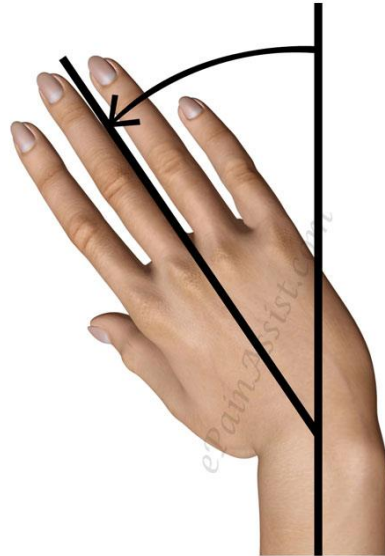


Varus

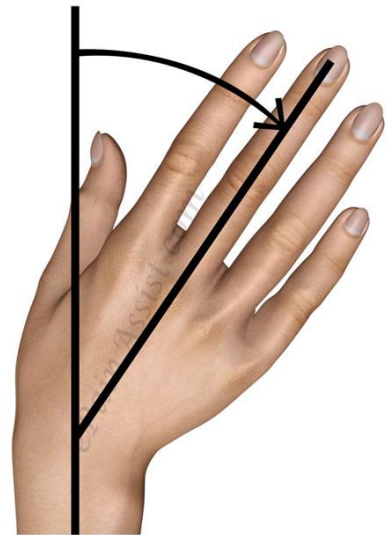


Knock knees (valgus)

ePainAssist.com



Radial Deviation

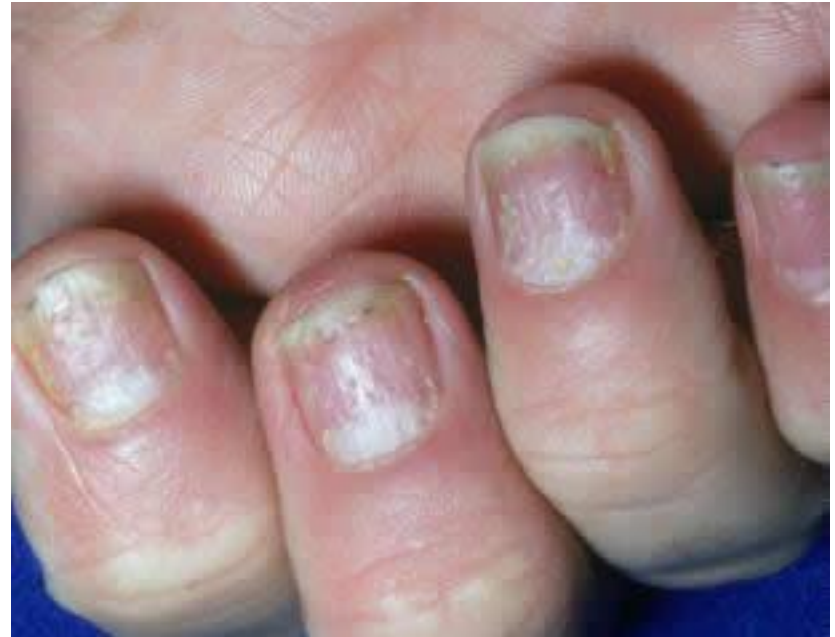
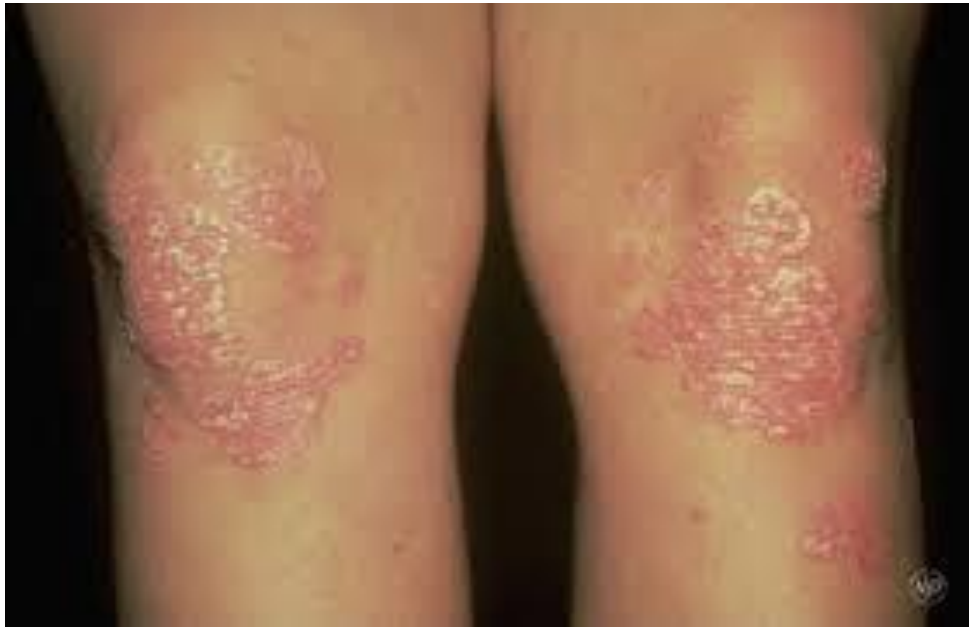
Ulnar Deviation

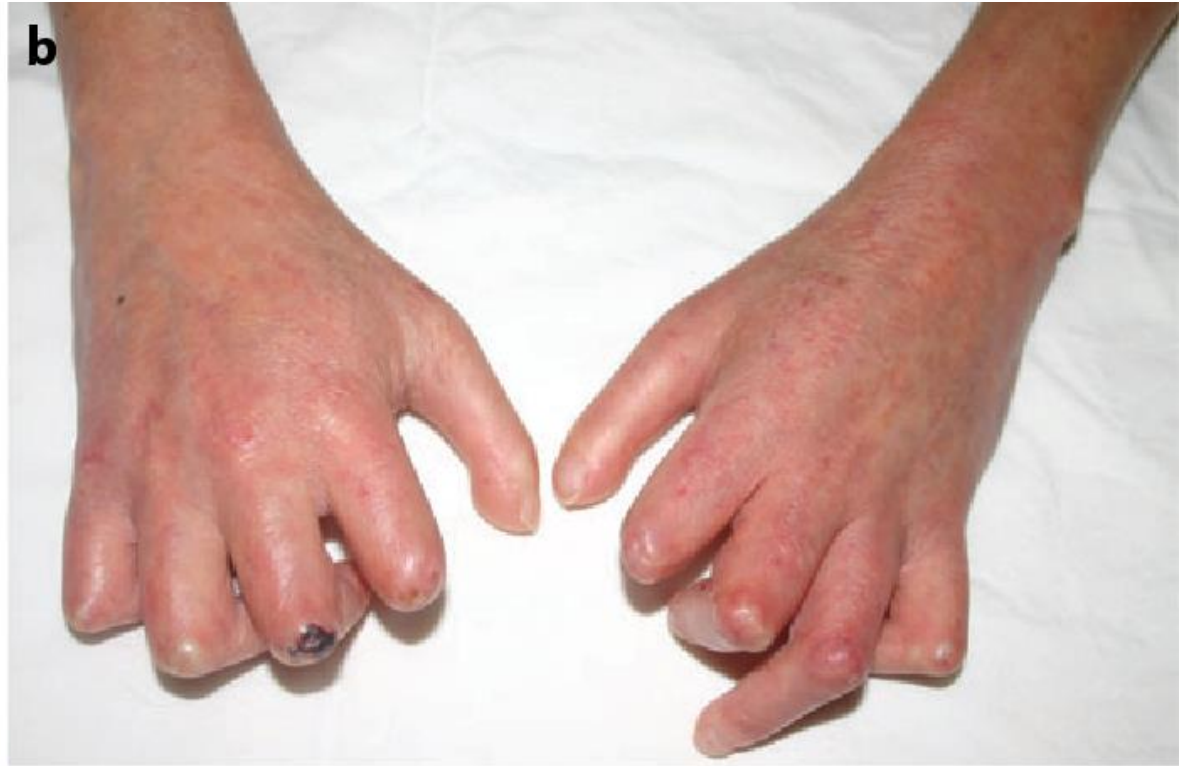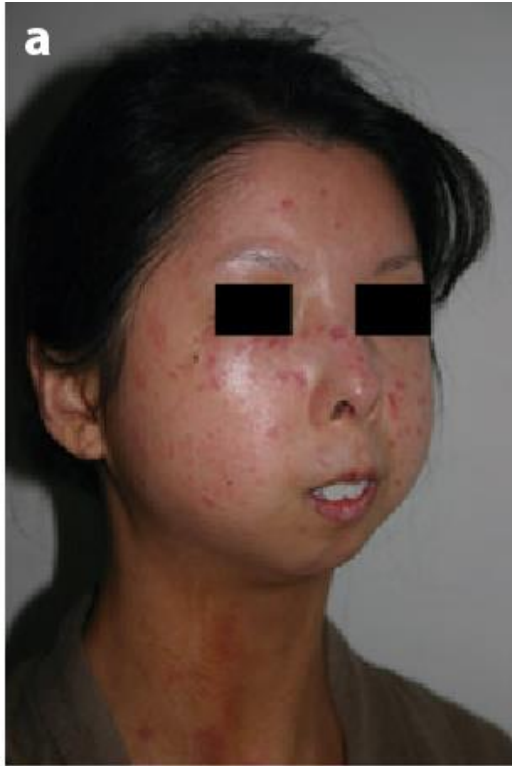Skin, nail and soft tissues :

General hints

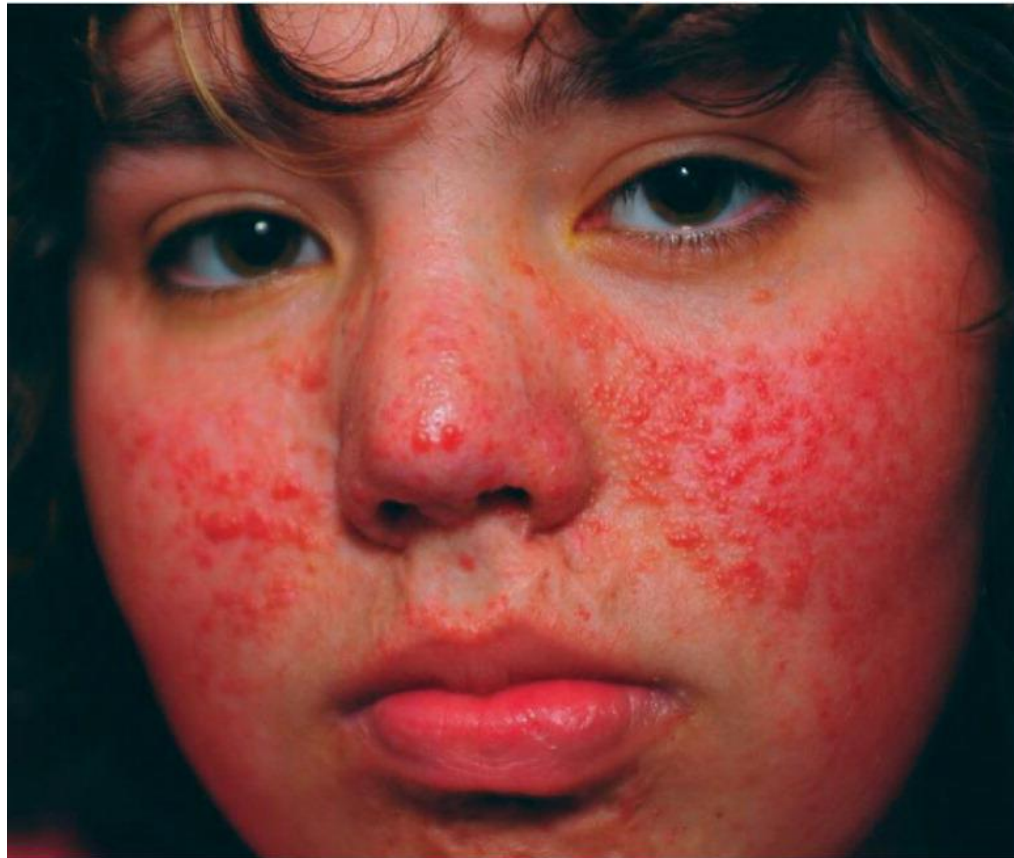Psoriasis :



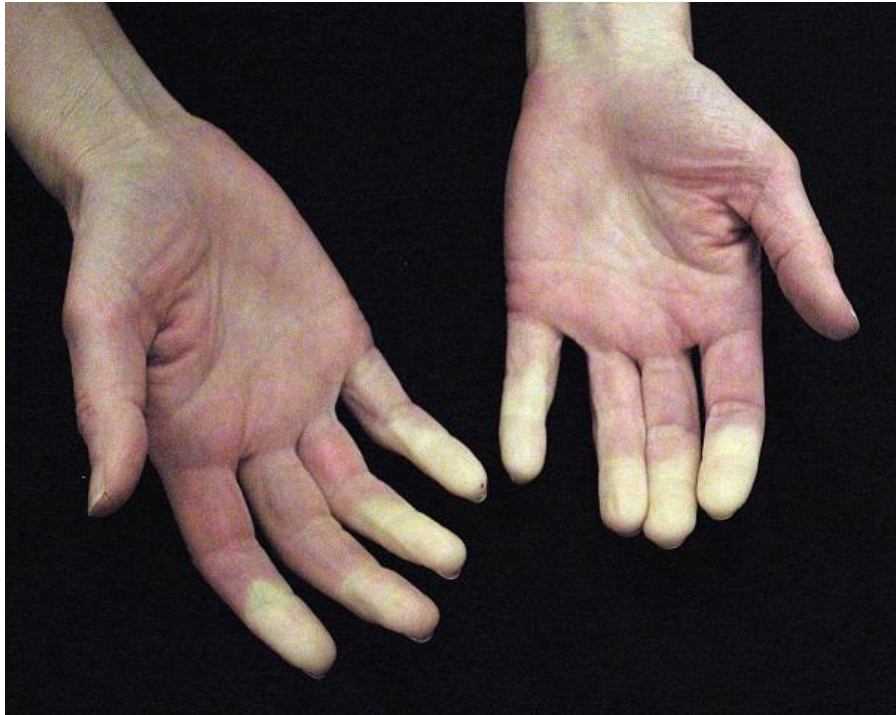
- Systemic sclerosis:



Systemic lupus erythematosus:



Reynaud's phenomenon :



Reactive arthritis :

Conjunctivitis



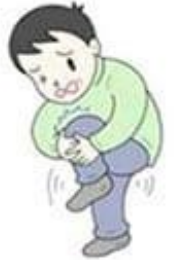"Can't see"

Urethritis



"Can't pee"

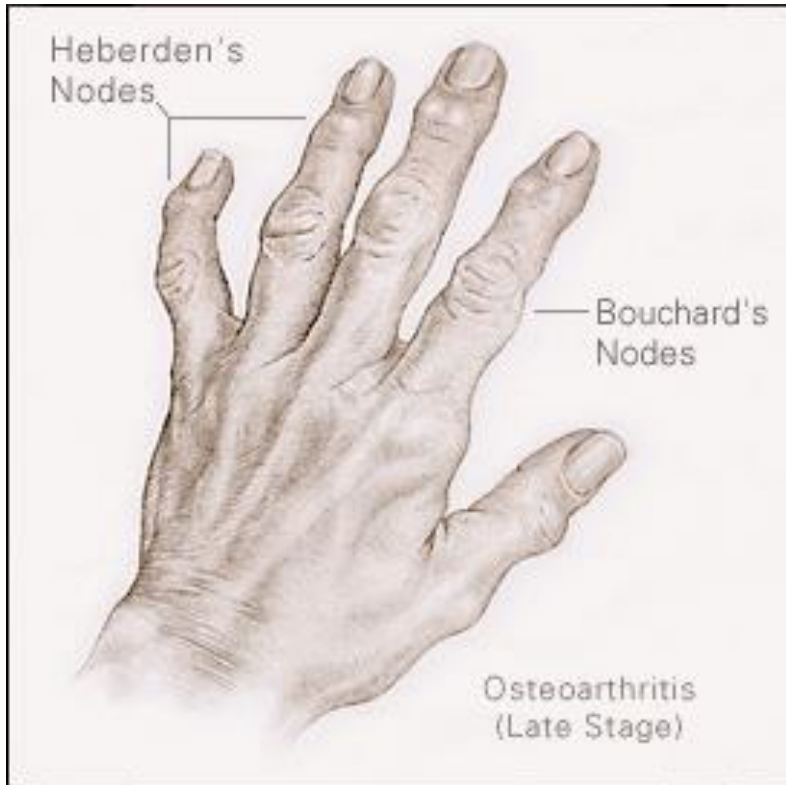
Arthritis



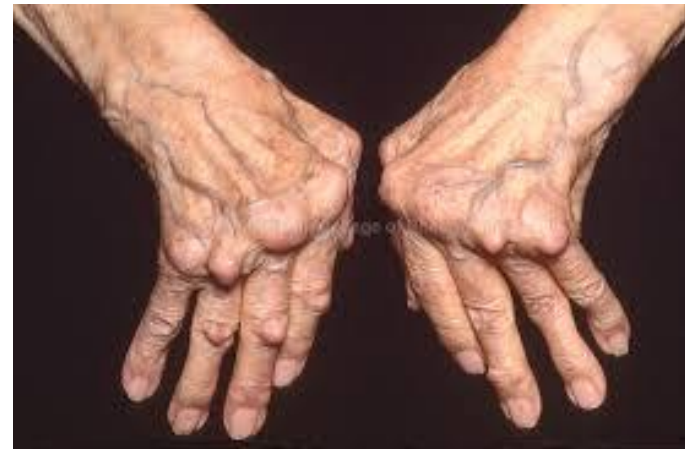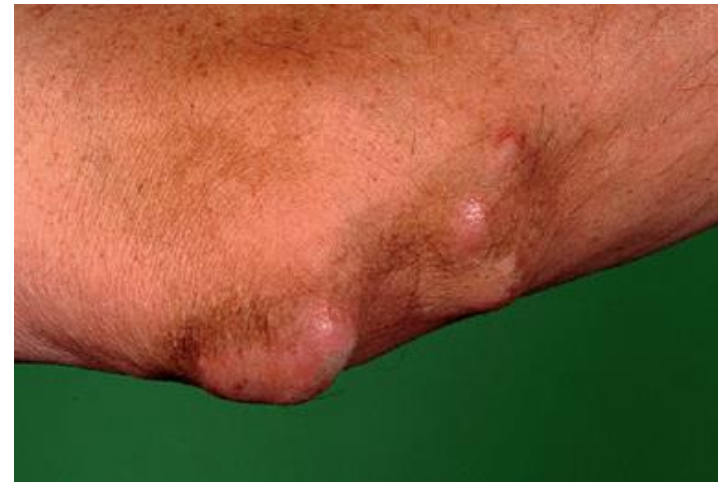"Can't climb a tree"

Nodules

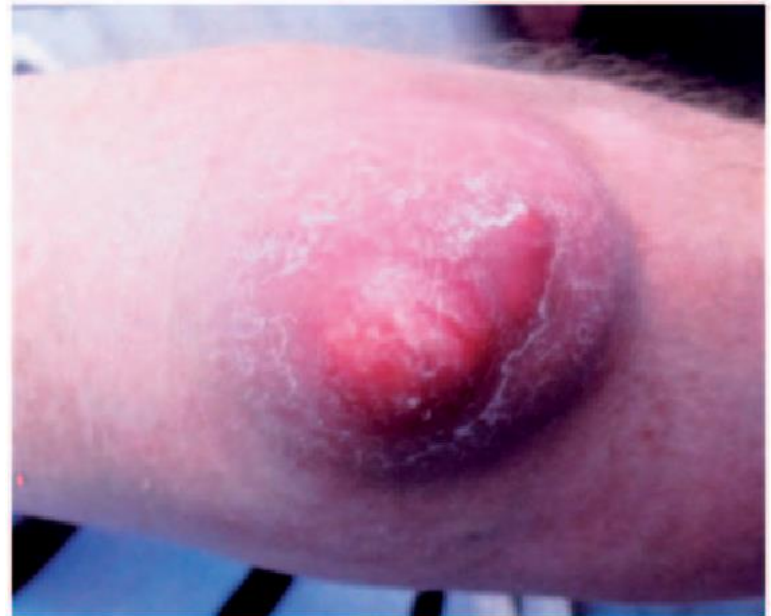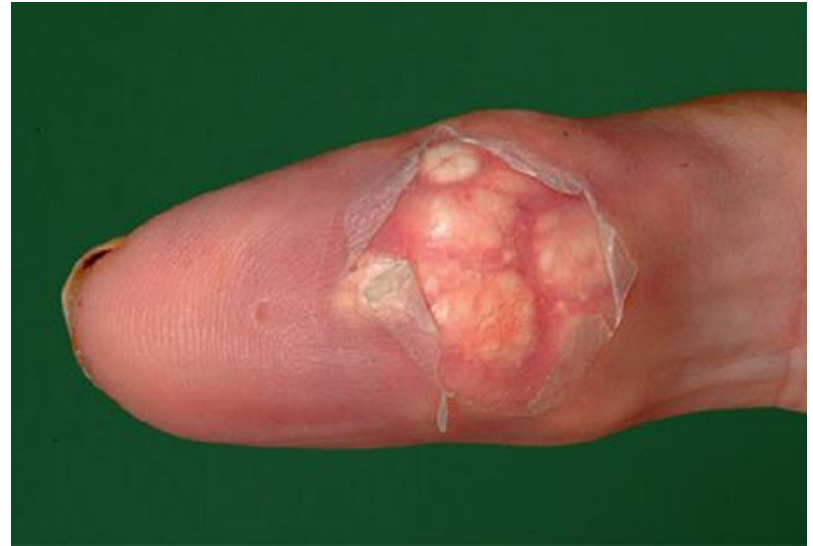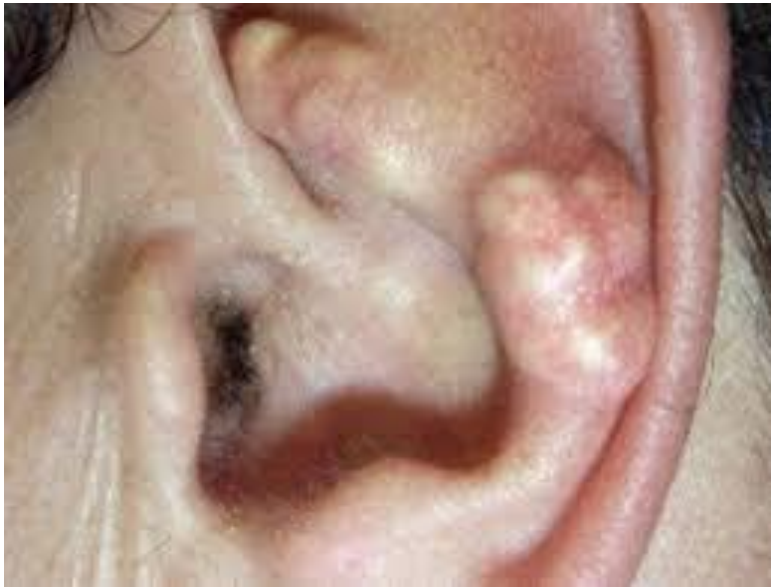Osteoarthritis



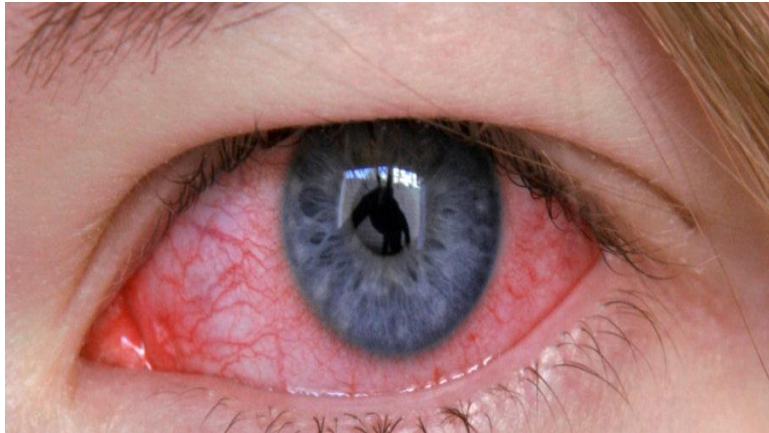
Rheumatoid arthritis



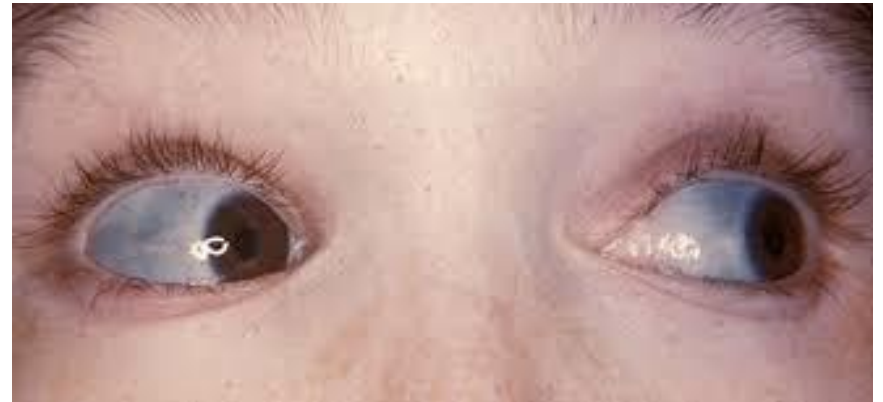- Gout Tophi (Monosodium urate monohydrate)



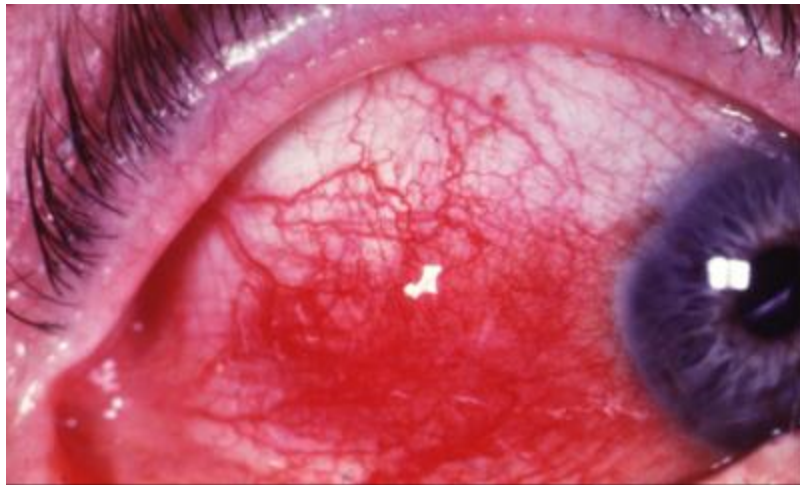- Eye presentations:



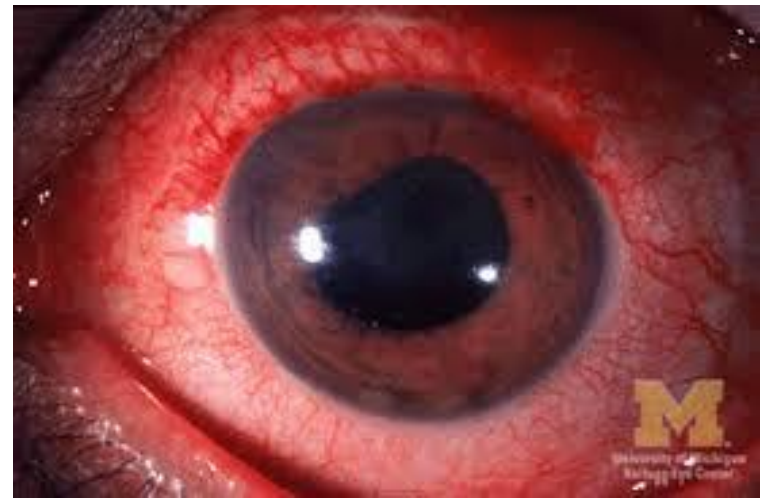Reactive arthritis



Osteogenesis imperfecta



Rheumatoid and psoriatic arthritis



axial spondyloarthritis

Spine

Common spinal problems

- Mechanical back pain
- Prolapsed intervertebral disc
- Spinal stenosis
- Ankylosing spondylitis
- Compensatory scoliosis from leg-length discrepancy
- Cervical myelopathy
- Pathological pain/deformity, e.g. osteomyelitis, tumour, myeloma
- Osteoporotic vertebral fracture resulting in kyphosis
- Cervical rib
- Scoliosis
- Spinal instability, e.g. spondylolisthesis

Cervical Spine

Nodding... Atlanto-occipital joints.

Rotation... Atlantoaxial joint.

Flexion, extension and lateral flexion... Midcervical level.

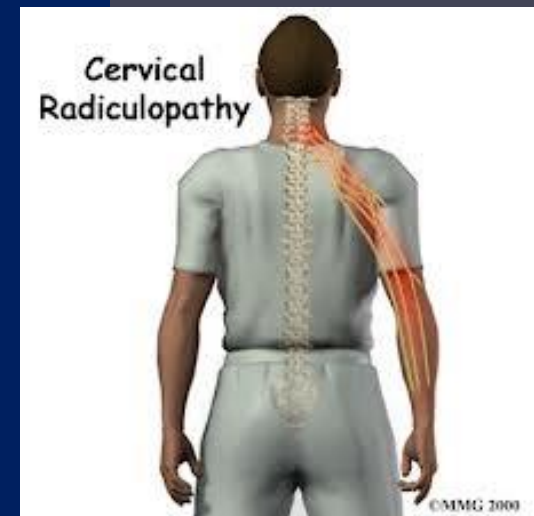
History

Pain

Cervical disc lesions (radiculopathy)

Cervical myelopathy

RA... Atlantoaxial instability



Causes of abnormal neck posture

Loss of lordosis or flexion deformity

Acute lesions, rheumatoid arthritis, trauma

Increased lordosis

Ankylosing spondylitis

Torticollis (wry neck)

Sternocleidomastoid contracture, trauma

Lateral flexion

Erosion of lateral mass of atlas in rheumatoid arthritis

Examination Sequence

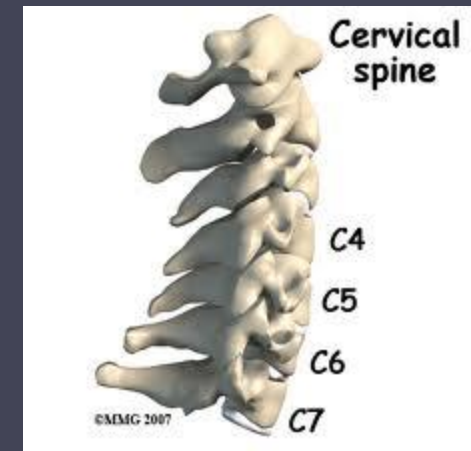
Look: Posture
Lordosis
Scars
Swellings
Deformity

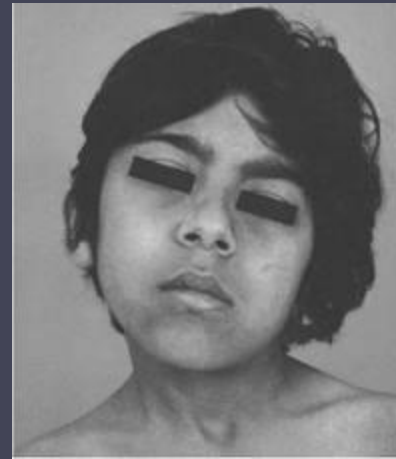
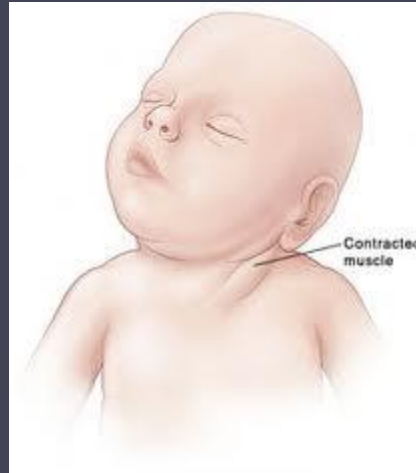
Fig 2. Caso 3, durante uma de suas crises de inclinação cefálica lateral, que costumavam apresentar duração de 8 horas.

Feel:

- Spinous processes (T1 most prominent).
- Paraspinal muscles.
- Supraclavicular fossae (cervical rib, LN).
- Anterior neck and thyroid.
- tenderness



Examination Sequence

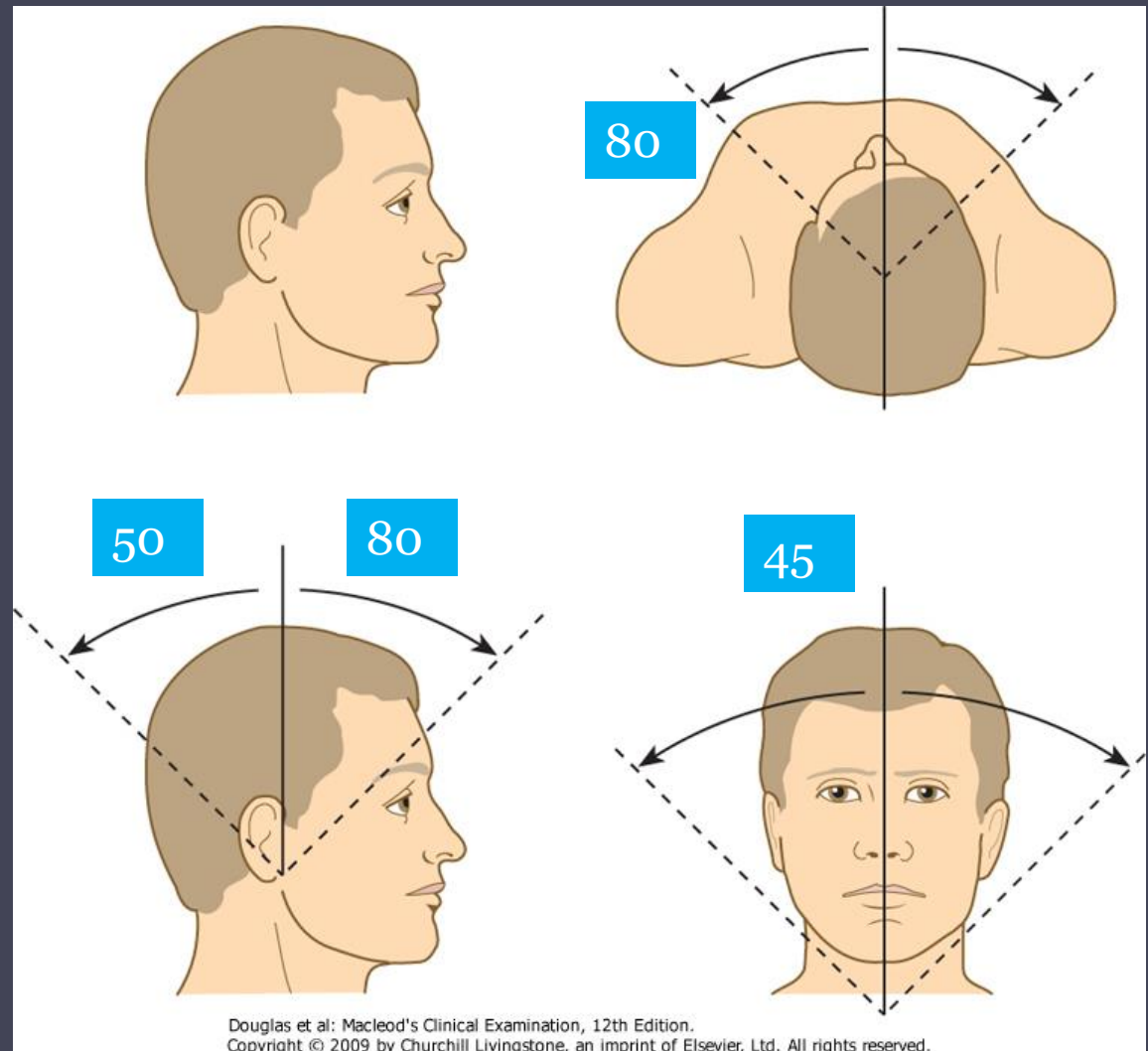
Move:

Active

Passive

UL & LL

(Neurological assessment
if pathology is present)



Thoracic Spine

- The least mobile segment of the spine
- Movement: mainly rotational

History:

- Pain: localized, radiating, poorly localized
- Neurological symptoms
- Loss of height

Adolescents and young adults

- Scheuermann's disease
- Ankylosing spondylitis
- Disc protrusion (rare)

Middle-aged and elderly

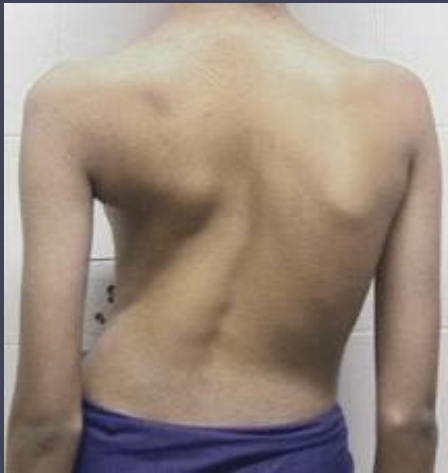- Degenerative change
- Osteoporotic fracture

Any age

- Tumour
- Infection

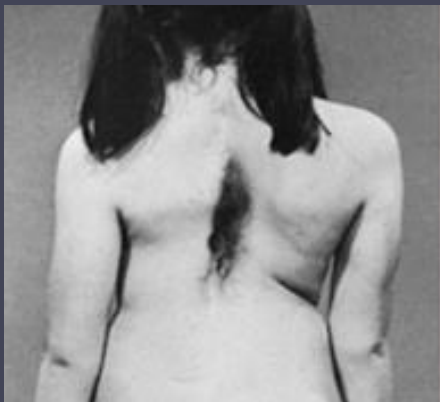Examination Sequence

Look: Posture, Scars, Hair patch, Deformity, wasting

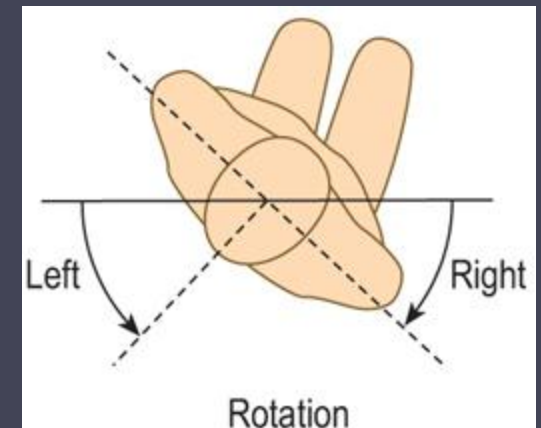


Feel:

- Spinous processes (T1-T12).
- Paraspinal soft tissue



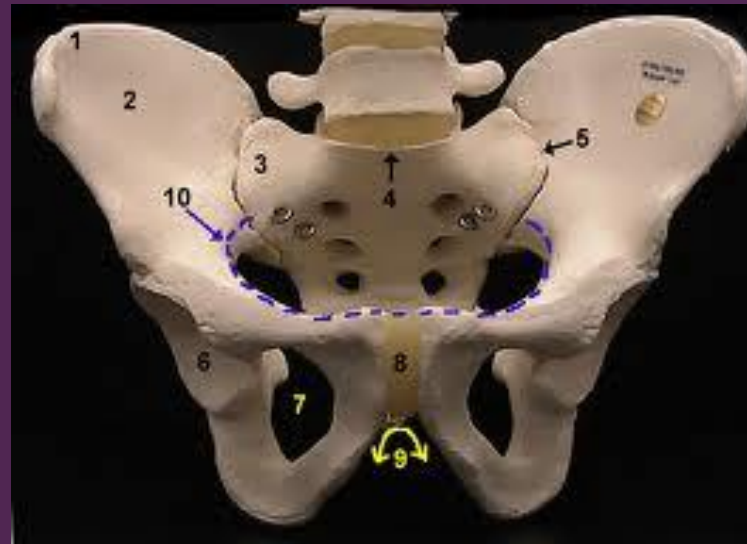
Move: Rotation



Lumbar Spine

Anatomy:

- Spinous processes of L4/5 are level with the pelvic brim.



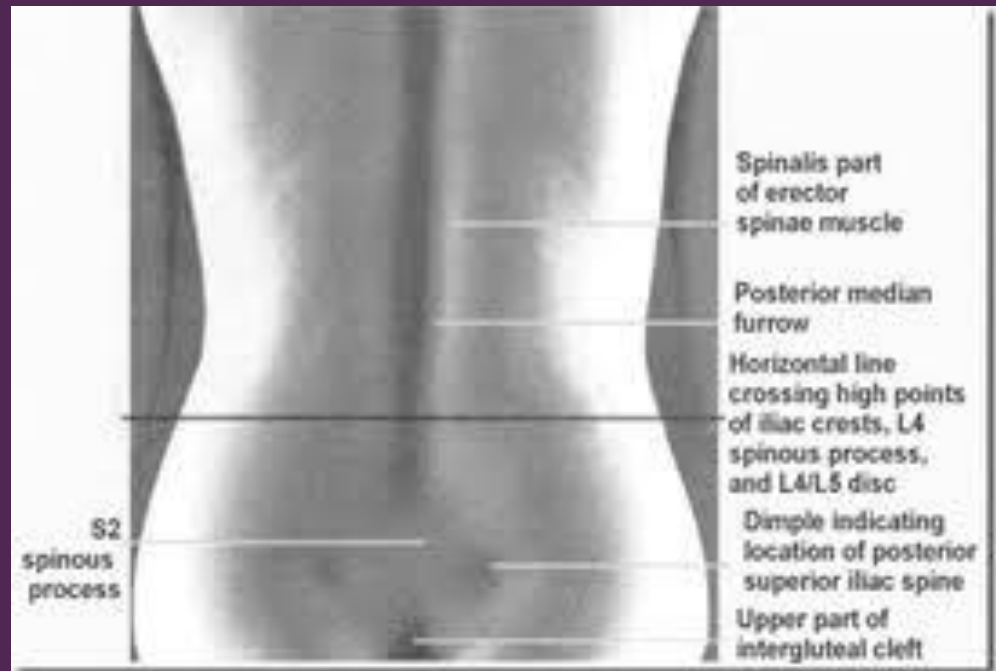
- The spinal cord ends at the L2 level.

Lumbar Spine

Anatomy:

- The 'dimples of Venus' overlie the sacroiliac joints.

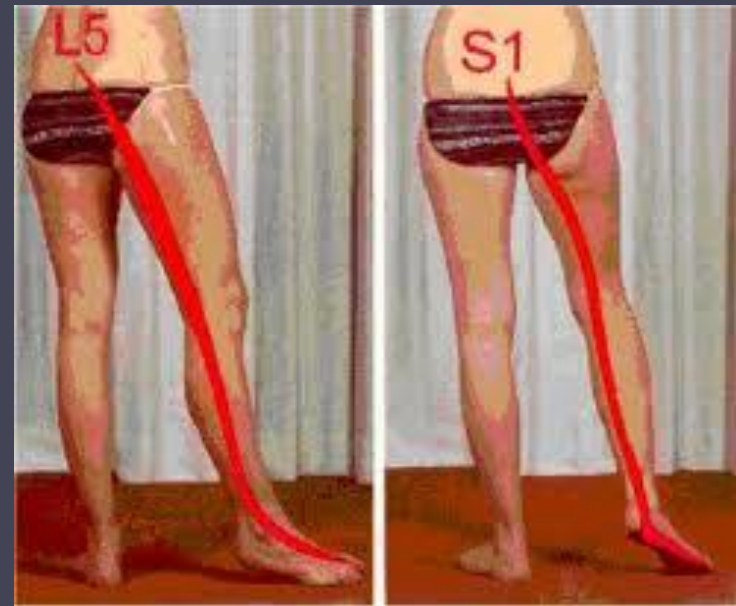- Movements



History...

Pain:

- Low back pain
- Radicular pain
- Buttock pain
- Groin pain



Mechanical

- After standing too long or sitting poor position
 - Worse at end of day and improve on resting
1. **Acute disc prolapse** : acute onset , young age , increased by coughing and straining.
 2. **Osteoporotic fractures**: acute onset , middle aged and elderly , comorbidities, increased by movement , localized

3. **Degenerative disc disease** : chronic, intermittent , associated with stiffness but < 30 mins
4. **Lumbosacral canal stenosis** :diffuse pain in buttocks and thighs with numbness , relieved by rest and spinal flexion, increased by spinal extension

Non-mechanical

- **Inflammatory**: insidious onset, worst at morning , stiffness lasts at least 30 mins after activity.
- **Infectious** : acute, progressive , not related to activity , associated with constitutional symptoms
- **Malignancy**: insidious onset , unremitting pain, weight loss , sleep disturbance ,

History...

- Mechanical
- Inflammatory
- Acute pain: young, elderly, constitutional symptoms
- Unremitting pain
- Intermittent pain
- Claudication
- Emergencies

Cauda equina syndrome

- Cauda equina syndrome occurs when a central disc prolapse, or other space-occupying lesion, compresses the cauda equina.
- There are features of sensory and motor disturbance,
- including diminished perianal sensation and bladder function disturbance.
- The motor disturbance may be profound, as in paraplegia.
- Cauda equina syndrome is neurosurgical emergency.

13.12 'Red flag' and 'yellow flag' features for acute low back pain

'Red flag' features

Features that may indicate serious pathology and require urgent referral

History

- Age <20 years or >55 years
- Recent significant trauma (fracture)
- Pain:
 - Thoracic (dissecting aneurysm)
 - Non-mechanical (infection/tumour/pathological fracture)
- Fever (infection)
- Difficulty in micturition
- Faecal incontinence
- Motor weakness
- Sensory changes in the perineum (saddle anaesthesia)
- Sexual dysfunction, e.g. erectile/ejaculatory failure
- Gait change (cauda equina syndrome)
- Bilateral 'sciatica'

Past medical history

- Cancer (metastases)
- Previous glucocorticoid use (osteoporotic collapse)

System review

- Weight loss/malaise without obvious cause, e.g. cancer

'Yellow flag' features

Psychosocial factors associated with greater likelihood of long-term chronicity and disability

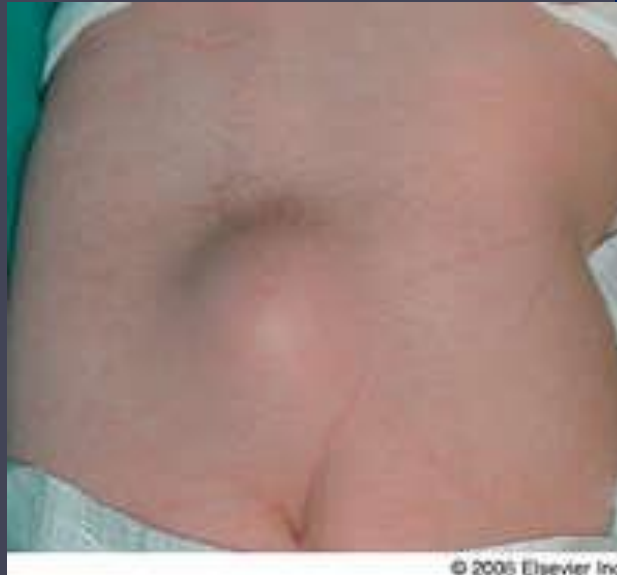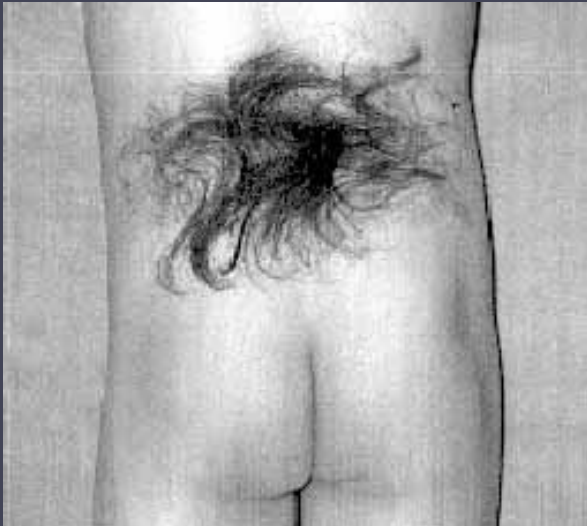- A history of anxiety, depression, chronic pain, irritable bowel syndrome, chronic fatigue, social withdrawal
- A belief that the diagnosis is severe, e.g. cancer. Faulty beliefs can lead to 'catastrophisation' and avoidance of activity
- Lack of belief that the patient can improve leads to an expectation that only passive, rather than active, treatment will be effective
- Ongoing litigation or compensation claims, e.g. work, road traffic accident

Examination Sequence

Look: Deformity
Soft Tissue
Scars, Rash
Muscle wasting
Hair patch
lordosis

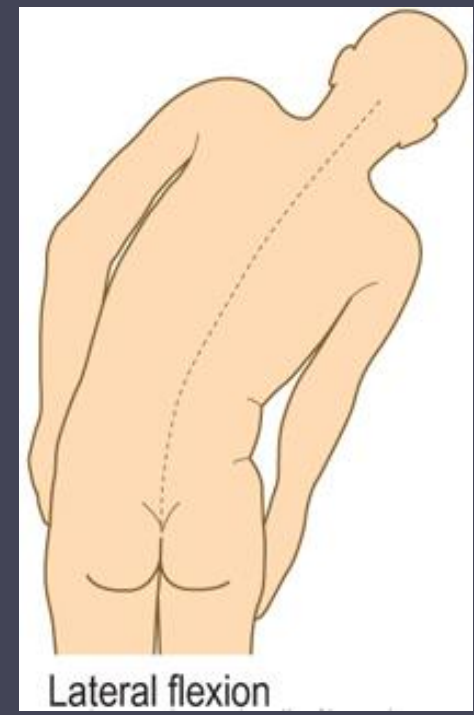
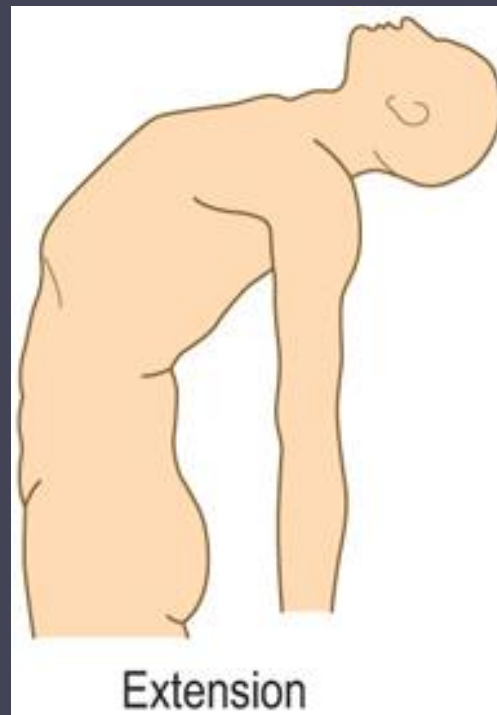
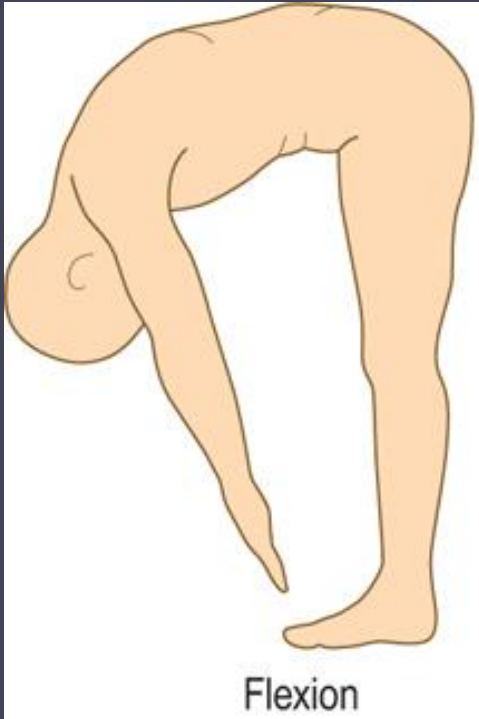
Feel:

- Spinous processes
- Paraspinal tissues
- Gentle percussion



Examination Sequence

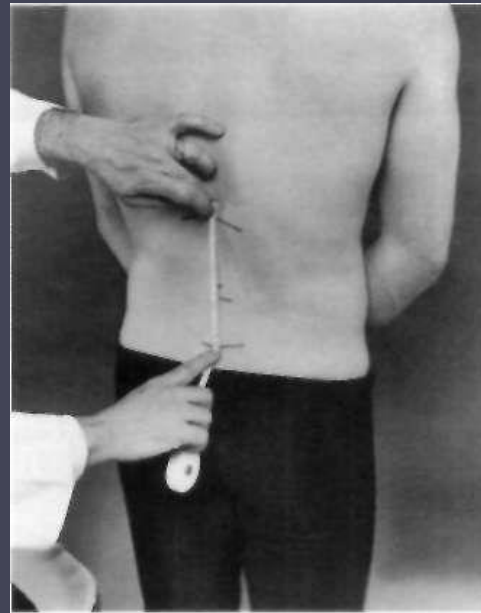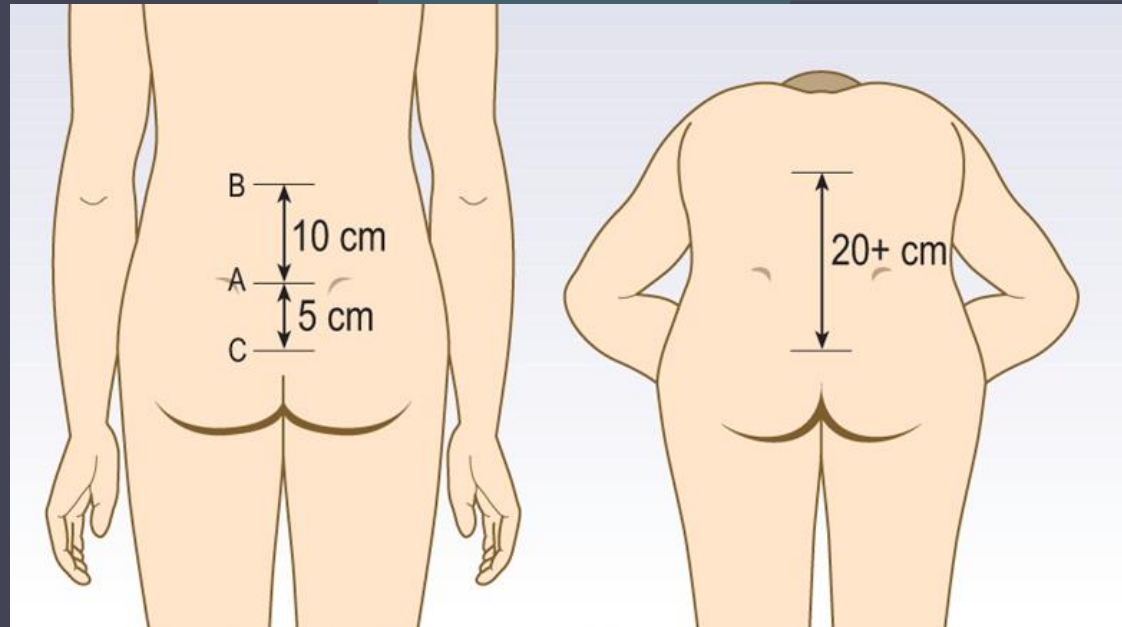
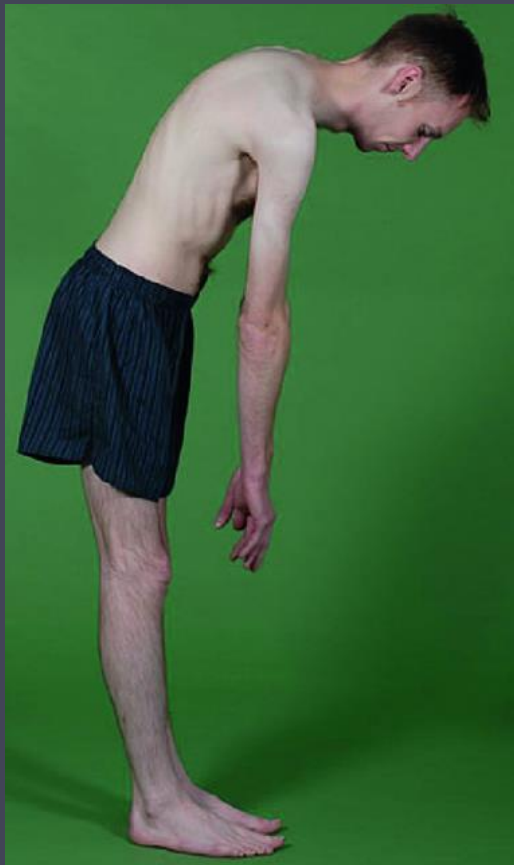Move



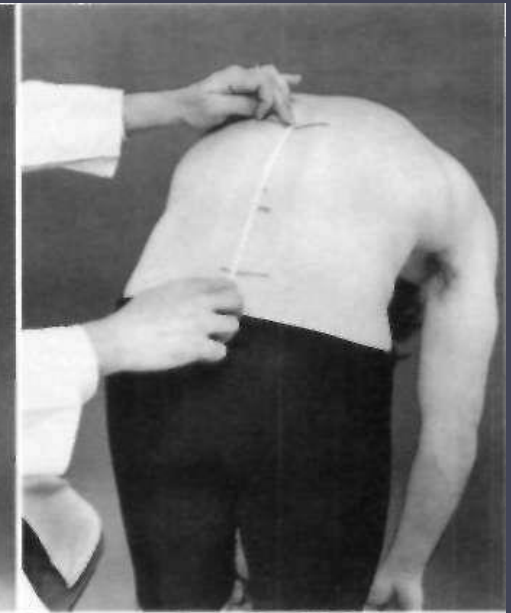


Special tests

Schober's test for forward flexion



A



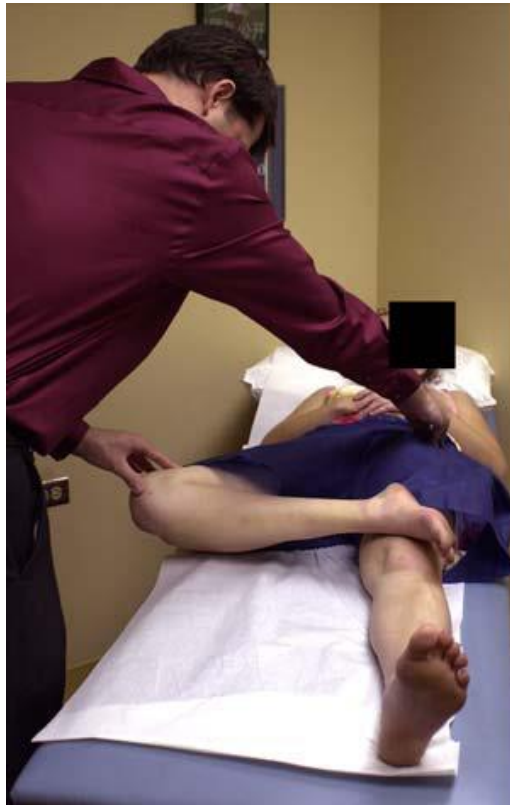B

Special tests

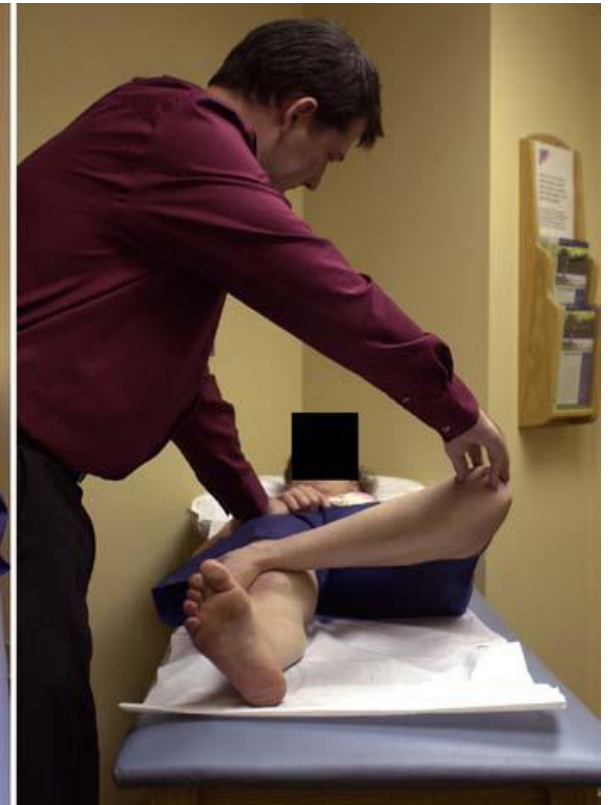
Sacroiliac Joints

Direct pressure in prone position with fist

Patrick's test (FABER)



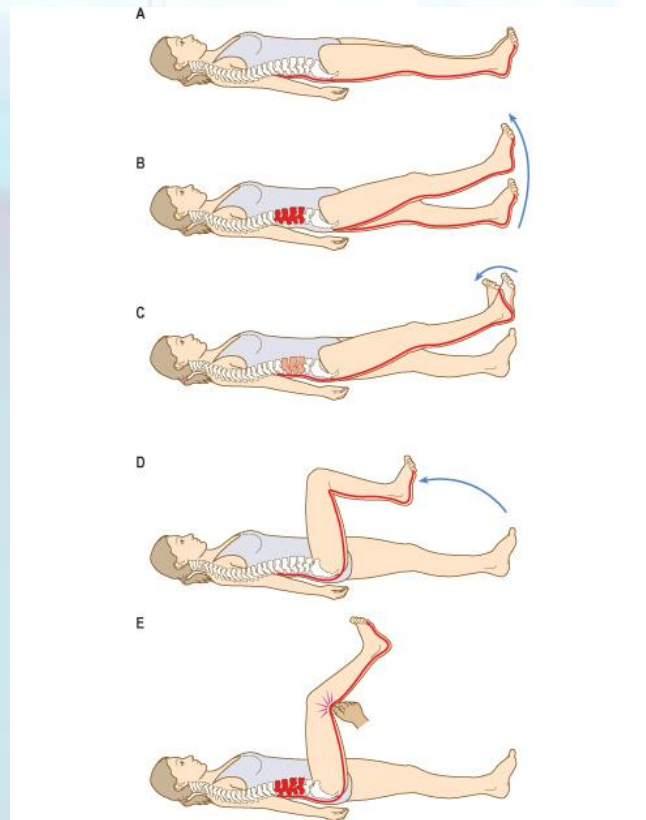
FABER -ve



FABER +ve

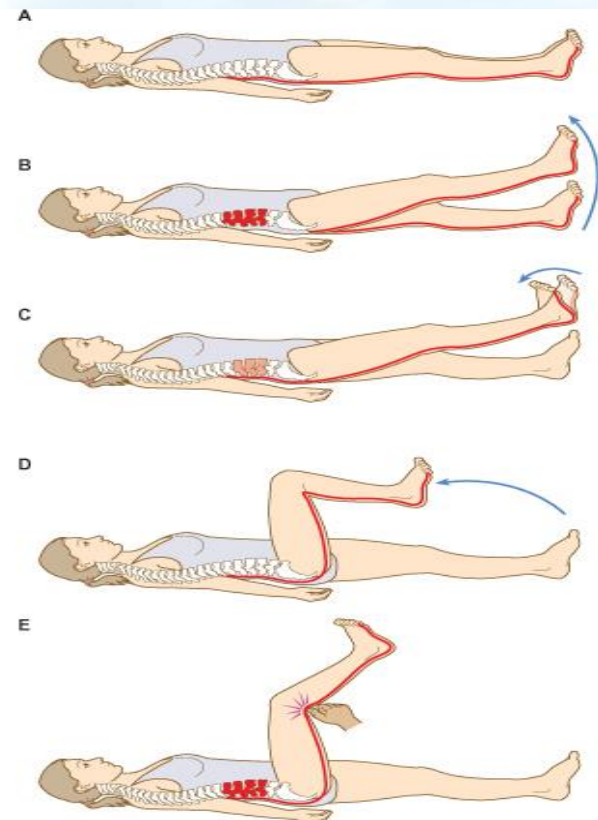
Straight leg raise.

This tests for L4, L5, S1 nerve root tension, e.g. in L3/4, L4/5 and L5/S1 disc prolapse (respectively). With the patient lying supine, lift the foot to flex the hip passively with the knee kept straight. Measure the angle between the couch and the flexed leg to determine any limitation (normal 80-90° hip flexion). If a limit is reached, raise the leg to just less than this level, and test for nerve root tension by dorsiflexing the foot



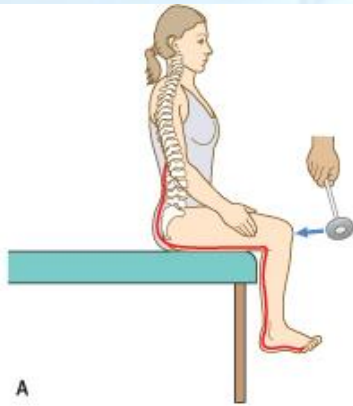Stretch tests - sciatic nerve roots and tibial nerve

Stretch tests - sciatic nerve roots. (A) Neutral position - nerve roots slack. (B) Straight leg raising limited by tension of root over prolapsed disc. (C) Tension increased by dorsiflexion of foot (Bragard's test). (D) Root tension relieved by flexion at the knee. (E) Pressure over centre of popliteal fossa bears on posterior tibial nerve which is 'bowstringing' across the fossa causing pain locally and radiation into the back.

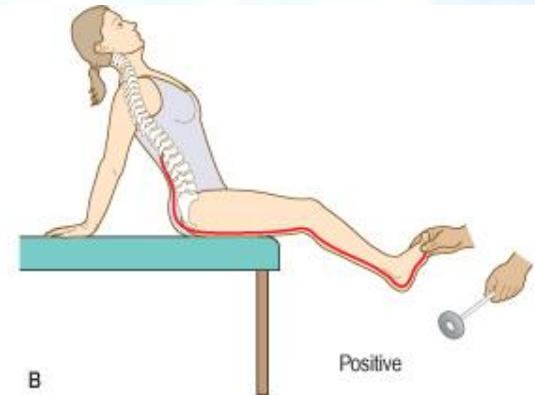

Flip test.

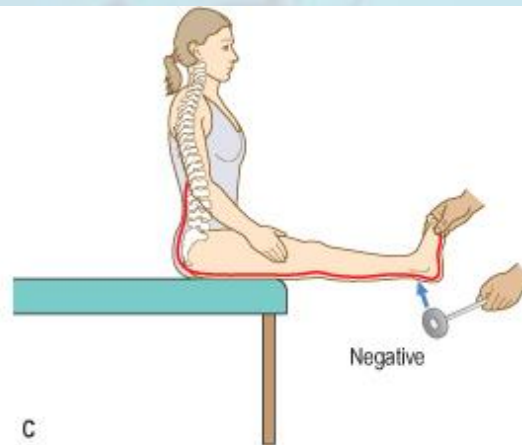
the patient with actual nerve root compression cannot permit full extension of the leg.



© Elsevier. Douglas et al.: MacLeod's Clinical Examination 11e - www.studentconsult.com



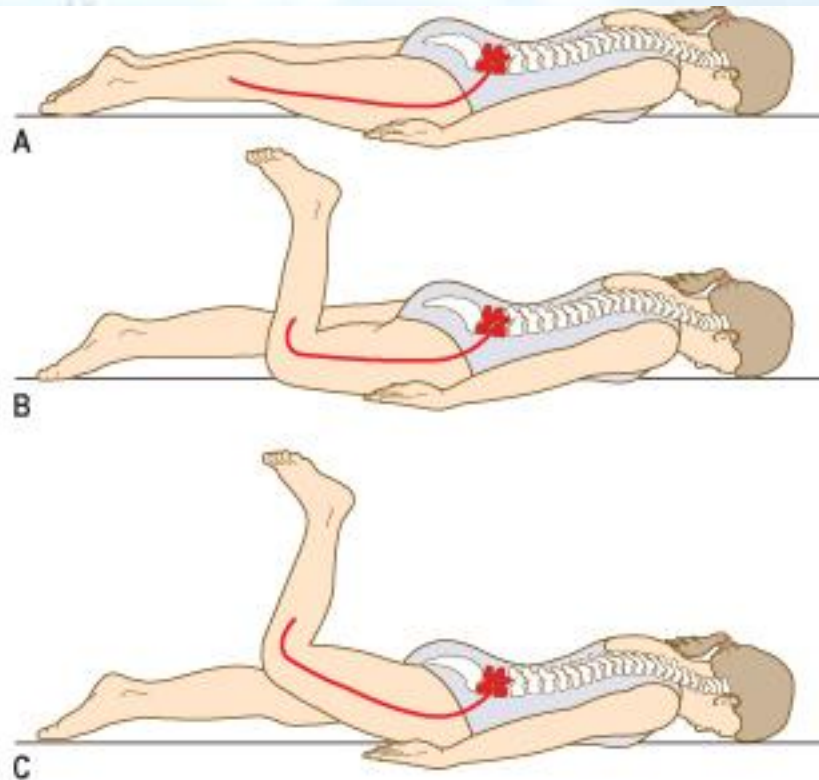
© Elsevier. Douglas et al.: MacLeod's Clinical Examination 11e - www.studentconsult.com



© Elsevier. Douglas et al.: MacLeod's Clinical Examination 11e - www.studentconsult.com

Femoral nerve stretch test.

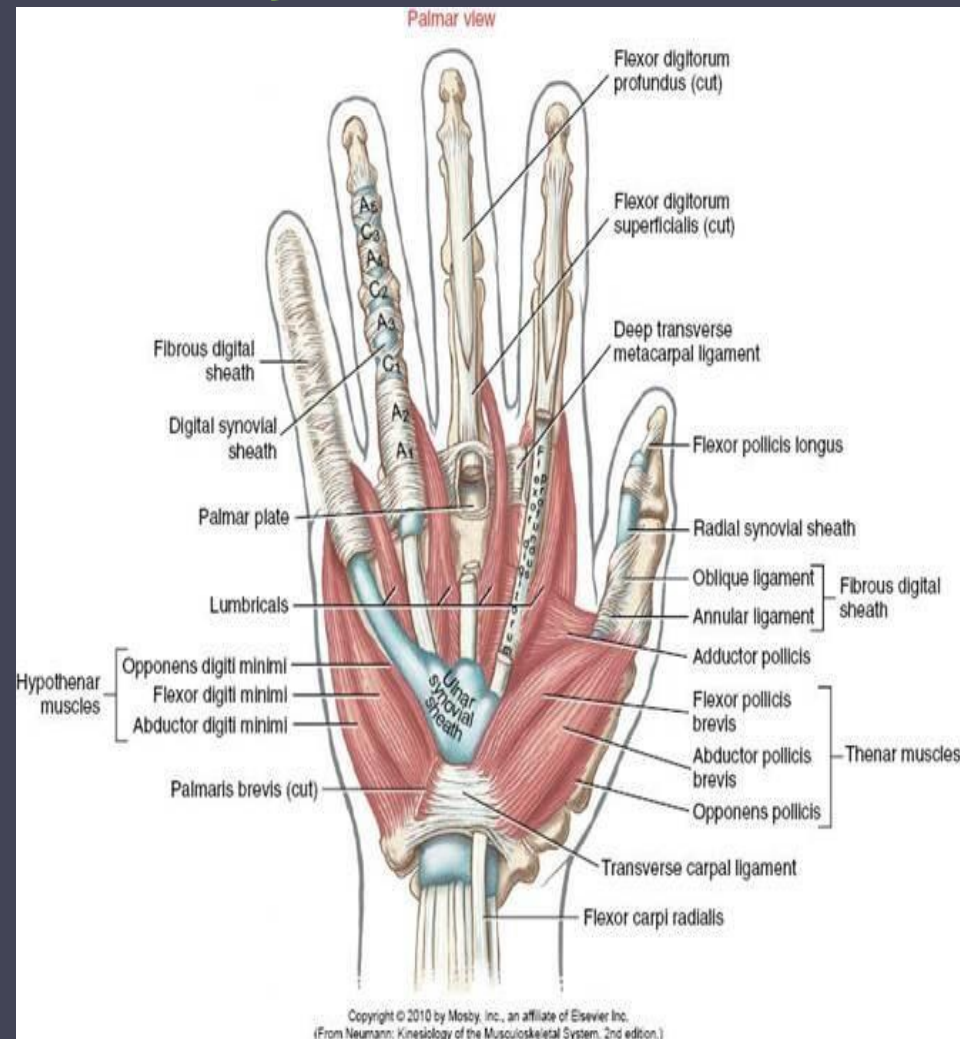
With the patient lying on the front (prone) **flex the knee and then extend the hip** This stretches the femoral nerve. A positive result is when pain is felt in the back or the front of the thigh.



Hand and Wrist

Hand and wrist joint

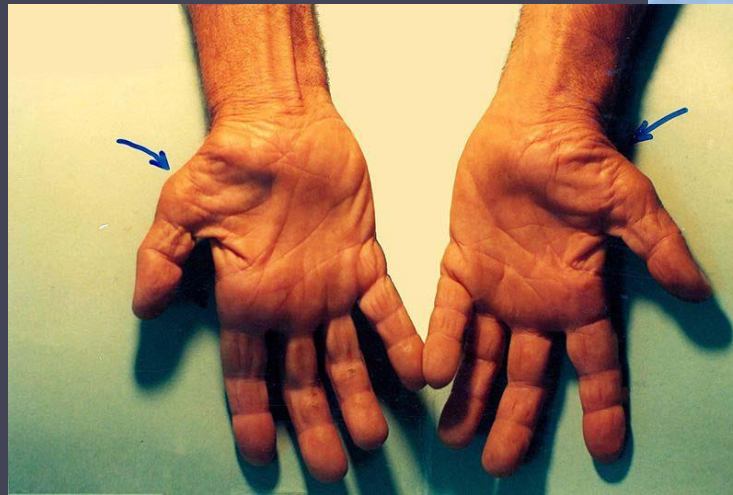
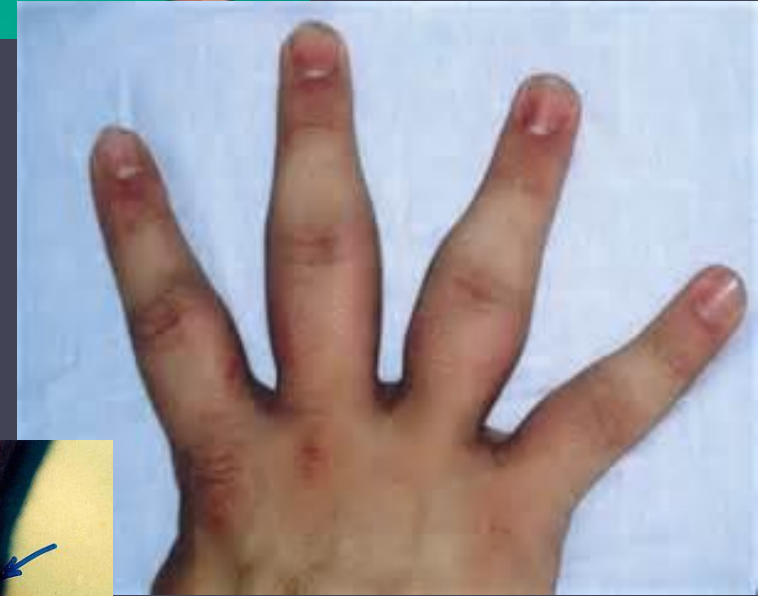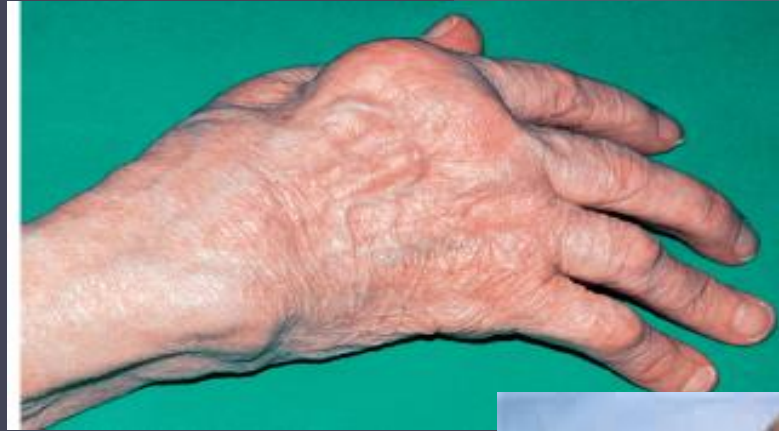- Wrist joint: metacarpocarpal, intercarpal, ulnocarpal, radiocarpal
- PIP and DIP hinge joints
- MCP joint allow adduction and abduction in addition to flexion/ extension

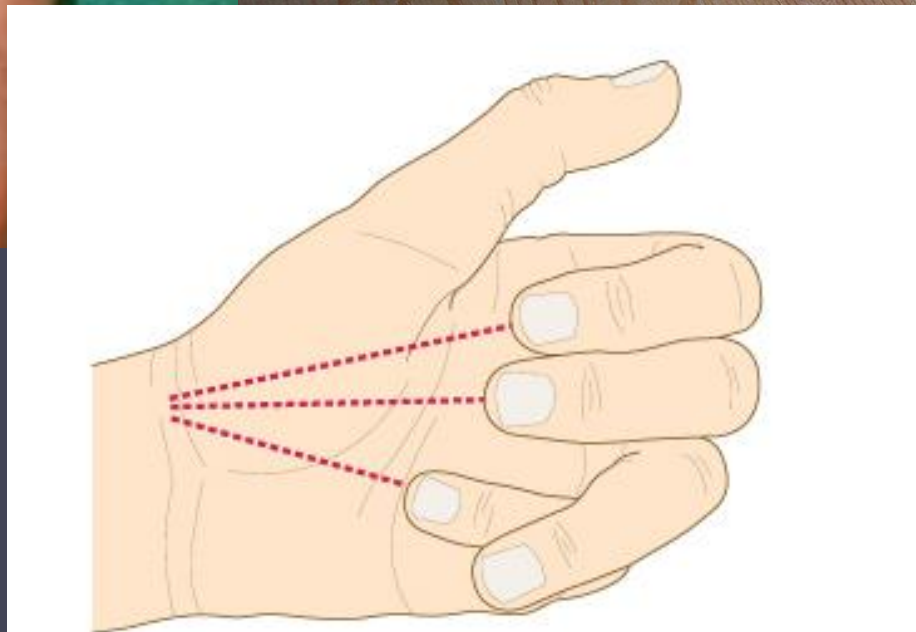
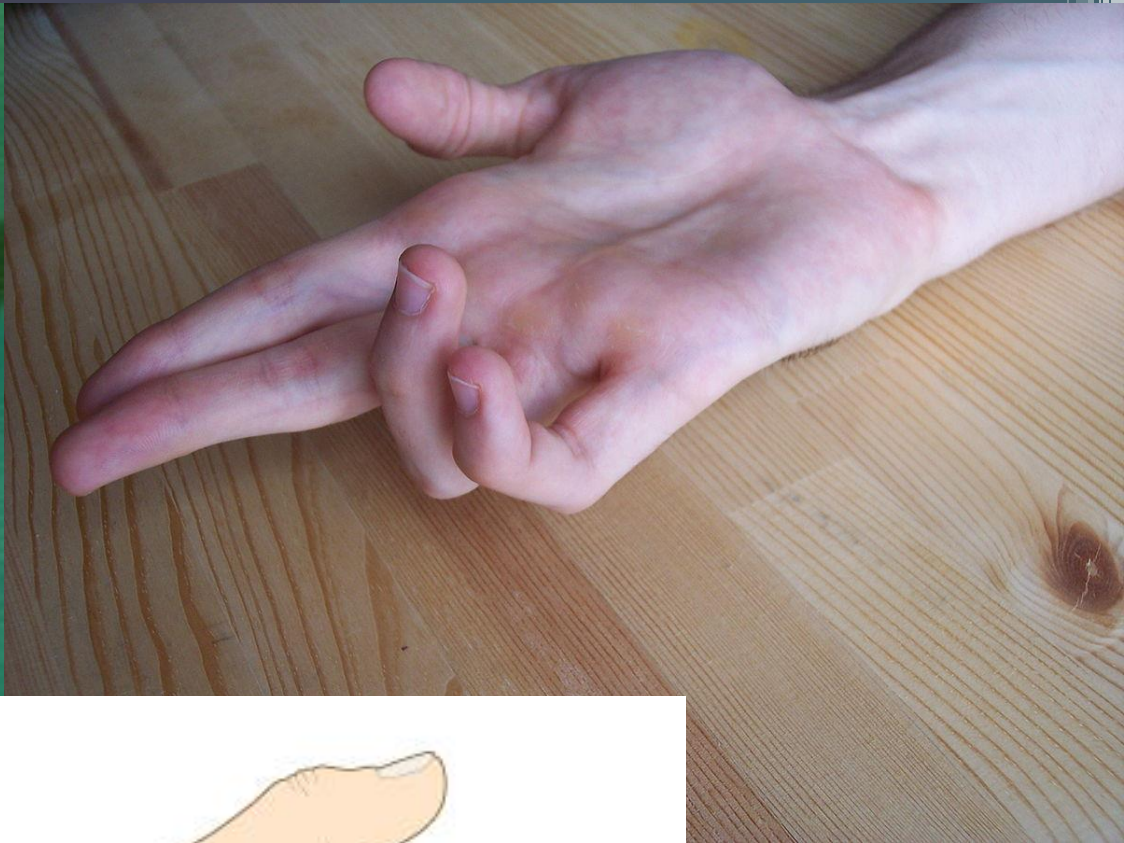
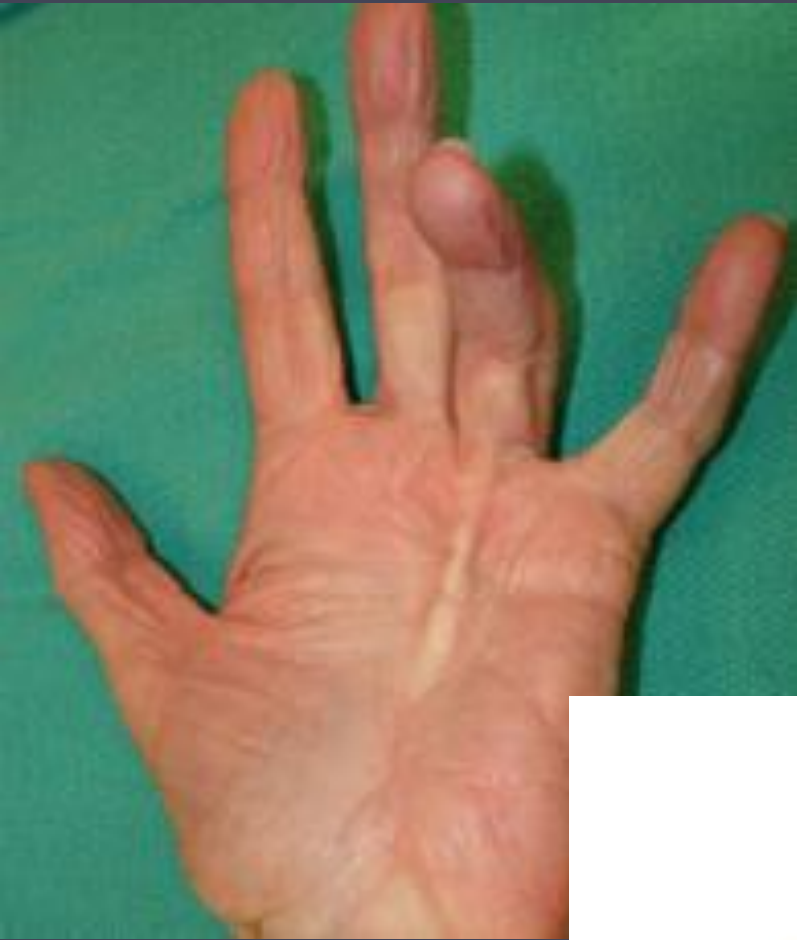

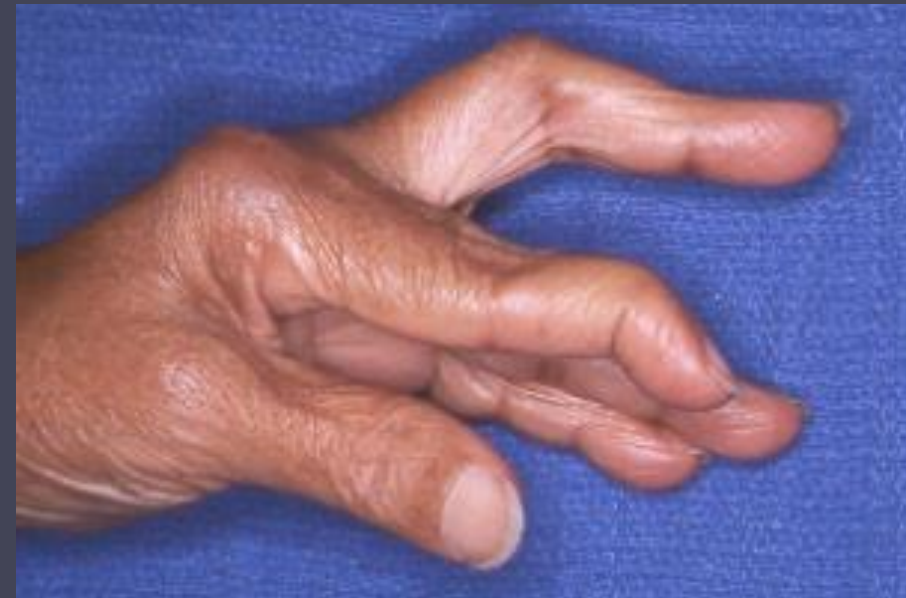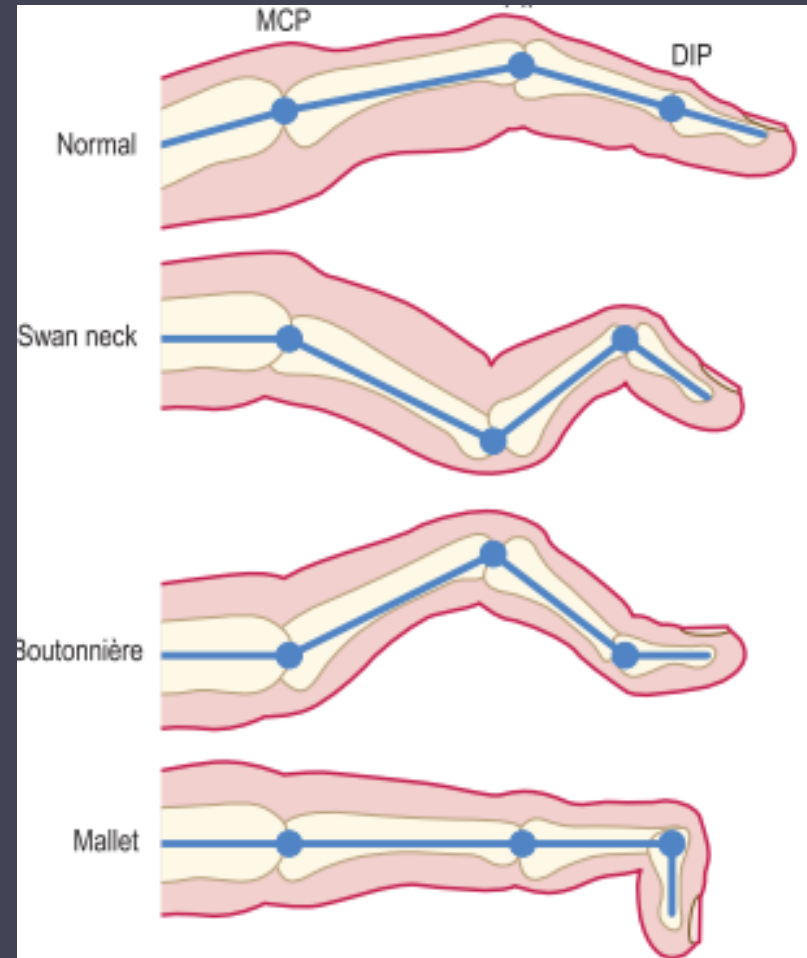
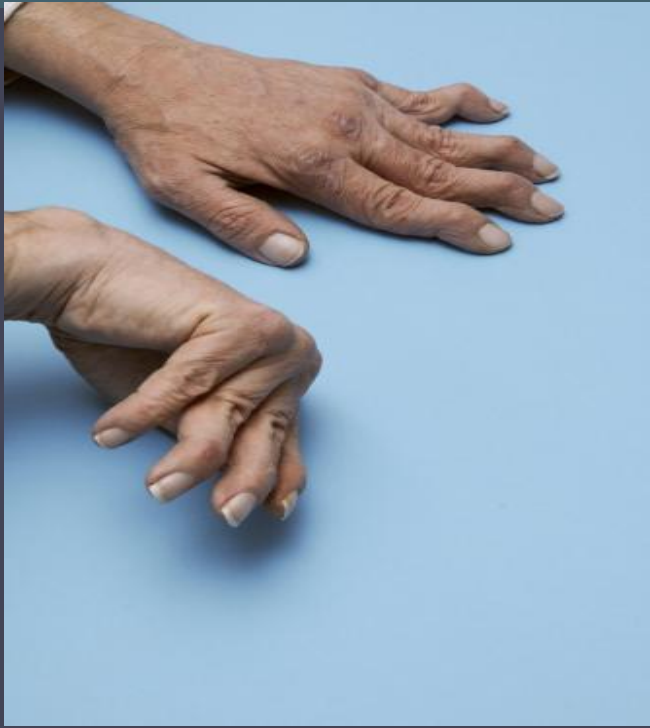- The patient will often localize complaints of pain, stiffness, loss of function, contractures, disfigurement and trauma.
- If symptoms are more vague or diffuse, then consider referred pain or a compressive neuropathy (e.g. median nerve in carpal tunnel syndrome).
- Functionality is very important

Look:

- *Colour change*
- *Swelling*
- *Deformity*
- *Small muscle wasting*
- *Vasculitis of the fingers*
- *Palmar erythema*
- *Nail changes*
- *Ulnar deviation*





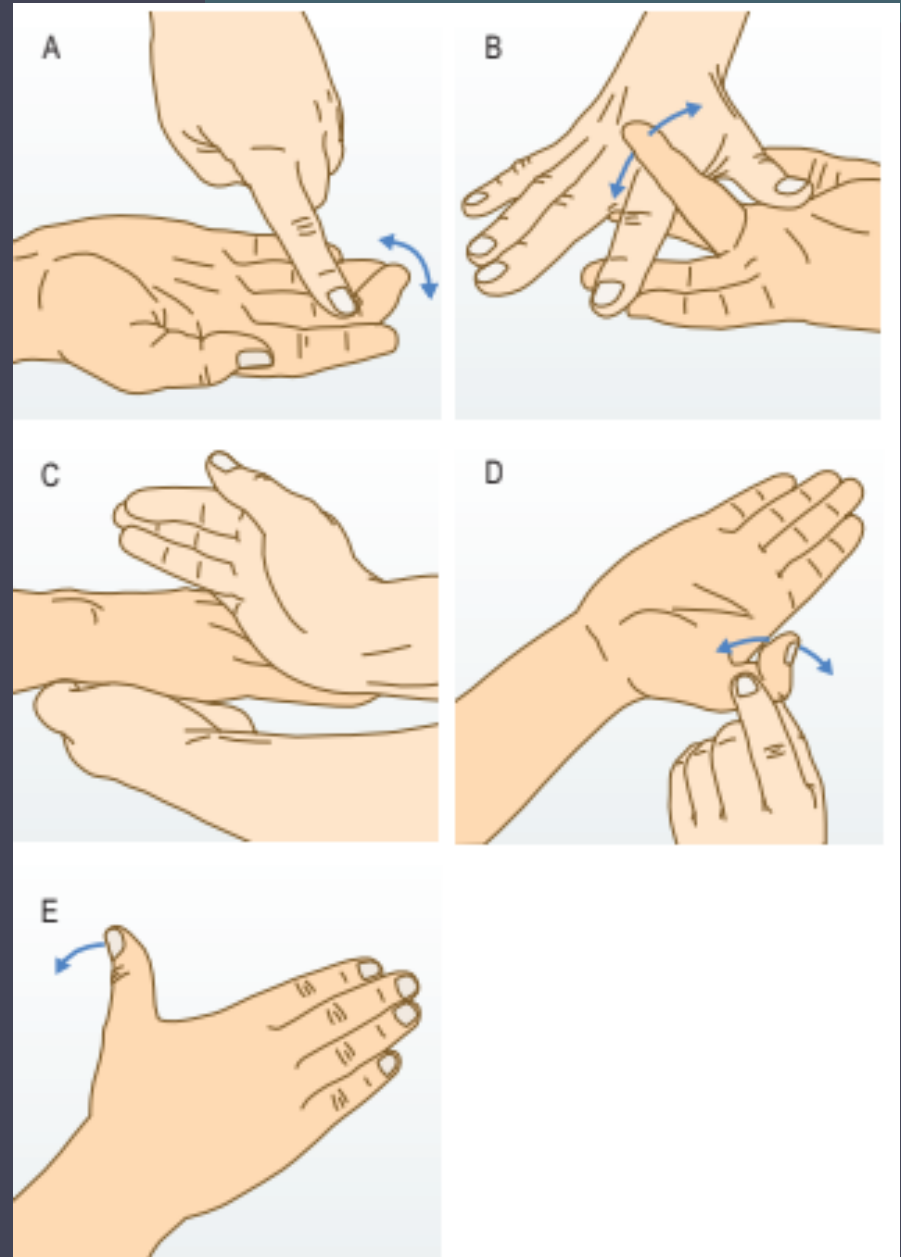


Feel

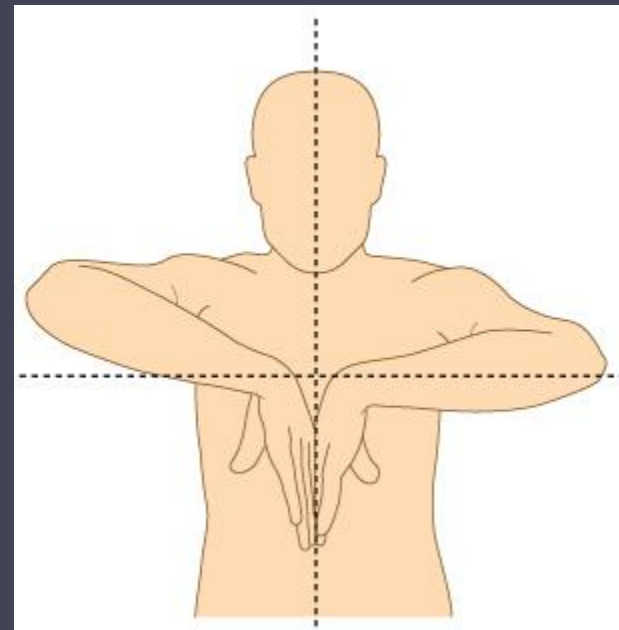
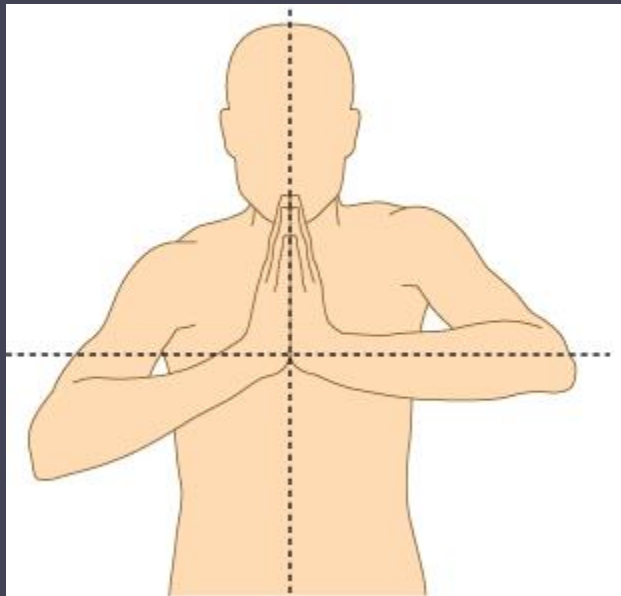
- *Temperature*
- *Hard swellings*: Heberden's and Bouchard's nodes of OA.
- *Soft spongy swellings* suggesting synovitis, palpate joints and flexor tendon sheaths (swelling and tenderness).
 - Trigger fingers.
 - De Quervain's tenosynovitis. >> Finkelstein test.
 - Crepitus in wrist O.A.

Move

- Wrist and small joints.
- Don't forget to test grip.
- Assess function of each tendon alone in patients with cut wounds.



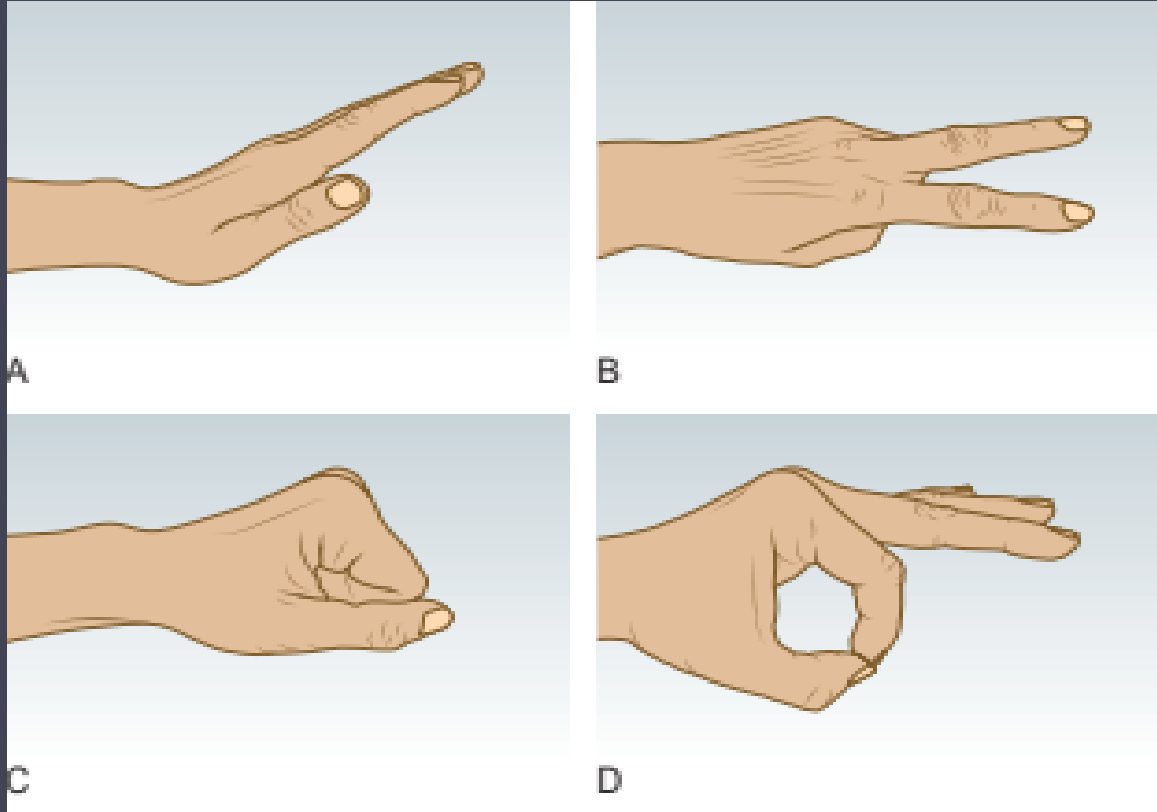
Carpal tunnel syndrome



Median, ulnar and radial nerve exam

- Paper-scissors-stone

- OK sign for AIN



- AIN: anterior interosseous nerve

The Knee Joint

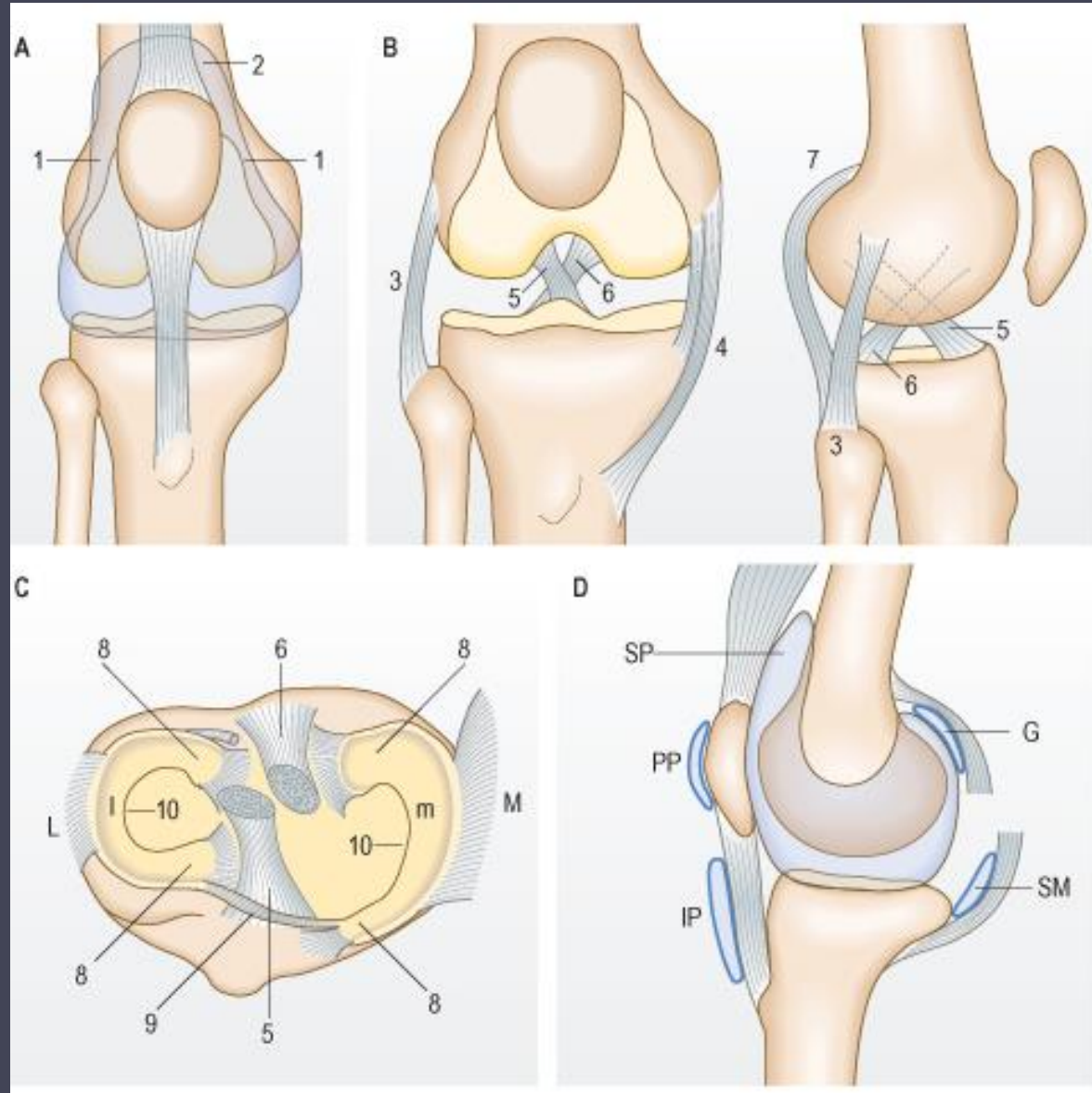
Hinge joint

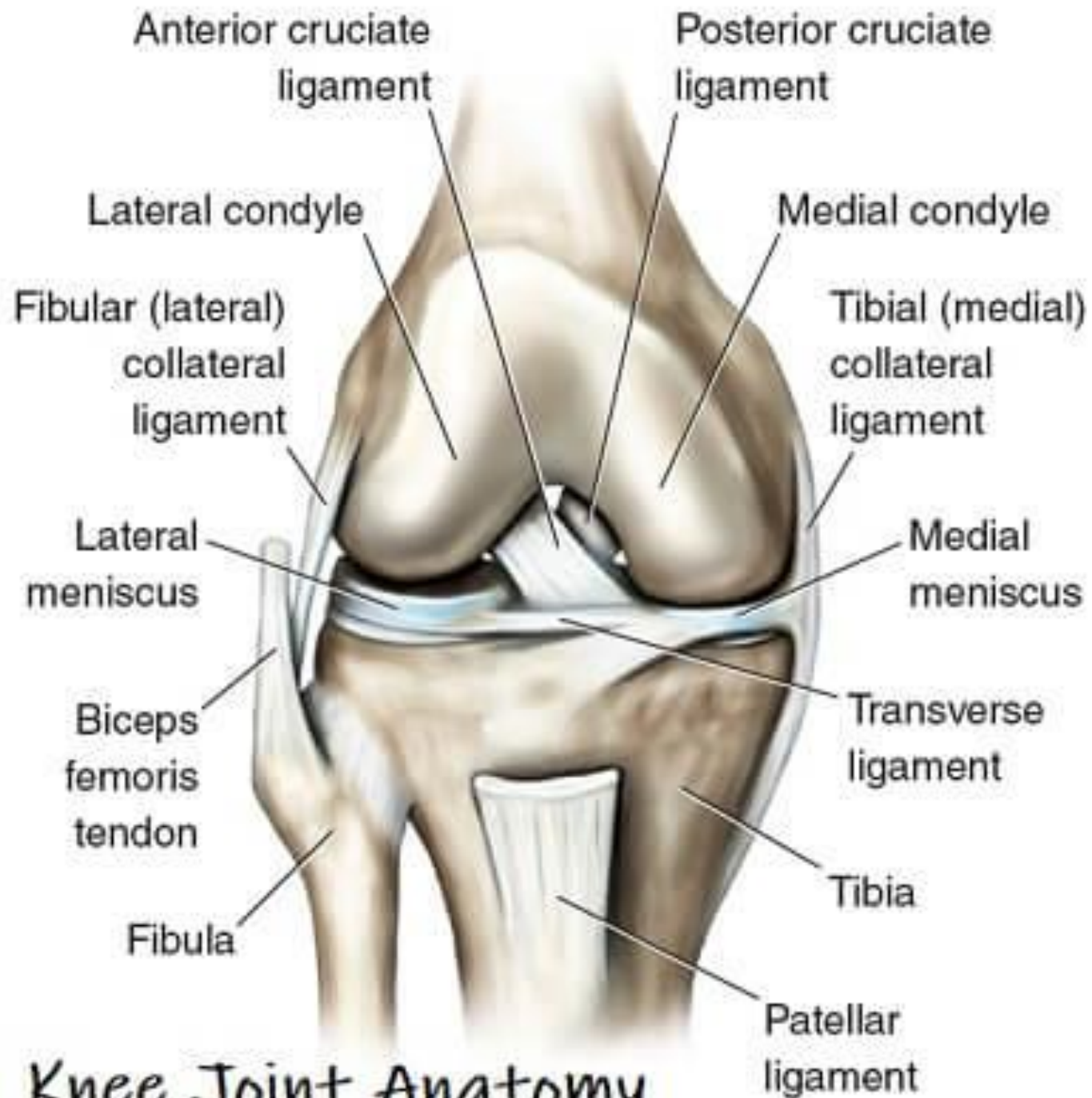Extensor apparatus

Capsule

Stability

Bursae





Knee Joint Anatomy

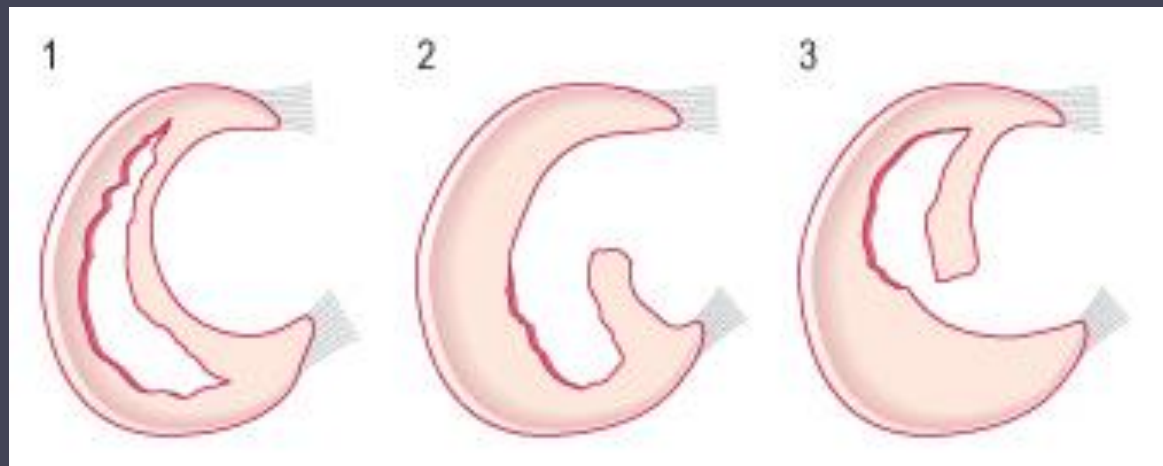
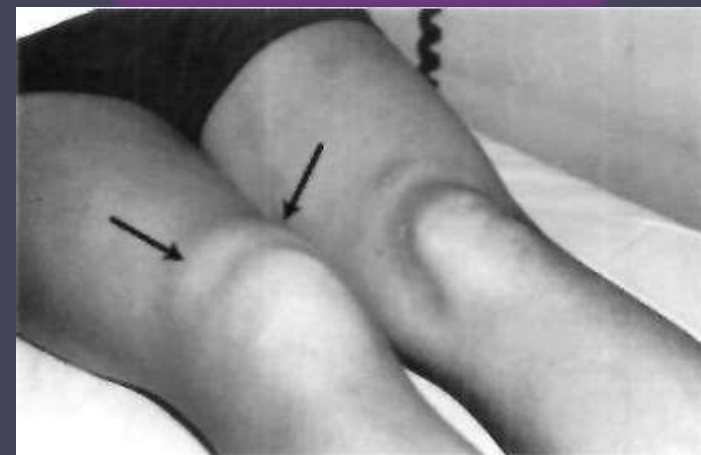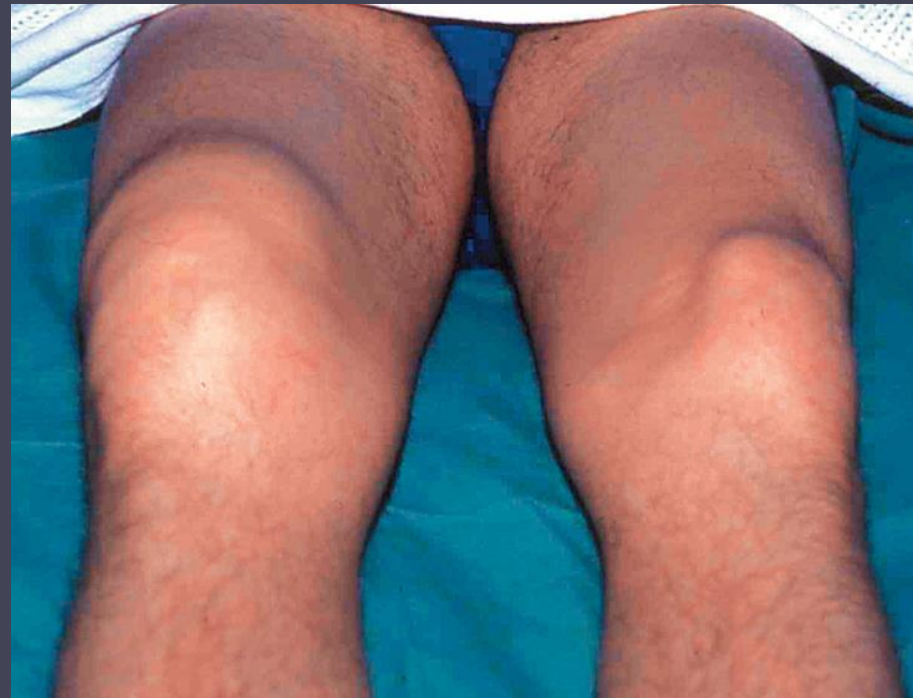Abnormal Findings

Pain

Swelling

Locking

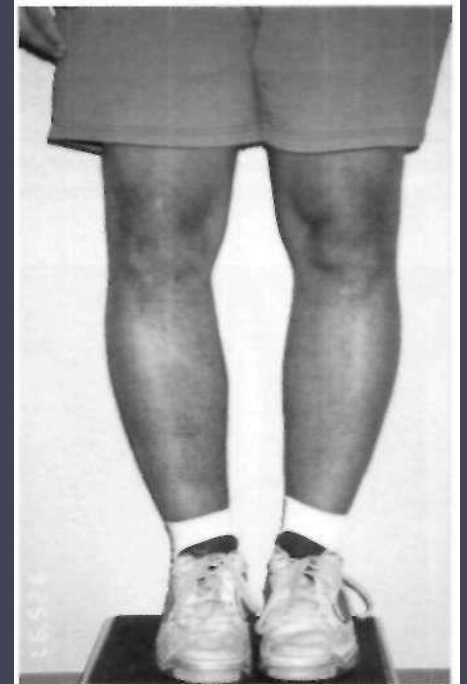
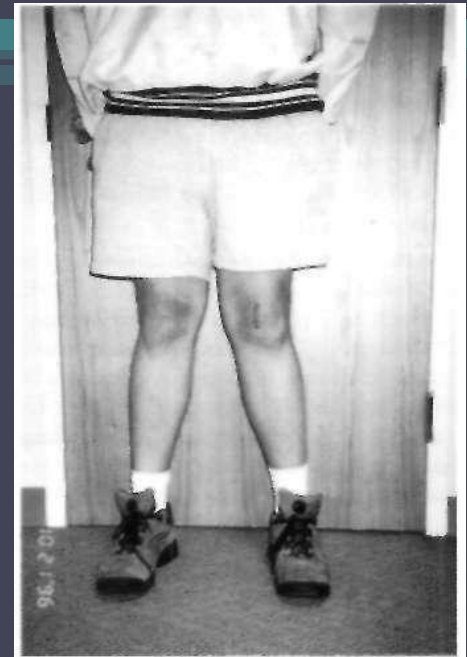Giving way

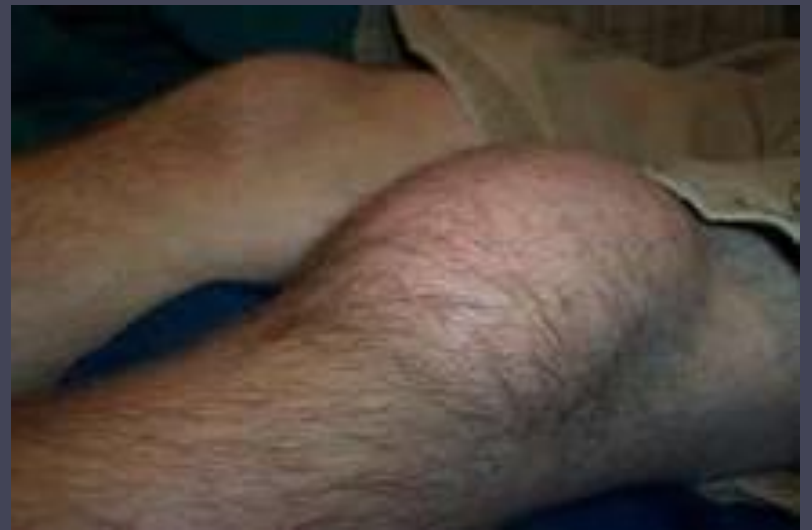
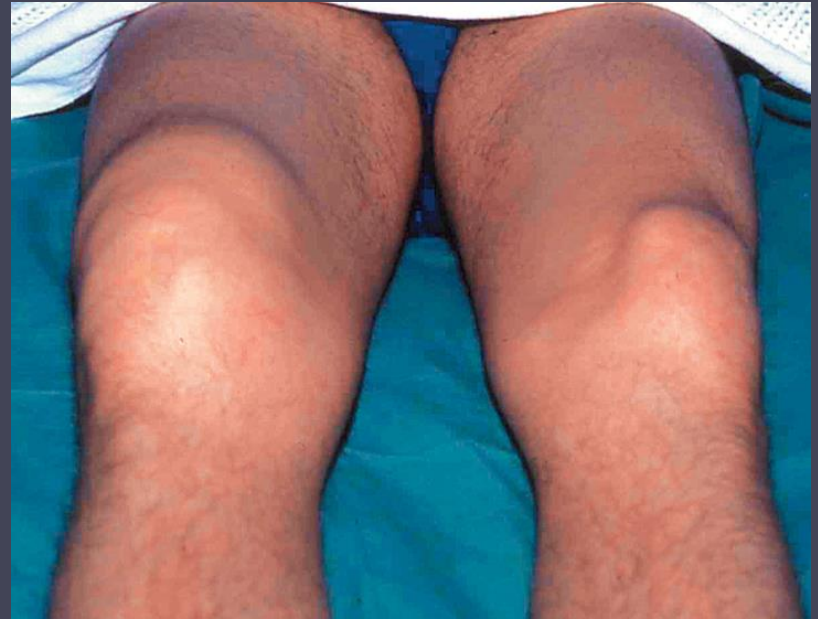
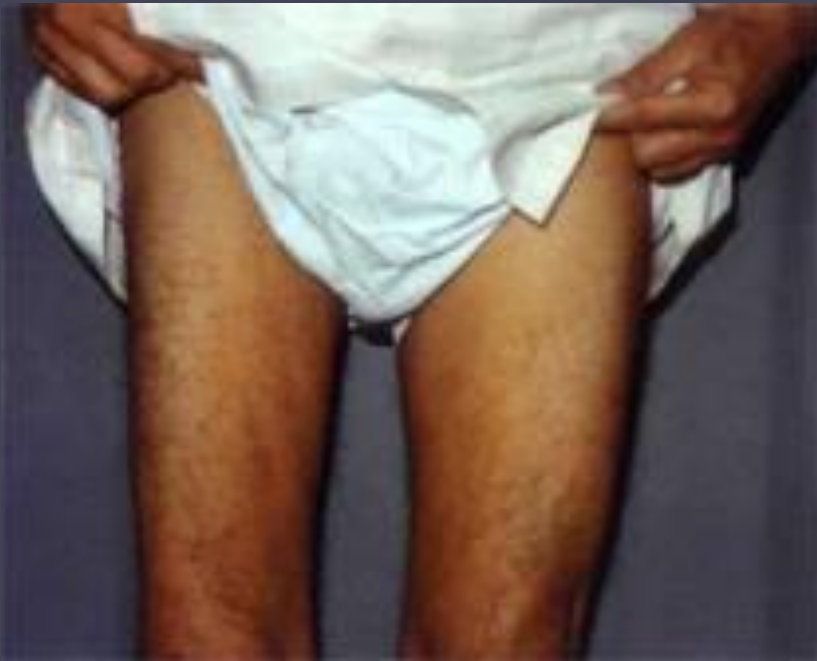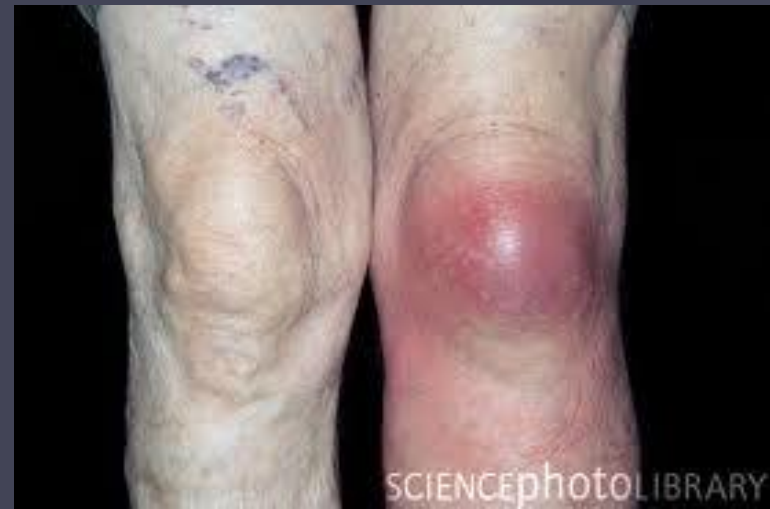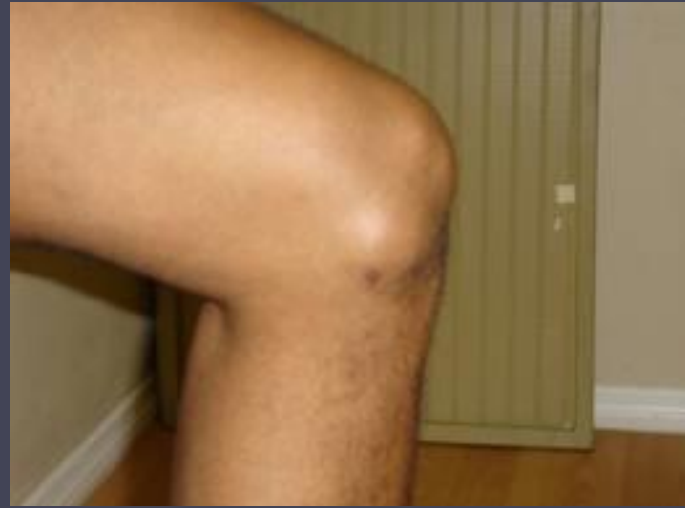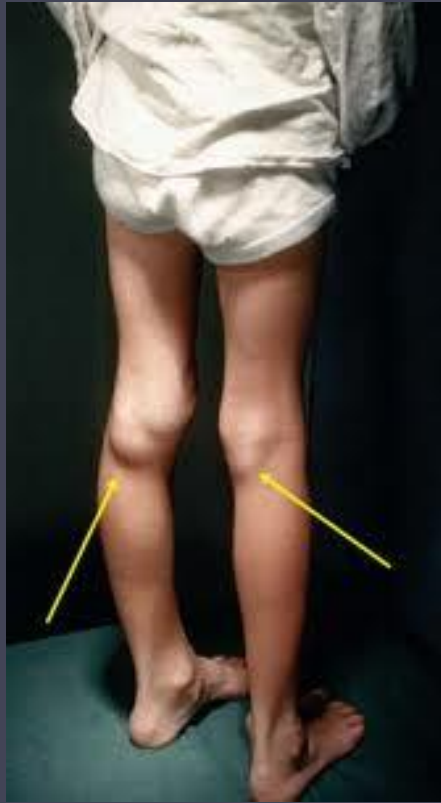Examination Sequence

Look:

- ❖ Gait
- ❖ Scars, sinuses, redness or rashes
- ❖ Deformities
- ❖ Muscle wasting (measure)
- ❖ Leg length discrepancy
- ❖ Flexion deformity
- ❖ Swelling: effusion, bursae
- ❖ Baker's cyst Vs. aneurysm







Examination Sequence

Feel:

Warmth

Joint lines, patella , tibial tuberosity

Patellar tendon

Effusion

Parapatellar hollow

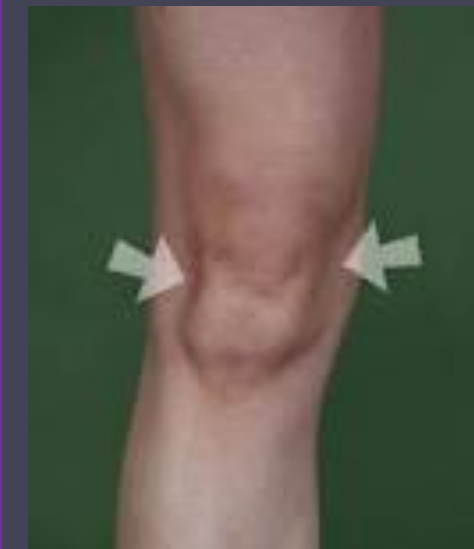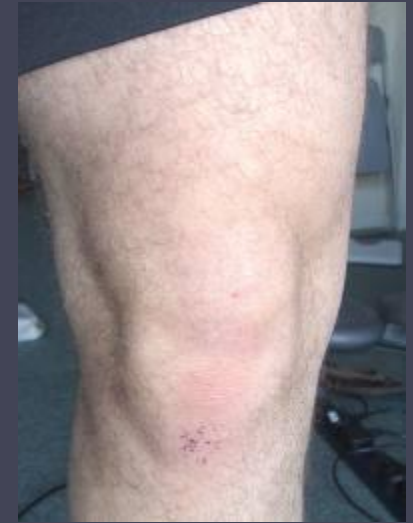The 'ripple test' (Bulge, Milking)

The patellar tap

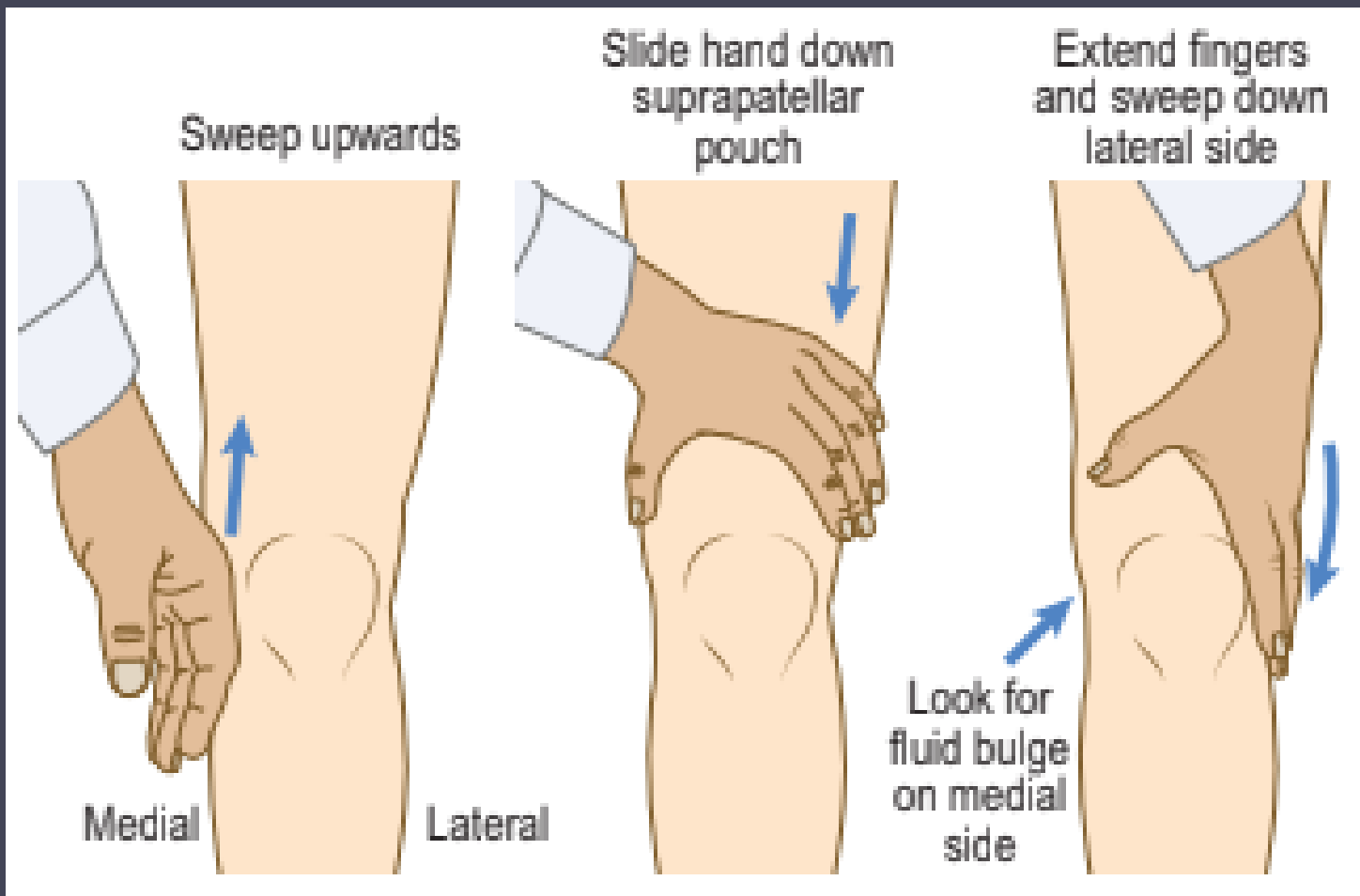
Fluctuation

Synovitis: sponginess

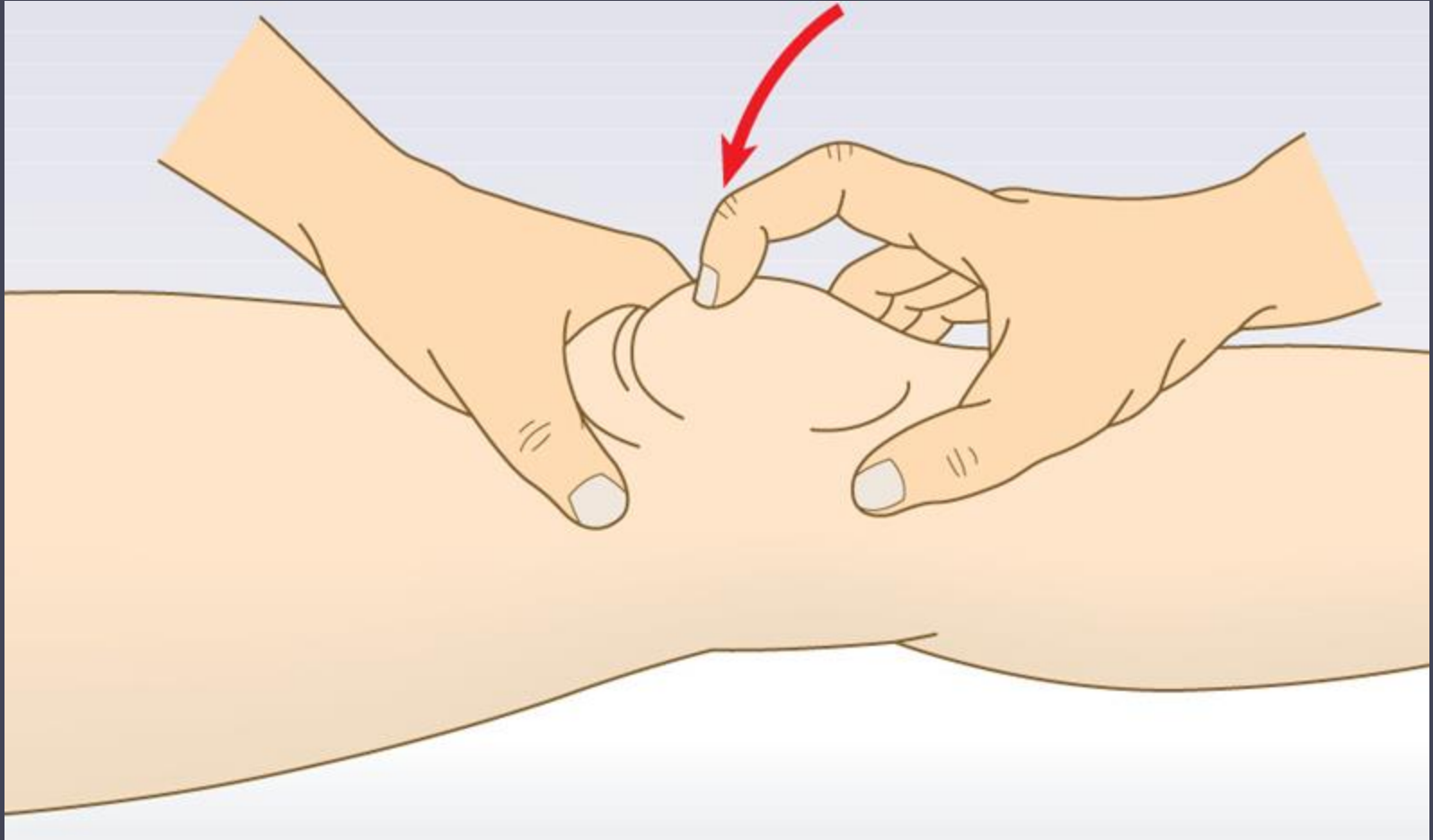
Joint lines



Ripple Test



Patellar Tap



Move . . .

- Active flexion and extension:

Supine

0-140

Feel for crepitus

- Extensor apparatus (SLR) Vs. Fixed flexion deformity

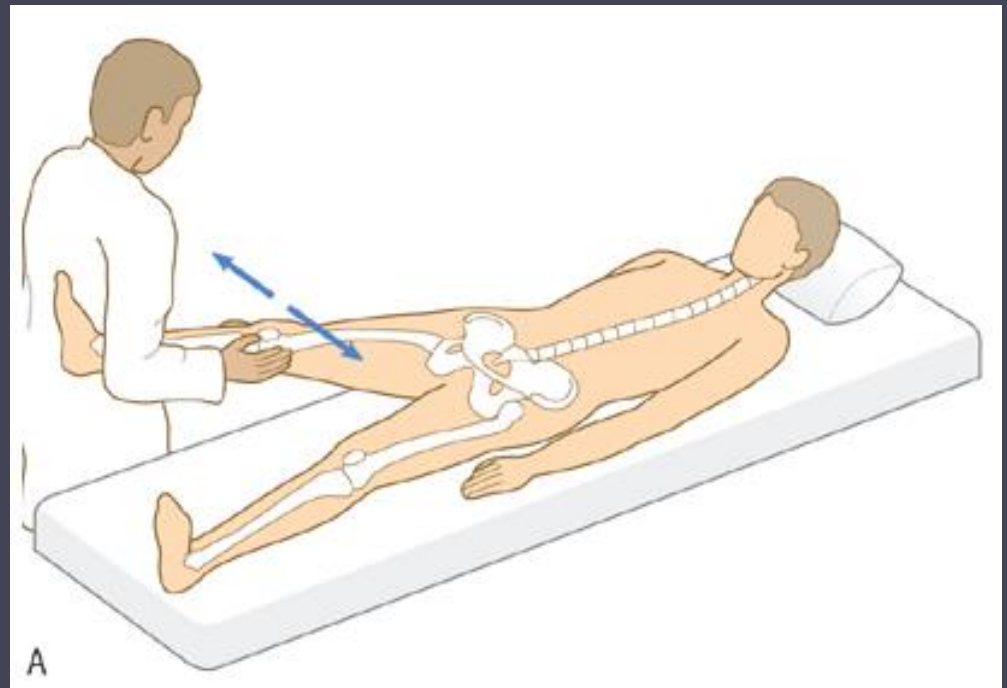
- Passive flexion and extension:

Genu recurvatum-10 is normal

Special Tests:

Collateral Ligaments:

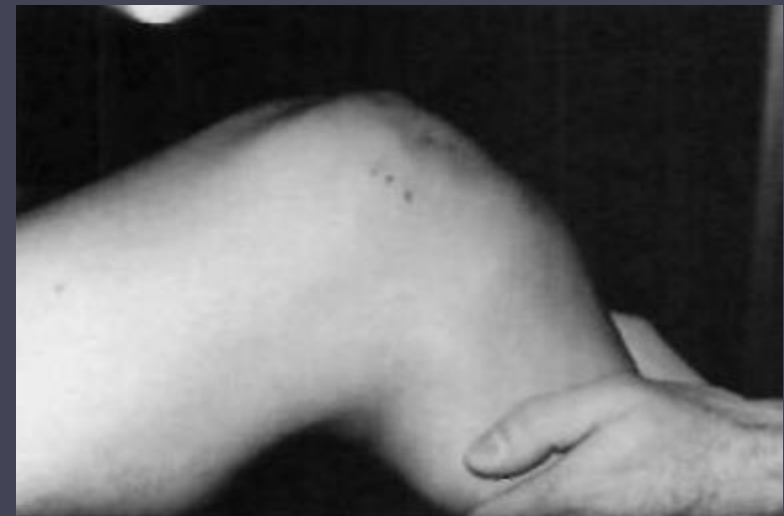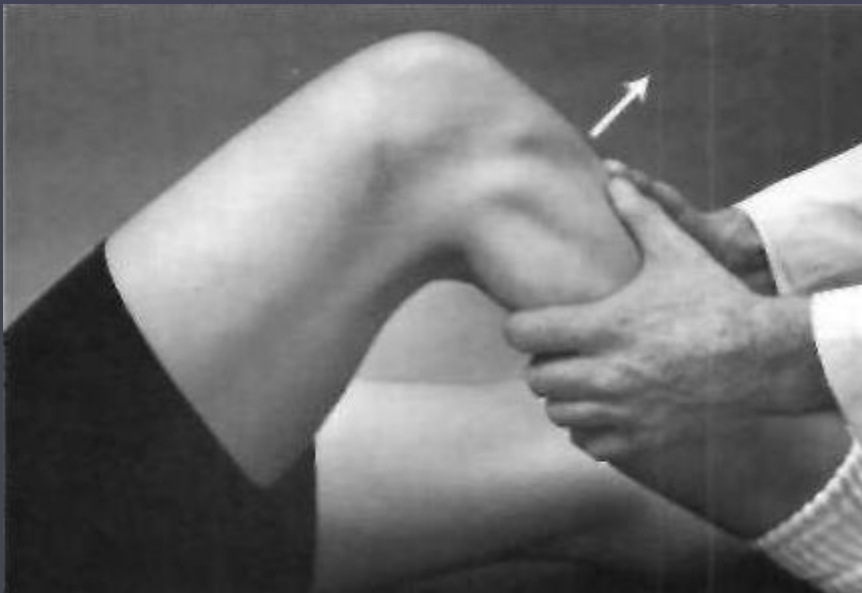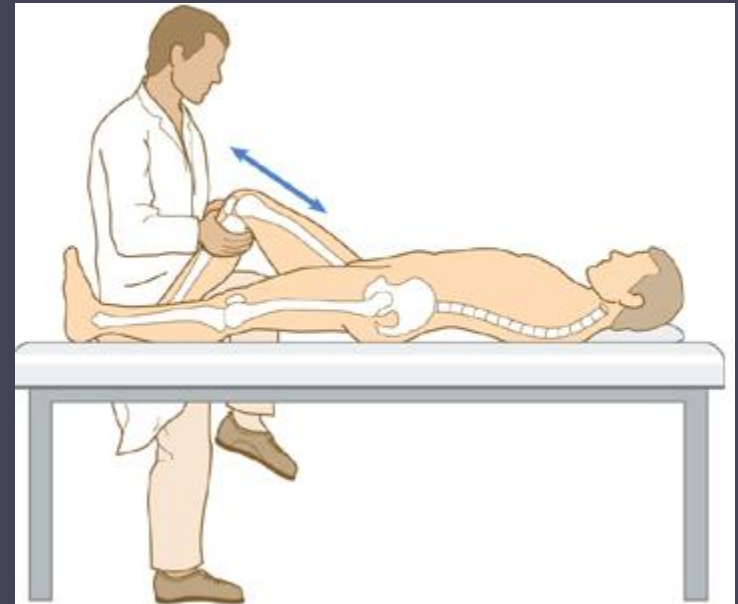
Varus & valgus stress tests



Special Tests:

**Cruciate
Ligaments:**

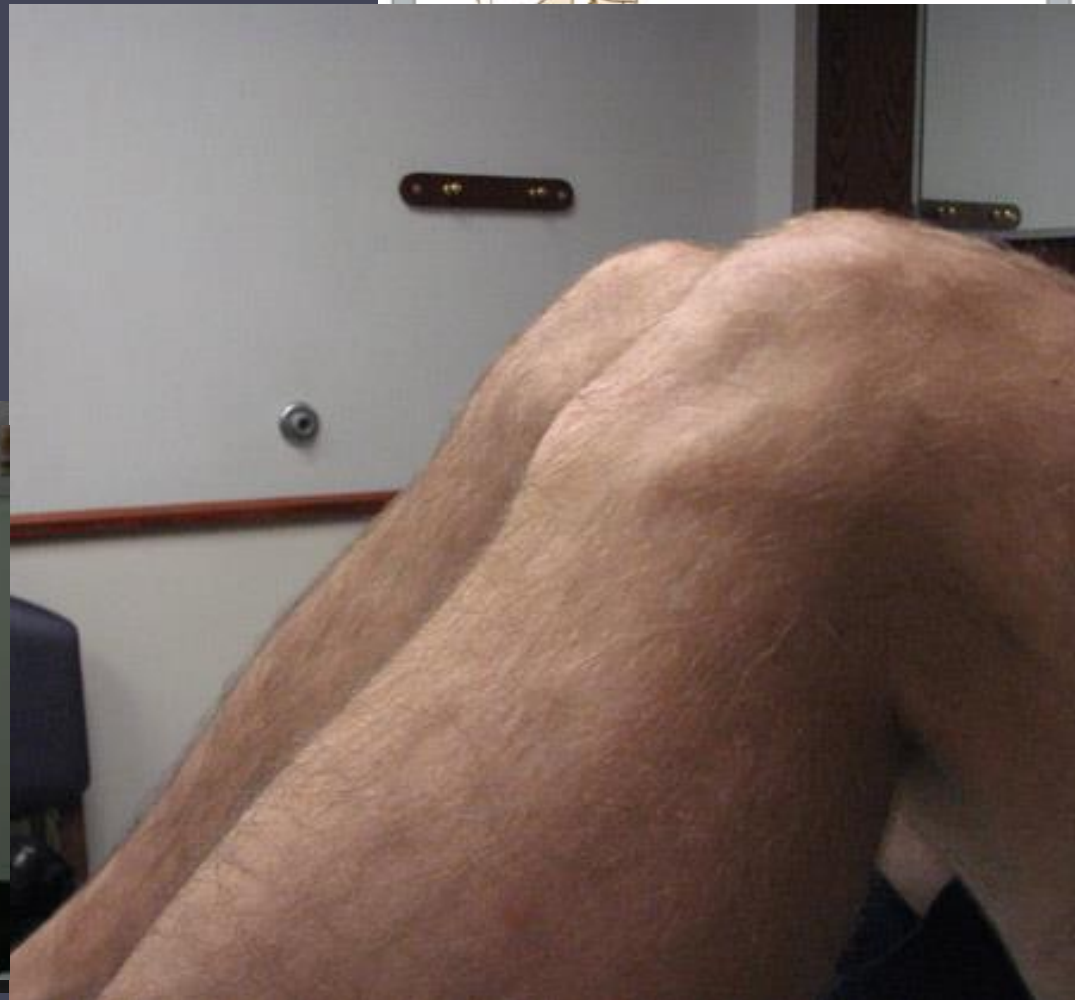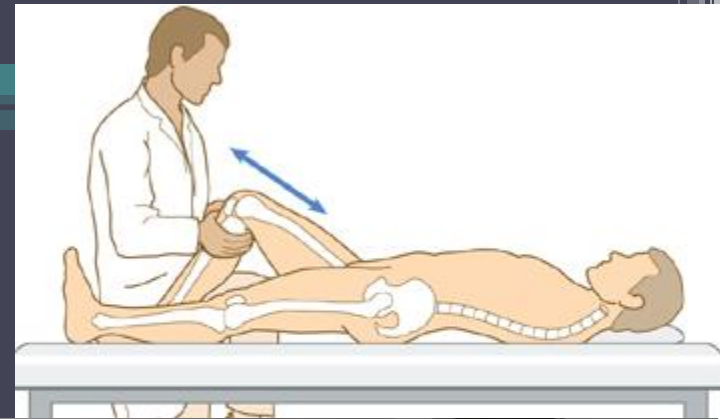
**Anterior
drawer (ACL)**



Special Tests:

**Cruciate
Ligaments:**

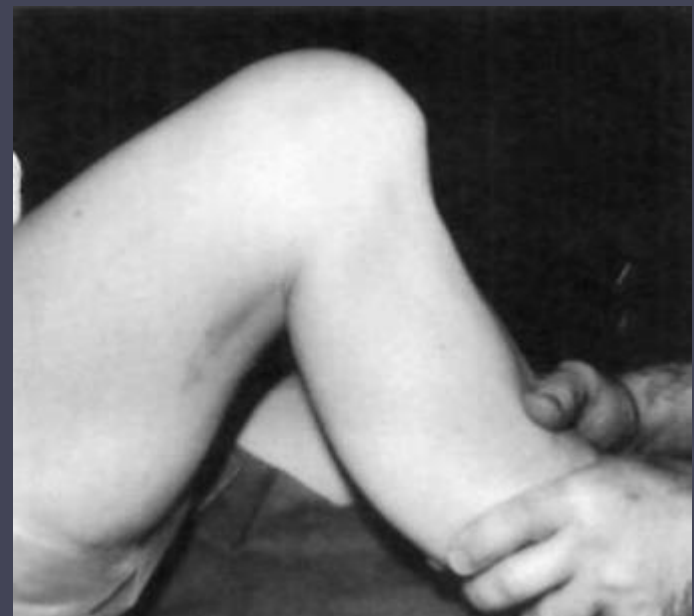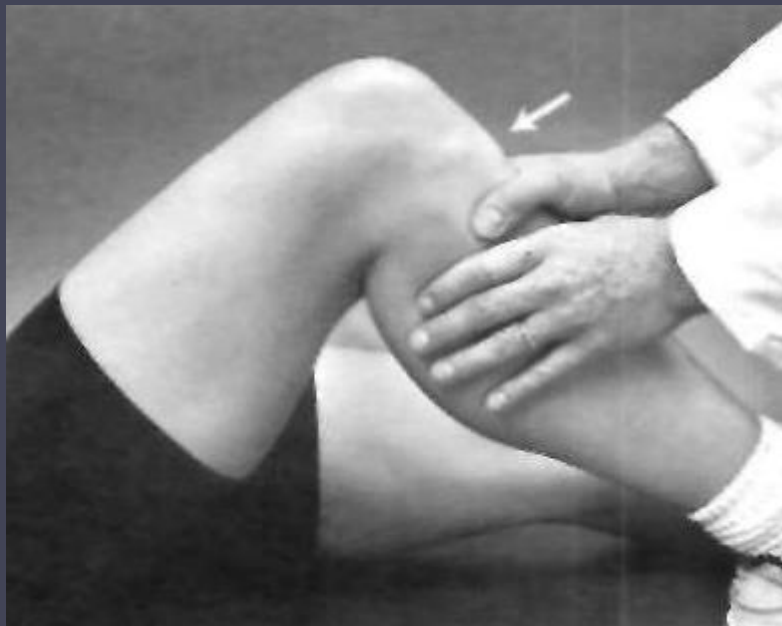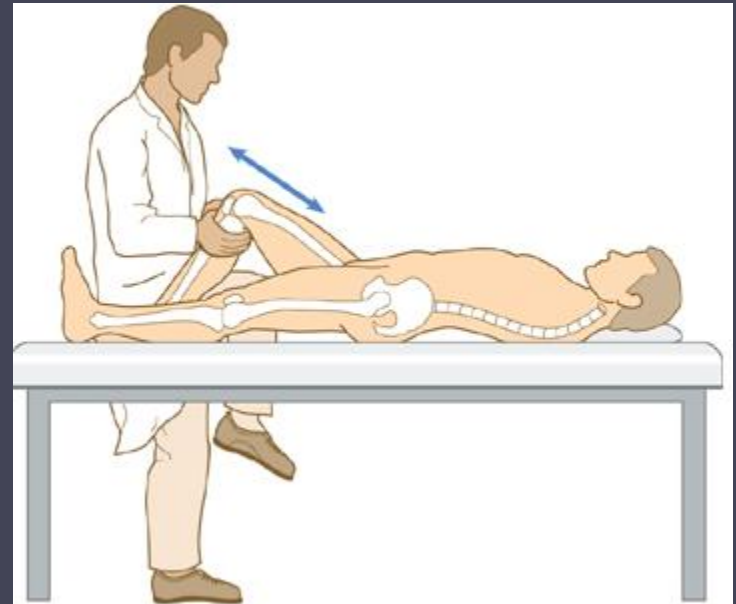
**Anterior
drawer (ACL)**



Special Tests:

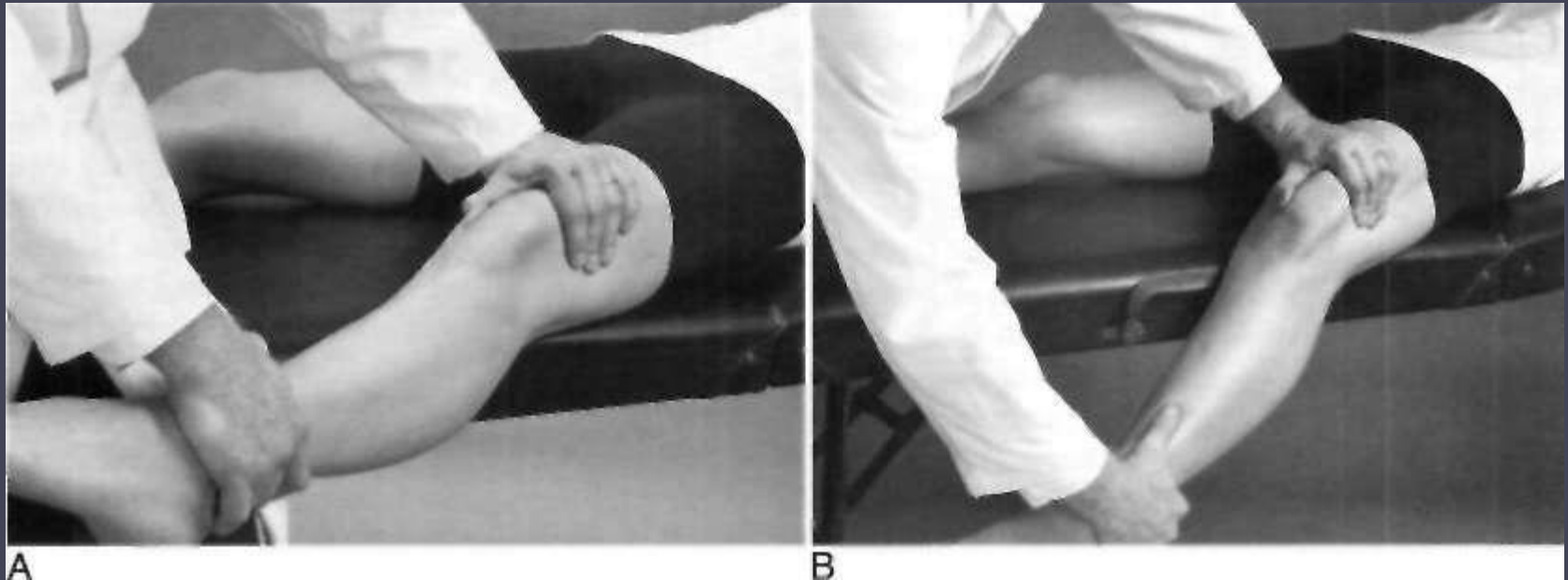
**Cruciate
Ligaments:**

**Posterior
drawer (PCL)**



Special Tests:

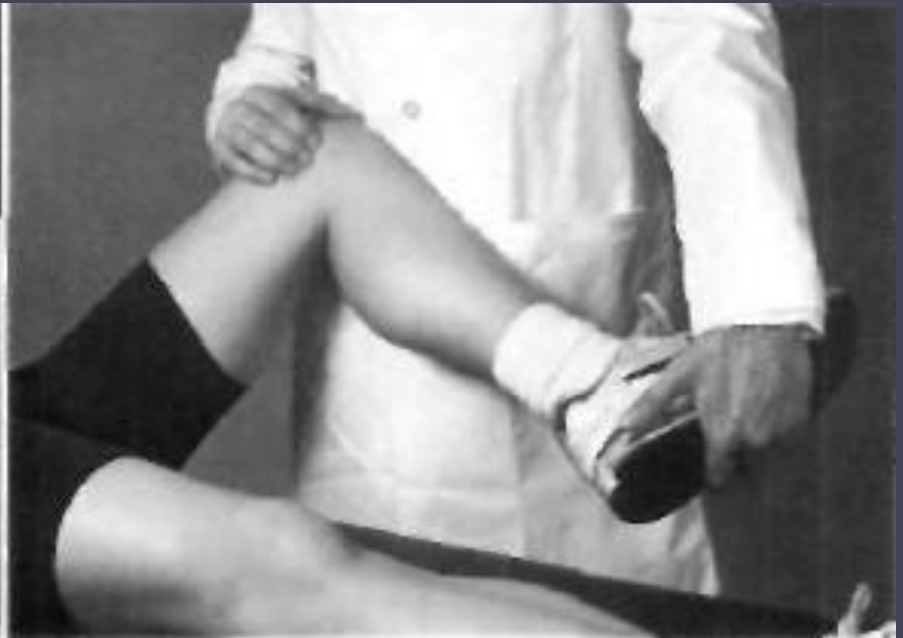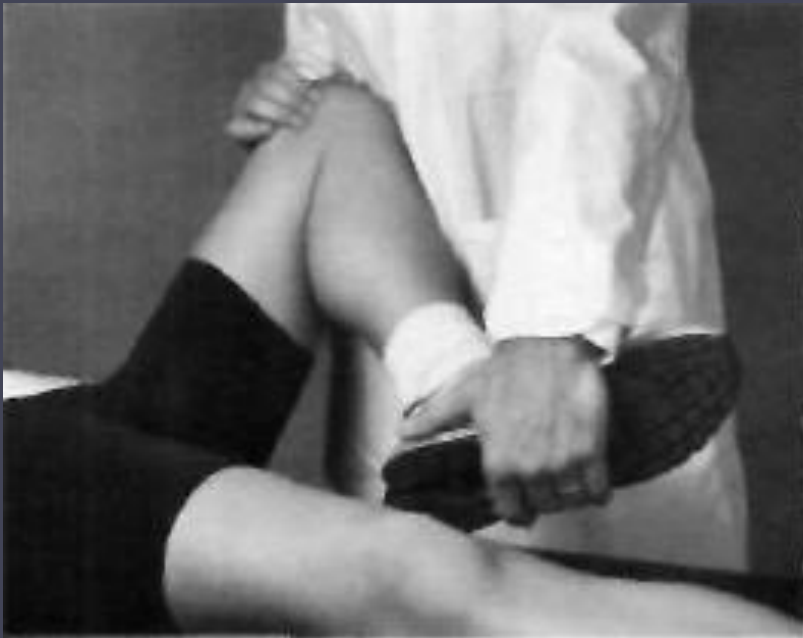Patellar apprehension test



Special Tests:

Medial Meniscal tears:

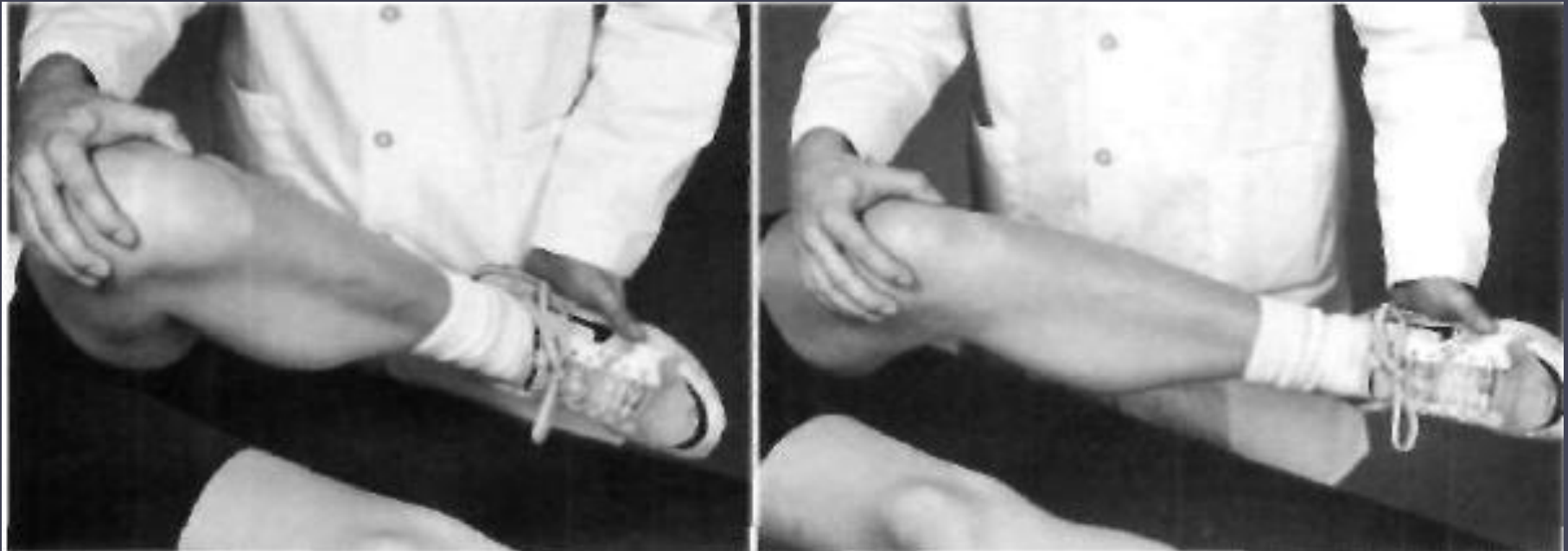Medial McMurray test



Special Tests:

Lateral Meniscal tears:

Lateral McMurray test



THANK
YOU

