



# Test Bank



**Subject:**

**Intro-3<sup>rd</sup> Theoretical**

**Quiz**

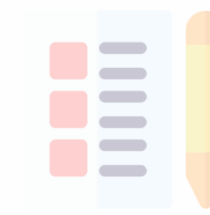

**Collected by:**

**Ameen Alsaras**

**Noor Adnan**

**Samia Sami**

**Dena Kofahi**



بجانب

# 009 3<sup>rd</sup> Quiz

1-Ramsay hunt syndrome is:

- severe lower motor neuronal lesion involving 7th cranial nerve

2-Which of the following is true:

- bilateral upper motor neuronal lesion above the level of the pons causes brisk jaw reflex

3-A patient is present with right homonymous hemianopia, and no mentioned motor loss. Where is the lesion?

- left temporoparietal lobe

4-Patient with Lt visual field inattention, Lt side paralysis, Lt side negligence (Rt non-dominant hemisphere lesion). The patient does not have:

- Apraxia

5-All of the following support the diagnosis of epileptic seizure over vasovagal syncope except:

- upright posture restores consciousness

6-All of the following can be seen in a patient with carpal tunnel syndrome except:

- loss of sensation over thenar muscles

7-All of the following can be seen in a patient with acute presentation of an UMNL except:

- muscle atrophy

8-Which of the following can be seen in a patient with brown Sequard syndrome:

- ipsilateral extensor planter reflex

9-All of the following is true except:

- loss of meningism always exclude meningitis

10-Patient after knee replacement surgery (injury to common peroneal nerve). All of the following are found except:

- loss of sensation on the inner aspect of the leg

11-Air conduction is better than bone conduction on both ears, in Webers's test sound lateralizes to right ear:

- left sensorineural hearing loss

12-Non-febrile symptoms, neck stiffness and positive Kernig's sign:

- subarachnoid heamorrhage (SAH)

13- One of the following produces diffuse goiter:

- Graves disease

Answer:

14-A patient, non vocalized, opens eye to pain, and has abnormal flexion to pain.

What is his glasgow coma scale score?

- 6

15-All of the following can be seen usually in a Parkinson patient except:

- symmetrical hand rest tremor

16-Patient of hyperlipidemia with proximal myopathy. Which of the following drugs might be the cause?

- Statins

17-Patient presented with ipsilateral loss of sensation on face, contralateral loss of sensation on body, deviation of tongue on protrusion, which of the following causes this pattern of symptoms?

- **Medullary infarction**

18-Ankle dorsiflexion intact, but loss of ankle tendon reflex. A lesion in which of the following might causes this?

- **L5/S1**

19-Patient with convulsions, loss of consciousness, confusion, no prodromal phase:

- **Generalized seizure**

20-Which of the following indicates isolated tear of lateral collateral ligament of knee joint:

- a. with the knee fully extended, applying a varus will make a cleft laterally
- b. with the knee 30 flexed, applying a varus will make a cleft laterally

Answer: b

21-All of the following support your diagnosis of carpal tunnel syndrome except:

- a. thenar muscle atrophy
- b. tinel's sign
- c. reproduction of symptoms by reverse prayer sign
- d. loss of opposition of thumb
- e. forment's sign

Answer: e

22-A wife house cut her wrist parallel to wrist crease and proximal to it, all of the following can be found except:

- a. partial cut of FDS tendon as the patient can't flex her DIP of middle finger
- b. complete cut of FDS tendon as the patient can't flex her ring finger to her palm
- c. cut of FDS and FDP as the patient can't flex her index finger at all
- d. ulnar nerve cut as the patient lost sensation on ulnar side of the hand
- e. median nerve cut as the patient lost sensation on radial side of index

Answer: a

23-All true except:

- pain disproportionately greater than expected is benign joint arthritis

24-All true except:

- chronic Charcot joint... painful joints

25-Ankyloising spondylitis, all are true except:

- loss of neck lordosis

26-Regarding the innervation of the hand, the wrong statement:

- adductor muscles of the thumb are supplied by radial nerve

27-All are seronegative arthritis except:

- a. rheumatoid arthritis
- b. psoriatic arthritis

Answer: a

28-All are associated with reactive arthritis except:

- a. otitis media
- b. conjunctivitis
- c. mouth ulcers
- d. genital ulcers
- e. right knee effusion

Answer: a

29-All are red flags for lower back pain except:

- a. weeks age > 55
- b. a duration of more than 2
- c. urinary incontinence

d. fractures

Answer: b

30-The mismatched drug with its side effect:

- steroids >> positive antinuclear antibody

31-The true statement about rheumatoid nodules:

- a. can occur in the lung
- b. they're tender
- c. they're hard
- d. located at the flexor surface of the forearm
- e. they are seronegative for rheumatoid factor

Answer: a

32-Choose the correct match:

- graves' disease >> digital acropachy

## 014 3<sup>rd</sup> Quiz

1-True about Schober test:

- More than 20 cm is normal

2-All of the following are red flags except:

- Patient believes he has cancer

3-Clinical case in which patient has severe knee pain, tenderness, swelling, fever and malaise:

- Septic arthritis

4-Clinical case in which a patient is present with arthritis and has a history of diarrhea and vomiting. which of the following is wrong?

- It is associated with positive rheumatoid factor

5-Clinical case in which young man with positive family history of IBD and gradual back pain; which will you find upon cervical exam:

- Increased lordosis

6-Clinical case in which 25 year old male presented to ER complaining knee pain of 1 day duration associated with erythema and hotness, least likely diagnosis:

- RA
- septic arthritis
- gout
- hemophilia

Answer: a

7-Clinical case in which patient with anterior deviation of tibia with past history of trauma, the injury is in:

- Anterior cruciate ligament

8-Clinical case in which patient with pain upon internal rotation and varus of the leg:

- Trauma in lateral meniscus

9-Clinical case in which patient with numbness in thumb, index and middle finger indicating:

- Median nerve entrapment

10-Clinical case of RA, all are found except:

- Sacroiliitis

11-Clinical case of osteoarthritis, which of the following is least likely to see?

- Bouchard nodes on the extensor surface of the forearm

12-Clinical case of benign single thyroid nodule. what of the following is wrong?

- This nodule is typically fixed to its surrounding structures

13-Clinical case in which adult female, BP=170/90, 36.7 C, with minimal lid lag.

Which of the following is true?

- menstrual irregularities can be seen in this disease

14-Which of the following is wrong about thyroid:

- Most patients with goiters are hyperthyroid patients

## 017 3<sup>rd</sup> Quiz

1-Wrong about cluster headache:

- rapid in onset
- during cluster pain is always at the same side
- associated with conjunctival injection
- remission can reach to years
- more common in females than males

Answer: e

2-Change in personality + urinary incontinence + partial motor weakness in one side on lower limbs (4/5 power) which of the following is involved?

- anterior circulation
- vertebral basilar

Answer: a



3-Anterior spinal artery syndrome, which is not affected:

- a. pain + temperature
- b. autonomic
- c. motor
- d. vibration + proprioception

Answer: d

4-Neck stiffness + kernig's sign + blood pressure 180/120 +no fever. The diagnosis is most likely:

- a. subarachnoid hemorrhage
- b. Meningitis

Answer: a

5-Which of the following is wrong about cranial nerve V innervations?

- a. mastication muscles
- b. taste of anterior 2/3 of tongue
- c. corneal reflex

Answer: b

6-Which of the following is wrong about upper motor neuron lesion?

- a. cause pseudobulbar palsy
- b. cause dysarthria and dysphonia
- c. cause dysphagia
- d. cause weakness and fasciculation
- e. cause brisk jaw jerk

Answer: d

7-Primitive reflexes are due to?

- a. Frontal lobe damage

- b. Temporal lobe damage
- c. Parietal lobe damage

Answer: a

8-Wrong about carpal tunnel syndrome:

- a. it can radiate to arm
- b. typical at Night
- c. affect adductor of thumb
- d. most common entrapment neuropathy

Answer: c

9-A patient's left eye is deviated out and downward with some diplopia. His right eye is normal and both eyes are reactive to light, he has HTN and DM, what is the cause:

- a. 3<sup>rd</sup> nerve palsy
- b. 4<sup>th</sup> nerve palsy
- c. diabetic neuropathy
- d. 6<sup>th</sup> nerve palsy
- e. 7<sup>th</sup> nerve palsy

Answer: a

10-Positive Rinne's test at both side with sound deviated to left on Weber's test what is the cause?

- a. left sensorineural loss
- b. right sensorineural loss
- c. right +left sensorineural loss

Answer: b

11-Joint not involved in rheumatoid arthritis

- a. MCP

- b. PIP
- c. cervical spine
- d. lumber spine
- e. wrist joints

Answer: d

12-Case of knee joint pain + conjunctivitis + urethritis two days ago:

- a. reactive arthritis
- b. gout
- c. rheumatoid arthritis

Answer: a

13-Joint pain with pitting and nail separation from nail bed?

- a. rheumatoid arthritis
- b. reactive arthritis
- c. pseudogout
- d. psoriatic arthritis

Answer: d

14-Child with fever + joint pain + recent gastroenteritis:

- a. reactive arthritis
- b. septic arthritis
- c. rheumatoid arthritis
- d. gout

Answer: a

15-Which of the following is not a red flag in low back pain?

- a. Fever
- b. faecal incontinence
- c. chronic low back pain

d. perineum sensory loss

Answer: c

16-Which of the following is the least specific to graves disease?

- a. Exophthalmos
- b. Pretibial myxedema
- c. Lid retraction
- d. Thyroid bruits

Answer: c

17-Wrong match:

- a. Pressure speech with hypothyroidism
- b. Goitre with euthyroid patients
- c. midsystolic murmur with hyperthyroidism
- d. hashimoto with diffuse neck swelling

Answer: a

## FINALS

1-Right homonymous hemianopia with macular sparing, which lobe is affected?

- a. parietal
- b. temporal
- c. occipital
- d. frontal

Answer: c

2-Someone with sudden loss of consciousness for 1 minute , she reported no confusion after waking, her sister had similar symptom, her mother died recently from heart block, what is the cause:

- a. seizure

- b. vasovagal syncope
- c. heart block

Answer: c

3-Someone neglect his left side and when drawing a clock he draws the right side only, which lobe is affected:

- a. frontal
- b. parietal
- c. occipital
- d. temporal

Answer: b

4-Which of the following is not in the cavernous sinus:

- a. Abducent
- b. ophthalmic division v1
- c. mandibular division v3
- d. trochlear
- e. maxillary division v2

Answer: c

5-A patient is present with movement tremor in his upper limb bilateral and sometimes involves the head, his mother has the same condition, choose the right about his condition:

- a. it is not very common
- b. alcohol can help
- c. beta blocker can cause this

Answer: b

6-In facial nerve injury, all of the following happens except:

- a. high pitched sound

- b. deviation of the mouth
- c. smiling is affected
- d. unable to close his eye

Answer: a

7-A man is unable to walk on his heels and has foot drop, what is the cause?

- a. common peroneal nerve injury
- b. peripheral neuropathy
- c. muscular problem

Answer: a

8-All of the following might cause dilated pupils except:

- a. atropine (anti-cholinergic agent)
- b. physiological
- c. Adie's tonic pupil
- d. Pilocarpine (parasympathomimetic agent)

Answer: d

9-Which of the following is not related to hyperthyroidism:

- a. amenorrhea
- b. proximal muscle weakness
- c. delayed relaxation of knee reflex
- d. diarrhea

Answer: c

10-Patient came with sudden very painful joints in addition to erythema and hotness. He is on dialysis. What is the most likely diagnosis?

- a. gout
- b. Rheumatoid arthritis
- c. SLE

- d. osteoarthritis
- e. septic arthritis

Answer: a

11-Raynaud's syndrome occur in all of the following except:

- a. SLE
- b. Rheumatoid arthritis
- c. Rheumatic fever
- d. systemic sclerosis
- e. sjogren syndrome

Answer: c

12-Choose the right sentence:

- a. locking is incomplete movement due to pain
- b. Heberden nodes in PIP
- c. Bouchard nodes in DIP
- d. pseudolocking is incomplete movement due to anatomical block
- e. Boutonniere deformity is flexion on PIP + hyperextension on DIP

Answer: e

13-Choose the wrong sentence:

- schober test is normal when lumbar vertebra moves 2cm

14-Knee instability to varus on 0 and 30 degree flexion. What is affected?

- a. Anterior cruciate ligament
- b. medial collateral
- c. lateral collateral
- d. medial menisci
- e. lateral menisci

Answer: c

15-Women takes ciprofloxacin (quinolone) + statins + glucocorticoids, she recently had Achilles tendon rupture, what is the cause?

- a. ciprofloxacin
- b. glucocorticoid
- c. statin
- d. lack of mobility

Answer: a

16-A patient is present with shingle-like rash around eyes. What is the cause?

- Herpes varicella zoster virus

17-A girl was playing under the sun, lost consciousness shortly, and recovered immediately:

- vasovagal attack

18- Which of the following is least connected to a vasovagal attack:

- duration of loss of consciousness of 3 minutes

19-Not in UMNL:

- hand fasciculation

20-Patient with asymmetrical face, mouth deviates to left, preserved frontal wrinkles:

- UMNL of left VII nerve

21-Not part of trigeminal exam:

- platysma power

22-Boy with memory loss, inappropriate social behavior, incontinence, mother thinks he is “mahsood”:

- frontal lobe lesion



23-Patient undergoing right temporal lobectomy, she would have:

- left upper quadrantanopia

24-Patient with visual hallucinations, agnosia and macropsia:

- secondary visual areas lesion

25-A hypertensive patient presented with sudden severe headache with neck stiffness:

- subarachnoid hemorrhage

26-A patient with hesitant gait, little arm swing, short steps:

- Parkinson's disease

27-A girl with rapid, brief, purposeless movements:

- chorea

28-Man with fluent, but meaningless speech:

- Wernicke's area lesion

29-Not a cause of fast fine tremor:

- exercise

30-Ruptured tendon Achilles:

- quinolone

31-True about meniscal tear:

- minimal effusion in about 24 hours

32-Wrong about the knee:

- posterior cruciate ligament prevents posterior subluxation of femur on tibia

33-True about knee:

- suprapatellar pouch is an extension of synovial membrane beneath quadriceps

34-Not part of the wrist joint:

- Ulnoradial joint

35-True about spine:

- kyphosis is curvature in sagittal plane with posterior apex

36-Not a red flag symptom of back pain:

- sole paresthesia

37-Not a cause of lower back pain:

- rheumatoid arthritis

38-Causes splenomegaly and leg ulcers:

- rheumatoid arthritis

39-Wrong about cervical spine:

- flexion, extension and lateral flexion happen at the distal segments

40-Sudden toe pain with redness, tenderness, hotness:

- acute gouty attack

41-All are metabolic causes of myalgia except:

- Rhabdomyolysis

42-Patient with morning stiffness for less than 10 minutes with crepitation:

- Osteoarthritis

43-Sudden onset of lower back pain after lifting heavy object:

- Acute disc protrusion

44-Not a red flag for acute lower back pain:

- IBS

45-Atrophy of the thenar muscles and numbness of the palm of hand occurs in:

- Median nerve entrapment

46-Wrong about frozen shoulder:

- It is called calcific tendonitis

47-Wrong about the anterior cruciate ligament:

- It gives way (is unstable) when valgus stress is applied to the knee

48-Case of reactive arthritis, all are related except:

- Aortic regurgitation

49-Case of rheumatoid arthritis, which is not accurate:

- a. Can be associated with malar rash
- b. Can be mono, oligo, or polyarticular

Answer: a

50-Wrong about rotator cuff muscles:

- Subscapularis>>> external rotation

51-Left sided headache with lacrimation:

- Cluster headache

52-Acute recurrent headache except:

- Cervicogenic

53-A woman received news that her father died and lost consciousness. What occurred?

- Vasovagal attack

54-Fever, neck stiffness and altered level of consciousness:

- Meningitis

55-Lower motor neuron lesions:

- Fasciculations

56-Proximal muscle weakness:

- Waddling gait

57-Disinhibition, change in behavior and urinary incontinence:

- Frontal lobe lesion

58- An open-heart surgery resulted in restricted tongue movement and absent gag reflex, where is the lesion?

- Cranial nerves IX, X and XII

59-Mismatching?

- Nipple>>>T4

60-Repetitive knee compression, which is incorrect:

- Foot drop caused by injury to tibial nerve

61- A patient opens their eyes in response to pain, vocalizes sounds and exhibits flexion withdrawal to pain. What are their Glasgow Coma Scale scores?

- E2,V2,M4

62-Overshooting and intention tremor in the left side, where is the lesion?

- Left cerebellar hemisphere

63-Right sensory loss of hearing; what is true?

- .Weber test localizes to left and positive right Rinne test

64-Enlarged blind spot?

- Papilloedema

65-Lesion in right parietal lobe:

- **Left inferior quadrantanopia**

66-Patient with inferiolaterally shifted right eye, what occurs when you test the pupillary reflex?

- **The pupil of the right eye will not constrict while the pupil of the left will constrict**

67- A patient with occipital triangle injury cannot turn his head to the right and is unable to shrug his left shoulder. They also have impaired sensation of the posterior one third of the tongue. You will find:

- **Dry mouth**

68- A 25-year-old lady with double vision, weakness of her arms and family history of thyroid disease, most likely the diagnosis is:

- multiple sclerosis**
- myasthenia gravis**

**Answer:** Both could technically be true, but since we emphasized symptoms of MS are separated in time and space, B may be the correct answer.

69-Left upper motor neuron lesion:

- **Increased tone of right upper limb muscles**

70-Parotid gland surgery results in all of the following neurological symptoms except:

- **Decreased general sensation of anterior two thirds of the tongue**

71- A 70-year-old man with change in behavior and a tendency to be alone, the most likely diagnosis is:

- Alzheimer disease**
- Parkinson**

Answer: a

72- 65-year-old male patient experienced recurrent fallings and now has behavioral changes of two weeks duration:

- **Chronic subdural hematoma**

73- All of the following are specific for Grave's disease except:

- a. acropachy
- b. exophthalmos
- c. periorbital edema
- d. myxedema
- e. ophthalmoplegia

Answer: c

74-Patient with hyperthyroidism, you will find all of the following except:

- **Dry skin**

75-Wrong about thyroid gland and its diseases:

- **Goiter indicates hyperthyroidism in most cases**

76-Not found in hypothyroidism:

- **Oligomenorrhea**

77-Finger changes with loss of skin wrinkles and beaking of the nose:

- **Systemic sclerosis**

78-A patient with RA underwent surgery and anesthesia and developed paraplegia shortly after, what is the most likely cause of this?:

- **Atlanto-axial instability**

79-A patient presented with cough of 9 months duration, physical exam revealed tightening of skin around the lips and late fine crackles, what is the most likely Dx:

- a. Sjögren with....
- b. systemic sclerosis with pulmonary fibrosis
- c. systemic sclerosis with pulmonary effusion

Answer: b

80-A 54-year-old patient that undergoes hemodialysis presented to the clinic with pain in their elbow joint that began last night, and they were barely able to move the joint, even putting it on the bed was painful. Physical exam revealed erythema, redness, effusion in the joint. What is the most likely cause?:

- a. Gout
- b. Osteoarthritis

Answer: a

81-Case where the patient drew only the right side of a house, shaves only their right side, and when asked to raise their hands they only raise their right hand. Which part of the cortex did a stroke occur in?:

- Right Parietal

82-Loss of half of the visual field with macular sparing, where is the lesion:

- Occipital cortex

83- Eye movement pain with vesicular rash on forehead, eye, and nose:

- Herpes ophthalmicus

84-Facial paralysis of both upper and lower face on the right, which is least likely associated with it:

- a. high pitched noises appear louder
- b. inability to close right eye
- c. Deviation of mouth to right when smiling

Answer: c

85- A young male presents with pain in his buttocks only and not his legs. It first appeared 5 years ago and then dissipated, and now came back. It wakes him up from sleep and he has prolonged stiffness in the morning. The patient has a history of abdominal pain diarrhea. Which of the following support the most likely Dx:

- a. Modified Schober index of 2 cm
- b. motor weakness in both legs

Answer: a

86-Which of the following is least likely associated with psoriasis:

- a. Onycholysis
- b. Nail pitting

Answer: None of the above

87-Pain in knee, on examination varus stress increased pain and displaced the knee outside, which is the structure most likely injured:

- a. Meniscus tear
- b. medial collateral ligament
- c. lateral collateral ligament
- d. patellar dislocation

Answer: c

88-A patient with tremor upon moving his hand reports that his mother also has tremor, what is most likely true about its Dx:

- Improves with alcohol

89-The least likely to be associated with Raynaud's phenomenon is:

- a. Systemic Sclerosis
- b. Rheumatoid arthritis
- c. SLE
- d. Sjögren



**e. Rheumatic Fever**

**Answer: e**

**90-Which of the following is true about superficial reflexes?**

- **The abdominal reflex can be absent in healthy people**

**91-A patient is able to extend his elbow while standing, but unable to extend it while prone. What's the muscle power scale according to medical research council scale:**

- a. 1**
- b. 2**
- c. 3**
- d. 4**
- e. 5**

**Answer: b**

**92-All of the following are normal in the thumb except:**

- **Froment's sign**

**93-Which of the following resists varus stress at knee:**

- a. LCL only at 30 flexion**
- b. LCL only at full extension**
- c. LCL only at 90 flexion**
- d. MCL only at 30 flexion**
- e. MCL only at 90 flexion**

**Answer: a**

**94- A patient with aphasia and UMNL symptoms on the right side of the body, which is the cause:**

- **obstruction of the left middle cerebral artery**

95-Which of the following is true about cerebellar lesions:

- a. finger nose test can be negative in tumors involving the vermis
- b. rt hemisphere lesion causes abnormality of the contraletral side of the body
- c. result in hyper-reflexia

Answer: A

96-All are true except :

- expressive dysphasia patients have fluent speech

97- which of the following isn't associated with HLA b27 :

- a. reactive arthritis
- b. ankylosing spondylitis
- c. crohn's disease
- d. rhematoid arthritis
- e. psoriatic arthritis

Answer: d

98-The most common cause of low back pain is:

- a. disc prolapse
- b. degenerative change
- c. tumors

Answer: b

99-All supplied by the median nerve except:

- abductor digiti minimi

100-All of the following is true about a Parkinson's patient except:

- tremor present on hand movement

101- Loss of consciousness in generalized seizure occurs at which phase:

- tonic phase

102-Analgic gait is caused by:

- lower limb pain

103-A patient with carpal tunnel syndrome, after having surgery to remove the pressure over the median nerve, will have all of the following return back to normal except:

- Wasting of the thenar muscles

104- All of the following are true of musculoskeletal system except:

- deltoid muscle initiates abduction of the shoulder joint

105-Which of the following is not a member of rotator cuff muscles:

- teres major

106-(loss of pin prick + touch + stereognosis) at right side, and mouth deviation to left side indicate lesion at which level:

- a. right parietal lobe
- b. right thalamus
- c. cervical spine

Answer: a

107-Weber's test in the middle, both ear bone conduction better than air conduction:

- bilateral conductive deafness

108-Case... anterior spinal syndrome, all found except:

- positive romberg's test

109- All of the following matches are true except:

- abductor pollicis brevis : radial nerve

110-All can be caused by a lesion in the temporal lobe except:

- apraxia

111-In the comparison btw bulbar and pseudobulbar palsy, all are true except:

- in bulbar palsy there is emotional lability

وليس على الإنسان إنجاز سعيه

ولكن عليه أن يُجيدَ المساعي

اذكرونا بدعوة. ✨