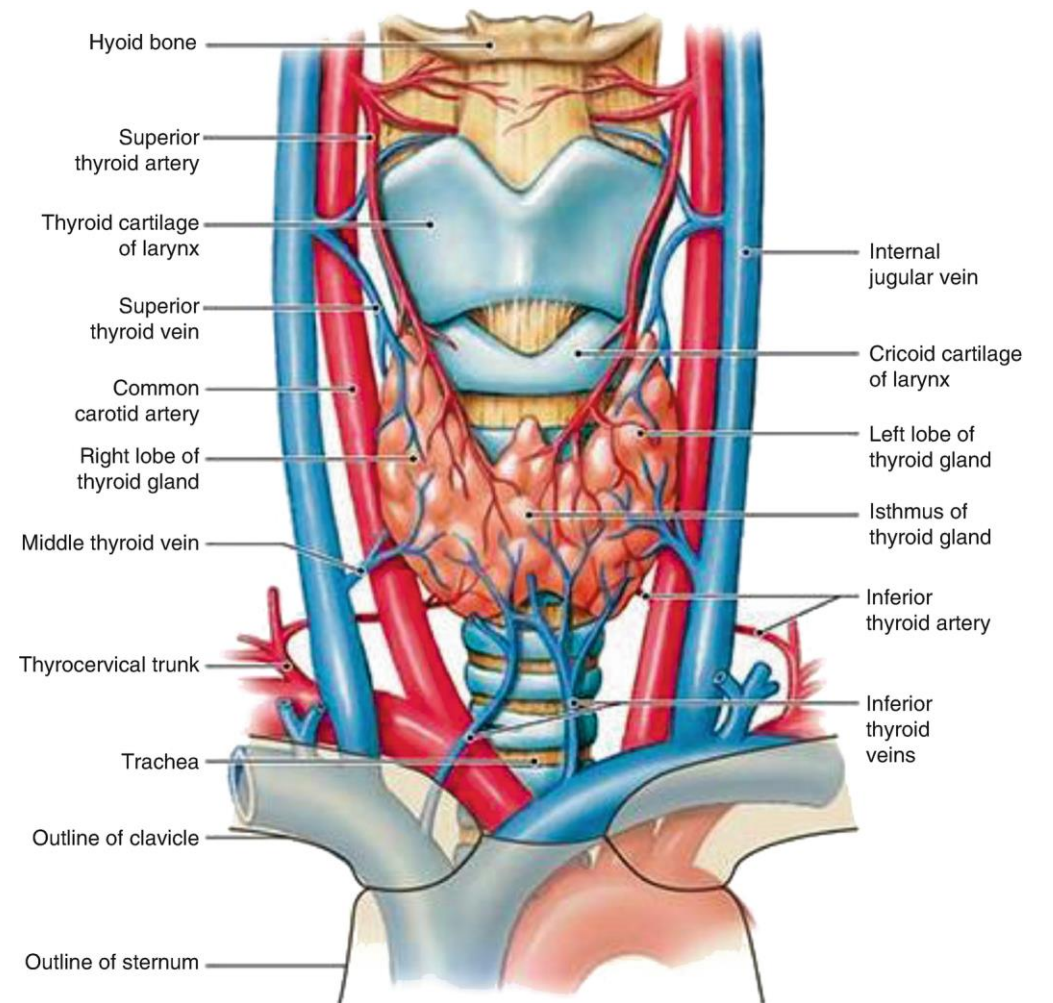
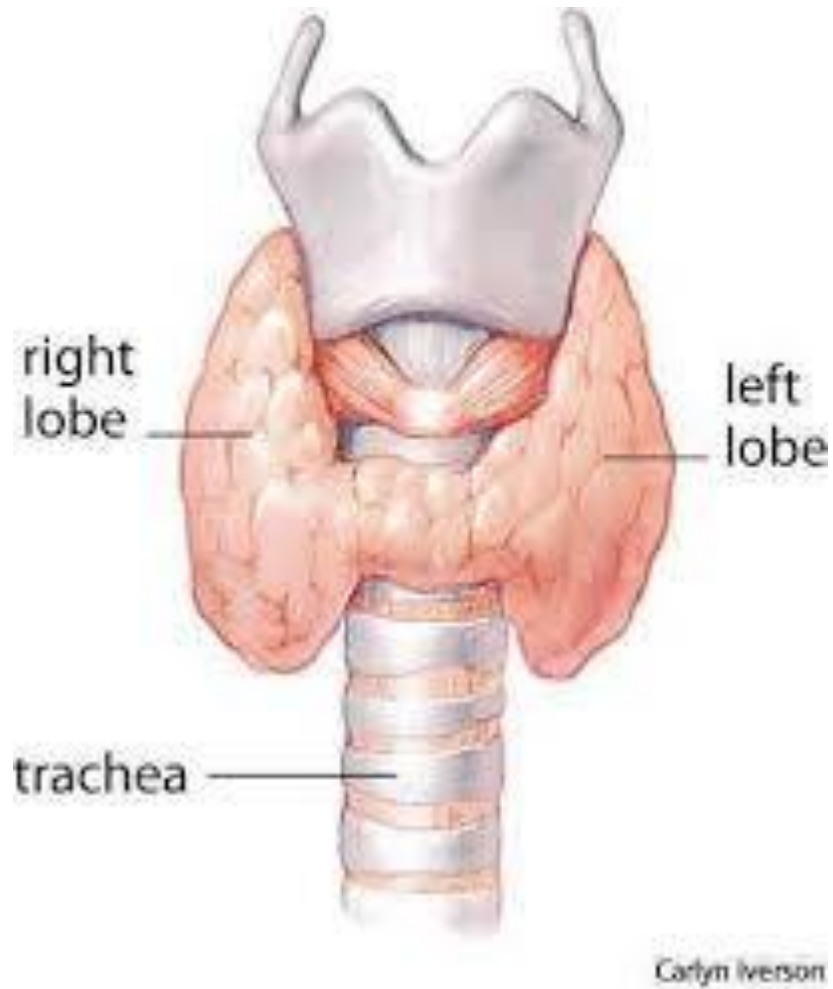




THYROID GLAND

Prepared by: Yousef Elayyan

ANATOMY AND PHYSIOLOGY



ANATOMY AND PHYSIOLOGY

- ❖ Butterfly-shaped gland
- ❖ Inferior to Cricoid cartilage
- ❖ 4 cm below the superior notch of the thyroid cartilage
- ❖ Palpable in about 50% of women and 25% of men
- ❖ Central isthmus 1.5 cm width covering the 2nd to 4th tracheal cartilage
- ❖ Two lateral lobes
- ❖ Extends into the superior mediastinum
- ❖ Can be partially or entirely retrosternal
- ❖ Thyroglossal duct (movement with tongue protrusion)
- ❖ Attached to para-tracheal fascia (movement with swallowing or neck extension)

THYROTOXICOSIS

- ❖ Clinical state of increased metabolism

- ❖ Elevated levels of hormones

- ❖ Causes:

Graves disease (Autoimmune; women (20-50s) > men): M.C.C.

Multinodular goitre

Solitary toxic nodule

Thyroiditis

Exogenous thyroid

HYPOTHYROIDISM

- ❖ Reduced levels of thyroid hormones

- ❖ Low metabolic state

- ❖ Causes:

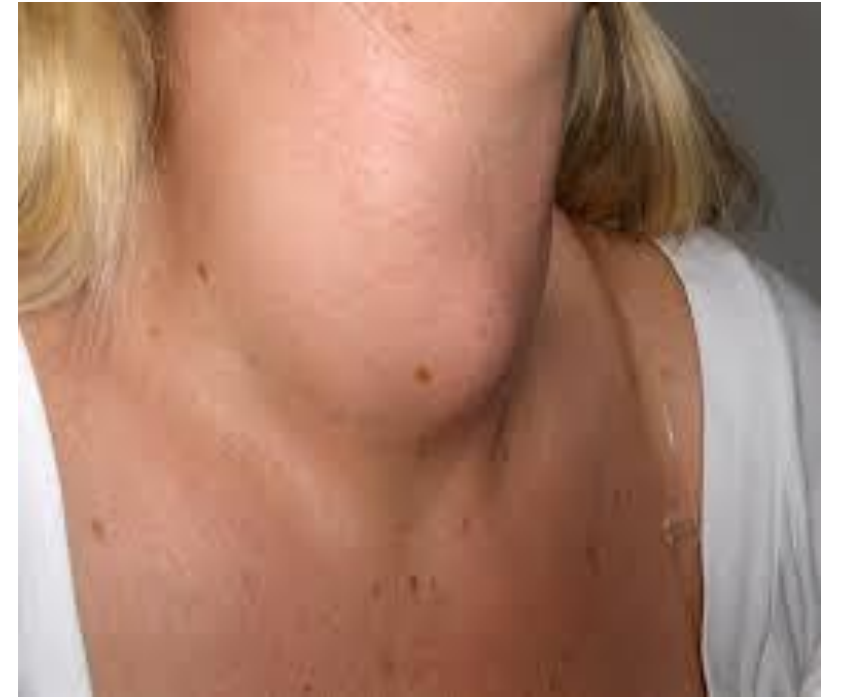 - Hashimoto thyroiditis (women 6X)

 - Radiation exposure

 - Thyroidectomy

HISTORY — NECK SWELLING (GOITRE)

- ❖ Enlargement of the thyroid gland
- ❖ Associated with thyroid dysfunction ? (Most patients are euthyroid)
- ❖ Compressive symptoms (dysphagia; stridor; breathlessness)

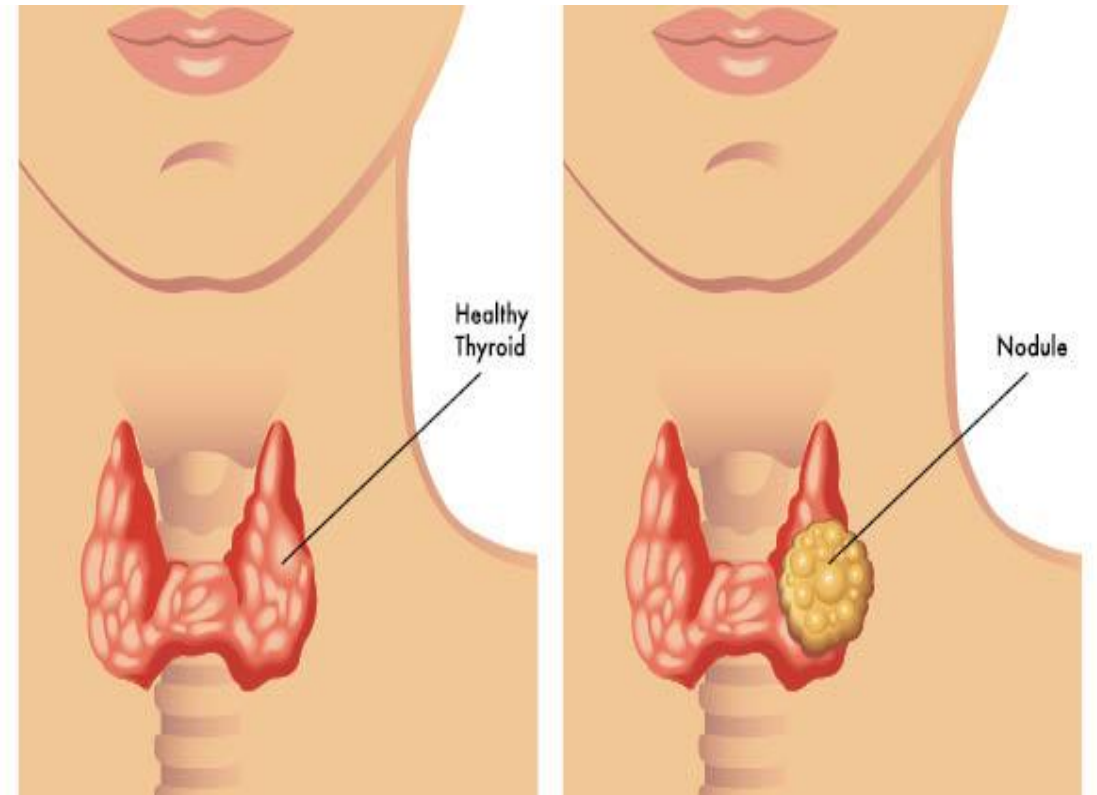


HISTORY — NECK SWELLING (NODULE)

- ❖ Solitary nodule
- ❖ Dominant nodule within multinodular gland
- ❖ 5% of women and less commonly in men

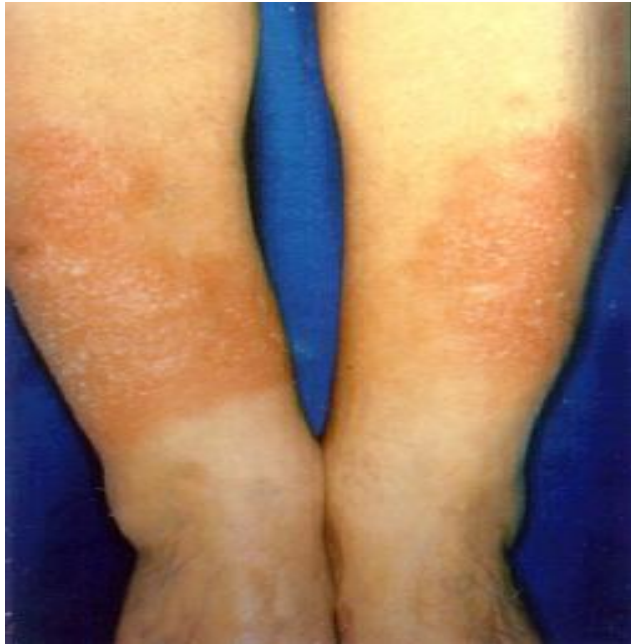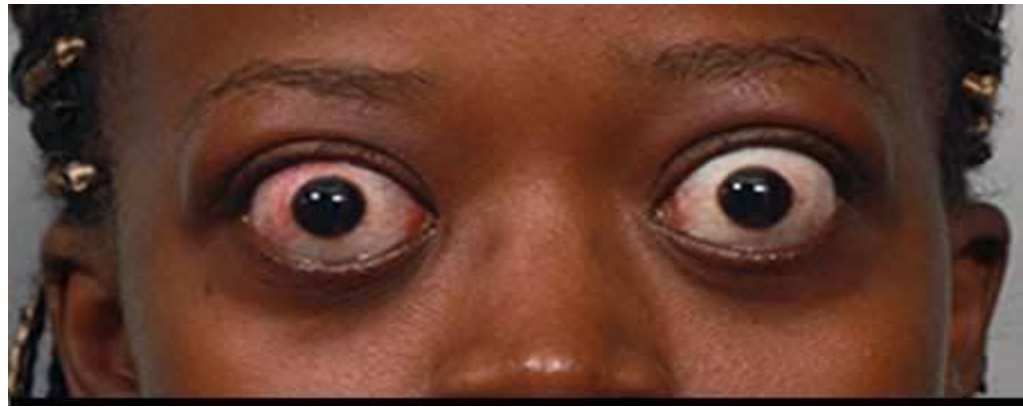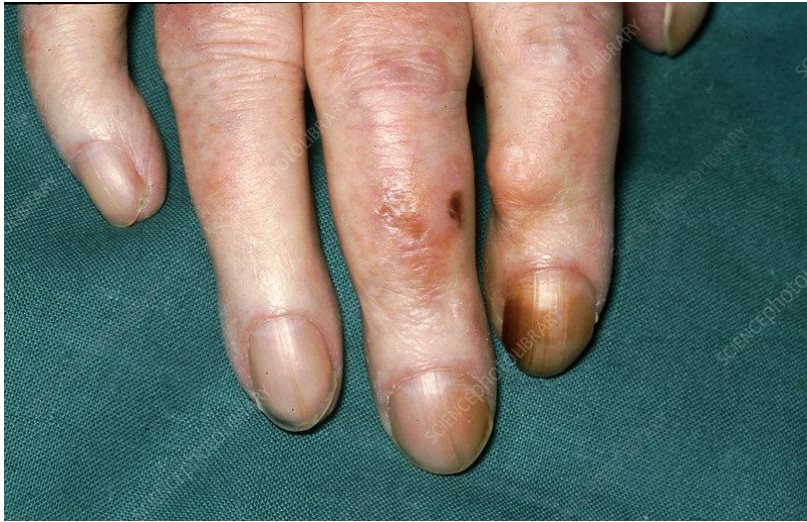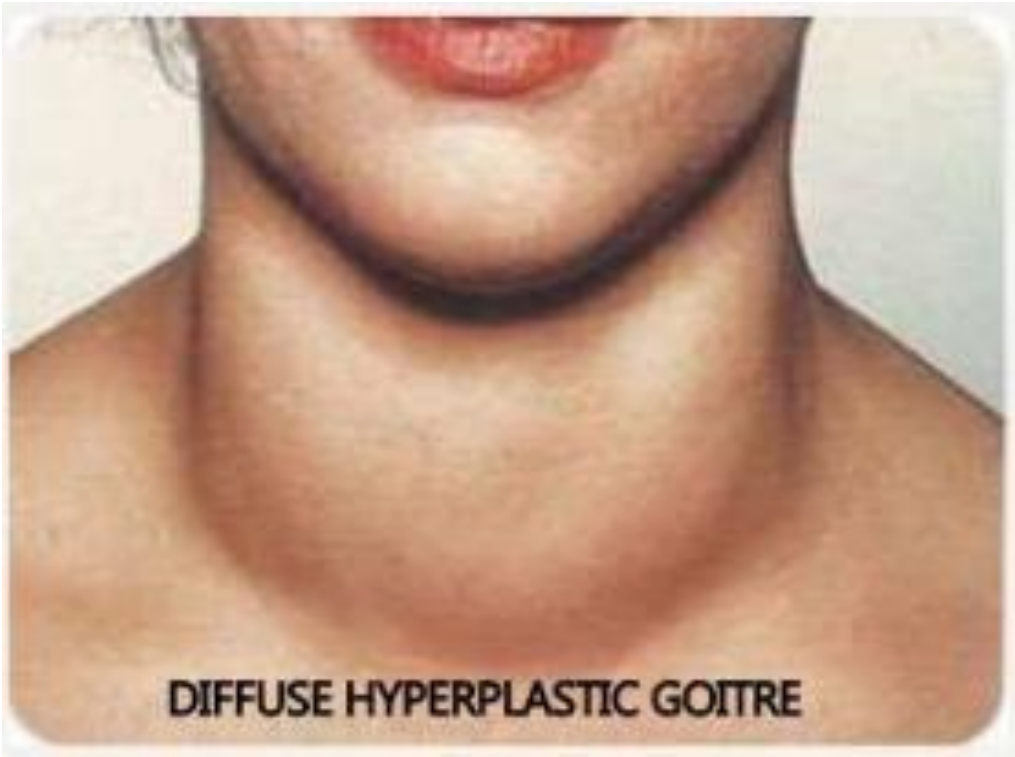NECK PAIN

- ❖ Relatively uncommon
- ❖ If sudden and associated with thyroid enlargement, may represent bleeding into existing nodule



HISTORY SUGGESTING HYPERTHYROIDISM

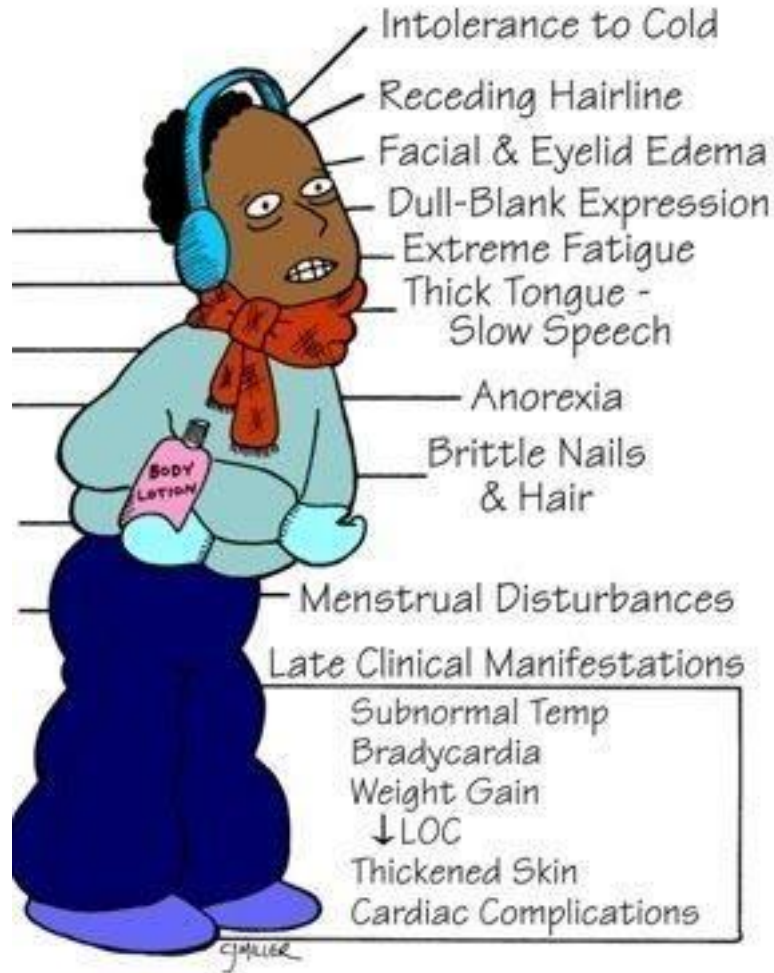- ❖ Fatigue, poor sleep
- ❖ Tremor, heat intolerance, excessive sweating (hyperhidrosis)
- ❖ Pruritus (itch), onycholysis, hair loss
- ❖ Irritability, anxiety, emotional lability
- ❖ Dyspnea, palpitations, ankle swelling
- ❖ Weight loss, Hyperphagia, faecal frequency, diarrhea
- ❖ Proximal muscle weakness
- ❖ Oligomenorrhea or amenorrhea
- ❖ Eye symptoms (grittiness, excessive tearing, retro-orbital pain, eyelid swelling or erythema, blurred vision or diplopia) in the setting of autoimmune disease



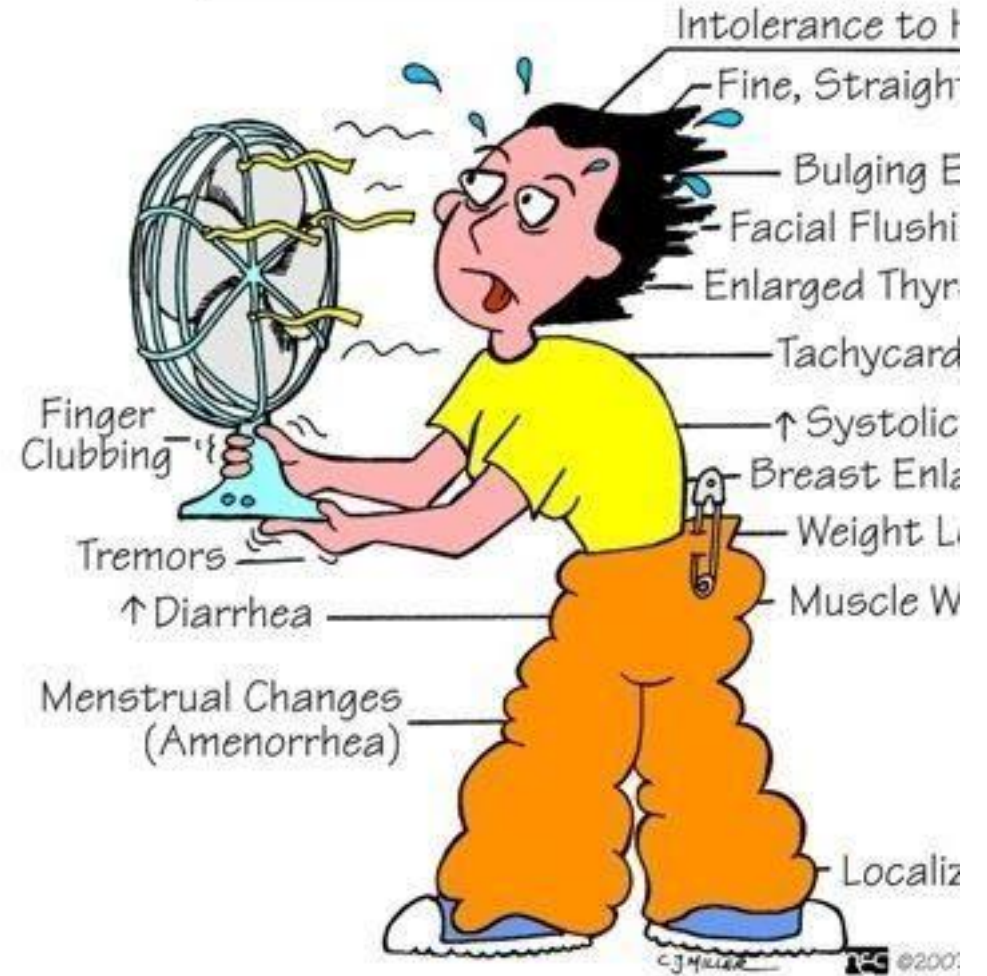
HISTORY SUGGESTING HYPOTHYROIDISM

- ❖ Fatigue, mental slowness, depression
- ❖ Cold intolerance
- ❖ weight gain, constipation
- ❖ Carpal tunnel syndrome
- ❖ Dry skin or hair

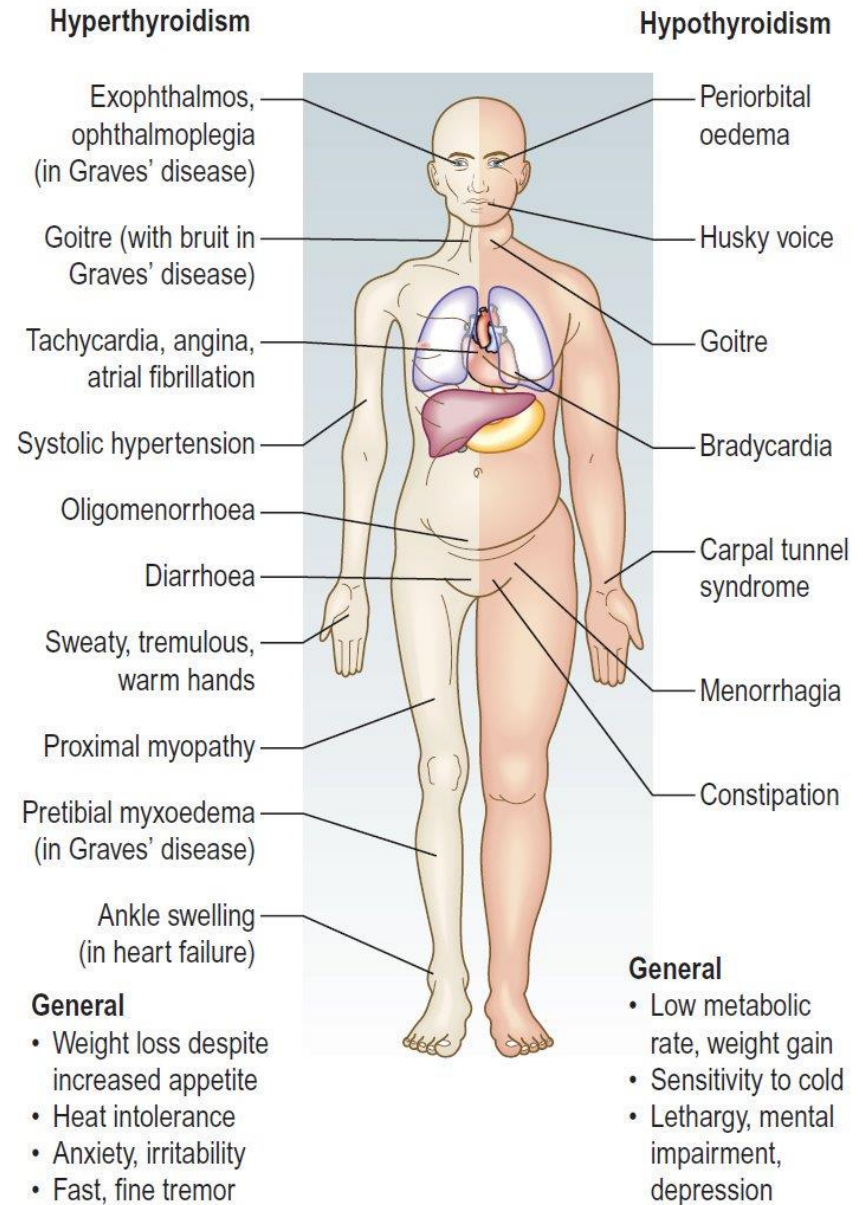
HYPOTHYROIDISM



HYPERTHYROIDISM



PHYSICAL EXAMINATION



Features of hyper- and hypothyroidism.

Source : Macleods Clinical Examination 13th Ed (2013)

EXAMINATION FOR THYROID DISEASE

□ Hands

▪ Inspection

Inspect the patient's hands for peripheral stigmata of thyroid-related pathology:

- **Dry skin:** associated with hypothyroidism.
- **Excessive sweating:** associated with hyperthyroidism.
- **Thyroid acropachy:** similar in appearance to finger clubbing but caused by periosteal phalangeal bone overgrowth secondary to Graves' disease.
- **Onycholysis:** painless detachment of the nail from the nail bed associated with hyperthyroidism.
- **Palmar erythema:** reddening of the palms associated with hyperthyroidism, chronic liver disease and pregnancy.

H A N D S

- **Peripheral tremor**

Peripheral tremor is a feature of hyperthyroidism reflecting **sympathetic nervous system overactivity**.

To assess for evidence of a subtle **peripheral tremor**:

1. Ask the patient to stretch their arms out in front of them.
2. Place a piece of paper across the back of the patient's hands.
3. Observe for evidence of a peripheral tremor (the paper will quiver).

- **Carpal tunnel syndrome**

- **Vitiligo**

RADIAL PULSE

Palpate the patient's **radial pulse**, located at the radial side of the wrist, with the **tips** of your **index** and **middle fingers** aligned longitudinally over the course of the artery.

Once you have located the radial pulse, assess the **rate** and **rhythm**.

You can calculate the heart rate in a number of ways, including measuring for 60 seconds, measuring for 30 seconds and multiplying by 2 or measuring for 15 seconds and multiplying by 4.

For **irregular rhythms**, you should measure the pulse for a **full 60 seconds** to improve accuracy.

F A C E

□ General inspection

Inspect the patient's **face** for clinical signs suggestive of thyroid pathology:

- **Dry skin:** associated with hypothyroidism.
- **Excessive sweating:** associated with hyperthyroidism.
- **Eyebrow loss:** the absence of the outer third of the eyebrows is associated with hypothyroidism (although this is a rare sign).

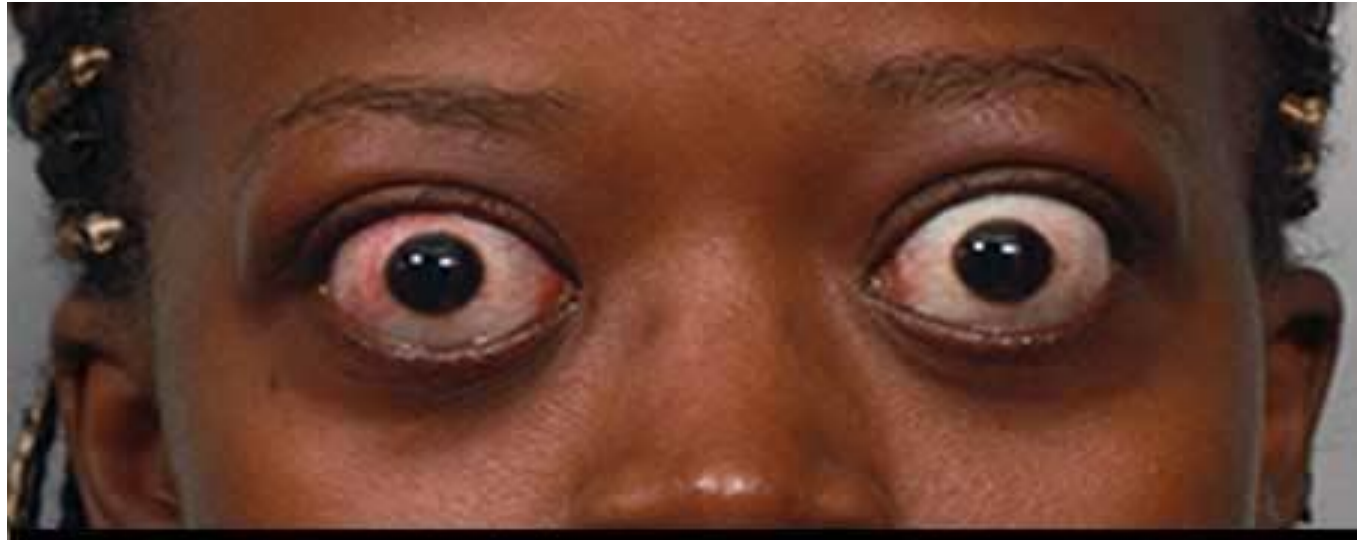EYES

Inspect the eyes for evidence of **eye pathology** associated with **Graves' disease** (known as Graves' ophthalmopathy) including: **lid retraction**, **eye inflammation**, **exophthalmos** (also known as proptosis), **eye movement abnormalities** and **lid lag**.

- **Lid retraction**

To identify lid retraction **inspect the eyes** from the **front** and note if **sclera** is visible between the **upper lid margin** and the **corneal limbus** (this indicative of lid retraction).

Upper eyelid retraction is the most common ocular sign of **Graves' disease** and is thought to occur due to **sympathetic hyperactivity** causing excessive contraction of the superior tarsal and levator palpebrae superioris muscles.



EYES

- **Exophthalmos**

To identify exophthalmos, **inspect the eye** from the **front**, the **side** and from **above**.

Exophthalmos is **bulging of the eye anteriorly** out of the orbit. Bilateral exophthalmos develops in Graves' disease, due to **oedema** and **lymphocytic infiltration** of **orbital fat**, **connective tissue** and **extraocular muscles**.

- **Eye inflammation**

Inspect for evidence of **inflammation** affecting the **eyes**.

Due to lid retraction and exophthalmos, the eye is more **prone to dryness** and the development of **conjunctival oedema** (chemosis), **conjunctivitis** and in severe cases **corneal ulceration**.

EYE MOVEMENTS

- **Eye movements**

Assess for evidence of **ophthalmoplegia** (e.g. restricted eye movement, diplopia) and **pain during eye movement** caused by **Graves' disease** (lymphocytic infiltration of orbital fat, connective tissue and extraocular muscles):

1. Ask the patient to keep their head still and follow your finger with their eyes.
2. Move your finger through the various axes of eye movement ("H" shape).
3. Observe for restriction of eye movements and ask the patient to report any double vision or pain.

LID LAG

- **Lid lag**

Lid lag refers to a **delay in the descent of the upper eyelid in relation to the eyeball** when looking downward. Lid lag is another feature of **Graves' disease** and occurs due to a combination of lid retraction and exophthalmos.

To assess for evidence of **lid lag**:

1. Hold your finger superiorly and ask the patient to follow it with their eyes, whilst keeping their head still.
2. Move your finger in a downwards direction whilst observing the patient's upper eyelids as the patient's eyes follow your finger. If lid lag is present, the upper eyelids will be observed lagging behind the eyes' downward movement, with the sclera being visible between the upper lid margin and the corneal limbus.

THYROID GLAND EXAMINATION

INSPECTION

The patient should be seated or standing in a comfortable position with the neck in a neutral or slightly extended position.

Inspect the **midline of the neck** from the front and the sides noting any **masses** (e.g. goitre) or **scars** (e.g. previous thyroidectomy). The normal thyroid gland should **not be visible**.

Further inspection of a mass

If a mass is identified during the initial inspection, perform some **further assessments** to try and narrow the differential diagnosis.

SWALLOWING

Ask the patient to **swallow some water** and observe the movement of the mass:

- Thyroid gland masses (e.g. a goitre) and thyroglossal cysts typically move upwards with swallowing.
- Lymph nodes will typically move very little with swallowing.
- An invasive thyroid malignancy may not move with swallowing if tethered to surrounding tissue.
- **Tongue protrusion**

Ask the patient to **protrude their tongue**:

Thyroglossal cysts will move upwards noticeably during tongue protrusion.

Thyroid gland masses and lymph nodes will not move during tongue protrusion.

THYROID PALPATION

Palpation

Note: There is no data comparing palpation using the anterior approach to the posterior approach so examiners should use the approach that they find most comfortable.

Palpate each of the thyroid's **lobes** and the **isthmus**:

1. Stand behind the patient and ask them to tilt their chin slightly downwards to relax the muscles of the neck to aid palpation of the thyroid gland.
2. Place the three middle fingers of each hand along the midline of the neck below the chin.
3. Locate the upper edge of the thyroid cartilage (“Adam’s apple”) with your fingers.
4. Move your fingers inferiorly until you reach the cricoid cartilage. The first two rings of the trachea are located below the cricoid cartilage and the thyroid isthmus overlies this area.

THYROID PALPATION

5. Palpate the thyroid isthmus using the pads of your fingers.
6. Palpate each lobe of the thyroid in turn by moving your fingers out laterally from the isthmus.
7. Ask the patient to swallow some water, whilst you feel for the symmetrical elevation of the thyroid lobes (asymmetrical elevation may suggest a unilateral thyroid mass).
8. Ask the patient to protrude their tongue (if a mass represents a thyroglossal cyst, you will feel it rise during tongue protrusion).

LYMPH NODE PALPATION

Assess for **local lymphadenopathy** which may indicate the **metastatic spread** of **primary thyroid malignancy**.

1. Position the patient sitting upright and examine from behind if possible. Ask the patient to tilt their chin slightly downwards to relax the muscles of the neck and aid palpation of lymph nodes. You should also ask them to relax their hands in their lap.
2. Stand behind the patient and use both hands to start palpating the neck.
3. Use the pads of the second, third and fourth fingers to press and roll the lymph nodes over the surrounding tissue to assess the various characteristics of the lymph nodes. By using both hands (one for each side) you can note any asymmetry in size, consistency and mobility of lymph nodes.
4. Start in the submental area and progress through the various lymph node chains. Any order of examination can be used, but a systematic approach will ensure no areas are missed:
(Submental, Submandibular, Pre-auricular, Post-auricular, Superficial cervical, Deep cervical, Posterior cervical, Supraclavicular)

P E R C U S S I O N

Percussion of the sternum

Percuss the sternum moving downwards from the **sternal notch** to assess for **retrosternal dullness**.

Retrosternal dullness may indicate a **large thyroid mass** extending posteroinferiorly to the manubrium.

AUSCULTATION

Auscultation of the thyroid gland

Auscultate each lobe of the thyroid gland for a **bruit** using the **bell** of the stethoscope.

A bruit indicates **increased vascularity**, which typically occurs in Graves' disease.

CARDIAC EXAMINATION

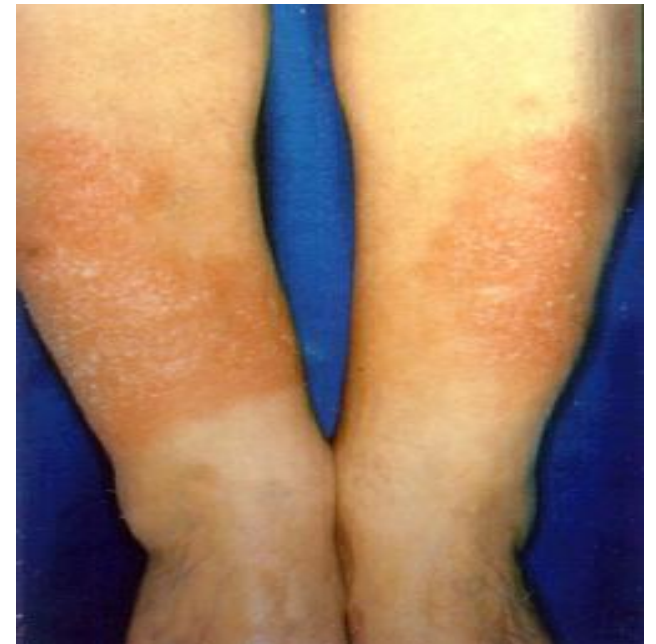- Midsystolic murmurs due to increased cardiac output in hyperthyroidism

REFLEXES

Reflexes are assessed to screen for **hyporeflexia** and delayed reflexes which is associated with **hypothyroidism**. The most commonly tested reflexes are the **biceps reflex** or the **knee jerk reflex** (you only need to assess one).

PRETIBIAL MYXOEDEMA

Pretibial myxoedema is a form of diffuse mucinosis in which there is an accumulation of excess glycosaminoglycans in the dermis and subcutis of the skin. It usually presents itself as a **waxy, discoloured induration** of the **skin** on the anterior aspect of the lower legs (pretibial region). Pretibial myxoedema is a rare complication of **Graves' disease**.



PROXIMAL MYOPATHY

Proximal myopathy is a potential complication of both **multinodular goitre** and **Graves' disease**. Patients develop wasting of their proximal musculature causing difficulties in tasks such as standing from a sitting position.

To screen for proximal myopathy **ask the patient to stand from a sitting position with their arms crossed** (to minimise their ability to mask proximal muscle weakness). Make sure to stand close to the patient to prevent them from falling. An inability to stand up would suggest proximal muscle weakness.



THANK YOU