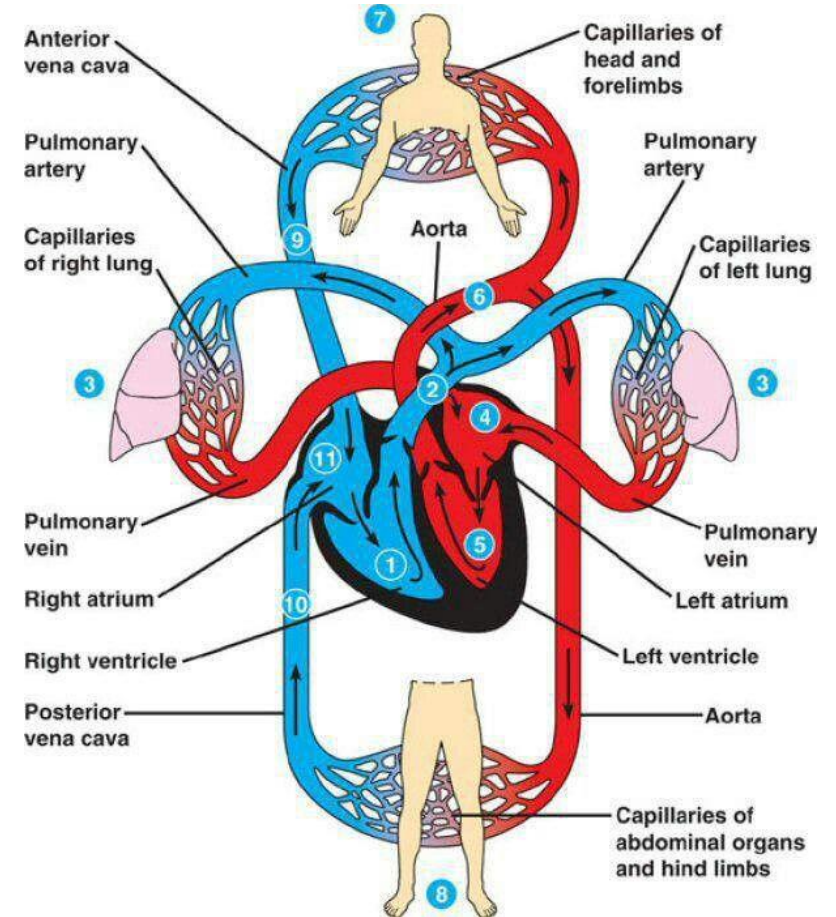
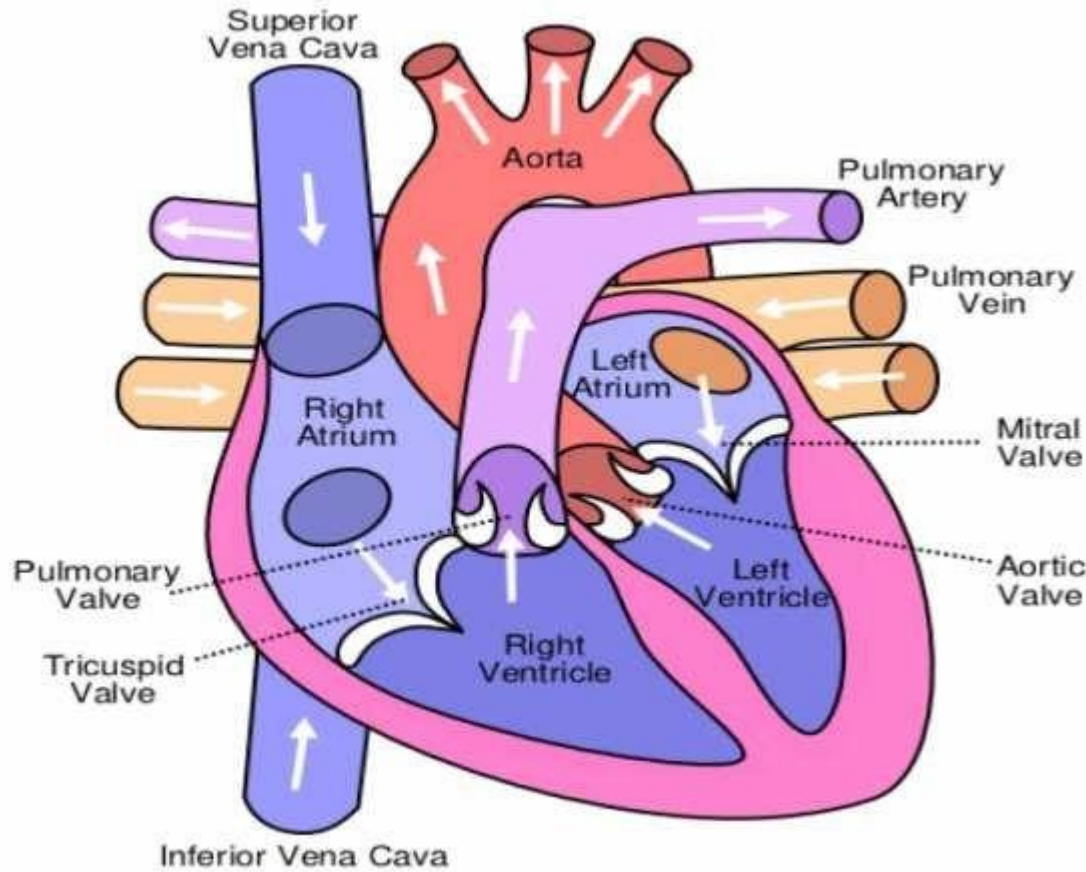


Cardiovascular system

History and physical examination

Farah Abuazzam

ANATOMY & PHYSIOLOGY



Normal resting pressure in the heart and great vessels

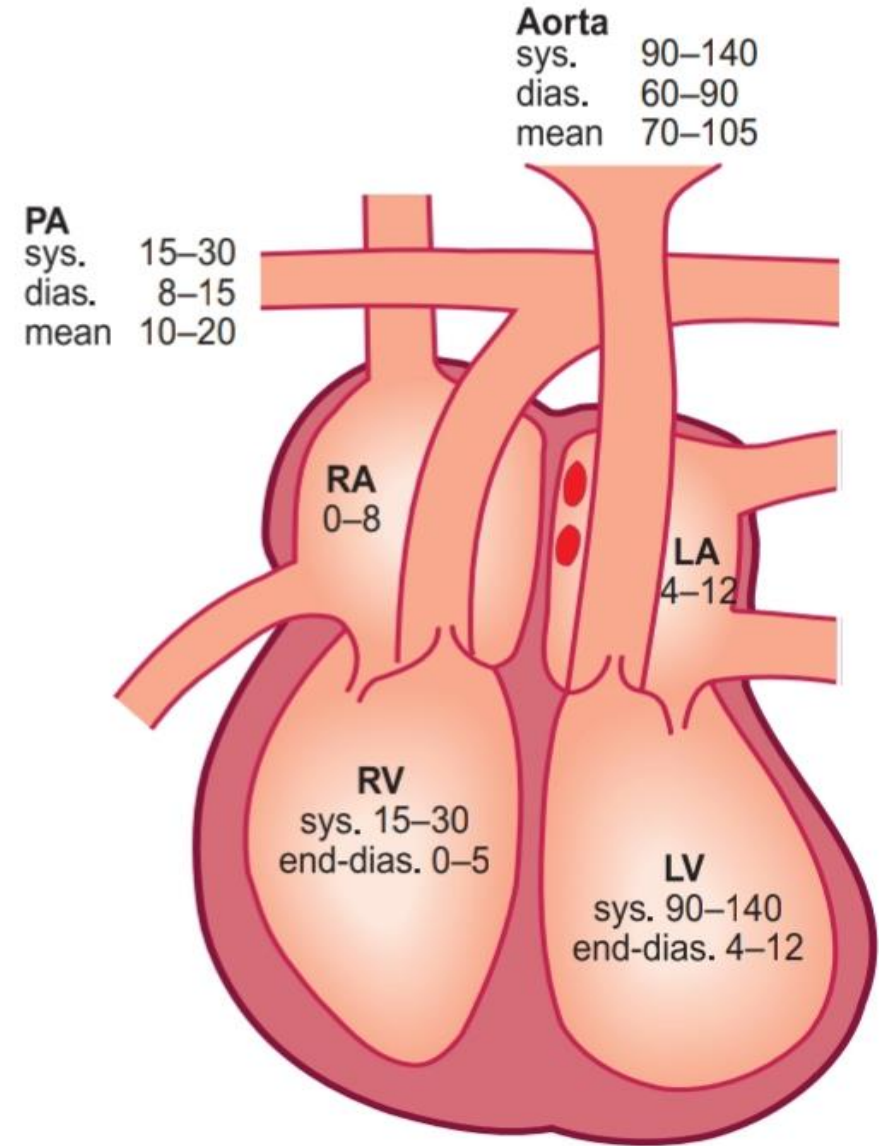


Fig. 4.2 Normal resting pressures (mmHg) in the heart and great vessels. *dias.*, diastolic; *LA*, left atrium; *LV*, left ventricle; *PA*, pulmonary artery; *RA*, right atrium; *RV*, right ventricle; *sys.*, systolic.

HISTORY

- Common presenting symptoms:
 1. Chest pain
 2. Dyspnoea
 3. Palpitation
 4. Syncope and presyncope
 5. Oedema

1. Chest pain

Chest pain

- **SOCRATES**

- Always ask about its relation to **exertion** and degree of limitation caused by symptoms

- DDx:

1. Angina
2. Myocardial infarction
3. Aortic dissection
4. Pericarditis
5. Oesophageal Spasm
6. Pneumothorax
7. Musculoskeletal pain

Angina

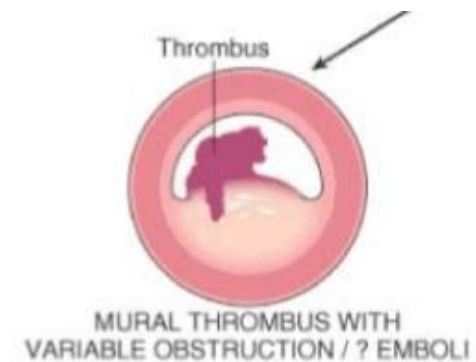
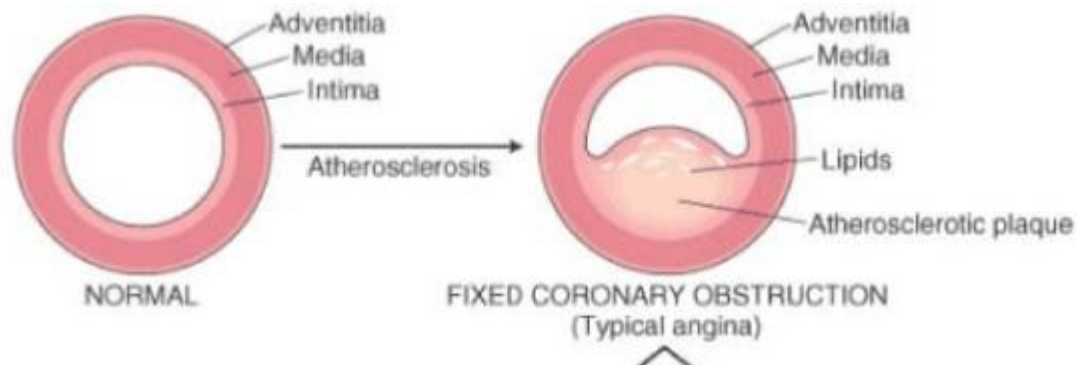
- Chest pain due to inadequate oxygen supply to the heart muscle
- Causes:
 1. Coronary atherosclerosis (Chronic fixed narrowing of the coronaries)
 2. Aortic stenosis
 3. Hypertrophic cardiomyopathy

Angina

Site	retrosternal
Onset	progressive, increase in intensity over 1-2 minutes
Character	Constricting, heavy
Radiation	Sometimes arm, neck, epigastrium
Associated features	Dyspnoea
Timing	Intermittent, with episode lasting 2-10 minutes
Exacerbating/relieving factors	Triggered by emotion, exertion, cold, large meal Relieved by rest, nitrates
Severity	Mild to moderate

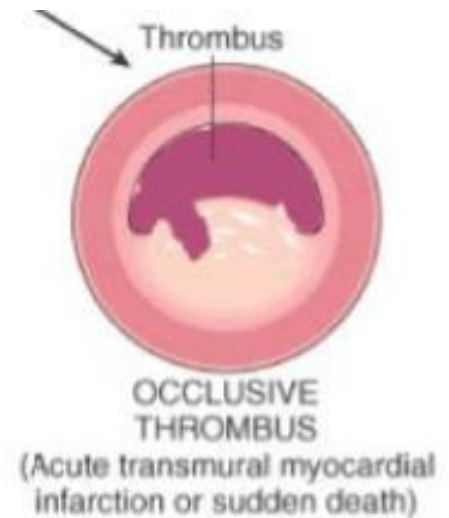
Stable vs. unstable angina

- Unstable angina: atherosclerotic plaque rupture with non-occlusive thrombus
 1. New onset chest pain < 6 weeks, or < 2 weeks post-MI
 2. Worsening in severity, frequency, less responsive to nitrates
 3. Occur with minimal exertion or at rest



Myocardial infarction

- Atherosclerotic plaque rupture with occlusive thrombus
- The symptoms are more severe and prolonged than angina
- +ve autonomic symptoms: nausea, vomiting, pallor, sweating
- Angor animi: feeling of impending death

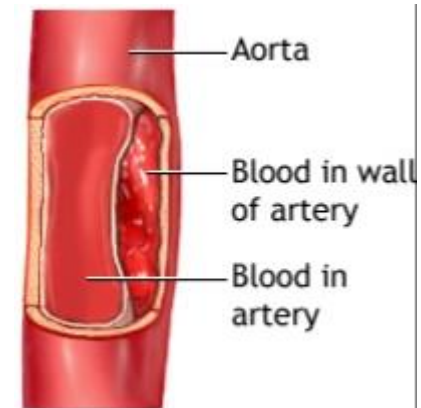


MI

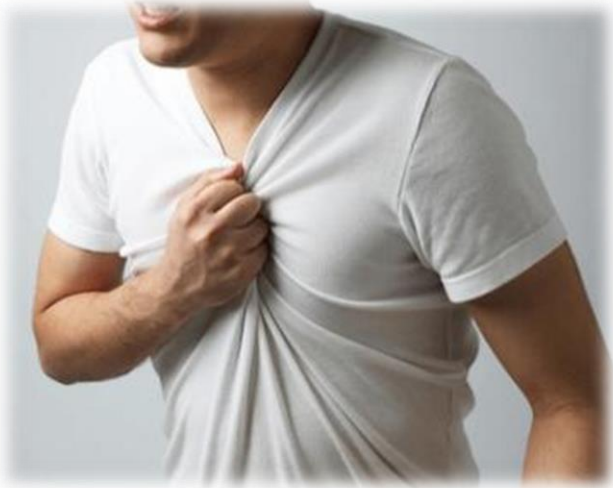Site	Retrosternal
Onset	Rapid over few minutes
Character	Constricting, heavy
Radiation	Arms, neck, jaw, epigastrium
Associated symptoms	Autonomic symptoms, angor animi, SOB
Timing	Acute presentation, prolonged duration >30 minutes
Exacerbating/relieving factors	Stress and exercise are rare triggers, usually spontaneous Not relieved by rest or nitrates
Severity	Usually severe

Aortic dissection

- Tear in the intima of aorta
- Associated with profound autonomic stimulation
- If the tear involves the cranial or upper limb arteries, there may be associated syncope, stroke, or upper limb pulse asymmetry
- Predisposing factors:
 1. HTN
 2. CTD (Marfan syndrome)



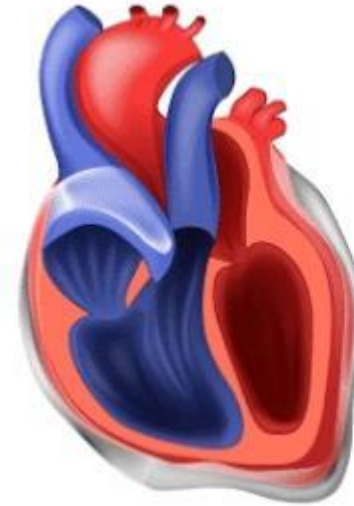
Aortic dissection



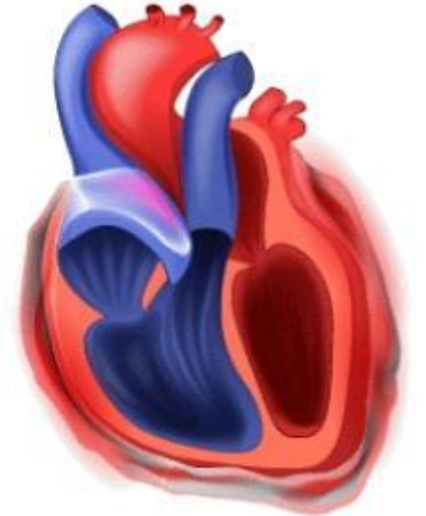
Site	Interscapular/retrosternal
Onset	Very sudden
Character	Tearing, ripping
Radiation	Back, interscapular
Associated features	Sweating, syncope, focal neurological deficit, signs of limb ischemia, mesenteric ischemia
Timing	Acute presentation, prolonged duration
Exacerbating/relieving factors	Spontaneous, no manoeuvres relieve pain
Severity	Very severe

Pericarditis

- Inflammation of the pericardium
- Causes:
 1. Viral infection
 2. CTD
 3. MI
 4. After surgery, catheter ablation or radiotherapy



a healthy pericardium



pericarditis

Pericarditis

Site	Retrosternal or left sided
Onset	Gradual, postural changes may suddenly aggravate
Character	Sharp, stabbing
Radiation	Left shoulder or back
Associated symptoms	Flu-like prodrome, SOB, fever
Timing	Acute presentation, variable duration
Exacerbating/relieving factors	Sitting up/lying down, inspiration worsen pain Relieved by NSAID, leaning forward
Severity	Can be severe

Oesophageal spasm

Site	Retrosternal or epigastric
Onset	Over 1-2 minutes, can be sudden (spasm)
Character	Gripping, tight or burning
Radiation	Often to back, sometimes to arms
Associated symptoms	Heartburn, acid reflux
Timing	Intermittent, often at night-time, variable duration
Exacerbating/relieving factors	Triggered by lying flat and some food Not relieved by rest Nitrates sometimes relieve
Severity	Usually mild but oesophageal spasm can mimic MI

2. Dyspnea

Dyspnoea (breathlessness)

- Unpleasant awareness of breathing
- Acute vs. Chronic
- Causes of acute SOB:
 1. Heart failure-most common cause (Acute or chronic)
 2. Pulmonary embolism
 3. Arrhythmias

Mechanisms of heart failure

4.4 Some mechanisms and causes of heart failure

Mechanism	Cause
Reduced ventricular contractility (systolic dysfunction)	Myocardial infarction Dilated cardiomyopathy, e.g. genetic, idiopathic, alcohol excess, cytotoxic drugs, peripartum cardiomyopathy Myocarditis
Impaired ventricular filling (diastolic dysfunction)	Left ventricular hypertrophy Constrictive pericarditis Hypertrophic or restrictive cardiomyopathy
Increased metabolic and cardiac demand (rare)	Thyrotoxicosis Arteriovenous fistulae Paget's disease
Valvular or congenital lesions	Mitral and/or aortic valve disease Tricuspid and/or pulmonary valve disease (rare) Ventricular septal defect Patent ductus arteriosus

Angina equivalent

- SOB caused by MI
- May be accompanied with chest pain
- Elderly, DM
- Identical precipitant to angina and relived with nitrate

Exertional dyspnea, orthopnea, paroxysmal nocturnal dyspnea

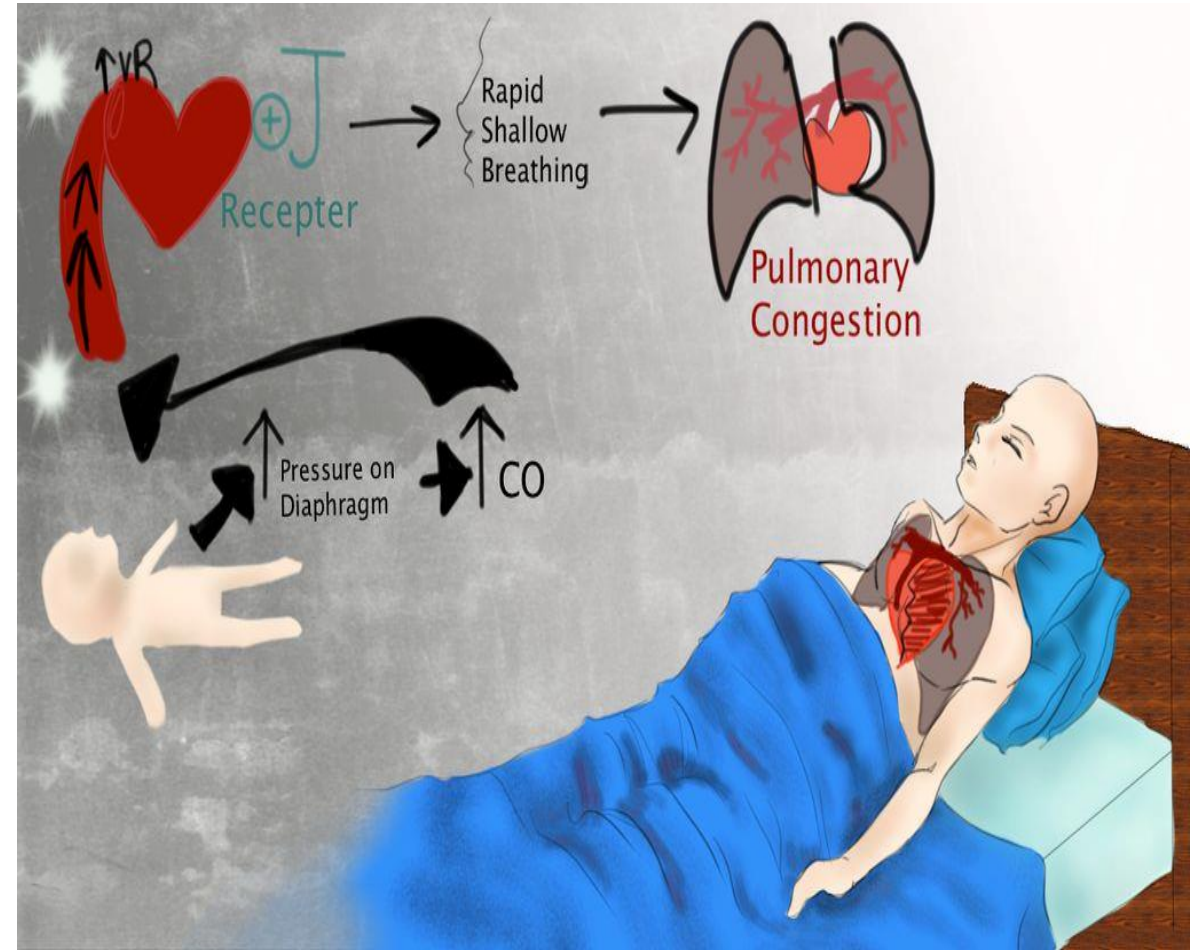
- **Exertional dyspnea**: the symptomatic hallmark of heart failure
- NYHA grading system to assess the degree of symptomatic limitation caused by exertional SOB of heart failure

4.5 New York Heart Association classification of heart failure symptom severity

Class	Description
I	No limitations. Ordinary physical activity does not cause undue fatigue, dyspnoea or palpitation (asymptomatic left ventricular dysfunction)
II	Slight limitation of physical activity. Such patients are comfortable at rest. Ordinary physical activity results in fatigue, palpitation, dyspnoea or angina pectoris (symptomatically 'mild' heart failure)
III	Marked limitation of physical activity. Less than ordinary physical activity will lead to symptoms (symptomatically 'moderate' heart failure)
IV	Symptoms of congestive heart failure are present, even at rest. With any physical activity, increased discomfort is experienced (symptomatically 'severe' heart failure)

Orthopnea

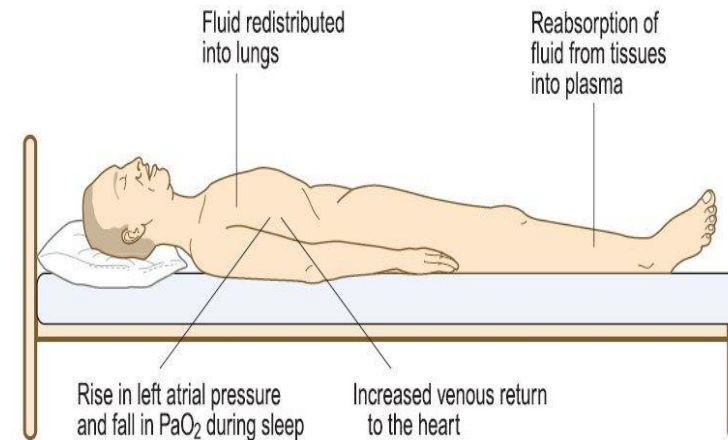
- Dyspnea on lying flat
- Mechanism: increase venous return
- Severity is assessed by the number of pillows used at night
- The most severe form on dyspnea



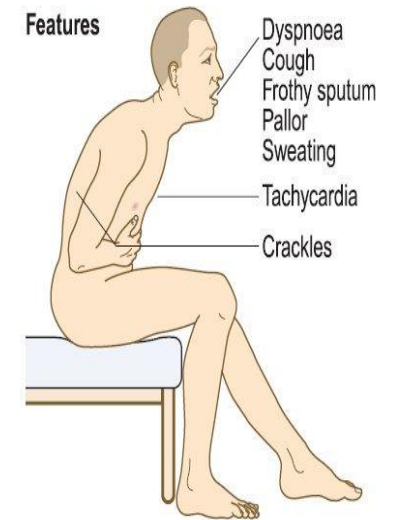
Paroxysmal nocturnal dyspnea (PND)

- SOB awakes patient from sleep
- Same mechanism as orthopnea
- Pt describe episode of choking or gasping for air, relieved by sitting
- VS. Asthma attack

Mechanism



Features



- Causes**
- Ischaemic heart disease
 - Aortic valve disease
 - Hypertension
 - Cardiomyopathy
 - Atrial fibrillation
 - Mitral valve disease
 - Atrial tumours

Paroxysmal nocturnal dyspnoea.

Source : Macleods Clinical Examination 13th Ed (2013)

Acute dyspnoea

Ask about:

- duration of onset
- Background symptoms of exertional dyspnoea and usual exercise tolerance
- Associated symptoms: chest pain, syncope, palpitation or respiratory symptoms (cough, sputum, wheezes, haemoptysis)

Chronic dyspnoea

• Ask about:

- Relationship between symptoms and exertion
- degree of limitation caused by symptoms and their impact on everyday activities
- effect of posture on symptoms and/or episodes of nocturnal breathlessness
- associated symptoms: ankle swelling, cough, wheeze or sputum.

3. Palpitation

Palpitation

- Unexpected or unpleasant awareness of the heart beating in the chest
- Ask about:
 1. Nature of palpitation (Heart beats rapid, forceful, irregular)
 2. Timing of symptoms: speed on onset and offset, frequency and duration of episodes
 3. Precipitants for symptoms or relieving factors
 4. Associated symptoms: presyncope, syncope, chest pain
 5. History of cardiac disease

In healthy people

- More common in bed at night in slim people while lying on their left side
- After exercise or in stressful situation will be aware of their heart beating with normal sinus rhythm

4.6 Descriptions of arrhythmias

	Extrasystoles	Sinus tachycardia	Supraventricular tachycardia	Atrial fibrillation	Ventricular tachycardia
<u>S</u> ite	–	–	–	–	–
<u>O</u> nset	Sudden	Gradual	Sudden, with 'jump'	Sudden	Sudden
<u>C</u> haracter	'Jump', missed beat or flutter	Regular, fast, 'pounding'	Regular, fast	Irregular, usually fast; slower in elderly	Regular, fast
<u>R</u> adiation	–	–	–	–	–
<u>A</u> ssociated features	Nil	Anxiety	Polyuria, lightheadedness, chest tightness	Polyuria, breathlessness Syncope uncommon	Presyncope, syncope, chest tightness
<u>T</u> iming	Brief	A few minutes	Minutes to hours	Variable	Variable
<u>E</u> xacerbating/ <u>r</u> elieving factors	Fatigue, caffeine, alcohol may trigger Often relieved by walking (increases sinus rate)	Exercise or anxiety may trigger	Usually at rest, trivial movements, e.g. bending, may trigger Vagal manœuvres may relieve	Exercise or alcohol may trigger; often spontaneous	Exercise may trigger; often spontaneous
<u>S</u> everity	Mild (usually)	Mild to moderate	Moderate to severe	Very variable, may be asymptomatic	Often severe

Benign, At rest
Abolished by exercise
underfilling alternating with overfilling of left ventricle

Affects young
Regular, sudden paroxysms

Affects pts with underlying cardiomyopathy, or previous MI

High risk features for life-threatening arrhythmia

1. Previous MI or cardiac surgery
2. Associated syncope or severe chest pain
3. Family hx of sudden death
4. Wolff-Parkinson-white syndrome
5. Significant structural heart disease (HCM, AS)

4. Syncope/presyncope

Syncope and presyncope

- Syncope: Transient loss of consciousness due to transient cerebral hypoperfusion
- Presyncope: sensation of lightheadedness and impending loss of consciousness without progressing to acute LOC



For SYNCOPE ask about:

- Ask about witness
- Circumstances of the event and any preceding symptoms (palpitation, chest pain, lightheadedness, nausea, tinnitus, sweating and visual disturbance)
- Duration of LOC, appearance of the patient while unconscious and any injuries sustained.
- Time to recovery to full consciousness and normal cognition
- Current driving status, including occupational driving

For PRESYNCOPE ask about:

- Exact nature of symptoms and associated features as palpitation
- Precipitants for symptoms such as postural changes, prolonged standing, intense emotion or exertion
- Frequency of episodes and impact on lifestyle
- Possible contributing medications as antihypertensive meds

Causes of syncope/presyncope

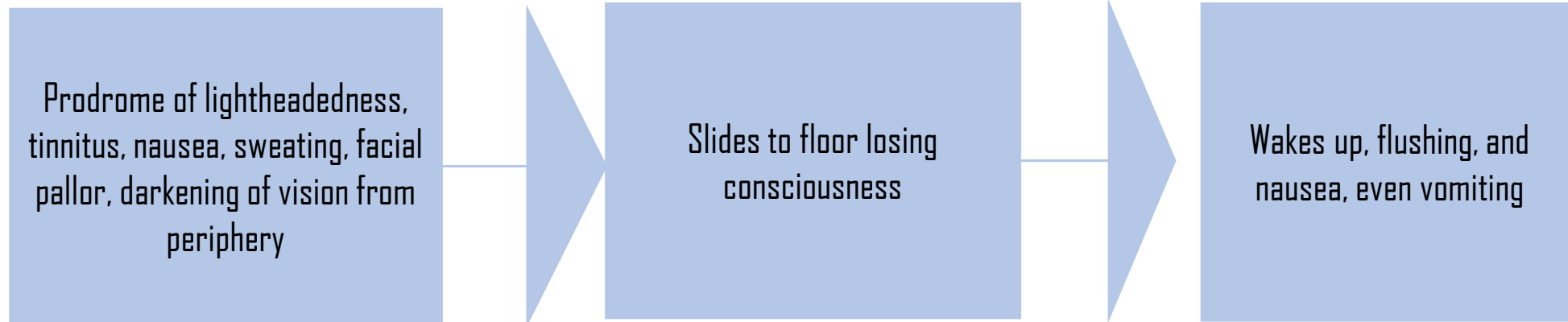
- Postural hypertension
- Neurocardiogenic syncope
- Hypersensitive carotid sinus syndrome (pressure over carotid sinus may lead to reflex bradycardia and syncope)
- Arrhythmia
- Mechanical obstruction of cardiac output

Postural hypotension as a cause of syncope

- A fall > 20 mmHg in systolic BP, > 10 mmHg in diastolic BP on standing with reflex tachycardia of 15-20 bpm increase in heart rate
- Causes:
 1. Hypovolemia
 2. Drugs
 3. Autonomic neuropathy
- Common in elderly, esp. above 65 years

Vasovagal syncope

- Mechanism: abnormal autonomic reflexes produce a sudden bradycardia and/or vasodilatation
- In healthy people forced to stand for a long time in warm environment or subject to painful or emotional stimuli such as sight of blood
- VS. seizure



DON'T HOLD THE PATIENT UPRIGHT

This will worsen cerebral hypoperfusion, leading to delays recovery and possible progression into seizure

Arrhythmia as a cause of syncope

- Most common cause is bradyarrhythmia
 1. Stoke-Adams attacks: episodic LOC secondary to sinoatrial disease or AV block
 2. Drugs
 3. Ventricular tachycardia causes syncope more often than supraventricular tachycardia esp. in patient with impaired LV function

Mechanical obstruction to ventricle outflow as a cause of syncope

1. Left ventricular outflow obstruction (related to exertion)

- Severe aortic stenosis
- Hypertrophic cardiomyopathy

2. Right ventricular outflow obstruction

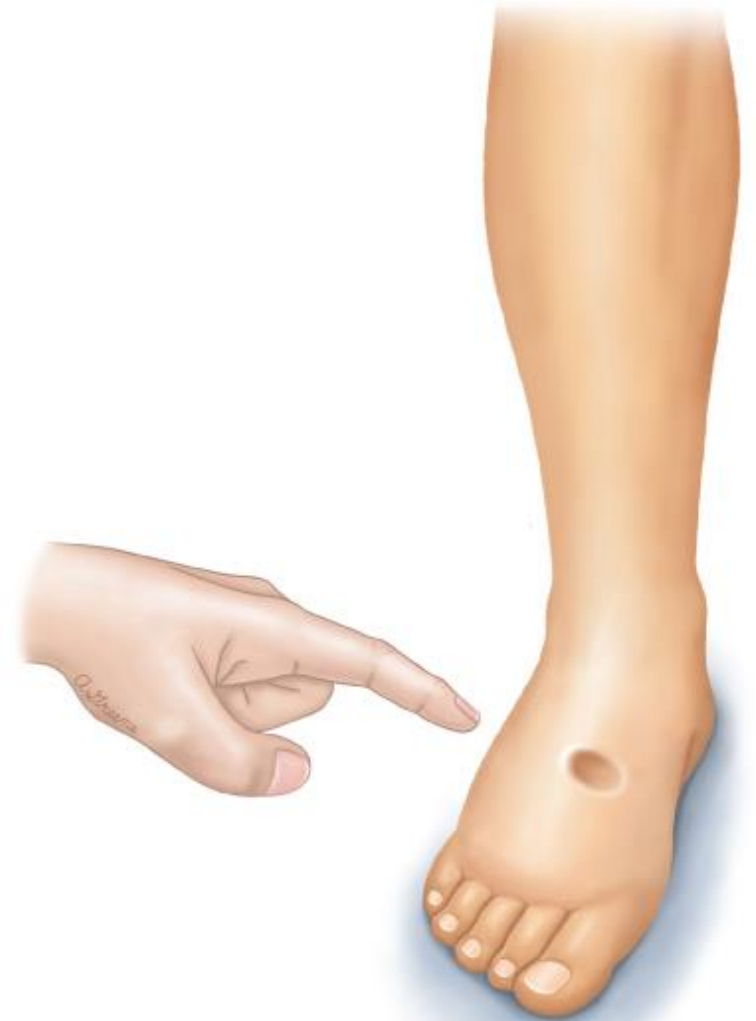- Pulmonary embolism

3. Atrial myxoma, thrombosis of prosthetic heart valves

5. Edema

Edema

- Excess fluid in the interstitial space
- Usually gravity dependent
- Where to look for?
- Unilateral vs bilateral
- If suggestive of cardiac cause of edema > check for JVP
- Check for other symptoms of volume overload



Other symptoms of cardiac disease

- Non-specific symptoms; weight loss, generalized weakness, fever, night sweats (infective endocarditis)
- Symptoms of stroke, acute mesenteric ischemia, acute limb ischemia (patients with atria myxoma or infective vegetations)
- Abdominal distension due to ascites, muscle wasting due to cardiac cachexia (advanced heart failure)

Past medical history

- Ask about:
 - Detailed record for any previous cardiac disease, investigations, and interventions
 - Conditions associated with increased risk of vascular diseases
 - Rheumatic fever or heart murmur during childhood
 - Potential causes of bacteremia in patients with suspected infective endocarditis
 - Systemic disorders with cardiac manifestations

4.8 Key elements of the past cardiac history

	Ischaemic heart disease	Heart failure	Valvular disease
Baseline symptoms	Exertional angina? If so, ascertain functional limitation (see Box 4.2)/response to GTN spray	Dyspnoea, fatigue, ankle swelling Record usual functional status (see Box 4.5)	Often asymptomatic Exertional dyspnoea (common), chest pain or syncope
Major events	Previous myocardial infarction/unstable angina	Hospitalisation for decompensated heart failure Ventricular arrhythmias	Infective endocarditis Previous rheumatic fever
Investigations	Coronary angiography (invasive or computed tomography): presence, extent and severity of coronary artery disease Exercise electrocardiogram (or other stress test): evidence of inducible ischaemia? Exercise capacity and symptoms	Echocardiogram (\pm cardiac magnetic resonance imaging): left ventricular size, wall thickness and systolic function; valvular disease; right ventricular function	Echocardiogram (transthoracic \pm transoesophageal): nature and severity of valve lesion; ventricular size and function
Procedures	Percutaneous coronary intervention (angioplasty and stenting) Coronary artery bypass graft surgery	Implantable cardioverter–defibrillator Cardiac resynchronisation therapy	Surgical valve repair or replacement (note whether mechanical or bioprosthetic) Transcatheter valve procedures
GTN, <i>glyceryl trinitrate</i> .			

Premature CAD

- In the patient

CAD < 55 years in female, < 45 years in male

- In the family

First degree relative

CAD < 65 years in female, < 55 years in male

Drug history

4.7 Symptoms related to medication

Symptom	Medication
Angina	Aggravated by thyroxine or drug-induced anaemia, e.g. aspirin or NSAIDs
Dyspnoea	Beta-blockers in patients with asthma Exacerbation of heart failure by beta-blockers, some calcium channel antagonists (verapamil, diltiazem), NSAIDs
Palpitation	Tachycardia and/or arrhythmia from thyroxine, β_2 stimulants, e.g. salbutamol, digoxin toxicity, hypokalaemia from diuretics, tricyclic antidepressants
Syncope/ presyncope	Vasodilators, e.g. nitrates, alpha-blockers, ACE inhibitors and angiotensin II receptor antagonists Bradycardia from rate-limiting agents, e.g. beta-blockers, some calcium channel antagonists (verapamil, diltiazem), digoxin, amiodarone
Oedema	Glucocorticoids, NSAIDs, some calcium channel antagonists, e.g. nifedipine, amlodipine

ACE, *angiotensin-converting enzyme*; NSAIDs, *non-steroidal anti-inflammatory drugs*.

Family history

- Family history of premature coronary artery diseases (angina, interventions/surgery, sudden cardiac death)

First degree relative (< 65 years in female, < 55 years in male)

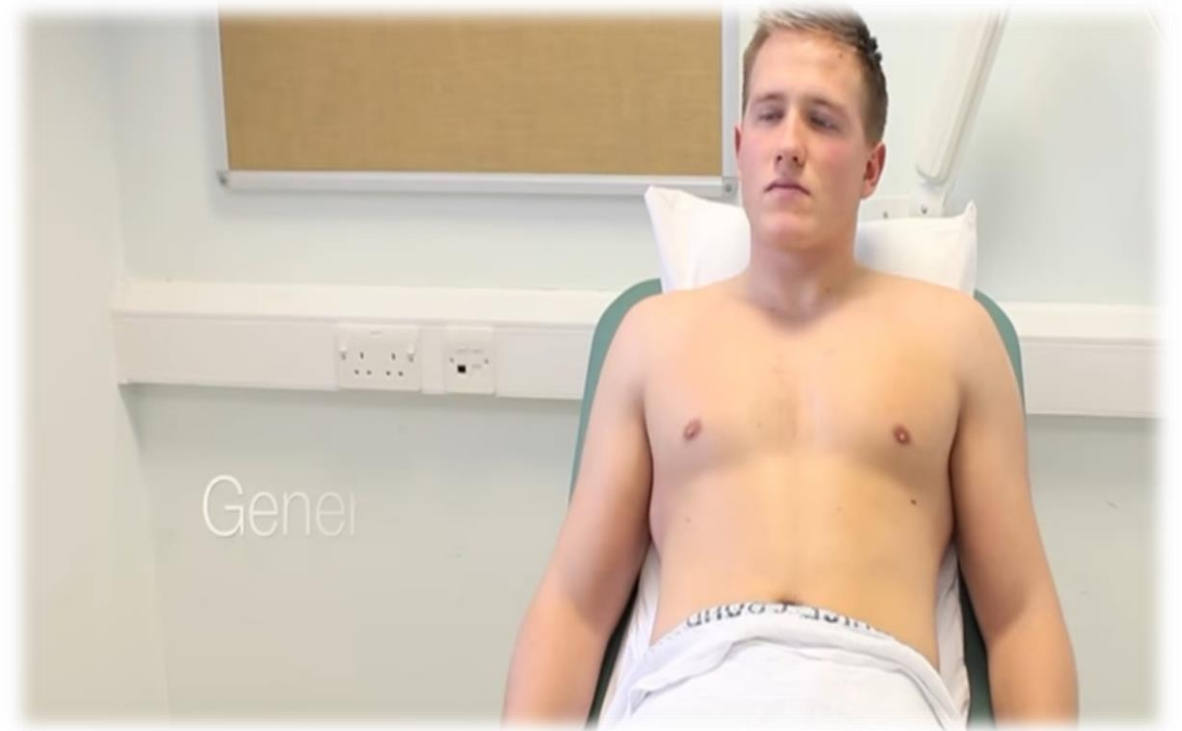- Cardiac diseases with genetic components such as cardiomyopathies
- Venous thrombosis due to inherited hemophilia's
- Familial hypercholesterolemia

Social history

- Smoking
- Alcohol
- Recreational drugs
- Daily life activity and change of limitations
- Eligibility for certain occupations

General examination

- Ensure privacy, good light, explain what you are going to do and take permission
- Wash hand, wear gloves
- **Exposure**
- **Position**



From **right side** of the patient

General:

- Comment on patient position in bed
- Level of consciousness
- Looks well or ill
- Breathless, cyanosed
- Distressed, frightened

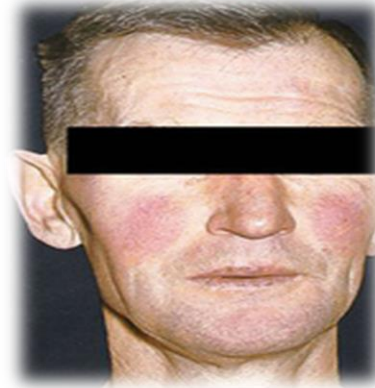Face

Eyes

- Xanthelasmata on eyelids
- Conjunctival pallor and petechial hemorrhage
- Corneal arcus on iris
- Fundoscopy to view the fundus looking for DM or HTN changes, or Roth spots

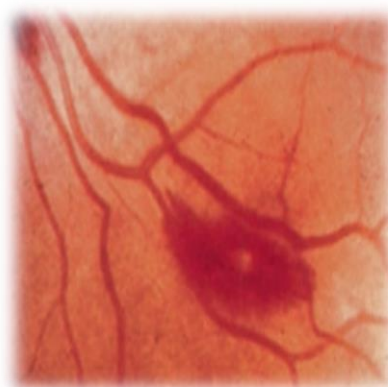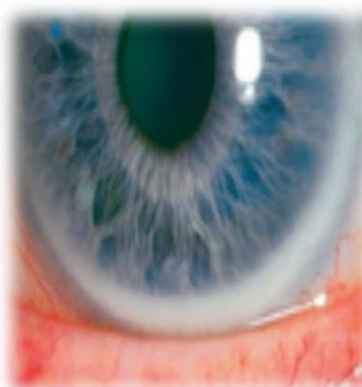
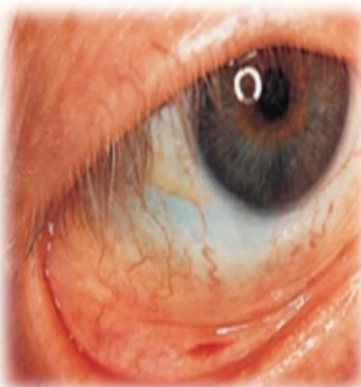
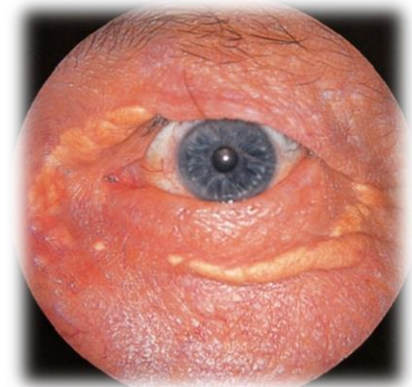
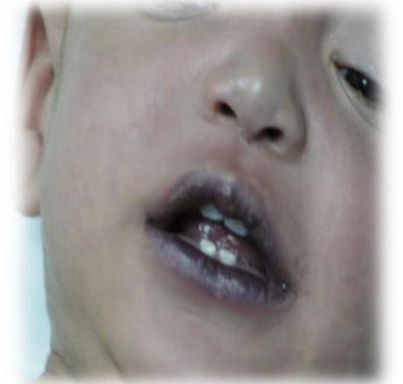Cheeks

Malar flush



Mouth

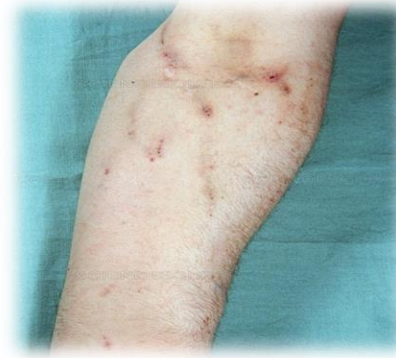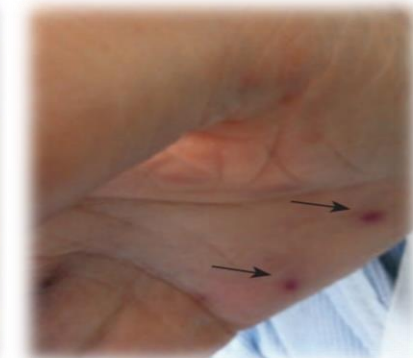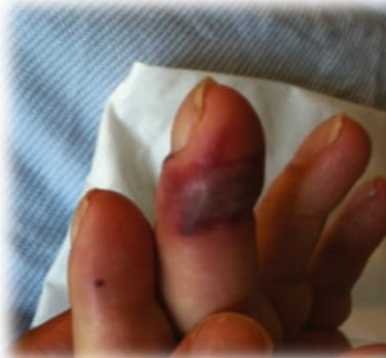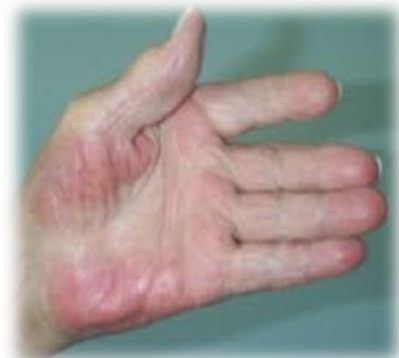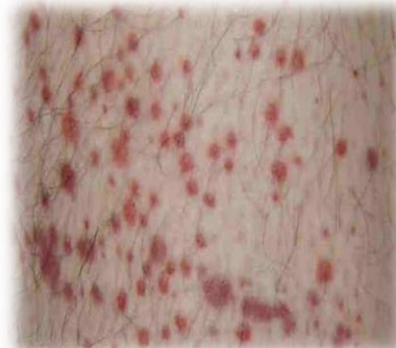
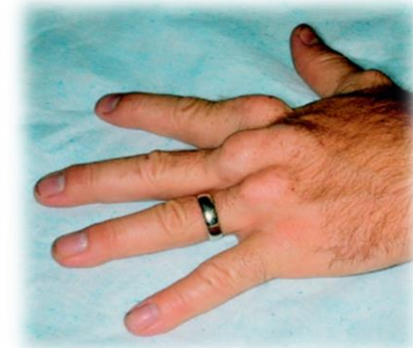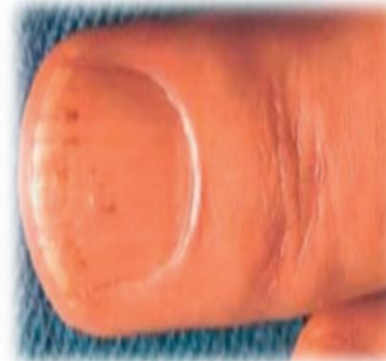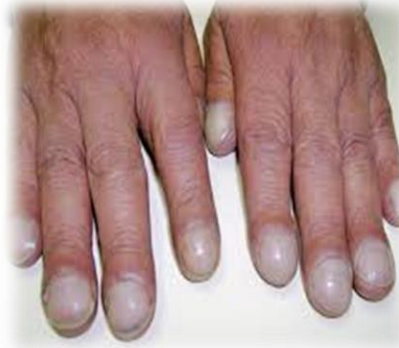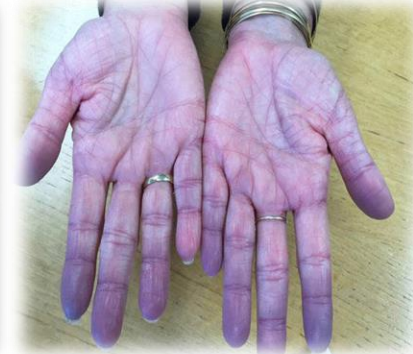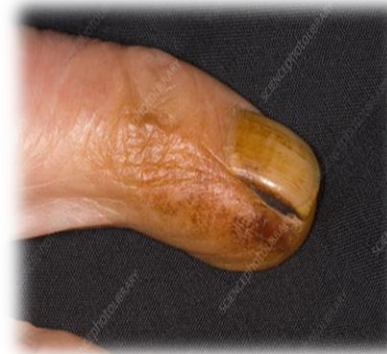Cyanosis under the tongue or on the lips



Hands

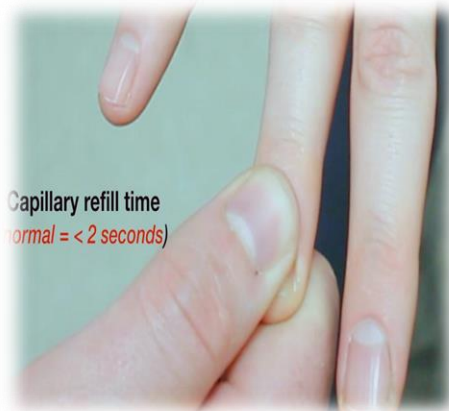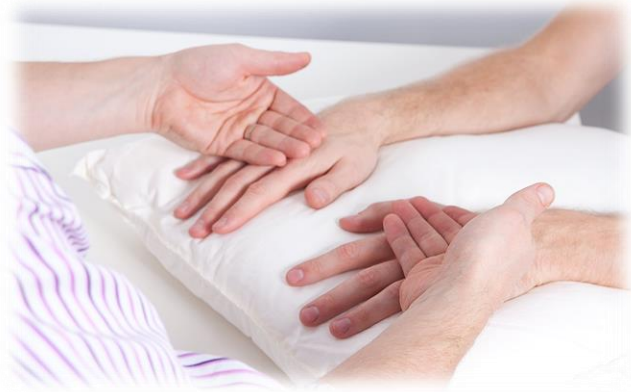- Inspection

- Nails: tobacco stain, cyanosis, clubbing, splinter hemorrhage
- dorsum: tendon xanthoma, petechial rash
- Palmar aspect: palmar erythema, Osler nodes, Janeway lesion
- IV drug use site
- Tremor



Palpation

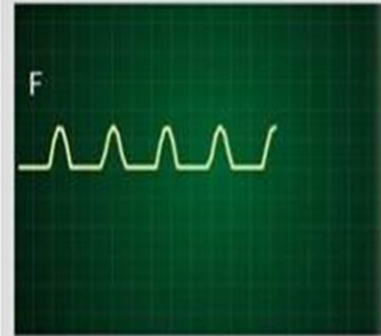
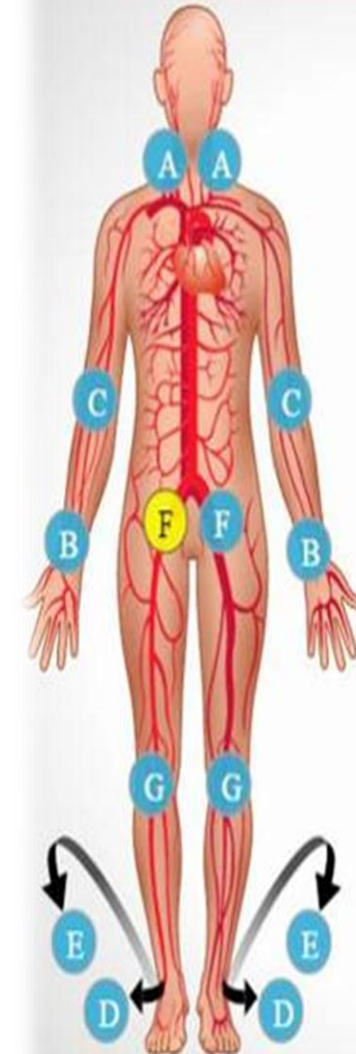
- Temperature
- Wet/dry
- Capillary refill
- Pulses



Capillary refill time
(normal = < 2 seconds)



Peripheral Pulses

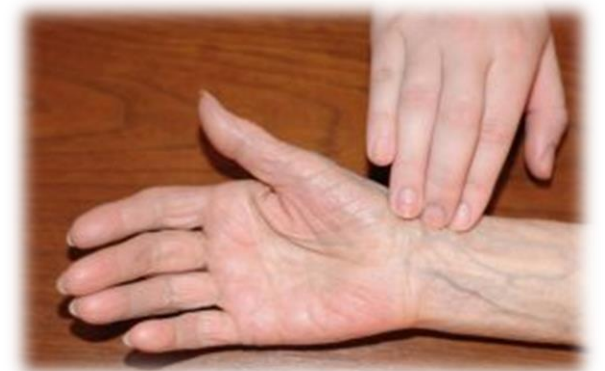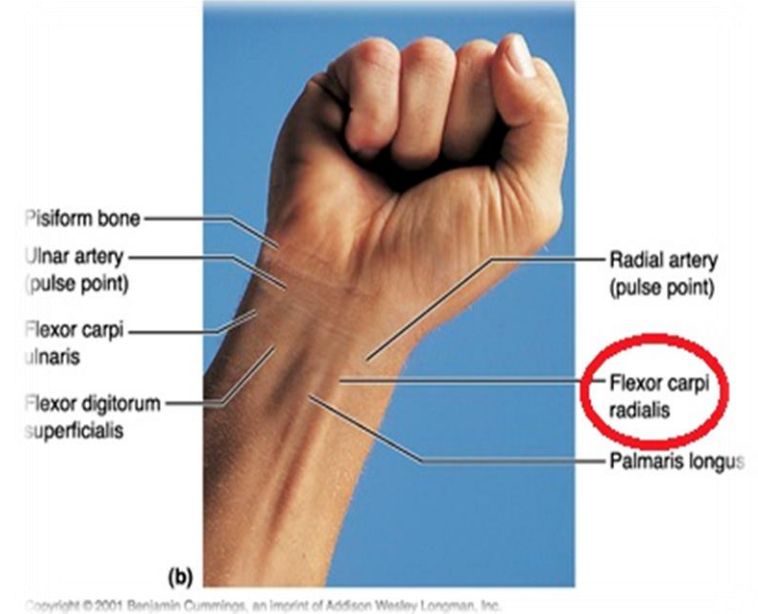


A	Common Carotid Artery	A
B	Radial Artery	B
C	Brachial Artery	C
D	Dorsalis Pedis artery	D
E	Posterior Tibial Artery	E
F	Femoral Artery	F
G	Popliteal Artery	G
B&F	Radiofemoral delay	B&F
B&B	RadioRadial delay	B&B

Arterial pulses

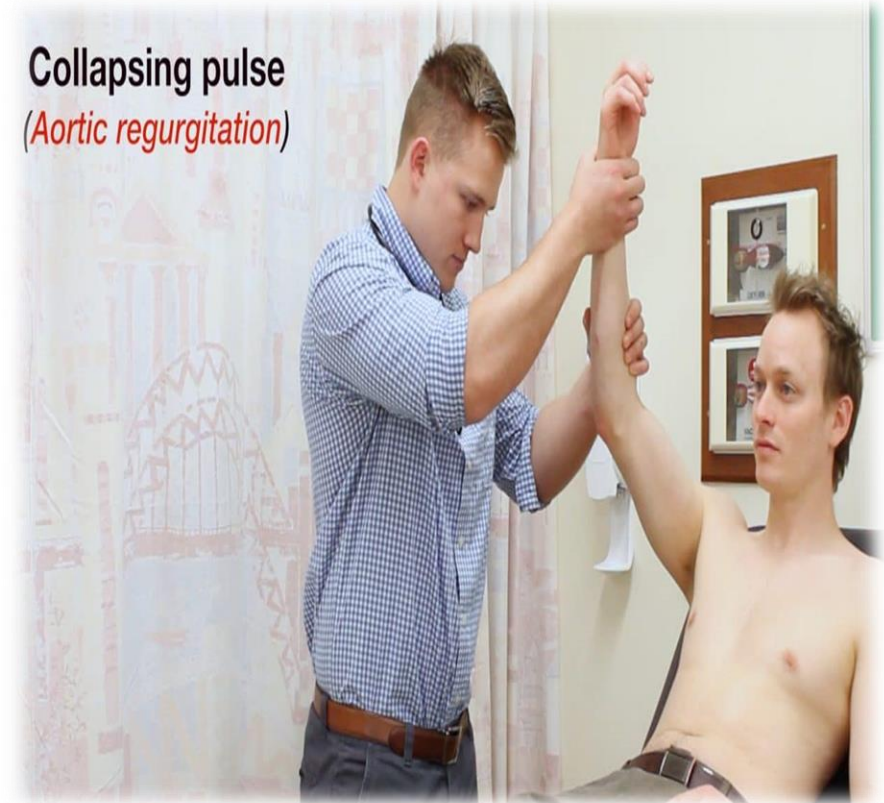- Radial pulse:

- On the right wrist, locate flexor carpi radialis tendon
- Feel just lateral to the tendon with the pads of 3 fingers
- Count for 1 minute
- Comment of rate, rhythm, volume character and compressibility
- Feel both sides simultaneously for radio-radial delay
- Feel radial artery and femoral artery simultaneously for radio-femoral delay
- Check for collapsing pulse
- Calculate pulse deficit



Collapsing pulse

- Palpate the radial pulse
- Ask the patient if he has shoulder or arm pain
- Using base of the fingers, elevate the hand above the patient's head



Pulse deficit

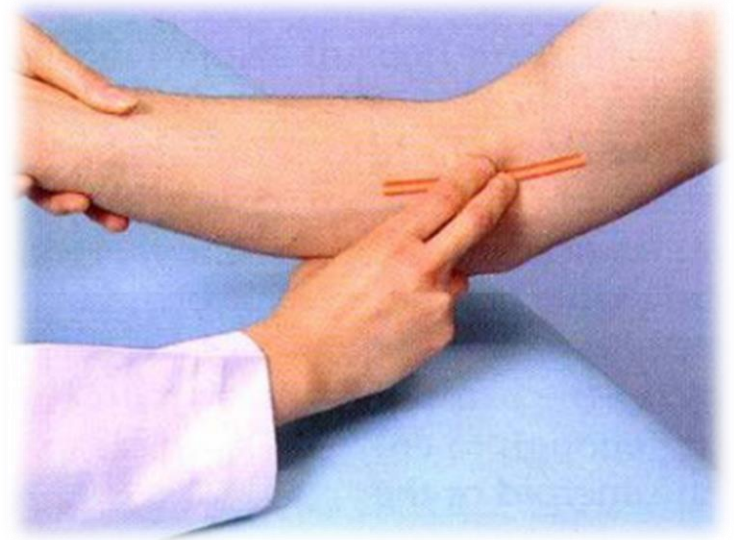
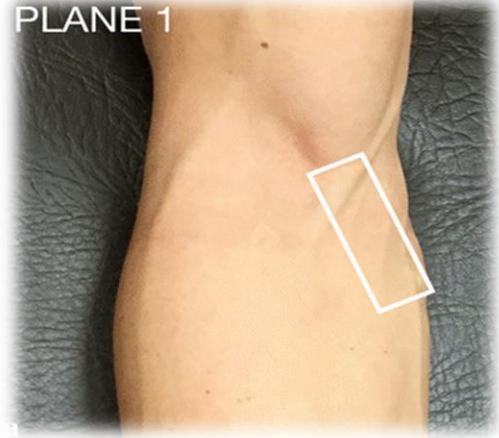
- Should have 2 examiners, one for palpation and one for auscultation
- If one examiner only; can palpate for 1 minute, auscultate for another 1 minute
- Palpate the radial artery and calculate the rate over 1 minute
- Auscultate over the heart apex and calculate the rate over 1 minute
- The deficit between HR by auscultation and pulse rate by palpation should not exceed 10 bpm



Brachial artery

- Medial to biceps tendon in antecubital fossa by index and middle fingers
- Comment of volume, character, and compressibility

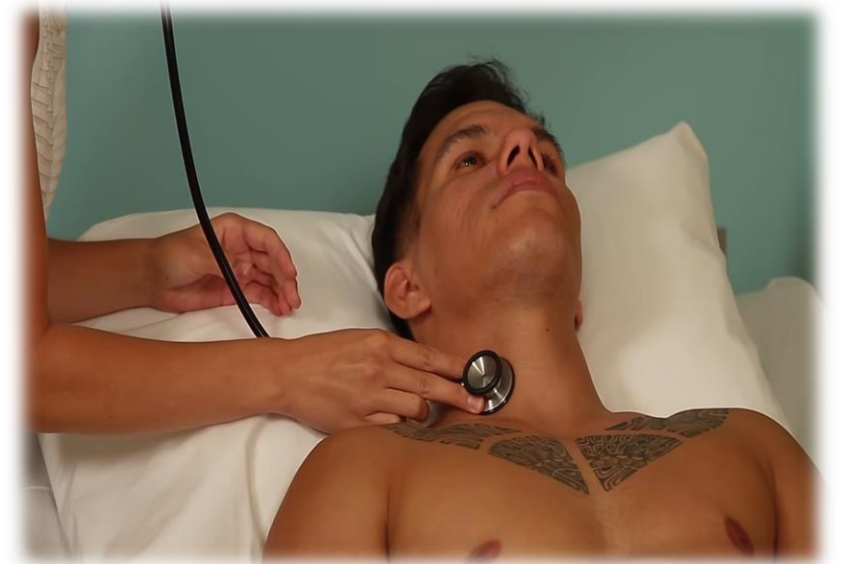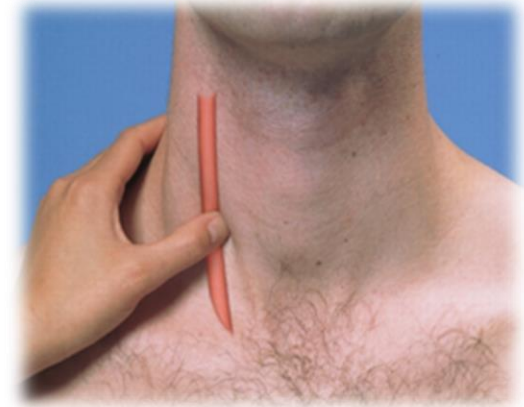
PLANE 1



Carotid pulse

- Explain what are you going to do.
- Feel it between the larynx and anterior border of SCM muscle
- Press gently by the thumb
- **DON'T FEEL BOTH SIDES SIMULTANEOUSLY**

- AUSCULTATE FOR **BRUIT** ON BOTH SIDES WHILE HOLDING HIS BREATH



Rate

- Normal heart rate 60-100 bpm
- Tachycardia > 100 bpm
- Bradycardia < 60 bpm

4.9 Causes of abnormal pulse rate or rhythm

Abnormality	Sinus rhythm	Arrhythmia
Fast rate (tachycardia, > 100 bpm)	Exercise Pain Excitement/anxiety Fever Hyperthyroidism Medication: Sympathomimetics, e.g. salbutamol Vasodilators	Atrial fibrillation Atrial flutter Supraventricular tachycardia Ventricular tachycardia
Slow rate (bradycardia, < 60 bpm)	Sleep Athletic training Hypothyroidism Medication: Beta-blockers Digoxin Verapamil, diltiazem	Carotid sinus hypersensitivity Sick sinus syndrome Second-degree heart block Complete heart block
Irregular pulse	Sinus arrhythmia Atrial extrasystoles Ventricular extrasystoles	Atrial fibrillation Atrial flutter with variable response Second-degree heart block with variable response

Rhythm

- Normally should be regular with some physiological hemodynamic changes
- Comment: regular, irregularly regular, irregularly irregular

4.10 Haemodynamic effects of respiration

	Inspiration	Expiration
Pulse/heart rate	Accelerates	Slows
Systolic blood pressure	Falls (up to 10 mmHg)	Rises
Jugular venous pressure	Falls	Rises
Second heart sound	Splits	Fuses

4.11 Common causes of atrial fibrillation

- Hypertension
- Heart failure
- Myocardial infarction
- Thyrotoxicosis
- Alcohol-related heart disease
- Mitral valve disease
- Infection, e.g. respiratory, urinary
- Following surgery, especially cardiothoracic surgery

Volume

- Stroke volume
- Since ventricles fill during diastole, longer diastolic interval associated with increase stroke volume so increase in pulse volume on examination

• Large pulse volume

• Low pulse volume

• Asymmetrical pulse volume

- Sever heart failure
- Condition associated with inadequate ventricular filling (hypovolemia, cardiac tamponade, mitral stenosis)

- Peripheral artery disease
- Aortic dissection
- Coarctation of aorta

Physiological

- Exercise
- Pregnancy
- Advanced age
- Increased environmental temperature

Pathological

- Hypertension
- Fever
- Thyrotoxicosis
- Anaemia
- Aortic regurgitation
- Paget's disease of bone
- Peripheral atrioventricular shunt

Character

- Slow rising pulse
- Collapsing pulse
- Pulsus bisferiens
- Pulsus alternans (volume rather than character)
- Pulsus paradoxus

Slow rising pulse

- Gradual upstroke with a reduced peak occurring late in systole
- Severe aortic stenosis

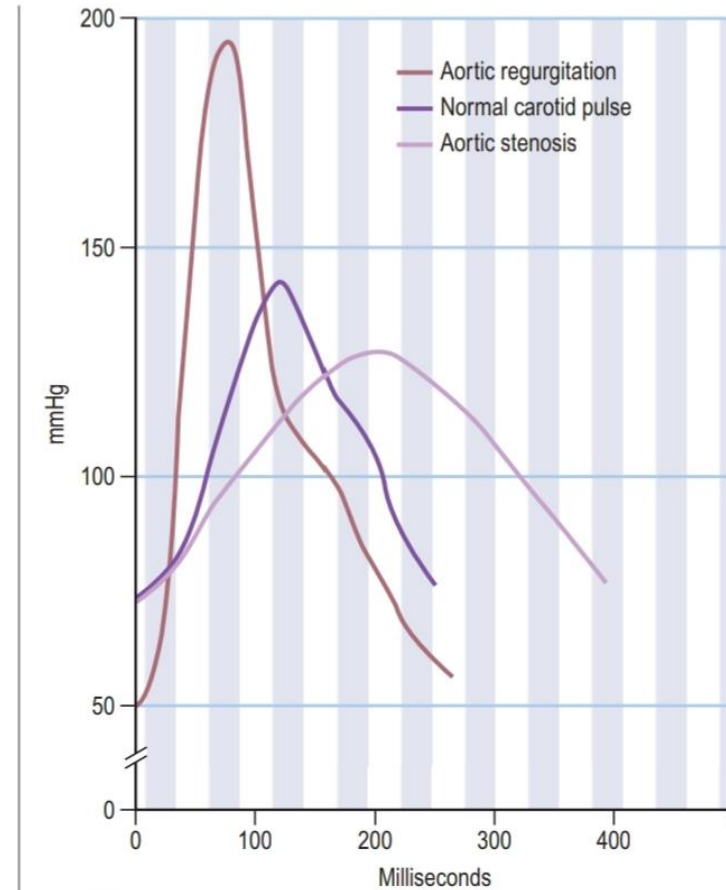
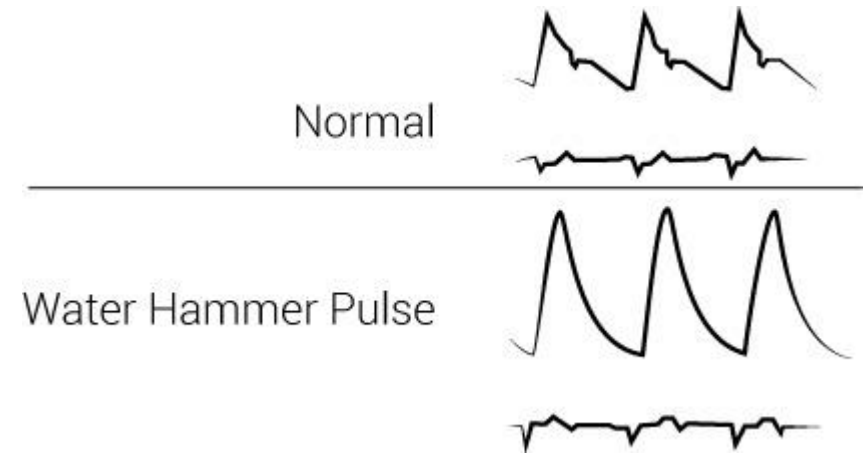


Fig. 4.10 Pulse waveforms.

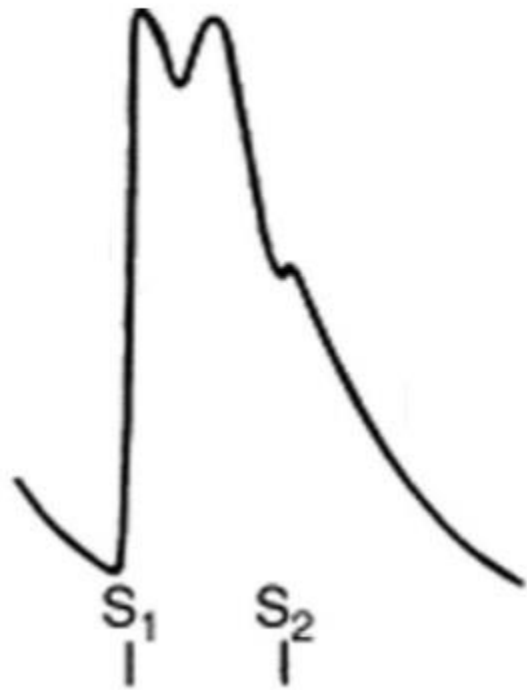Collapsing pulse

- The peak of the pulse wave arrives early and is followed by rapid fall in pressure as blood flows back into LV, resulting in wide pulse pressure
- Pulse pressure (systolic Bp- diastolic Bp > 80 mmHg)
- Severe aortic regurgitation



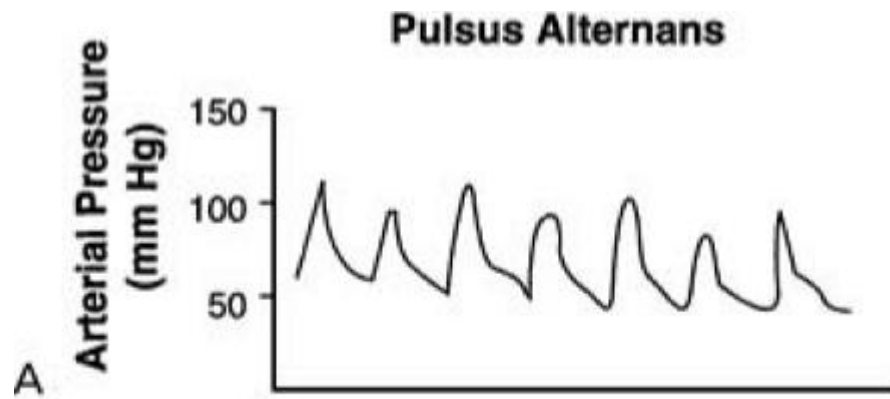
Pulsus bisferiens

Pulsus Bisferiens



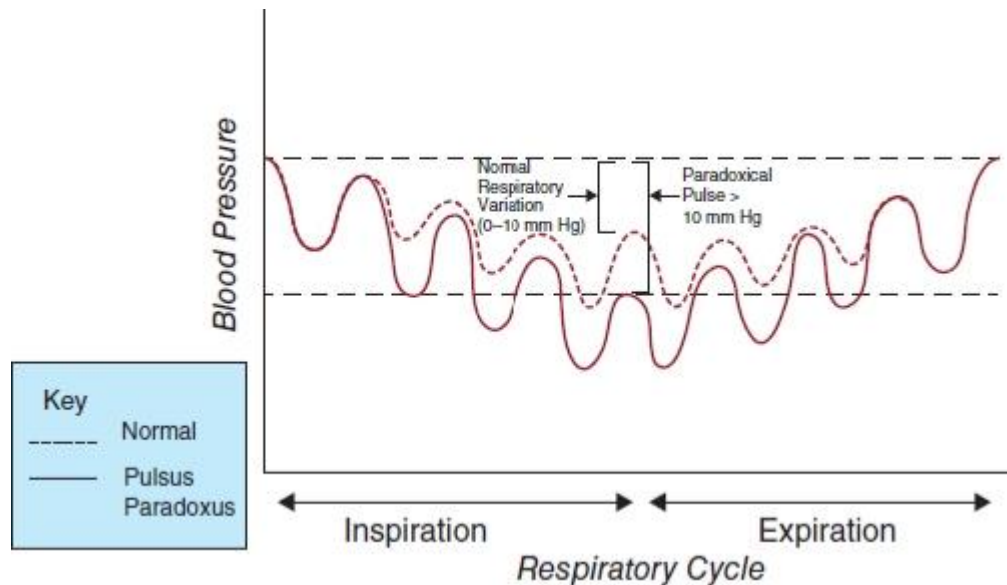
- Increased pulse with a double systolic peak separated by distinct mid-systolic dip
- Concomitant aortic stenosis and aortic regurgitation
- HCOM

Pulsus alternans



- Beat-to-beat variation in pulse volume with normal rhythm
- Advanced heart failure

Pulsus paradoxus



- Exaggeration of the normal variability of pulse volume with breathing
- Pulse volume normally increase with expiration decreases during inspiration due to intrathoracic pressure changes affecting venous return to the heart
- This variability is exaggerated when ventricular diastolic filling is impeded by elevated intrapericardial pressure
- cardiac tamponade, pericardial constriction, acute severe asthma

Blood pressure

- Blood pressure is the measure of the pressure that the circulating blood exerts against arterial wall
- Systolic pressure: maximal pressure that occur during systole
- Diastolic pressure: the lowest value of pressure during diastolic filling, which is maintained at a lower level by elasticity and compliance of the vessel wall
- Is measured by sphygmomanometer or invasively by intra-arterial catheter in ICU setting
- Record the reading as systolic pressure/diastolic pressure with mmHg as the measurement unit, note of where and how it was recorded

e.g. 120/85 mmHg, left arm, sitting

Hypertension

- Abnormal elevation of blood pressure from normal range
 - Many guidelines
 - SILENT KILLER
1. Essential hypertension: most cases, without identifiable cause
 2. Secondary hypertension: rare
 3. Whit coat Hypertension: elevated BP in healthcare setting, while normal away, use ambulatory measurement to diagnose it

4.13 British Hypertension Society classification of blood pressure (BP) levels

BP	Systolic BP (mmHg)	Diastolic BP (mmHg)
Optimal	<120	<80
Normal	<130	<85
High normal	130–139	85–89
Hypertension		
Grade 1 (mild)	140–159	90–99
Grade 2 (moderate)	160–179	100–109
Grade 3 (severe)	>180	>110
Isolated systolic hypertension		
Grade 1	140–159	<90
Grade 2	>160	<90

Reproduced by kind permission of the British and Irish Hypertension Society.

Approach to hypertension

- Assess symptoms
 - Assess for potential cause
 - Assess for end-organ damage
1. Cardiac
 2. Renal
 3. Eye

4.14 Clinical clues to secondary hypertension

Clinical feature	Cause
Widespread vascular disease Renal bruit	Renovascular disease, including renal artery stenosis
Episodes of sweating, headache and palpitation	Phaeochromocytoma
Hypokalaemia	Primary aldosteronism
Cushingoid facies, central obesity, abdominal striae, proximal muscle weakness Chronic glucocorticoid use	Cushing's syndrome
Low-volume femoral pulses with radiofemoral delay	Coarctation of the aorta
Bilateral palpable kidneys	Adult polycystic kidney disease (p. 243)

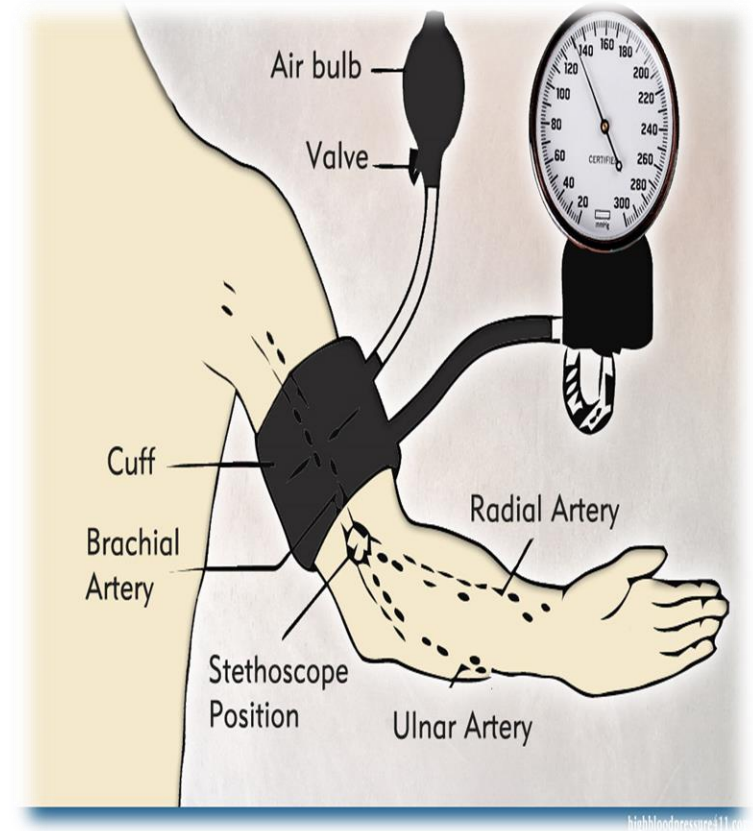
Korotkoff sounds

- Snapping sound that is produced when the cuff pressure is between systolic and diastolic because the artery collapses completely and reopen with each heartbeat
- First sound appearance (phase 1) indicate systole
- When the sounds muffle and then disappear (phase 5) indicate diastole

Phase	Korotkoff sounds
	120 mmHg systolic
1	A thud
	110 mmHg
2	A blowing noise
	100 mmHg
3	A softer thud
	90 mmHg diastolic (1st)
4	A disappearing blowing noise
	80 mmHg diastolic (2nd)
5	Nothing

How to measure blood pressure?

- Rest for 5 minutes
- No tight clothing
- Support the arm at the heart level
- Proper cuff size
- Apply the cuff to the upper arm, with the center of bladder over brachial artery
- Palpate brachial artery
- Inflate cuff until the pulse is impalpable around 30 mmHg above, put the diaphragm of stethoscope on brachial artery and deflate slowly
- Measure in both arms



- First sound to hear is systolic pressure
- When the sounds completely disappear this is diastolic pressure
- If the muffled sounds persist (phase 4) and do not disappear, use the point of muffling as diastolic pressure

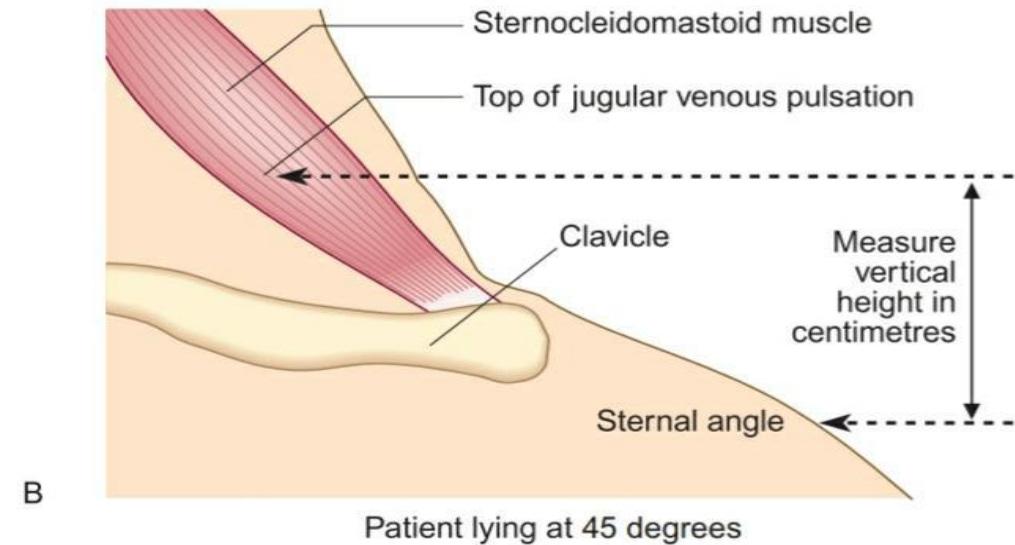
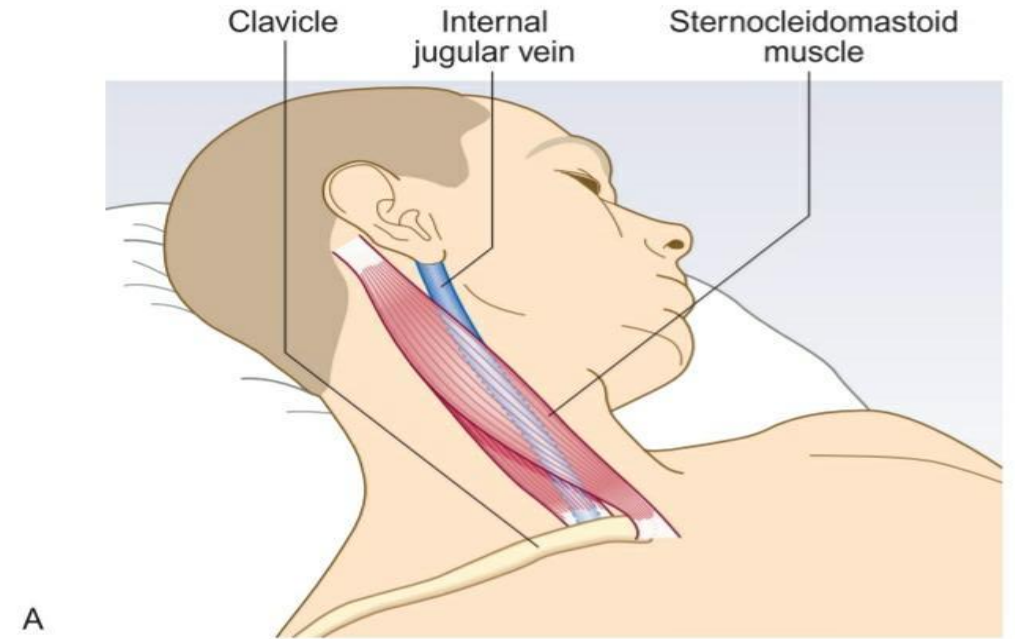
Common BP measurement problems

- **Difference** > 10 mmHg in each arm (suggest aortic or subclavian artery disease)
- **Wrong cuff size:** the bladder should be 80% of the length and 40% of the width of upper arm
- **Auscultatory gap:** 20% of elderly hypertensive patients, when Korotkoff sounds appear at systolic BP and disappear for an interval between systolic and diastolic pr. Avoid by palpating the systolic BP
- Pt's arm at **the wrong level:** elbow should be at the level of the heart
- **Postural change:** check for postural hypotension
- **Atrial fibrillation:** take average value

Jugular venous pressure

Jugular venous pressure and waveform

- What does the JVP reflect?
- Normally measures < 7 mmHg/ 9 cmH₂O when the patient lies at 45 degrees
- Internal jugular vein vs. External jugular vein?
- How to differentiate between jugular and venous pulsation?



4.15 Differences between carotid artery and jugular venous pulsation

Carotid	Jugular
Rapid outward movement	Rapid inward movement
One peak per heart beat	Two peaks per heart beat (in sinus rhythm)
Palpable	Impalpable
Pulsation unaffected by pressure at the root of the neck	Pulsation diminished by pressure at the root of the neck
Independent of respiration	Height of pulsation varies with respiration
Independent of the position of the patient	Varies with the position of the patient
Independent of abdominal pressure	Rises with abdominal pressure

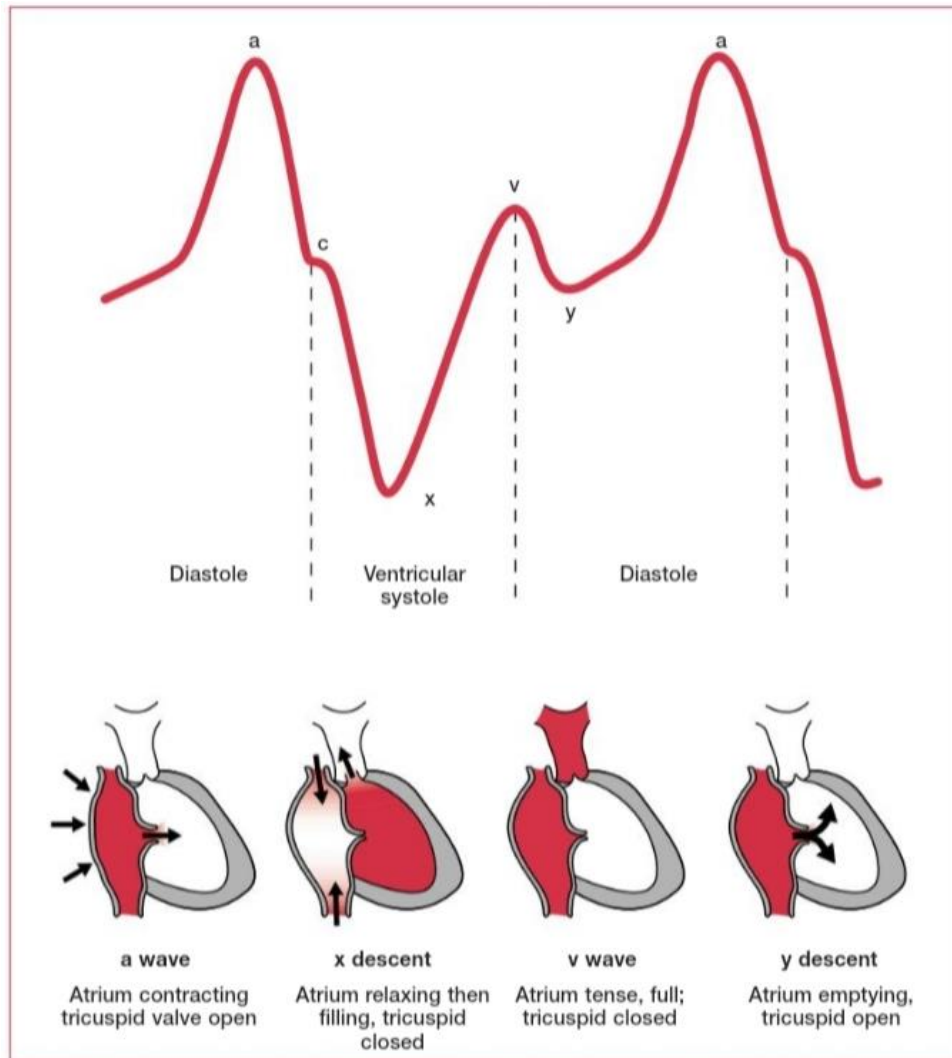


Figure 1. Waveforms of the jugular venous pressure (including a brief explanation for each wave). The “c” wave represents right ventricular contraction “pushing” the tricuspid valve back into the right atrium. Reproduced with permission from Oxford University Press (Longmore JM et al. *The Oxford Handbook of Clinical Medicine*, 5th Edn, p. 79).

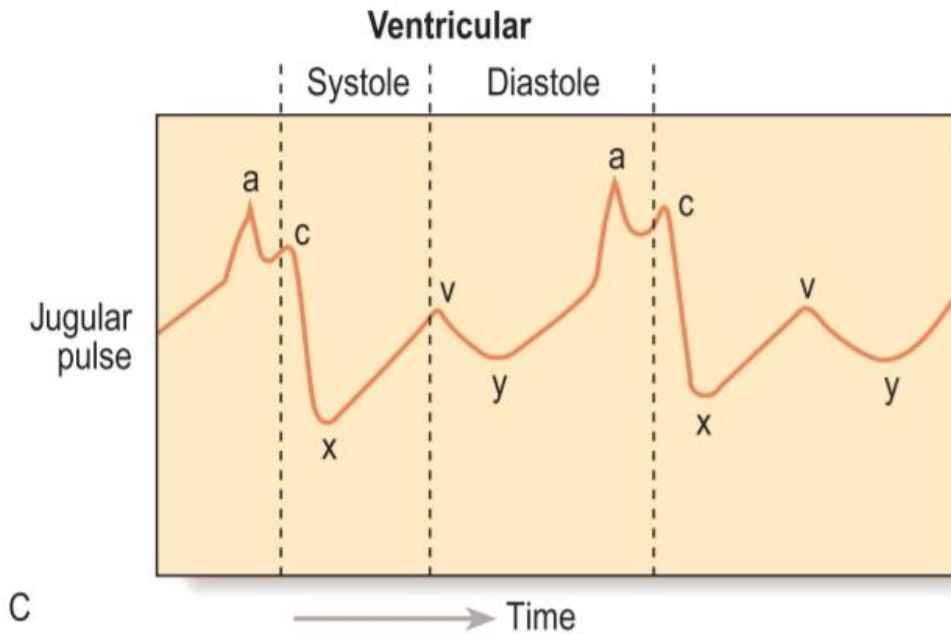
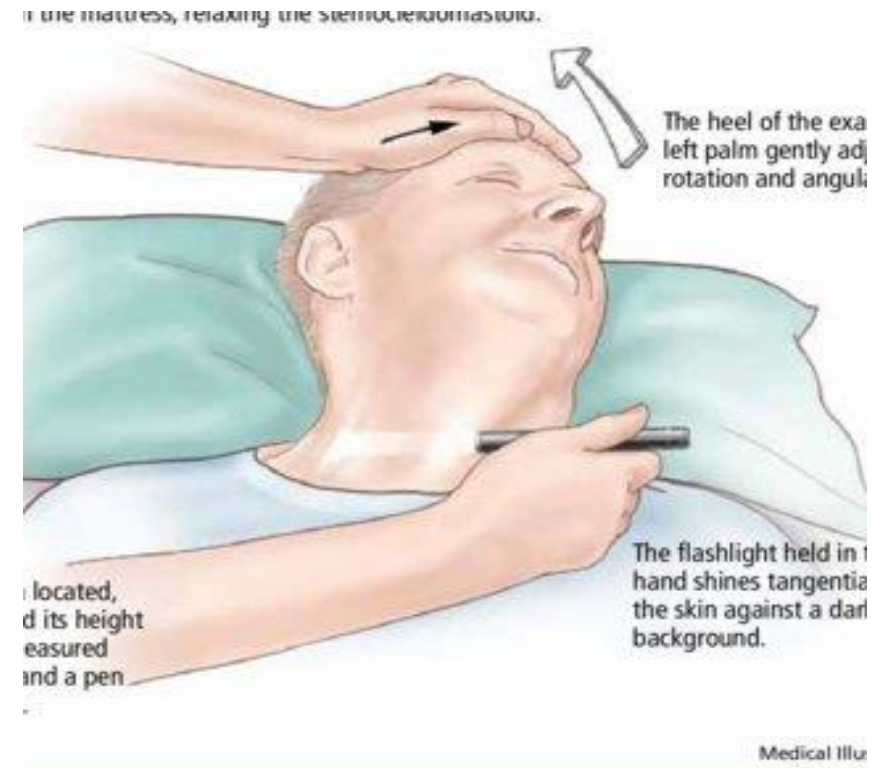


Fig. 4.15 Jugular venous pressure. **A** Inspecting the jugular venous pressure from the side (the internal jugular vein lies deep to the sternocleidomastoid muscle). **B** Measuring the height of the jugular venous pressure. **C** Form of the venous pulse wave tracing from the internal jugular vein: *a*, atrial systole; *c*, closure of the tricuspid valve; *v*, peak pressure in the right atrium immediately prior to opening of the tricuspid valve; *a*–*x*, descent, due to downward displacement of the tricuspid ring during systole; *v*–*y*, descent at the commencement of ventricular filling.

Jugular venous pressure examination

- Be on the right side of the patient
- Position the patient supine, reclined on 45 degrees, with pillow below the head and slightly turned to the left with adequate exposure
- Use the light
- Identify Jugular venous pulsation



1. Inspection

- Diffuse inward movement
- Two waves per pulse

2. Palpation

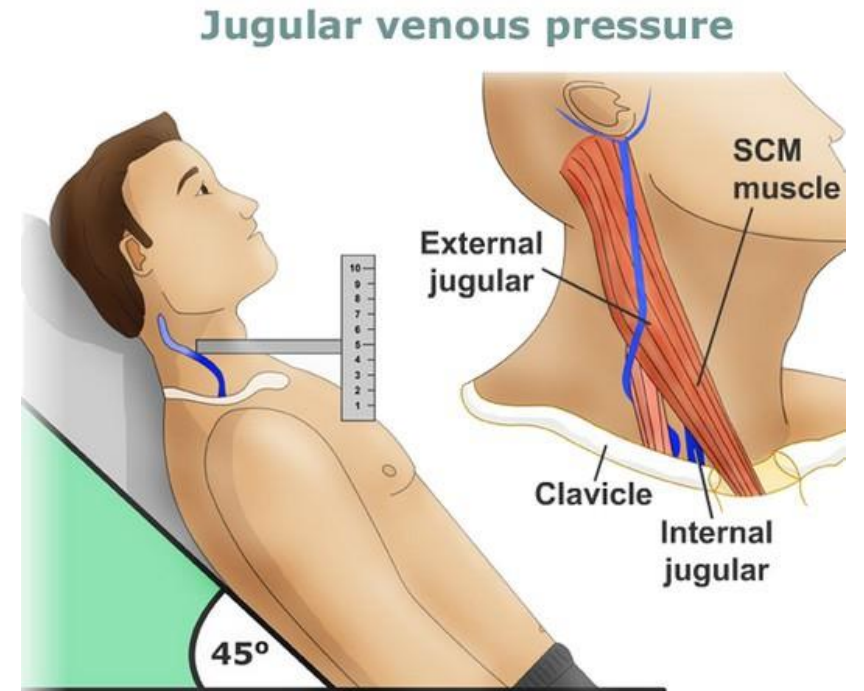
- Impalpable
- Compress at the root of the neck it will disappear with pressure

3. Special maneuvers

- Varies with respiration (decreases with inspiration)
- Ask patient to lie flat (increase with lying flat)
- Abdominojugular reflux

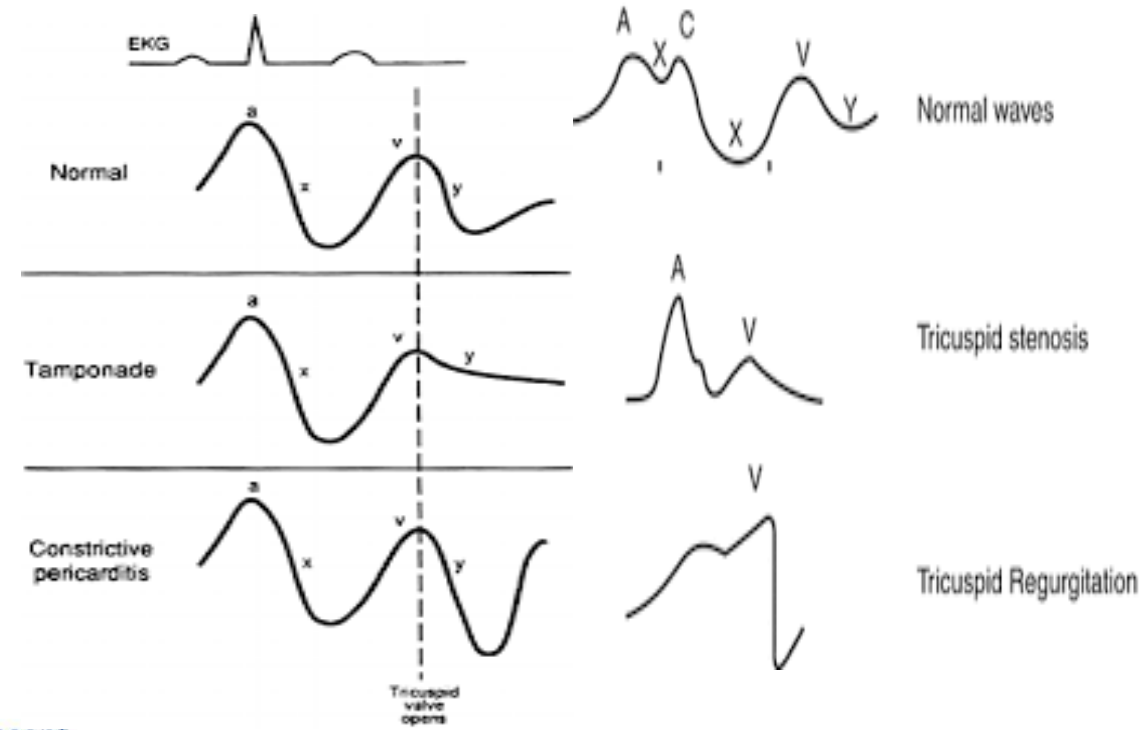
4. Measure JVP height

- Between tip of visible pulsation and the sternal angle
- Unit: cmH₂O

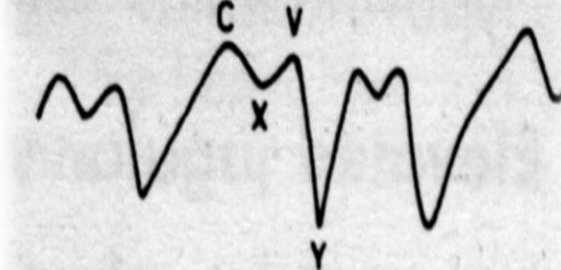


4.16 Abnormalities of the jugular venous pulse

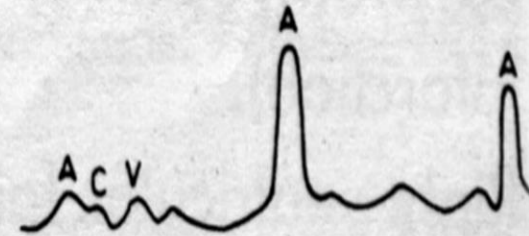
Condition	Abnormalities
Heart failure	Elevation, sustained abdominojugular reflux > 10 seconds
Pulmonary embolism, tamponade	Elevation
Pericardial effusion	Elevation, prominent flattened 'y' descent
Pericardial constriction	Elevation, Kussmaul's sign, prominent 'y' descent 'x' descent
Superior vena cava obstruction	Elevation, loss of pulsation
Atrial fibrillation	Absent 'a' waves
Tricuspid stenosis	Giant 'a' waves Large, prominent
Tricuspid regurgitation	Giant 'v' or 'cv' waves
Complete heart block	'Cannon' waves



E. Atrial Fibrillation

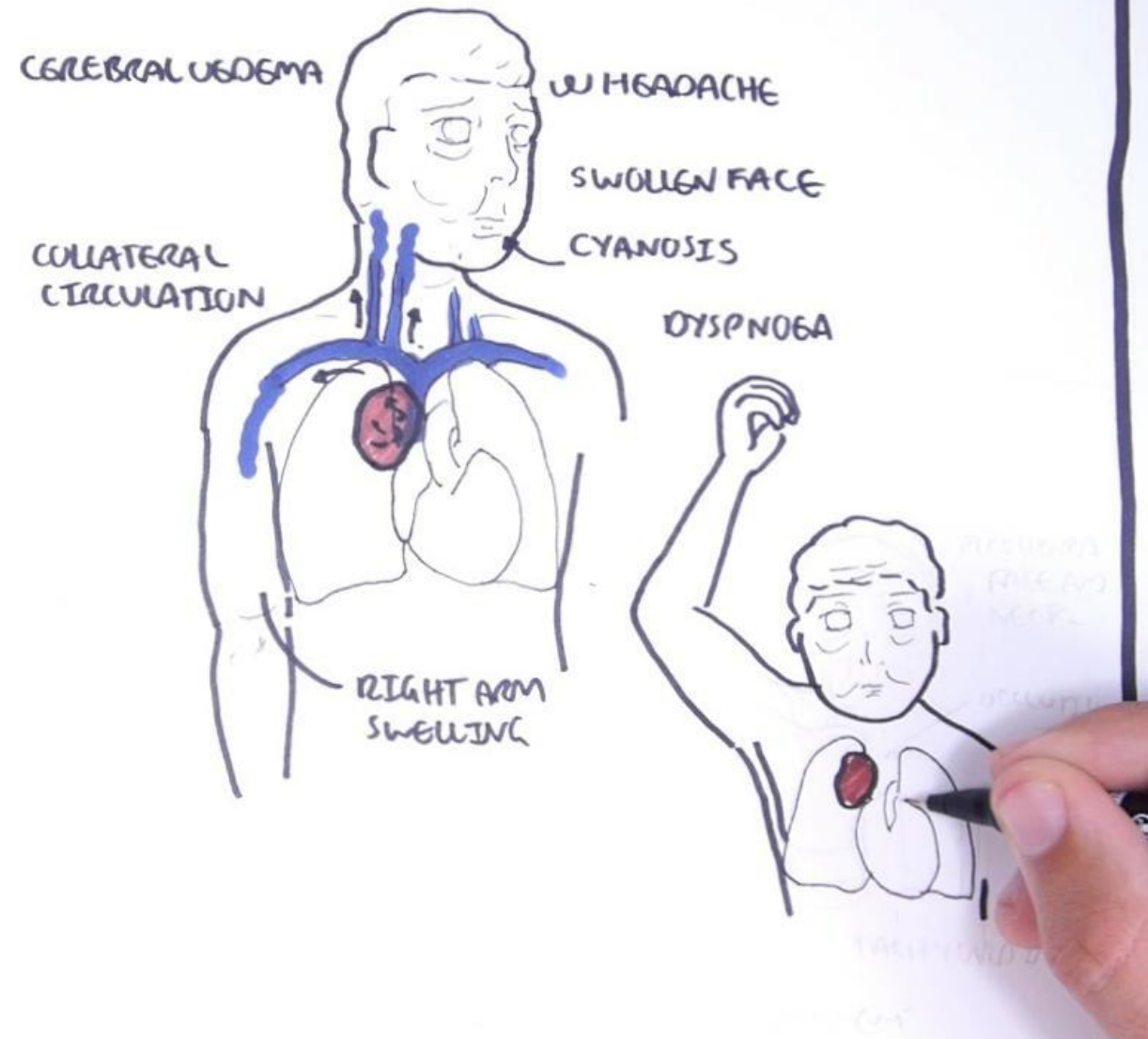


G. Complete AV Block



Superior vena cava obstruction

- Non-pulsatile JVP elevation
- Negative abdominojugular reflux
- DOESN'T reflect right atrial pressure



Kussmaul's sign

- Paradoxical elevation of JVP with inspiration
- Differential diagnosis:
 1. Pericardial constriction
 2. Severe right ventricular failure
 3. Restrictive cardiomyopathy

