

Which of the following is anterior to the left kidney



Skip

23



9
Answers

▲ Liver

◆ Hepatic flexure


● Second part of duodenum

■ Coils of the small intestine

Which of the following is anterior to the left kidney



Next



Show media

End game

▲ Liver ✕

◆ Hepatic flexure ✕

● Second part of duodenum ✕


■ Coils of the small intestine ✓

Which of following is posterior to the right ureter



Skip

29



0
Answers

▲ Liver

◆ Right colon

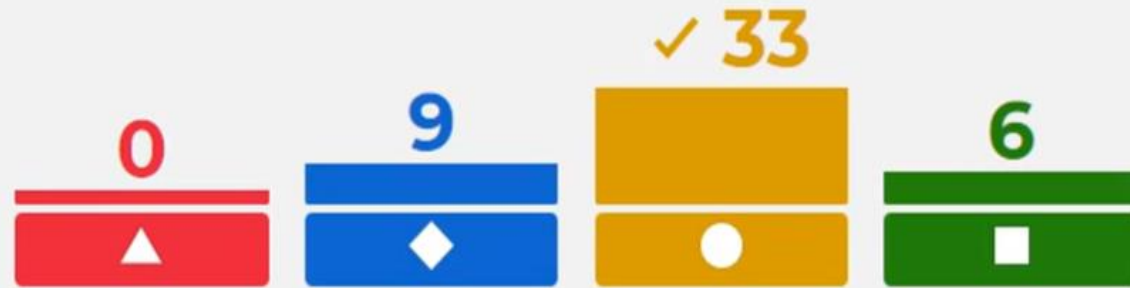● psoas major

■ quadratus lumborum

Which of following is posterior to the right ureter



Next



Show media

End game

▲ Liver



◆ Right colon



● psoas major



■ quadratus lumborum



The renal artery arises at the level of



skip

22



19
Answers

▲ T12

◆ L1

● L2

■ L3

The renal artery arises at the level of



Next

3 19 ✓ 25 2

▲ L2

◆ L1

● L2

■ L3

Show media

End game

▲ T12



◆ L1



● L2



■ L3



The Inferolateral surface of urinary bladder is related to



Skip

26



0
Answers

▲ Ischial spine

◆ Obturator internus

● Obturator externus

■ Iliac crest

The Inferolateral surface of urinary blader is related to



Next



Show media

End game

▲ Ischial spine



◆ Obturator internus



● Obturator externus



■ Iliac crest

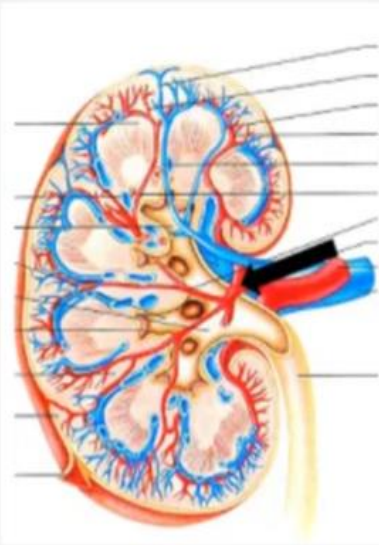


The pointed structure isvessels



Skip

27



0
Answers

▲ Lobar

◆ Arcuate

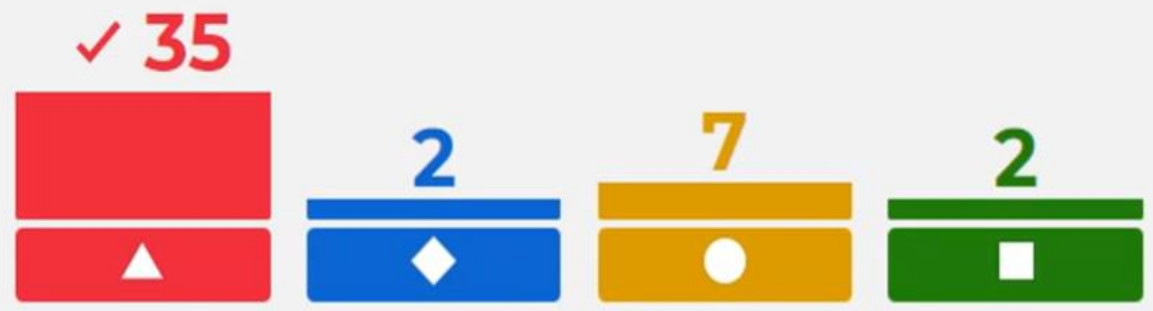● Interlobar

■ Interlobular

The pointed structure isvessels



Next



Show media

End game

▲ Lobar	✓	◆ Arcuate	✗
● Interlobar	✗	■ Interlobular	✗

The shape of the pelvic inlet in females is



Skip

24



8
Answers

▲ Anterior posterior Oval

◆ Heart

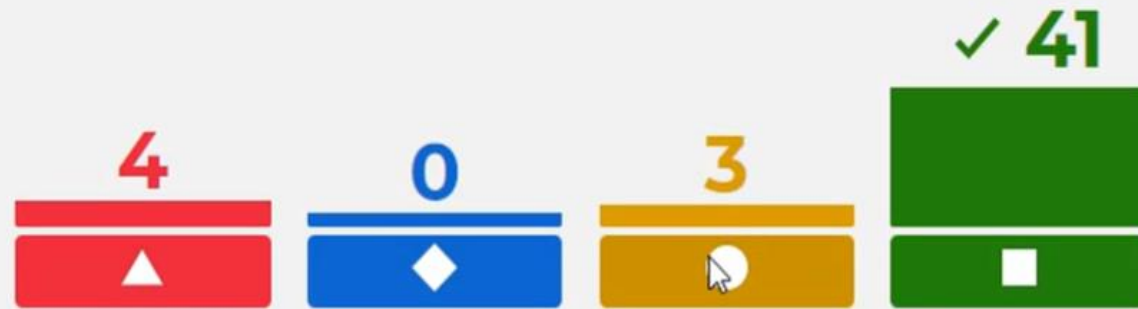● Rounded

■ Transverse Oval

The shape of the pelvic inlet in females is



Next



Show media

End game

▲ Anterior posterior Oval



◆ Heart



● Rounded



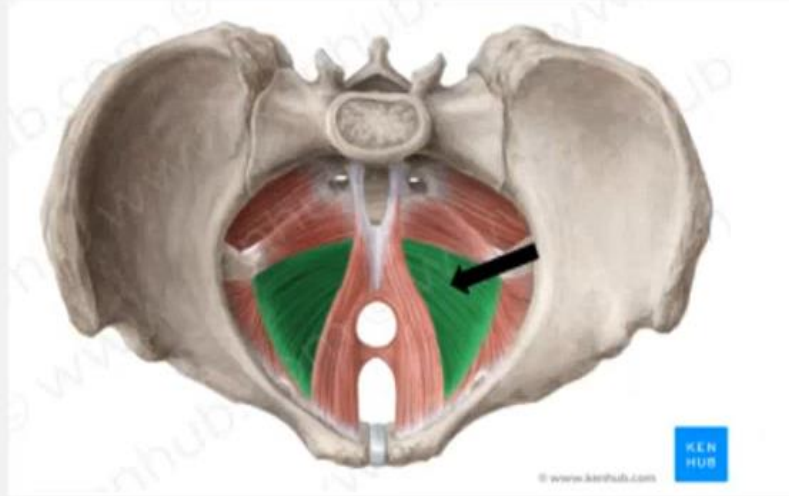
■ Transverse Oval



The pointed structure is muscle



Skip



0
Answers

29

▲ Coccygeus

◆ Iliococcygeus

● puborectalis

■ Pubococcygeus proper

The pointed structure is muscle



Next

8
15
9
16

Show media

End game

▲ Coccygeus ✕

◆ Iliococcygeus ✓

● puborectalis ✕

■ Pubococcygeus proper ✕

Sensation from the small intestine is carried by sympathetic



Skip

13



20
Answers

◆ True

▲ False

Sensation from the small intestine is carried by sympathetic



Next

✓ 34



14



Show media

End game

◆ True



▲ False



All the following are a branch of anterior division of internal iliac artery EXCEPT



Skip

25

Kahoot!

1
Answer

▲ Superior vesical

◆ Middle rectal

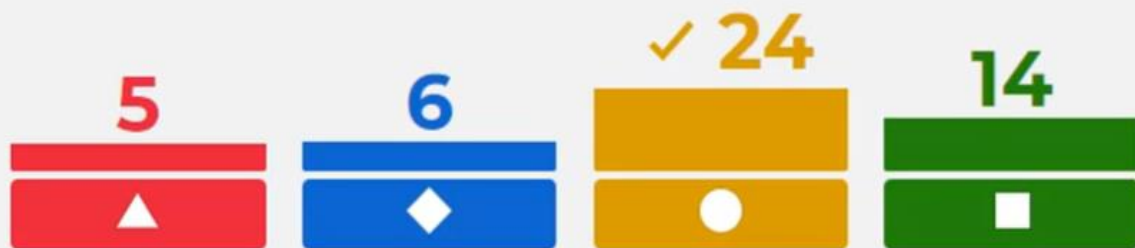● Superior gluteal

■ Internal pudendal

All the following are a branch of anterior division of internal iliac artery EXCEPT



Next



Show media

End game

▲ Superior vesical



◆ Middle rectal



● Superior gluteal



■ Internal pudendal



Which of the following is posterior to the left kidney



Skip

4

Kahoot!

17
Answers

Iliacus

Psoas Major

Internal oblique

External oblique

Which of the following is posterior to the left kidney



Next



Show media

End game

- ▲ Iliacus
- ◆ Psoas Major ✓
- Internal oblique
- External oblique

Which of the following is Anterior to the right kidney



Skip

18



0

Answers

3rd part of duodenum

Right colic flexure

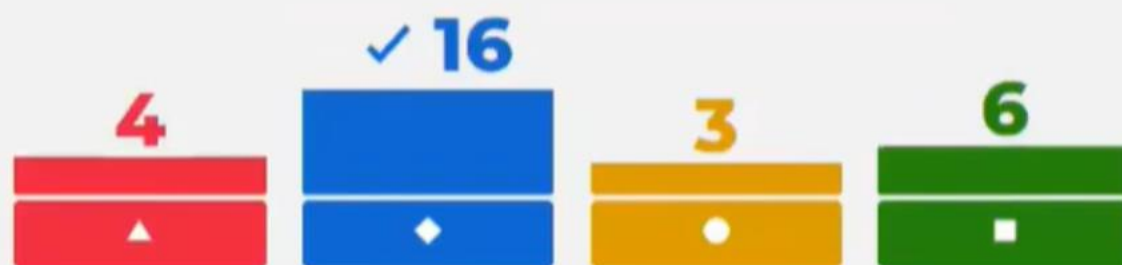Spleen

Ascending colon

Which of the following is Anterior to the right kidney



Next



Show media

End game

▲ 3rd part of duodenum

◆ Right colic flexure ✓

● Spleen

■ Ascending colon

The left renal vein is passing betweenand Aorta



Skip

18

0

Answers

Inferior mesentric artery

Superior mesentric vein

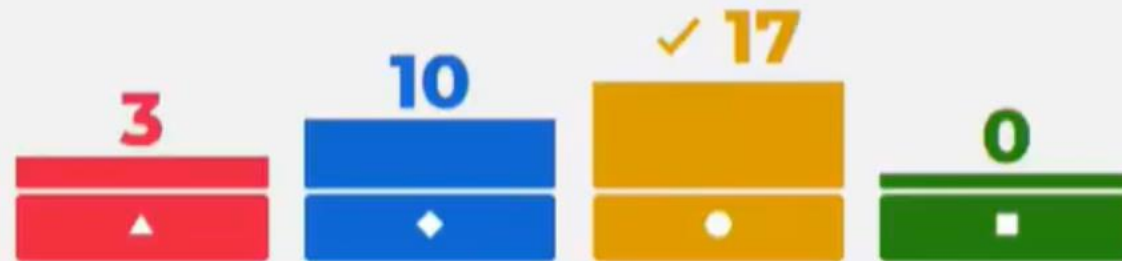
Superior mesentric artery

Portal vein

The left renal vein is passing betweenand Aorta



Next



Show media

End game

▲ Inferior mesentric artery

◆ Superior mesentric vein

● Superior mesentric artery ✓

■ Portal vein

The renal colic pain is referred to



kip



1
Answer

▲ Medial side of thigh


◆ The flanks

● Scrotum

■ around umbilicus

17

The renal colic pain is referred to



text

Show media

End game

▲ Medial side of thigh

◆ The flanks ✓

● Scrotum

■ around umbilicus

External oblique muscle in anterior abdominal wall is replaced in the scrotum by



Skip

23



9
Answers

▲ Skin

◆ External spermatic fascia

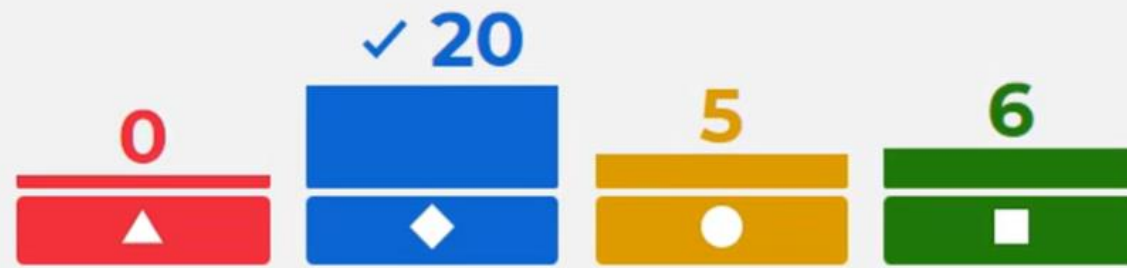● Cremasteric muscle and fascia

■ Colles 's fascia

External oblique muscle in anterior abdominal wall is replaced in the scrotum by



Next



Show media

End game

▲ Skin ✕

◆ External spermatic fascia ✓

● Cremasteric muscle and fascia ✕

■ Colles 's fascia ✕

The left testicular vein is drained by



Skip

22



14
Answers

▲ Inferior Vena cava

◆ Left External iliac vein

● Left internal iliac vein

■ Left renal vein

The left testicular vein is drained by



Next



Show media

End game

▲ Inferior Vena cava ✕

◆ Left External iliac vein ✕

● Left internal iliac vein ✕

■ Left renal vein ✓

The fascia of Denonvilliers is



Skip

24



0
Answers

▲ Anterior to prostate

◆ Anterior to the urinary bladder

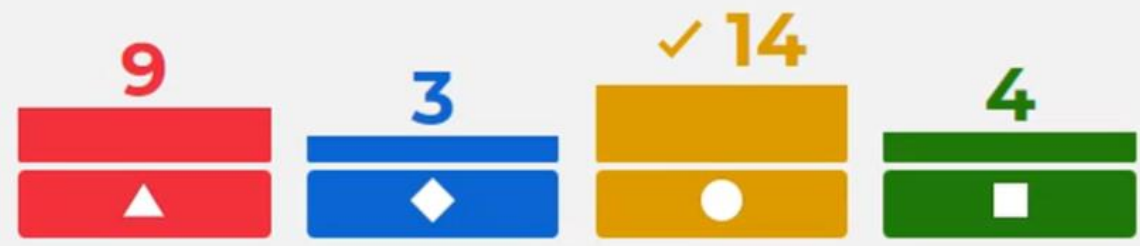● Posterior to prostate

■ Posterior to rectum

The fascia of Denonvilliers is



Next



Show media

End game

▲ Anterior to prostate ✕

◆ Anterior to the urinary bladder ✕

● Posterior to prostate ✓

■ Posterior to rectum ✕

The Bulbourethral Glands is located in



Skip

28



0
Answers

▲ Superficial perineal pouch

◆ False pelvis

● Deep perineal pouch

■ True Pelvis

The Bulbourethral Glands is located in



Next

4 1 ✓ 16 9

Show media

End game

▲ Superficial perineal pouch ✕

◆ False pelvis ✕

● Deep perineal pouch ✓

■ True Pelvis ✕

The deep layer of superficial fascia of testis is called Scarpa's fascia



Skip

14



12
Answers

◆ True

▲ False

The deep layer of superficial fascia of testis is called Scarpa's fascia



Next

9



✓ 20



Show media

End game

◆ True



▲ False

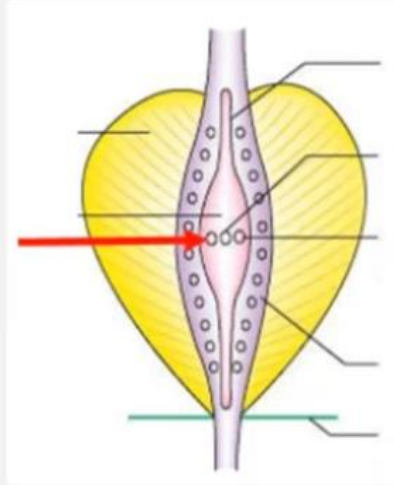


The pointed structure is the opening of



Skip

22



12
Answers

▲ Prostatic utricle

◆ Ejaculatory duct

● Bulbourethral gland

■ Vas deferens

The pointed structure is the opening of



Next

3 18 3 5

Show media

End game

▲ Prostatic utricle ✕

◆ Ejaculatory duct ✓

● Bulbourethral gland ✕

■ Vas deferens ✕

The external oblique muscle is replaced by in the scrotum



Skip

11



17
Answers

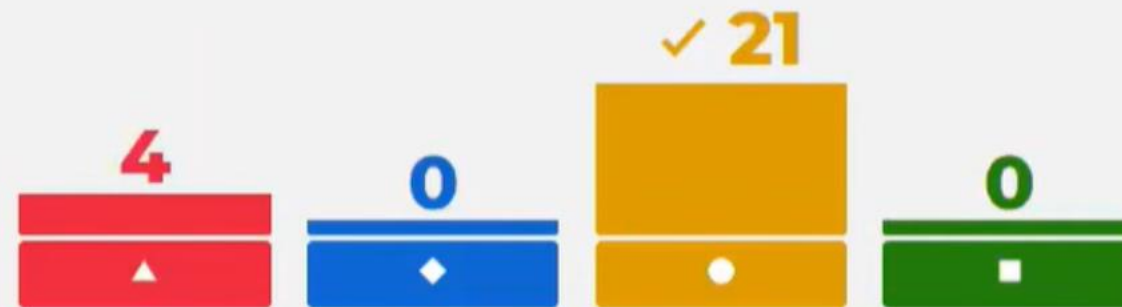
▲ Cremastic muscle and fascia

◆ Internal spermatic fascia

● External spermatic fascia

■ Tunica vaginalis

The external oblique muscle is replaced by in the scrotum



Next

Show media

End game

▲ Cremastric muscle and fascia

◆ Internal spermatic fascia

● External spermatic fascia ✓

■ Tunica vaginalis

The Tunica vaginalis is absent atof the testis



Skip



6

Answers

15



▲ Anterior border

◆ Upper pole

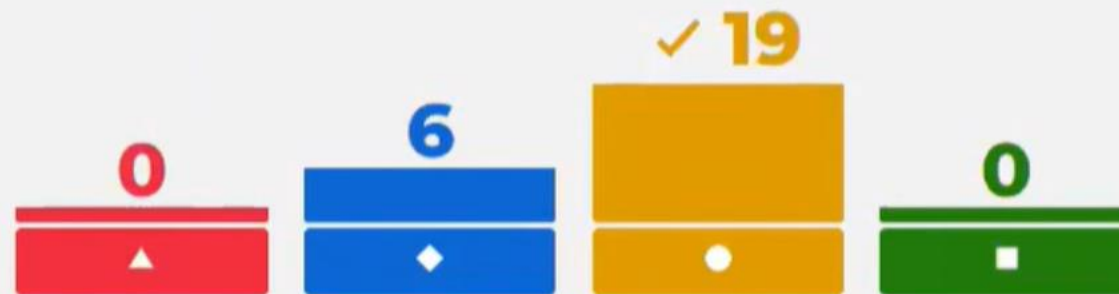
● Posterior border

■ lateral surface

The Tunica vaginalis is absent atof the testis



Next



Show media

End game

▲ Anterior border

◆ Upper pole

● Posterior border ✓

■ lateral surface

The lymphatic drainage of testis is



Skip



16



10
Answers

Players, type your answer!

The lymphatic drainage of testis is



The correct answer is:

Next

7 ✓
lateral aortic

Show media

End game

The uterine tube is related toof the ovary

Adjust volume

Skip

18



0
Answers

▲ Lateral surface

◆ Posterior border

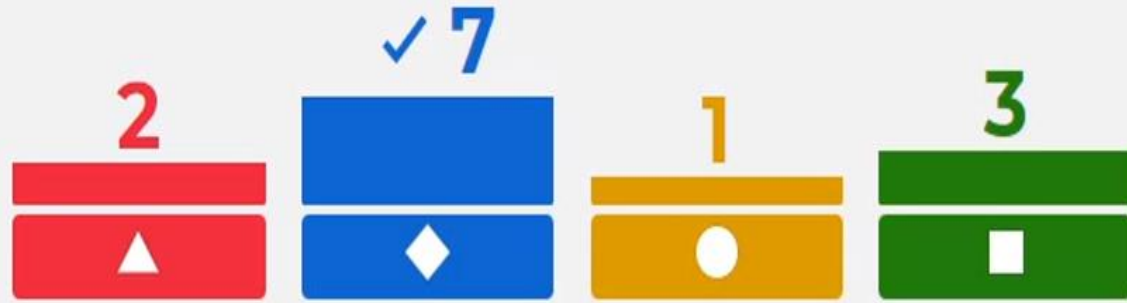● Lower pole

■ Anterior border

The uterine tube is related toof the ovary



Next



Show media

End game

▲ Lateral surface ✕

◆ Posterior border ✓

● Lower pole ✕


■ Anterior border ✕

anteversion is the right angle between the uterus and the vagina.



skip

16



2
Answers

◆ True


▲ False

anteversion is the right angle between the uterus and the vagina.



Next

✓ 11



Show media

End game

◆ True



▲ False



Culdocentesis is done by the passage of a needle through



Skip

0
Answers

17



▲ Anterior vaginal fornix

◆ Lateral vaginal fornix

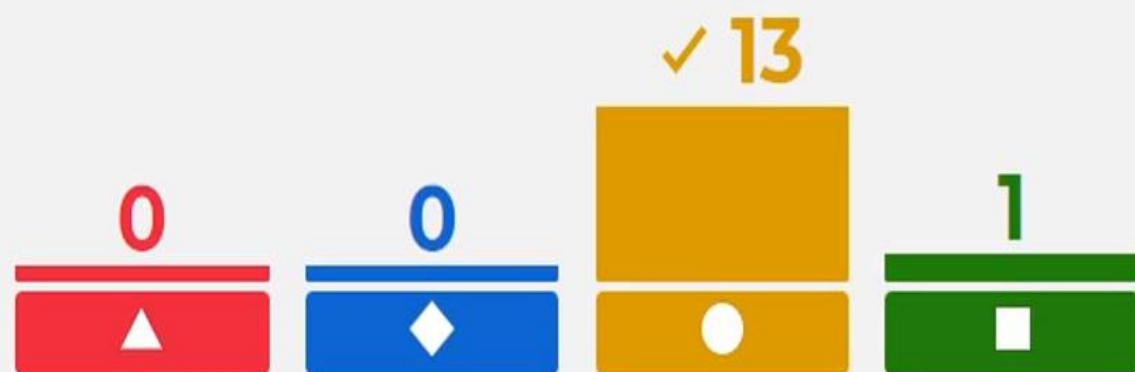● Posterior vaginal fornix

■ Supravaginal cervix

Culdocentesis is done by the passage of a needle through



Next



Show media

End game

▲ Anterior vaginal fornix ✕

◆ Lateral vaginal fornix ✕

● Posterior vaginal fornix ✓

■ Supravaginal cervix ✕

The round ligament of the ovary is attached toaspect of the uterotubal junction



Skip

18



0

Answers

▲ Posterior superior

◆ Anterior inferior

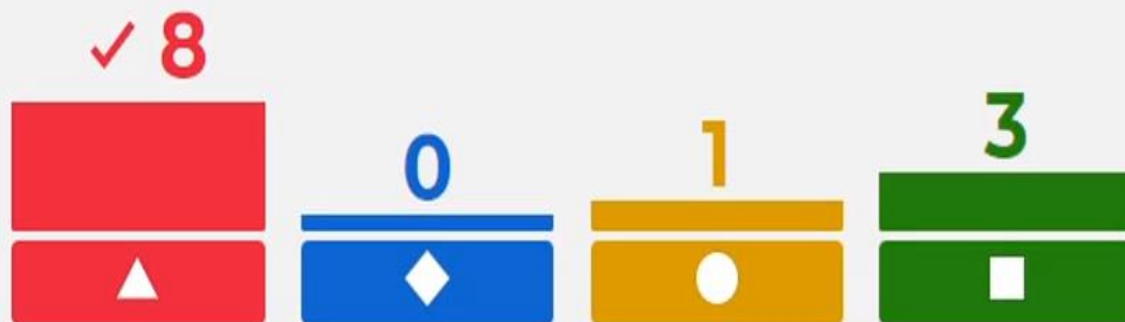● Posterior Inferior

■ Anterior superior

The round ligament of the ovary is attached toaspect of the uterotubal junction



Next



Show media

End game

▲ Posterior superior ✓

◆ Anterior inferior ✗

● Posterior Inferior ✗

■ Anterior superior ✗

Supravaginal part of the cervix is related anteriorly to



Skip

3



11
Answers

▲ Ureters

◆ Urinary bladder

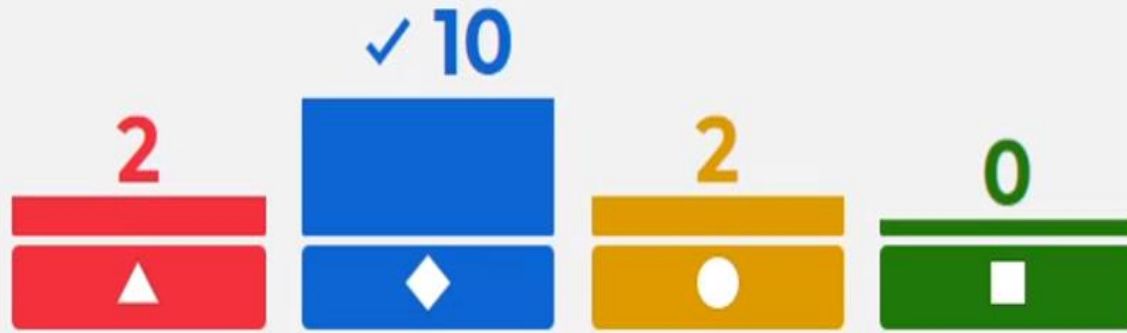● Urethra

■ Rectum

Supravaginal part of the cervix is related anteriorly to



Next



Show media

End game

▲ Ureters ✕

◆ Urinary bladder ✓

● Urethra ✕

■ Rectum ✕

Which of the following is covered with peritoneum



Skip

17



0
Answers

▲ Anterior vaginal fornix

◆ Lateral vaginal fornix

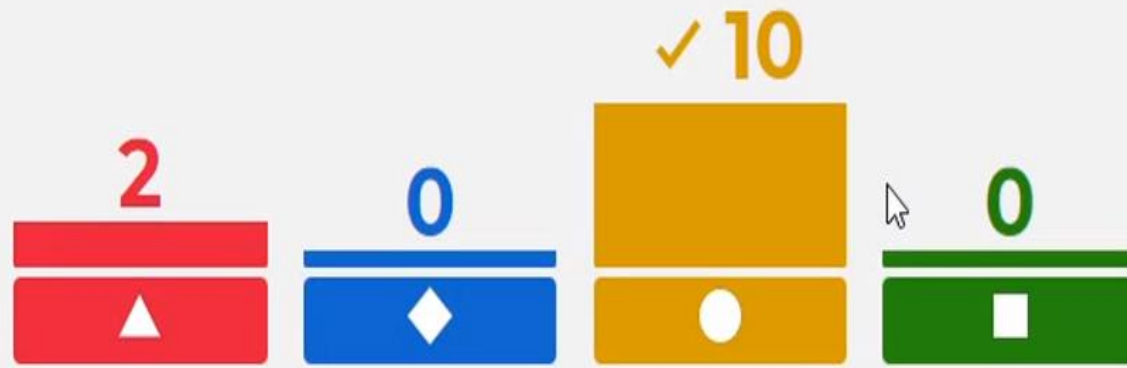
● Posterior vaginal fornix

■ Anterior vaginal wall

Which of the following is covered with peritoneum



Next



Show media

End game

▲ Anterior vaginal fornix ✘

◆ Lateral vaginal fornix ✘

● Posterior vaginal fornix ✔

■ Anterior vaginal wall ✘