Edited by: Dana Alnasra ❤️

UTERUS

The uterus is a hollow thick-walled, pear-shaped muscular organ situated in the lesser pelvis between the urinary bladder and rectum.

It is piriform in shape.

Communications :

Superolateral angles : the uterus receives the uterine tubes.

Inferiorly : it opens into the vagina at external os.

Normal Position of the Uterus : important!

Normally, the uterus is anteverted, anteflexed.

- Angle of **anteversion** : it is the angle between the uterus and the **vagina.**

It is about 90°

- Angle of **anteflexion** : it is the angle between the body of the uterus and the **cervix.**

It is about 170°

Retroflexed uterus

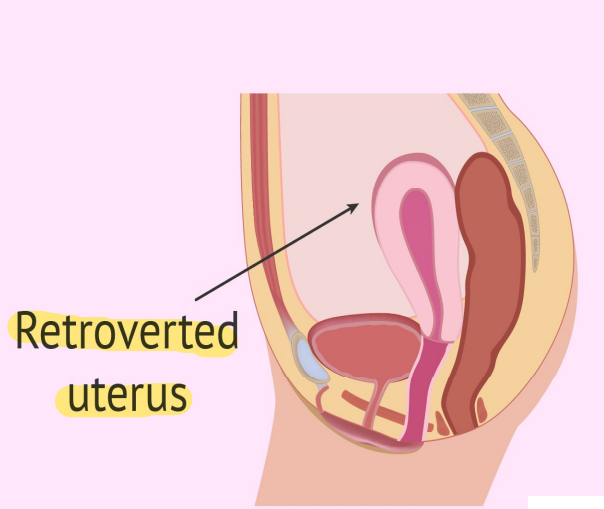

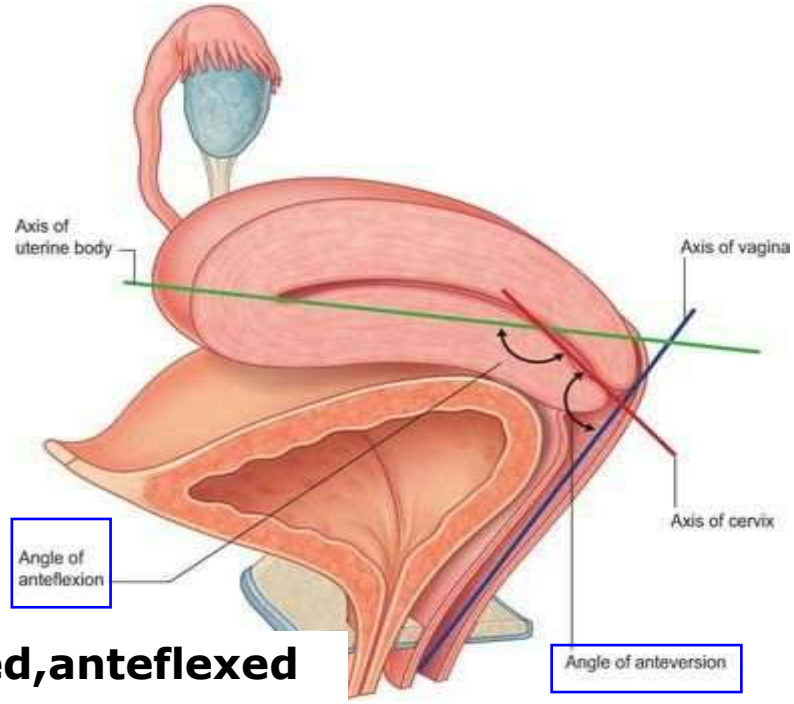

Anteverted,anteflexed

abnormal positions, usually result in infertility

Description of the Uterus :

The external surface of the uterus presents a transverse constriction called the ***isthmus*** which divides the uterus into a large upper part called the *body* and a smaller lower part called the cervix

A. Body of the Uterus :

- It forms upper 2/3 of uterus. It is two inches long,
- It has a fundus, two surfaces (anterior and posterior) and two lateral borders :

1- Fundus:

* It is that part of the body above the entry of the uterine tube's.
*It is completely covered by peritoneum.
* It is related to coils of small intestine and sigmoid colon

2- Anterior (vesical) Surface :

* Is covered by peritoneum down to the level of internal os
* Is related to the urinary bladder, with uterovesical pouch in between.

internal os: opening at the junction between the fundus and the cervix
external os: opening at the junction between the cervix and the vagina

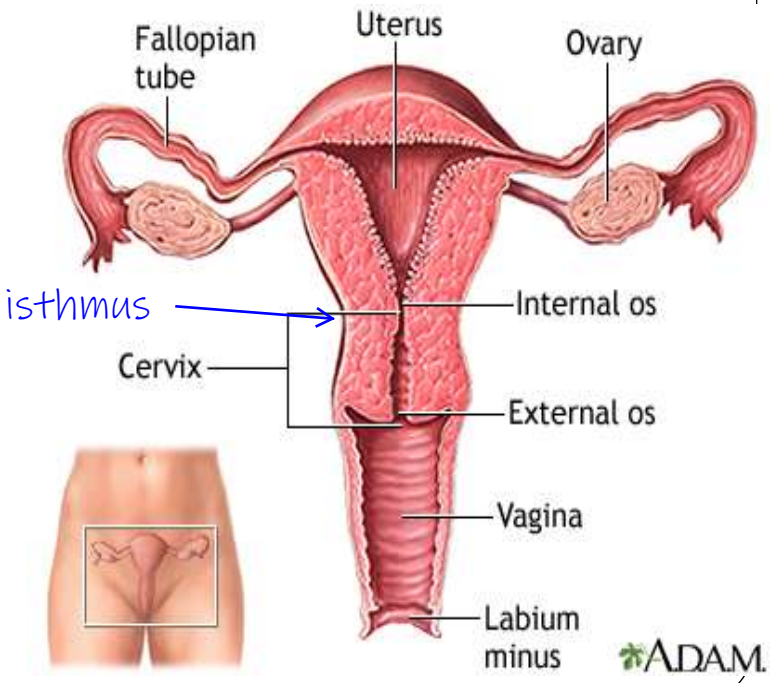

3- Posterior (intestinal) Surface :

* Is covered by the peritoneum which is continued down onto the cervix and posterior vaginal fornix.

* Is related to sigmoid colon and coils of small intestine. +Douglas pouch and part of the rectum

4- The lateral borders :

Each receives the uterine tube at its upper end.

- **Anteroinferior** to the uterotubal junction it is attached to **round ligament of uterus**
- **Posterosuperior** to the uterotubal junction, it is attached to the **round ligament of the ovary** .
- The uterine tube and the two ligaments are all running in the broad ligament which stretches from the lateral border to the lateral pelvic wall.

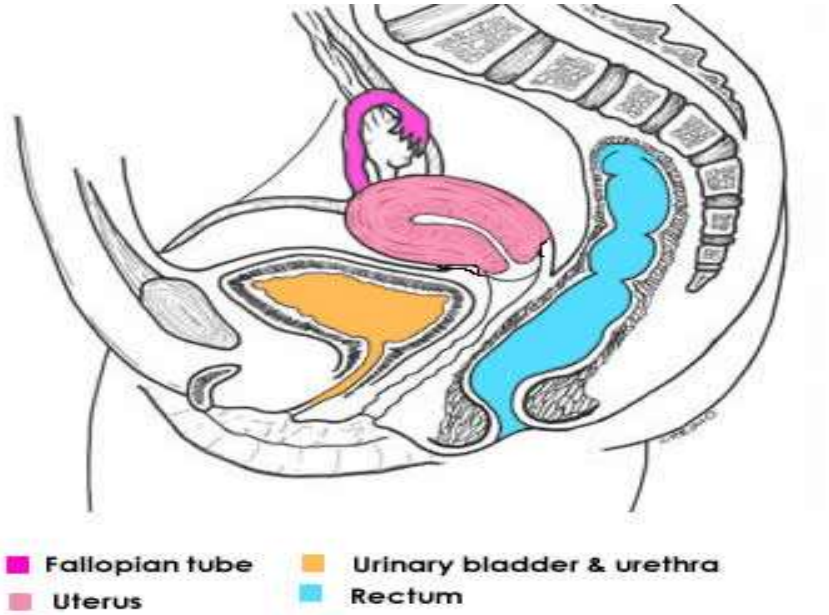

B- Cervix of the Uterus :

- It forms the lower 1/3 of the uterus. It is one inch long.
- Cervix protrudes into the upper part of the vagina, thus the cervix has supravaginal and vaginal parts :

1- The Supravaginal part of the cervix :

Anteriorly : it is *not* covered by peritoneum. It is related to urinary bladder with a cellular connective tissue in between called *parametrium.*

On each side : it is related to *parametrium,* in which the uterine artery *crosses* the ureter 2 cm from the supravaginal cervix. close to the lateral fornix

Posteriorly : is *covered* by peritoneum and related to the rectum with Douglas pouch in between.

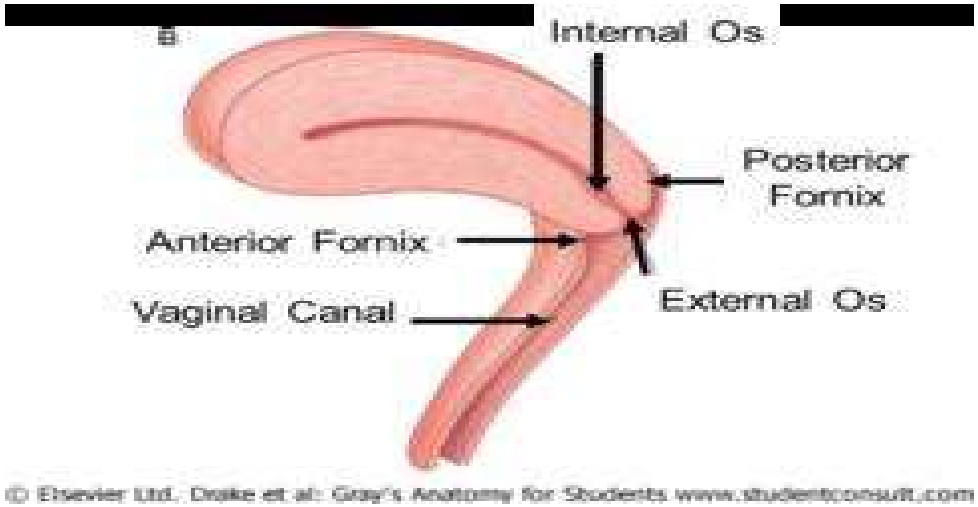

this crossing is called "water underneath the bridge" in which "water" is the ureter, and "bridge" is the artery

this is important to keep in mind because in a hysterectomy (removal of the uterus) accidental ligation of the ureter can happen

2- Vaginal part of the cervix :

It projects into upper part of the vagina, dividing that part of vagina into four vaginal fornices

The posterior vaginal fornix is the ***deepest*** and the *only* one **covered by peritoneum**.

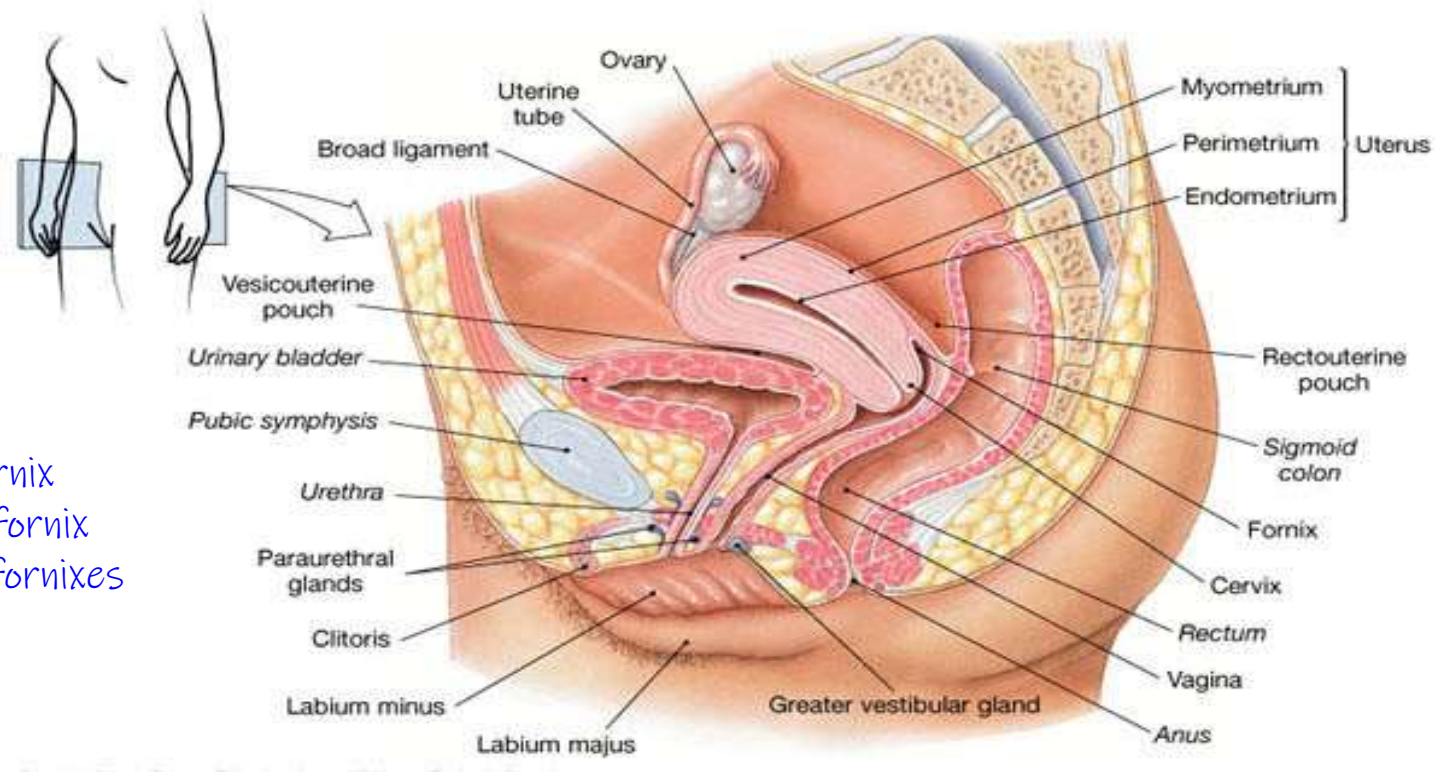

relations:
anterior: anterior fornix
posterior: posterior fornix
lateral: two lateral fornixes

Peritoneal Covering of the Uterus :

- The posterior surface and fundus of body of uterus are covered by peritoneum
- The peritoneium descends to cover its anterior surface down to the level of *internal os,* where it is reflected on to the bladder.
- The supravaginal cervix is covered by peritoneum *only posteriorly.*
- The front and sides of The supravaginal cervix are ***bare*** of peritoneum and related to cellular connective tissue, the parametrium.

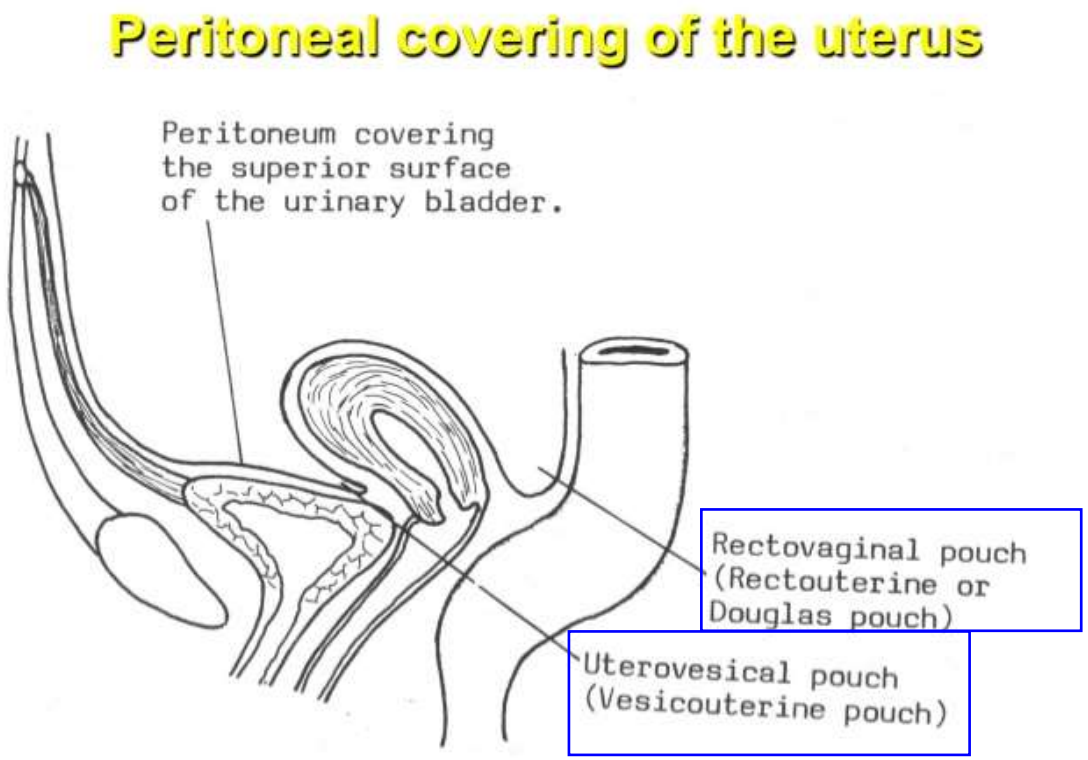

Culdocentesis

Drain a pelvic abscess or blood collection through the vagina by the passage of a needle through the posterior fornix.

Misguided nonsterile instruments, which pierce the wall of the posterior fornix in a failed attempt at an illegal abortion.

This leads to Pelvic peritonitis, often with fatal consequences.

accidental piercing of the posterior fornix, when the instrument should have been insterted in the uterus. this pierces the peritoneum and leads to peritonitis

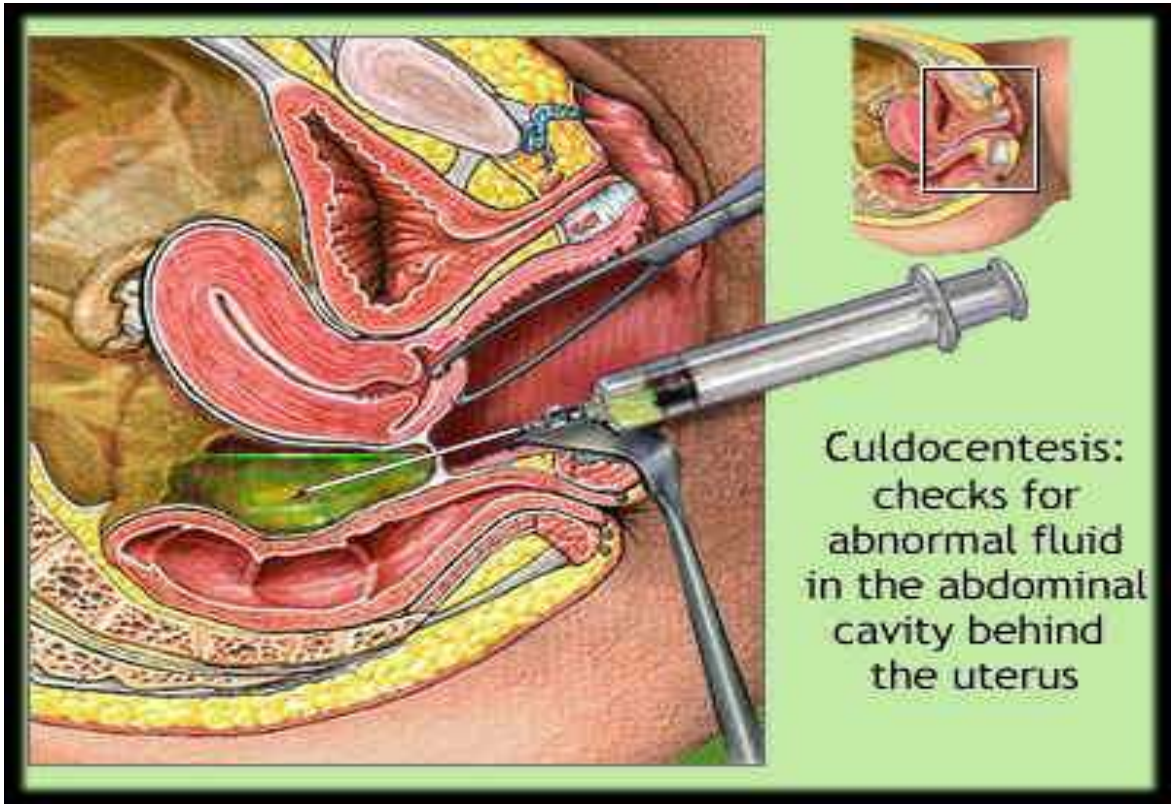

Uterine Cavity :

A. Cavity of the Body :

B. in coronal section is triangular, with its base between the openings of the uterine tubes and its apex is the internal os leading to the cervical canal .

B. The cervical canal:

- Is fusiform, broad at its mid-level.
- It communicates with the cavity of the body at the ***internal* os** and with the vagina by the ***external os***.

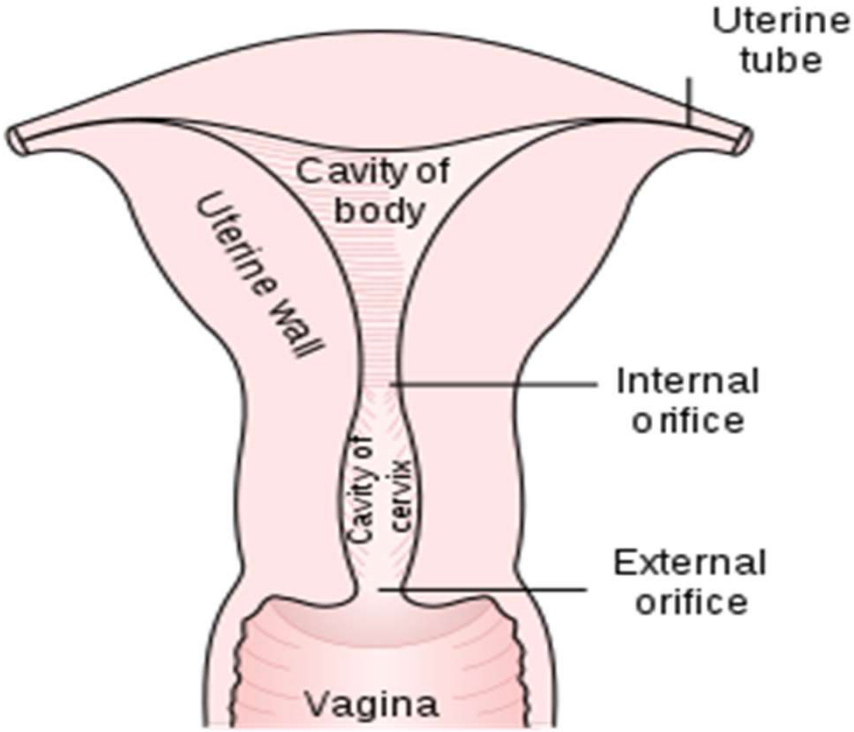

Anatomical significance of the internal os :

- It corresponds to the isthmus of the uterus.
- It is the site of junction between uterine cavity and cervical canal.
- It is the level of the angle of anteflexion.
- It is the level at which the peritoneum is reflected anteriorly on to the bladder

Gynaecological significance of the external os :

- In nulliparous women, it is small and *circular*.
- In multiparous women, it is a *transverse* slit .

nulliparous women

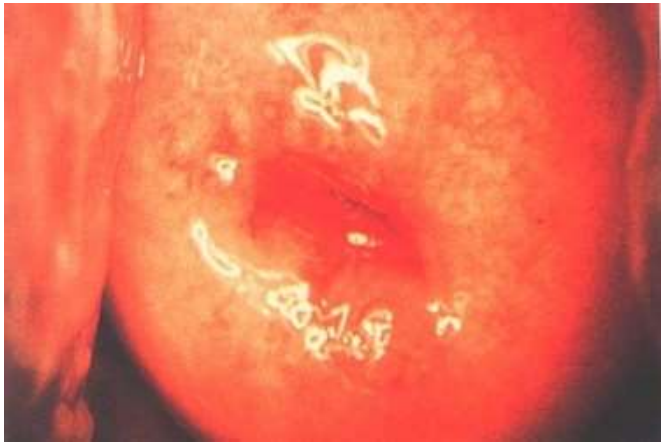

multiparous women

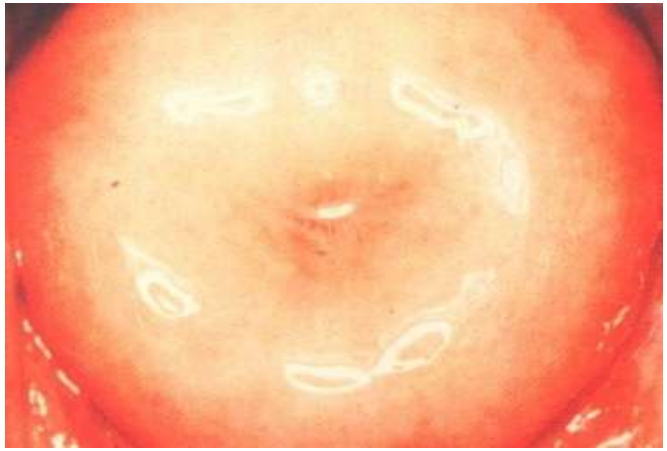

menopause narrow os

Arterial Blood Supply: by uterine artery

- It runs medially on the upper surface of the pelvic diaphragm to reach the root of broad ligament close to the lateral vaginal fornix.
- It enters the broad ligament and runs a tortuous course along the lateral margin of the uterus. It ends by anastomosing with the ovarian A.
- It gives branches to pelvic part of ureter, vagina (azygos arteries), cervix and of uterus, medial part of the uterine tube **.**

The ureters pass at lateral fornixes of the vagina, they cross the uterine arteries. ***(like water underneath the bridge)***

So The ureters are at great risk during surgical procedures on the uterus and ovaries.

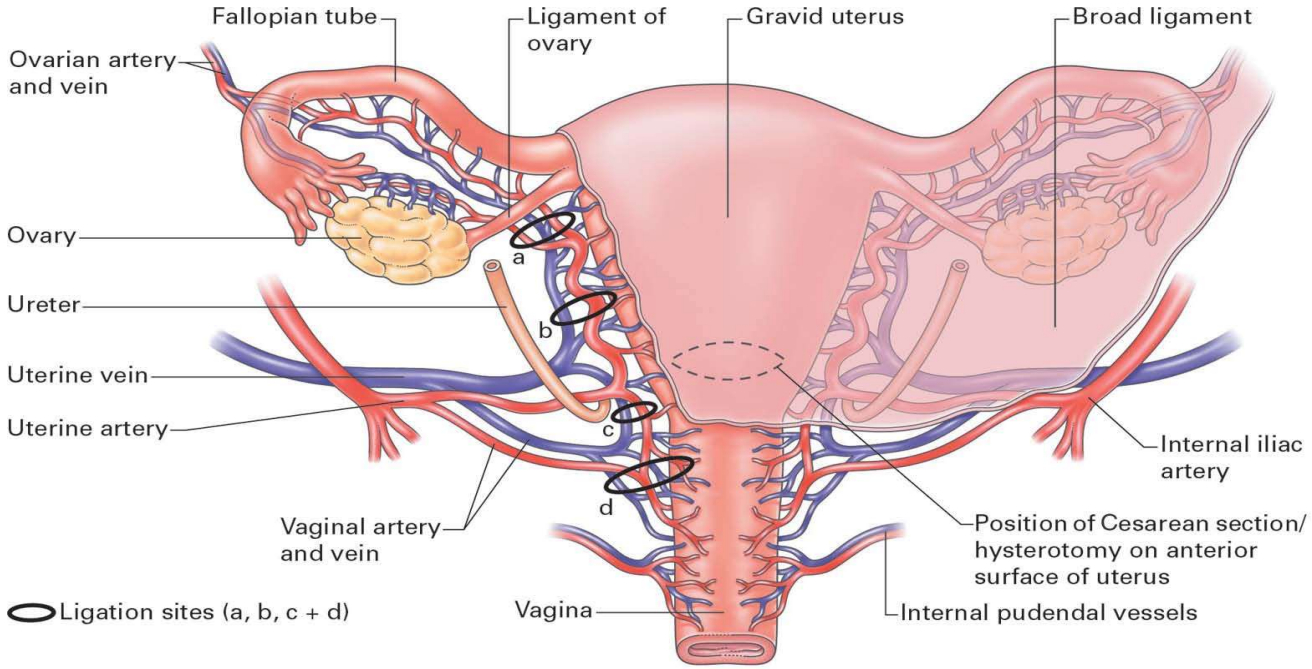

Venous Drainage :

- Begins by the uterine venous plexuses.
- Each extends along the lateral side of the uterus within the broad ligament.
- The lower part of the plexus is drained by uterine veins which open into the internal iliac vein.
- The plexus communicates with the ovarian and vaginal venous plexuses.

in the lower limbs

→ **Varicose Vein and hemorrhoids** is common during pregnancy due to compression of gravid uterus on inferior vena cava and inferior mesenteric vein (venous congestion)

Nerve Supply : by the uterovaginal nerve plexus derived from the inferior hypogastric plexus.

Lymphatic Drainage :

Area	Lymph group
Fundus	lateral aortic lymph nodes
Uterotubal junction along the round ligament of the uterus	superficial inguinal lymph nodes. since the ligament extends to labia majora (skin)
Body, lymphatics pass through the broad ligament	external iliac lymph nodes
Cervix	external, internal and sacral lymph nodes iliac

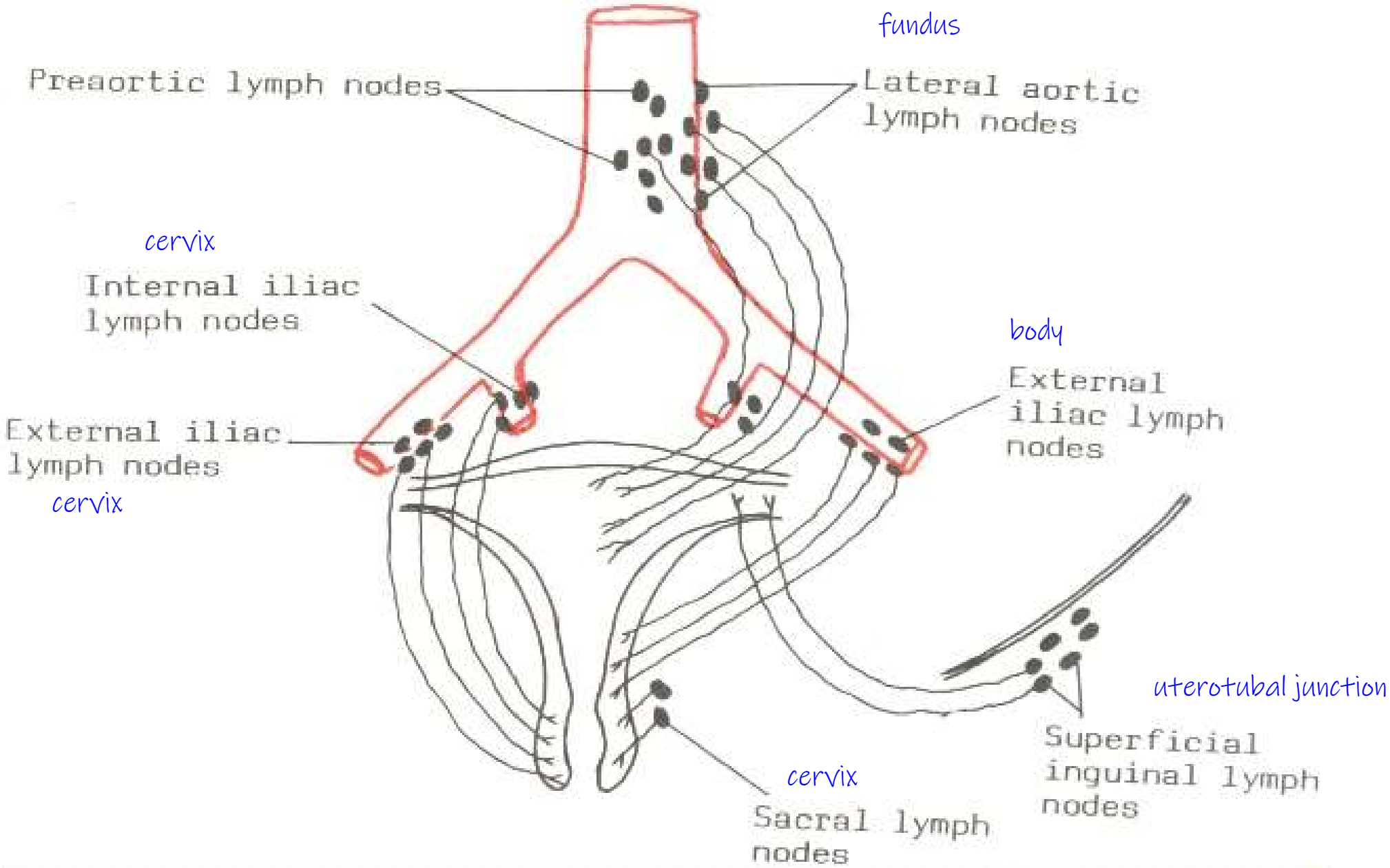

Lymphatic drainage of the uterus

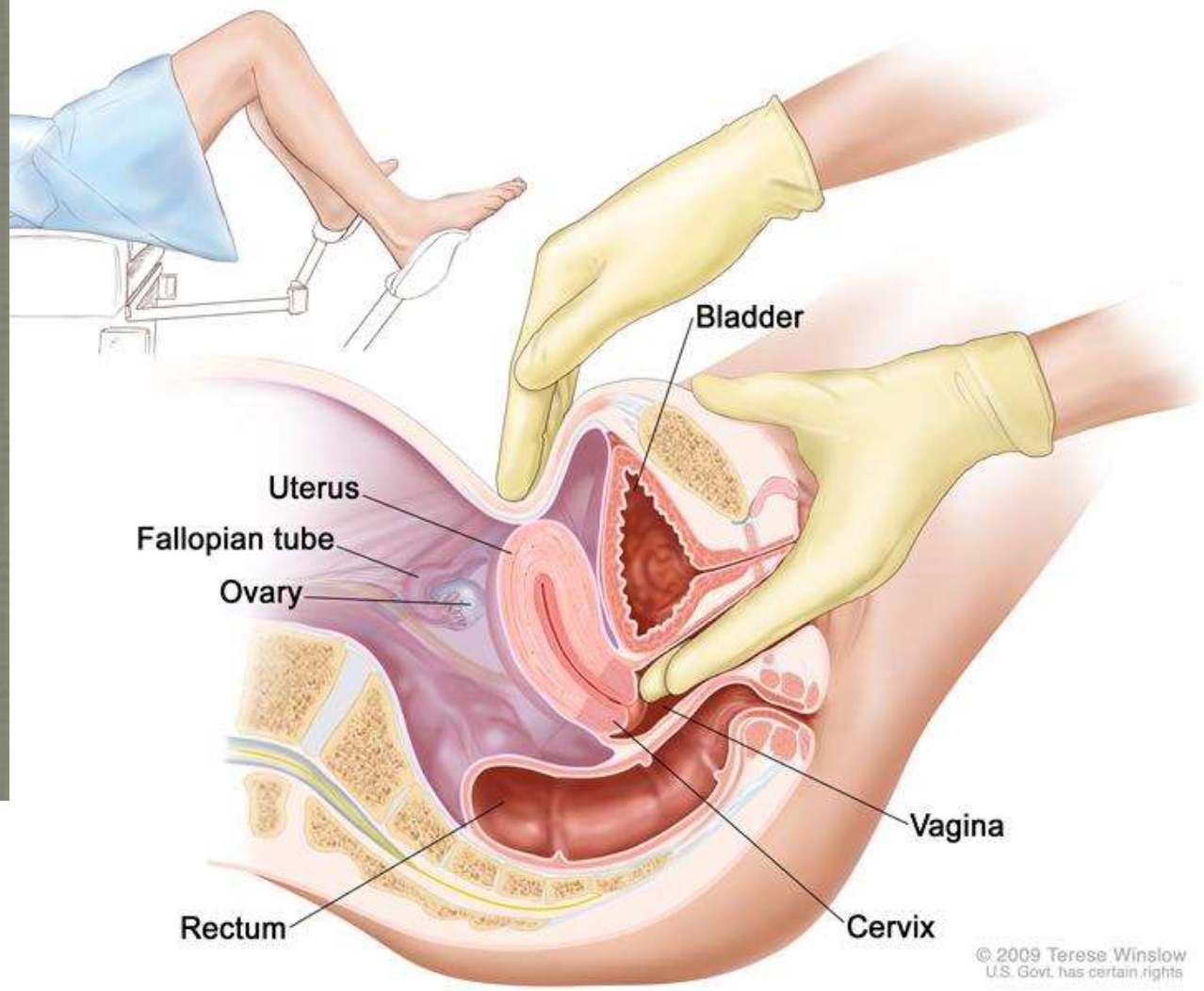

Fundus examination

a way to estimate weeks/ months of pregnancy for example here, pregnancy is estimated to be 8-9 months because the fundus is above the level of the umbilicus

Bimanual pelvic examination of uterus

used to check a woman's internal pelvic organs. The health care provider inserts two fingers into the vagina and then places pressure with the other hand to the lower part of the belly.

Ligaments of the uterus

Ligaments attached to the body of uterus

1. Round ligament of uterus
2. Broad ligament.

Ligaments attached to cervix of uterus

1. Pubocervical ligaments
2. Transverse cervical ligaments
3. Uterosacral ligaments

1- Round ligament of the uterus :

It extends from anteroinferior aspect of the uterotubal junction to the subcutaneous tissue of the labia majora.

Course :

- Its proximal part runs within the broad ligament.
- Its distal part crosses the structures in the side wall of the pelvis and hooks around the beginning of inferior epigastric A.
- Then it enters the deep inguinal ring and traverses the inguinal canal to end in the labia majora.

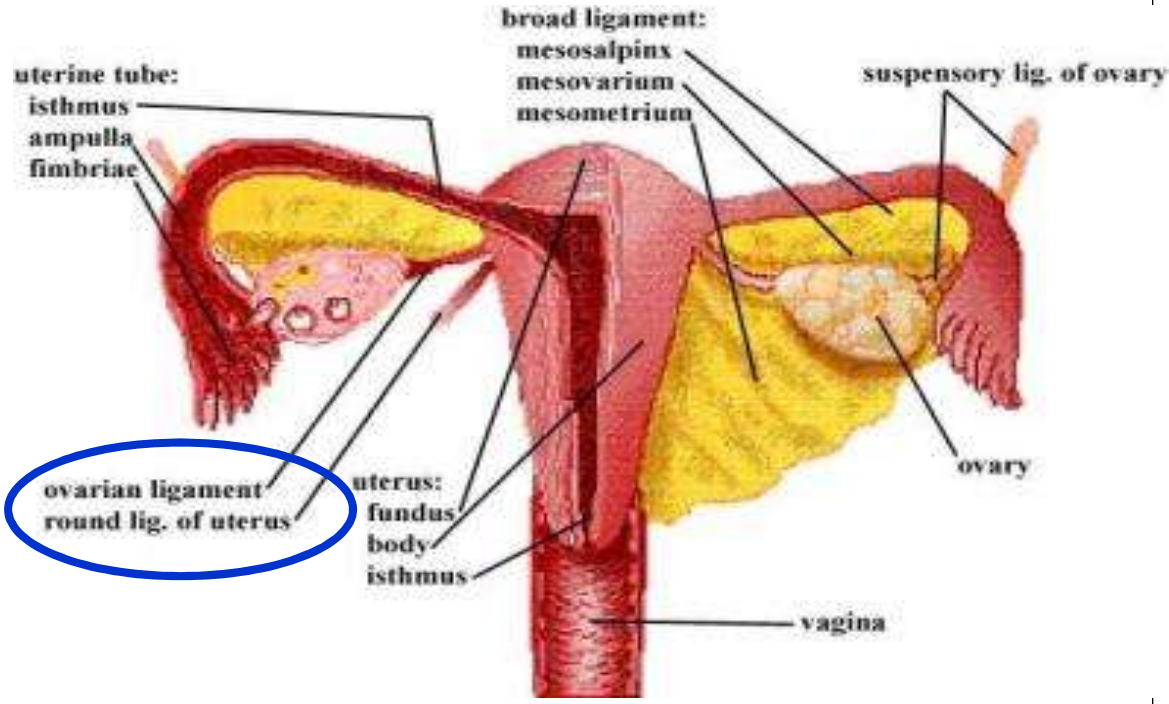

Structures accompany the ligament in inguinal canal :

- Artery of the round ligament (corresponds to the cremasteric A. in the male).
- Genital branch of genitofemoral N. ; supplies the labia majora.
- Lymphatics from the uterotubal junction to the superficial inguinal lymph nodes.

Function : i.e. pulls the uterus anteriorly

it keeps the angle of anteversion against the backward pull of the uterosacral ligaments.

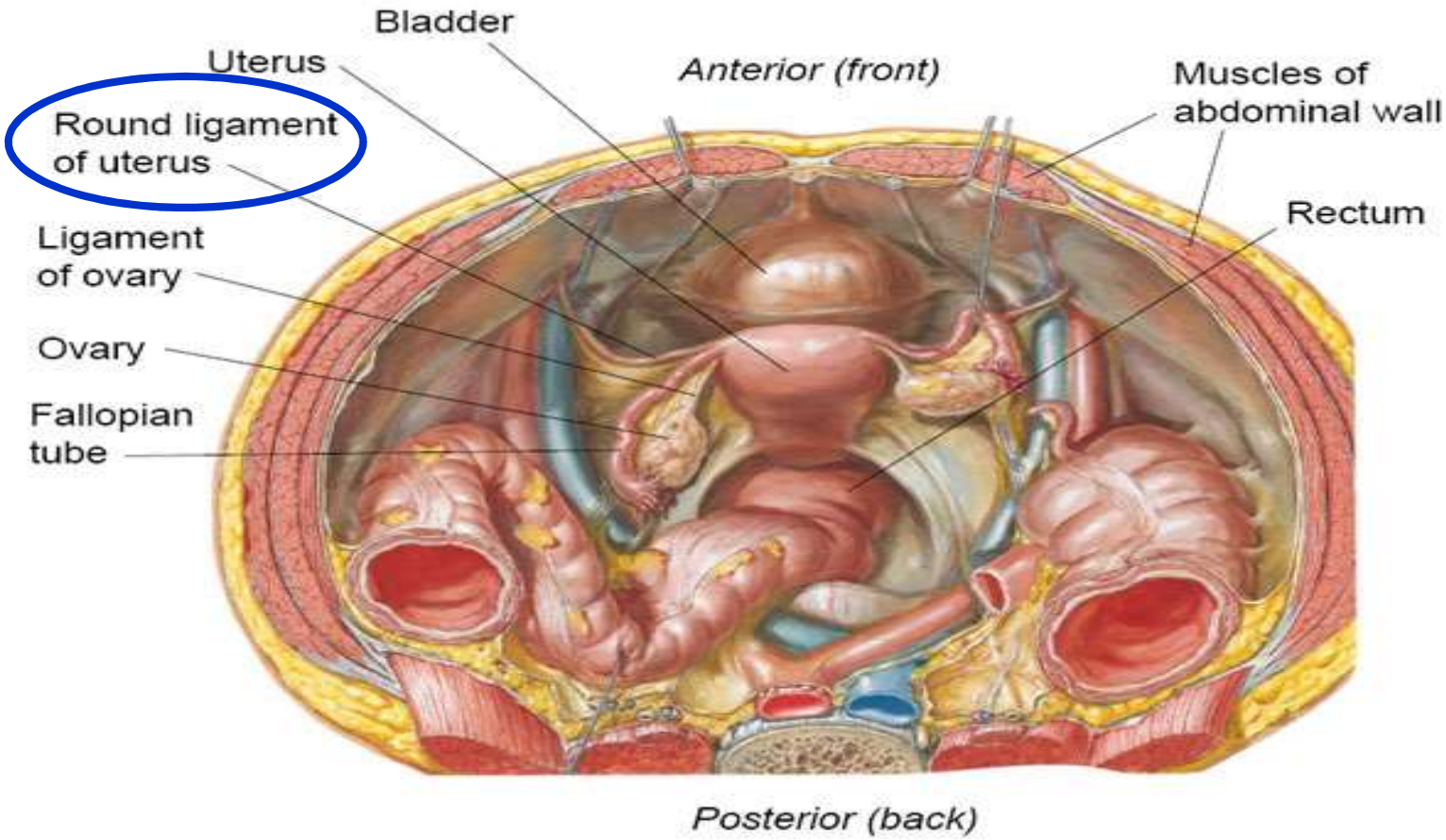

Round Ligament Pain

Symptoms : a sharp, sudden spasm in the belly
Increase by coughing , laughing, rolling over in bed, standing up too quickly
Cause : Stretch of round ligament during pregnancy

treatment is only with painkillers

2. The broad ligament :

it's important that you fully understand the description of this ligament

It is the double-layered fold of peritoneum which extends from the side of the uterus to the lateral wall and floor of the pelvis.

Description :it has 4 borders and 2 layers

1- Upper free border :

- Contains the uterine tube in its medial 4/5.
- The lateral 1/5 represents the suspensory ligament of the ovary.

2- Lower attached border :

- Rests on the pelvic floor (levator ani).
- It is related to the ureter crossed by the uterine artery about 2 cm from the supravaginal cervix.

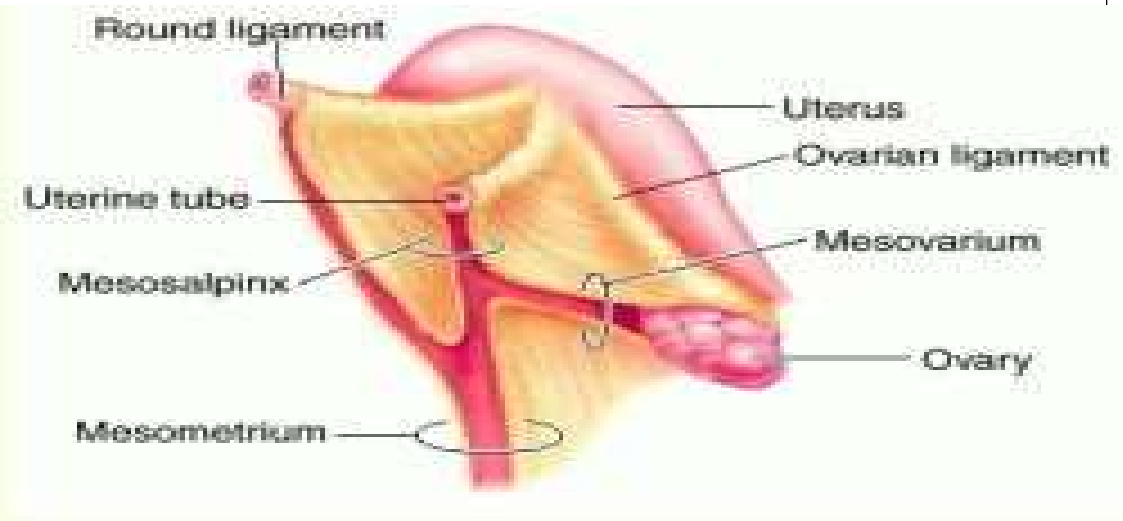

3-Medial border :

- Attached to the side of the uterus.
- The 2 layers of the broad ligament become continuous, with peritoneum of the body of the uterus .

4- Lateral border :

- Attached to the side wall of the pelvis.
- The 2 layers of the ligament become continuous with the parietal peritoneum of the lateral pelvic wall.

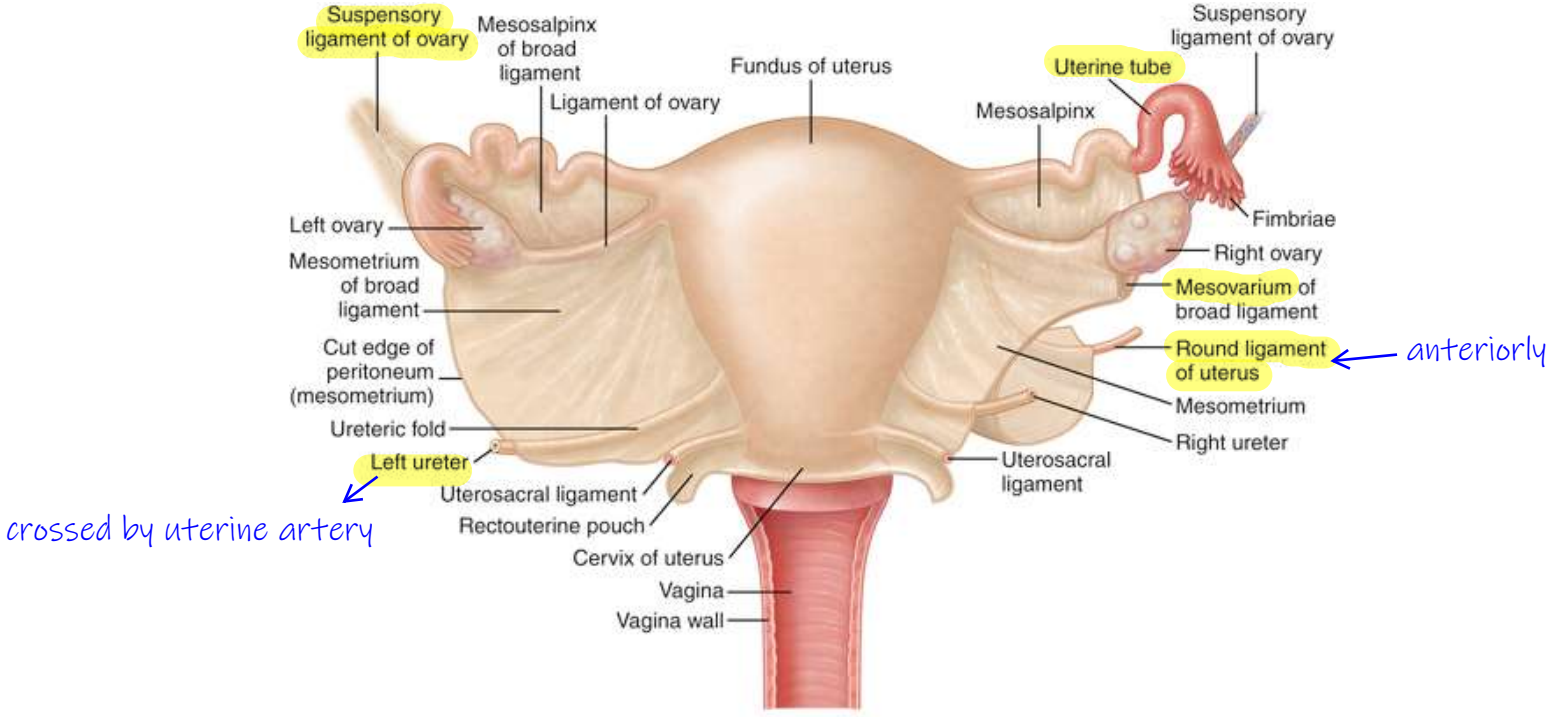

Uterus and broad ligament (posterior view)

5- Anterior layer :
Is bulged by the round ligament of the uterus.

6. Posterior layer :
- Is connected to the ovary by the mesovarium.
- It is pierced by lateral end of the uterine tube

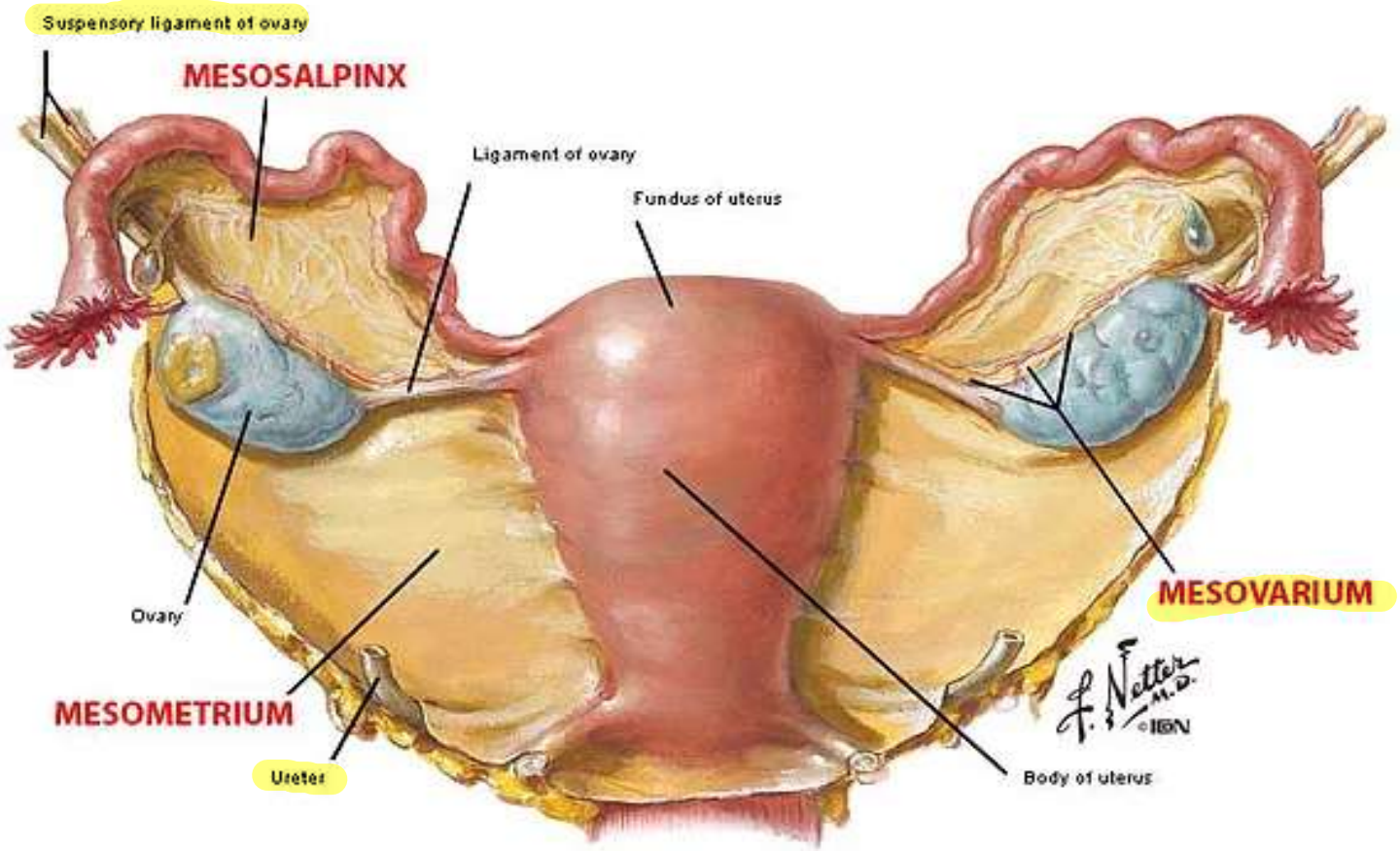

Parts of the broad ligament : is divided into four parts :

1. **Mesovarium :** between the broad ligament and the ovary.
2. **Suspensory ligament of the ovary :** between ovary and side wall of the pelvis, contains ovarian vessels and lymphatics.
3. **Mesosalpinx :** between the uterine tube and the ovarian ligament.
4. **Mesometrium :** between the ovarian ligament and uterine body.

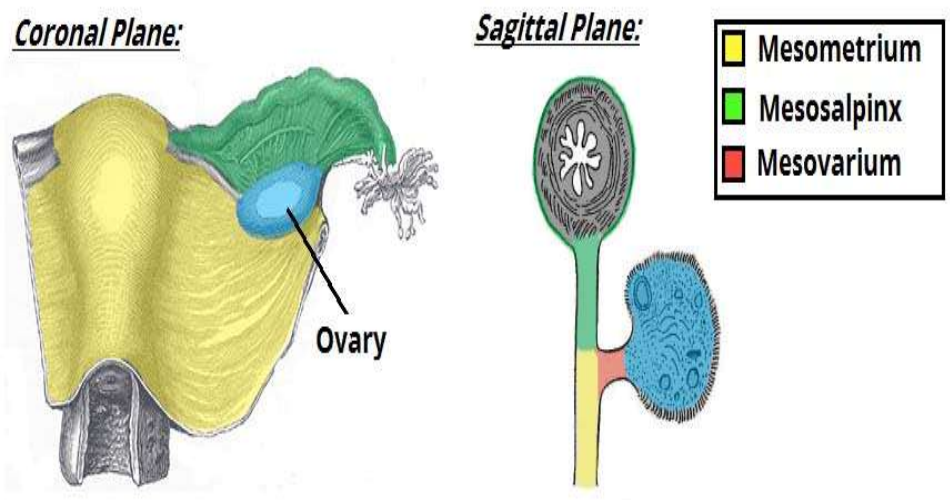

Figure 27.11a The Ovaries, Uterine Tubes, and Uterus

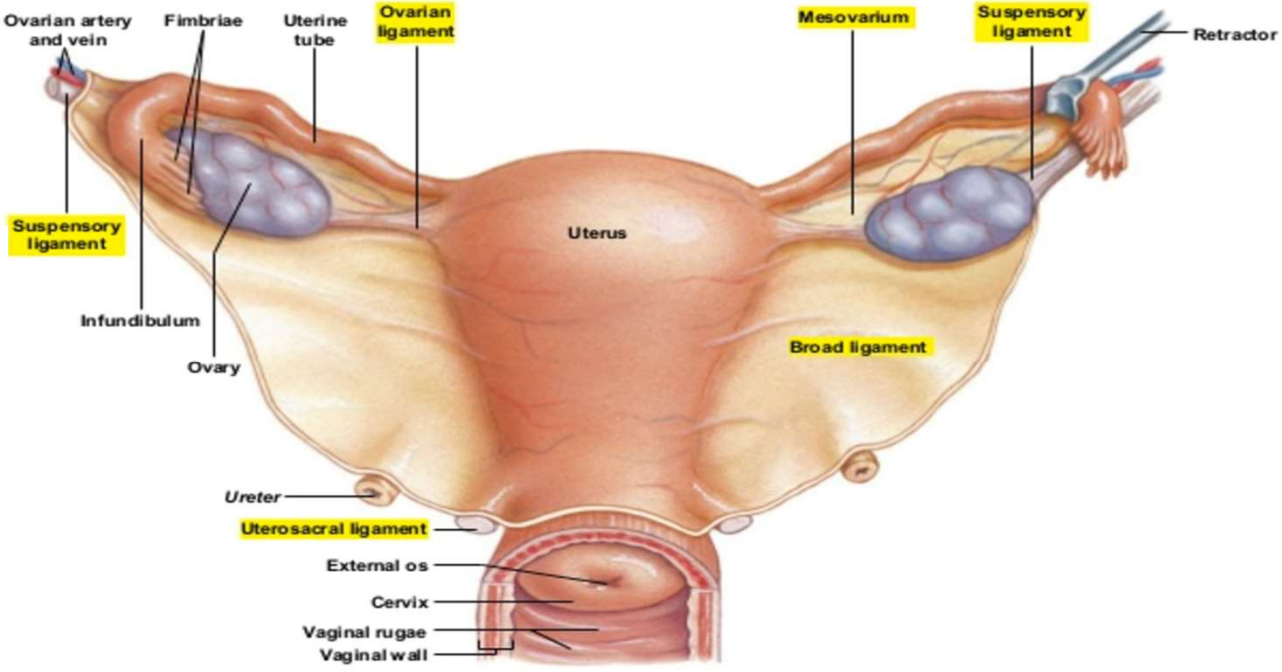

Posterior view of the ovaries, uterine tubes, and uterus along with their supporting ligaments

Contents of the broad ligament:

1. **Uterine tube** in the free border.
2. **Two ligaments :**
   Round ligament of the uterus.
   Round ligament of the ovary.
3. **Two vessels :**
   Uterine vessels .
   Ovarian vessels.
4. **Two nerve plexuses :**
   Uterovaginal plexus around the uterine A.
   Ovarian plexus around the ovarian A.
5. **Two embryological remnants :**
   Epoophoron and the duct of epoophoron (Gartner's duct).
   Paroophron.

They are embryonic remnants of mesonephric tubules and mesonephric duct.

6. **Two other structures**
   Lymphatic vessels.
   Parametrium (cellular connective tissue) continuous with that around the cervix of the uterus.

Ligaments attached to cervix of uterus

1. Pubocervical ligaments: extend anteriorly from the cervix of uterus to the pubis.

2. Transverse cervical ligaments (Mackenrodt's ligaments): extend laterally from the cervix and upper part of vagina to the side walls of the pelvis.

They are the main ligaments for uterine support.

3. Uterosacral ligaments : extend backwards from the posterolateral aspect of the cervix and the lateral vaginal fornixes to the front of S2, S3 vertebrae.

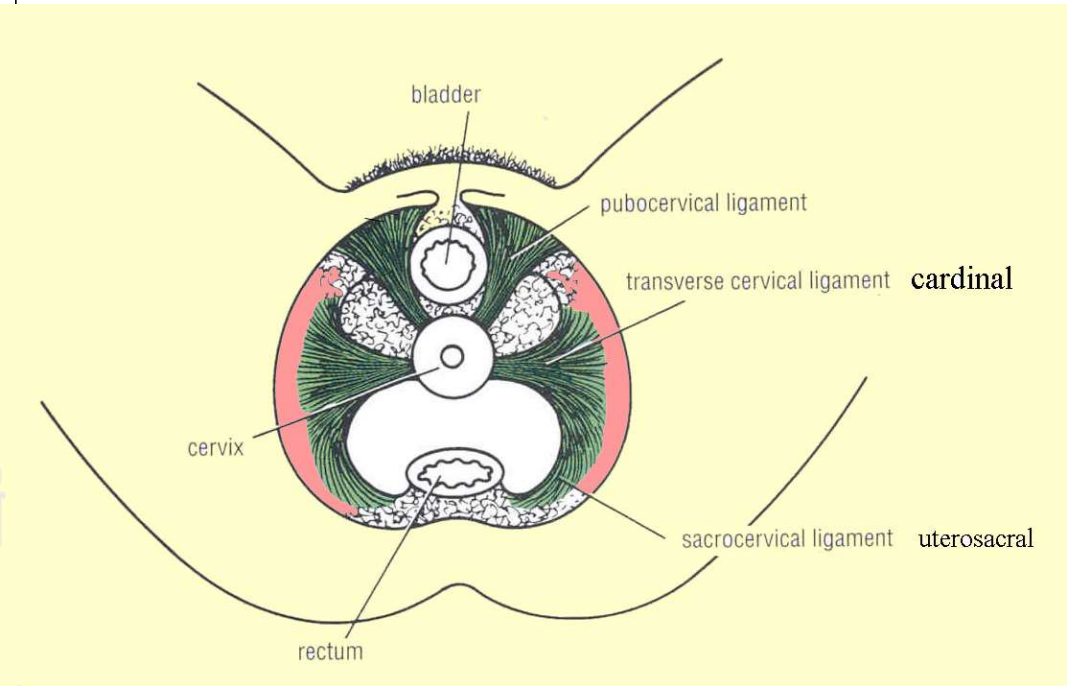

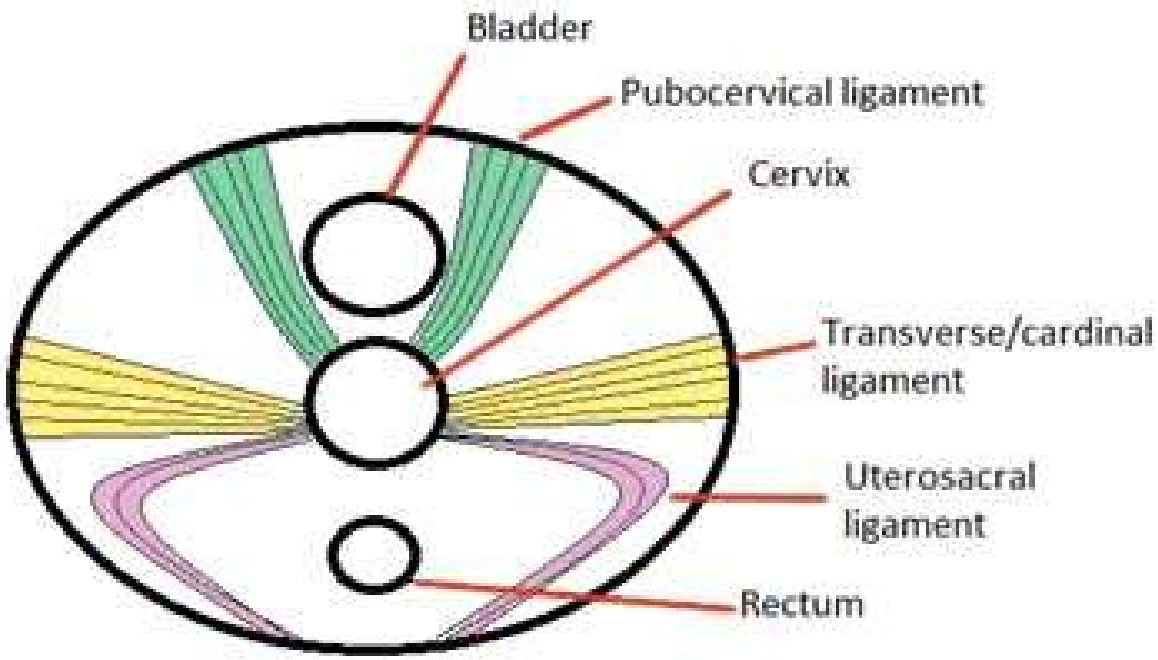

Supporting Factors of Uterus

main support

Ligaments

1-Pubocervical ligaments

2-Transverse cervical ligaments

3-Uterosacral ligaments

coccygeus + shpincter vaginae of levator ani

Muscles

1-Muscles of the pelvic diaphragm

2-Muscles of urogenital diaphragm

3-Perineal body

between anal canal and vagina (insertion of sphincter vaginae), rupture of perineal body results in prolapse of the uterus

Mechanical Factors

anteversion angle prevents prolapse (sustained by round ligament of the uterus)

weakness in any of the supporting factors may lead to uterine prolapse

Supporting Factors of Uterus :

Prolapse of the uterus into the vagina (due to increased intra-abdominal pressure) is prevented by the following factors

A. Ligaments :

1. Pubocervical ligaments
2. Transverse cervical ligaments (Mackenrodt's ligaments)
3. Uterosacral ligaments

B. Muscles :

1. Muscles of the pelvic diaphragm (levator ani and coccygeus) especially sphincter vaginae part of levator ani.
2. Muscles of urogenital diaphragm in the deep perineal pouch.
3. Perineal body : it is the central tendon of perineum which keeps integrity of pelvic floor.

Rupture of the perineal body leads to prolapse of uterus.

C. Mechanical Factors :

- The angle of anteversion prevents prolapse of uterus into the vagina.
- The angle is maintained by the forward pull by round ligaments on the uterine fundus and the backward pull by the Uterosacral ligaments on the cervix.

uterine prolapse

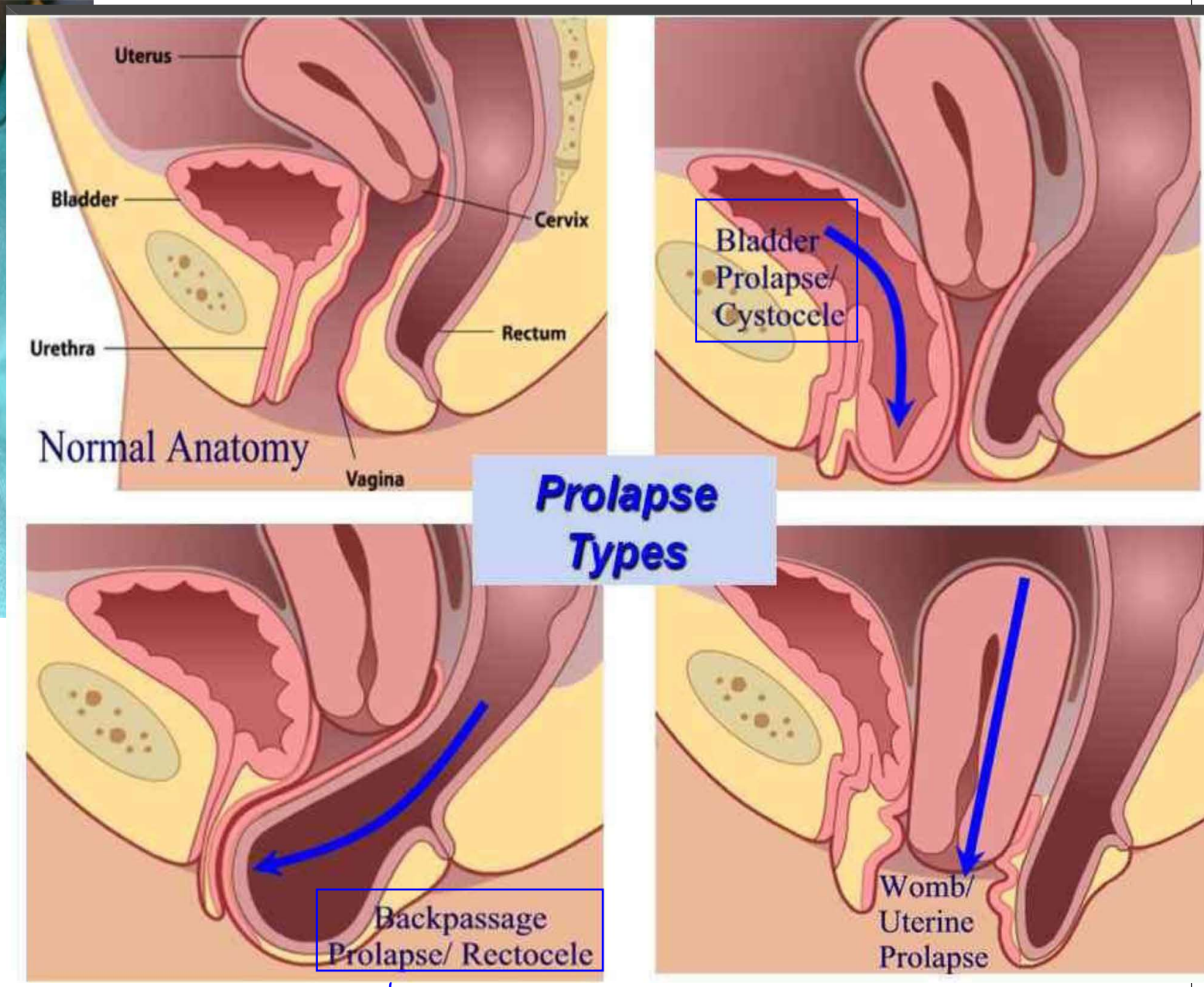

rectum

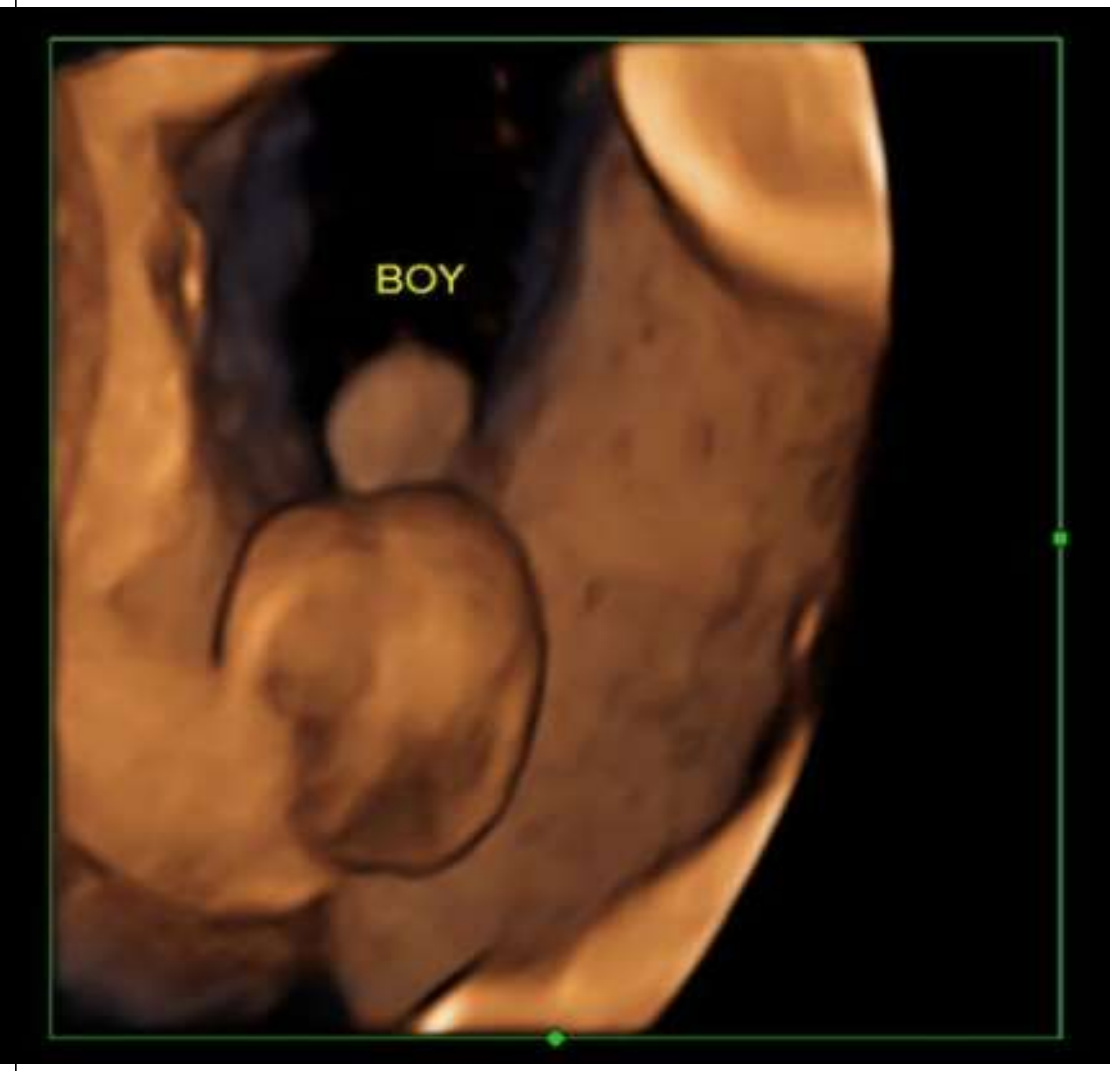

3D and 4D ultrasound

The most significant difference between 3D and 4D ultrasound is that 4D ultrasound is essentially 3D ultrasound in live motion. i.e. it can show the baby's movement

pregnant female

2D ultrasound

normal non-pregnant female

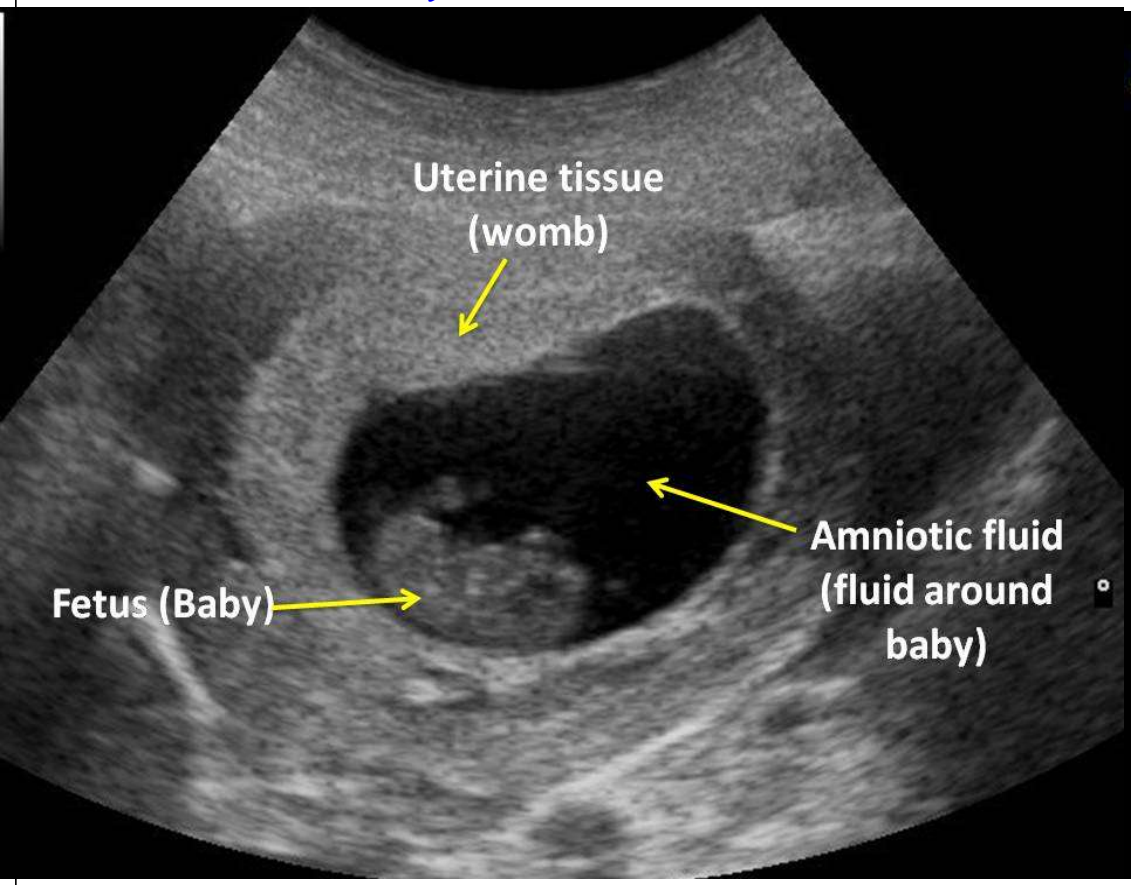

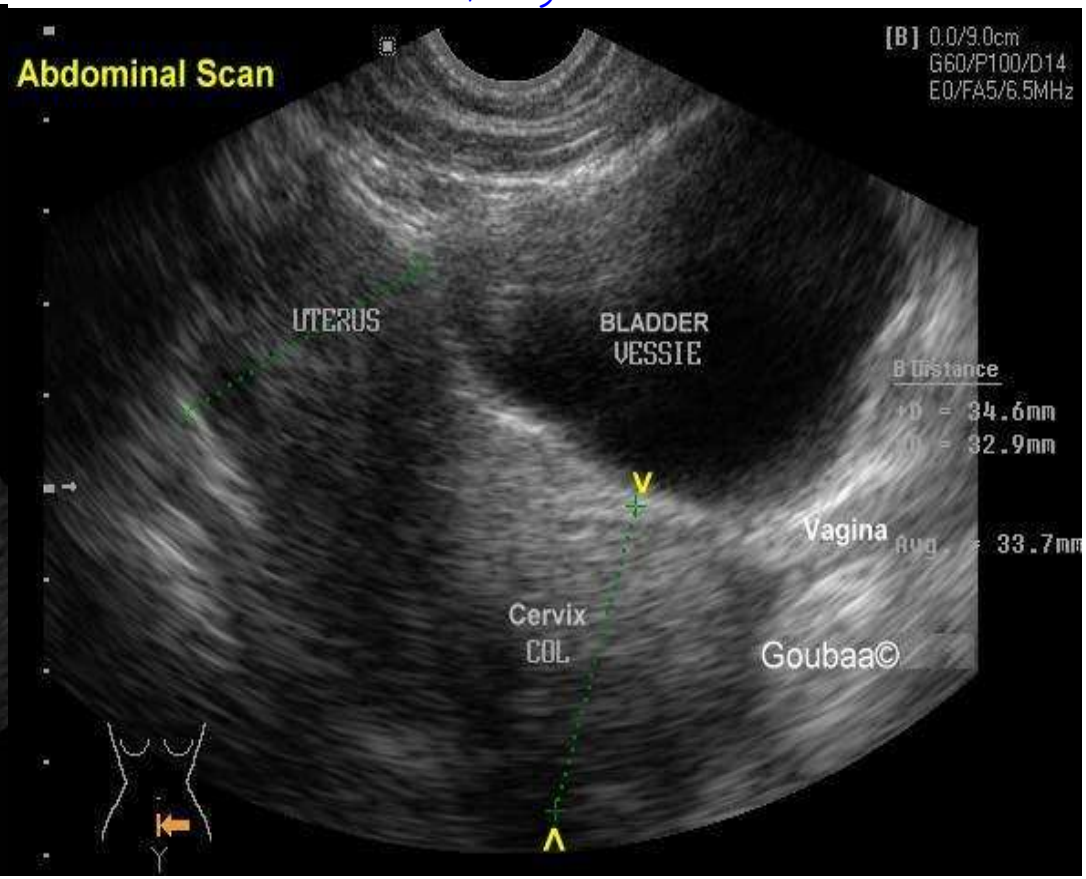

THANK YOU!