Midterm questions

1)A 17-year-old boy suffers a traumatic groin injury during a soccer match. The urologist notices tenderness and swelling of the boy's left testicle that may be produced by thrombosis in which of the following veins?
(A) Left internal pudendal vein
(B) Left renal vein
(C) Inferior vena cava
(D) Left inferior epigastric vein
(E) Left external pudendal vein

2) On a busy Saturday night in Chicago, a 16-year-old boy presents to the emergency department with a stab wound from a knife that entered the pelvis above the piriformis muscle. Which of the following structures is most likely to be damaged?
(A) Sciatic nerve
(B) Internal pudendal artery
(C) Superior gluteal nerve
(D) Inferior gluteal artery
(E) Posterior femoral cutaneous nerve

3) A 29-year-old carpenter sustains severe injuries of the pelvic splanchnic nerve by a deep puncture wound, which has become contaminated. The injured parasympathetic preganglionic fibers in the splanchnic nerve are most likely to synapse in which of the following ganglia?
(A) Ganglia in or near the viscera or pelvic plexus
(B) Sympathetic chain ganglia
(C) Collateral ganglia
(D) Dorsal root ganglia
(E) Ganglion impar

4) A 29-year-old woman is admitted to a hospital because the birth of her child is several days overdue. Tearing of the pelvic diaphragm during childbirth leads to paralysis of which of the following muscles?
(A) Piriformis
(B) Sphincter urethrae
(C) Obturator internus
(D) Levator ani
(E) Sphincter ani externus

5) A 58-year-old man is diagnosed as having a slowly growing tumor in the deep perineal space. Which of the following structures would most likely be injured?
(A) Bulbourethral glands
(B) Crus of penis
(C) Bulb of vestibule
(D) Spongy urethra
(E) Great vestibular gland

6) An elderly man with a benign enlargement of his prostate experiences difficulty in urination, urinary frequency, and urgency. Which of the following lobes of the prostate gland is commonly involved in benign hypertrophy that obstructs the prostatic urethra?
(A) Anterior lobe
(B) Median lobe
(C) Right lateral lobe
(D) Left lateral lobe
(E) Posterior lobe

7)A 59-year-old man is diagnosed with prostate cancer following a digital rectal examination. For the resection of prostate cancer, it is important to know that the prostatic ducts open into or on which of the following structures:
(A) Membranous part of the urethra
(B) Seminal colliculus
(C) Spongy urethra
(D) Prostatic sinus
(E) Prostatic utricle

8)A 37-year-old man is suffering from carcinoma of the skin of the penis. Cancer cells are likely to metastasize directly to which of the following lymph nodes?
(A) External iliac nodes
(B) Internal iliac nodes
(C) Superficial inguinal nodes
(D) Aortic (lumbar) nodes
(E) Deep inguinal nodes

9)A 42-year-old woman who has had six children develops a weakness of the urogenital diaphragm. Paralysis of which of the following muscles would cause such a symptom?
(A) Sphincter urethrae
(B) Coccygeus
(C) Superficial transversus perinei
(D) Levator ani
(E) Obturator internus

10)A 39-year-old man is unable to expel the last drops of urine from the urethra at the end of micturition because of paralysis of the external urethral sphincter and bulbospongiosus muscles. This condition may occur as a result of injury to which of the following nervous structures?
(A) Pelvic plexus
(B) Prostatic plexus
(C) Pudendal nerve
(D) Pelvic splanchnic nerve
(E) Sacral splanchnic nerve

11)A 62-year-old man is incapable of penile erection after rectal surgery with prostatectomy. The patient most likely has a lesion of which of the following nerves?

(A) Dorsal nerve of the penis
(B) Perineal nerve
(C) Hypogastric nerve
(D) Sacral splanchnic nerve
(E) Pelvic splanchnic nerve

12)A first-year resident in the urology department reviews pelvic anatomy before seeing patients. Which of the following statements is correct?
(A) The dorsal artery of the penis supplies the glans penis.
(B) The seminal vesicles store spermatozoa.
(C) The duct of the bulbourethral gland opens into the membranous urethra.
(D) The duct of the greater vestibular gland opens into the vagina
(E) The anterior lobe of the prostate gland is prone to carcinomatous transformation.

13)A 16-year-old boy presents to the emergency department with rupture of the penile urethra. Extravasated urine from this injury can spread into which of the following structures?
(A) Scrotum
(B) Ischiorectal fossa
(C) Pelvic cavity
(D) Testis
(E) Thigh

14)A 72-year-old man comes to his physician for an annual checkup. Which of the following structures is most readily palpated during rectal examination?
(A) Prostate gland
(B) Epididymis
(C) Ejaculatory duct
(D) Ureter
(E) Testis

15)While performing a pelvic exenteration, the surgical oncologist notices a fractured or ruptured boundary of the pelvic inlet. Which of the following structures is most likely damaged?
(A) Promontory of the sacrum
(B) Anterior–inferior iliac spine
(C) Inguinal ligament
(D) Iliac crest
(E) Arcuate pubic ligament

16)A radiologist interprets a lymphangiogram for a 29-year-old patient with metastatic carcinoma. Upper lumbar nodes most likely receive lymph from which of the following structures?
(A) Lower part of the anal canal
(B) Labium majus
(C) Clitoris

(D) Testis
(E) Scrotum

17)A 21-year-old man is involved in a highspeed motor vehicle accident. As a result, he has extensive damage to his sphincter urethra. Which of the following best describes the injured sphincter urethra?
(A) Smooth muscle
(B) Innervated by the perineal nerve
(C) Lying between the perineal membrane and Colles fascia
(D) Enclosed in the pelvic fascia
(E) Part of the pelvic diaphragm

18)An elderly man with prostatitis is seen at an internal medicine clinic. The seminal colliculus of his prostate gland is infected, and its fine openings are closed. Which of the following structures is/are most likely to be disturbed?
(A) Ducts of the prostate gland
(B) Prostatic utricle
(C) Ducts of the bulbourethral glands
(D) Ejaculatory ducts
(E) Duct of the seminal vesicles

19)Which of the following structures is present in the male urethra but is not present in the female urethra?
(A) Stratified squamous epithelium
(B) Pseudostratified columnar
(C) Glands of Littre
(D) External sphincter of skeletal muscle
(E) Connective tissue layer underlying the epithelium

20)Blood in the renal arcuate arteries flows next into which vessels?
a. Afferent arterioles
b. Efferent arterioles
c. Glomerular capillaries
d. Interlobar arteries
e. Interlobular arteries

21)Which cell type comprises the visceral layer of Bowman capsule?
a. Endothelial cells
b. Juxtaglomerular cells
c. Mesangial cells
d. Podocytes
e. Extraglomerular mesangial (or Lacis) cells

22)Which type of epithelium lines the thick ascending limb of the loop of Henle?

a. Pseudostratified columnar
b. Simple columnar
c. Simple cuboidal
d. Simple squamous
e. Transitional (urothelium)

23)Which cell is a modified smooth muscle cell that secretes renin?
a. Macula densa cells
b. Mesangial cells
c. Podocytes
d. Juxtaglomerular cells
e. Endothelial cells

24)An immunohistochemical technique using antibodies against aquaporins to stain a section of kidney would be expected to stain cells in which structures most intensely?
a. Collecting ducts
b. Lining of the major and minor calyces
c. Proximal convoluted tubules
d. Distal convoluted tubules
e. Glomeruli

25)What type of epithelium lines the prostatic urethra?
a. Simple columnar
b. Pseudostratified columnar
c. Stratified squamous
d. Simple squamous
e. Transitional (urothelium)

26)A 20-year-old, sexually-active female presents at her family physician's office with fever, painful arthritis of the right knee, and several small pustules on her extremities. Material from the pustules and joint fluid were collected for culture on modified Thayer-Martin medium. Which of the following results are consistent with a diagnosis of gonococcal infection?
A. Growth of small colonies consisting of gram-negative diplococci. Bacteria grown on plates are catalase and oxidase positive.
B. Growth of small colonies consisting of gram-positive cocci. Bacteria growth on plates are catalase and oxidase positive.
C. Growth of small colonies consisting of gram-negative diplococci. Bacteria growth on plates are catalase and oxidase negative.
D. Growth of large mucoid colonies consisting of gram-negative bacilli. Bacteria growth on plates are catalase and oxidase negative.

E. Growth of gram-negative diplococci within polymorphonuclear leukocytes. Bacteria can utilize glucose and maltose as a carbon sources.

27)A 22-year-old male presents to his physician, complaining of a 2-week history of a sore on his penis. Physical examination shows a firm, raised, red, nontender chancre midway between the base and glans. Which of the following is the most appropriate course of action for the physician?
A. Test a serum sample for antibodies to herpes simplex virus.
B. Swab the chancre and culture on Thayer-Martin agar.
C. Swab the chancre and perform a Gram stain.
D. Perform a dark-field examination on a swab of the active lesion.
E. Swab the chancre and culture on blood agar.

28)Which one of the following is characteristic of chlamydiae?
A. Reticulate bodies are an infectious, extracellular form of the organism.
B. Most genital tract infections are asymptomatic and undiagnosed.
C. They are sensitive to β-lactam antibiotics.
D. They stain gram-positive.
E. Inclusion bodies are formed from division of elementary bodies

29)A feature of chlamydiae that is unique to this group is:
A. the requirement of an obligate intracellular habitat.
B. its replicative cycle is distinguished by two morphologic forms that develop within cytoplasmic vacuoles.
C. the lack of detectable peptidoglycan in its cell envelope.
D. its use of host coenzymes of energy metabolism.
E. all of the above.

30)A 19-year old male presents at an STD clinic with a urethral discharge and dysuria. A swab specimen was collected and examined by Gram stain followed by light microscopy. Polymorphonuclear leukocytes were detected in the exudate along with intracellular and extracellular Gram negative diplococci. How should this patient's infection be treated?
A. No treatment is necessary
B. With a tetracycline-based antibiotic such as doxycycline.
C. With a third-generation cephalosporin antibiotic such as ceftriaxone
D. With a combination of ceftriaxone and doxycycine
E. With penicillin

31)Which of the following antibiotics is most likely to be effective for chlamydial infections?
A. Penicillins
B. Vancomycin
C. Cephalosporins
D. Carbapenems
E Macrolides

32)A 3-year-old girl presents with generalized edema shortly after recovery from an upper respiratory infection. Laboratory studies reveal marked albuminuria, as well as hypoalbuminemia and hyperlipidemia. Prior similar episodes responded to adrenal steroid medication. The most likely diagnosis is
(A) focal segmental glomerulosclerosis.
(B) membranous glomerulonephritis.
(C) minimal change disease.
(D) poststreptococcal glomerulonephritis.
(E) rapidly progressive glomerulonephritis.

33)Two weeks after recovery from a severe bout of pharyngitis, an 11-year-old girl is seen because of the acute onset of periorbital edema, hematuria, malaise, nausea, and headache. Which of the following findings is expected?
(A) Hypotension
(B) Increased antistreptolysin O titer
(C) Marked hypoalbuminemia
(D) Polyuria
(E) Positive urine cultures for β-hemolytic streptococci

34)A 28-year-old woman presents with fever, dysuria, urinary frequency, and flank tenderness. The urine contained numerous neutrophils and many white cell casts. Urine protein was moderately increased. A quantitative urine culture revealed more than 105 bacteria per milliliter. The most likely causative organism is
(A) Escherichia coli.
(B) Haemophilus influenzae.
(D) Proteus vulgaris.
(E) Pseudomonas aeruginosa.

35)A 2-year-old boy with visible abdominal distention is found to have an enormous left-sided flank mass apparently arising from, but dwarfing, the left kidney. The most likely diagnosis is
(A) angiomyolipoma.
(B) polycystic kidney.
(C) renal cell carcinoma.
(D) transitional cell carcinoma.
(E) Wilms tumor.

36)A 4-year-old boy presents with severe proteinuria, hypoalbuminemia, generalized edema, and hyperlipidemia. The patient improves on an empiric trial of corticosteroids, with complete resolution of proteinuria. Which of the following is the most likely diagnosis?
(A) Diabetic nephropathy
(B) Focal segmental glomerulosclerosis
(C) Lupus nephropathy
(D) Membranous glomerulonephritis

(E) Minimal change disease

37)A 55-year-old man presents with painless hematuria. On cystoscopy, a papillary mass is found in the bladder. Which of the following is a characteristic of this lesion?
(A) Hematuria as a late manifestation
(B) Marked tendency to recur after resection
(C) Much more likely to be benign than malignant
(D) Occurrence only in the bladder and nowhere else in the urinary tract
(E) Usual presence of distant metastases at the time of diagnosis

38)A 5-year-old boy presents with "tea colored urine," oliguria, and periorbital edema. He had a sore throat 2 weeks ago that had resolved before his parents sought medical treatment. The patient is found to be hypertensive. Urea nitrogen and creatinine are elevated. Antistreptolysin O titer and anti-DNAase B titer are also elevated. Urine tests are positive for blood and red cell casts. Which of the following is the most likely mechanism for this patient's condition?
(A) Acute bacterial infection of the kidneys
(B) Amyloid deposits
(C) ANCA-positive vasculitis
(D) Antibody against glomerular basement membrane antigens
(E) Immune complex deposits

39)A 5-year-old boy presents with hematuria. His mother states that he has had a sore throat for the past 2 days and that he has had hematuria a few times in the past, also concomitantly with a sore throat. She states that his urine usually returns to a normal clear yellow color after a few days. Which of the following is the most likely diagnosis?
(A) Alport syndrome
(B) Goodpasture syndrome
(C) IgA nephropathy
(D) Membranoproliferative glomerulonephritis
(E) Poststreptococcal glomerulonephritis

40)An 18-year-old woman presents with suprapubic pain, urinary frequency, dysuria, and hematuria for the past hour. Urine tests show the presence of pyuria but no white cell casts. Physical examination is remarkable only for suprapubic tenderness on palpation. Which of the following is the most likely diagnosis?
(A) Acute pyelonephritis
(B) Chronic pyelonephritis
(C) Cystitis
(D) Fanconi syndrome
(E) Nephrocalcinosis

41)A 45-year-old man comes to the emergency department in obvious severe pain. He states that he has severe pain in his right flank that extends down to his right groin. The pain is sharp and severe, and it started several

minutes earlier. An abdominal radiograph demonstrates the presence of right ureteral urolithiasis. Which of the following is the most likely composition of this patient's stone?
(A) Ammonium magnesium phosphate
(B) Calcium
(C) Cystine
(D) Uric acid

42)Secretion of K+ by the distal tubule will be decreased by:
(A) metabolic alkalosis
(B) a high-K+ diet
(C) hyperaldosteronism
(D) spironolactone administration
(E) thiazide diuretic administration

43)A 45-year-old woman develops severe diarrhea while on vacation. She has the following arterial blood values: pH = 7.25 PCO2 = 24 mm Hg [HCO3 −] = 10 mEq/L Venous blood samples show decreased blood [K+] and a normal anion gap. 3. A)The correct diagnosis for this patient is
(A) metabolic acidosis
(B) metabolic alkalosis
(C) respiratory acidosis
(D) respiratory alkalosis
(E) normal acid–base status 4.

B)Which of the following statements about this patient is correct?
(A) She is hypoventilating
(B) The decreased arterial [HCO3 −] is a result of buffering of excess H+ by HCO3 −
(C) The decreased blood [K+] is a result of exchange of intracellular H+ for extracellular K+
(D) The decreased blood [K+] is a result of increased circulating levels of aldosterone
(E) The decreased blood [K+] is a result of decreased circulating levels of antidiuretic hormone (ADH)

44)Use the values below to answer the following question. Glomerular capillary hydrostatic pressure = 47 mm Hg Bowman space hydrostatic pressure = 10 mm Hg Bowman space oncotic pressure = 0 mm Hg At what value of glomerular capillary oncotic pressure would glomerular filtration stop?
A) 57 mm Hg (B) 47 mm Hg (C) 37 mm Hg (D) 10 mm Hg (E) 0 mm Hg

45)The reabsorption of filtered HCO3 − :
(A) results in reabsorption of less than 50% of the filtered load when the plasma concentration of HCO3 − is 24 mEq/L
(B) acidifies tubular fluid to a pH of 4.4
(C) is directly linked to excretion of H+ as NH4 +
(D) is inhibited by decreases in arterial PCO2
(E) can proceed normally in the presence of a renal carbonic anhydrase inhibitor

46)To maintain normal H+ balance, total daily excretion of H+ should equal the daily:
(A) fixed acid production plus fixed acid ingestion
(B) HCO3 − excretion
(C) HCO3 − filtered load
(D) titratable acid excretion
(E) filtered load of H+

47)A 58-year-old man is given a glucose tolerance test. In the test, the plasma glucose concentration is increased and glucose reabsorption and excretion are measured. When the plasma glucose concentration is higher than occurs at transport maximum (Tm), the
(A) clearance of glucose is zero
(B) excretion rate of glucose equals the filtration rate of glucose
(C) reabsorption rate of glucose equals the filtration rate of glucose
(D) excretion rate of glucose increases with increasing plasma glucose concentrations
(E) renal vein glucose concentration equals the renal artery glucose concentration

48)A buffer pair (HA/A−) has a pK of 5.4. At a blood pH of 7.4, the concentration of HA is :
(A) 1/l00 that of A−
(B) 1/10 that of A−
(C) equal to that of A−
(D) 10 times that of A−
(E) 100 times that of A−

49)At plasma para-aminohippuric acid (PAH) concentrations below the transport maximum (Tm), PAH :
(A) reabsorption is not saturated
(B) clearance equals inulin clearance
(C) secretion rate equals PAH excretion rate
(D) concentration in the renal vein is close to zero
(E) concentration in the renal vein equals PAH concentration in the renal artery

50)Which of the following would cause an increase in both glomerular filtration rate (GFR) and renal plasma flow (RPF)?
(A) Hyperproteinemia
(B) A ureteral stone
(C) Dilation of the afferent arteriole
(D) Dilation of the efferent arteriole (
E) Constriction of the efferent arteriole

51)A patient has the following arterial blood values: pH = 7.52 PCO2 = 20 mm Hg [HCO3 −] = 16 mEq/L Which of the following statements about this patient is most likely to be correct?
(A) He is hypoventilating
(B) He has decreased ionized [Ca 2+] in blood
(C) He has almost complete respiratory compensation

(D) He has an acid–base disorder caused by overproduction of fixed acid
(E) Appropriate renal compensation would cause his arterial [HCO3 −] to increase

52)Which of the following would best distinguish an otherwise healthy person with severe water deprivation from a person with the syndrome of inappropriate antidiuretic hormone (SIADH)?
(A) Free-water clearance (CH2O)
(B) Urine osmolarity
(C) Plasma osmolarity
(D) Circulating levels of antidiuretic hormone (ADH)
(E) Corticopapillary osmotic gradient

53)Which of the following causes a decrease in renal Ca 2+ clearance?
(A) Hypoparathyroidism
(B) Treatment with chlorothiazide
(C) Treatment with furosemide
(D) Extracellular fluid (ECF) volume expansion
(E) Hypermagnesemia

54)Which of the following responses would also be expected to occur in this patient?
(A) Hyperventilation
(B) Decreased K+ secretion by the distal tubules
(C) Increased ratio of H2PO4 − to HPO4 −2 in urine
(D) Exchange of intracellular H+ for extracellular K+

55)A woman has a plasma osmolarity of 300 mOsm/L and a urine osmolarity of 1200 mOsm/L. The correct diagnosis is
(A) syndrome of inappropriate antidiuretic hormone (SIADH)
(B) water deprivation
(C) central diabetes insipidus
(D) nephrogenic diabetes insipidus
(E) drinking large volumes of distilled water

56)Which of the following substances has the highest renal clearance?
(A) Para-aminohippuric acid (PAH)
(B) Inulin
(C) Glucose
(D) Na +
(E) Cl –

57)Which of the following causes hyperkalemia?
(A) Exercise
(B) Alkalosis
(C) Insulin injection

(D) Decreased serum osmolarity
(E) Treatment with β-agonists

58)Which of the following is a cause of metabolic alkalosis?
(A) Diarrhea
(B) Chronic renal failure
(C) Ethylene glycol ingestion
(D) Treatment with acetazolamide
(E) Hyperaldosteronism
(F) Salicylate poisoning

59)Which of the following is an action of parathyroid hormone (PTH) on the renal tubule?
(A) Stimulation of adenylate cyclase
(B) Inhibition of distal tubule K+ secretion
(C) Inhibition of distal tubule Ca 2+ reabsorption
(D) Stimulation of proximal tubule phosphate reabsorption
(E) Inhibition of production of 1,25-dihydroxycholecalciferol

60)A man presents with hypertension and hypokalemia. Measurement of his arterial blood gases reveals a pH of 7.5 and a calculated HCO3 − of 32 mEq/L. His serum cortisol and urinary vanillylmandelic acid (VMA) are normal, his serum aldosterone is increased, and his plasma renin activity is decreased. Which of the following is the most likely cause of his hypertension?
(A) Cushing syndrome
(B) Cushing disease
(C) Conn syndrome
(D) Renal artery stenosis
(E) Pheochromocytoma

61)Which set of arterial blood values describes a heavy smoker with a history of emphysema and chronic bronchitis who is becoming increasingly somnolent?

	pH	HCO_3^- (mEq/L)	P_{CO_2} (mm Hg)
(A)	7.65	48	45
(B)	7.50	15	20
(C)	7.40	24	40
(D)	7.32	30	60
(E)	7.31	16	33

62)Which set of arterial blood values describes a patient with partially compensated respiratory alkalosis after 1 month on a mechanical ventilator?

	pH	HCO_3^- (mEq/L)	P_{CO_2} (mm Hg)
(A)	7.65	48	45
(B)	7.50	15	20
(C)	7.40	24	40
(D)	7.32	30	60
(E)	7.31	16	33

63)Which set of arterial blood values describes a patient with chronic renal failure (eating a normal protein diet) and decreased urinary excretion of NH4 +?

	pH	HCO_3^- (mEq/L)	P_{CO_2} (mm Hg)
(A)	7.65	48	45
(B)	7.50	15	20
(C)	7.40	24	40
(D)	7.32	30	60
(E)	7.31	16	33

64)Which set of arterial blood values describes a patient with untreated diabetes mellitus and increased urinary excretion of NH4 +?

	pH	HCO_3^- (mEq/L)	P_{CO_2} (mm Hg)
(A)	7.65	48	45
(B)	7.50	15	20
(C)	7.40	24	40
(D)	7.32	30	60
(E)	7.31	16	33

65)Which set of arterial blood values describes a patient with a 5-day history of vomiting?

	pH	HCO_3^- (mEq/L)	P_{CO_2} (mm Hg)
(A)	7.65	48	45
(B)	7.50	15	20
(C)	7.40	24	40
(D)	7.32	30	60
(E)	7.31	16	33

*** The following figure applies to Questions (66-70):**

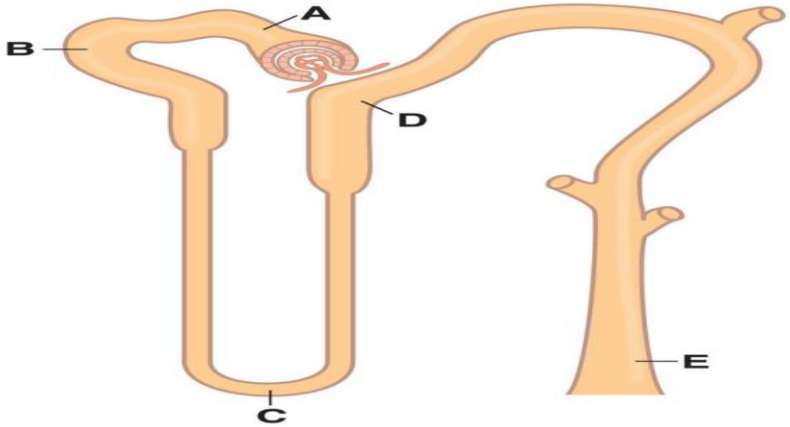

66)At which nephron site does the amount of K+ in tubular fluid exceed the amount of filtered K+ in a person on a high-K+ diet? (A) Site A (B) Site B (C) Site C (D) Site D (E) Site E
67)At which nephron site is the tubular fluid/plasma (TF/P) osmolarity lowest in a person who has been deprived of water? (A) Site A (B) Site B (C) Site C (D) Site D (E) Site E
68)At which nephron site is the tubular fluid inulin concentration highest during antidiuresis? (A) Site A (B) Site B (C) Site C (D) Site D (E) Site E
69)At which nephron site is the tubular fluid inulin concentration lowest? (A) Site A (B) Site B (C) Site
70) At which nephron site is the tubular fluid glucose concentration highest? (A) Site A (B) Site B (C) Site C (D) Site D (E) Site E

***The following graph applies to Questions (71-73). The curves show the percentage of the filtered load remaining in the tubular fluid at various sites along the nephron.**

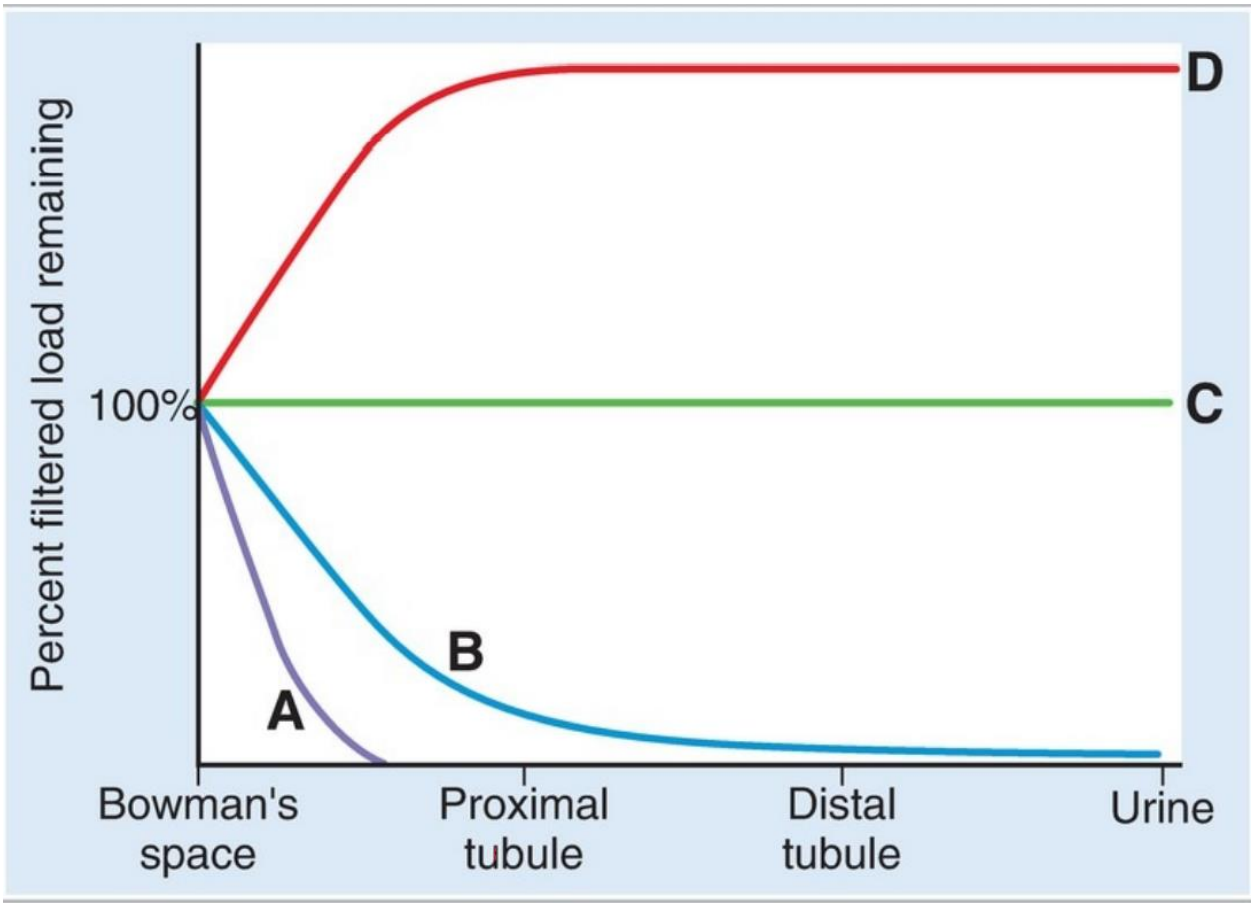

71)Which curve describes the inulin profile along the nephron? (A) Curve A (B) Curve B (C) Curve C (D) Curve D
72)Which curve describes the alanine profile along the nephron? (A) Curve A (B) Curve B (C) Curve C (D) Curve D
73)Which curve describes the para-aminohippuric acid (PAH) profile along the nephron?(A) Curve A (B) Curve B (C) Curve C (D) Curve D

74)A 5-year-old boy swallows a bottle of aspirin (salicylic acid) and is treated in the emergency room. The treatment produces a change in urine pH that increases the excretion of salicylic acid. What was the change in urine pH, and what is the mechanism of increased salicylic acid excretion?

(A) Acidification, which converts salicylic acid to its HA form (B) Alkalinization, which converts salicylic acid to its A− form (C) Acidification, which converts salicylic acid to its A− form (D) Alkalinization, which converts salicylic acid to its HA form

75)A female graduate student is hyperventilating prior to her oral comprehensive examination. She is light-headed, and her feet and hands are numb and tingling. Which of the following set of blood values would be observed in the emergency room?

	pH	Pco_2, mm Hg	Po_2, mm Hg	Ionized Ca^{2+}
(A)	7.3	30	100	Decreased
(B)	7.3	50	90	Increased
(C)	7.4	40	100	Normal
(D)	7.5	30	110	Decreased
(E)	7.5	50	90	Increased

1	B	11	E	21	D	31	E	41	B	51	B	61	D	71	C
2	C	12	A	22	C	32	C	42	D	52	C	62	B	72	A
3	A	13	A	23	D	33	B	43A	A	53	B	63	E	73	D
								43B	D						
4	D	14	A	24	A	34	A	44	C	54	D	64	E	74	B
5	A	15	A	25	E	35	E	45	D	55	B	65	A	75	D
6	B	16	D	26	A	36	E	46	A	56	A	66	E		
7	D	17	B	27	D	37	B	47	D	57	A	67	D		
8	C	18	D	28	B	38	E	48	A	58	E	68	E		
9	D	19	B	29	B	39	C	49	D	59	A	69	A		
10	c	20	E	30	D	40	C	50	C	60	C	70	A		

DONE BY: SUHAIB AL-MUSHIT

GOOD LUCK