Neuroanatomy

Dr. Maha ELBeltagy

Associate Professor of Anatomy

Faculty of Medicine

The University of Jordan

2021

Development of the Central Nervous System

Development of the nervous system

Development of the neural tube:

- At the beginning of the 3rd week an ectodermal thickening appears in the middle of the trilaminar germ disc known as the neural plate.
- The neural plate invaginates to form a neural groove.
- The lips of the neural groove approach each other & fuse together transforming the groove into a neural tube with an anterior & posterior neuropores which are obliterated on day 25 & 27 respectively transforming the neural tube into a closed tube.

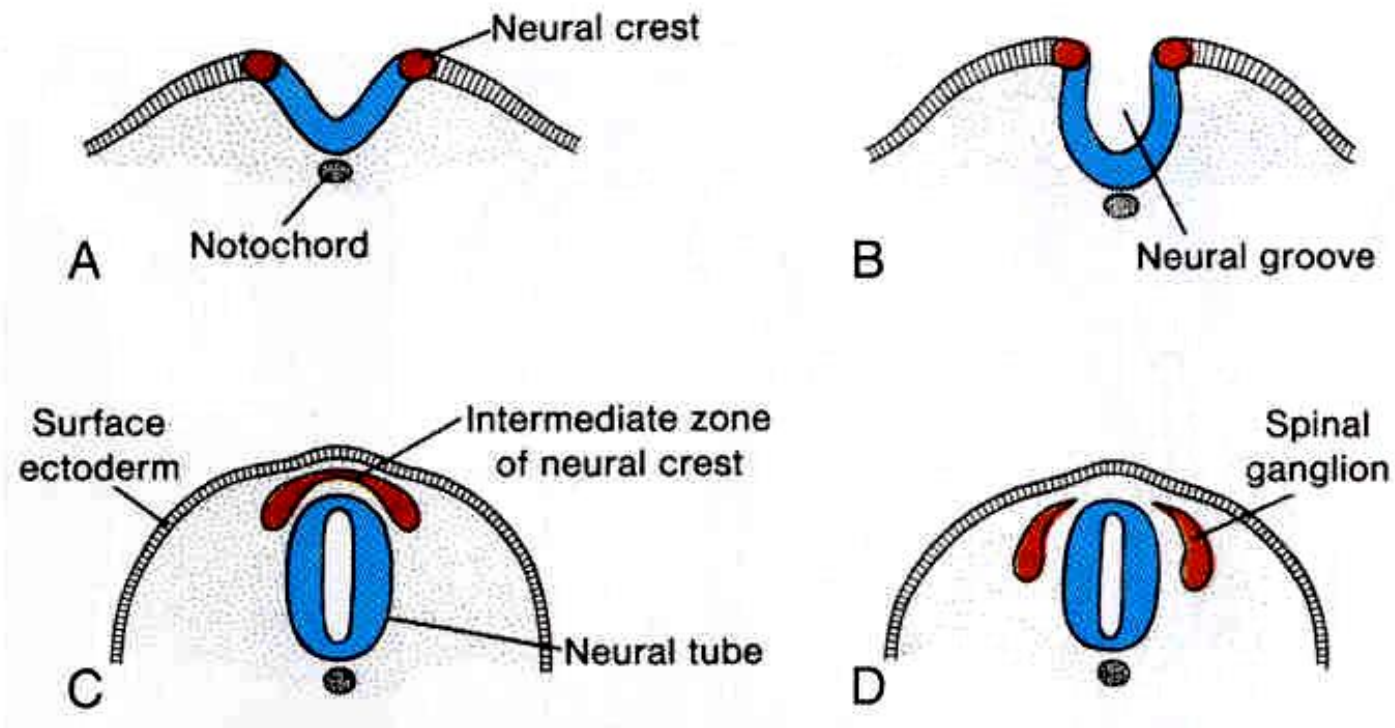

Development of the spinal cord

- The neural tube is lined by one cell layer called matrix.

- This epithelium, which extends from the cavity of the tube to the exterior, is referred to as the **ventricular zone.**

- Repeated division of the matrix cells results in an increase in length and diameter of the neural tube.

- cells migrate peripherally to form the **intermediate zone (grey matter).**

- The neuroblasts give rise to nerve fibers that grow peripherally and form a layer external to the intermediate zone called the **marginal zone (myelinated white matter).**

- neuroblasts give rise to **astrocytes** and **oligodendrocytes** .

- **Microglia** is derived from **surrounding mesenchym**

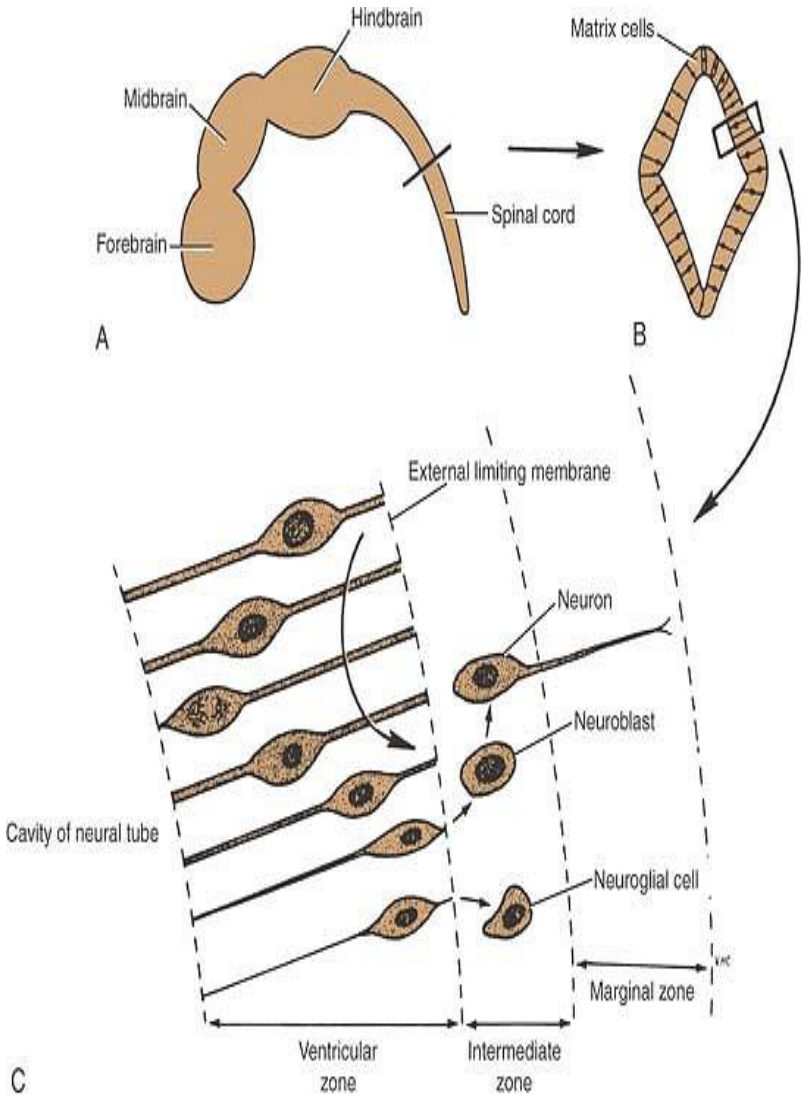

the cells in the lateral wall of the **neural tube** proliferate & are differentiated into 3 layers:

- **Inner ependymal Layer**: forms the ependymal lining of the central canal & ventricles.
- **Middle Mantle Layer**: Cellular layer which forms the grey matter of the spinal cord.
- **Outer Marginal Layer**: forms the white matter of the spinal cord.

- The thick lateral walls are connected together by thin **roof plate** (dorsal) & **floor plate** (ventral).
- A groove (sulcus limitans) appears in the lateral wall dividing it into:
  - Dorsal part **(Alar Plate)** which expands to form the dorsal **(sensory)** horn.
  - Ventral part (**basal plate**) which expands to form the ventral **(motor)** horn.
- The cavity of the tube remains narrow & forms the central canal of the spinal cord.

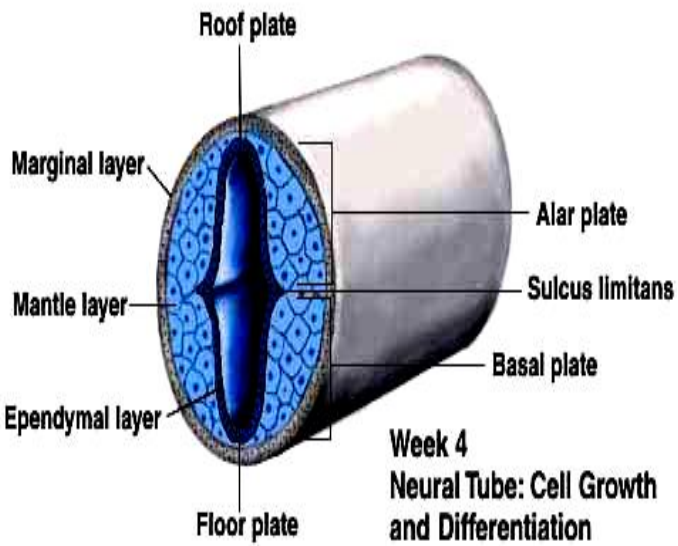

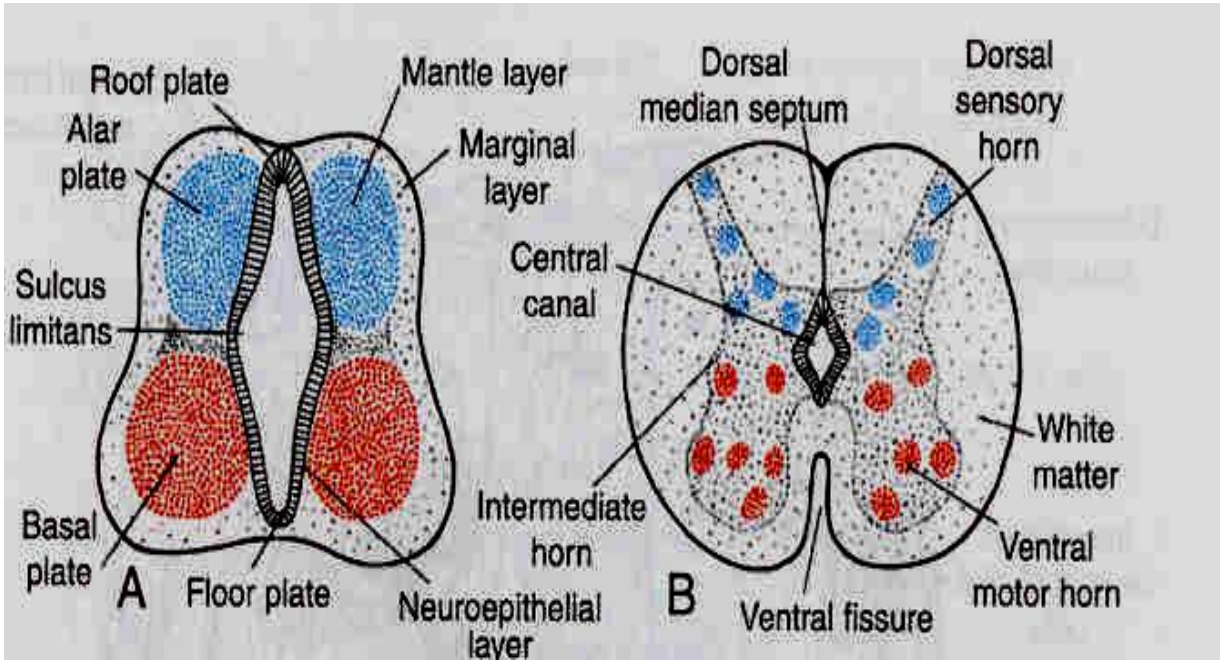

Development of sensory and motor roots

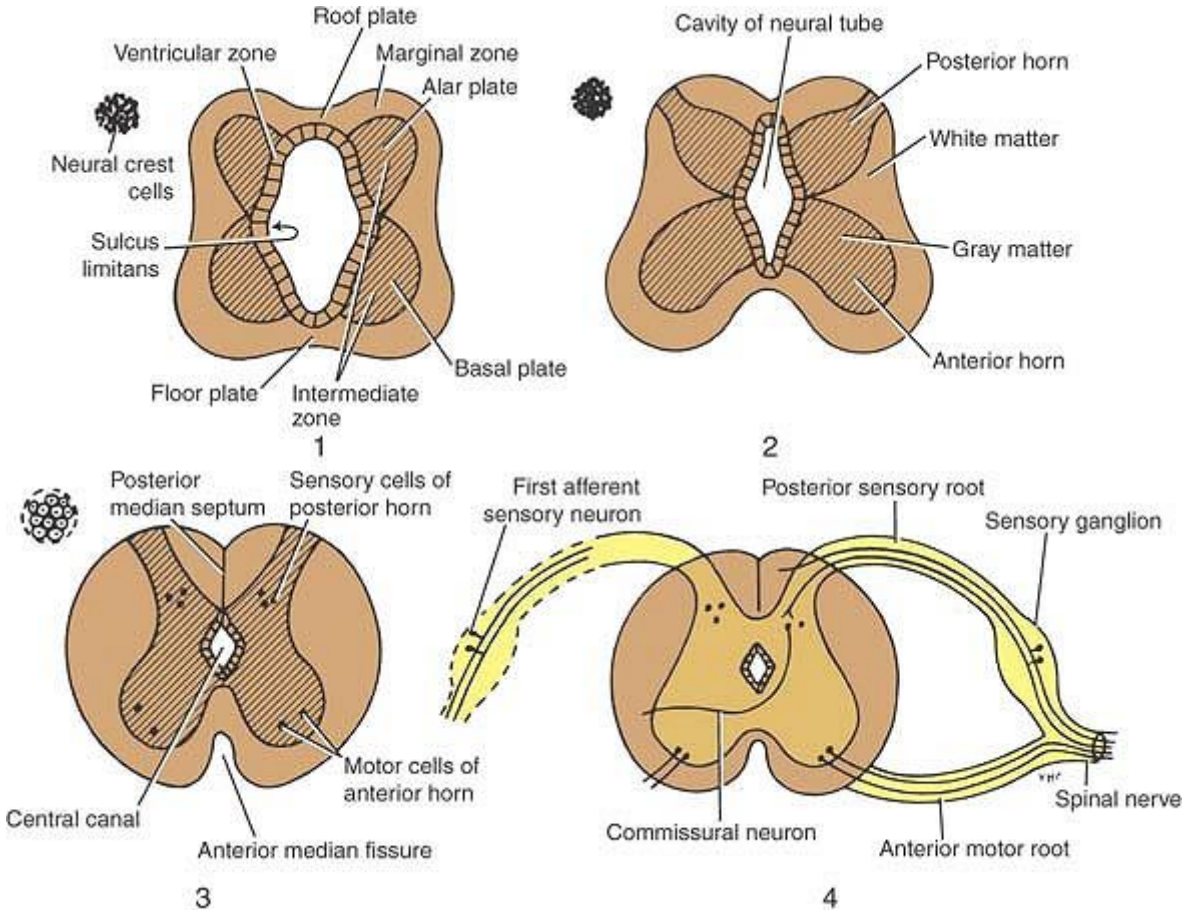

Development of the Meninges

The **pia, arachnoid and dura maters are formed from the mesenchyme.** (sclerotome) that surrounds the neural tube.

The **subarachnoid space develops as a** cavity in the mesenchyme, which becomes filled with **cerebrospinal fluid.**

During the first 2 months of intrauterine life, the spinal cord is the same length as the vertebral column.

at birth, the coccygeal end of the cord lies at the level of the third lumbar vertebra.

In the adult, the lower end of the spinal cord lies at the level of
the lower border of the body of the first lumbar vertebra.

The oblique spinal nerves below L1 form the **cauda equina.**

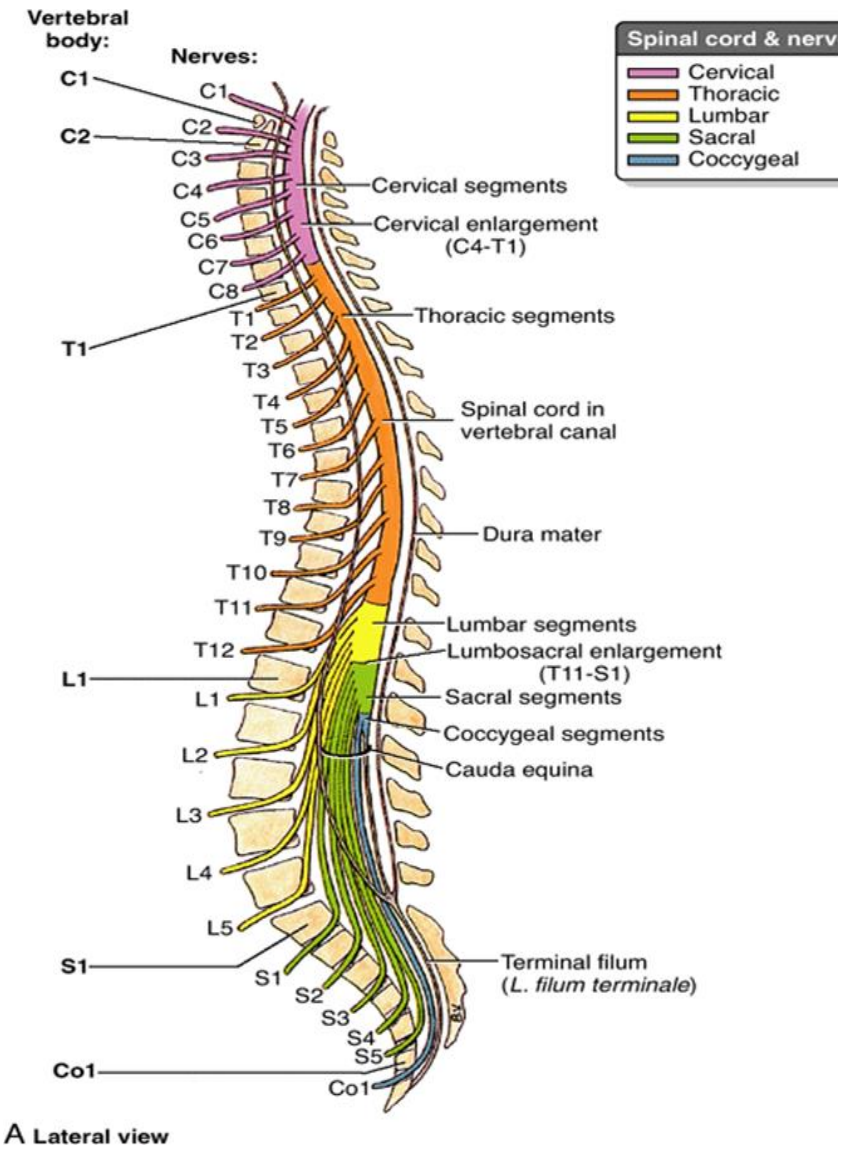

Corresponding relationship between spinal segments and vertebrae

spinal segments	vertebrae bodies
C1-C4	C1-C4
C5 ~ C8, T l~ T4	C4 ~ T3
T5 ~ T8	T3 ~ T6
T9-T12	T6-T9
L1-L5	T10-T12
S l~S5,Co1	LI

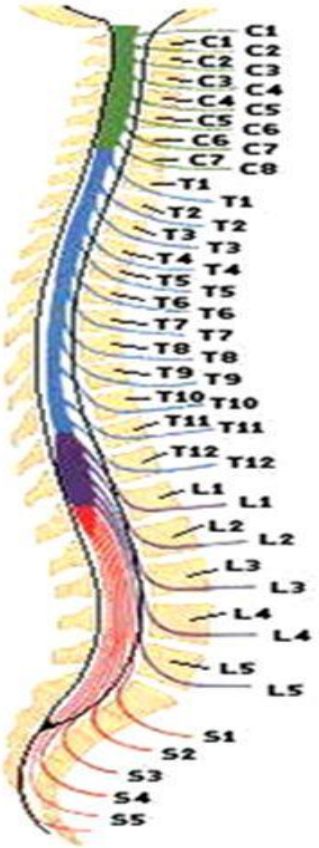

Regions	Spinal segments	Vertebral level	General rule
Upper cervical	C2	C2	Same level
Lower cervical	C6	C5	One vertebra above
Upper thoracic	T5	T3	Two vertebrae above
Lower thoracic	T10	T7	Three vertebrae above
Lumbar	L1–L5	T10–T11	Three to five vertebrae above
Sacral and coccygeal	S1–S5 and C × 1	T12–L1	Six to ten vertebrae above

Congenital Malformations of spinal cord development

1) **Spina bifida occulta**: Absent **vertebral arch** with normal spinal cord. It affects the lumbosacral area & is usually covered with hairy skin.

2) **Spina bifida cystica**:

- **Meningocele**: The meninges herniates through the spina bifida to form subcutaneous sac filled with CSF.
- **Meningomyelocele**: The spinal cord herniates through the meningocele.
- **Myelocele (Rachischisis):** Failure of obliteration of the neural tube.

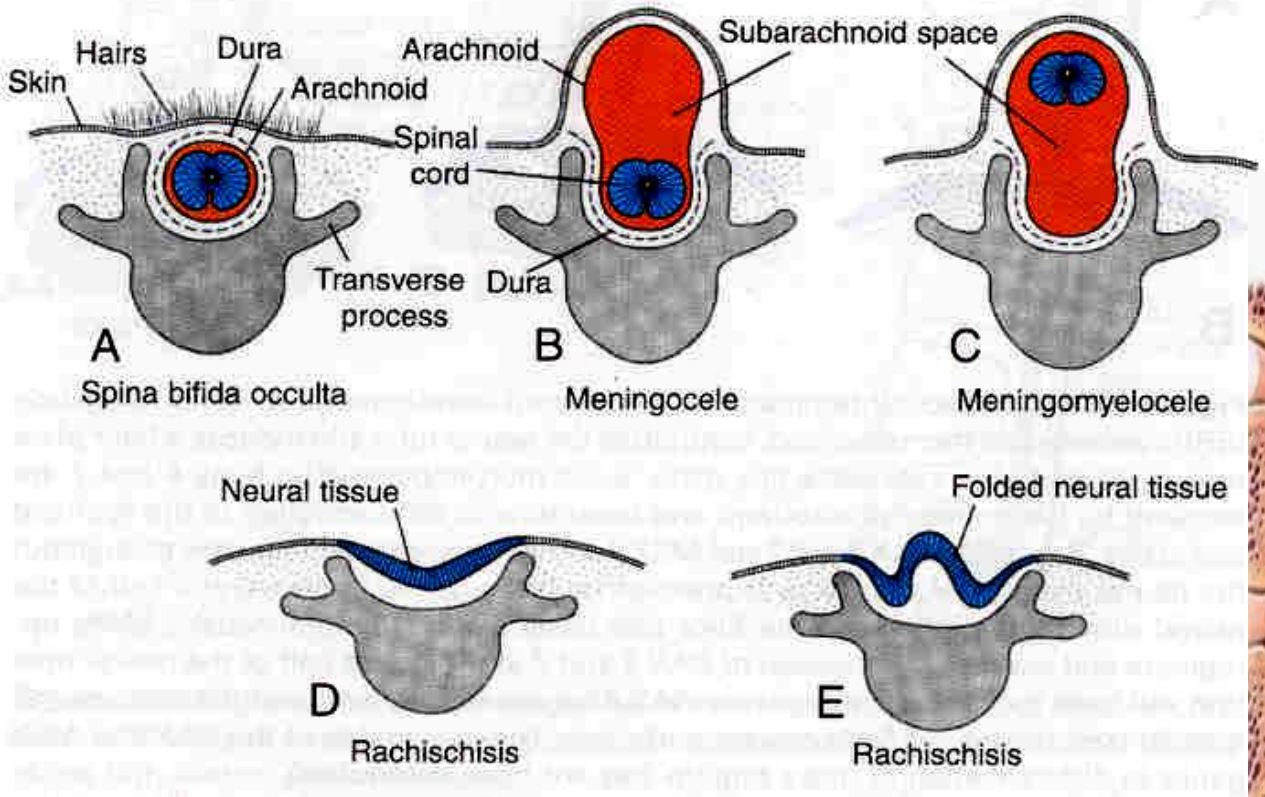

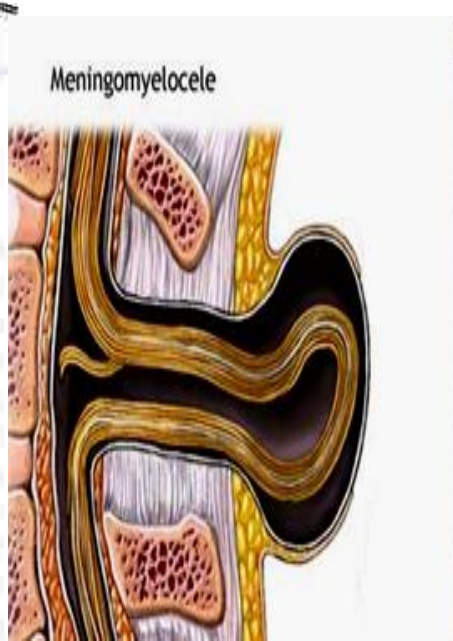

Development of the brain

The cranial part of the neural tube forms 3 brain vesicles:

- **Forebrain vesicle(Prosencephalon):** forms 2 lateral evaginations which develop to form the **2 cerebral hemispheres** (their cavities form the lateral ventricles)& the median part develops to form the **diencephalon** (its cavity forms the 3rd ventricle.
- **Midbrain vesicle (Mesencephalon):** develops to form the midbrain & its cavity forms cerebral aqueduct.
- **Hindbrain vesicle (Rhombencephalon):** develops to form pons, medulla & cerebellum. Its cavity forms the 4th ventricle.

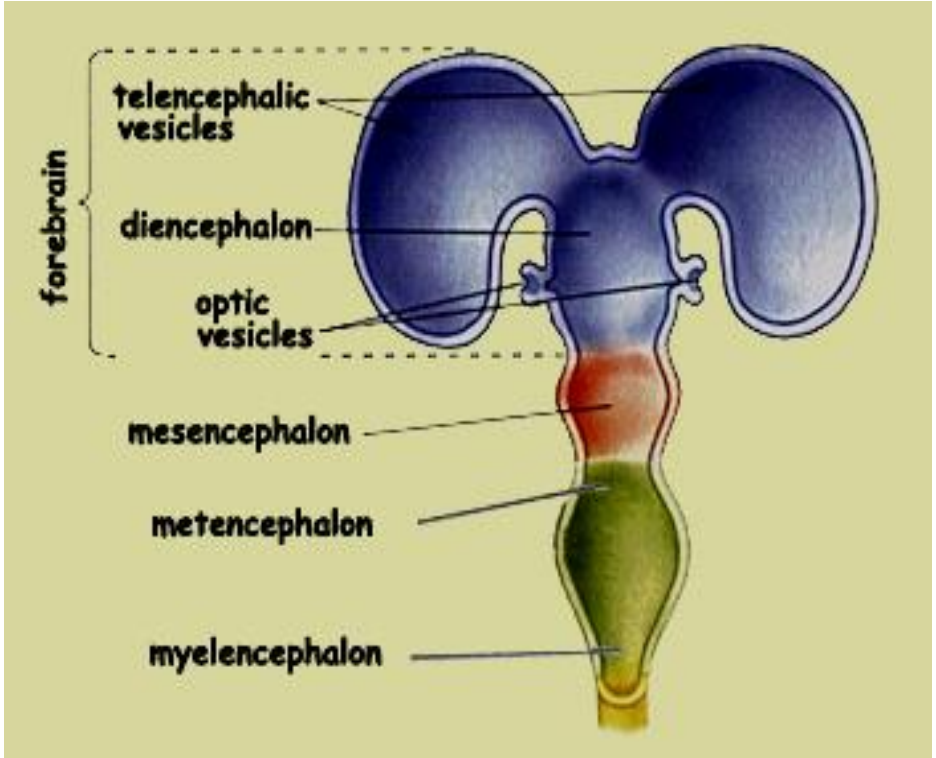

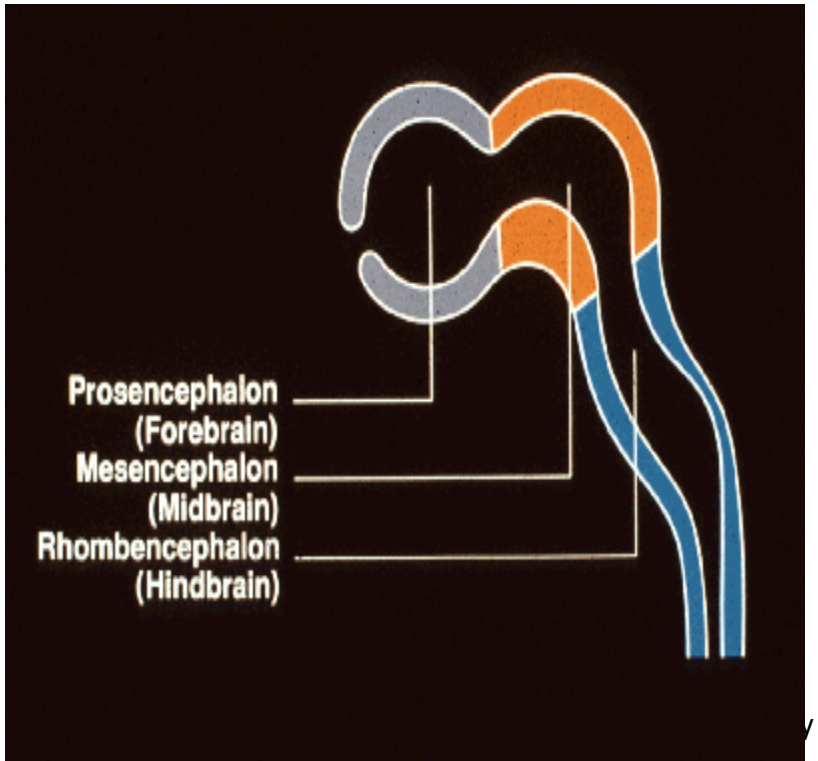

Embryonic (developmental) divisions of the Brain

Primary vesicle	Secondary vesicle	Derivatives
Prosencephalon	telencephalon	Cerebral cortex Cerebral white matter Basal ganglia
	diencephalon	Thalamus Hypothalamus Subthalamus Epithalamus
Mesencephalon	mesencephalon	Midbrain
Rhombencephalon	metencephalon	Cerebellum Pons
	myelencephalon	Medulla oblongata

DEVELOPMENT OF THE MEDULLA OBLONGATA

- As in the development of the spinal cord the medulla will have an alar plate & a basal plate separated by a sulcus limitans & connected by a thin roof plate & a floor plate.
- The lateral walls move away from each other stretching the roof plate & enlarging its cavity which forms the 4th ventricle.

The alar plate forms the sensory nuclei of the medulla & the basal plate forms the motor nuclei.

Between the fourth and fifth months, local resorptions of the roof plate occur, forming lateral **foramina of Luschka, and a median** foramen **of Magendie.**

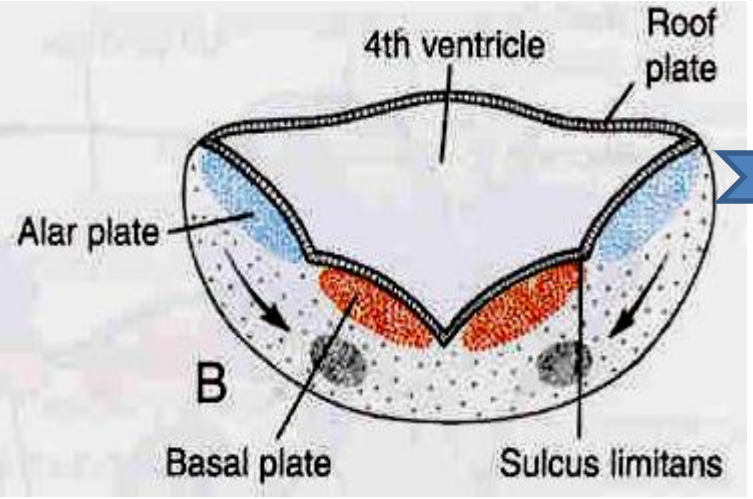

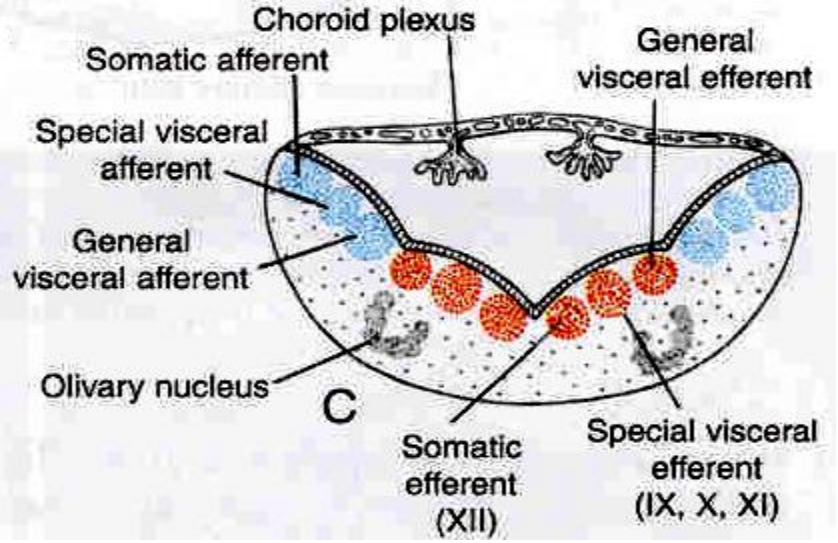

Development of the pons & cerebellum

- The same steps in the development of the medulla occur but the **alar plates** bend medially to form **2 rhombic lips**.
- The rhombic lips approach each other & fuse together forming a **cerebellar plate**.
- The cerebellar plate differentiates into a median part which forms the **vermis** & 2 lateral masses which form the **cerebellar hemispheres**.
- The cavity forms part of the 4th ventricle.

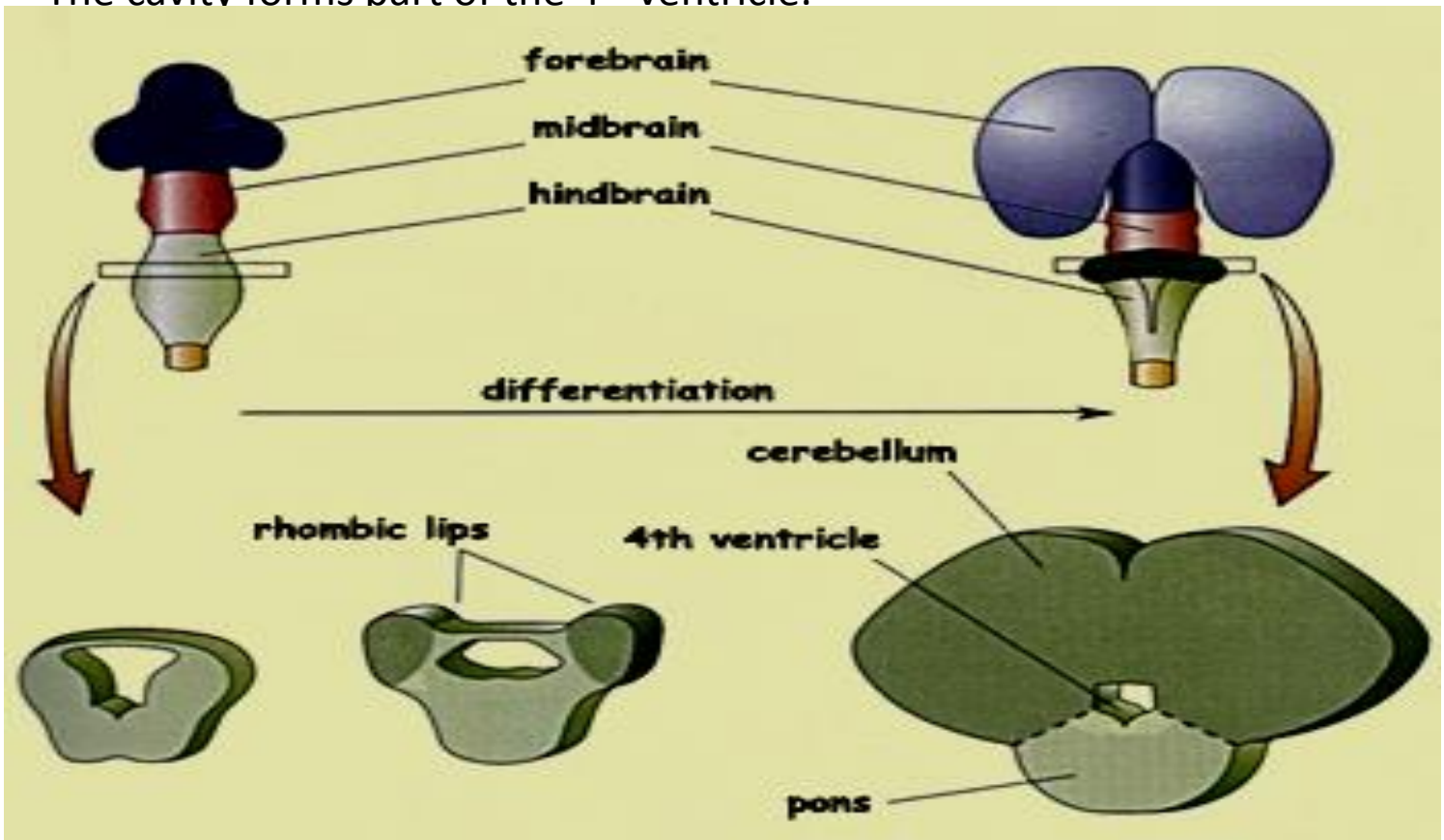

Development of Midbrain

- As in the development of the spinal cord & the medulla the midbrain will have an alar plate & a basal plate separated by a sulcus limitans & connected by a thin roof plate & a floor plate.
- The **alar plates** develop to form the **tectum** which is divided by a vertical & transverse grooves into 4 colliculi.
- The **basal plate** forms the motor nuclei in the tegmentum of midbrain
- The **marginal layer** of the basal plate enlarges greatly to form the crus cerebri.
- It cavity remains narrow & forms the cerebral aqueduct.

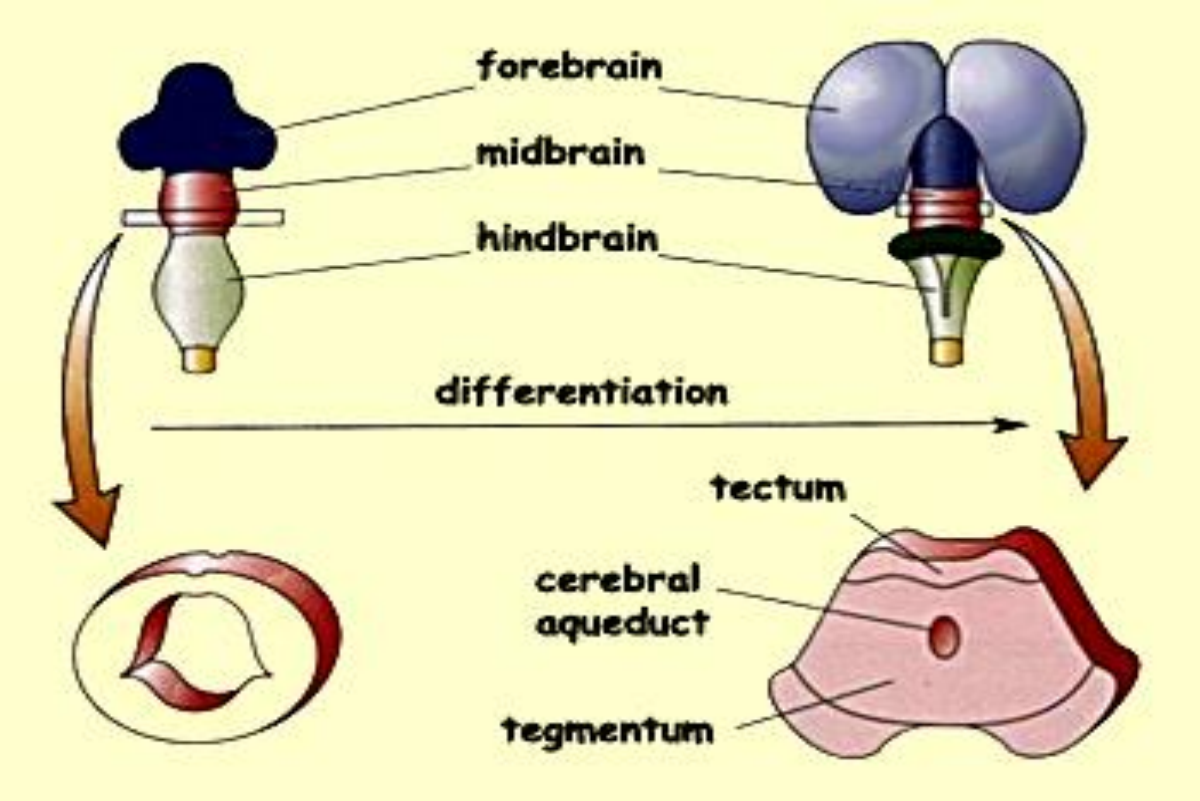

Development of the Diencephalon

It develops from the median part of the forebrain. It consists of 2 lateral walls connected by a roof plate & a floor plate, its cavity is called the 3rd ventricle.

The roof plate:

- Its anterior part forms the choroid plexus of the 3rd ventricle.
- Its posterior part forms the pineal body.

A hypothalamic sulcus appears in the lateral wall which separates the **thalamus** above from the **hypothalamus** below.

The floor plate forms the posterior lobe of the **pituitary gland.**

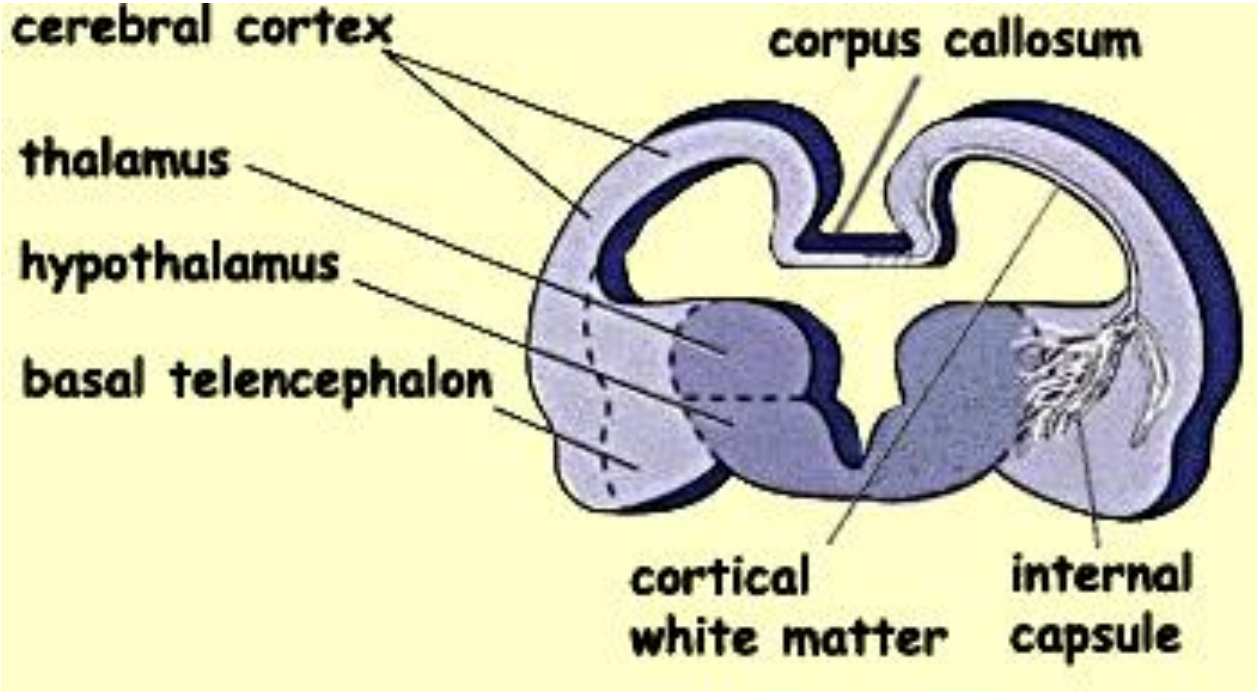

Development of the cerebral hemisphere

The 2 cerebral hemispheres arise as 2 evaginations from the lateral wall of the forebrain.

The cavity of each of them expands to form the **lateral ventricle**.

The wall of the hemisphere consists of 3 layers: ependymal, mantle & marginal.

The **mantle layer** at the base of the hemisphere forms the **basal ganglia**.

The hemispheres enlarge & overlaps the brain stem & cerebellum.

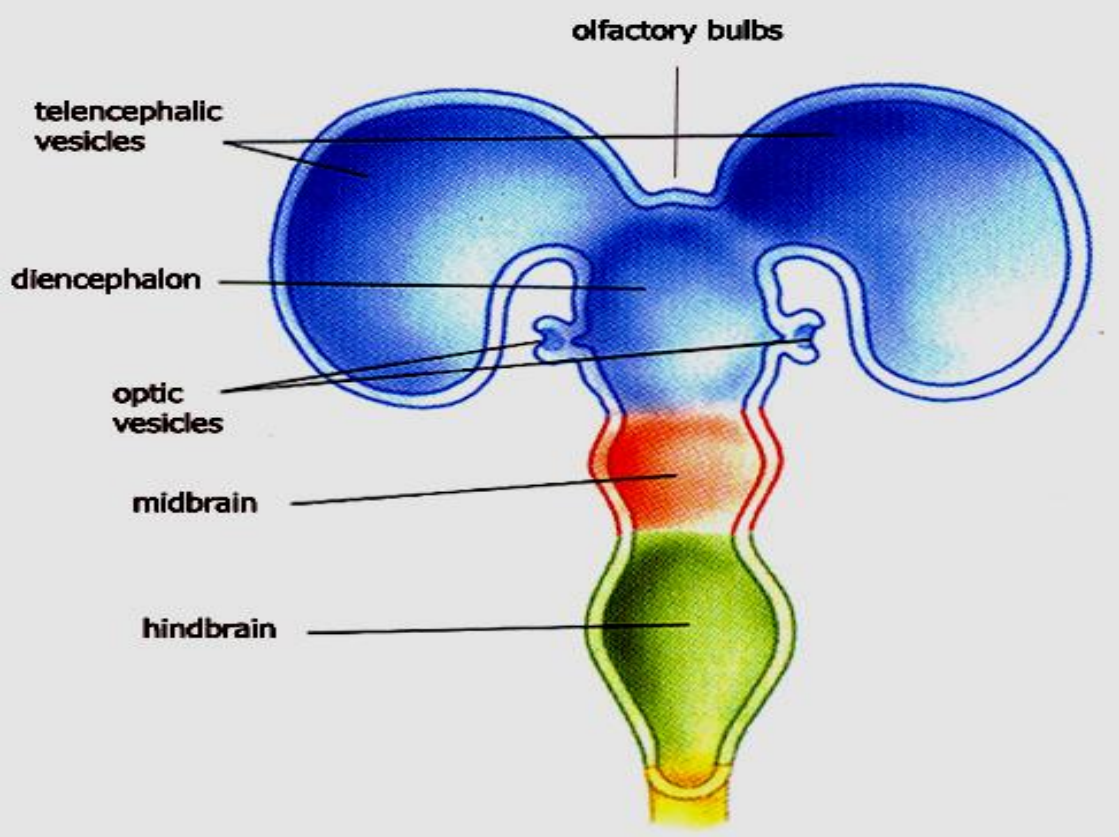

Congenital Malformations of brain development

1) **Hydrocephalus**: It is of 2 types

- **Internal hydrocephalus**: Excessive accumulation of CSF within the ventricles of the brain.
- **External hydrocephalus**: Excessive accumulation of the CSF between the brain & arachnoid mater.

2) **Exencephaly**: It is due to failure of closure of anterior neuropore. The vault of the skull is absent & the brain is exposed. When the brain is degenerated the anaomaly is known as **Anencephaly.**

3) **Menigocele**: the meninges herniated through a deficient part of the skull.

4) **Meningoencephalocele**: part of the brain herniated through the meningocele.

5) **Meningo-hydro-enecephalocele**: part of the ventricle is found within the brain tissue which herniated through the meningocele.

6) **Holoprosencephaly**: Results from degeneration of midline structures leading to fusion of lateral ventricles, orbital & nasal cavities.

THANK YOU