CNS
ANATOMY

N

Writer: RAWAN ALKHAZALEH

Science: SARAH OBEIDAT

Final: RAWAN AWWAD

Doctor: MAHA ELBELTAGY

In the name of Allah, the most compassionate the most merciful

Hello everyone, in this lecture, we will gonna talk about new different topics, so let's start,

As you know inside the CNS we have the gray matter and,The **white matter** which is consists of three types of fibers ;

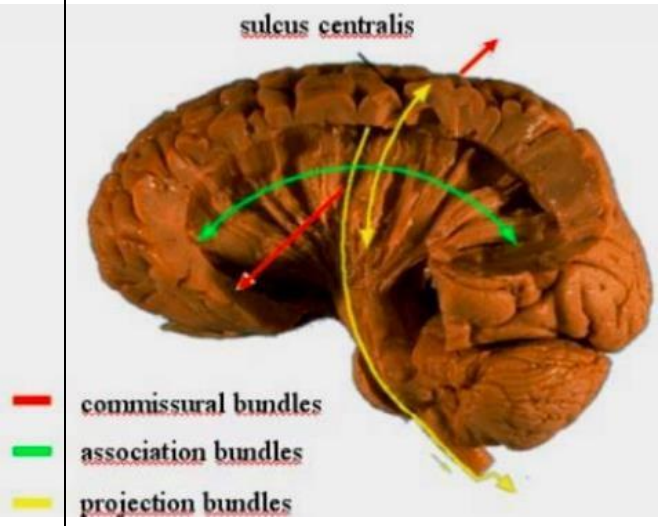

- Association fibers that connect different areas in the same hemisphere so that each lobe aware of the other lobe's function.
- commissural fibers that connect similar areas in the two hemispheres (area #1 in the left hemisphere with area #1 in the right hemisphere).
- projection fibers connect cortex with brainstem and spinal cord,(from cortex-descending fibers- and to cortex-ascending fibers-).

DEEPLY ON THEM:

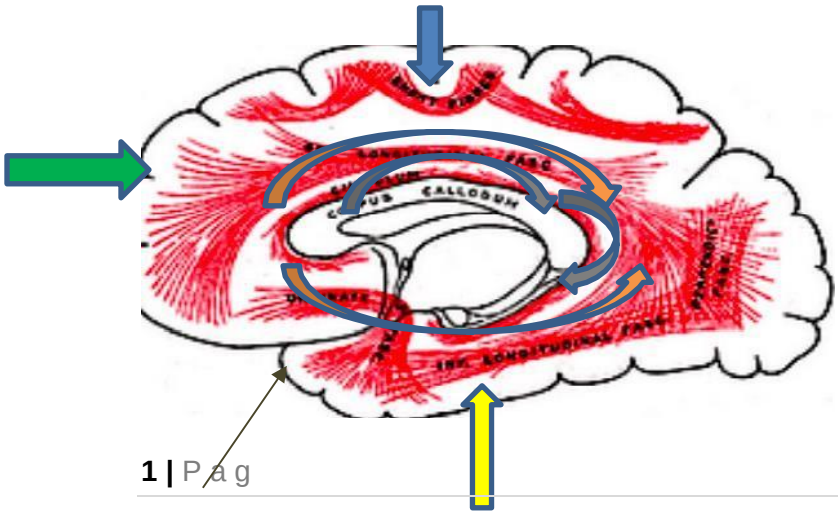

Association fibers according to their length divided into;

- Short association fibers a -u- shaped bundle that connect adjacent gyri blue arrow.

- .long association fibers green arrows, these fibers long enough to connect multiple gyri in different lobes together, and it is subdivided into:
- Superior longitudinal bundle: that passes from the frontal lobe to temporal, parietal, and occipital lobe and connect them.
- Inferior longitudinal bundle: connect temporal lobe with the occipital lobe yellow arow.
- Cingulum bundle gray arrows: in the medial surface of the brain, there is a corpus callosum, and above it lies the cingulate gyrus (the sixth lobe which is related to the limbic system) ok cingulum bundle related to the cingulate gyrus. cingulum forms an incomplete circle around the corpus callosum near the rostrum(we will talk about this structure shortly) and completes its way until reaches the uncus. this bundle is part of the limbic system and is a connection between frontal, parietal, and temporal lobes.
- *Uncinate fasciculus: a connection between frontal and temporal lobes black thin arrow.

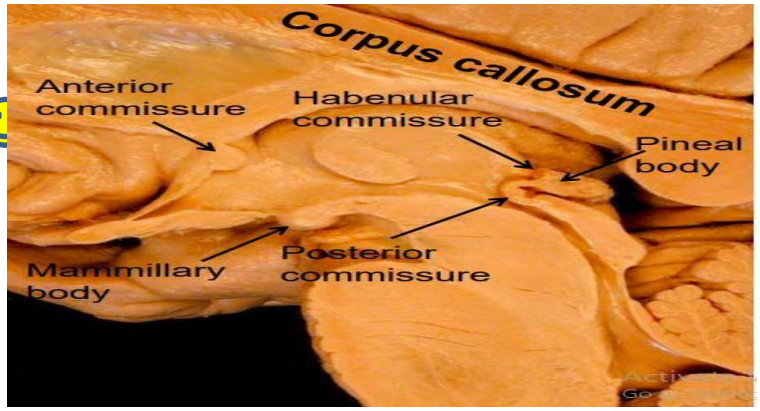

Commissural fibers:

count on your fingers these five types

1.***anterior commissure***: lies in the front of the anterior column of the fornix remember it we will talk about it nearly, connect the piriform fossae on one side with the other. piriform fossae located in

the most anterior part of the temporal lobe and it has a role in smelling and transmission of fast acute pain.

---

in the posterior part of the brain there is a gland-pineal body- this gland plays an important role in the regulation of the dark light circle (secret the melatonin). the pineal gland hanged by two limbs the superior one is the habenular commissure and the inferior one is the posterior commissure.

2.***posterior commissure***: the inferior limb of the pineal gland it has a role in the light reflex.

there are two types of light reflex: the direct reflex the one that makes your left pupil constrict when the light focuses on your left aye .and the consensual reflex what makes the constriction of the right pupil in the previous case.

3.***Habenular commissure***: the superior limb of the pineal gland, connect the two amygdaloid nuclei.

what is the amygdala ?its a collection of neuron bodies in the uncus and it is part of the limbic system .and it has an important role in smelling and fear sensation remember the amygdala has an anatomical relation with basal ganglia but functionally to the limbic system.

habenular is the center of integration of olfactory and visceral pathways.

4.***fornix commissure***(hippocampal commissure):

fornix is the two fornices.fornix separated from corpus callosum by septum pellucidum

❖ let's go back again to the tentorial surface below the uncus there was the parahippocampal gyrus, inside this gyrus you can find an aggregation of neuron bodies related to the limbic system responsible for short term and recent memory called the hippocampus t.The hippocampal efferent fibers forming the crura -the posterior part of the fornix-, crura arches in the superior surface of the thalamus forming the fornix body and then run anteriorly to form the anterior column of the fornix, now the anterior part pass deeply in the brain and form the- mamillary body- the nucleus of the hypothalamus. so because its relationship with the hypothalamus and with the parahippocampus nucleus; fornix is part of the limbic system.The two fornices connected by fornix commissure.

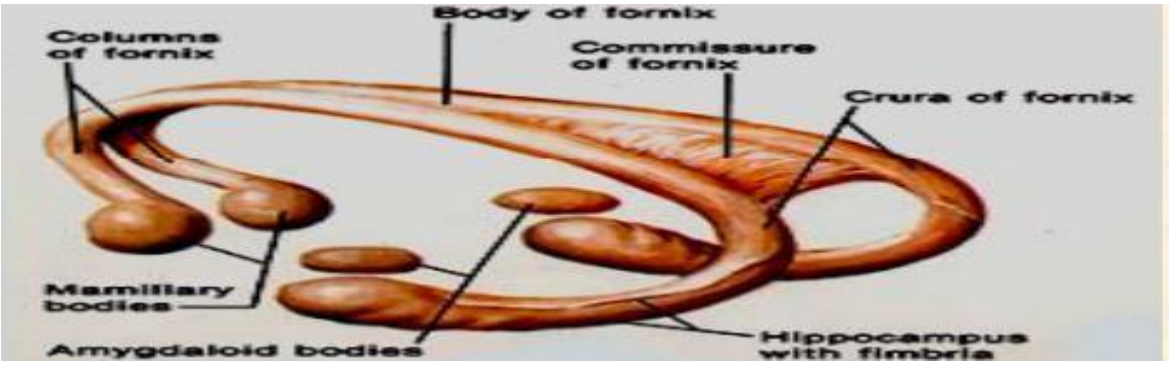

FORNIX

5. ***Corpus callosum***: the largest and the last commissural fibers around 300 billion fibers and 10 cm.

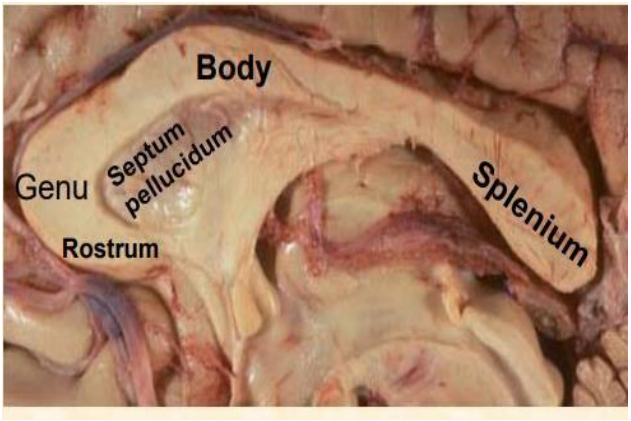

CORPUS CALLOSUM CAN SEEN BY SAGGETAL SECTION ONLY

The corpus callosum connects all parts of the cerebral hemisphere by one side to the other except a small part of the temporal lobe that is connected through the anterior commissure.
anatomically corpus callosum consists of four parts: the most anterior part the ***rostrum***, ***genu*** the curvature, the ***body***, and the most posterior part the ***splenium***.
While you looking at this picture notice with me these three concepts:

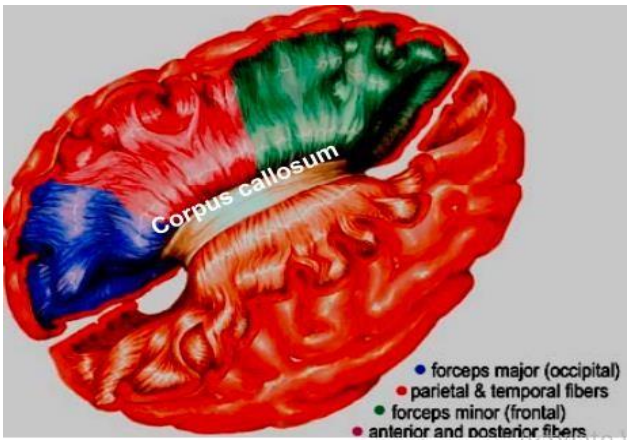

- ***Forceps minor*** green: the anterior fibers that originate from the genu and make a connection BTW frontal lobes.
- ***Forceps major*** blue: the backward fibers that originate from the splenium and connect the occipital lobes.

- ***Tapetum***: the remainder fibers that connect the different parts of the cerebral hemisphere.

Now look again at our picture if someone asks you to recognize the anterior and posterior part of the corpus callosum, all you need to do is measuring the distance between either end of the cerebral cortex and either end of the corpus callosum, the shortest distance is towards the frontal lobe.

Now what is happened if there is a lesion in the corpus callosum? it is the largest fibers connect the right and the left hemispheres so if this connection has been cut -maybe in a neuronal surgery- it will result in* disassociation brain phenomena also it is called the callosal syndrome or the split-brain phenomena* .in these phenomena the right side of the brain work separately with the left one that's lead to *apraxia* apraxia is a motor disorder, no paralysis happened but the coordination of motor movements is not occurring properly.Apraxia also can result from a lesion in the premotor area or the parietal area (**Parietal lesions** are likely to cause ideo-kinetic **apraxia** because they interrupt the fibers traveling through the **parietal** lobe on their way to motor regions *from google*.)

All corpus callosal parts supplied by the anterior cerebral artery except the splenium which is supplied by posterior cerebral artery.

Projection fibers:

There are two types of these fibers ether to the cortex- ascending sensory fibers- or away from the cortex- descending motor fibers-.

1.projection fibers to the cortex (thalamocortical sensory fibers): all these fibers are a projection from the thalamus the largest relay station in the brain, its receive all the sensation from the body. these collections of fibers called radiation because they fanning like a rise of the sun.

the thalamus is divided into so many nuclei :

- Nucleus in the posterior part called posto-lateral-ventral nucleus **plvnt** .the fibers that projected from this nucleus to the area 312 in the postcentral gyrus transient general sensation .these projection fibers called sensory radiation.
- Nnuclei of the anterior part of the thalamus, fibers from this nucleus project to the cingulate gyrus .these fibers called the anterior thalamic radiation and it related to the limbic system.

The most posterior part of the thalamus -the pulvinar- divided into medial geniculate body and lateral geniculate body .

- Projection fibers from LGB to the visual area 17 in the occipital lobe called visual(optic)radiation.
- Projection fibers from MGB to the auditory area 41,42 in the superior temporal gyrus called auditory radiation.

2.projection fibers from the cortex (motor fibers):

- Pyramidal tract from areas number 4,6and 312 this tract crossed to the opposite side in the medulla.
- Extrapyramidal tract.
- Cortico-ponto-cerebellar fibers.
- Corticothalamic fibers.

Our shinest example on the projection fibers is the **internal capsule**, so let's talk about it :

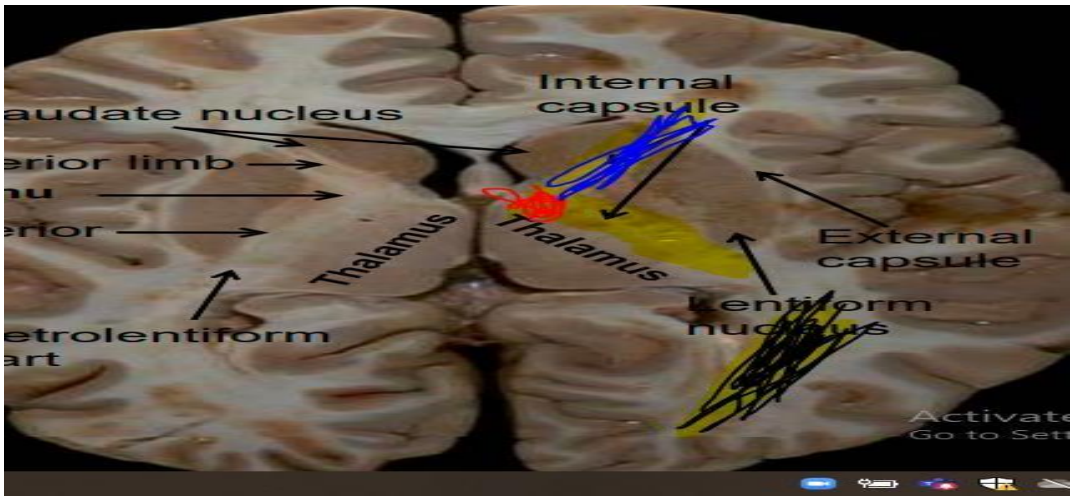

BACK TO THIS PICTURE WHEN YOU REACH ITS PARTS

Internal capsule:

- a -v-shaped bundle of projection fibers between the thalamus and caudate nucleus medially and the lentiform nucleus laterally.
- Lies on the medial surface of the lentiform nucleus separating it from the caudate nucleus above and the thalamus below.
- Continues above as a corona radiata and below with the crus cerebri, pons and medulla.

Now in your other fingers count with me the five parts of the capsule:

1. ***anterior limb*** ***IN*** THE BLUE which lies between caudate and lentiform nucleus. the types of fibers in this part are

- descending fronto-pontocerebellar fibers.
- ascending anterior thalamic radiation.

2. ***Genu*** IN RED of the internal capsule which lies between thalamus and caudate medially and lentiform laterally. genu fibers type is corticobulbar (nuclei of the cranial nerve).

3. Posterior limb IN YELLOW lies between thalamus and lentiform .two types of fibers again in this part *descending corticospinal fibers from area number 4 .*ascending sensory thalamic radiation to area 312

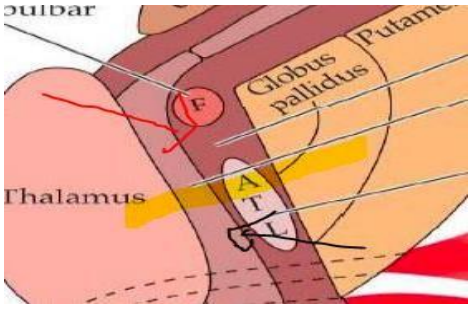

posterior limb divided into the anterior motor part red arrow and the posterior sensory part black arrow

4. ***Retrolentiform part*** IN BLACK: lies behind the capsule and contains an important type of fibers which is the optic radiation fibers(posterior thalamic radiation).

5. ***sublentiform part***: does not appear in this horizontal section. It contains auditory radiation(inferior thalamic radiation).

Its important to know these parts and which type of fibers they have because the internal capsule very tight place inside the brain and the vessels in this area are very soft and delicate so they are easily ruptured in the case of hypertension, so blood could accumulate and make pressure on the fibers and affect their function .

what about taking a short break, then go to the next topic which is the:

Basal ganglia or nuclei *depend on your fashion *

Functions of BG:

1.Postural control:

- control axial and girdle movements.
- automatic association movement(dancing, walking)

2.**Voluntary control of movement**:

what is the difference between BG and the cortex at this point? is that the cortex controls the fine movement, but BG controls a group of movements or sequencing of movement like what you do when playing football(flex your hip and knee, extend your leg at the same time and focus your body).

- Initiation of movement.
- Change from one pattern to another.
- Learning skill (singing, drawing)
- Programming and correcting movement while in progress.

Anatomy of BG:

Take a sagittal section with horizontal one to can understand the anatomy and the relations.

Thalamus has a medial relationship with BG.

Parts of BG:

- ***Striatum*** (neostriatum):- consist of caudate and putamen nuclei.

❖ Caudate: -comma liked structure - it is head joined with the anterior part of the lentiform nucleus, then it runs posteriorly to form the body and the tail of the caudate nucleus then continue until reaching the amygdala.

❖ Putamin: the lateral part of the lentiform nucleus.

Called striatum because the appearance of the ' pale internal capsule between the dark caudate and the dark lentiform.

- ***lentiform*** divided into putamen laterally and globus pallidus medially.
-
- Globus pallidus(palliostraiatum) divided into : *globus pallidus external and *globus pallidus internal.

- ***amydala*** (archistiatum): connected to the caudate nucleus.

- ***Subthalamic nucleus***: the motor zoon of the diencephalon, it produces an excitatory glutamine neurotransmitter.

- ***Substantia nigra***: lies in the midbrain anterior to the cerebral aqueduct, it has the inhibitory dopamine neurotransmitter .lesion in this area as you know causing Parkinson's.

- ***Claustrum***: sheth of gray matter in the external capsule lateral to lentiform, no known function until now.

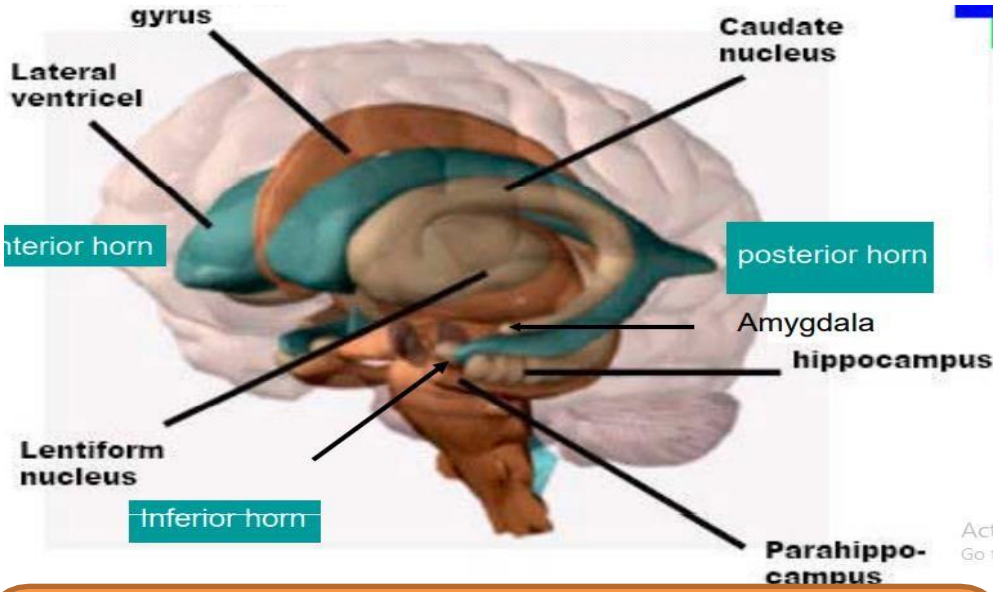

Basal ganglia interact with other parts via efferent and afferent fibers. Corpus striatum receives inputs and globus pallidus sends output

THERE ARE SLIEDS TALKING ABOUT THE DIRECT AND INDIRECT PATHWAYS IN BG , WE DISCUSSED IT ALREADY IN THE PHYSIOLOGY LECTURES.

YOU KNOW ALL THE BELOW

Disease of basal ganglia

(on the opposite side)

1- Hypokinetic +hypertonia

- **Parkinsonism**
- Lesion of direct pathway
  - **Degeneration of dopamine**-producing cells in substantia nigra-depletion of dopamine in striatum
  - **Resting tremor** (N.B: intention tremor in cerebellar disease)
  - **Rigidity** – simultaneous contraction of flexors and extensors
  - **Bradykinesia** = Slowness of movement (slurred speech) and mask face
  - **Postural disturbance**
  - **No loss of motor or sensory function**
  - **Treated by L-Dopa not dopamine**

Disease of basal ganglia

2- Hyperkinetic

(lesion of indirect pathway)

•Huntington's disease

(hypotonia+hyperkinesia)

- hereditary disease of unwanted movements. It results from degeneration of the caudate and putamen, and produces continuous dance-like movements of the face and limbs –choreoathetosis
- **Sydenham Chorea**

Rheumatic fever- transient- full recovery

•Hemiballism

- flailing movements of one arm and leg (one-sided), which is caused by damage (i.e., stroke) of the subthalamic nucleus.

WELL DONE DOCTORS,GOOD JOB