RESPIRATORY SYSTEM ANATOMY

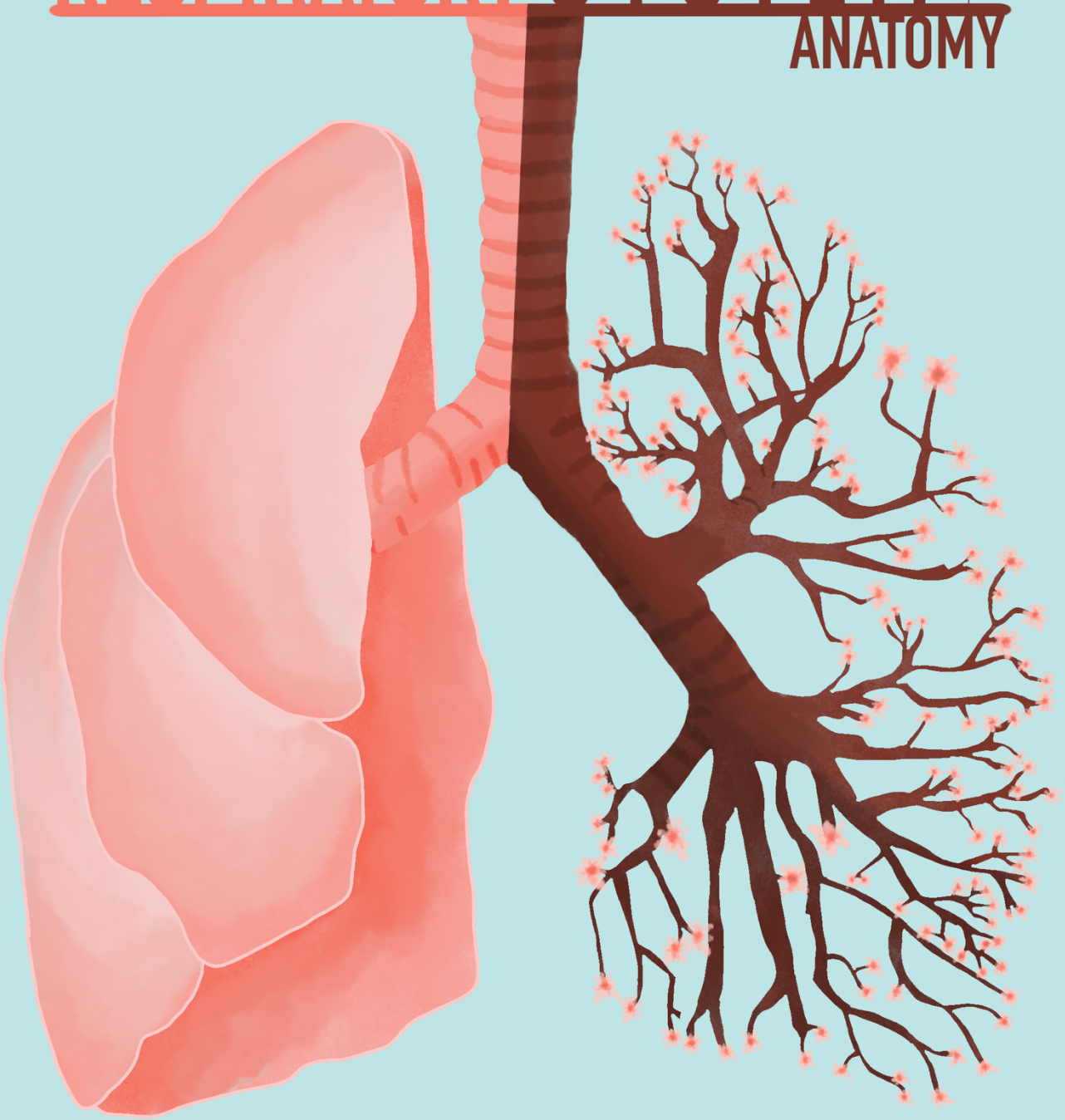

Title: Embryology 2– Maturation of The Lungs

Writer: Alia Abbadi

Science: Anas Zayad

Final: Dena Kofahi

Doctor: Mohammad Almuhtaseb

00:00

Last lecture, we talked about the development of the larynx, trachea, primary, secondary, and tertiary bronchi. Remember that we said during development the secondary bronchi undergo division in a dichotomous fashion to give off the tertiary bronchi, with 10 on the right and 8 on the left. By the end of the 6th month, approximately 17 generations of subdivisions have formed. Postnatally, an additional 6 divisions occur leaving us with a total of 23 divisions, completing the bronchial tree.

The **bronchioles appear** due to further branching of the segmental bronchi. They are of two types: **terminal bronchioles and respiratory bronchioles**. This marks the beginning of the maturation of the lung, the alveolar ducts, alveolar sacs, and alveoli. *In this sheet, we will be mainly covering the development of the respiratory bronchioles and the lung, in addition to some congenital anomalies of the lung.*

Maturation and development of the lungs

The development of the respiratory bronchioles and the lung is divided into 4 stages.

✓ Stage 1: Pseudo-glandular period

- This period occurs **from weeks 5 to 16 of gestation**, ending approximately halfway through the 4th month.
- The process of branching continues in this stage to result in the formation of conducting airways **(terminal bronchioles) ONLY**. There are ***no*** respiratory bronchioles nor alveoli at this stage.
- The epithelium present at this stage is **simple cuboidal epithelium.**

✓ Stage 2: Canalicular period

- This stage occurs **from weeks 16 to 26**; i.e. approximately up to 6th and a half months of gestation.
- The word "canalicular" is derived from "canaliculi" which refers to alveolar ducts. This helps you remember that in this phase, each terminal bronchiole will divide to form about 2 respiratory bronchioles, and each of those will divide to form 3-6 *alveolar ducts.*

- Important changes that occur during this stage:
  I. The epithelium starts changing into **simple squamous epithelium** *(thin flat cells).*
  II. Vascular supply increases steadily as alveolar capillaries begin to appear *as you can see in the picture.*

→ This means gas exchange **may be possible** at this stage.

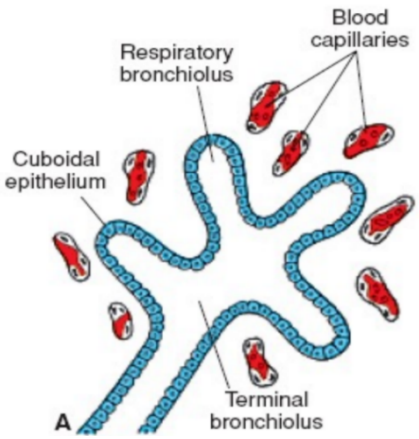

- This brings us to an important question: Can a baby born at this stage survive?

  Yes, because at this stage, simple squamous epithelium would have formed and alveolar capillaries would be present, so gas exchange can happen.

  Many babies are born at the 7th month of pregnancy, which almost corresponds to this stage of development, and they *are able to survive*. Nowadays, due to advanced technology, even a child born at 5.5 months of pregnancy can survive with adequate treatment and support to enhance the development of alveoli and capillaries.

✓ Stage 3: Terminal Sac Period

- This period extends **from the 26th week of pregnancy (approximately 6.5-7th month) until delivery.**
- The term 'terminal sac' refers to the <u>alveolar sacs and alveoli</u>, which are formed at this period from respiratory bronchioles. At this stage, the alveoli are immature and called **terminal sacs or primitive alveoli**.
- Simple squamous epithelial cells are intimately associated (in contact) with numerous blood and lymph capillaries.

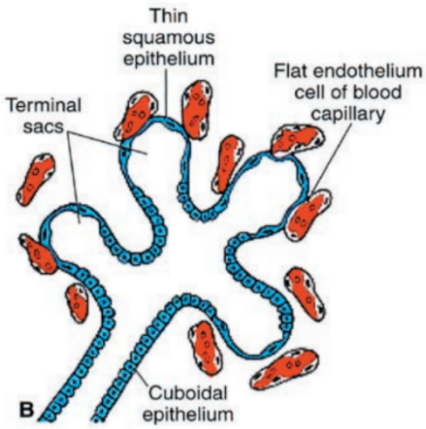

- Due to the close contact that has been established at this point between alveolar capillaries and alveolar sacs, and the fact that thin simple squamous epithelium is the dominant type of epithelium, gas exchange can occur (respiratory membrane starts to form). So, any baby born at 7+ months has normal respiration (*many times, even without the need for medical support*).

Remember: More time passes → closer contact between alveoli and capillaries

✓ Stage 4: Alveolar Period

- This period includes maturation of alveoli and an increase in their number. It starts **at the 8th month of pregnancy and continues through the first 10 years of life after delivery (childhood).**

⇨ This means that almost the entire process of alveolar maturation occurs AFTER delivery.

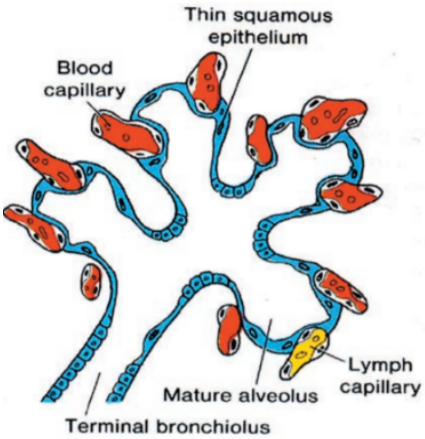

- At this point, the alveolar capillaries have established **complete contact with the alveoli** forming the respiratory membrane *with its multiple layers* or what we can also call the "**blood-air barrier.**" It is formed by the fusion between the endothelial cells of the capillaries and type I alveolar cells lining the alveolar sacs. What allows this close contact to be established is the fact that the type I alveolar cells become *thinner* at this stage to allow the alveolar capillaries to protrude into the alveolar sacs.
- Note that although lymphatic capillaries have started to appear in the previous stage, during the alveolar period they also achieve close contact with the alveolar sacs as seen in the picture.

❖ The table below summarizes what was previously mentioned:

TABLE 12.1 Maturation of the Lungs

Pseudoglandular period	5–16 weeks	Branching has continued to form terminal bronchioles. No respiratory bronchioles or alveoli are present.
Canalicular period	16–26 weeks	Each terminal bronchiole divides into 2 or more respiratory bronchioles, which in turn divide into 3–6 alveolar ducts.
Terminal sac period	26 weeks to birth	Terminal sacs (primitive alveoli) form, and capillaries establish close contact.
Alveolar period	8 months to childhood	Mature alveoli have well-developed epithelial endothelial (capillary) contacts.

❖ Important notes:

- Only one sixth of the total adult alveoli number is present at birth, and as previously mentioned, their maturation continues after birth. What matters most for the growth of the lungs is the increase in **the number** of alveoli and bronchioles, not the increase in size.

- The development of type II alveolar cells (*surfactant producing cells*) starts at the end of the 6th month of pregnancy or the beginning of the 7th month and continues until the 8th month, resulting in a peak in surfactant production in the 9th month of pregnancy; specifically when only **2 weeks** are left for delivery. Remember that lung surfactant reduces the surface tension at the **liquid (water)-air barrier** in the alveolar sacs and increases the compliance of the lungs, making them easy to inflate.

- About the lungs **12:25**

⇨ **Before birth**:

- The lungs are full of fluid that contains high chloride concentration, little protein, some mucus from the bronchial glands, and surfactant from the alveolar epithelial cells (type II).
- Breathing movements start in the fetus causing aspiration of the amniotic fluid. Amniotic fluid is important in the stimulation of further lung development and conditioning of the respiratory muscles to make the baby ready for pulmonary ventilation after delivery.

⇨ **At/After Birth**

- At birth, when respiration begins, the fluid filling the lungs has to be resorbed. This happens by the help of blood and lymphatic capillaries. A small amount of fluid also leaves through the trachea and bronchi during delivery. So now, the baby's lungs are only left with a liquid-air interface at the alveolar sac with the phospholipid surfactant deposited there.

- After birth, the doctor slaps the baby's back or legs to stimulate the skin receptors to send nerve impulses to the respiratory center of the brain → The brain will then respond by sending impulses through the **phrenic nerve** (motor nerve) to stimulate the diaphragm to contract causing the air to gush through the nose to the lungs → the lungs will now have to inflate to start the inspiration process. At that moment, the baby's first cry is heard.

- As we know, the surfactant causes reduced surface tension, which means that we need **less** pressure to keep the alveoli **OPEN**. So, the presence of the surfactant is actually more important for *expiration* than inspiration. The surfactant ensures the alveoli are kept open and prevents them from collapsing even when air is expelled. *This is why when surfactant is missing*, as soon as the baby expires **atelectasis** (collapse) of the alveoli will occur and the next inspiration will be very hard.

Congenital Anomalies

➢ RDS: Respiratory Distress Syndrome 19:00

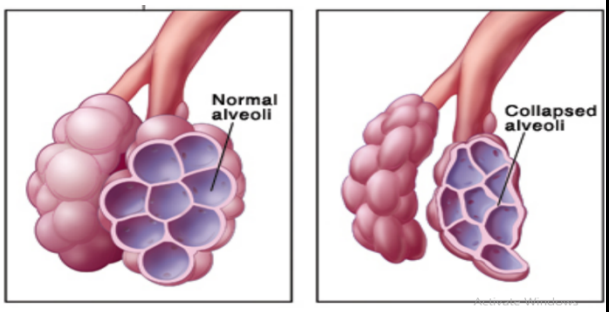

From our previous talk about surfactant, we come to our first congenital anomaly which is the exact consequence of "missing surfactant at birth." In this case, during expiration, the newborn's alveoli will collapse due to loss of compliance and the need for high pressure to overcome the collapsing force of the lung and to keep the alveoli open.

- It is relatively common, accounting for 30% of neonatal diseases and 20% of deaths of newborns.
- Prematurity is one cause of RDS. In premature newborns, insufficient amounts of surfactant are present since the peak of surfactant production occurs at the 9th month of pregnancy.
- A common complication of RDS is **intrauterine asphyxia** (suffocation caused by deprivation of oxygen) which can cause irreversible damage to type II cells. This may make it impossible for the newborn to survive even with treatment.
- Treatment with **glucocorticoids, like betamethasone,** is used to reduce mortality associated with RDS. Glucocorticoids help by stimulating surfactant production. It has also been found that **thyroxine** is the most important stimulator for surfactant production.
  Remember when we said that a premature infant born at 5.5 months can still survive because of treatment and support? This is one of the treatments that help in the survival of those newborns.
- RDS can also be called **hyaline membrane disease** because of the high protein content and lamellar bodies that are probably derived from the surfactant layer.

- Other anomalies: **22:25**
  - Although many abnormalities of the lung and bronchial tree have been found, most of these gross abnormalities are rare.

I. Blind-ending trachea (atresia) with agenesis (absence or imperfect development) of one of the lungs.

II. Abnormal division of the bronchial tree (*more common than no.1*). Some of these result in supernumerary lobes, e.g. 3 or 4 lobes in the left lung instead of 2. These variations of the bronchial tree usually do not have functional significance but may cause unexpected difficulty during bronchoscopy.

III. Ectopic lung lobes: This means that the lung lobes are developing somewhere outside the normal site; probably arising from the trachea or esophagus. This happens by the formation of additional respiratory buds of the foregut that develop independently of the main respiratory system.

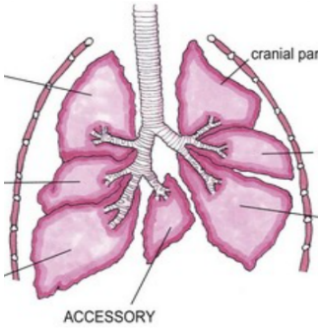

IV. Congenital cysts of the lung: *The most important clinically*.
These occur due to the dilation of terminal or larger bronchi. They could be small and multiple, giving the lung a **honeycomb** appearance on radiograph (x-ray, ultrasound scans...). Cysts can also be larger and/or singular (*uni-cyst*). One important complication is chronic infections because cystic structures of the lung drain poorly.

V. Lung Hypoplasia: Reduced lung volume i.e. smaller sized lung(s).
They are characterized of being associated with **Congenital Diaphragmatic Hernia (CDH)** which is an opening in the diaphragm that allows abdominal organs to move into the chest and compress the lung.

CDH is more common on the left side.

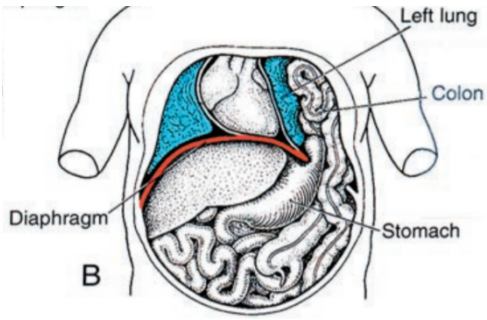

Most infants with lung hypoplasia die because of pulmonary insufficiency as their lungs are too hypo-plastic. This mainly depends on whether the other lung can compensate or not.

Note: This condition can be treated.

VI. **Oligohydramnios**: Reduced amount of amniotic fluid.
Remember that the amniotic fluid plays a very important role in the development of the lung, so if it is decreases, ***severe pulmonary hypoplasia*** will take place.

❖ Lastly, how can we tell if a newborn died after delivery, or if it was stillborn? **26:50**

We take a sample of the lung tissue and place it in water. If it **floats**, it means the lungs are healthy and fresh and the baby died **after delivery**. If it **sinks**, it means no air was present in the lungs at all and the baby did not take his first breath, so it was **stillborn**.

THE END