BLOOD SUPPLY
VENOUS DRINAGE
INNERVATION
CONDUCTING SYSTEM

OF THE HEART

EDITED BY: TASNIM AL-GHARABLI
CORRECTED BY: MAHA ALYASEEN

Anything written in **BLUE** is added by the doctor during the lecture.

THE BLOOD SUPPLY OF THE HEART

Coronary Collateral Circulation

The branches of the coronary arteries (main blood supply to the heart) are generally considered to be

Functional End arteries!!!!!

arteries that supply regions of the myocardium
lacking sufficient anastomoses
(this lack is unique about the blood supply of the heart)
from other large branches to maintain viability of the tissue should occlusion occur

Anastomosis is when numerous arteries supply an area of an organ so if occlusion happens to one area another blood supply would take over, especially around shoulder joints (joints) and internal organs in the body

However

Some Anastomoses do exist

Which artery is larger?

- **The calibre of coronary arteries**, both main stems and larger branches, based on measurements of arterial casts or angiograms, ranges between 1.5 and 5.5 mm for the coronary arteries at their origins.
- **The left exceed the right** (is larger than the right) **in 60%** of hearts, **the right being larger in 17%**, and both vessels being approximately equal in 23%.
  - The diameters of the coronary arteries may **increase up to the 30th year**

BLOOD SUPPLY OF THE HEART

from two coronary arteries

The two arteries, as indicated by their name, form an oblique inverted crown, in which an anastomotic circle in the atrioventricular groove is connected by marginal and interventricular (descending) loops intersecting at the cardiac apex

Anastomosis is not common, but it do exist. The coronary arteries make a circle around the heart, which is the best way. From this circle the arteries approach each other in most cases.

The right coronary artery (RCA)

The left coronary artery (LCA)

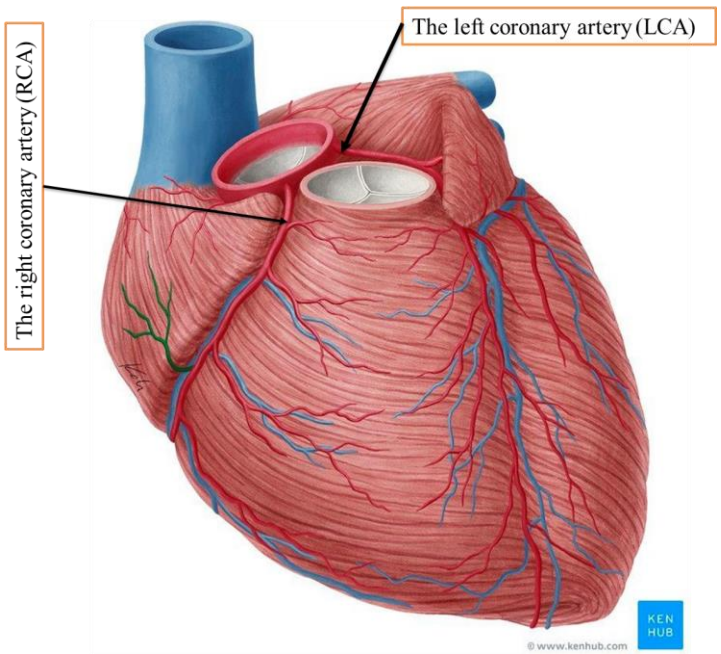

THE 2 ARTERIES ARE NOT THE ONLY WAY TO SUPPLY THE HEART

The endocardium (very thin layer of endothelium,lines the heart) and some subendocardial tissue located immediately external to the endocardium receive oxygen and nutrients by diffusion or microvasculature directly ***from the chambers of the heart***

THE AORTIC VALVE

consists of three semilunar cusps

Posterior (non-coronary) cusp
Right
Left

Just superior to right and left cusps in the Sinus of **Valsalva** are the openings of the right and left coronary arteries, respectively

THE CORONARY ARTERIES HAVE COMMON ORIGIN →
ASCENDING AORTA

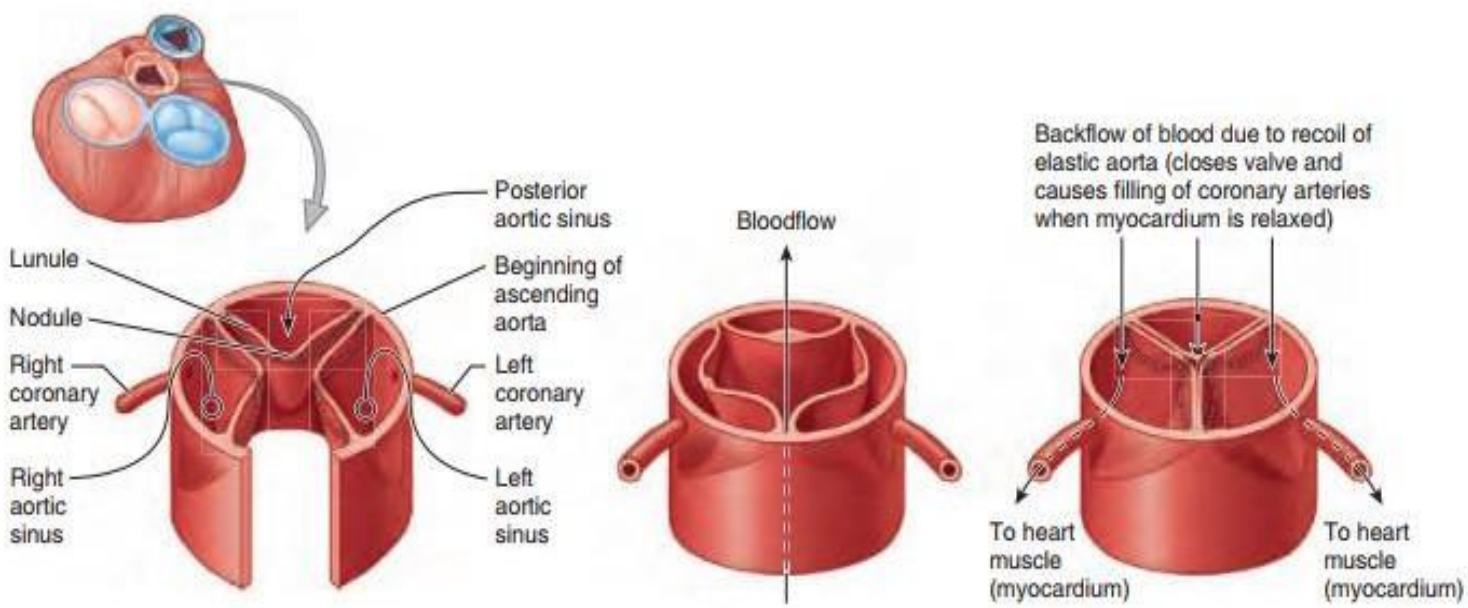

(A) Anterior view of aortic valve (B) Valve open (C) Valve closed

no artery arises from the posterior aortic **(noncoronary) sinus**

The mouth of the right coronary artery is in the right aortic sinus;

the mouth of the left coronary artery is in the left aortic sinus

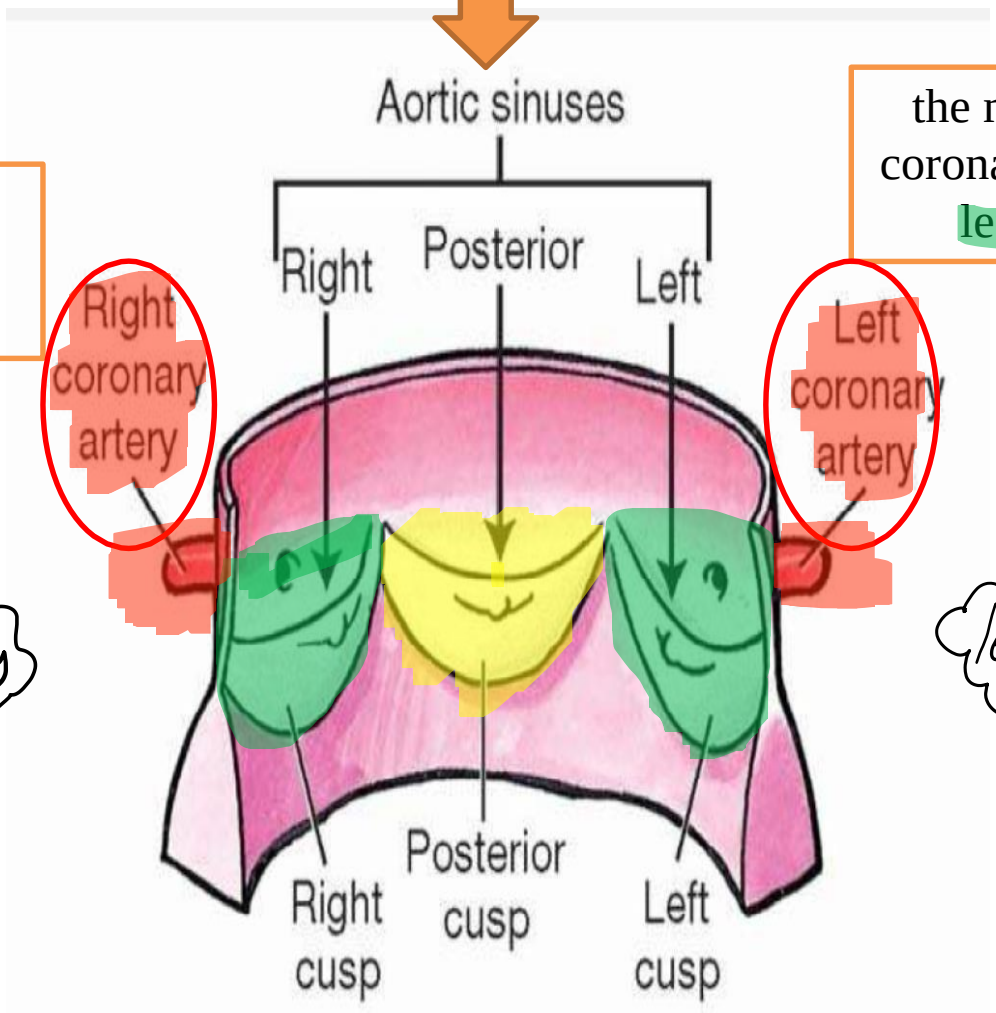

right sinus – right artery

left sinus – left artery

THE LEFT CORONARY ARTERY (LCA)

originates from: **The left sinus of Valsalva (the left aortic sinus) of the ascending aorta**

Passes between: **the left auricle** and **the left side of the pulmonary trunk**

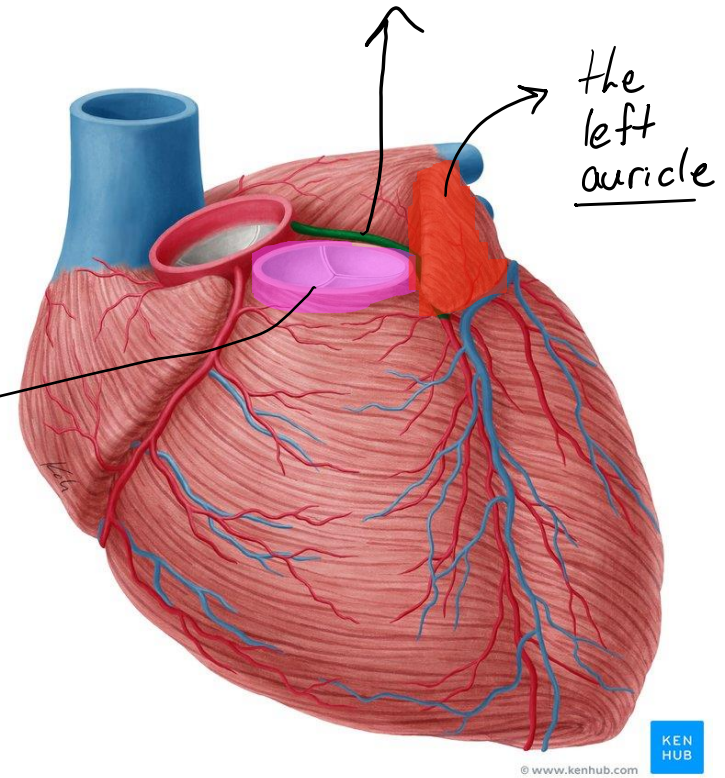

LCA is very short and divides immediately

The LCA usually has a short (0.5-2 cm) (the length depends on where it divides), common stem that

compared to Right Carotid

travels a short course between the left aurcle and ventricle, and divides into 2 branches: **anterior interventricular or left anterior descending (LAD) artery** and **circumflex artery.**

1 2

we rather say left side of pulmonary trunk

3 *

left diagonal artery, may arise directly from the trunk of the left coronary artery

1-THE ANTERIOR INTERVENTRICULAR or LEFTANTERIOR DESCENDING (LAD)

- Runs downward in the anterior interventricular groove to the apex of the heart
- In most individuals it then passes **around the apex of the heart to enter the posterior interventricular groove** and **anastomoses with the terminal branches of the right coronary artery.**

(LAD anastomose with PAD)

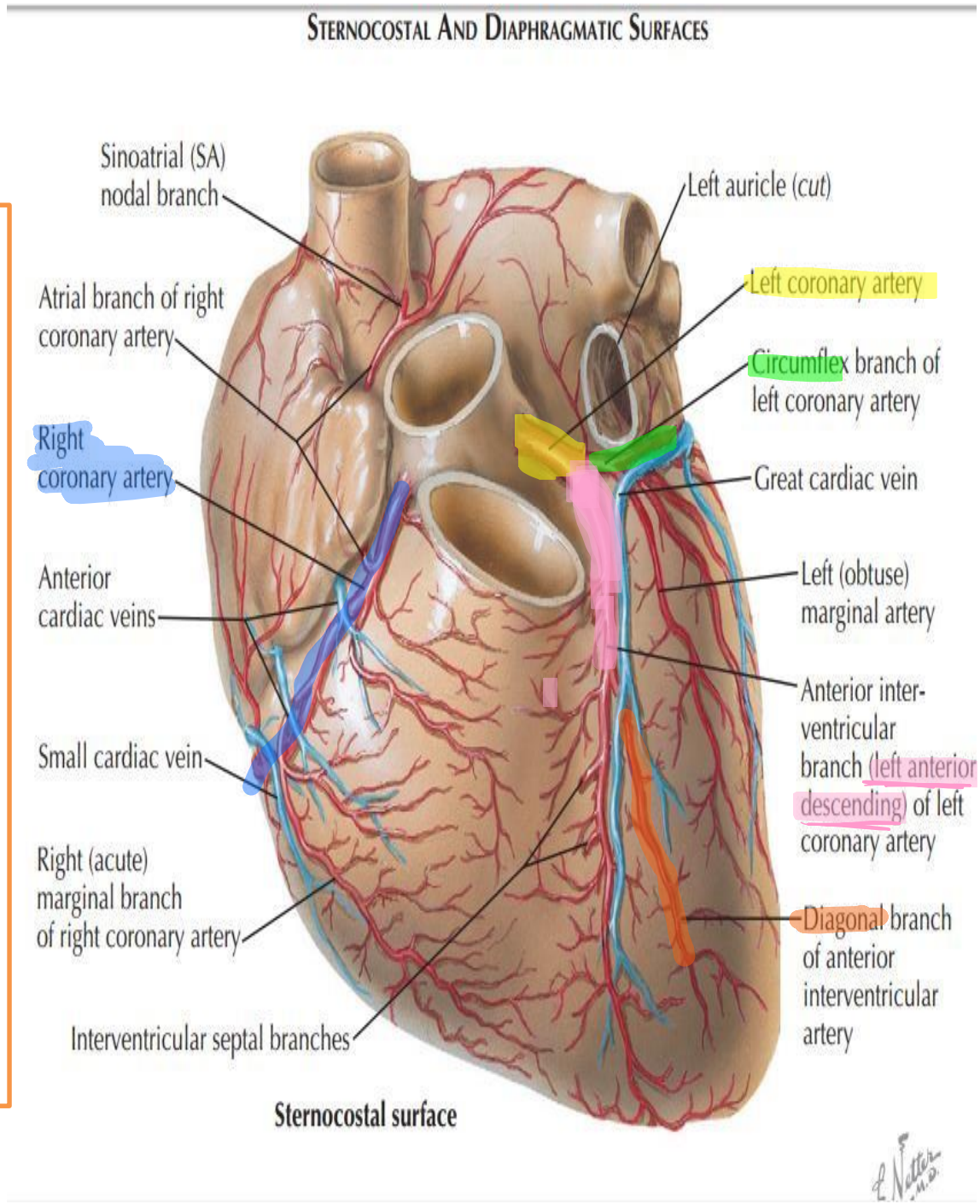

In one third of individuals it ends at the apex of the heart (it is much better to have anastomoses, but nothing would be wrong with the heart if there is no anastomoses, maybe other anastomoses would be there to replace it)

Clinical Correlate

In myocardial infarction, the left anterior descending artery is obstructed in 50% of cases, the right coronary in 30%, and the circumflex artery in 20% of cases.

LAD is the most common artery to be affected in **MYOCARDIAL INFARCTION**

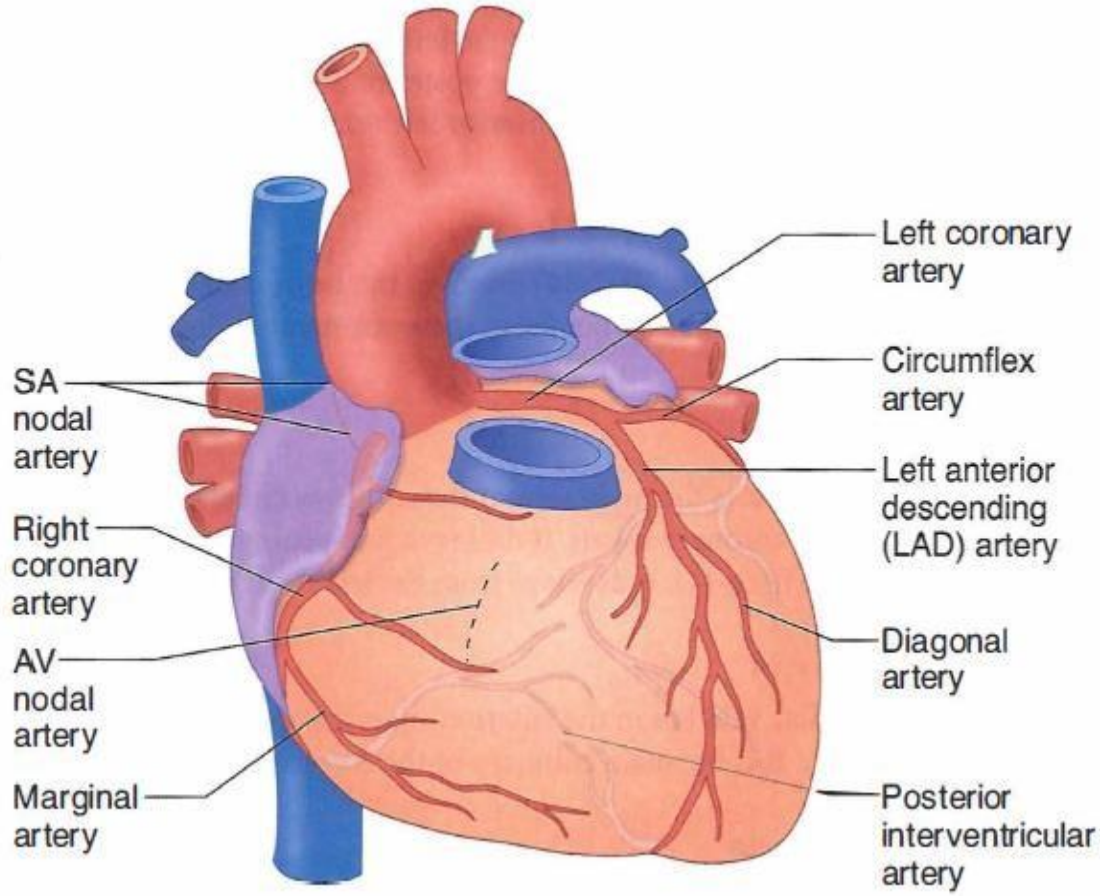

Supplies (1) anterior left ventricle wall, (2) anterior two-thirds of the interventricular septum, (3) bundle of His, and (4) apex. The LAD is the most common site of coronary occlusion.

2-THE CIRCUMFLEX ARTERY

- It is the same size as the anterior interventricular artery
- It winds around the left margin of the heart in the *atrioventricular groove*

VERY IMPORTANT

L coronary A→ its name doesn't mean that its running in the coronary sulcus.

LAD→ anterior interventricular sulcus

Circumflex → coronary sulcus

- **A left marginal artery** is a large branch that supplies the left margin of the left ventricle down to the apex.
- **Anterior ventricular and posterior ventricular** branches supply the left ventricle.
- **Atrial branches supply the left atrium**

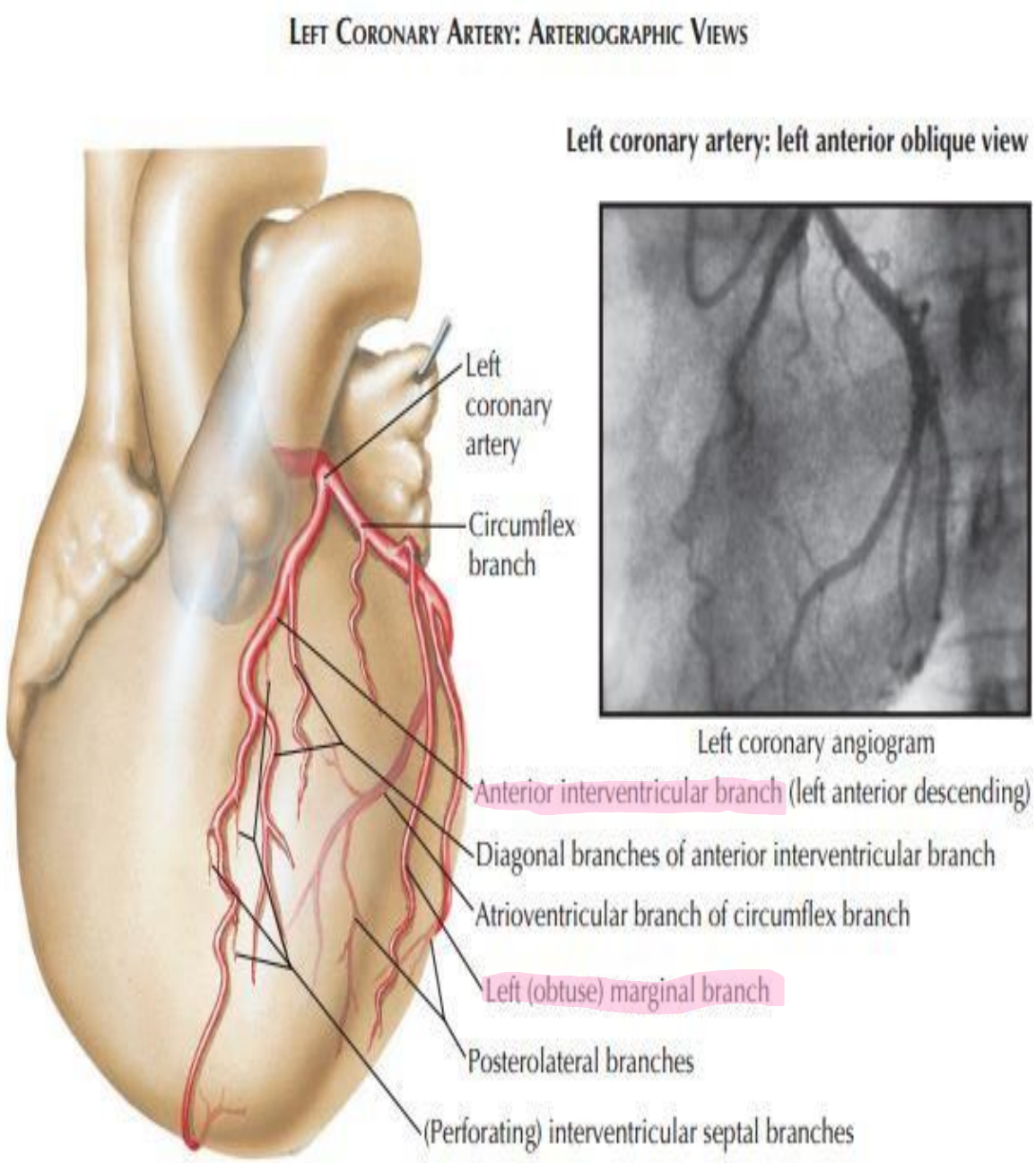

Sternocostal And Diaphragmatic Surfaces

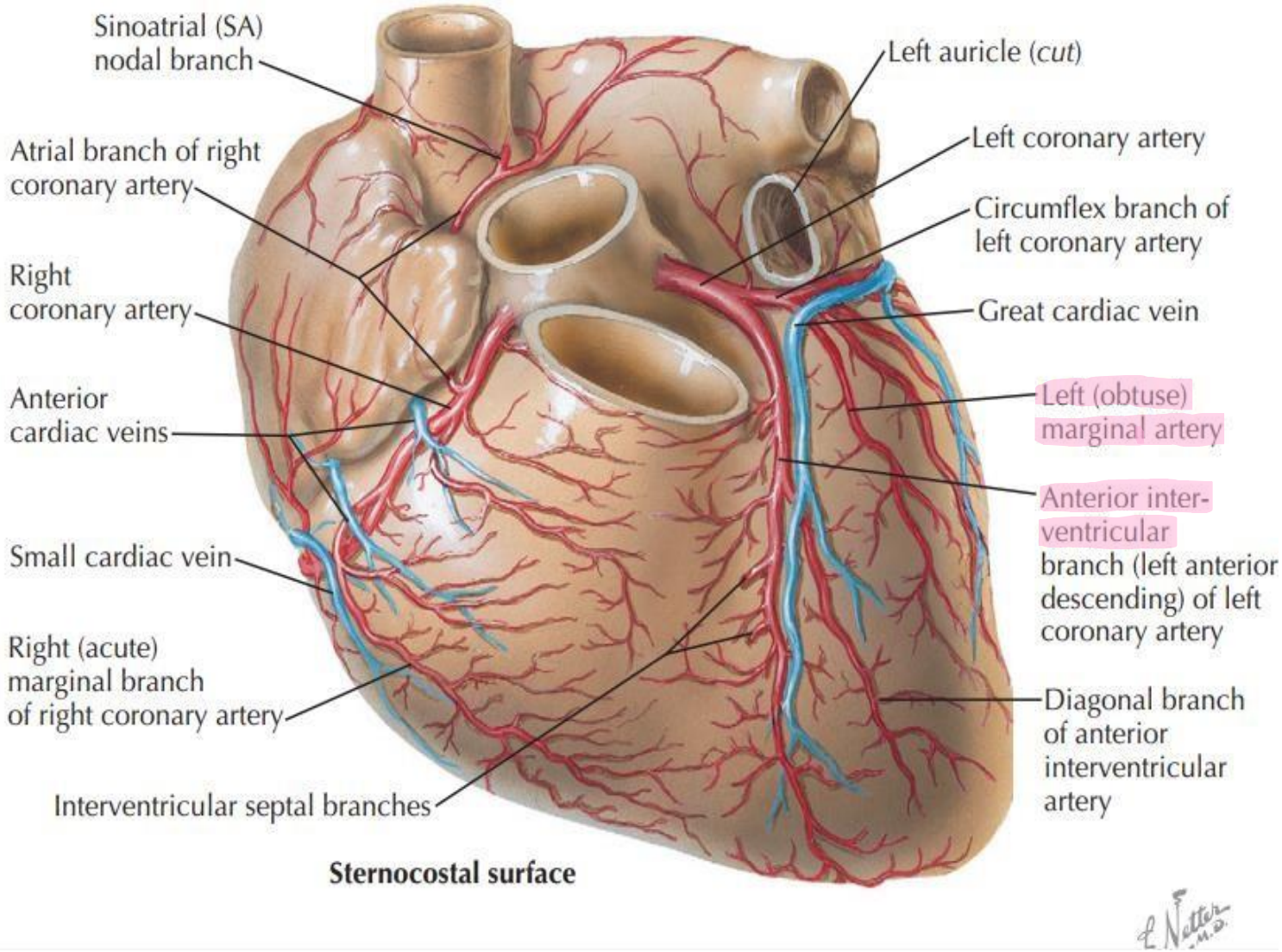

Sternocostal surface

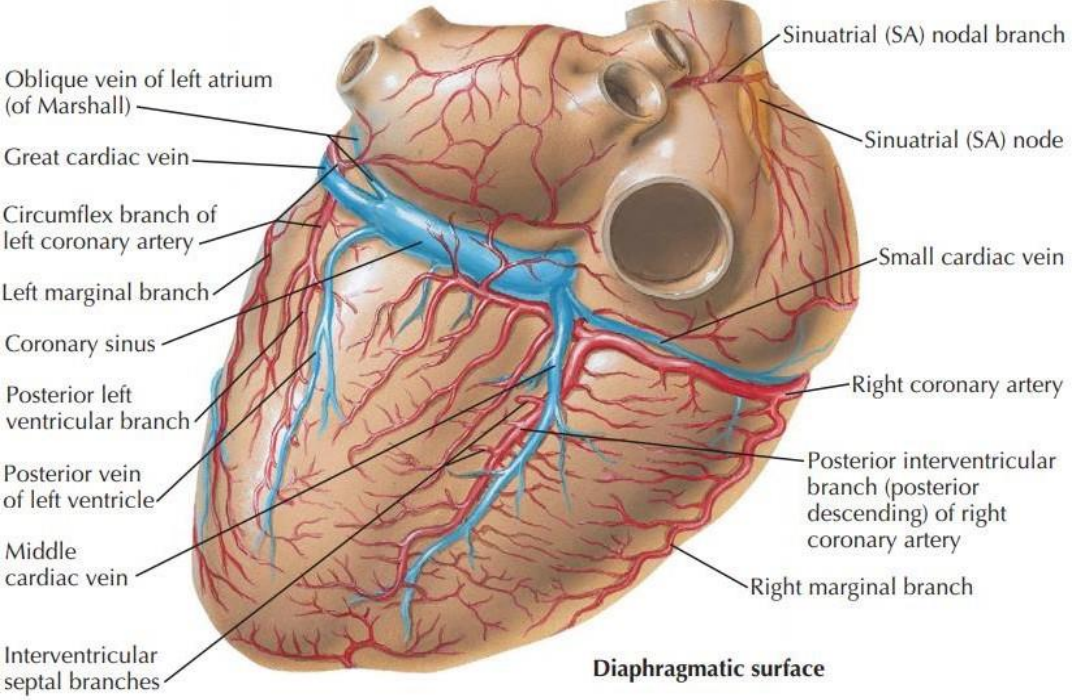

Summary of the Overall Arterial Supply to the Heart from the LCA

The left coronary artery supplies:

most of the left ventricle,

a small area of the right ventricle to the right of the interventricular groove,

the anterior two thirds of the ventricular septum

, **most of the left atrium,**

the RBB Right and left bundle branches

and the LBB

* EXTRA picture was not added by the doctor

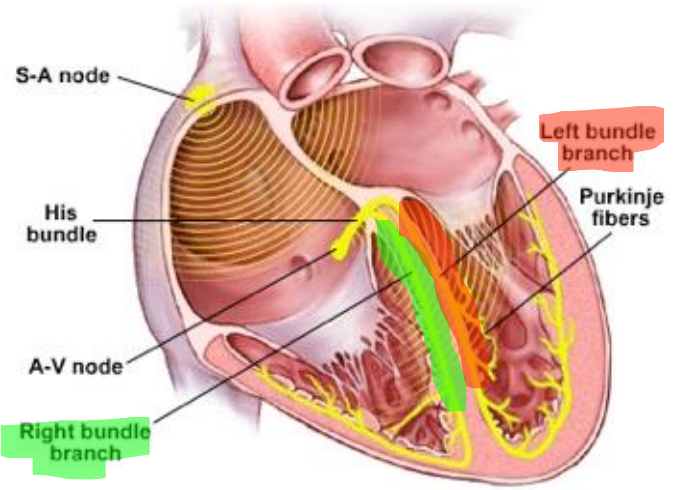

THE RIGHT CORONARY ARTERY (RCA)

arises from **The right anterior sinus of Valsalva** of the aorta and runs along the right AV sulcus, → another name for the coronary sulcus
embedded in fat.

The branches of the right coronary include the following:

- **Sinoatrial (SA) nodal artery:** One of the first branches of the right coronary, it encircles the base of the superior vena cava to supply the **SA node**.
- **Atrioventricular (AV) nodal artery:** It arises from the distal end of the right coronary artery as it forms the posterior interventricular artery and penetrates the interatrial septum to supply the **AV node**.
- **Posterior interventricular artery:** It is the terminal distribution of the right coronary artery and courses in the posterior interventricular sulcus to supply parts of the right and left ventricles and, importantly, **the posterior third** of the interventricular septum.

Summary of the Overall Arterial Supply to the Heart from the RCA

in Most Individuals The **RIGHT** coronary artery supplies

1. **all the right ventricle (except for the small area to the right of the anterior interventricular groove),**
2. the variable part of the diaphragmatic surface of the left ventricle,
3. the posteroinferior third of the ventricular septum,
4. the right atrium and part of the left atrium,
5. and the sinoatrial node and the atrioventricular node and bundle. (occlusion of the RCA may result in damage to the AV node especially→ may cause huge damage to the heart)
6. **The LBB also receives small branches.**

Left Coronary Artery, supply:

1. Left ventricle
2. A 2/3 of interventricular septum
3. Left auricle
4. Apex of the heart

→ So we can assume that the LCA is almost responsible for the left chambers of the heart; it supplies the pump of the heart.

→ And that's why LCA branches are more affected than RCA branches

Overall important notes:

LCA → is larger and the most to get affected and responsible for the main pump of the heart

RCA → is the one that is engaged in blood supply of the conducting system.

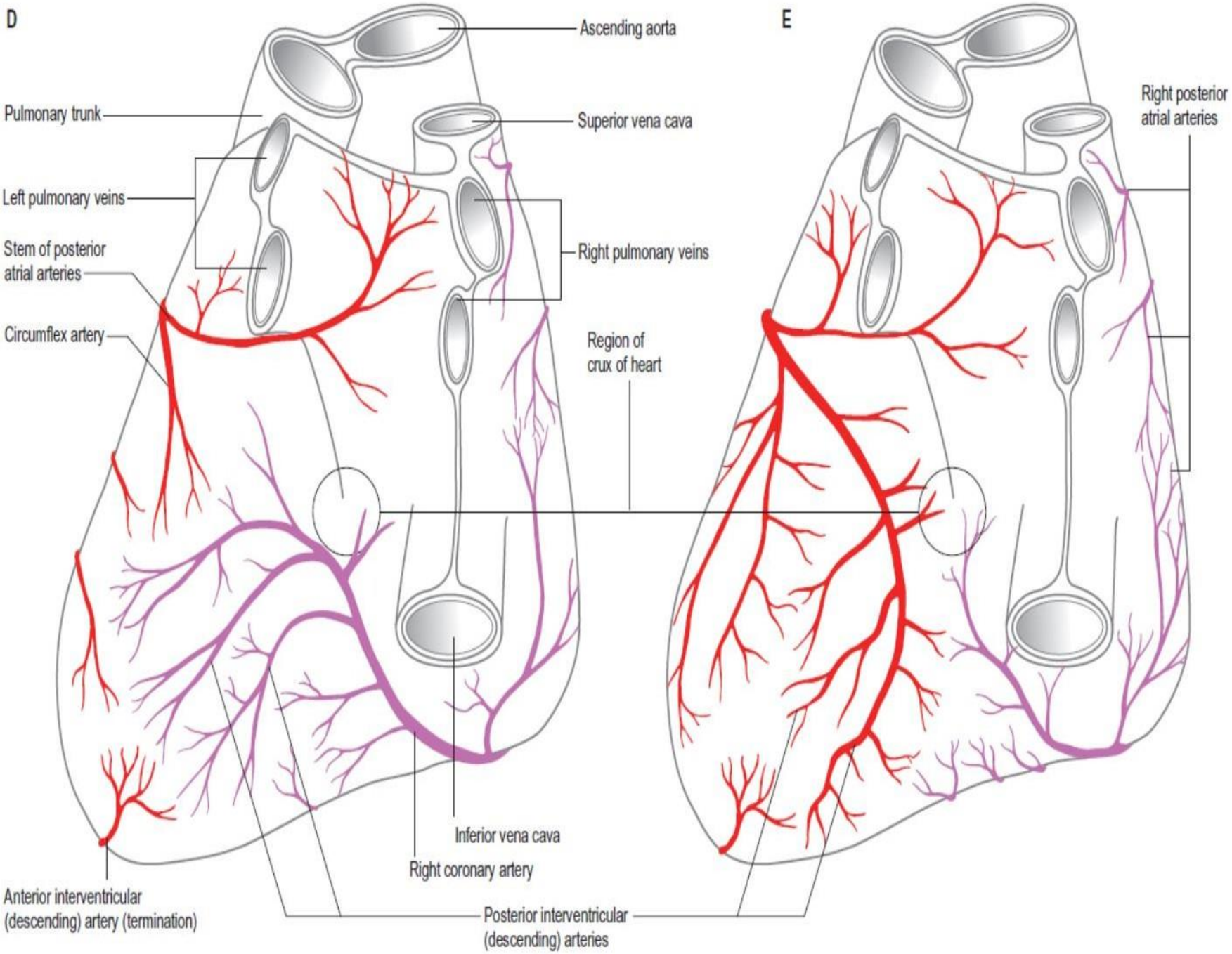
D
E
Ascending aorta
Pulmonary trunk
Superior vena cava
Left pulmonary veins
Right pulmonary veins
Stem of posterior atrial arteries
Circumflex artery
Region of crux of heart
Right posterior atrial arteries
Inferior vena cava
Right coronary artery
Anterior interventricular (descending) artery (termination)
Posterior interventricular (descending) arteries

ARTERIAL SUPPLY TO THE CONDUCTING SYSTEM

1-The sinuatrial node is usually supplied by the right but sometimes by the left coronary artery.

60% → FROM RCA

40% → FROM CIRCUMFLEX (BRANCH OF LCA)

From the RCA near its origin (in 60%)

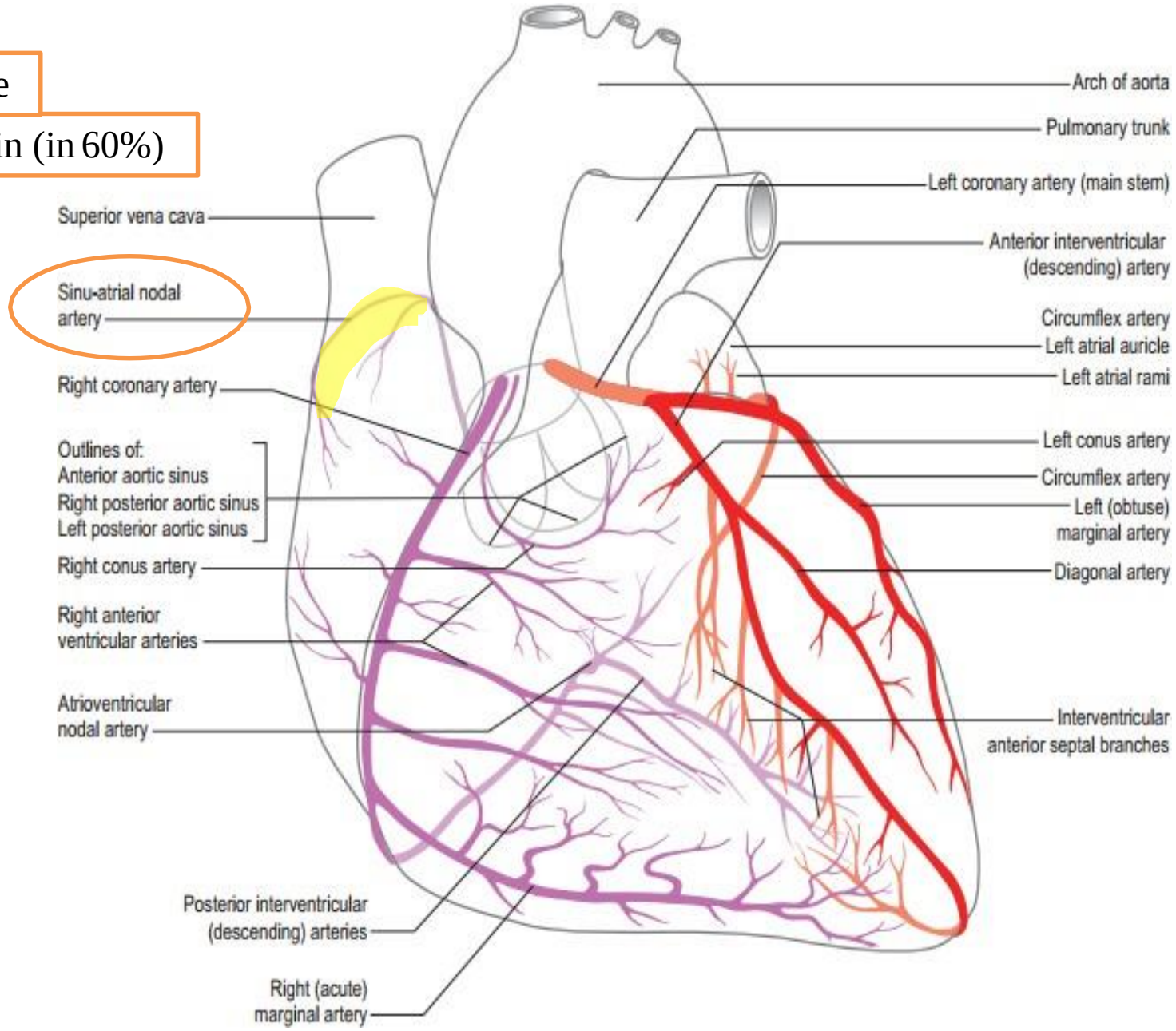

from

Circumflex branch of LCA
(in 40%)

A common variation in the origin of the sinoatrial nodal artery.

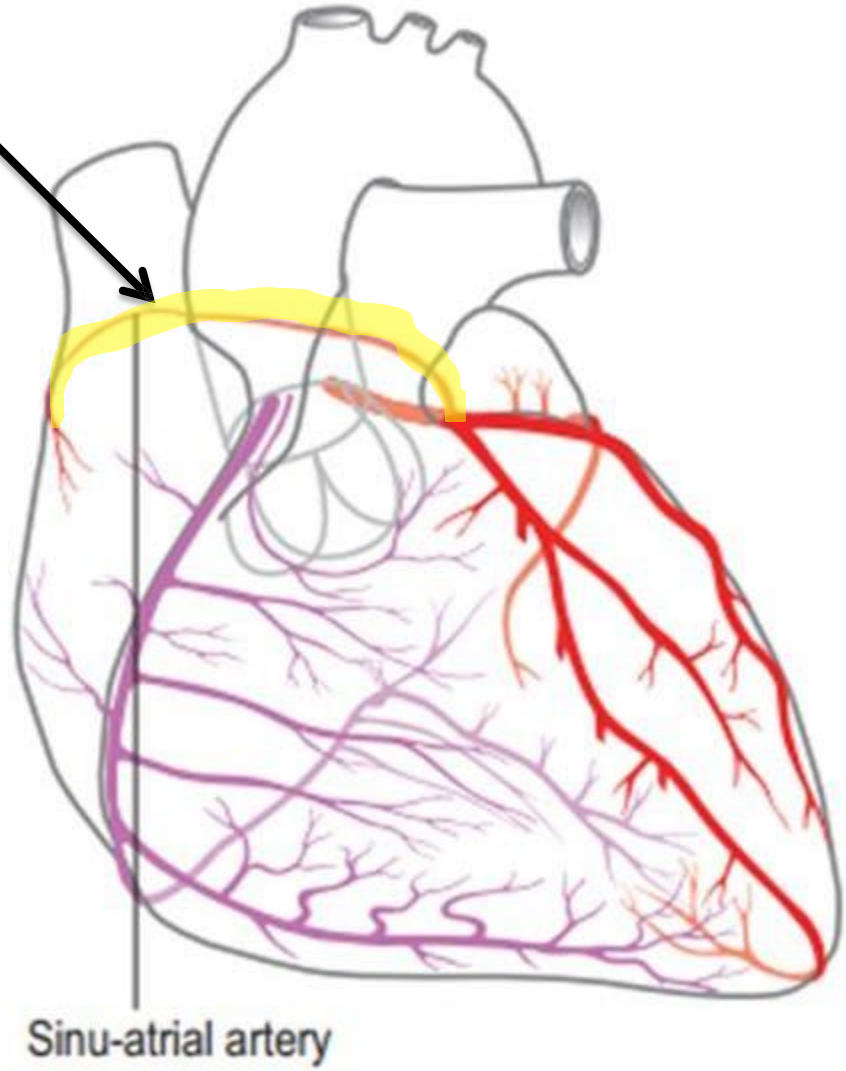

For the circumflex branch to supply the SA node it must travel a long distance from its origin to reach the RA where the SA is.

Sometimes surgeons need to cut through this artery which leads to damage to the SA node.

2-The **atrioventricular node** and the **atrioventricular bundle** are supplied by

THE RIGHT CORONARY ARTERY

3-The **RBB** of the atrioventricular bundle is supplied by

the left coronary artery

4-the **LBB** is supplied by

the right and left coronary arteries

* Summary of blood supply to conducting sys.

- SA → 60% RCA – 40% LCA
- AV → RCA
- RBB → LCA
- LBB → RCA + LCA

VARIATIONS IN THE CORONARY ARTERIES

The most common variations affect the blood supply to the diaphragmatic surface of both ventricles

the origin, size, and distribution of the **Posterior Interventricular Artery** **Can be** *variable*

In right dominance, the posterior interventricular artery is a large branch of the right coronary artery. Right dominance is present in most individuals (90%).

Right dominance

In left dominance the posterior interventricular artery is a branch of the circumflex branch of the left coronary artery (10%).

Left dominance

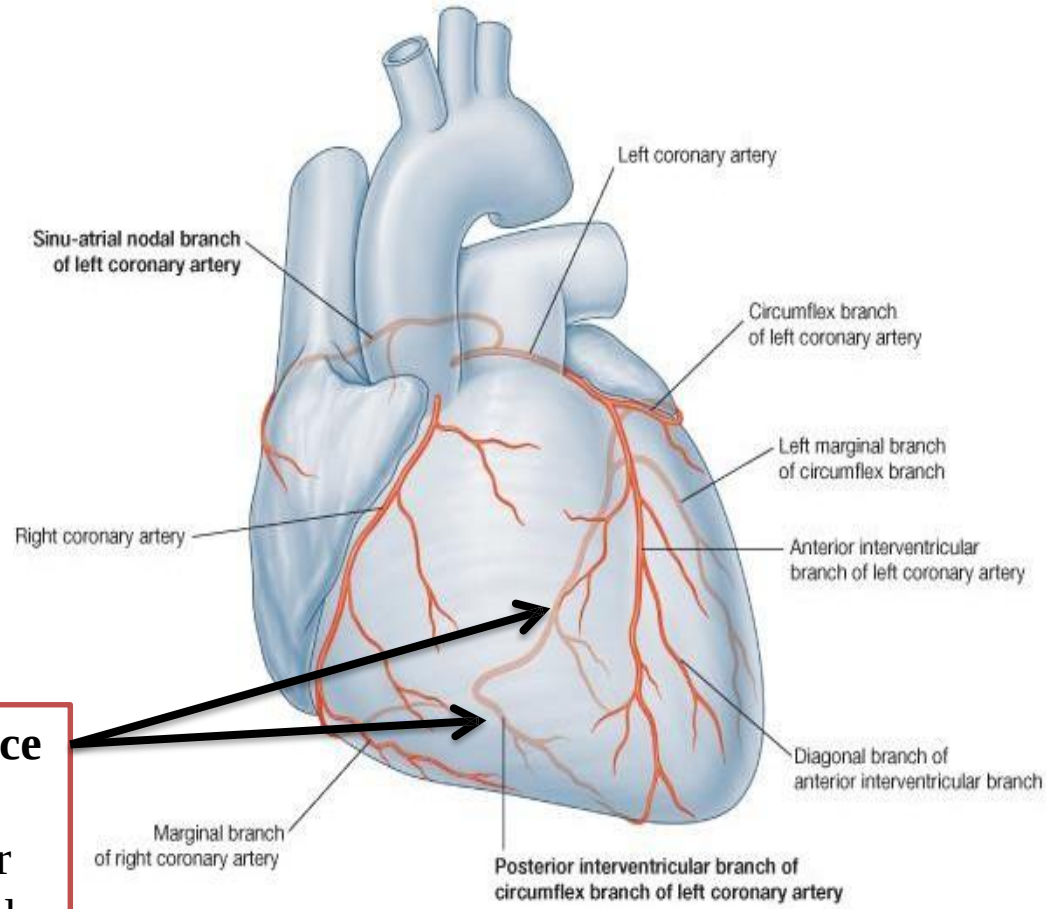

The term 'dominant' is used to refer to the coronary artery giving off the posterior interventricular (descending) branch

In other statistics the **POSTERIOR INTERVENTRICULAR ARTERY** is:

80% → a branch of RCA

10% → a branch of circumflex

10% → balanced (from LCA + RCA)

In the so-called **'balanced' pattern**, branches of both arteries run in or near the posterior interventricular groove

The term ‘dominant
Is misleading

Because even if the posterior interventricular artery is coming in 10% of cases from LCA→ THAT DOESN’T MEAN THAT ITS LESS IMPORTANT

because the left artery almost always supplies a greater volume of tissue (MORE MYOCARDIUM) than the right.

But not only, and why is the origin of this artery that important?
because the AV node is usually supplied by a branch of the RCA, so if it comes from the circumflex (branch of LCA) and it gets occluded the AV node will also suffer), and any complication in AV node will have a great in fluence on heart pumping activity which may lead to death.

SO DOMINANCE IS ALL ABOUT WICH ARTERY SUPPLY THE AV NODE

The most important to know about this slide is the impotence of the blood supply to the heart, and its one of the major causes leading to death, so every peace of information should be considered for its clinical value.

intra- and inter-coronary anastomoses in vessels up to 100–200 μm in calibre.

Read only

The most frequent sites of extramural anastomoses **are:**
The apex
The anterior aspect of the right ventricle
The posterior aspect of the left ventricle
Interatrial and interventricular grooves
Between the sinoatrial nodal and other atrial vessels

The functional value of such anastomoses must vary, but they appear to become more effective in ***slowly progressive pathological conditions***.

Extracardiac anastomoses
May connect **various coronary branches** with other thoracic vessels **via the pericardial arteries** and **arterial vasa vasora of vessels** which link the heart ***with the systemic and pulmonary circulations.***

The effectiveness of these connections as collateral routes in coronary occlusion is unpredictable
(we can't deny that they are there, but we can't tell if their existence can prevent occlusion or give the patient more anastomosis, or more blood

Coronary arteriovenous anastomoses and numerous connections between the coronary circulation and cardiac cavities, producing so-called ‘myocardial sinusoids’ and ‘arterioluminal’ vessels, have been reported; their importance in coronary disease is uncertain

THE VENOUS DRAINAGE OF THE HEART

VENOUS DRAINAGE OF THE HEART

Don't forget that the heart is a muscle so not every artery is uncombined by a vein that has the same name

Venous Drainage of the Heart

The major cardiac veins draining the heart course in the sulci and accompany the arteries but do not carry the same names. The major veins are the following:

- **Coronary sinus**

  The coronary sinus is the main vein of the coronary circulation; it lies in the posterior coronary sulcus. It drains to an opening in the right atrium It develops from the **left sinus venosus.**

- **Great cardiac vein**

  The great cardiac vein lies in the anterior interventricular sulcus with the LAD artery. It is the main tributary of the coronary sinus.

- **Middle cardiac vein**

  The middle cardiac vein lies in the posterior interventricular sulcus with the posterior interventricular artery. It joins the coronary sinus.

- **Venae cordis minimae (thebesian veins) and anterior cardiac veins**

  The venae cordis minimae and anterior cardiac veins open directly to the chambers of the heart.

Venous Drainage of the Heart

Most !blood from the heart wall drains into the right atrium through ***THE CORONARY SINUS*** which lies in the posterior part of the atrioventricular groove

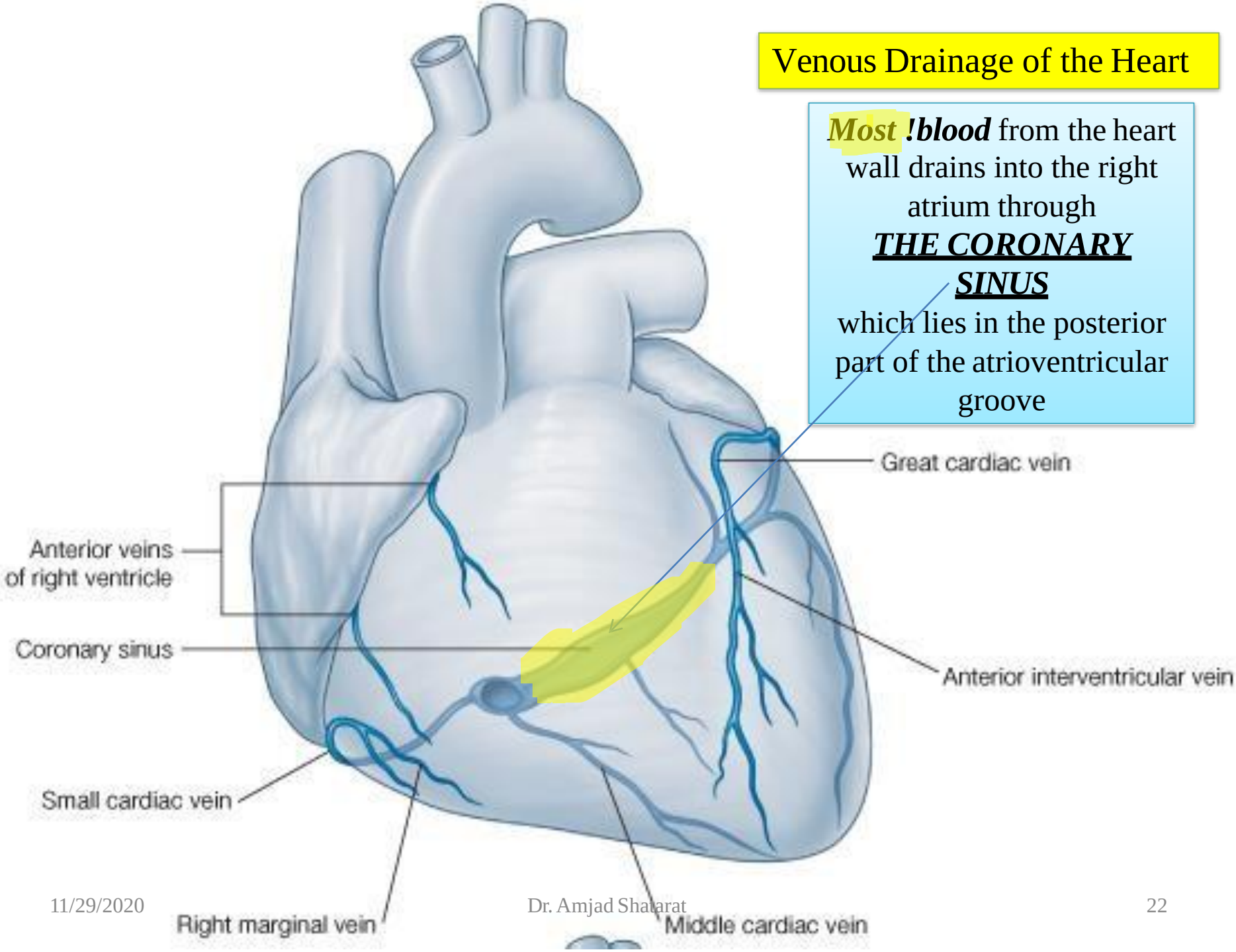

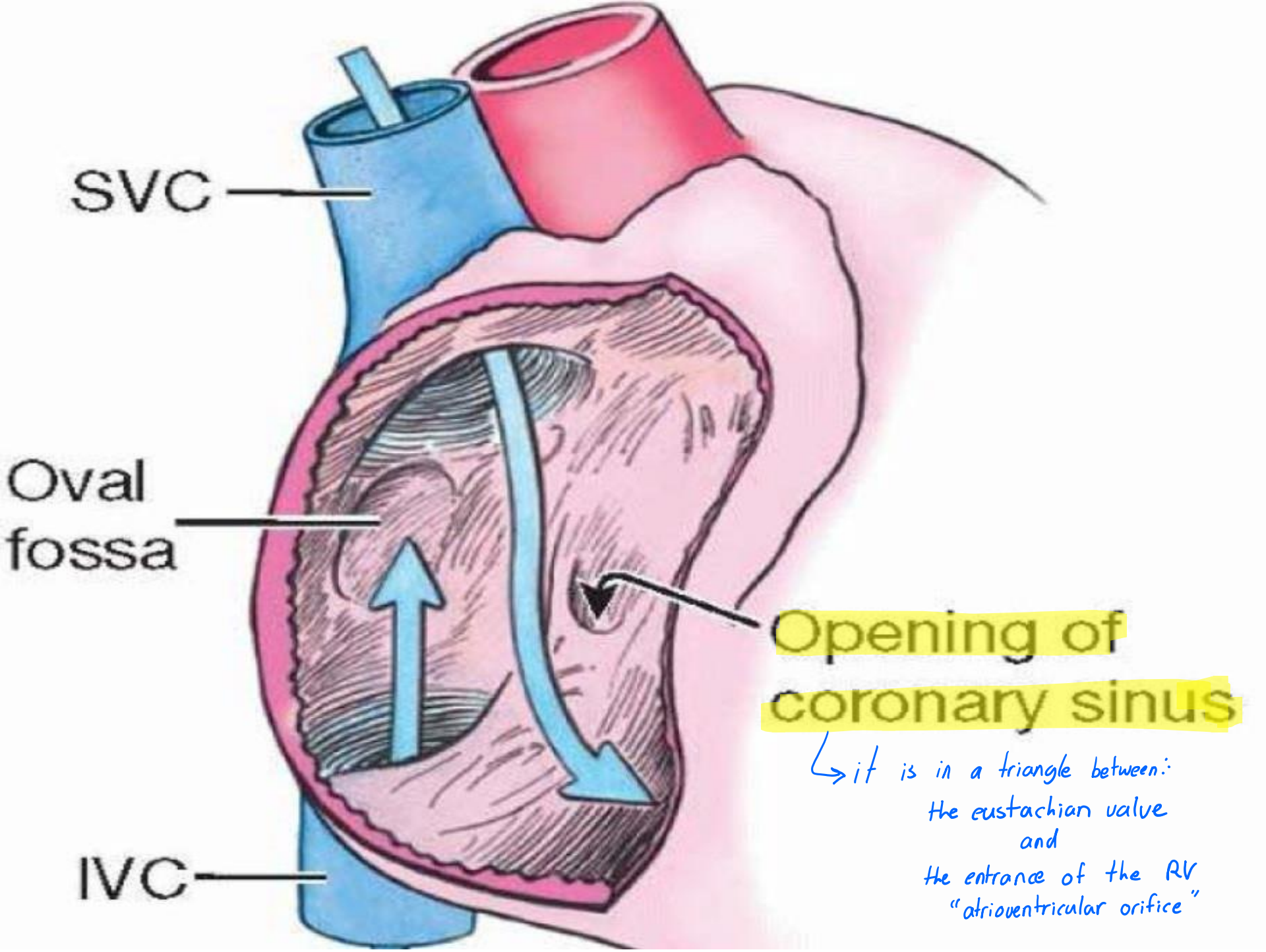

↳ it is in a triangle between:
the eustachian valve
and
the entrance of the RV
"atrioventricular orifice"

tributaries of the coronary sinus.

GREAT CARDIAC VEIN
SMALL CARDIAC VEINS
MIDDLE CARDIAC VEINS

↳ all open into the coronary sinus.

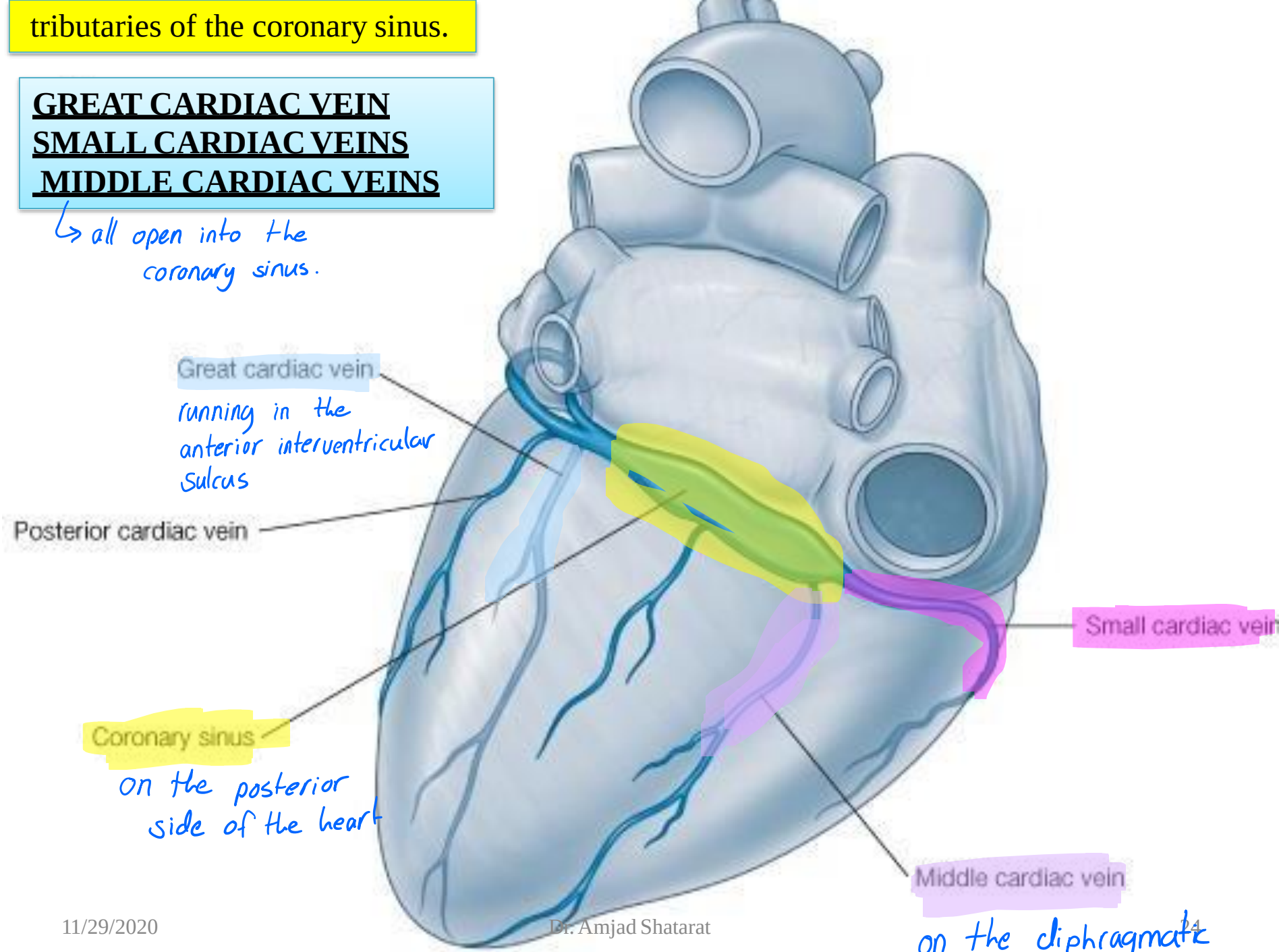

Here you can see an occlusion of the coronary arteries and their branches.

and here after embedding an angioplasty with a balloon that restores the diameter and the blood flow to normal state.

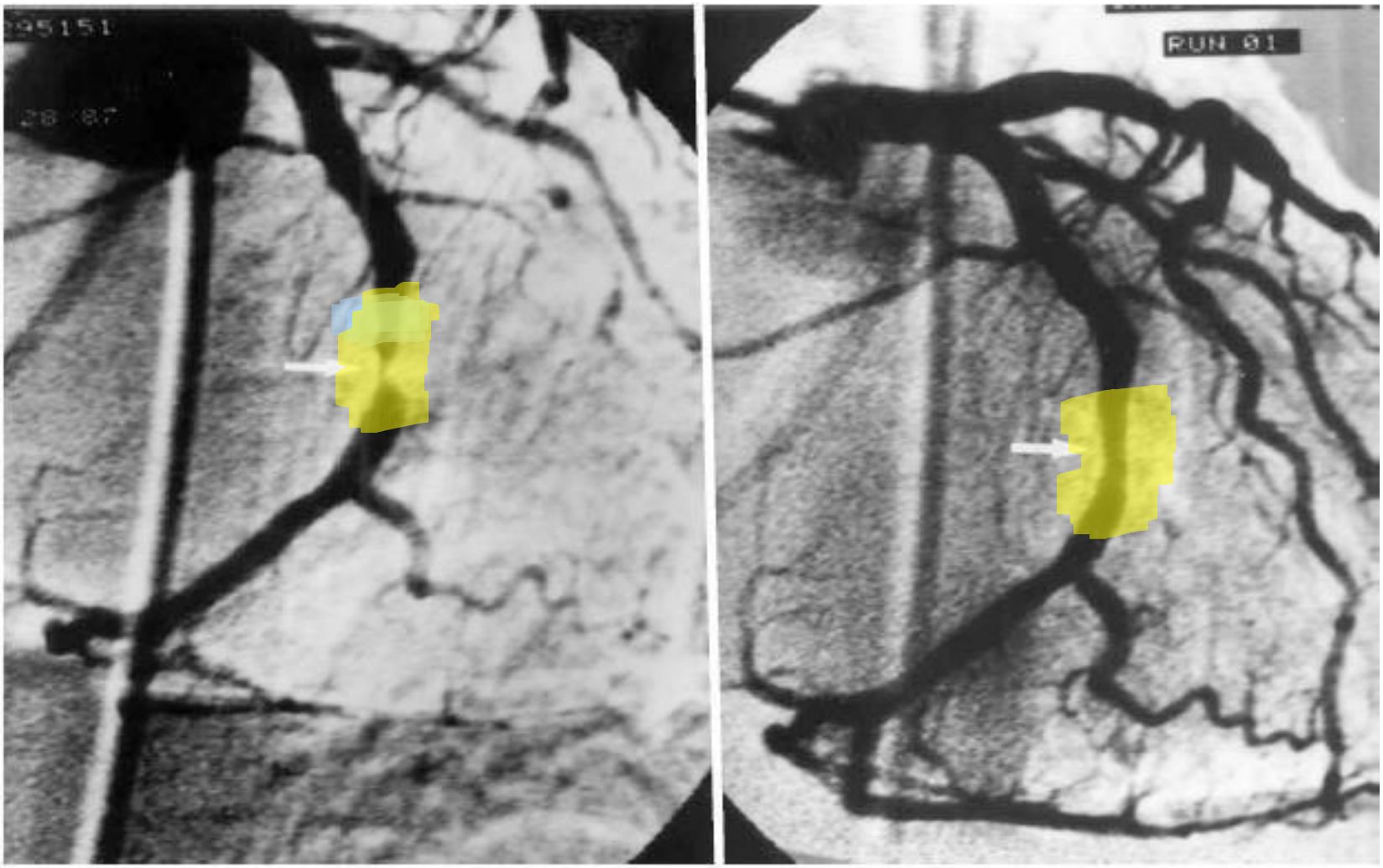

A B

CD Figure 4-1 Coronary angiograms. **A.** An area of extreme narrowing of the circumflex branch of the left coronary artery (white arrow). **B.** The same artery after percutaneous transluminal coronary angioplasty. Inflation of the luminal balloon has dramatically improved the area of stenosis (white arrow).

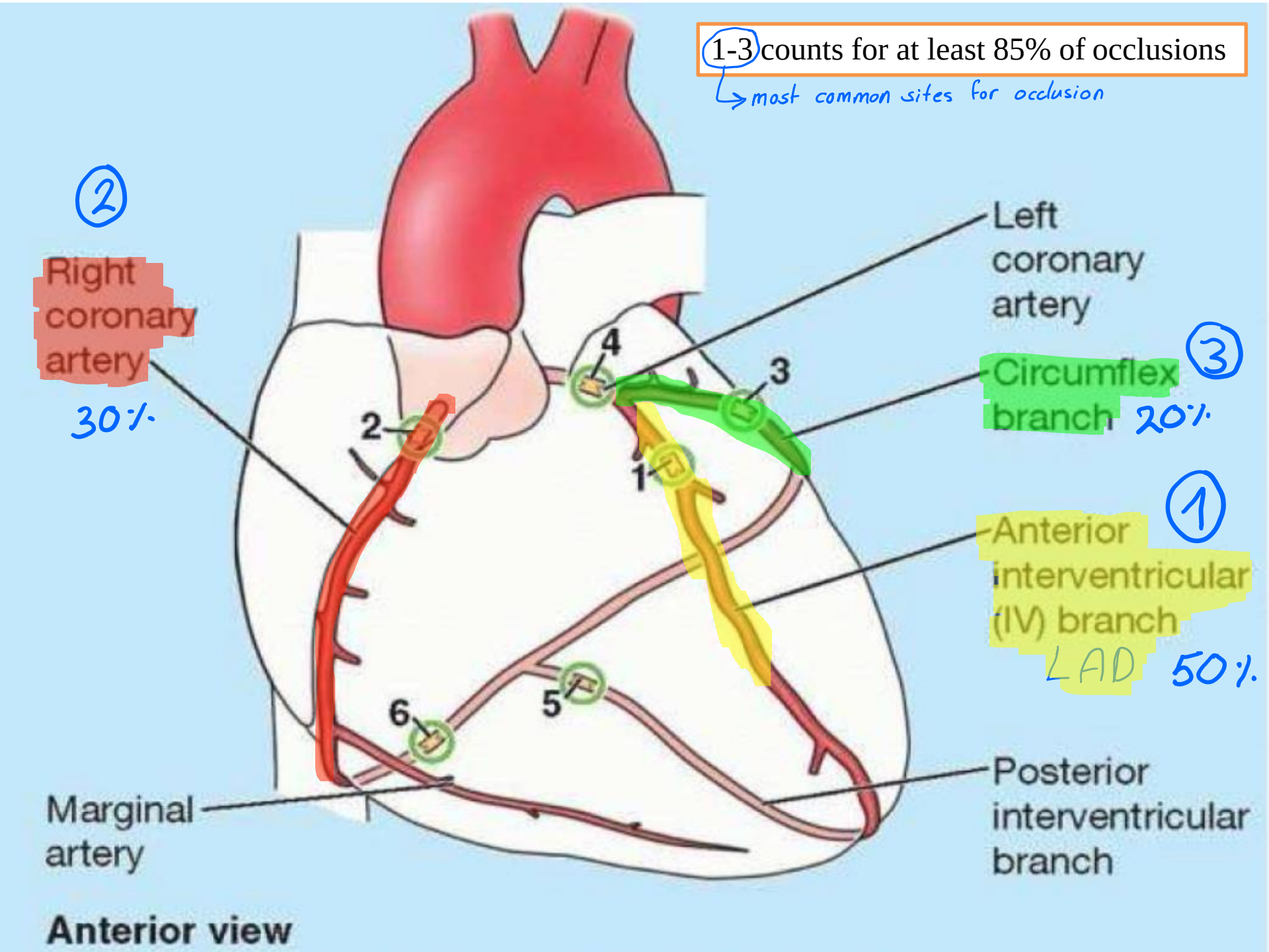

Percentages could vary among populations.
The doctor said he will not ask about the percentages, but he will ask about the names and order of these arteries in occlusion formation.

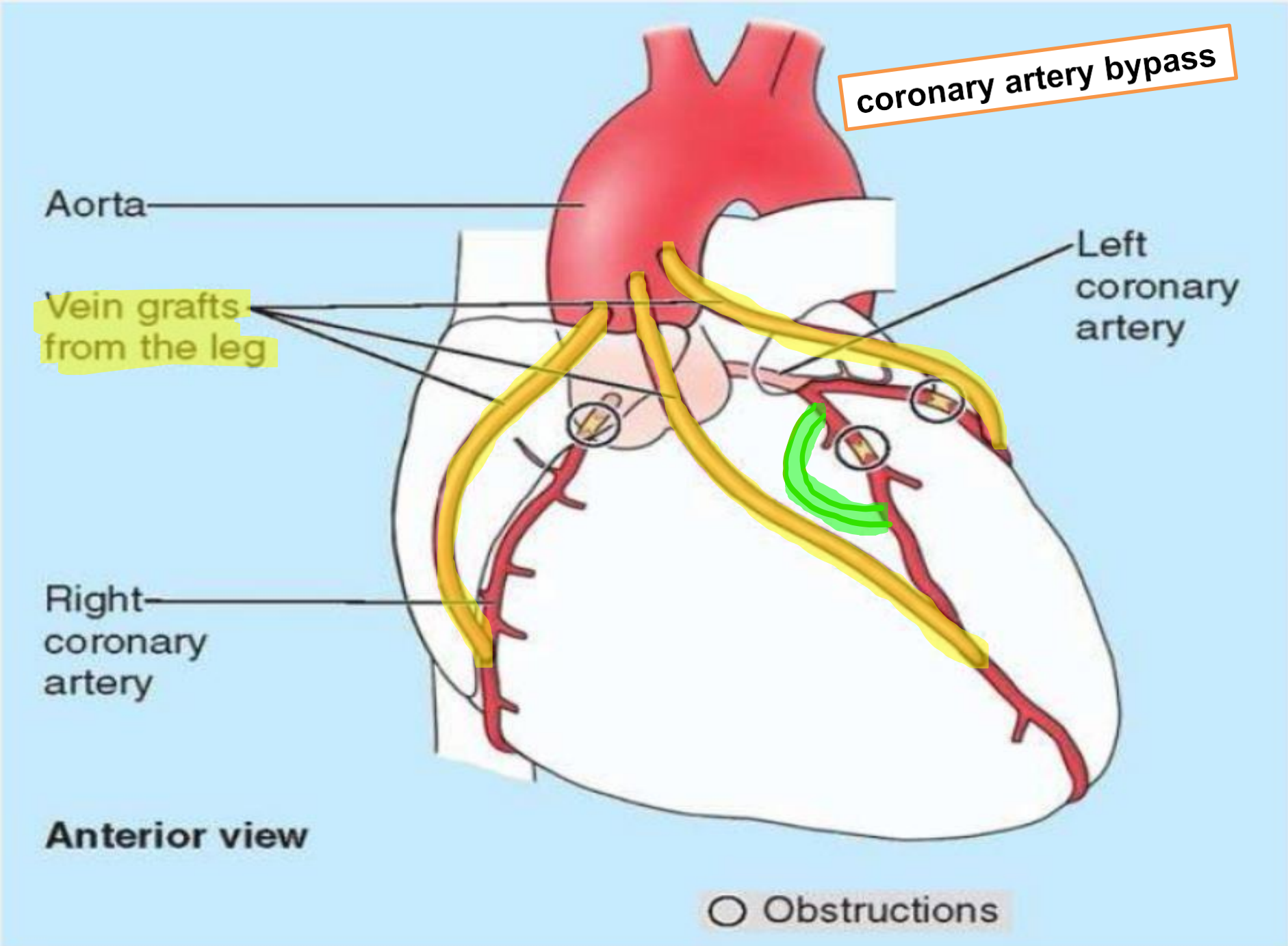

IF AN OCCLUSION OCCURS:

In the past: we were making a bypass (as drawn in green in the picture above)

Now adays we don't do this, instead we: take the great saphenous vein from one leg or 2 legs (the surgeon evaluate the structure, shape and valves of this vein and then they choose segments) and then just embed (make a whole) in the ascending aorta (which is in the pericardium) and put it Infront (distal) to the occlusion, and the blood supply would be restored. Sometimes we use 3 to 4 veins in the same surgery. In picture yellow colored.

Reading the ECG would be helpful in knowing which artery is occluded, the is a relation between them.

Read only and you will not enjoy?!!!!

CD Table 4-1 Coronary Artery Lesions, Infarct Location, and ECG Signature

Coronary Artery	Infarct Location	ECG Signature
Proximal LAD	Large anterior wall	ST elevation: I, L, V1–V6
More distal LAD	Anteroapical	ST elevation: V2–V4
	Inferior wall if wraparound LAD	ST elevation: II, III, F
Distal LAD	Anteroseptal	ST elevation: V1–V3
Early obtuse, marginal	High lateral wall	ST elevation: I, L, V4–V6
More distal marginal branch, circumflex	Small lateral wall	ST elevation: I, L, or V4–V6, or no abnormality
Circumflex	Posterolateral	ST elevation: V4–V6; ST depression: V1–V2
Distal RCA	Small inferior wall	ST elevation: II, III, F; ST depression: I, L
Proximal RCA	Large inferior wall and posterior wall	ST elevation: II, III, F; ST depression: I, L, V1–V3
	Some lateral wall	ST elevation: V5–V6
RCA	Right ventricular	ST elevation: V2R–V4R; some ST elevation: V1, or ST depression: V2–V3
	Usually inferior	ST elevation: II, III, F

ECG, electrocardiographic; LAD, left anterior descending (interventricular); RCA, right coronary artery.

THE INNERVATION OF THE HEART

INNERVATION OF THE HEART

The heart is an internal organ and therefor its nervous supply comes from the autonomic nervous system.

1. Sympathetic → sympathetic trunk
2. Parasympathetic → Vagus nerve

And all of them form plexuses "the cardiac plexuses"

The heart is supplied by autonomic nerve fibers from **The cardiac plexus** which is often quite artificially divided into superficial and deep portions

The cardiac plexus Leis on the anterior surface of the **bifurcation of the trachea** Between T4 and T5

It is formed of both **sympathetic and parasympathetic fibers** as well as **visceral afferent fibers** conveying reflexive and nociceptive fibers from the heart

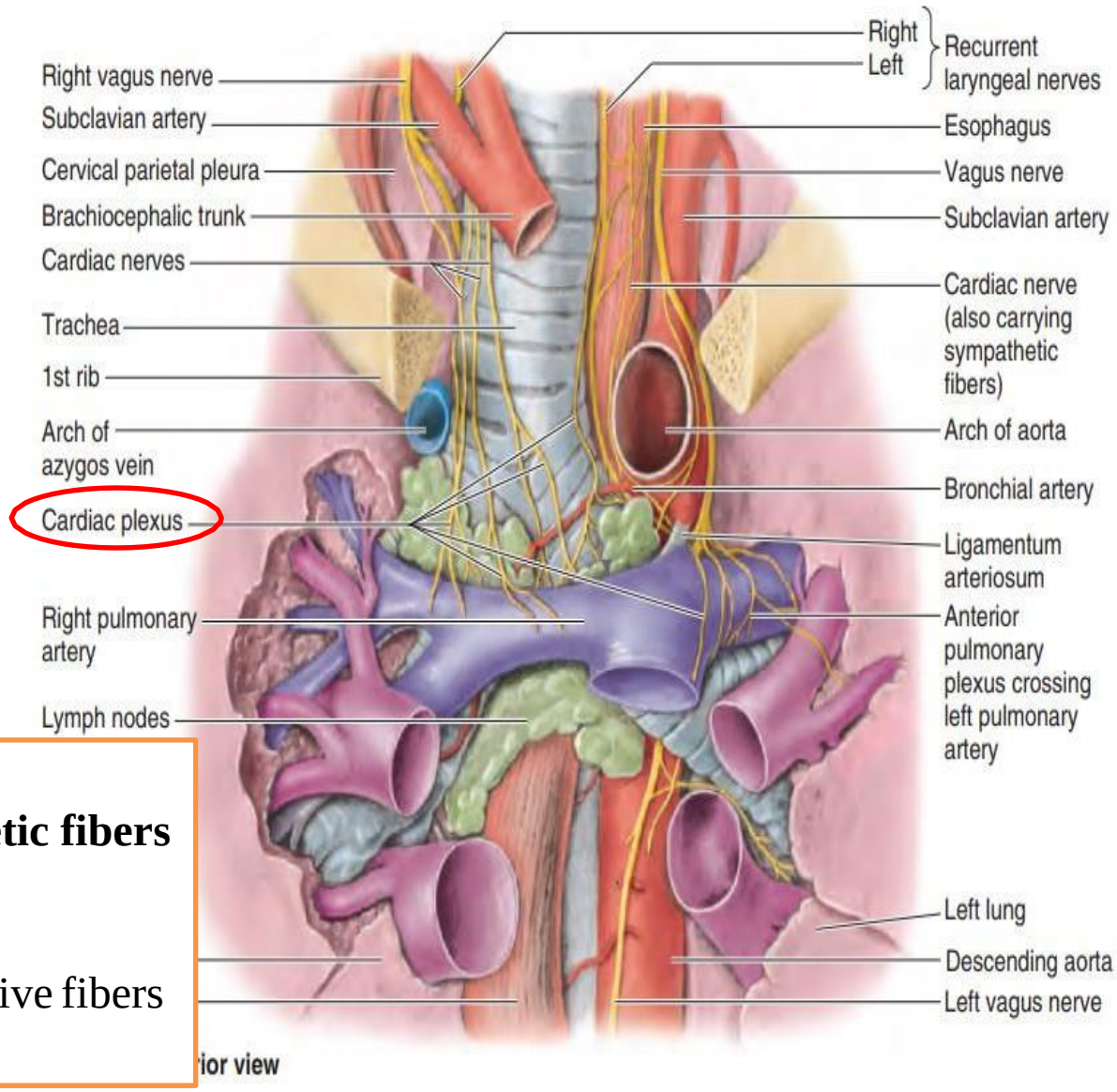

The sympathetic supply is from

Presynaptic Fibers, with cell bodies in the intermediolateral cell columns (IMLs) of the superior five or six thoracic segments of the spinal cord

Postsynaptic Sympathetic Fibers, with cell bodies in the cervical and superior thoracic paravertebral ganglia **of the sympathetic trunks**.
The postsynaptic fibers traverse cardio pulmonary splanchnic nerves and the cardiac plexus to end **in the SA and AV nodes**

Sympathetic stimulation

Adrenergic stimulation of the SA node and conducting tissue

- ❖increases the rate of depolarization of the pacemaker cells while increasing atrioventricular conduction

causes **increased heart rate**
impulse conduction
force of contraction

The sympathetic supply is from

posterior – dorsal horn
sensory

*you would find the A and P horns in all spinal cord sigments

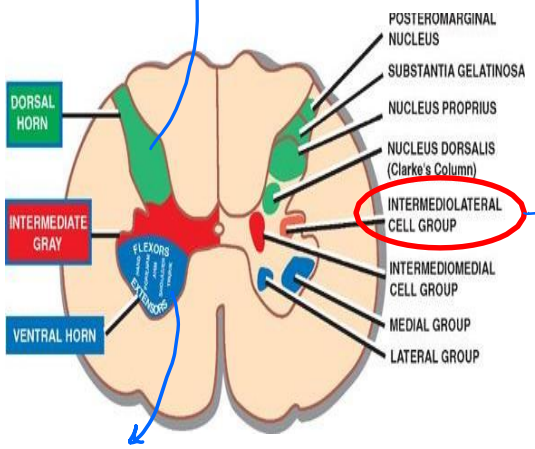

anterior – ventral horn
motor

The lateral horn "sympathetic" ((T1-L2 or L3))
↳ therefore we say that the sympathetic cells are only located in these columns and only in certain segments (T1-L2)

therefore we call it :
THORACOLUMBAR OUTFLOW

Presynaptic Fibers, with cell bodies in the intermediolateral cell columns (IMLs) of the superior five or six thoracic segments of the spinal cord They join the sympathetic trunk Where they synapse

Presynaptic nerves differ in the way they reach the sympathetic chain some will go up reaching the neck and then the head

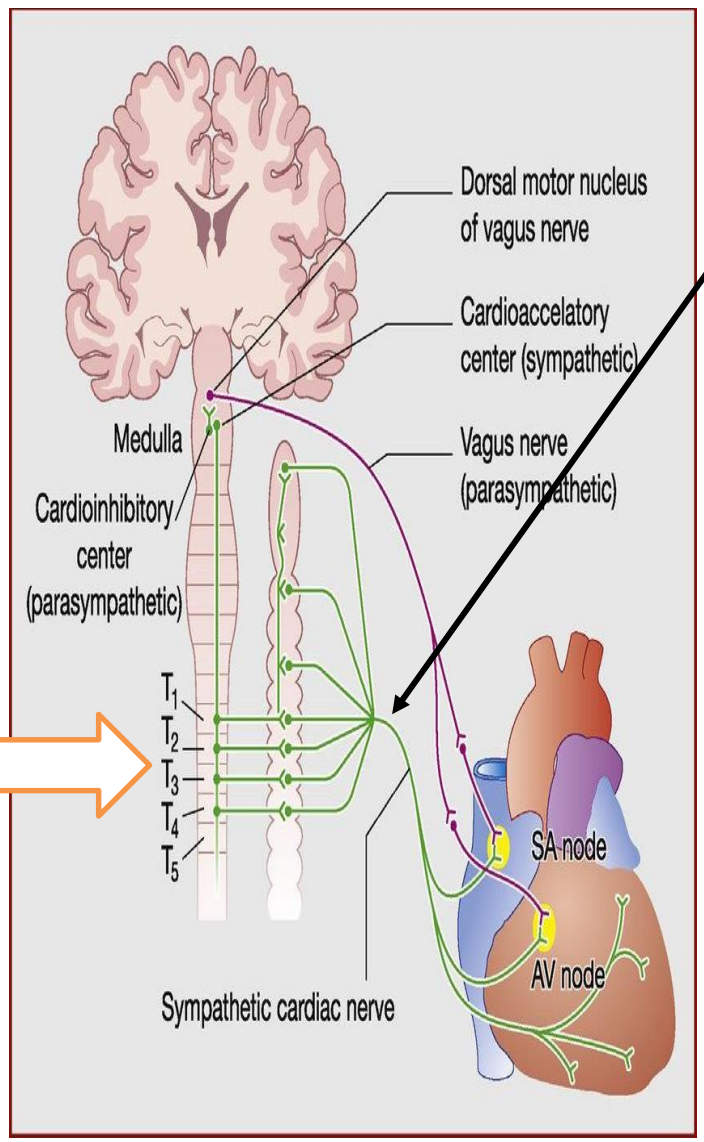

The presynaptic nerves from T1-T5 synapse in the sympathetic trunk,
The postsynaptic fibers traverse cardiopulmonary splanchnic nerves and the cardiac plexus to end **in the SA and AV nodes**

accelerates the heart rate

They reach the myocardium, but they don't give it motor innervation

And constrict blood vessels in the body! What about the coronary arteries? would they also be constricted!!!???

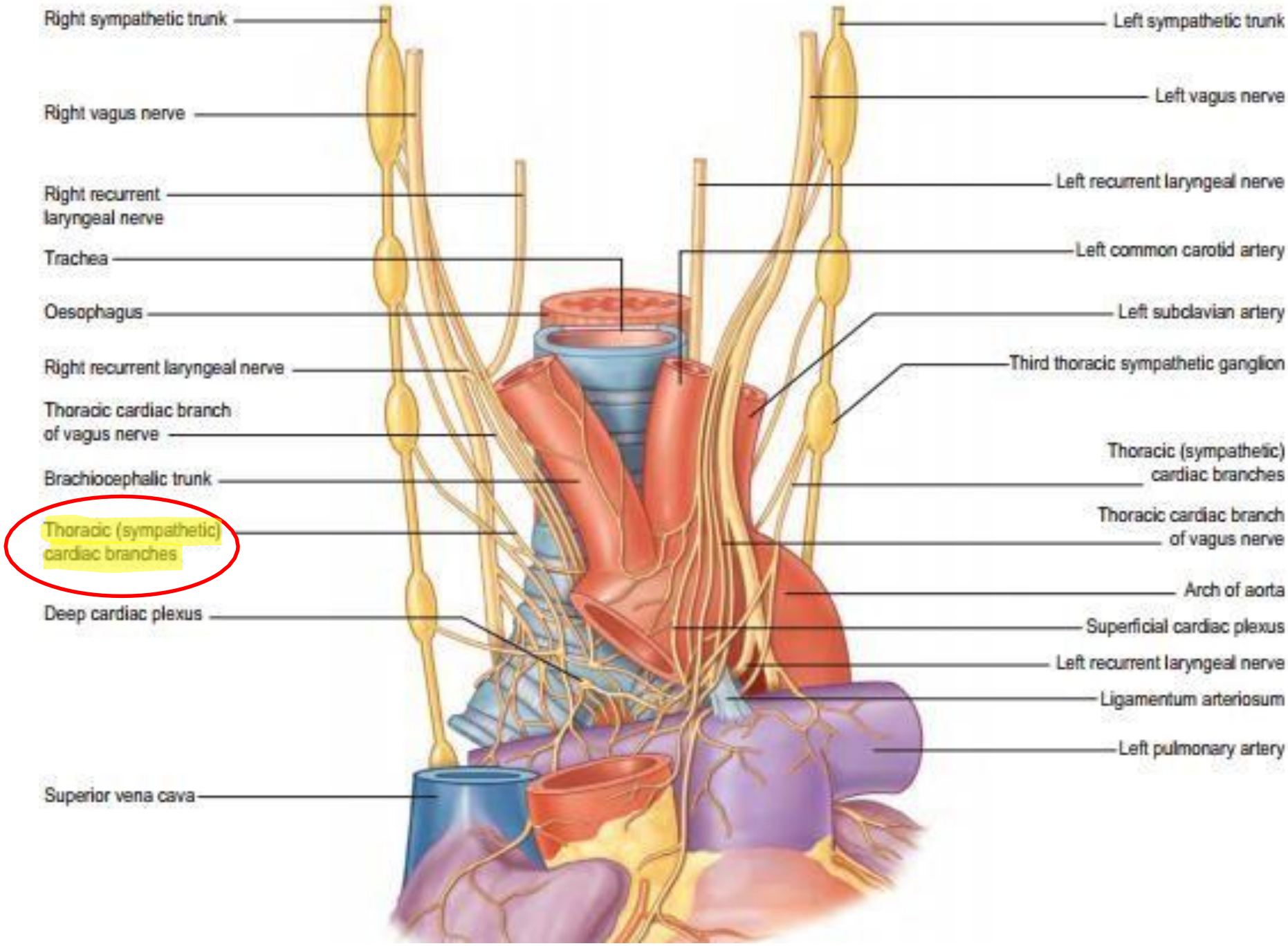
Right sympathetic trunk
Right vagus nerve
Right recurrent laryngeal nerve
Trachea
Oesophagus
Right recurrent laryngeal nerve
Thoracic cardiac branch of vagus nerve
Brachiocephalic trunk
Thoracic (sympathetic) cardiac branches
Deep cardiac plexus
Superior vena cava
Left sympathetic trunk
Left vagus nerve
Left recurrent laryngeal nerve
Left common carotid artery
Left subclavian artery
Third thoracic sympathetic ganglion
Thoracic (sympathetic) cardiac branches
Thoracic cardiac branch of vagus nerve
Arch of aorta
Superficial cardiac plexus
Left recurrent laryngeal nerve
Ligamentum arteriosum
Left pulmonary artery

Coronary arteries have sympathetic nerves in their adventitia (which secrete the sympathetic triad ATP, mainly NE), NE would cause certainly constriction of the blood vessel

BUT the sympathetic innervation increases the rate of the heart, so more oxygen should come to the heart, so the coronary arteries should be relaxed to get more blood.

SO, WHAT IS THE EFFECT OF NE ON CORONARY ARTERIES?

THW SYMPATHETIC INNERVATION INCREASES THE HEART, AND THEREFORE, THE CORONARY ARTERIES NEED TO RELAX.

At the same time

Increased blood flow through the coronary vessels!!!!!!!!!

to support the **increased activity**

Most adrenergic receptors on coronary blood vessels **are β_2-receptors,** which, when activated (by NE), **cause relaxation** (or perhaps inhibition) of vascular smooth muscle and, therefore, dilation of the arteries (Wilson-Pauwels et al., 1997). This supplies more oxygen and nutrients to the myocardium during periods of increased activity.

The parasympathetic supply

- is from presynaptic fibers of ***the vagus nerves***

- Postsynaptic parasympathetic cell bodies (intrinsic ganglia) are located in

  - The atrial wall
  - Interatrial septum near the SA and AVnode
  - Along the coronary arteries

Most arteries have sympathetic rather than parasympathetic innervation, and they don't need parasympathetic to dilate.
You could find parasympathetic fibers in glands and coronary arteries, but the heart has a lot of work every minute, that's why local mechanisms in the coronary arteries would be effective to relax the coronary arteries, that's why the parasympathetic nerves could also be in the arteries, but they would rather play constriction and moderation (neuromodulatory role) rather than anything else.

- Parasympathetic stimulation ***slows***
  - ***The heart rate***
  - ***reduces the force of the contraction***
  - ***constricts the coronary arteries***
- Postsynaptic parasympathetic fibers release

ACETYLCHOLINE

which binds with **muscarinic receptors** to slow the rates of depolarization of the pacemaker cells and atrioventricular conduction and decrease atrial contractility.

Opposite to sympathetic effect.

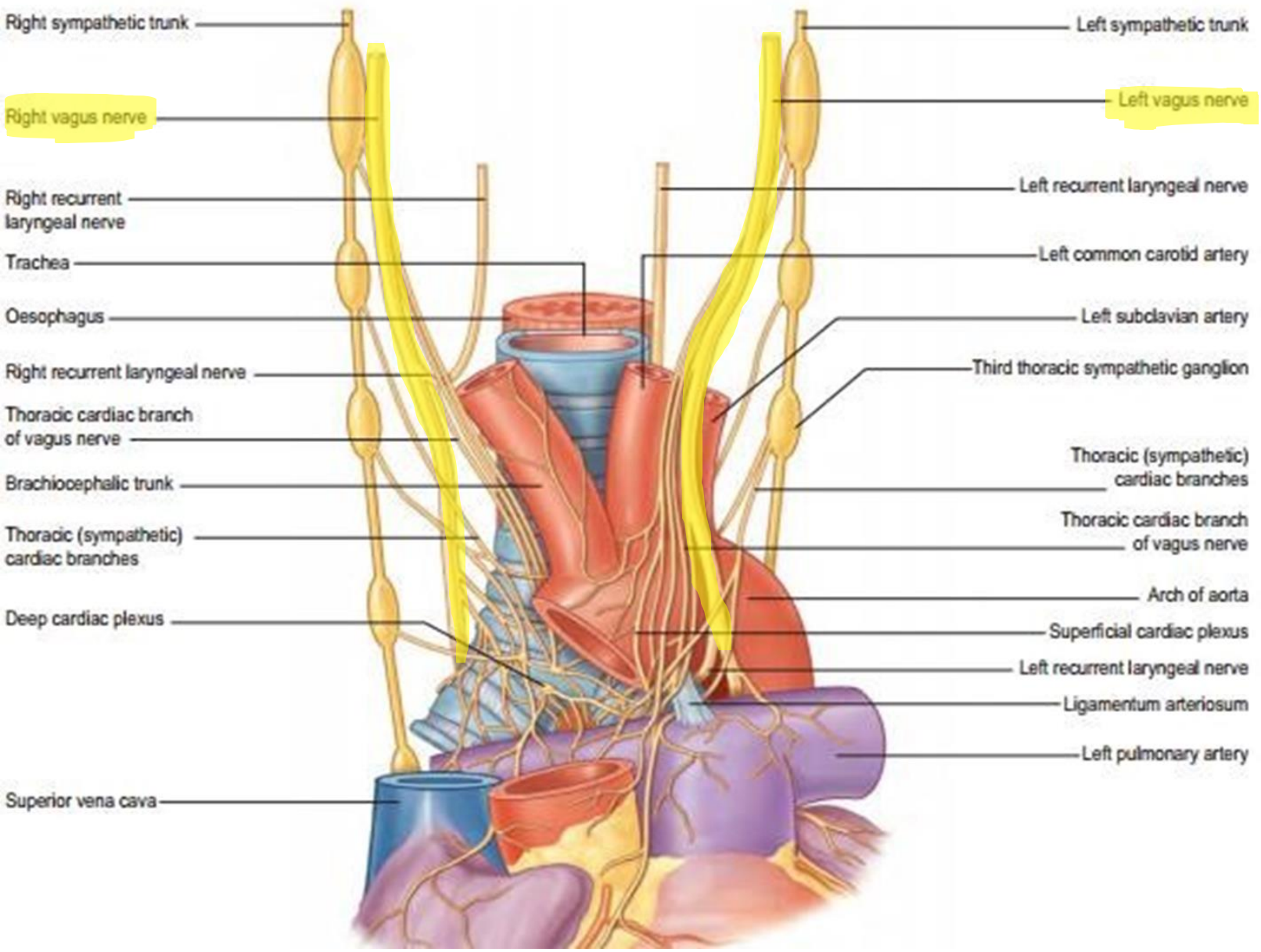

BOTH SYMPATHETIC AND PARASYMPATHETIC, NEVER INNERVATE THE MYCARDIUM OF THE HEART OR INNITIATE CONTRACTION, BUT THEY COULD REACH THE MYOCARDIUM WITHOUT INNERVATING IT, ESPACIALLY THE SYMPATHETIC.

Cardiac Pain

The heart as a visceral organ all the visceral sensory innervation would go back via the visceral sympathetic sensory to T1-T5

The nature of the pain varies considerably, from a severe crushing pain to nothing more than a **mild discomfort**

Pain originating in the heart stimulate the sensory nerve endings in the myocardium.

The afferent nerve fibers ascend to the central nervous system through ***the cardiac branches of the sympathetic trunk*** and enter the spinal cord through the posterior roots of **the upper four** (or till fifth, but it doesn't matter variability is always there) **thoracic nerves**

The heart in in the middle mediastinum which is below the imaginary plane (between sternal angle and intervertebral disc between T4-T5) that separates superior and inferior mediastinum. So, the heart is below these neural segments that we mentioned.

The pain is not felt in the heart, but is referred to the skin areas supplied by the upper four thoracic nerves (intercostal nerves; as they supply the 1-4 intercostal spaces, motor and sensory, so the patient would complain about upper pain in the chest)

The skin areas supplied by the upper four intercostal nerves and by the intercostobrachial (supplies the skin of the upper limb) nerve (T2) are therefore affected.

The intercostobrachial nerve communicates with the medial cutaneous nerve of the arm ***and is distributed to skin on the medial side of the upper part of the arm***

(and therefore, the brain may take this as a pain coming from the left side of the arm not from the heart itself, because the efferent signals coming from the heart and intercostobrachial nerves are going to the same segment→ called as referred pain)

Cardiac referred pain is **a phenomenon** whereby noxious stimuli originating in the heart are perceived by a person as pain arising from a superficial part of the body—the skin on the left upper limb

A certain amount of spread of nervous information must occur within the central nervous system, for the pain is sometimes ***felt in the neck and the jaw.*** (can't be explained on anatomical bases)

????

Myocardial infarction involving **the inferior wall or diaphragmatic surface of the heart** often gives rise to discomfort

in the epigastrium.

Patients could come complaining about epigastric discomfort combined with chest pain, left arm pain, jaw and neck or only epigastric discomfort.

This discomfort could be explained on anatomical bases.

The diaphragmatic surface is sitting on the central tendon of the diaphragm, and we know the diaphragm has not only the phrenic nerve supply but also the lower intercostal nerves 7,8,9.

One must assume that the afferent pain fibers from the heart ascend in the sympathetic nerves and enter the spinal cord in the posterior roots of

the ***seventh, eighth, and ninth thoracic spinal*** nerves and give rise to referred pain in the **T7, T8, and T9** thoracic

dermatomes in the epigastrium

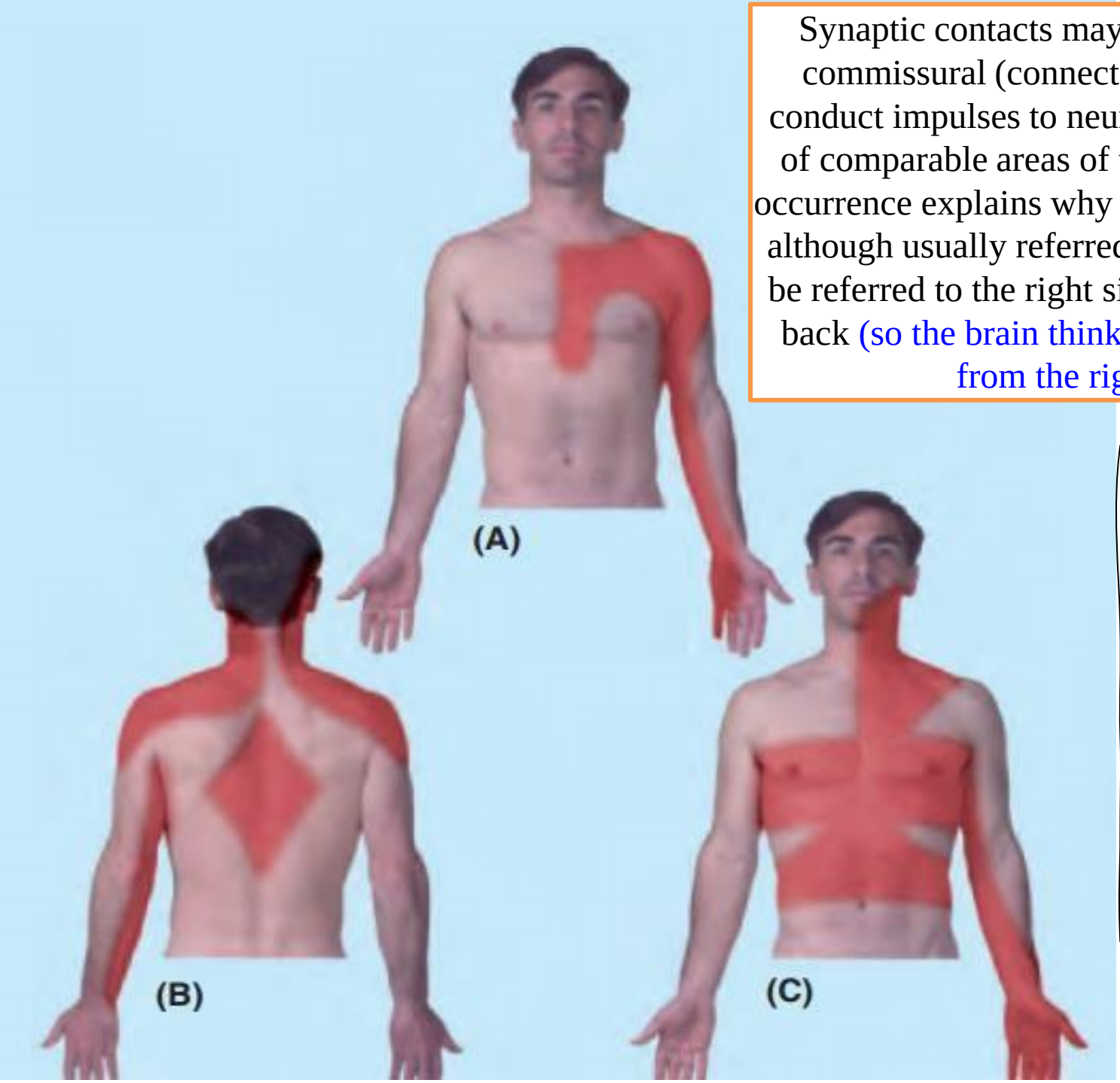

Synaptic contacts may also be made with commissural (connector) neurons, which conduct impulses to neurons on the right side of comparable areas of the spinal cord. This occurrence explains why pain of cardiac origin, although usually referred to the left side, may be referred to the right side, both sides, or the back (so the brain thinks the pain is coming from the right side)

Diabetic and old people, usually don't show typical signs of myocardial infarction, they usually come with:

1. Epigastric discomfort
2. Back pain between the 2 scapula

Dentists could have patients complaining about severe left jaw pain→ they have to know that this a sign of myocardial infarction.

THE CONDUCTING SYSTEM OF THE HEART

THE CONDUCTING SYSTEM OF THE HEART

consists of specialized cardiac muscle

(which are not any type of nerves)

present in

- **THE SINUATRIAL NODE**
- **THE ATRIOVENTRICULAR NODE**
- **THE ATRIOVENTRICULAR BUNDLE**
- **RIGHT AND LEFT TERMINAL BRANCHES**
- **THE SUBENDOCARDIAL PLEXUS OF PURKINJE FIBERS**

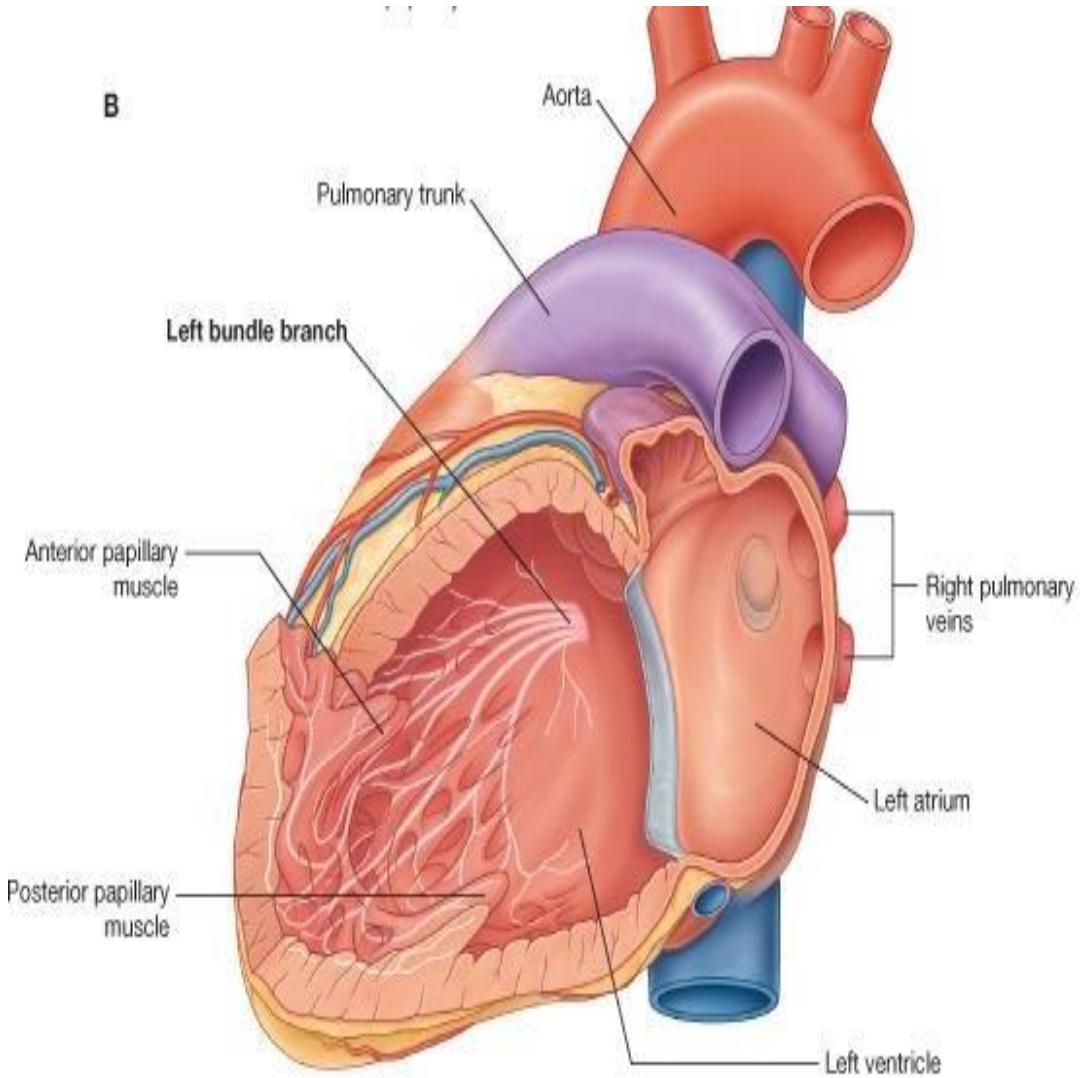

The sinu-atrial (SA) node

- is located anterolaterally just deep to the epicardium at the junction of the SVC and right atrium, near the superior end of the sulcus terminalis

- The SA node—a small collection of nodal tissue, specialized cardiac muscle fibers, and associated fibroelastic connective tissue— is the pacemaker of the heart

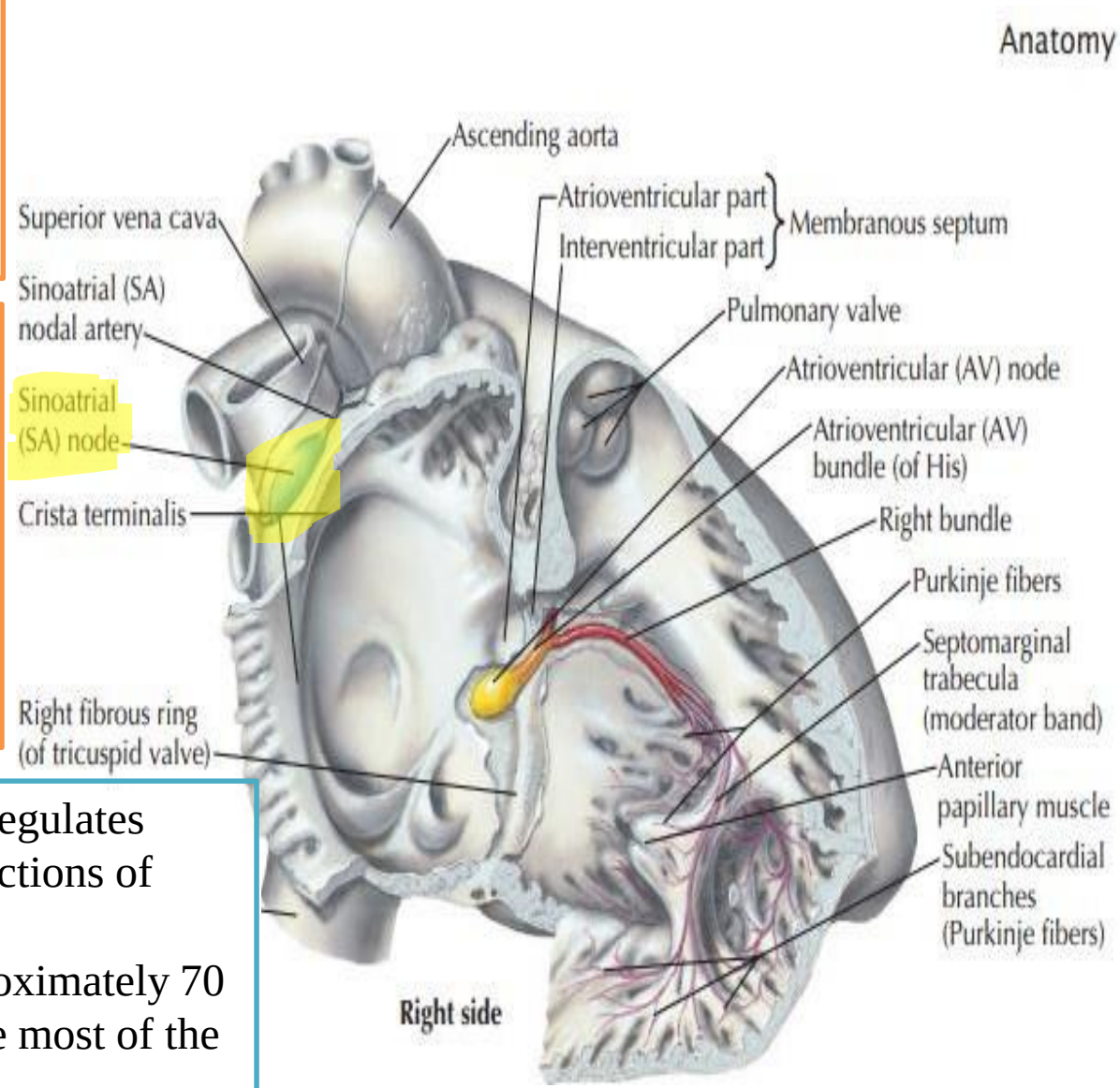

- The SA node initiates and regulates the impulses for the contractions of the heartgiving off an impulse approximately 70 times per minute in most people most of the time

The contraction signal from the SA node spreads myogenically (through the musculature) of both atria

- The SA node is stimulated by the sympathetic division of the autonomic nervous system to accelerate the heart rate and is inhibited by the parasympathetic division to return to or approach its basal rate.

The atrioventricular (AV) node

- is a smaller collection of nodal tissue than the SA node.
  - The AV node is located in the **posteroinferior** region of the **interatrial septum near the opening of the coronary sinus**
  - Its anatomical landmarks are the boundaries of the **triangle of Koch**
- The signal generated by the SA node passes through the walls of the right atrium, propagated by the cardiac muscle (**myogenic conduction**), which transmits the signal rapidly from the SA node to the AV node.
  - The AV node then distributes the signal to the ventricles through the **AV bundle (of His)**

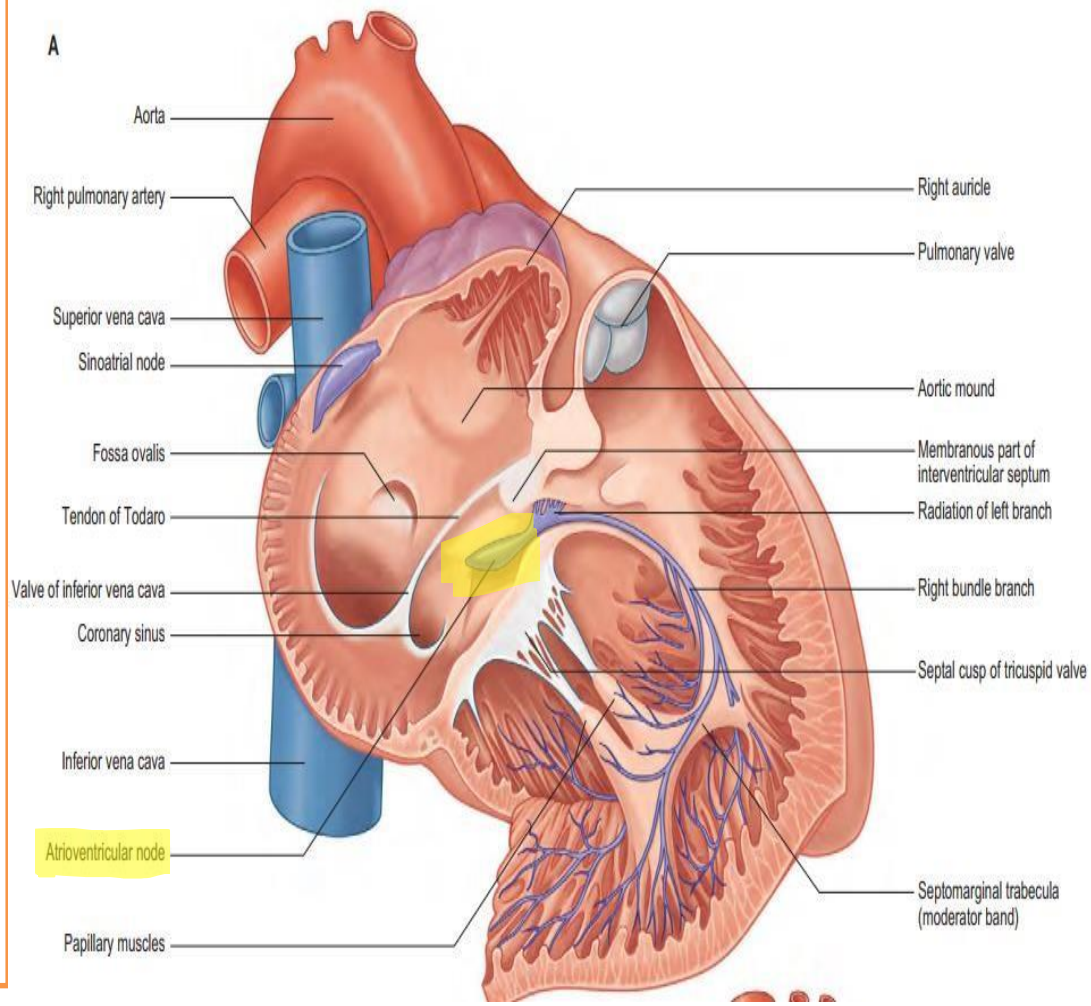

- Sympathetic stimulation speeds up conduction, and parasympathetic stimulation slows it down.

The AV bundle or bundle of His

The AV bundle is
the only bridge
between
THE ATRIAL
and
VENTRICULAR MYOCARDIUM

- It passes from **the AV node** through the ***fibrous skeleton of the heart and along the membranous part of the IVS***

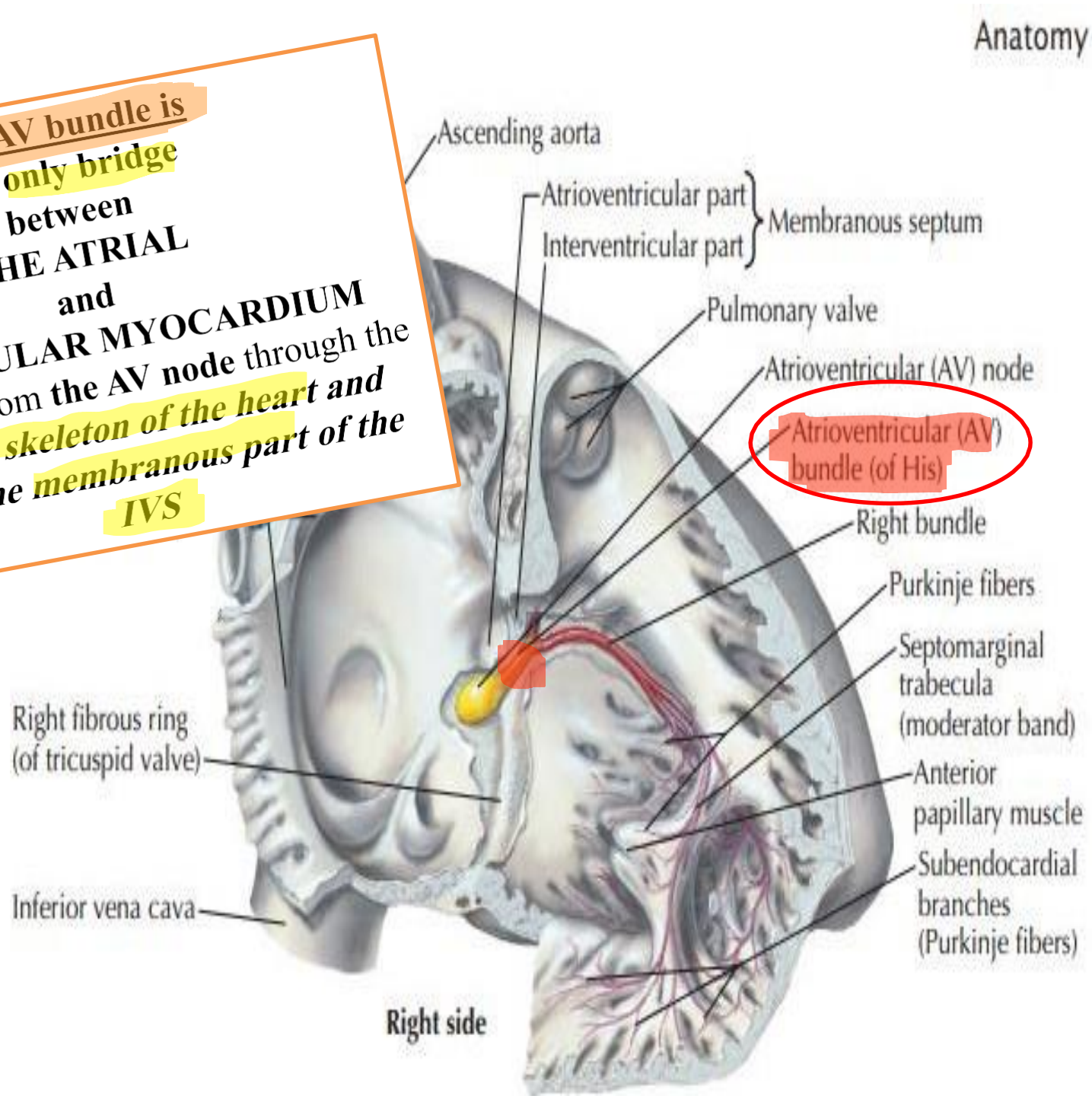

Why the bundle of HIS (AV bundle) is not running in the myocardium?
→ For isolation purposes, and the best insulator in the heart is the fibrous skeleton.

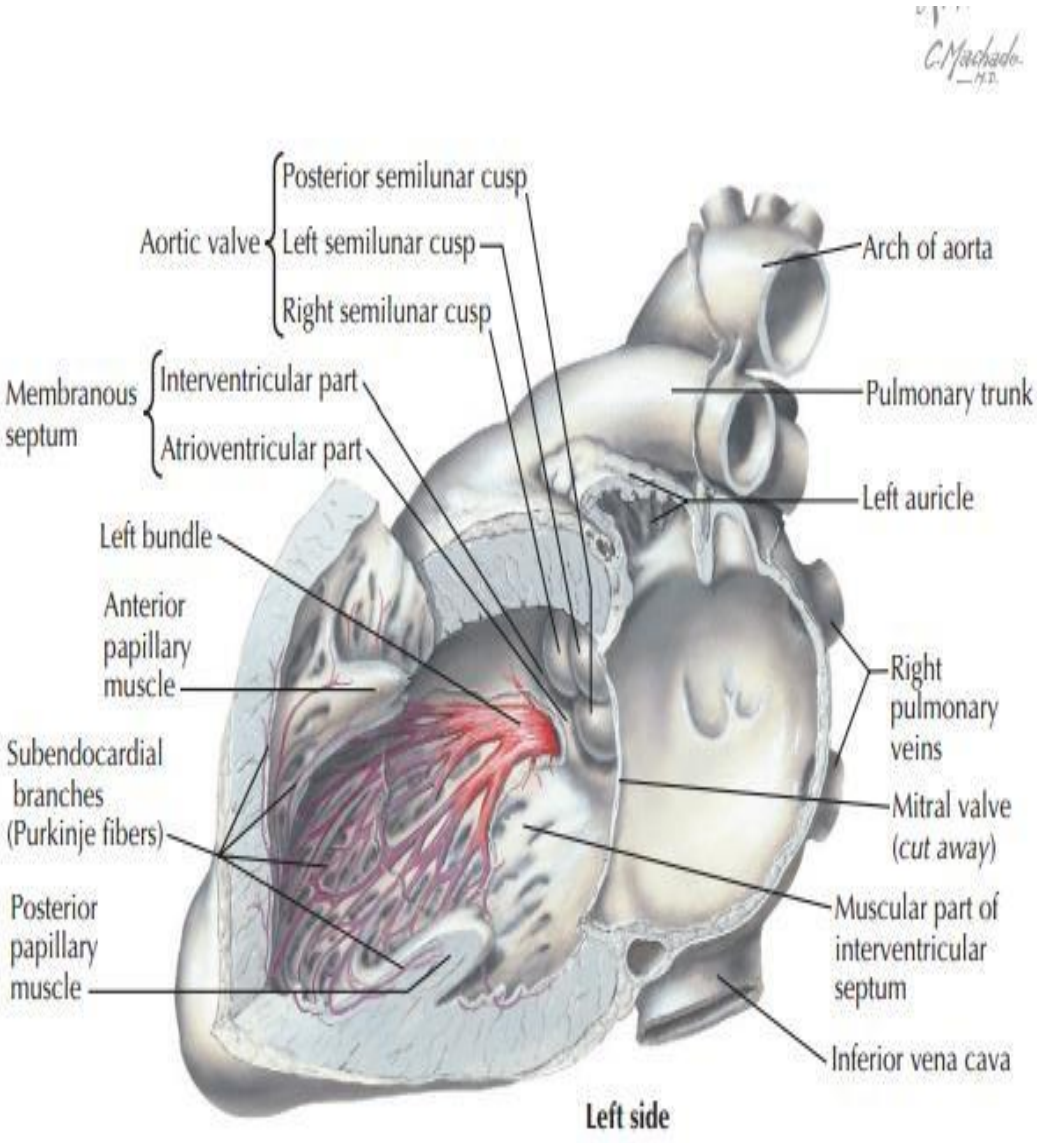

- At the junction of the **membranous and muscular parts** of the IVS, the AV bundle divides **<u>into right and left bundles</u>**
- These branches proceed on each side of the muscular IVS deep to the endocardium and then ramify into subendocardial branches **(Purkinje fibers)**
- which extend into the walls of the respective ventricles.
- The subendocardial branches **of the right bundle** stimulate the muscle of the IVS, the anterior papillary muscle through ***the septomarginal trabecula (moderator band),*** and the wall of the right ventricle.
- **The left bundle** divides near its origin into approximately six smaller tracts, which give rise to subendocardial branches that stimulate the IVS, the anterior and posterior papillary muscles, and the wall of the left ventricle.

The membranous part of the IV septum:
Is made up by 3 contributors and sometimes one of them would not come and therefore we would have newly born babies with defect in IV septum.
And we need to repair this defect if its large enough to cause symptoms.

With a VSD, the AV bundle usually **lies in the margin of the VSD. Obviously, this vital part of the conducting system must be preserved during surgical repair of the defect.**

Destruction of the AV bundle would cut the only physiological link between the atrial and ventricular musculature, also producing a heart block as described above.

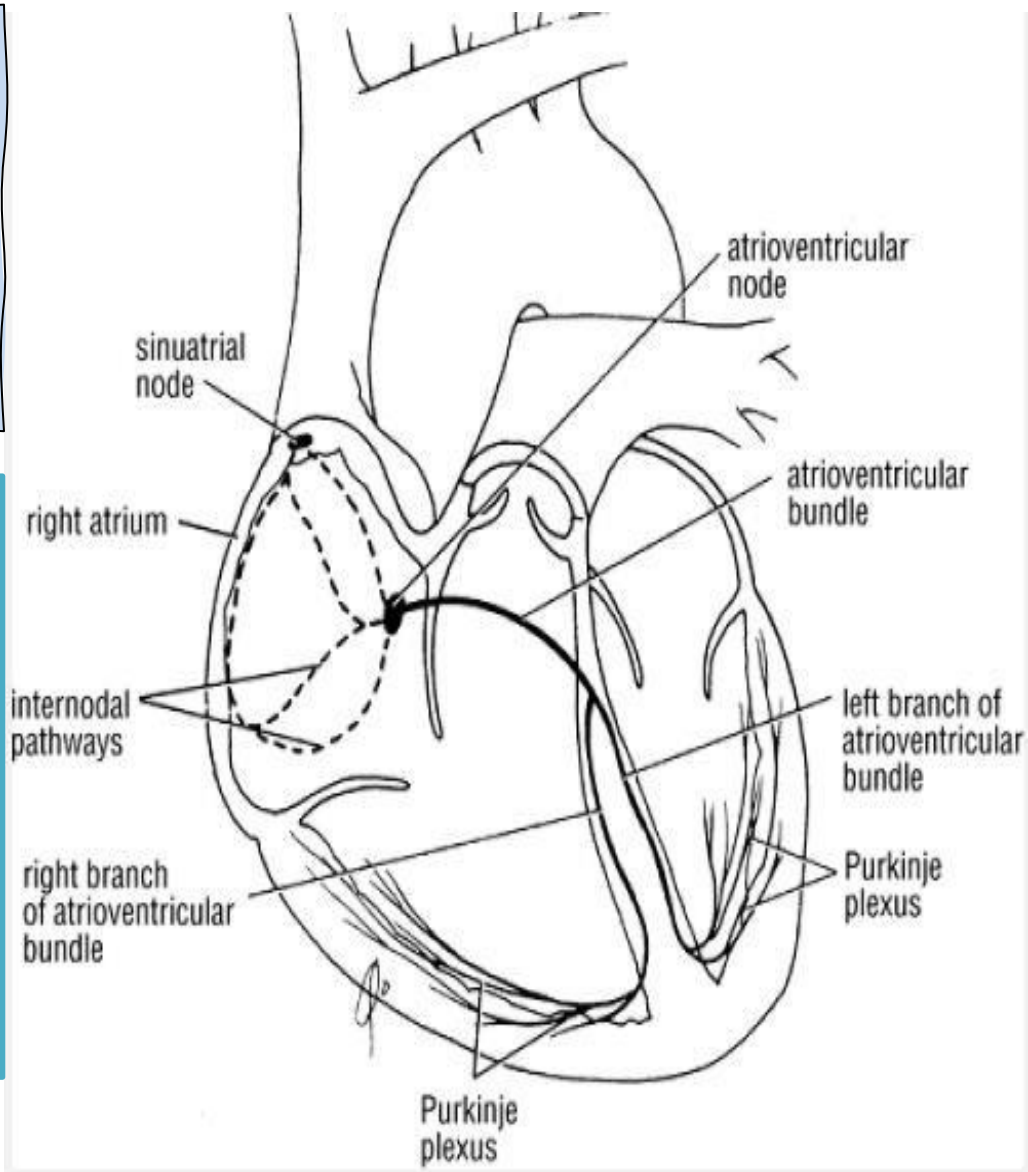

Purkinje fibers

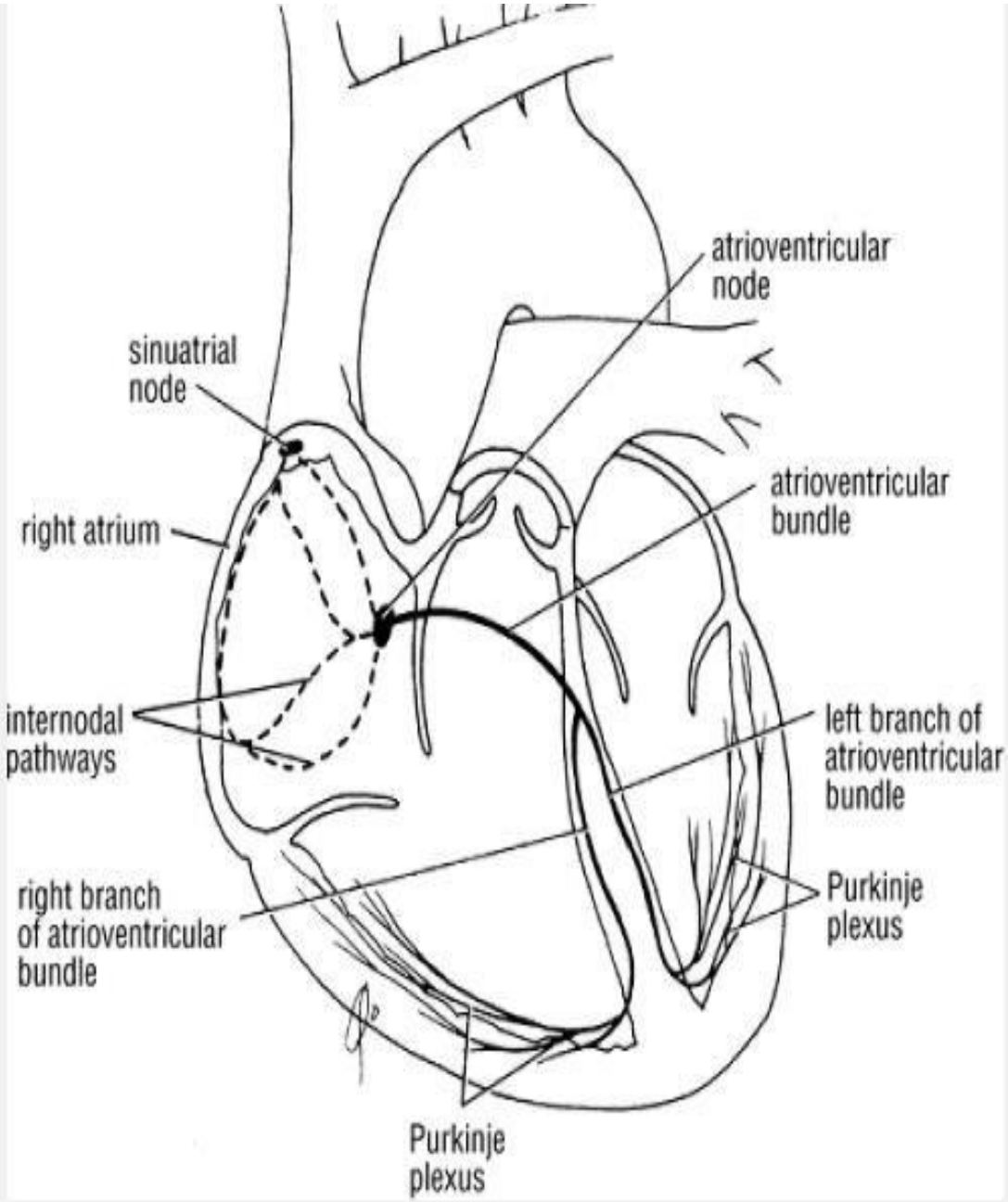

- subendocardial branches
- **(Purkinje fibers)**
- which extend into the walls of the respective ventricles.
- The subendocardial branches of the right bundle stimulate the muscle of the IVS, the anterior papillary muscle through ***the septomarginal trabecula (moderator band),*** and the wall of the right ventricle.

- The left bundle divides near its origin into approximately six smaller tracts, which give rise to subendocardial branches that stimulate the IVS, the anterior and posterior papillary muscles, and the wall of the left ventricle.

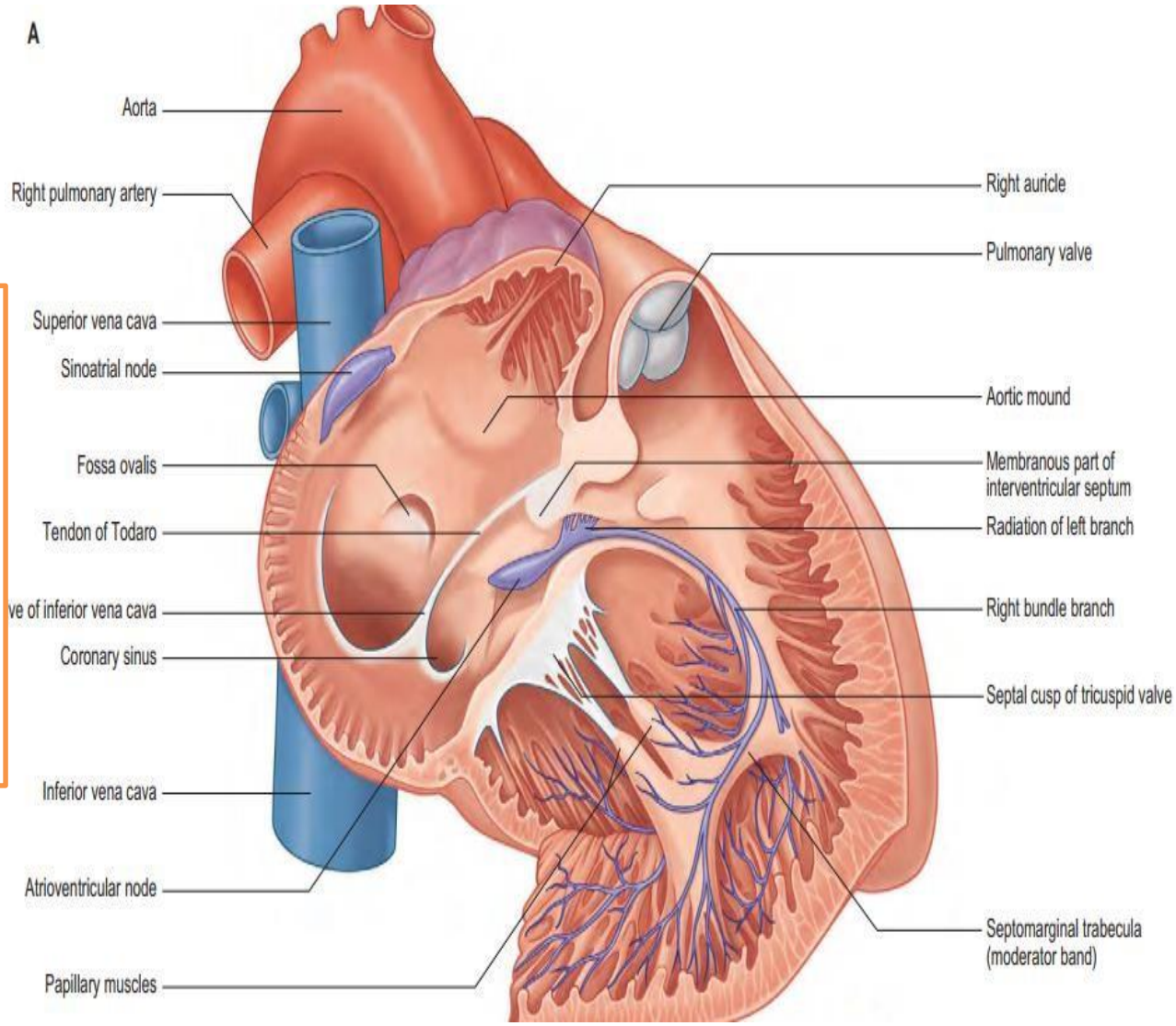

Internodal Conduction Paths

Impulses from the sinuatrial node have been shown to travel to the atrioventricular node more rapidly than they can travel by passing along **the ordinary myocardium.**

This phenomenon has been explained by the description of special pathways in the atrial wall which have a ***structure consisting of a mixture of Purkinje fibers and ordinary cardiac muscle cells***.

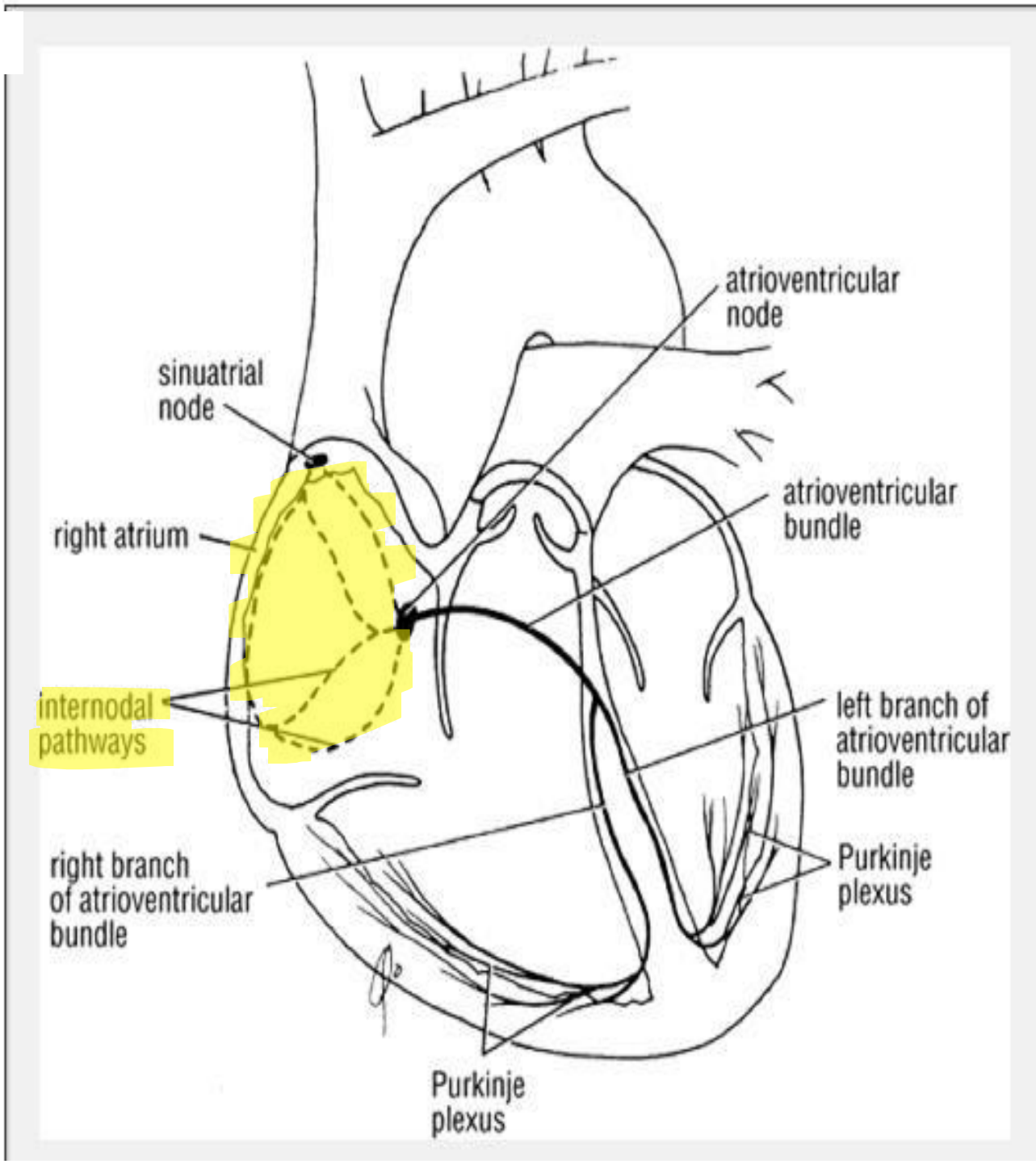

A-The anterior internodal pathway:
leaves ***the anterior end*** of the ***SA node*** and passes ***anterior to the superior vena caval opening***. It descends on the atrial septum and ends in the ***AV node.***

B- The middle internodal pathway
leaves ***the posterior end*** of the ***SA node*** and passes ***posterior to the superior vena caval opening***. It descends on the atrial septum to the ***AV node.***

C-The posterior internodal pathway:
leaves the ***posterior part*** of the ***SA node*** and descends through the **crista terminalis** and ***the valve of the inferior vena cava*** to the ***AV node***

Electrical System of the Heart

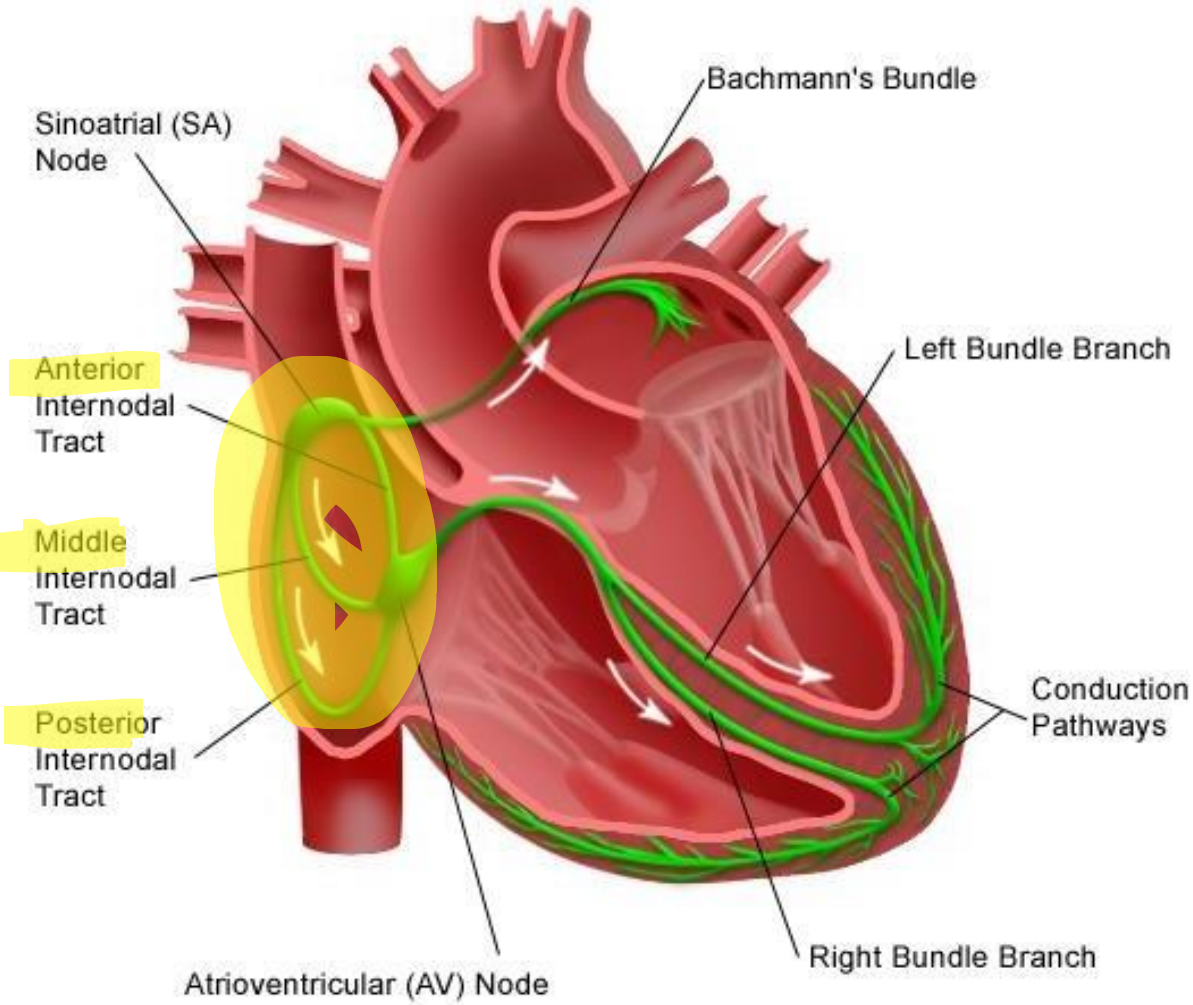

Any damage to the conducting system would lead to **ARRYTHMIAS**.
Coronary arteries are associated with myocardial infarction. The myocardial infarction can affect the conducting system, the papillary muscles and the contractility of the left and right ventricles.