USMLE Uworld questions collection (WEEK2)

I) 54 - year - old man is admitted to the hospital due to cough, shortness of breath, and chest discomfort. He has a known history of coronary artery disease and underwent coronary artery bypass graft surgery 3 years ago. As a result of drug therapy, the left ventricular pressure - volume loop changes from a solid to a dashed line as shown on the graph below.

Which of the following parameters is most likely to increase as a result of this change?

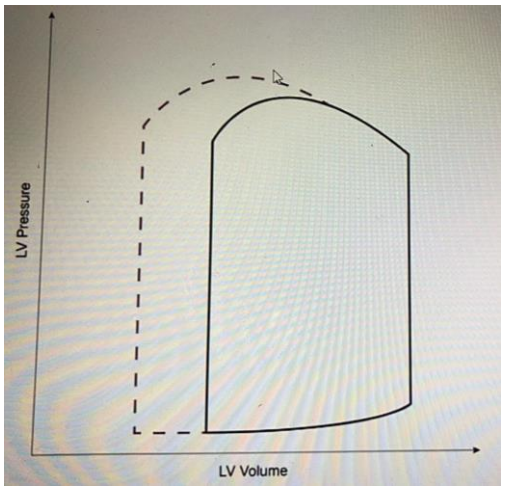

A. End - diastolic pressure
B. End - systolic volume
C. Stroke volume
D. Ventricular afterload
E. Ventricular preload

II) The volume and pressure tracings for the left ventricle of a 34 - year - old male are shown below. Which of the following points corresponds to aortic valve opening?

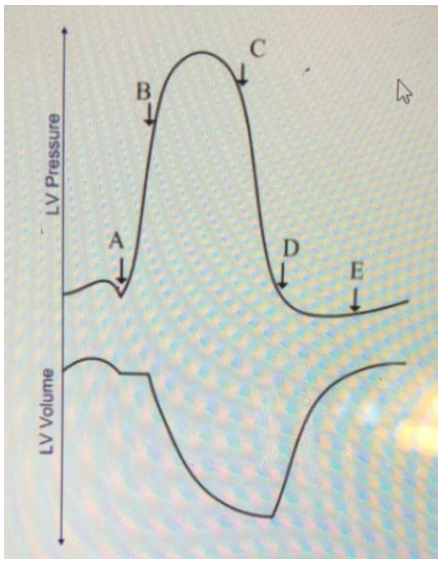

A. A
B. B
C. C
D. D
E. E

III) A 46 - year - old patient is undergoing cardiac catheterization. Initially, the catheter records periodic pressure changes with a maximum of 27 mmHg and minimum of 2 mmHg. The catheter is advanced further, and then shows periodic pressure changes with a maximum of 26 mmHg and a minimum of 10 mmHg.

The initial readings were most likely obtained from which of the following locations?

A. Right atrium

B. Right ventricle

C. Left ventricle

D. Left atrium

E. Pulmonary artery

IV) Microelectrodes placed into cardiac muscle cells detect a rapid decrease in cytoplasmic calcium level immediately preceding relaxation.

Which of the following mediates the observed response?

A. Voltage-dependent calcium channels
B. Ryanodine receptors
C. Na+ / Ca+2 exchange mechanism
D. Troponin C
E. Calmodulin

V) Membrane potential changes in an isolated cardiac muscle cell are recorded along with ion movements across the cell membrane (see graph below). Which of the following ion sequences corresponds to regions 1-2-3 on the graph, respectively?

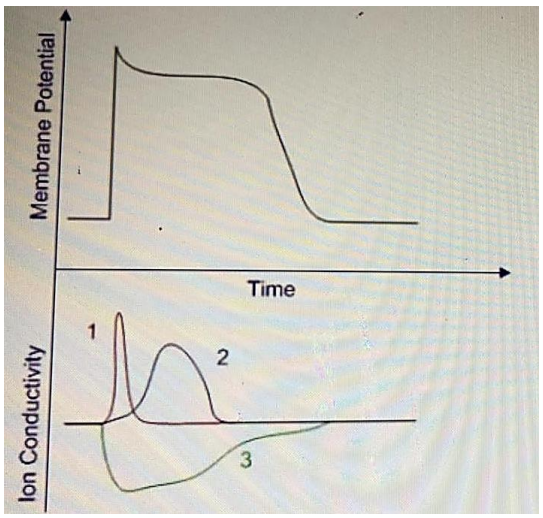

A. Potassium, sodium, calcium
B. Sodium, calcium, potassium
C. Calcium, sodium, chloride
D. Calcium, sodium, potassium
E. Sodium, potassium, calcium

VI) A 67 - year - old man is brought to the emergency department by his son after a syncopal episode. The son was helping his father clean out his garage when his father complained of dizziness. As his son was helping him into a chair, the patient lost consciousness. He woke up spontaneously about a minute later without any disorientation or confusion. An electrocardiogram demonstrates bradycardia with regular rhythm and narrow QRS complexes. However, there is complete desynchronization between the P waves and QRS complexes. Which of the following locations is most likely responsible for pacing this patient's ventricles?

A. Sinoatrial node
B. Atrioventricular node
C. Left bundle branch
D. Purkinje system
E. Left ventricular muscle

VII) A 35 - year - old previously healthy man is evaluated for several episodes of syncope in the past 6 weeks. Physical examination is unremarkable. Echocardiogram shows no structural heart defect. An electrophysiologic study is performed during which catheters are passed into the patient's right and left atrium to record atrial electric potentials. Cardiac monitor currently shows normal sinus rhythm. Which of the following is the most likely earliest site of electric activation?

A. Junction of left atrium and atrial appendage
B. Left atrium near the opening of pulmonary veins
C. Right atrium near the opening of inferior vena cava
D. Right atrium near the opening of superior vena cava
E. Right atrium near the septal cusp of tricuspid valve

VIII) A 56-year-old African American male is diagnosed with essential hypertension. He has no symptoms or comorbid illnesses. You prescribe hydrochlorothiazide. In response to this treatment, the serum level of which of the following is most likely to increase?

A. Potassium
B. Sodium
C. Creatinine
D. Cholesterol
E. High density lipoprotein
F. Alkaline phosphatase

IX) 21 - year - old Caucasian male presents to your office complaining of repeated episodes of palpitations that start and stop abruptly.

After completing a careful work – up, you believe that there is an abnormal muscle tract in this patient's heart that bypasses the AV node. If your diagnosis is correct, which of the following parts of the patient's ECG is most likely to be affected at baseline?

A. A
B. B
C. C
D. D
E. E

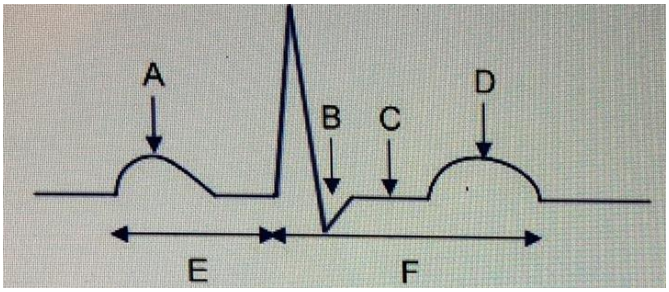

X) Animal experiments have shown that chronic chemical, intravascular injury results in intimal thickening and collagen deposition. Which of the following cells are most important in this intimal response?

A. Interstitial fibroblasts
B. Endothelial cells
C. Smooth muscle cells
D. Macrophages
E. Pericytes

Good luck

Ed3oli

Answers:

1	2	3	4	5	6	7	8	9	10
C	B	B	C	B	B	D	D	E	C