AORTIC ARCH SYSTEM

The major arteries in an early embryo are represented by a pair of vessels

THE DORSAL AORTAE,

which run with the long axis of the embryo and form the continuation of the endocardial heart tubes.

The cranial portion of each dorsal aorta forms an arc on both sides of the foregut, thus establishing the first pair of aortic arch arteries, termed aortic arches

aortic arches are divided into the first, second and third as pharyngeal arches. in fact each pharyngeal arche has it's own artery ,nerve,venous drainage and certain derivative from the mesoderm ,ectodeerm and etc.

* the pink (x) on slide means that the doctor didn't read it in lecture

Arterial System

- ***Aortic Arches***
- they run within branchial (pharyngeal) arches
- These arteries, the **aortic arches, arise from the aortic sac, the most distal** part of **the truncus arteriosus .**
- The aortic sac, giving rise to a total of five pairs of arteries.
- The pharyngeal arches and their vessels appear in a cranial-to-caudal sequence, so that they are not all present simultaneously.
- Consequently, the five arches are numbered I, II, III, IV, and VI .
- *During further development,* this arterial pattern becomes modified, and some vessels regress completely.

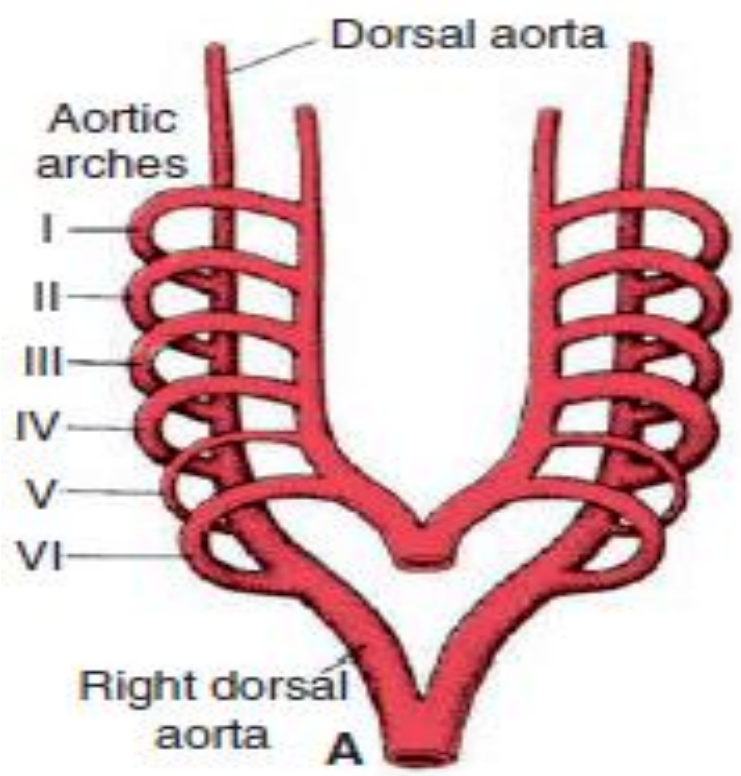

Dr. Amjad Shatarat, School of Medicine,
The University of Jordan

- Division of the **truncus arteriosus** by the **aorticopulmonary** septum divides the outflow channel of the heart into the **ventral aorta and the pulmonary trunk.**

The aortic sac then forms right and left horns, which subsequently give rise to
the **brachiocephalic artery and the proximal segment of** the **aortic arch, respectively .**

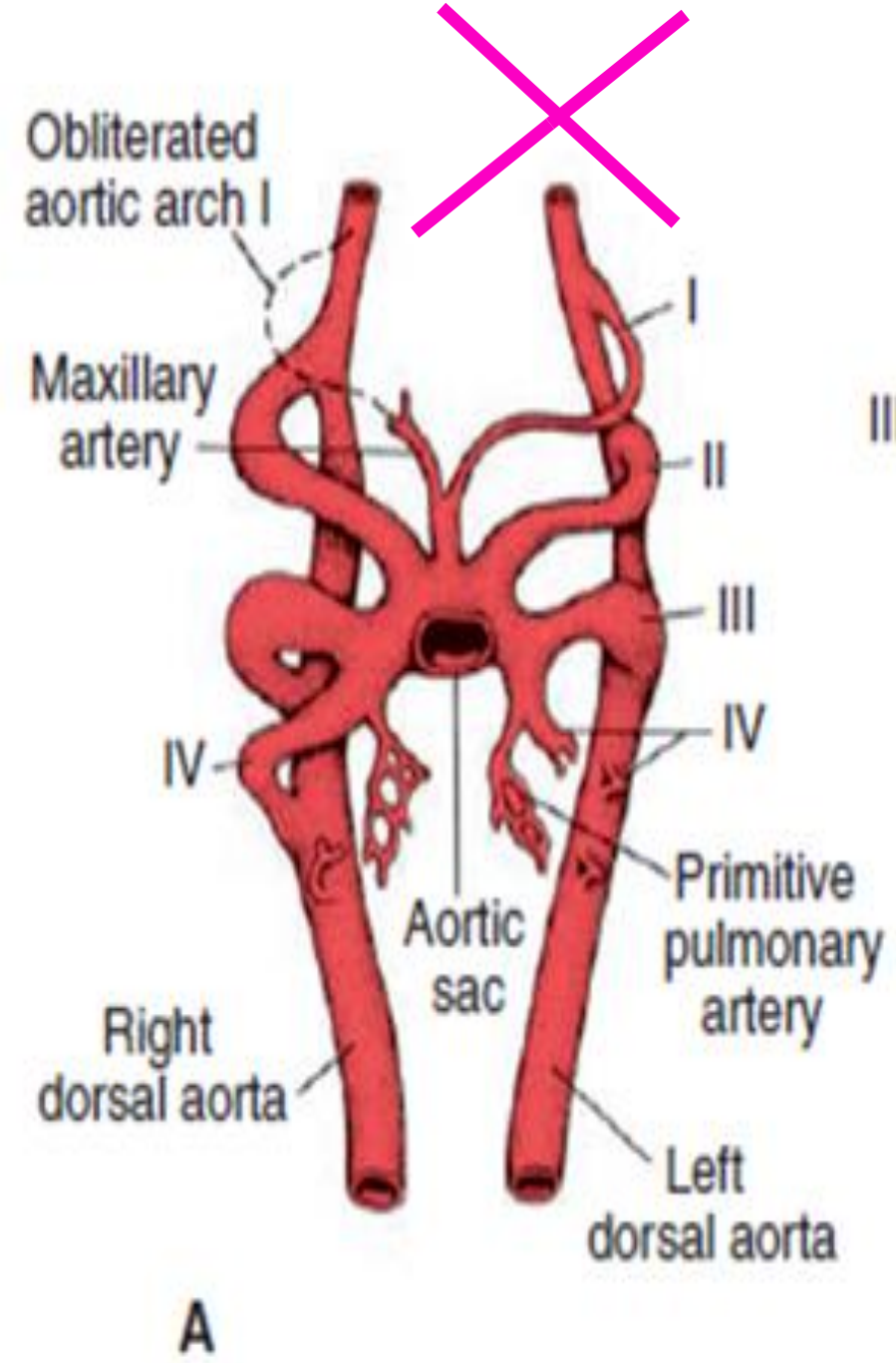

Dr. Amjad Shatarat, School of Medicine,
The University of Jordan

The first pair of arteries largely disappears but remnants of them form **part of the maxillary arteries,** which supply the ears, teeth, and muscles of the eyes and face

Derivatives of Second Pair of Pharyngeal Arch Arteries

Dorsal parts of these arteries persist and form the stems of **<u>the small stapedial arteries</u>**; these small vessels run through the ring of the stapes, a small bone in the middle ear

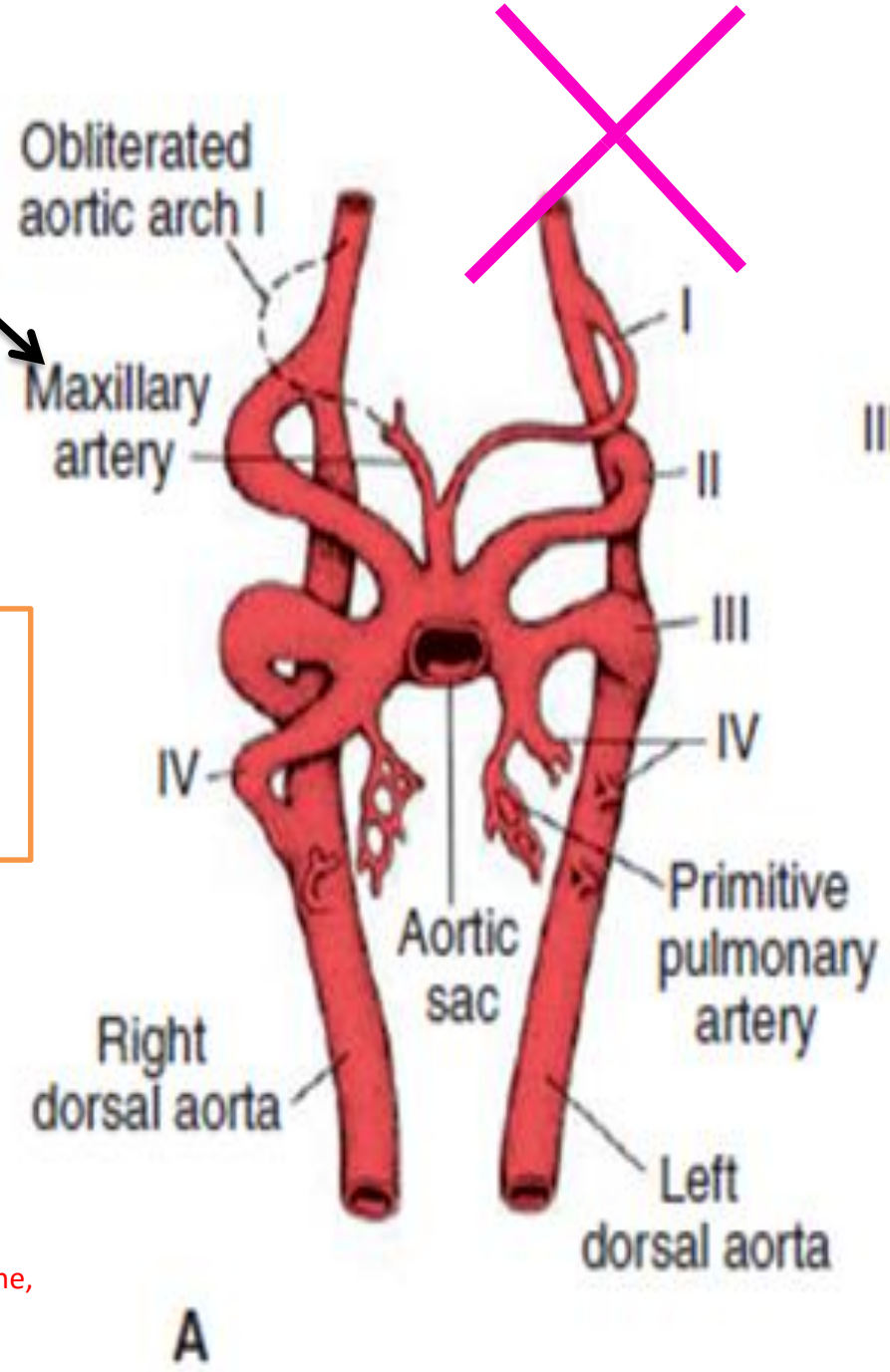

Derivatives of Third Pair of Pharyngeal Arch Arteries

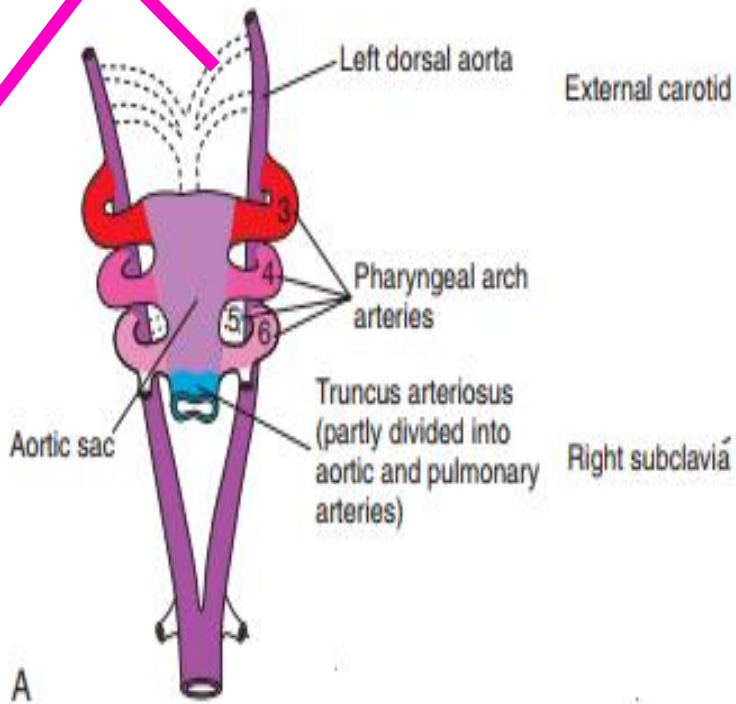

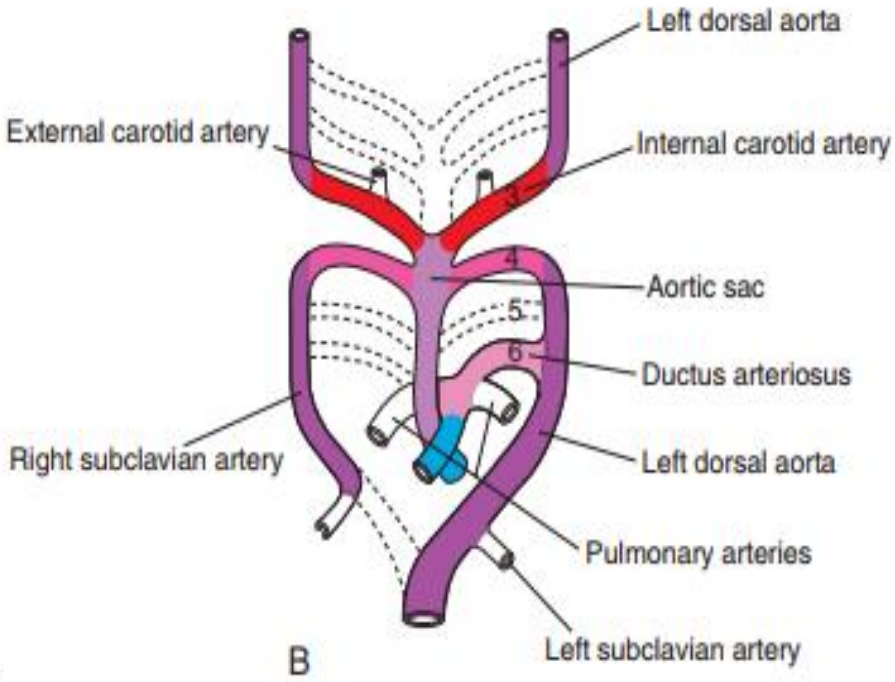

<u>Proximal parts</u> of these arteries form

THE COMMON CAROTID ARTERIES

<u>Distal parts</u> of these arteries join with **<u>the dorsal aortae</u>** to form

THE INTERNAL CAROTID ARTERIES

Dr. Amjad Shatarat, School of Medicine,
The University of Jordan

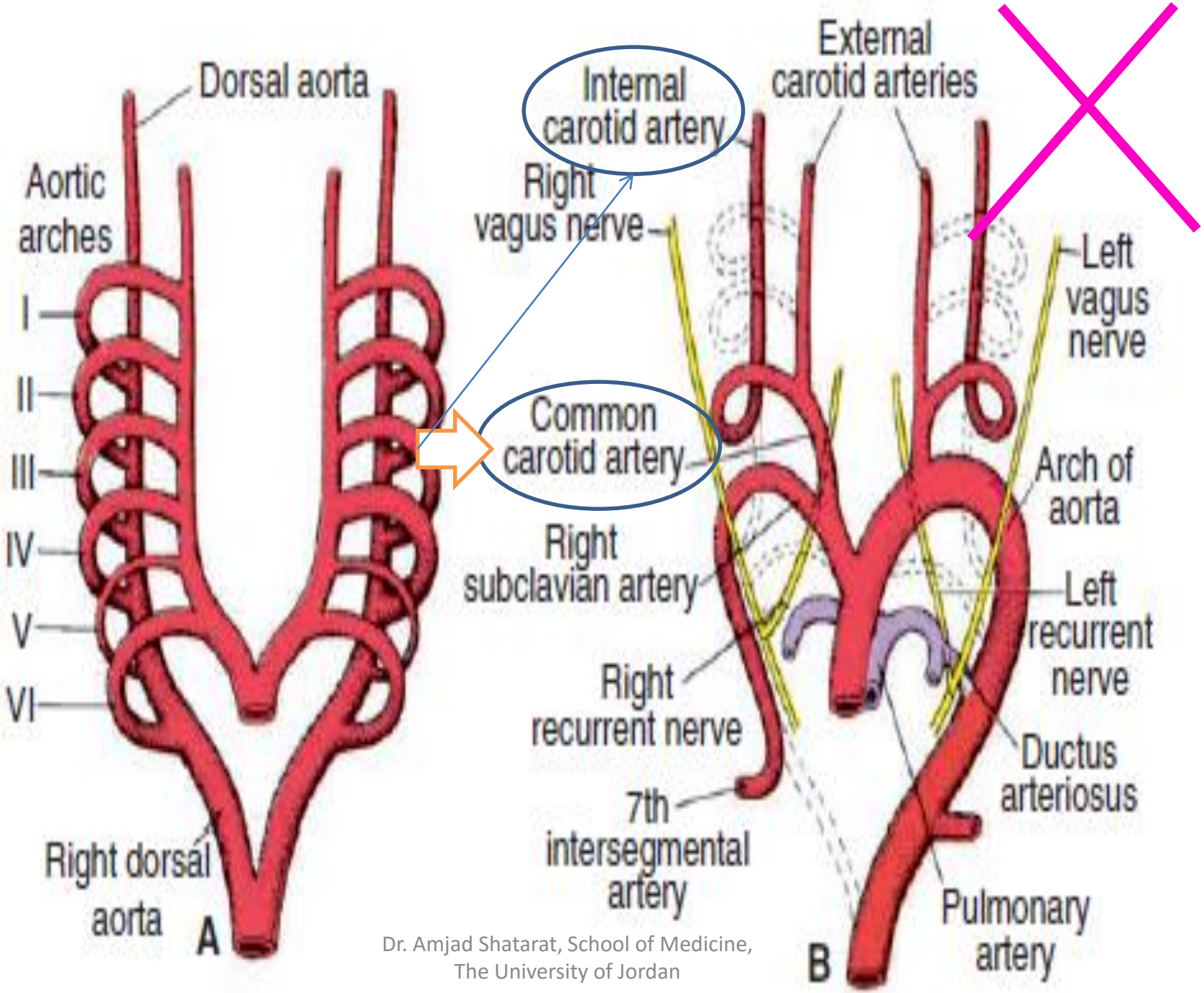
Dorsal aorta
Aortic arches
I
II
III
IV
V
VI
Right dorsal aorta
A
Internal carotid artery
Right vagus nerve
Common carotid artery
Right subclavian artery
Right recurrent nerve
7th intersegmental artery
External carotid arteries
Left vagus nerve
Arch of aorta
Left recurrent nerve
Ductus arteriosus
Pulmonary artery
B

Derivatives of Fourth Pair of Pharyngeal Arch

- The fourth aortic arch persists on both sides, but its ultimate fate is different on the right and left sides.

On the left, it forms **part of the arch of the aorta**, between the left common carotid and the left subclavian arteries.

On the right, it forms the most proximal segment of **the right subclavian artery**, the distal part of which is formed by a portion of the right dorsal aorta and the seventh intersegmental artery .

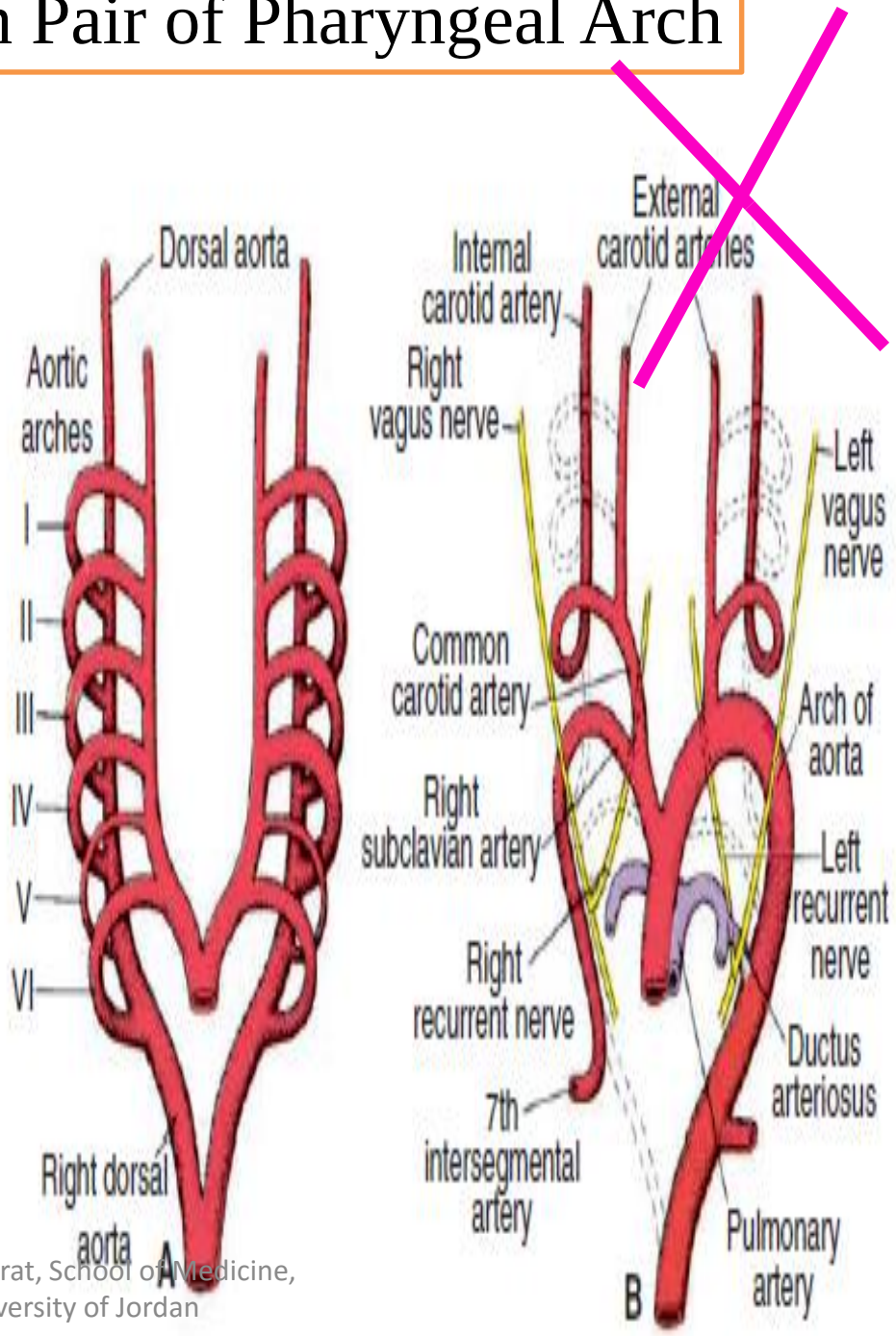

ARCH of the Aorta

1-The proximal part of the arch artery develops **from the aortic sac**

2- **left fourth aortic arch** , it forms part of the arch of the aorta, between the left common carotid and the left subclavian arteries.

the distal part is derived from the left **dorsal aorta**

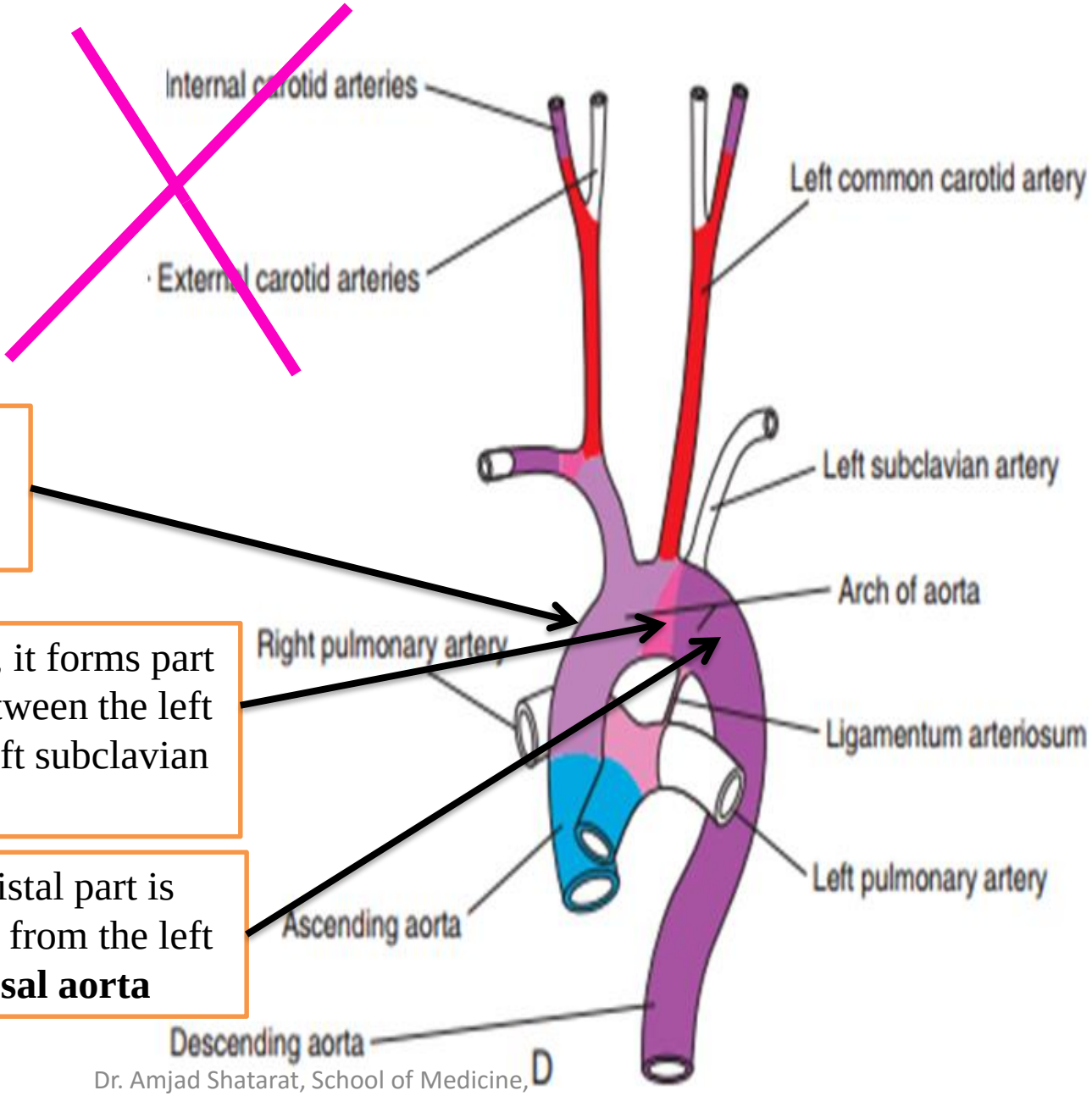

Dr. Amjad Shatarat, School of Medicine,
The University of Jordan

~~The **fifth aortic arch either never forms or forms incompletely** and then **regresses**.~~

the sixth aortic arch is different in left side from the right side.

The **sixth aortic arch**

also known as the pulmonary arch, gives off an important branch that grows toward the developing lung bud .

*On **the right side**, the **proximal** part* becomes the proximal segment of the **right pulmonary artery**.

The **distal portion** of this arch loses its connection with the dorsal aorta and **disappears**.

On **the left**, the distal part **persists** during intrauterine life as

THE DUCTUS ARTERIOSUS

The proximal part of the artery persists as the proximal part of the left pulmonary artery

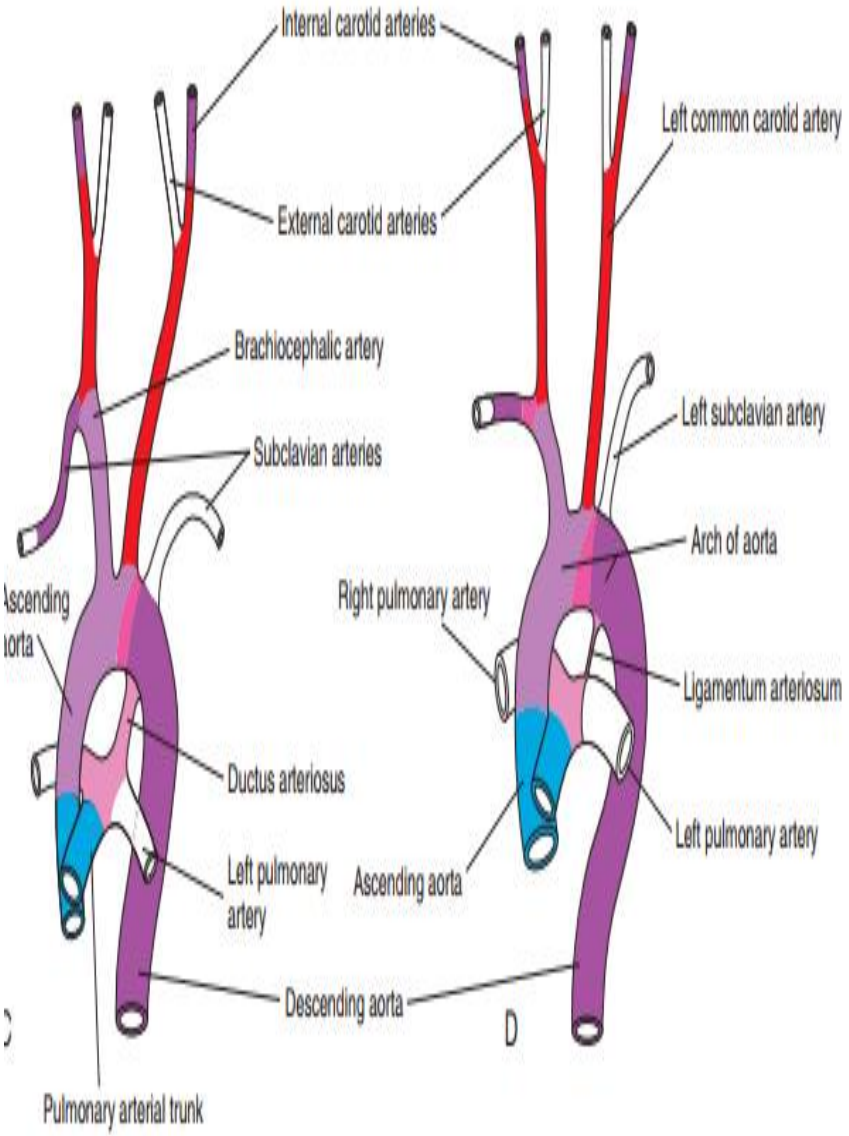

not for memorizing.

Arch	Arterial Derivative
1	Maxillary arteries
2	Hyoid and stapedial arteries
3	Common carotid and first part of the internal carotid arteries[a]
4 Left side	Arch of the aorta from the left common carotid to the left subclavian arteries[b]
Right side	Right subclavian artery (proximal portion)[c]
6 Left side	Left pulmonary artery and ductus arteriosus
Right side	Right pulmonary artery

- The vitelline arteries, initially a number of paired vessels supplying the yolk sac

- gradually fuse and form the arteries in the dorsal mesentery of the gut

- In the adult, they are represented by the ***celiac and superior mesenteric, arteries***.

- The inferior mesenteric arteries are derived ***from the umbilical arteries***.

Vitelline and Umbilical Arteries

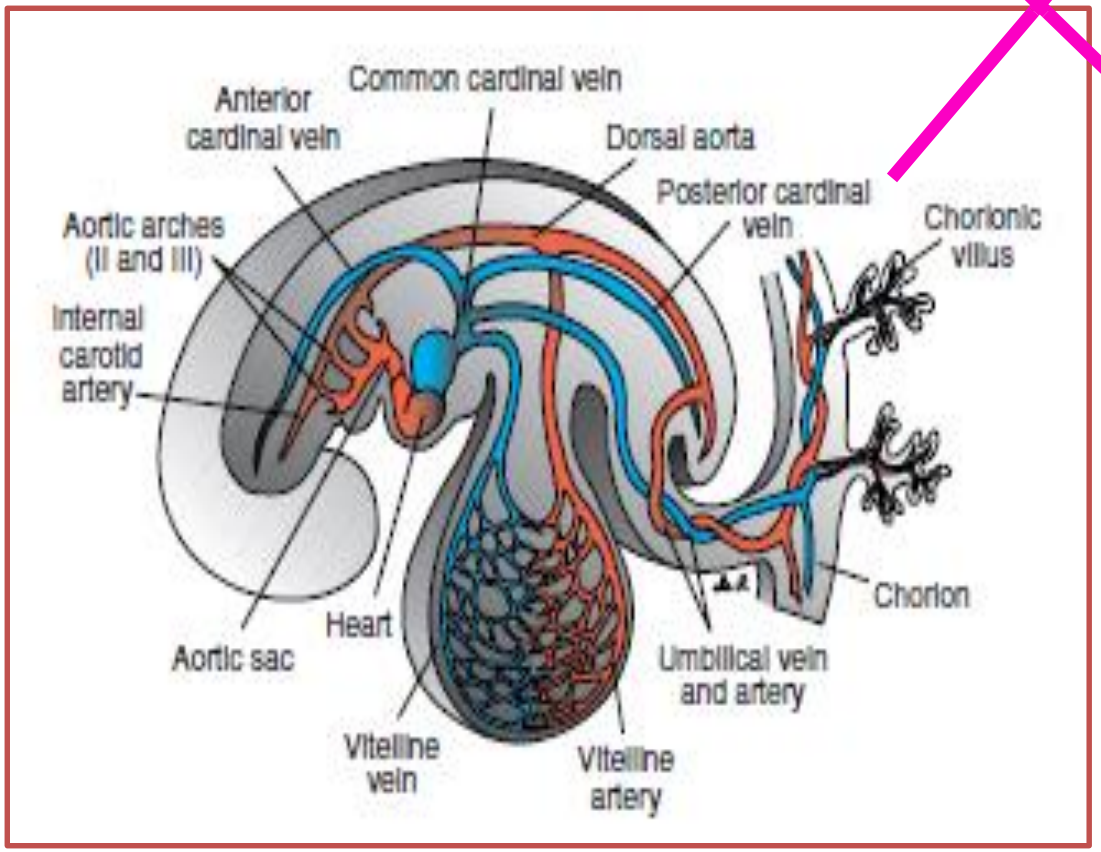

- These 3 vessels supply derivatives of

the foregut, midgut, and hindgut, respectively

The **umbilical arteries**

- The umbilical arteries, initially paired ventral branches of the dorsal aorta,
- course to the placenta in close association with the allantois .
- During the fourth week, each artery acquires a secondary connection with the dorsal branch of the aorta, the common iliac artery, and loses its earliest origin.

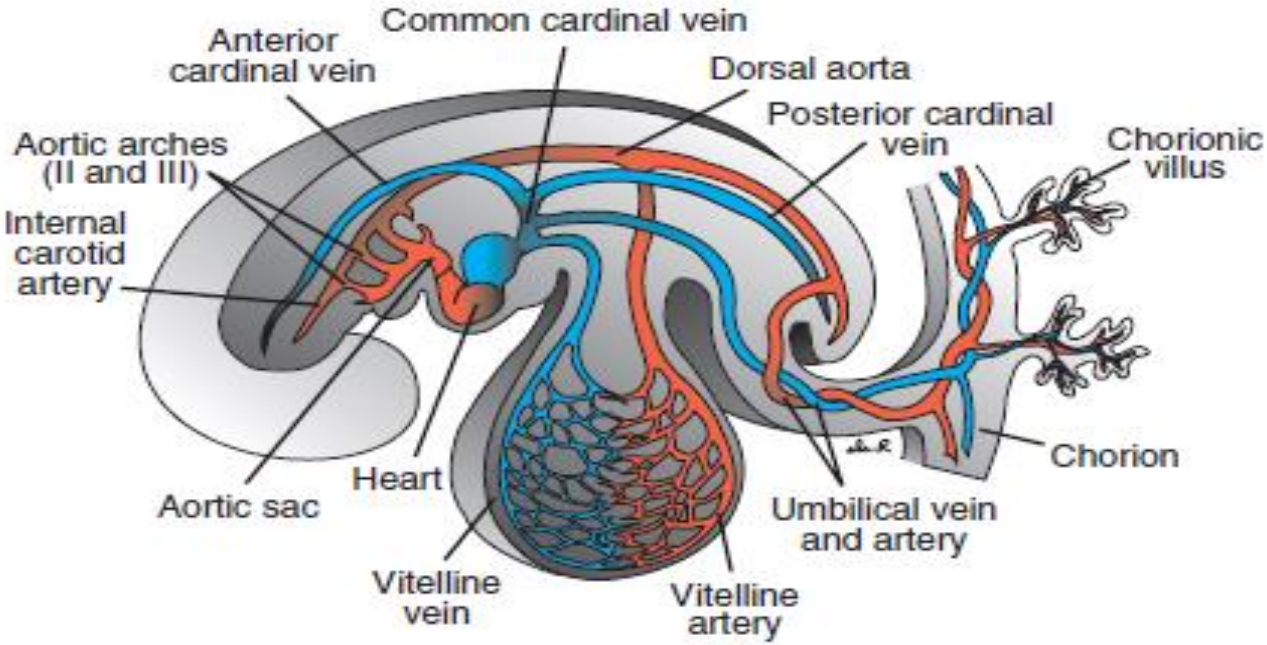

Figure 13.35 Main intraembryonic and extraembryonic arteries (*red*) and veins (*blue*) in a 4-mm embryo (end of the fourth week). Only the vessels on the left side of the embryo are shown.

Ductus Arteriosus and Ligamentum Arteriosum

means blood would not be shunted from the pulmonary trunk towards the aortic because of high pressure in the aorta.

- Functional closure of the DA is usually completed 10 to 15 hours after birth.
- Anatomical closure of the DA and formation of the ligamentum arteriosum usually occurs by the 12th postnatal week

it take more time than the closure of foramen ovale .

what if it is not closed ??

in some physiological intrauterine conditions, the blood is shunted from pulmonary artery to aorta by ductus arteriosus . But if the ductus arteriosus remains open after birth the opposite would happen ..

Dr. Amjad Shatarat, School of Medicine,
The University of Jordan

means opened

Patent ductus arteriosus (PDA)

a common birth defect, occurs two to three times more frequently in females than in males
Functional closure of the PDA usually occurs soon after birth; however, if it remains patent (open), aortic blood is shunted into the pulmonary artery

PDA is the most common birth defect associated with **maternal rubella infection during early pregnancy**. **Preterm neonates** and those born at high altitude may have PDA; this patency is the result of hypoxia **(decrease of oxygen)** and immaturity.
The embryologic basis of PDA is failure of the DA to involute after birth and form the ligamentum arteriosum

any condition causes hypoxia it may cause PDA

the doctor say I will not ask about it on the exam .but of course you will be asked about it on the next year so read it.

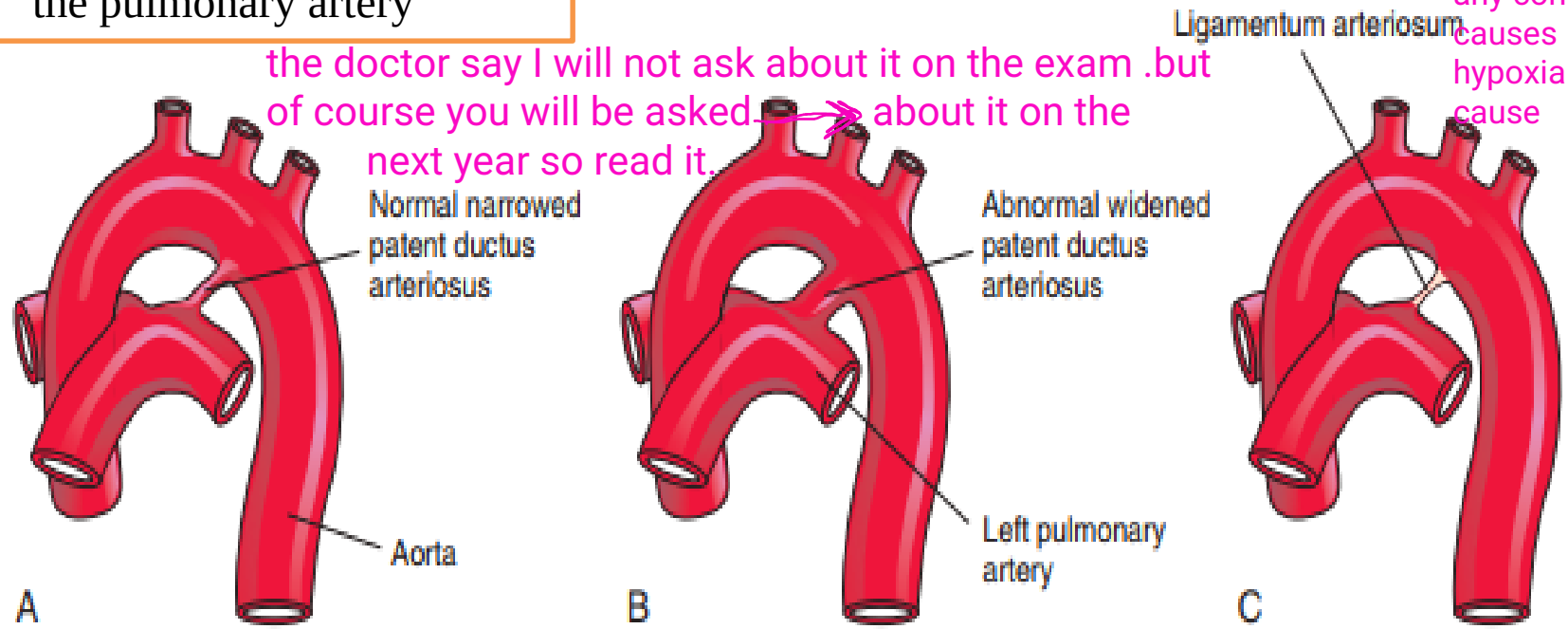

Figure 14–34 Closure of the ductus arteriosus (DA). A, The DA of a neonate. B, Abnormal patent DA in a 6-month-old infant. C, The ligamentum arteriosum in a 6-month-old infant.

Dr. Amjad Shatarat, School of Medicine, The University of Jordan

Coarctation of the aorta

which means that the right brachiocephalic trunk and left common carotid and left subclavian. all of them get normal flow of blood so the head and neck and upper limbs get normal amount of blood.

- ❖ is a congenital narrowing of the aorta just ***proximal***, ***opposite,*** or ***distal*** to the **site of attachment of the ligamentum arteriosum**..

- ❖ However, most constrictions occur distal to the origin of the left subclavian artery, at the entrance of the DA **(juxtaductal coarctation).**

- ❖ occurs in approximately 10% of children with CHDs. (congenital heart disease)

A classification system of preductal and postductal coarctations is commonly used; however, in 90% of cases, the coarctation is directly opposite the DA. Coarctation occurs two times as often in males as in females,

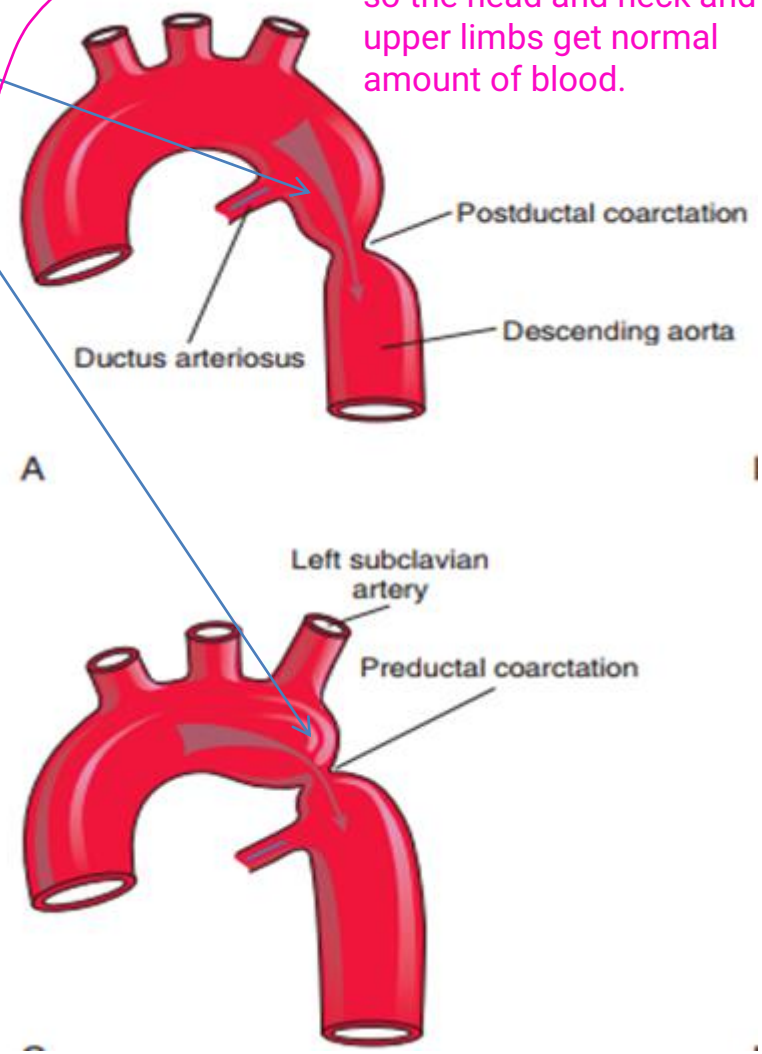

Cause: this condition is believed to result from an unusual quantity of ductus arteriosus muscle tissue in the wall of the aorta.

When the ductus arteriosus contracts, the ductal muscle in the aortic wall also contracts, and the aortic lumen becomes narrowed. Later, when fibrosis takes place, the aortic wall also is involved, and permanent narrowing occurs

Clinically, the cardinal sign of aortic coarctation is **absent or diminished pulses in the femoral arteries of both lower limbs**.

not on one lower limb .because you may get a patient complains about different complications such as isc emic disease but on one foot not on both

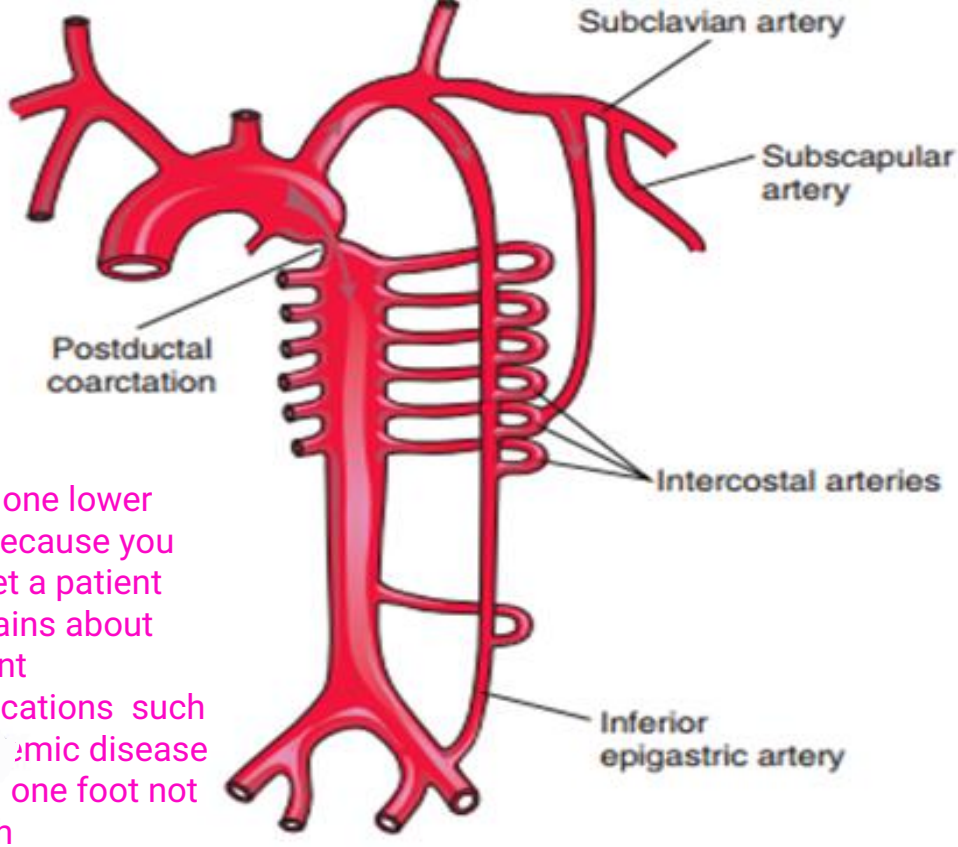

To compensate for the diminished volume of blood reaching the lower part of the body, an enormous **collateral circulation develops, with dilatation of the internal thoracic, subclavian, and posterior intercostal arteries.** The dilated intercostal arteries erode the lower borders of the ribs, producing characteristic notching, which is seen on radiographic examination. The condition should be treated surgically

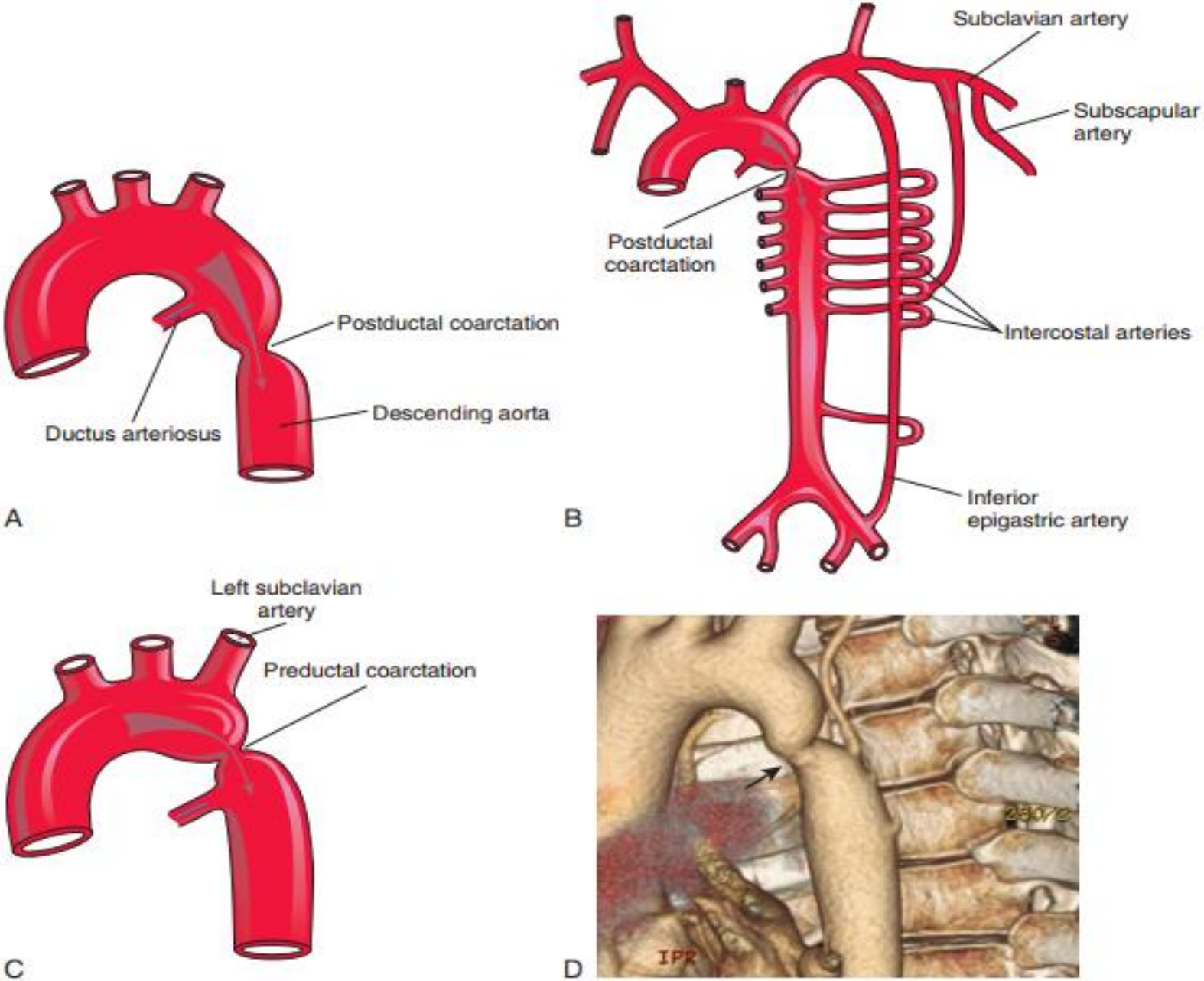

Figure 14–28 **A,** Postductal coarctation of the aorta. **B,** Common routes of the collateral circulation that develop in association with postductal coarctation of the aorta. **C,** Preductal coarctation. *Arrows* indicate flow of blood. **D,** Preductal coarctation *(arrow)* in the aorta in an adult.

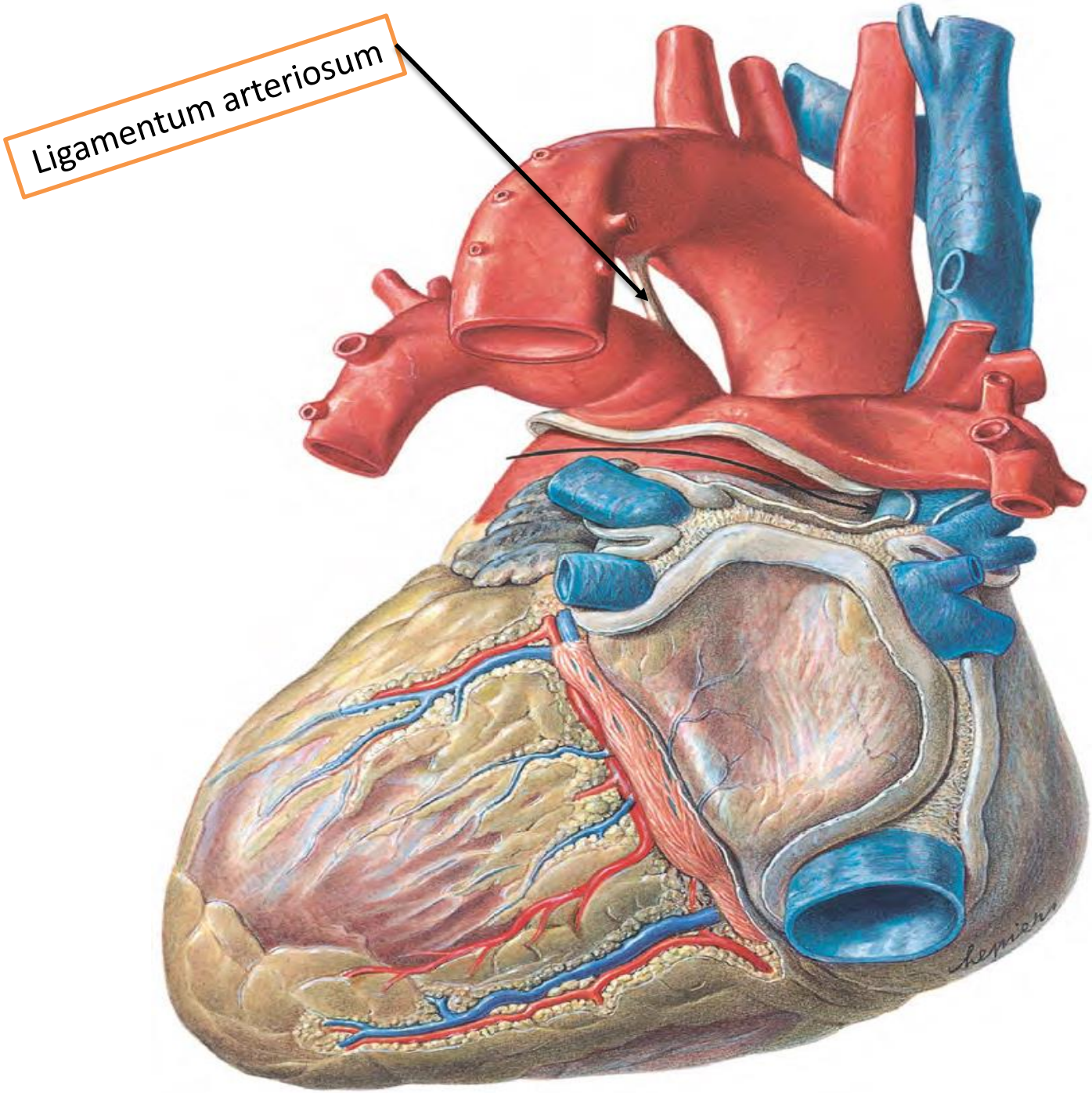
Ligamentum arteriosum

FETAL CIRCULATION

Dr. Amjad Shatarat, School of Medicine,
The University of Jordan

Arterial systems associated with the fetal heart

During fetal circulation,

- oxygenated blood flood from the placenta to the fetus passes through ***the umbilical vein***.
- Three vascular shunts develop in the fetal circulation to bypass blood flow around the liver and lungs
- **The ductus venosus** allows oxygenated blood in the umbilical vein to bypass the sinusoids of the liver into the inferior vena cava and to the right atrium.
- From the right atrium, oxygenated blood flows mostly through the **foramen ovale** into the left atrium then left ventricle and into the systemic circulation.
- The foramen ovale develops during atrial septation to allow oxygenated blood to bypass the pulmonary circulation. Note that this is a right-toleft shunting of blood during fetal life.
- During fetal circulation, the superior vena cava drains deoxygenated blood from the upper limbs and head into the right atrium. Most of this blood flow is directed into the right ventricle and into the pulmonary trunk.
- **The ductus arteriosus** opens into the underside of the aorta just distal to the origin of the left subclavian artery and shunts this deoxygenated blood from the pulmonary trunk to the aorta to bypass the pulmonary circulation

fetal circulation

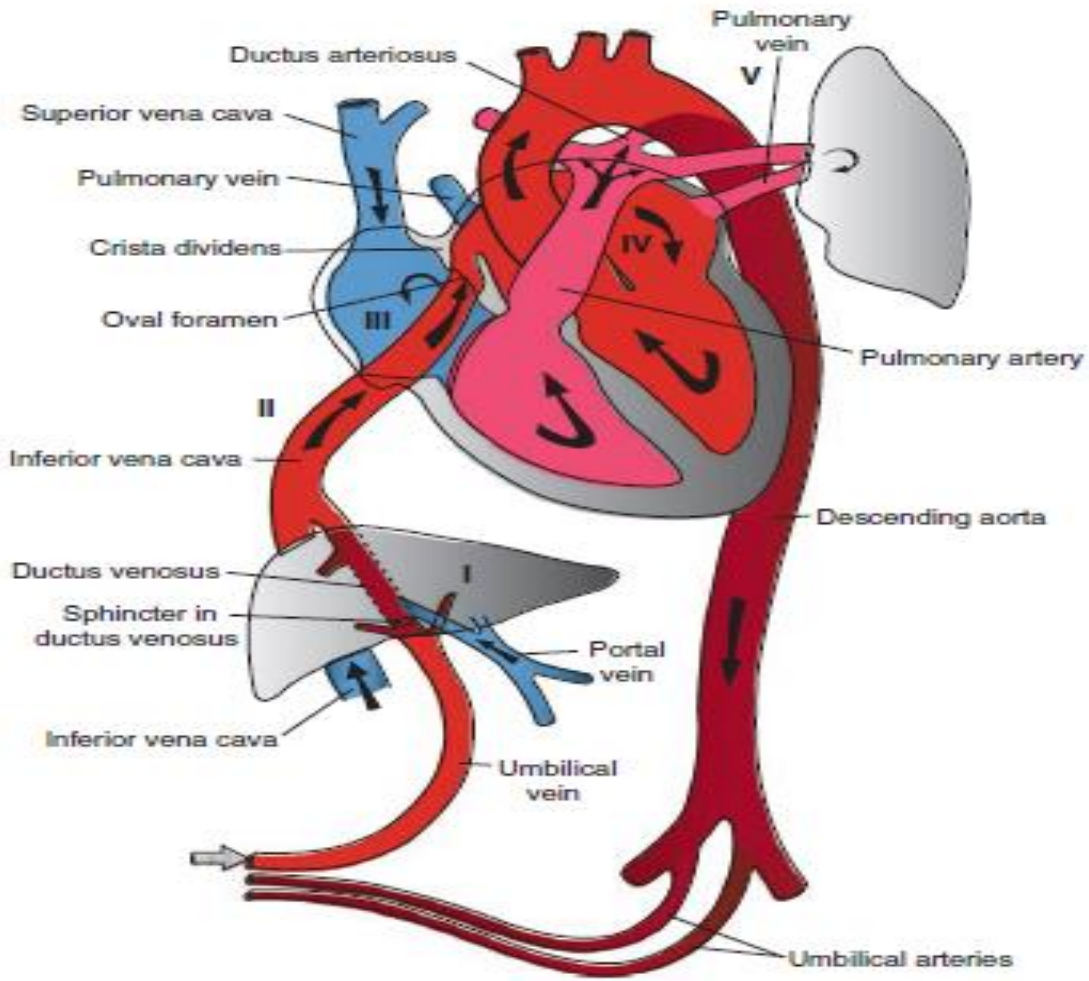

Figure 13.49 Fetal circulation before birth. *Arrows*, direction of blood flow. Note where oxygenated blood mixes with deoxygenated blood in: the liver (*I*), the inferior vena cava (*II*), the right atrium (*III*), the left atrium (*IV*), and at the entrance of the ductus arteriosus into the descending aorta (*V*).

Dr. Amjad Shatarat, School of Medicine,
The University of Jordan

Circulatory Changes at Birth

- **During prenatal life, the** placental circulation provides the fetus with its oxygen, but after birth, the lungs take on gas exchange.
- In the circulatory system, the following changes take place at birth and in the first postnatal months:
- (1) the ductus arteriosus closes
- (2) the oval foramen closes
- (3) the umbilical vein and ductus venosus close and remain as the **ligamentum teres hepatis and ligamentum venosum**
- **(4) the umbilical arteries form** the **medial umbilical ligaments.**

Dr. Amjad Shatarat, School of Medicine,
The University of Jordan

Ligamentum arteriosum

ligamentum venosum

ligamentum teres hepatis

the umbilical arteries form the **medial umbilical ligaments.**

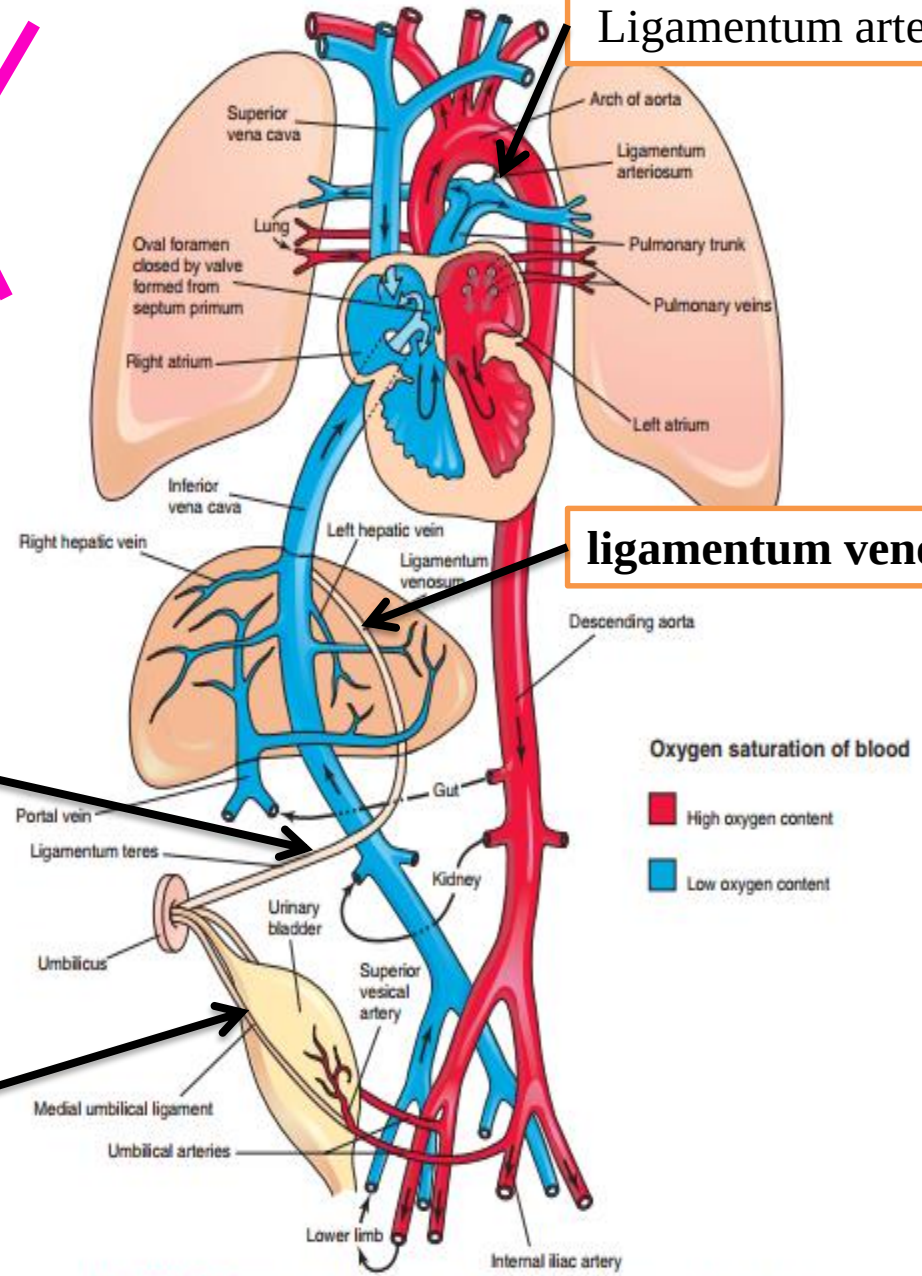

Figure 14–33 Neonatal circulation. The adult derivatives of the fetal vessels and structures that become nonfunctional at birth are shown. The arrows indicate the course of the blood in the infant. The organs are not drawn to scale. After birth, the three fetal shunts cease to function, and the pulmonary and systemic circulations become separated.

Dr. Amjad Shatarat, School of Medicine,
The University of Jordan

انتهى بحمد الله

The End
Thank you

Dr. Amjad Shatarat, School of Medicine,
The University of Jordan

Development of Major Blood Vessels

Venous system

Dr. Amjad Shatarat, 2019 School of Medicine, The University of Jordan

Remember that the sinus venosus has two horns

is a part of cardiac tube

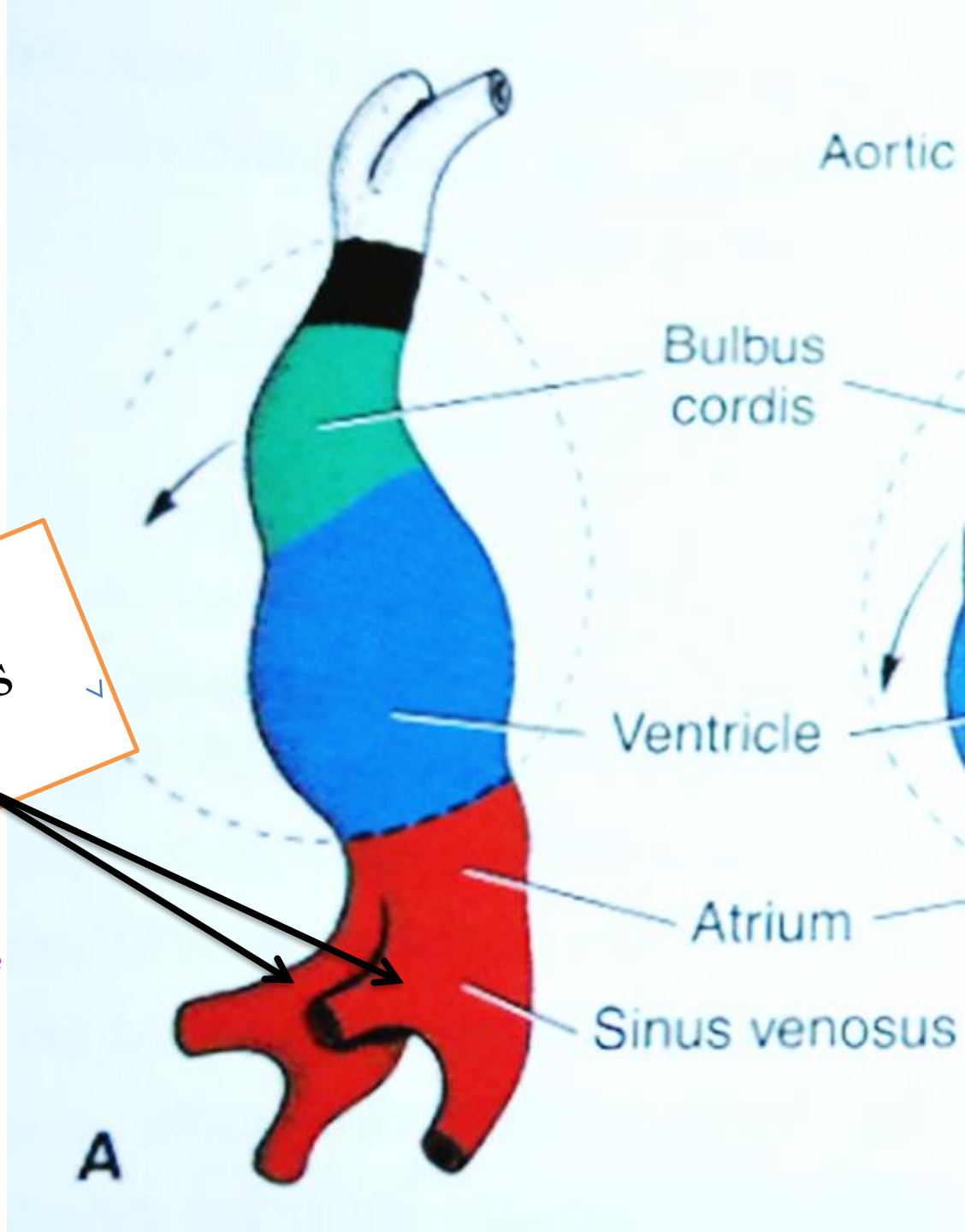

Dr. Amjad Shatarat, 2019 School of Medicine, The University of Jordan

<u>The sinus venosus represent the venous end</u> of the heart

It receives 3 veins:

1- Common cardinal vein → body wall

2- Umbilical vein → from placenta

3- Vitelline vein → from yolk sac

it is a pair vein which means we have right and left coomon cardinal veins . each one of the common cardinal vein is made by the union of anterior and posterior cardinal vein

right and left vitelline veins

**we have right and left umbilical veins . put one of them would disappear.
**called veins however they carry oxygenated blood

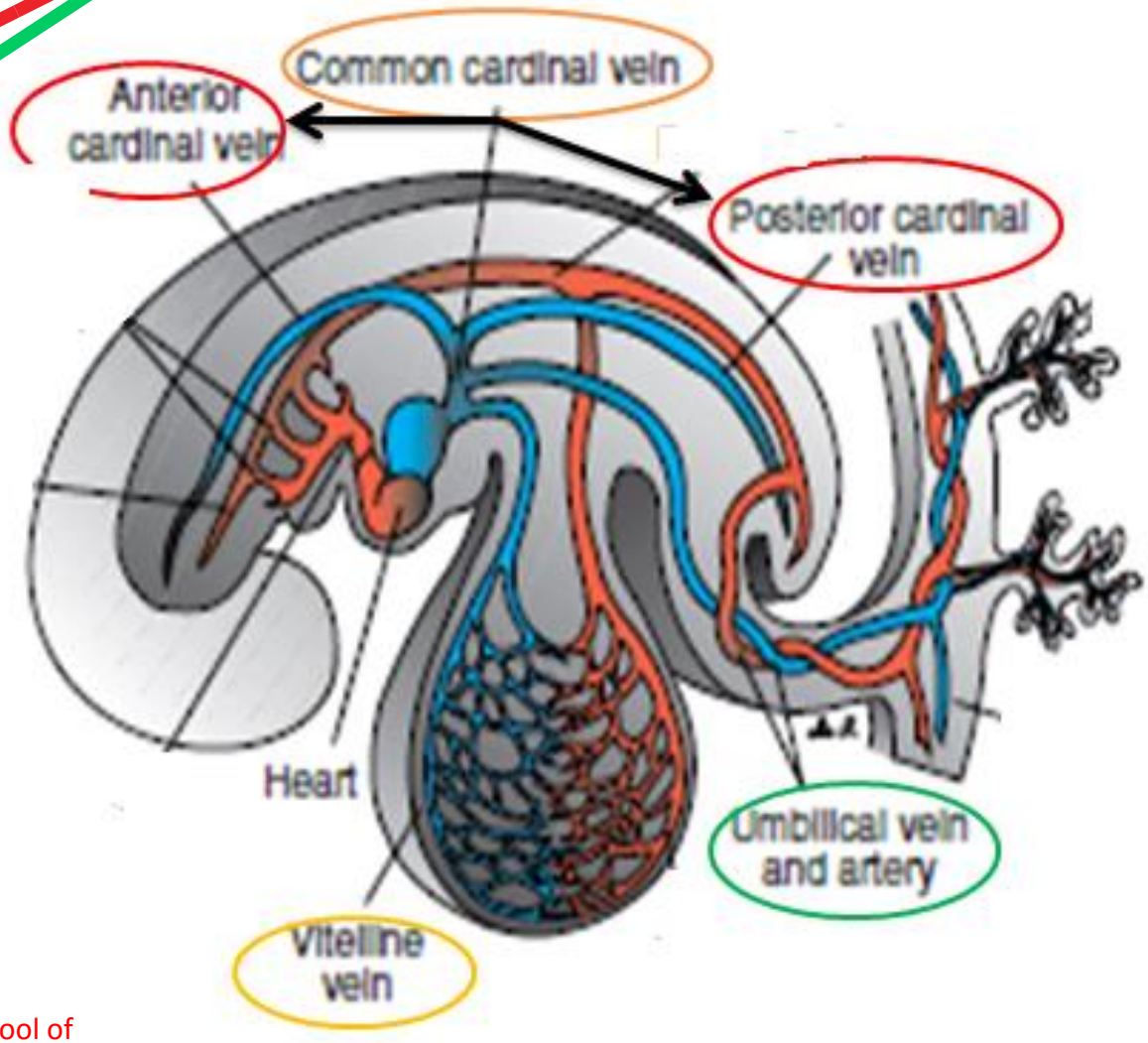

However!!!!!

The left sinus horn of the **sinus venosus** is loosing its importance and blood from the left side is **rechanneled** toward the ***right***

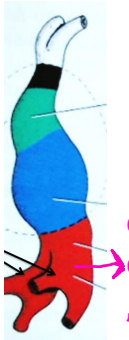

one of these horns
eventually would disappear
, exactly the left one

Why the left sinus horn looses Its importance????

Dr. Amjad Shatarat, 2019 School of Medicine,
The University of Jordan

Due to

left-to-right shunts of blood

1-The first left-to-right shunt is a result of the transformation of both vitelline and umbilical veins

this mean the vitelline and the umbilical veins on the left side would transform and part of them would disappear becoming a different thing. and their partners on right side would take over and become the only venous drainage of corresponding areas.

2-The second left-to-right shunt occurs when the left anterior cardinal vein becomes connected To the right anterior cardinal vein by an oblique anastomosis

????????

this means that the venous system on the left side of the body would be interrupted and redirected. how??? we will take about it in a moment

there are other 3 veins on the other side of embryo

Transformation of the vitelline veins

A- Vitelline Veins (omphalomesenteric) veins

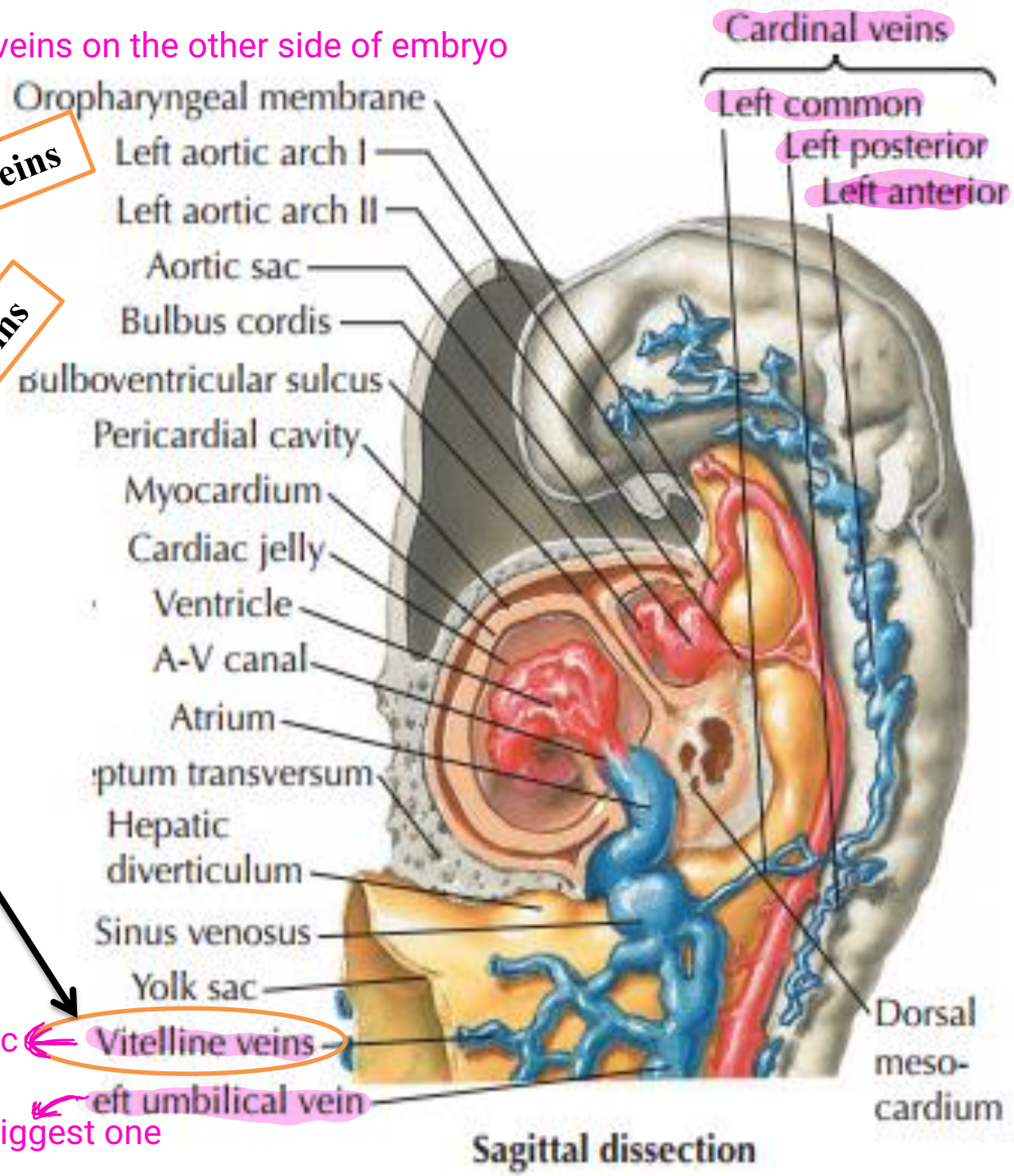

coming from yock sac

biggest one

Dr. Amjad Shatarat, 2019 School of Medicine, The University of Jordan

we sayed in the last lecture that the left sinus venosus disappear and what remains from the left horn of sinus venosus is nothing but coronary sinus as well as the oblique vein of the left atrium.
which mean all veins were connected to it (like left vitelline vein ,left umbilical vein and left cardinal vein) also would disappear

Vitelline Veins (omphalomesenteric) veins

1-The vitelline veins form a plexus around the developing duodenum then it enters **the sinus venosus**

the vitelline vein is made of 3 part
distal
middle
proximal

2-The growing liver cords interrupt the course of the vitelline veins, and incorporate it and form an extensive vascular network

only the middle vitelline

Called

THE HEPATIC SINUSOIDS

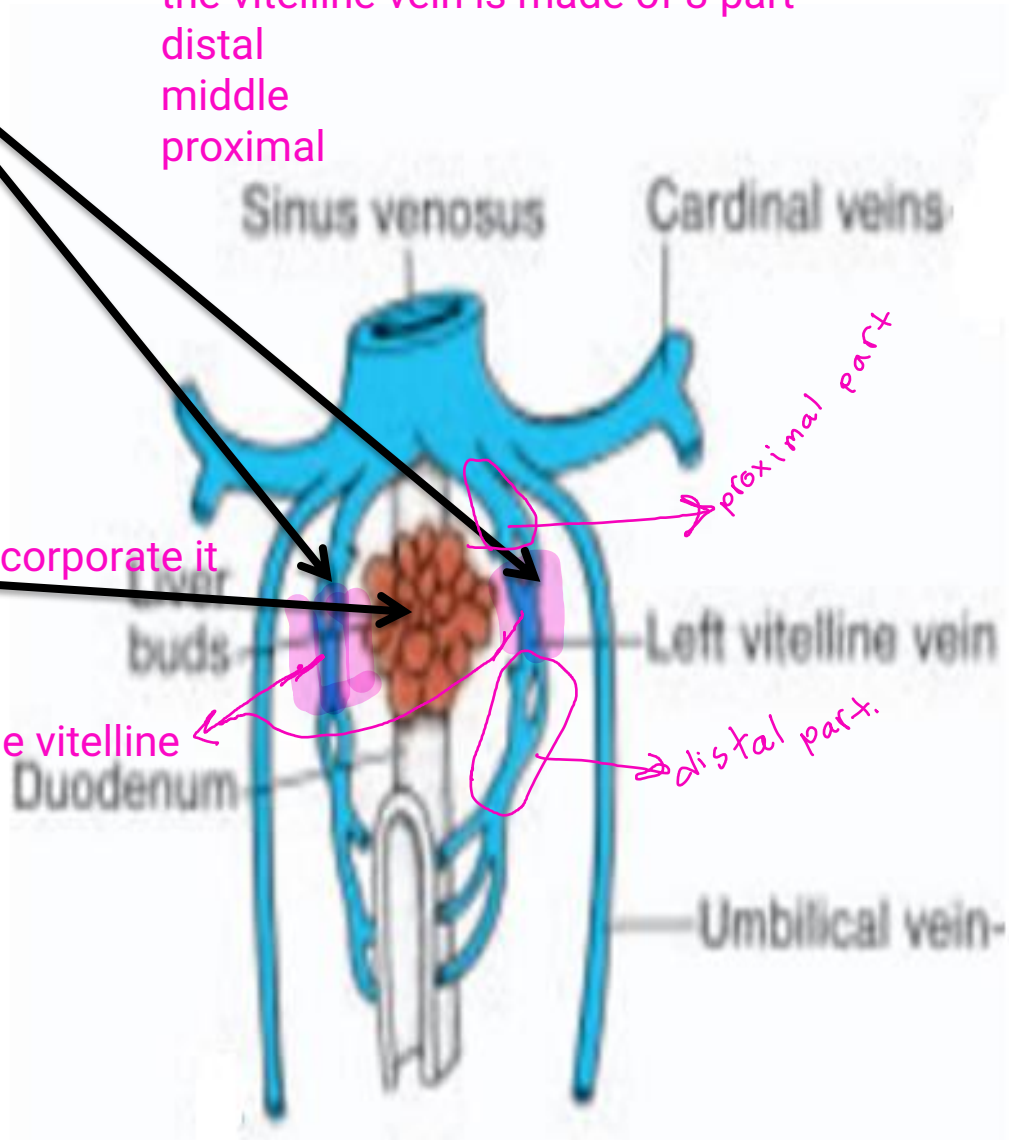

so what about distal and proximal part??
let's take about its future

Dr. Amjad Shatarat, 2019 School of Medicine, The University of Jordan

THE HEPATIC SINUSOIDS

What is the origin of the HEPATIC SINUSOIDS?

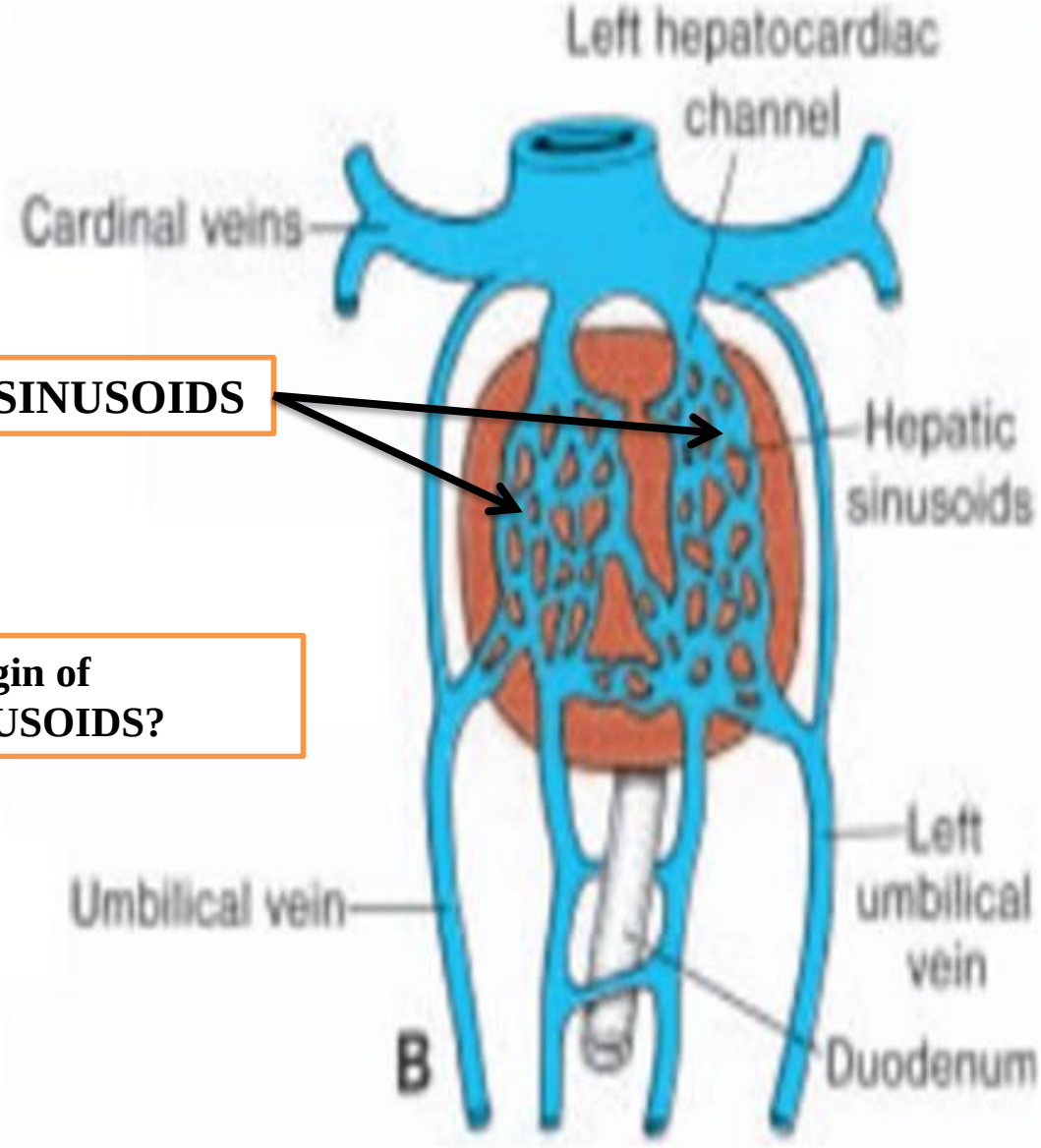

It should be noted that at this time **the left sinus horn** of the sinus venosus is loosing its importance and blood from the left side of the liver is rechanneled toward the right, resulting in an enlargement of the right vitelline vein

Also called

(right hepatocardiac channel)

Notice how the left vitelline vein Is redirected to the right vitelline vein which is in its turn getting bigger

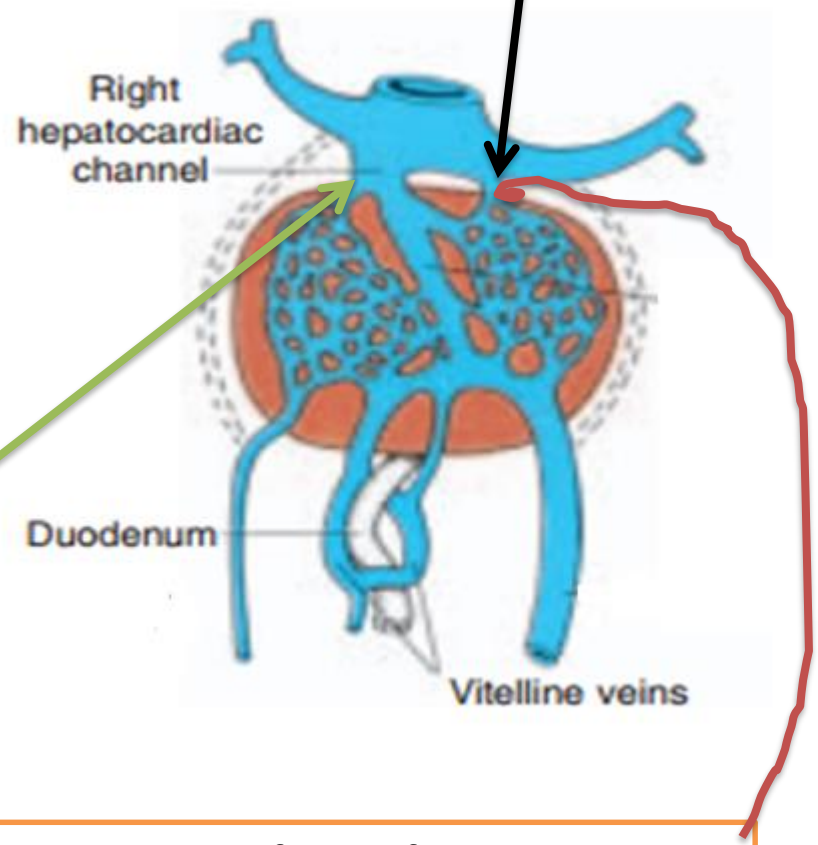

3-The right hepatocardiac channel forms the hepatocardiac portion of

<u>The inferior vena cava</u>

4-The proximal part of the left vitelline vein disappears

what you need to know : that we are loosing the left vitelline vein and this means that the right vitelline would take over and becomes bigger.
the right hepatic channel would take over. what does this mean ??
this means if this is left vitelline vein, the middle part is incorporated inside lever .at the same time the left vitelline vein itself is becoming smaller and smaller .so who is taking the lead ?? the right vitelline vein .and that's why the proximal part of right vitelline woud connect the heart to the lever . if I ask you which part of the venous system of your body connect the liver to the heart??the answer is the inferior vena cava (it passes behind the liver and as it does it , tow to three hepatic veins join the inferior vena cava . so there is a close relationship between the liver and IVC and if you understood this part you should now understand why the right vitelline vein contributes to the formation of IVC .
ofcourse the IVC is a huge long vein with three part one in the pelvis the other one is around the kidneys (renal)and the last one is called the hepatocardiac channel which becomes the hepatocardiac portion of the IVC .
ok, so what we have here is very simple transformation , each vitelline vein has 3 part (proximal ,middle and distal) .the middle one gives the hepatic sinusoid .now in the left side : the proximal part disappears ,it loses its connection so the left vitelline vein from now is not connected to sinus venosus so it can't convey blood from the liver to the sinus venosus to heart. and by doing this , al the vein within the liver should go from the left side towards the right side .so the right vitelline becomes bigger and bigger . now if we go to proximal part of right vitelline (which also called the hepatocardiac channel) is the hepatocardiac portion of IVC

5- The anastomotic network around the duodenum develops into a single vessel,

The portal vein

6- The **superior mesenteric vein,** which drains the primary intestinal loop, derives **from the right vitelline vein**

middle part of vitelline vein contributes to the formation of hepatic sinusoid

proximal part of right vitelline

proximal part of left vitelline which disappeared

the distal part of vitelline vein transforms into a single portal vein and mesenteric vein

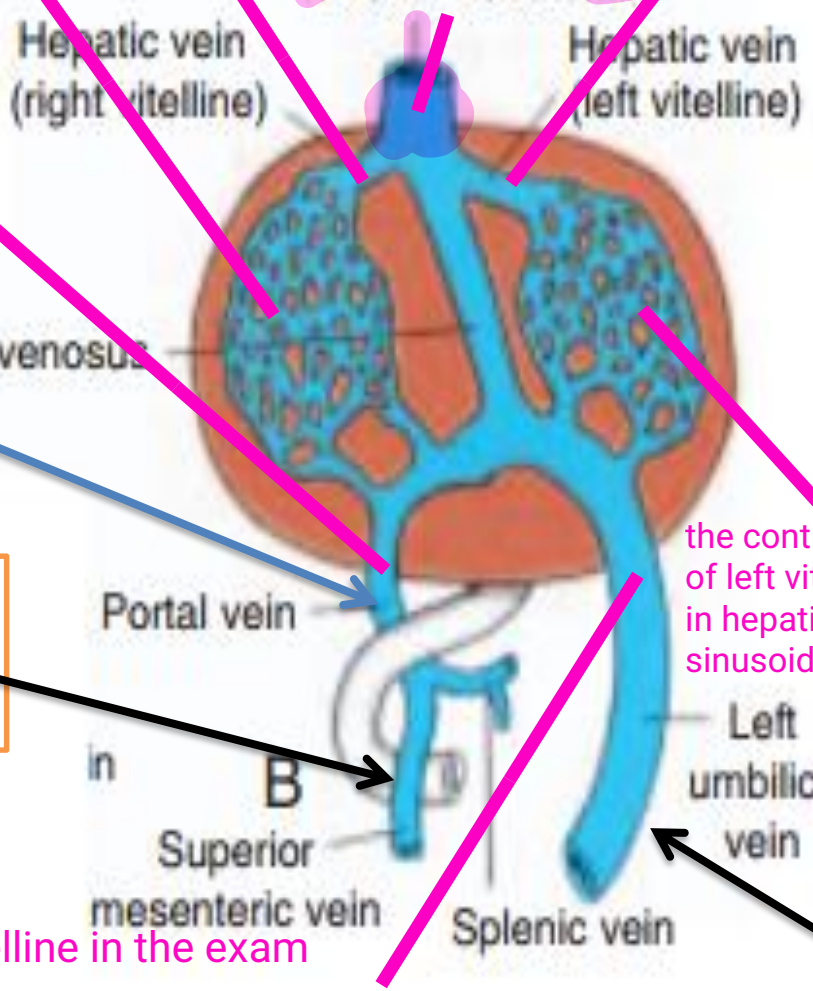

the contribution of left vitelline in hepatic sinusoid

the doctor says that he will ask about the right vitelline in the exam

7- The distal portion of the left vitelline vein also disappear

Dr. Amjad Shatarat, 2019 School of Medicine, The University of Jordan

remember that portal vein is formed by the union of splenic vein coming from the spleen and superior mesenteric vein. so there is a connection between superior mesenteric vein and portal vein.

You should know by now;
1-the origin of all of the following:

Right vitelline vein

- **THE HEPATIC SINUSOIDS**
- The hepatocardiac portion of **the inferior vena cava**
- **The portal vein**
- The **superior mesenteric vein**

you should understand that one leads to another.
the left horn of sinus venosus disappeared.
why?? because the left vitelline disappeared as the doctor just mentioned

2- what is the fate of the left vitelline vein

the middle portion of left vitelline contributed to the hepatic sinusoid

Left vitelline vein

- The proximal part of the left vitelline vein disappear
- The distal portion of the left vitelline vein also disappear

Transformation of the umbilical veins

B-Umbilical Veins

1-Initially the umbilical veins pass on each side of the liver

3-The proximal part of both umbilical veins disappear

No connection between the sinus venosus and the umbilical veins

How they will connect?

2-Some connect to the hepatic sinusoids

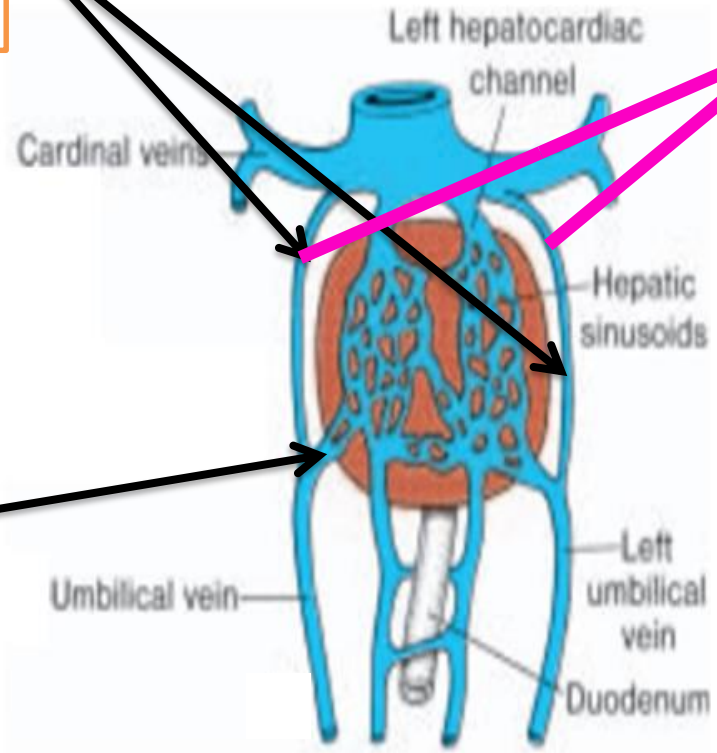

A

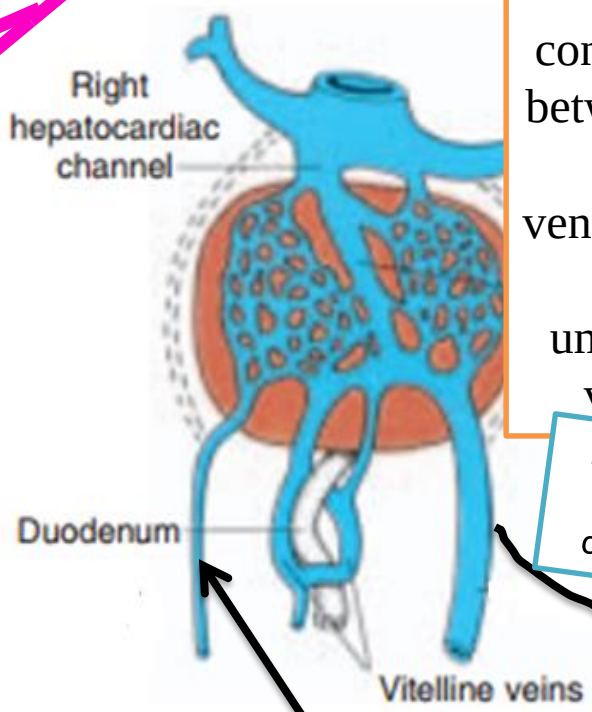

B

4-The remainder of the right umbilical vein then disappear, so that **the left vein** is **the only one** to carry blood from the placenta to the liver

Compare between umbilical veins in A and B

Dr. Amjad Shatarat, 2019 School of Medicine, The University of Jordan

both umbilical veins bring oxygenated blood (arterial blood)even if the name is vein.
so if they lose its proximal portion suddenly. this mean no connection between them and sinus venosus. which mean no oxygenated blood coming to sinus venosus which is the first part of cardiac tube so no oxygenated blood coming the heart!!!!

5-With the increase of the placental circulation, a direct communication forms between
the left umbilical vein
and
the right hepatocardiac channel
To Form

The ductus venosus

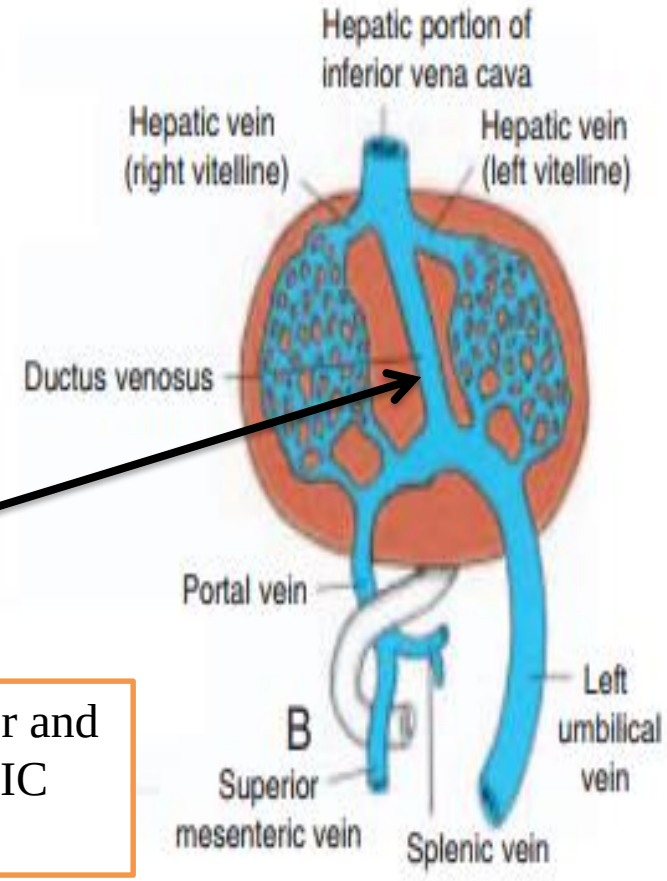

This vessel bypasses the sinusoidal plexus of the liver and directly connects the left umbilical vein to HEPATIC PORTION OF THE INFERIOR VENA CAVA

6- After birth the left umbilical vein and ductus venosus are **obliterated**

left umbilical vein forms…….. the ligamentum teres hepatis

ductus venosus forms……the ligamentum venosum

why does the left horn of sinus venosus is getting smaller and smaller ??
because the chande of its tributaries so the left vitelline vein disappeared and the left umbilical lose its connection to left horn of sinus venosus and make anew connection with right hepatocardiac channel then to inferior vena cava then to the right atrium.

at the moment of the embryo birth we ligate the umbilicus ,inside the umbilicus there is the only remaining left umbilical vein ,the source of all oxygenated blood. this should be ligated. when it is ligated and there is no blood inside it ,the pressure falls and with time it transform to ligamentum teris hepatis.
then , if there is no blood in umbilical, there is no blood going to ductus venosus, so it transform to ligamentum venosum .

note :ductus venosus located inside the liver and called venosus because it connect tow veins. don't forget it contains arterial blood but named vein because of the direction of blood flow (the veins going to heart while the arteries coming from heart.
also we have ductus arteriosus.

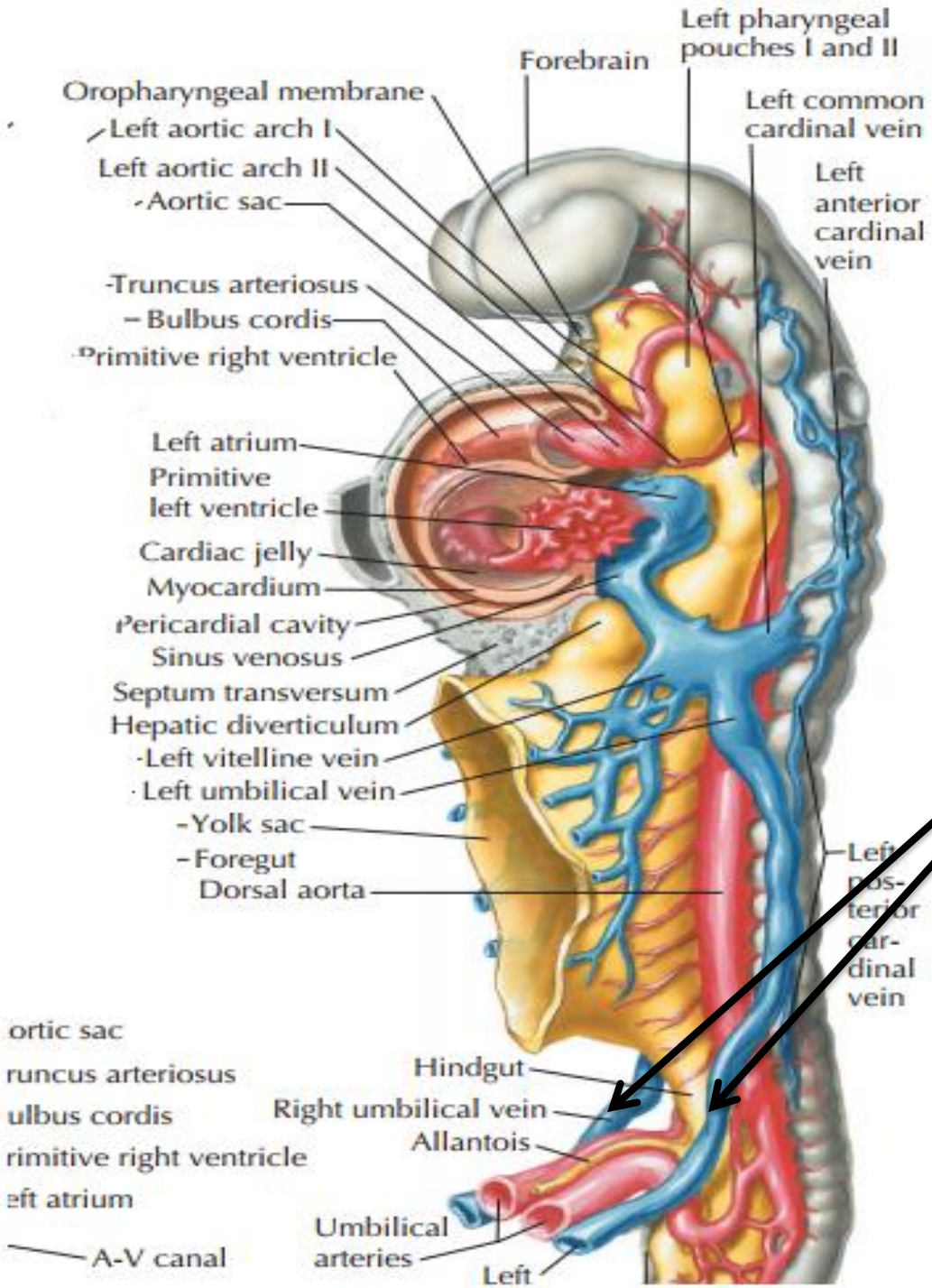

you should have known the answer to the question asked previously

Why the left sinus horn looses Its importance????

Umbilical Veins

the answer is on the next

Dr. Amjad Shatarat, 2019 School of Medicine, The University of Jordan

it loses its importance because the left vitelline vein has closed its importance ,it has been transformed . and the right vitelline vein is taking all its functions . its proximal and distal part disappeared and its middle part contributed in hepatic sinusoid.
on the other hand both umbilical veins have losed their connection with sinus venosus, on top of every thing the right one disappeared totally .and the left one remains the only blood supply to the embryo. but even the left umbilical vein shunt blood to IVC .

they have anterior part and posterior part . both come together and form common cardinal veins right and left .
tow anterior right and left
tow posterior right and left

C- Cardinal Veins

1-This system consists of:

Right and left anterior cardinal veins which drain the cephalic part of the embryo

Right and left posterior cardinal veins which drain the rest of the embryo

join before entering the sinus horn and form the short **right and left common cardinal veins**

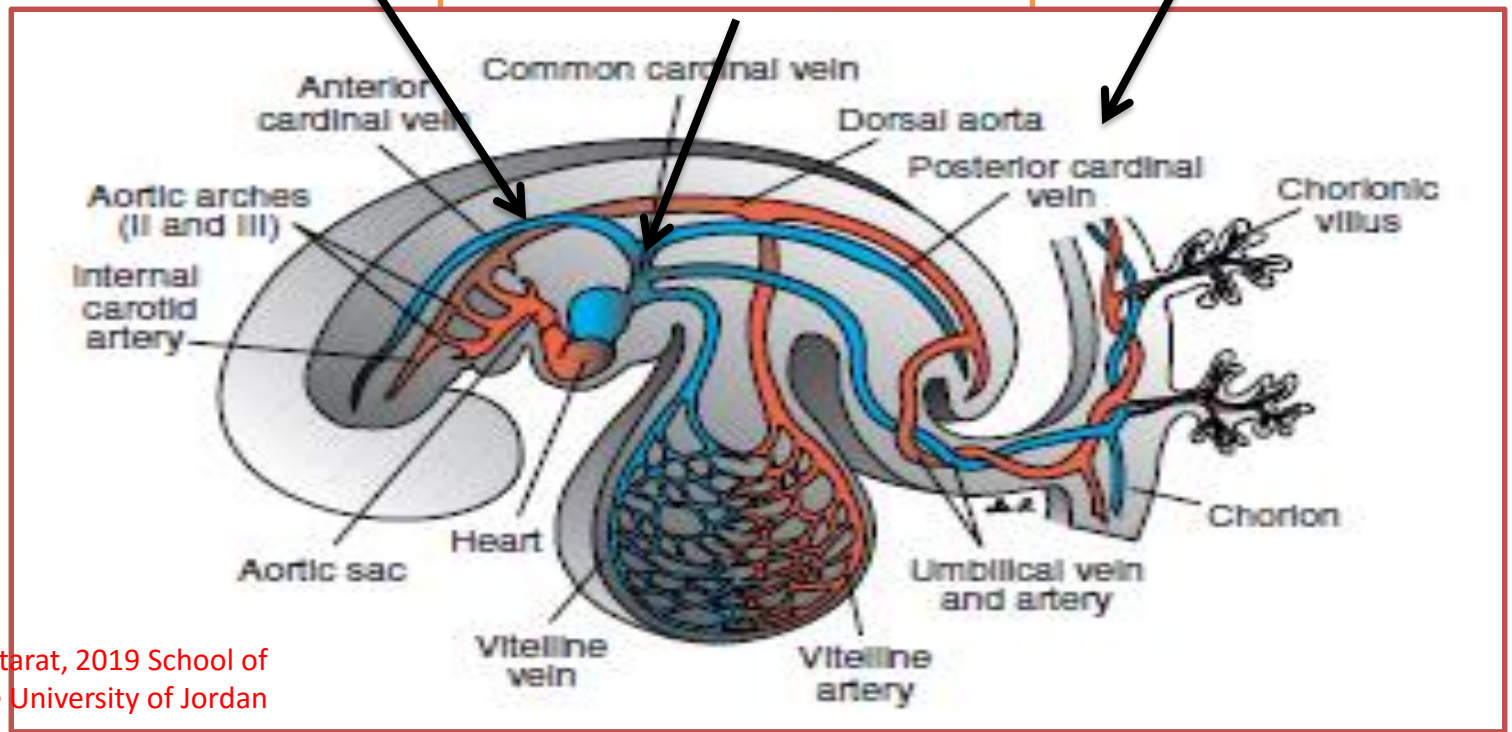

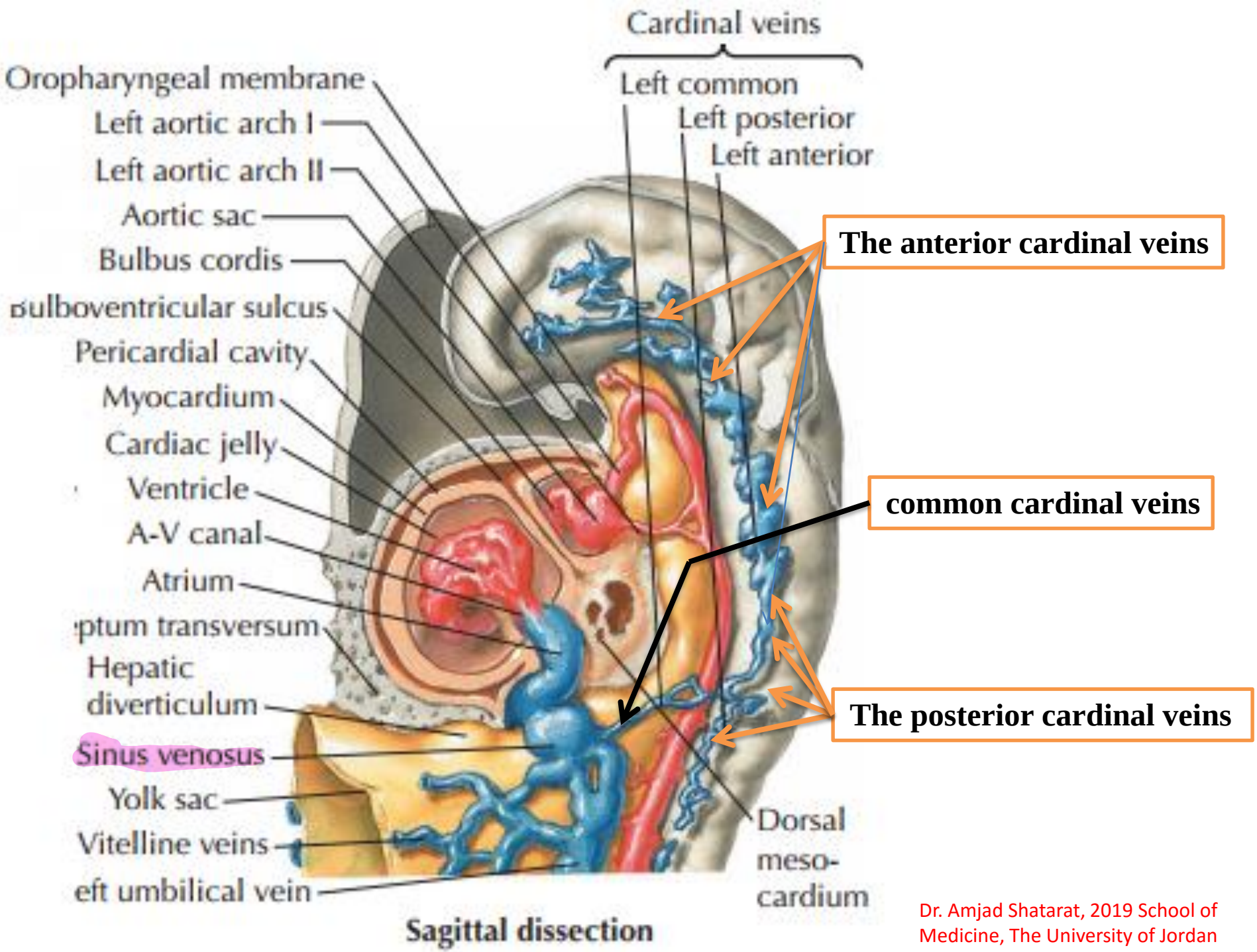

Sagittal dissection

Dr. Amjad Shatarat, 2019 School of Medicine, The University of Jordan

additional veins are formed:

if you imagine that the anterior and posterior cardinal vein are in an anterior position. behind them there are a 3 systems of veins are formed .

2- During the fourth week, the cardinal veins form a symmetrical system During the fifth to the seventh week a number of additional veins are formed:

(a)The subcardinal veins

which mainly drain the kidneys

(b) The sacrocardinal veins

which drain the lower extremities

(c) The supracardinal veins

which drain the body wall by way of the intercostal veins, taking over the functions of the posterior cardinal veins

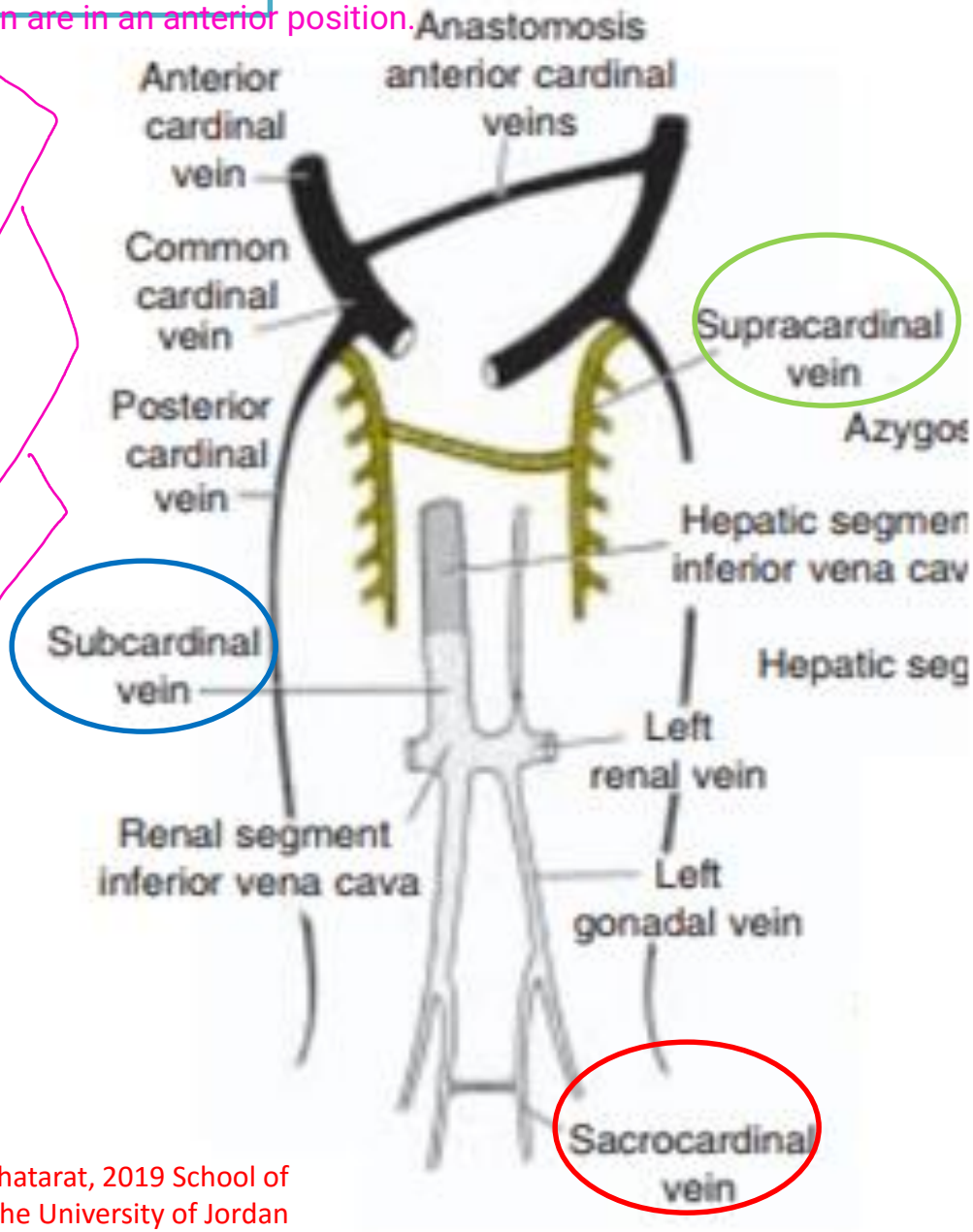

3-The anastomosis between the anterior cardinal veins develops into

<u>the left brachiocephalic vein</u>.

4- Most of the blood from the left side of the head and the left upper extremity is then channeled to the right

so , no superior vena cava in the left side

Now, you should have understood

The second left-to-right shunt occurs when the left anterior cardinal vein becomes connected To the right anterior cardinal vein by an oblique anastomosis called brachiocephalic

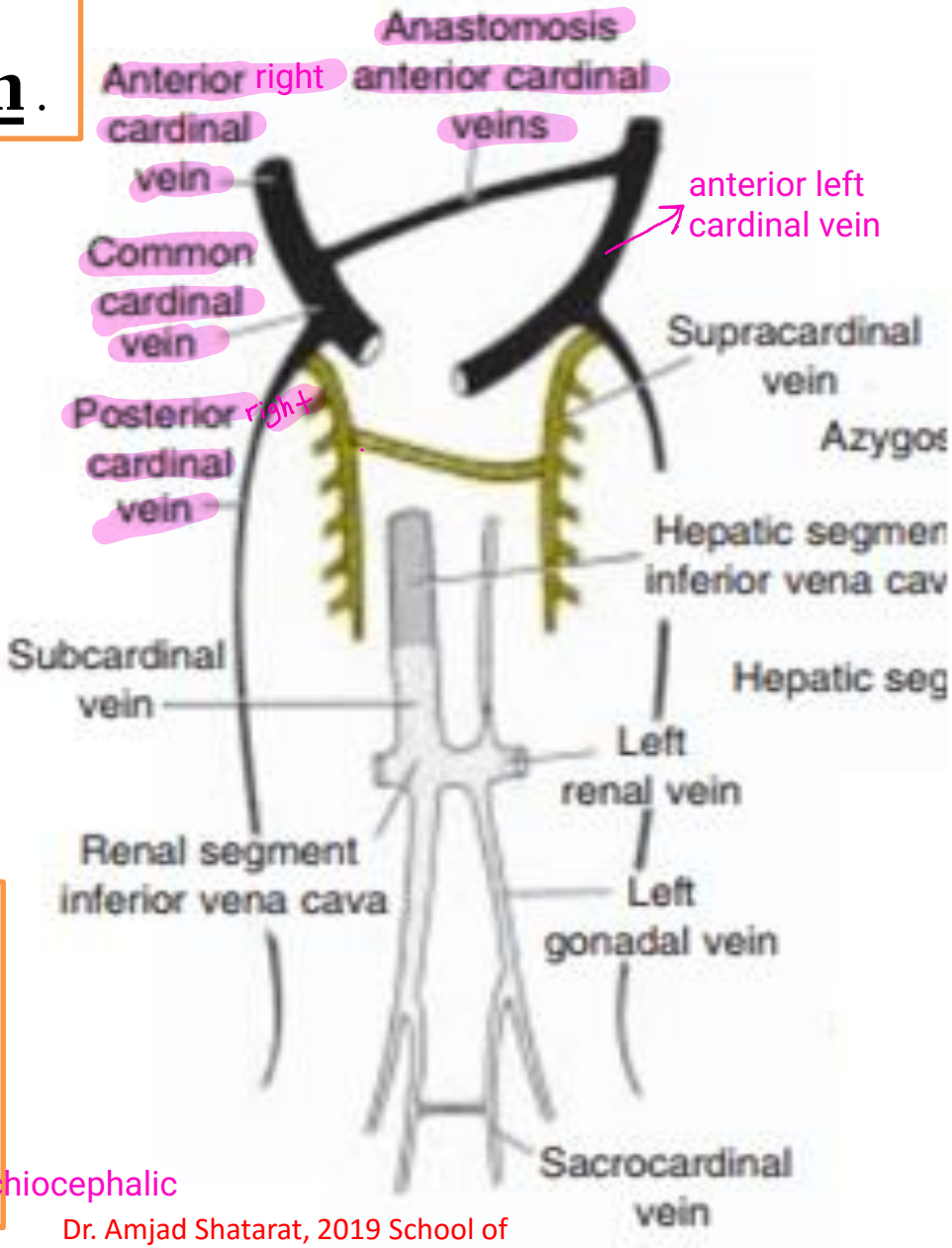

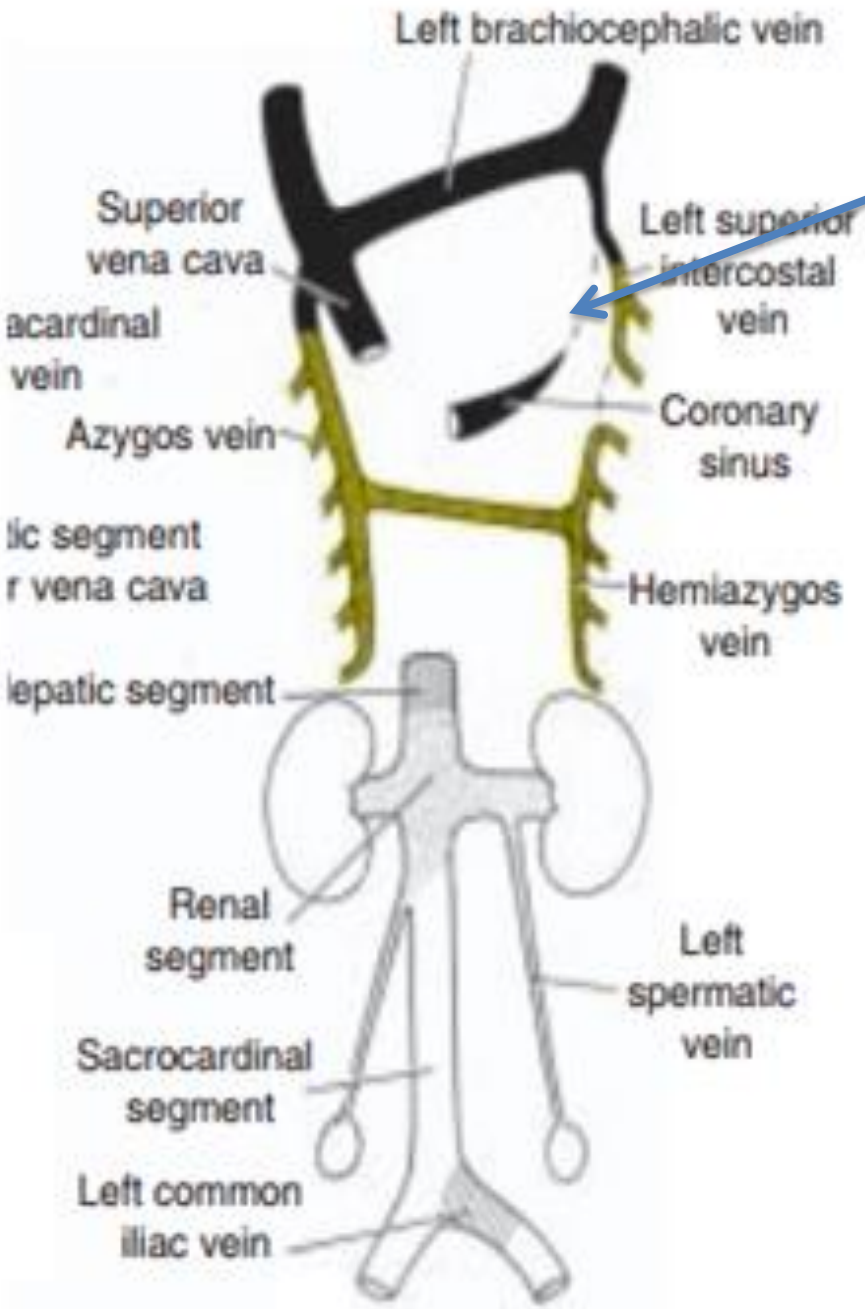

5- **<u>The terminal portion</u>** of the left posterior cardinal vein entering into the left brachiocephalic vein is retained as a small vessel, **<u>the left superior intercostal</u>** vein This vessel receives blood from the second and third intercostal spaces

You should understand, by now, why the left superior intercostal vein
Drains into
the left brachiocephalic vein

because they originate from the same cardinal system

Dr. Amjad Shatarat, 2019 School of Medicine, The University of Jordan

6- **The superior vena cava** is formed

by

A-The right common cardinal vein

B-The proximal portion of the right anterior cardinal vein

the distal portion would form the right brachiocephalic vein and its continuation the superior vena cava as it's United by the left brachiocephalic vein.

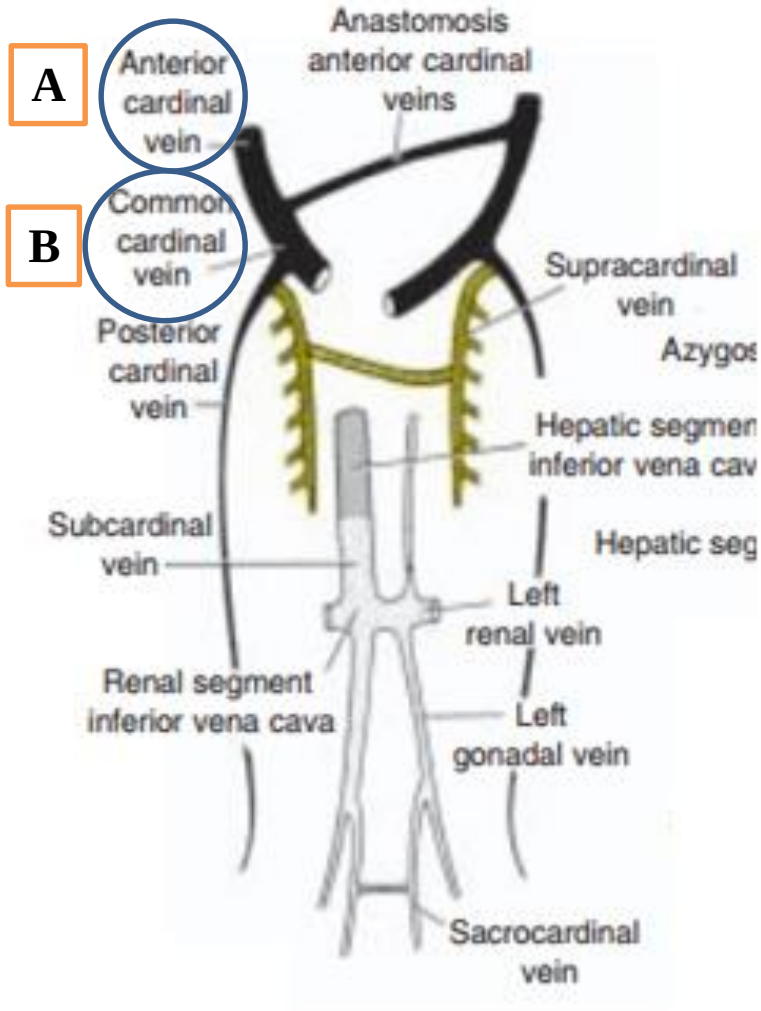

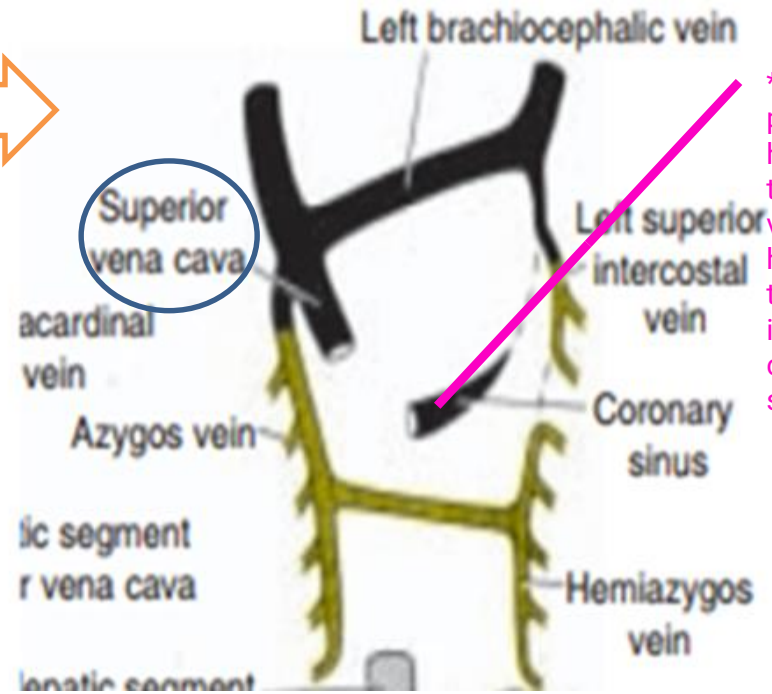

****and this part which has to join the sinus venosus has been transformed into left coronary sinus .

****enterior portion of the left cardinal vein connect withers the right cardinal.

***the posterior portion has been transformed into the left superior intercostal veins .

Dr. Amjad Shatarat, 2019 School of Medicine, The University of Jordar

summery of left cardinal veins.
we have tow common cardinal veins(right and left).each of them made by anterior and posterior portion .they drain the body wall.
the left cardinal vein:its anterior portion usually drains the head ,neck and upper limb.
immediately connect itself to the right anterior cardinal vein.
and from now , all the blood from head,neck and upper limb is shuted from the left to the right side through newly formed channel called the left brachiocephalic vein.
the smaller portion of the posterior cardinal vein form the left superior intercostal veins and coronary sinus.

Clinical correlates

Failure of the right brachiocephalic vein to form

Left superior vena cava

Persistence of the left anterior cardinal vein

Double superior vena cava

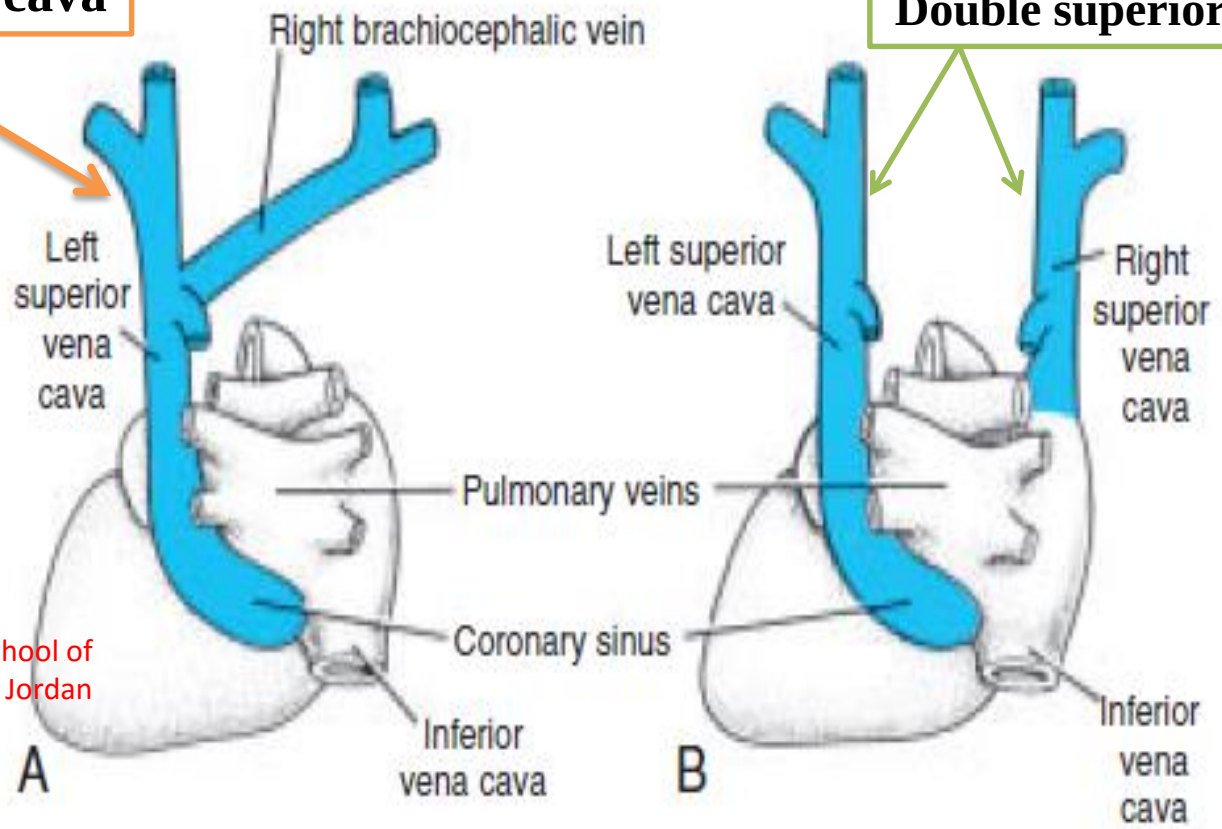

Dr. Amjad Shatarat, 2019 School of Medicine, The University of Jordan

Development of the inferior vena cava

7- The anastomosis between the **subcardinal veins** ***forms*** ***the left renal vein.*** When this communication has been established, **the left subcardinal vein** disappears, and only its distal portion remains as **the left gonadal vein.**

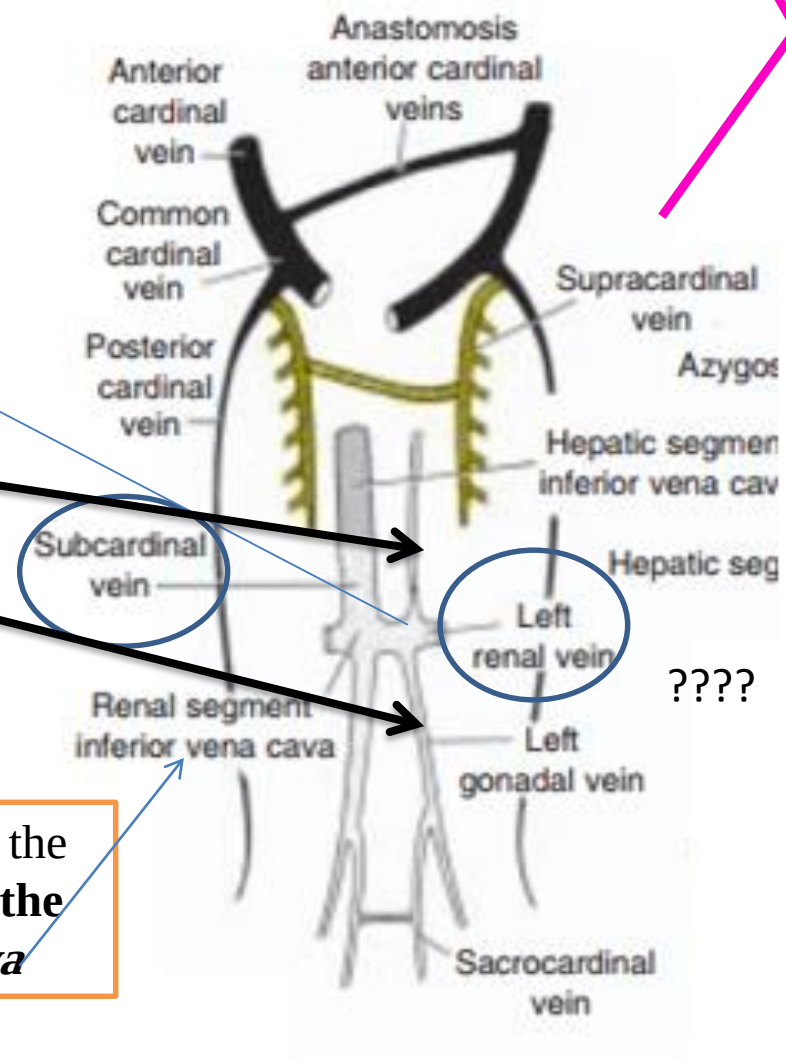

????

Hence the right subcardinal vein becomes the main drainage channel and develops **into the renal segment** ***of the inferior vena cava***

8- The anastomosis between the sacrocardinal veins forms

The left common iliac vein

The right sacrocardinal vein becomes **sacrocardinal segment of the inferior vena cava**. When the renal segment of the inferior vena cava connects with the hepatic segment, which is derived from the right vitelline vein, the inferior vena cava**, consisting of hepatic, renal, and sacrocardinal segments, is complete**

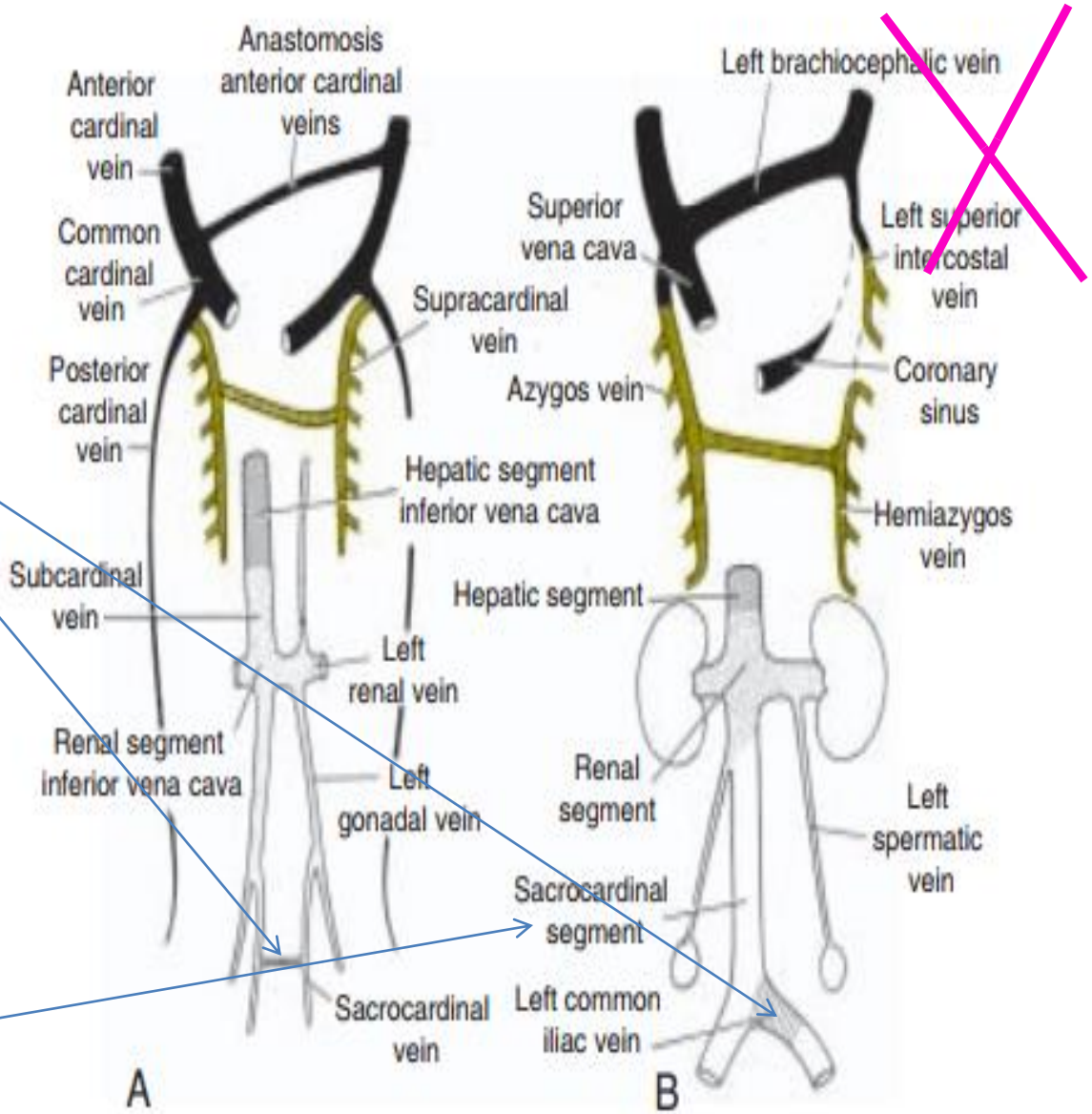

Figure 11.44 Development of the inferior vena cava, azygos vein, and superior vena cava. **A.** Seventh week. The anastomosis lies between the subcardinals, supracardinals, sacrocardinals, and anterior cardinals. **B.** The venous system at birth showing the three components of the inferior vena cava.

9- With obliteration of the major portion of the posterior cardinal veins, **the supracardinal veins assume a greater role in** draining the body wall.
The 4th to 11th right intercostal veins empty into **the right supracardinal vein**, which together **with a portion of the posterior cardinal vein forms the**

azygos vein

10- On the left, the 4th to 7th intercostal veins enter into the left supracardinal vein, and the left supracardinal vein, then known as the

hemiazygos vein

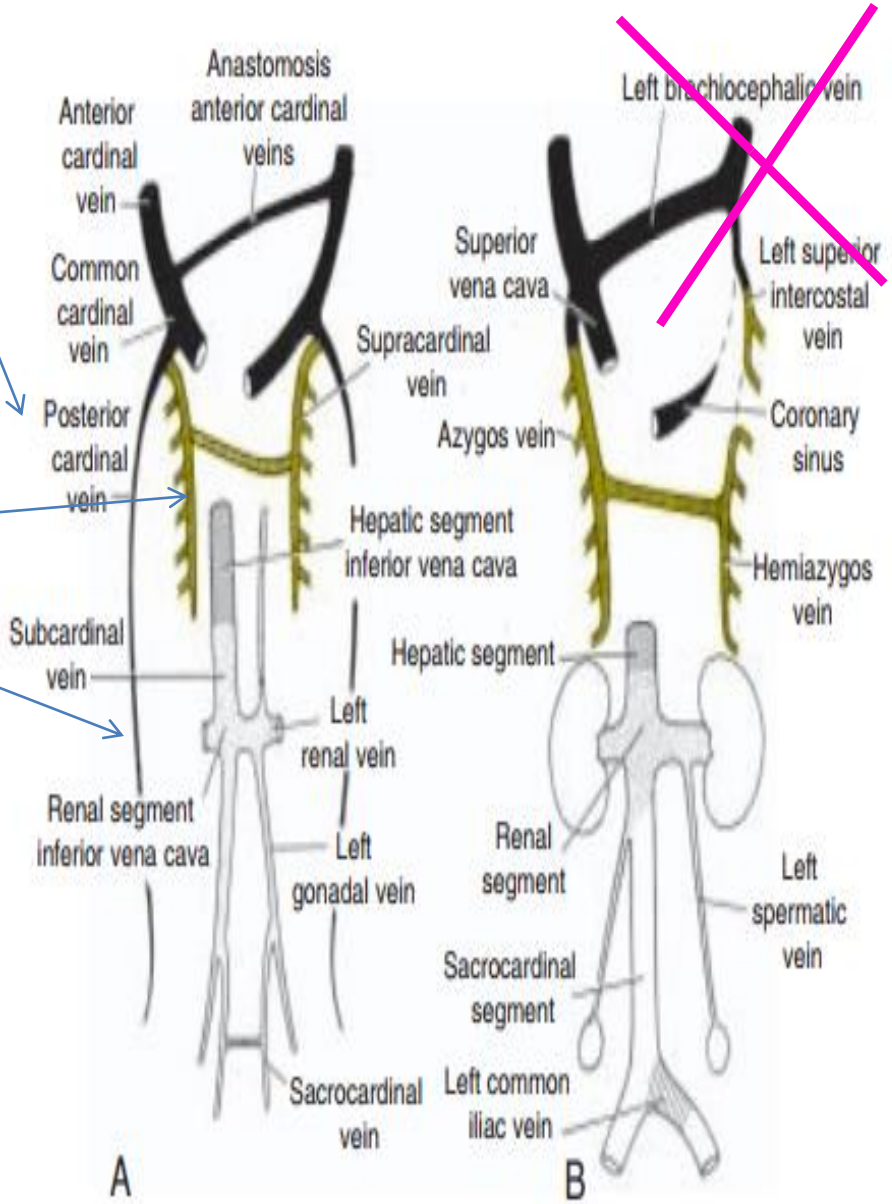

Figure 11.44 Development of the inferior vena cava, azygos vein, and superior vena cava. **A.** Seventh week. The anastomosis lies between the subcardinals, supracardinals, sacrocardinals, and anterior cardinals. **B.** The venous system at birth showing the three components of the inferior vena cava.

Dr. Amjad Shatarat, 2019 School of Medicine, The University of Jordan

Clinical correlates

Double inferior vena cava:
Left sacrocardinal vein remain connected to the left subcardinal vein

Absence of the inferior cava : The right subcardinal vein fails to make the connection with the liver