lecture 13
edited by yasmeen Khaled

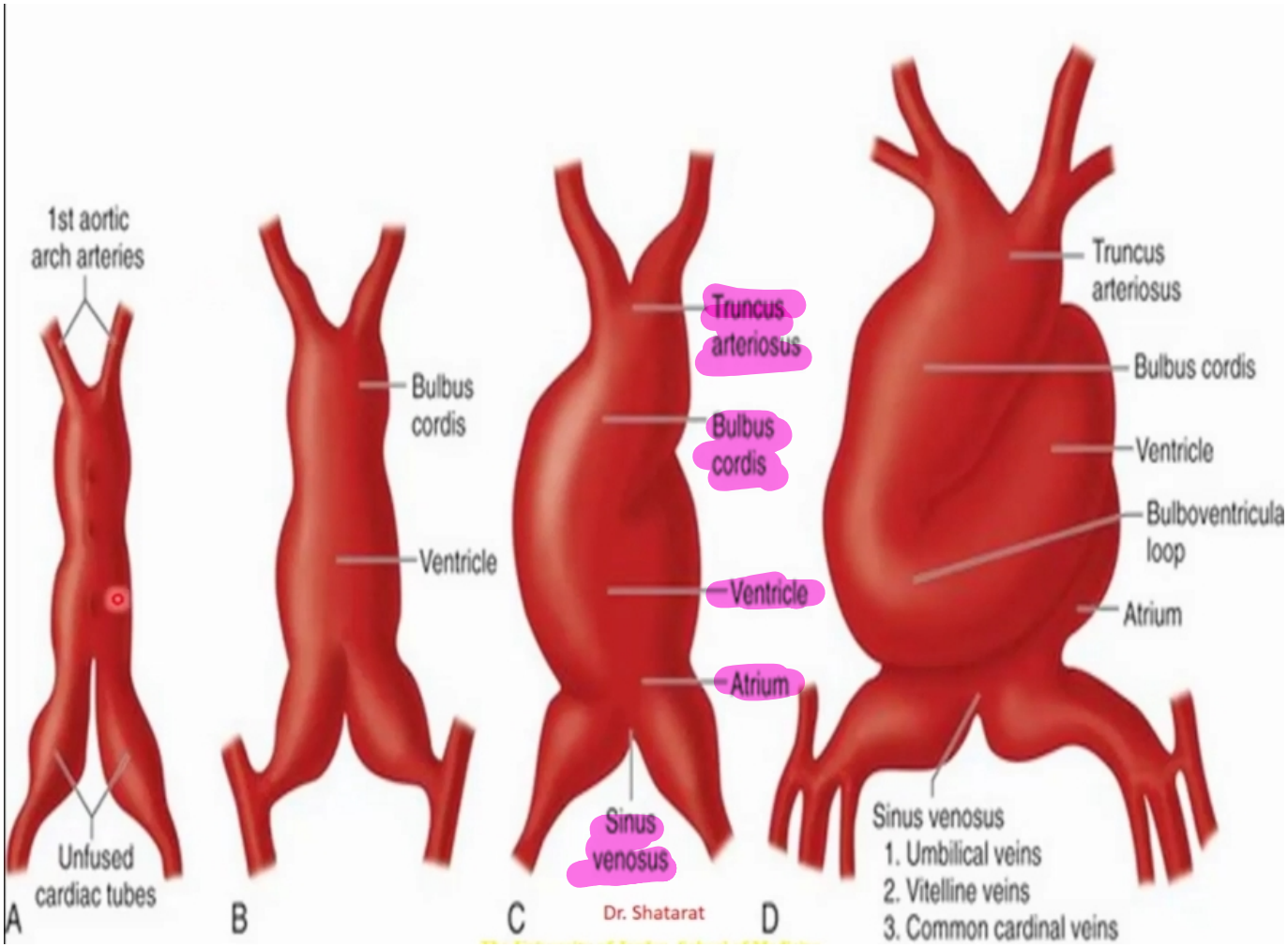

*the heart is now a tube consist of these parts: (from caudal to cranial direction:the same direction of blood flow).

1.venous end called sinus venosus inferiorly (caudally).
2.atrium
3.ventricle
4.bulbus cordis
5. arterial end called truncus arteriosus superiorly (cranially)

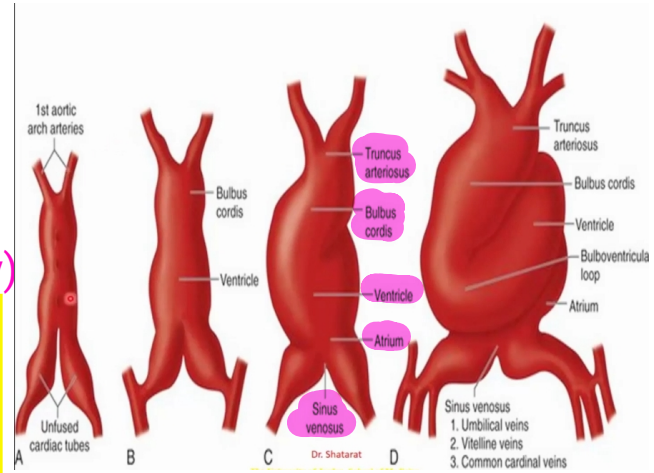

these are the only tow part which locate inside the pericardium sac so it grow faster than the other,but their growth is limited in small space , so like any tube it will coil when grows -coils to the right and anterior- . so making the u shape .as a result of this coiling ,the superior part (bulbous cordis) become near and next to the inferior part(ventricle).

at the same time

the lower part of heart tube (the atrium and sinus venosus) would be released (unfixed).it is free now and has 2 options to go up: (either anteriorly or posteriorly) .remember the tube coils to the right and anterior so the anterior space is filled by bulbous cordis and ventricle .so the free end (sinus venosus and atrium)would go up by the second option → posteriorly. now the heart is S shaped.
note :for this reason in the adult heart we find the atria posterior to the ventricles.

It should be noted that the atrium and the sinus come to lie **behind and above the ventricle**

**the blood flow in yellow arrows direction.
from venous end → common atrium → common ventricle → arterial end
this means that the coiled tube is continuous and not separated.

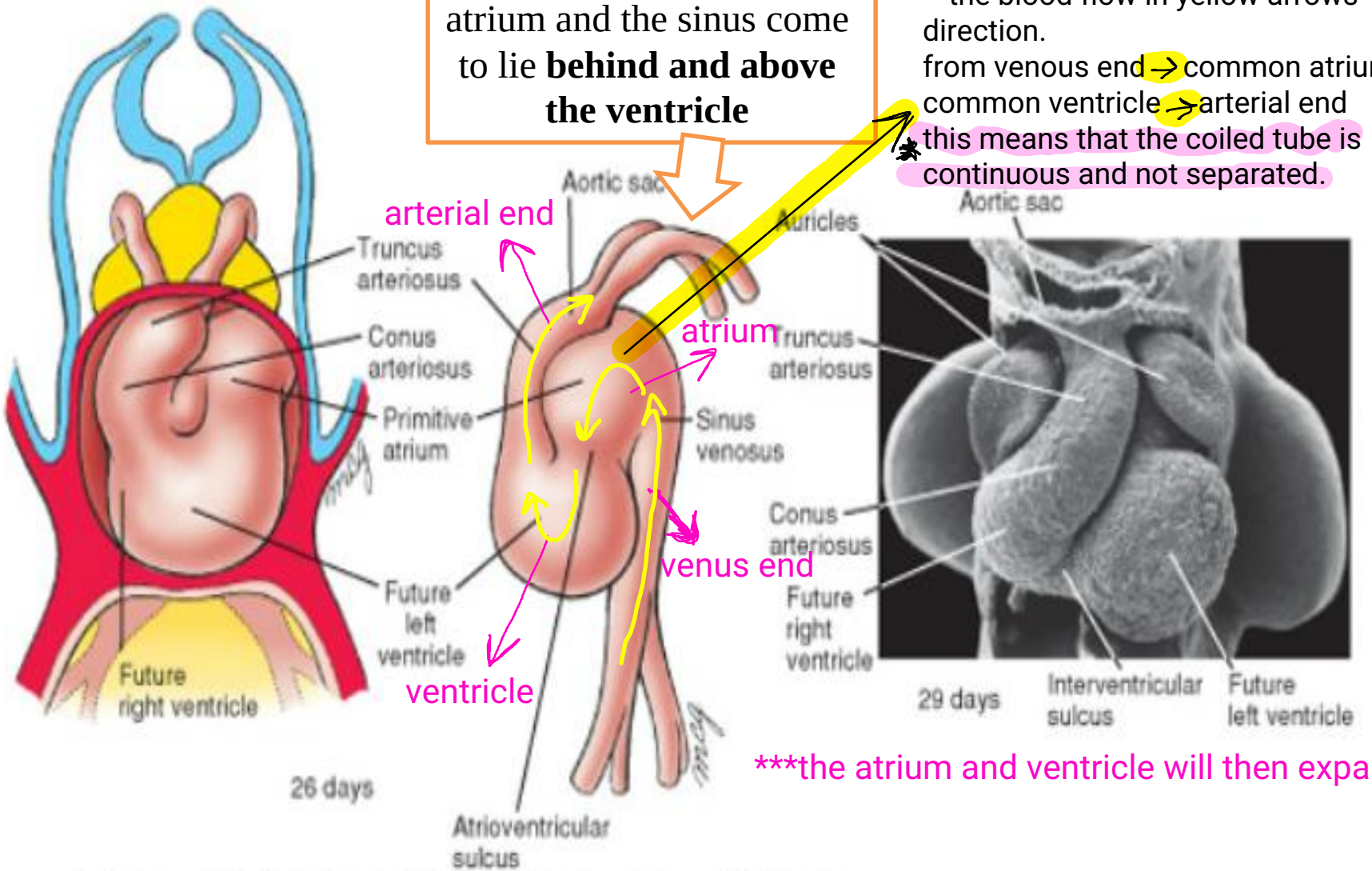

***the atrium and ventricle will then expand

At the end of the looping and rotation of the heart tube the arterial and venous ends come closer together

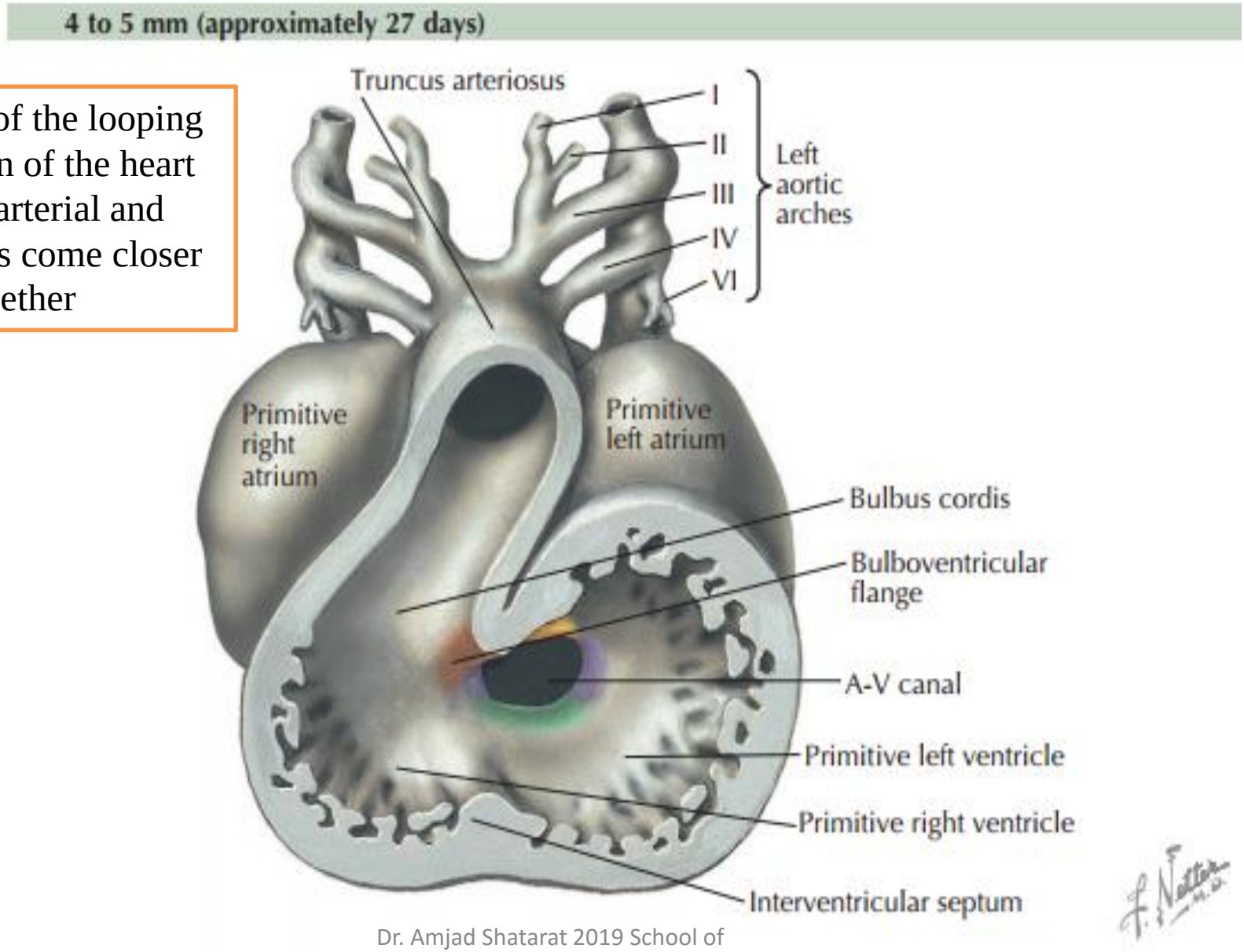

The **stage** is now set for the **septation of the heart**

lasts about 10 days

No major changes occur in the external appearance of the heart

The formation of the various cardiac septa occurs more or less simultaneously

Would you please appreciate The position of the AV canal

As the heart tube develops, it eventually pulls the AV canals and cushion from the ***left to the medially*** *as seen in the illustration below.*

wich called alignment of atrium and ventricle.
إنتظام .

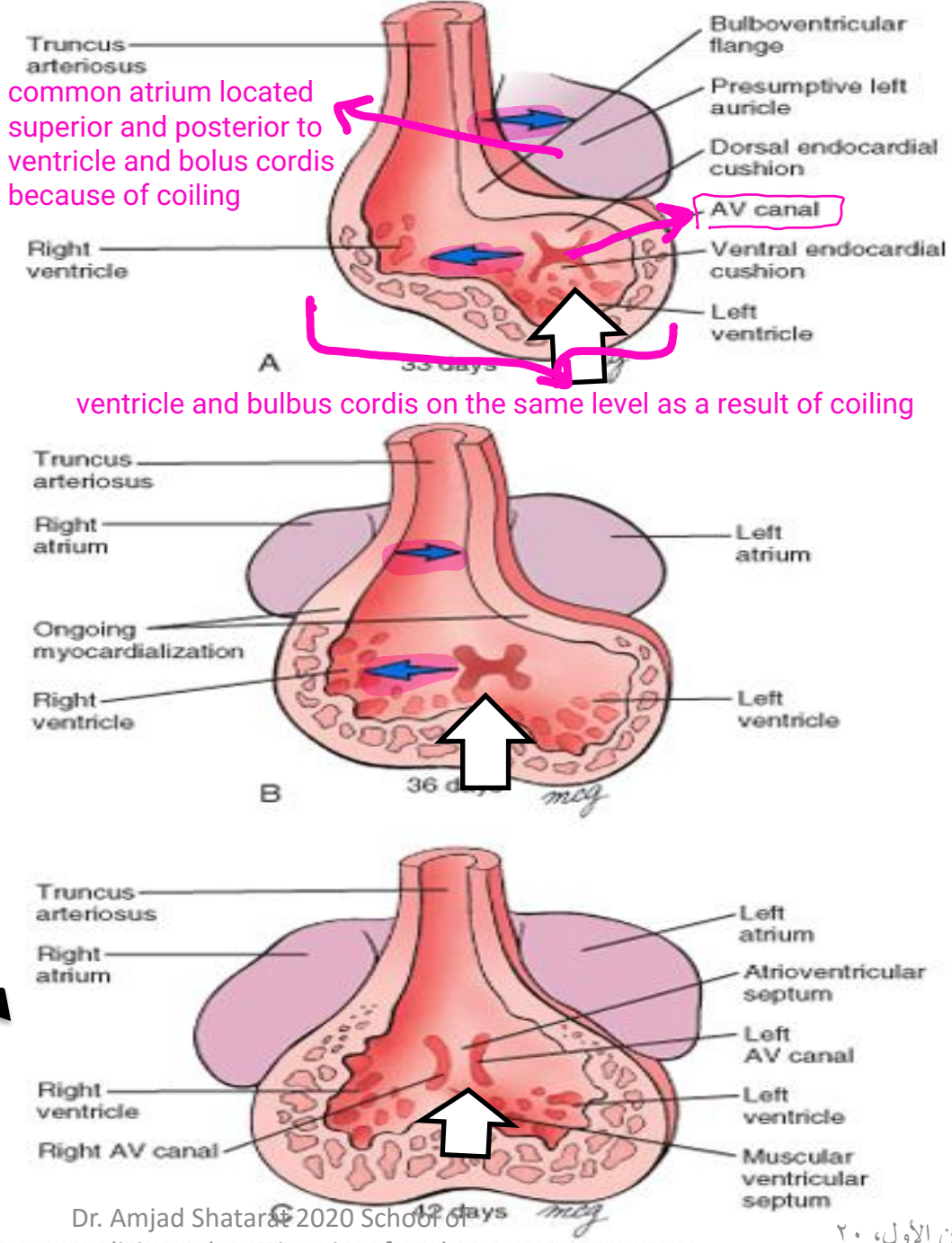

Fate of atrio-ventricular (A-V) canal

1- First it has a round opening then it becomes transverse.
by growth of superior,inferior and lateral endocardial cushion

2- Two thickenings (the atrio-ventricular or endocardinal cushions) appear on its dorsal and ventral walls.

3- They grow towards each other and fuse forming

THE SEPTUM INTERMEDIUM

Thus dividing the canal into right and left halves

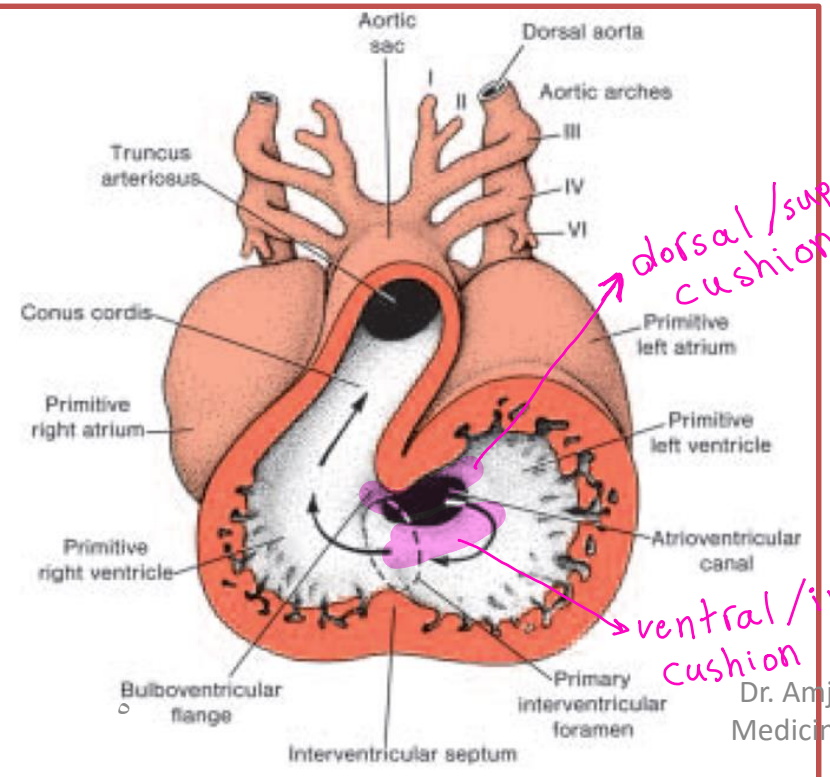

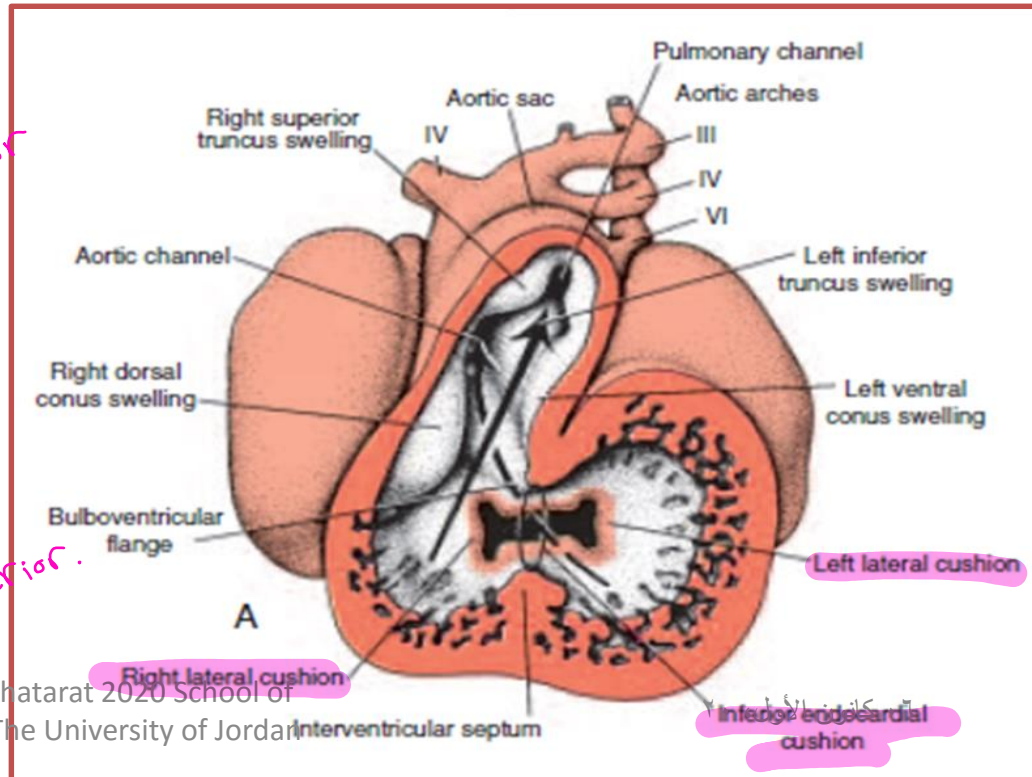

Common atrioventricular canal

Superior endocardinal cushion



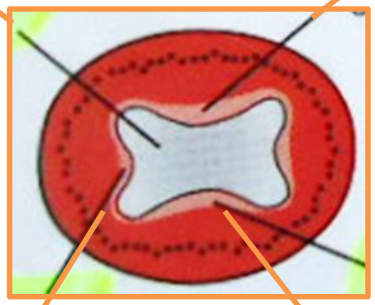

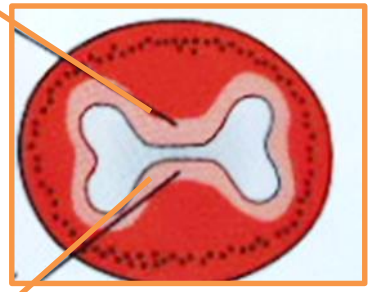

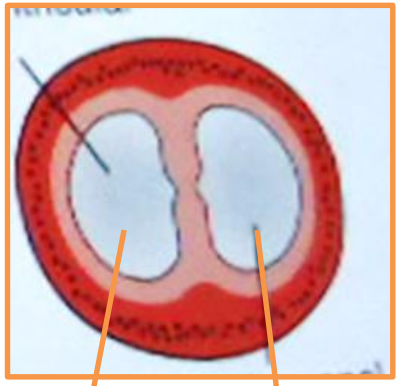

Lateral cushion

Inferior endocardinal cushion

Right and left atrioventricular canals

Round atrio-ventricular canal

Canal becomes transverse

Dorsal and ventral endocardial cushions

so we transform one AV canal into tow right and left AV canals. (bild a septum connecting a ventral and dorsal cushions). but they still common atria and common ventricles. which mean the septation is very limited.

Now we have Right and left atrioventricular canals

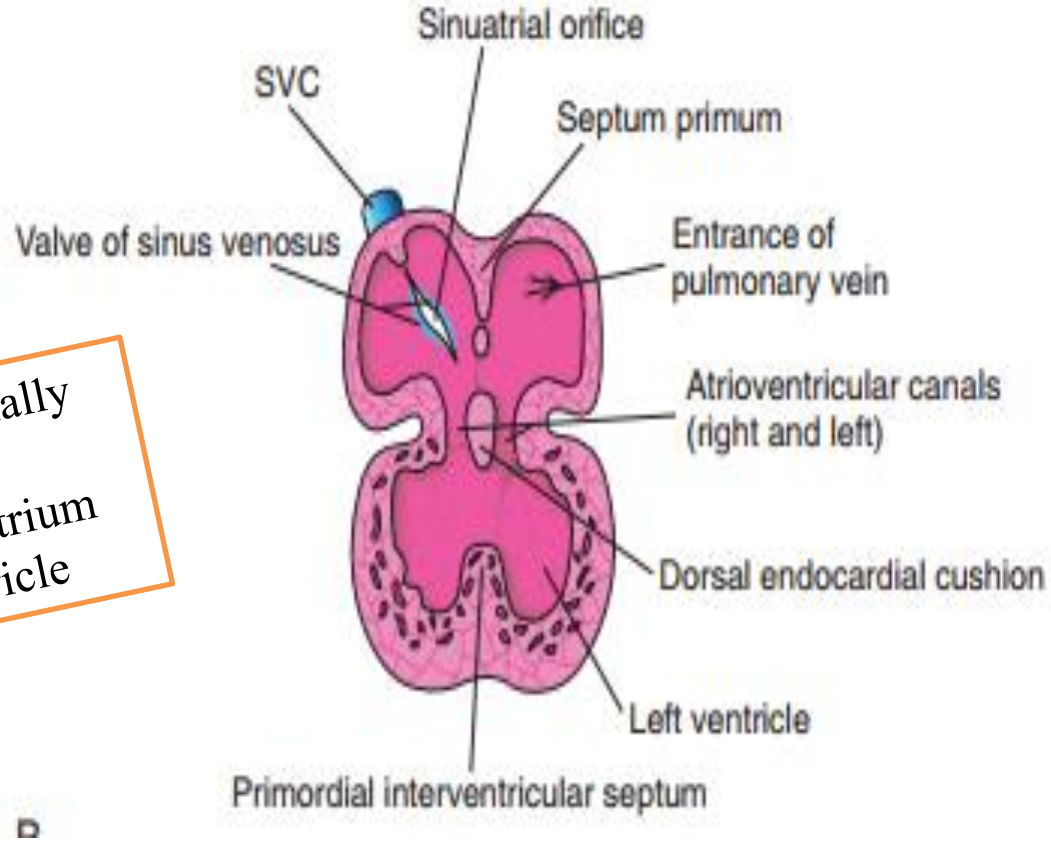

These canals partially separate the primordial atrium from the ventricle

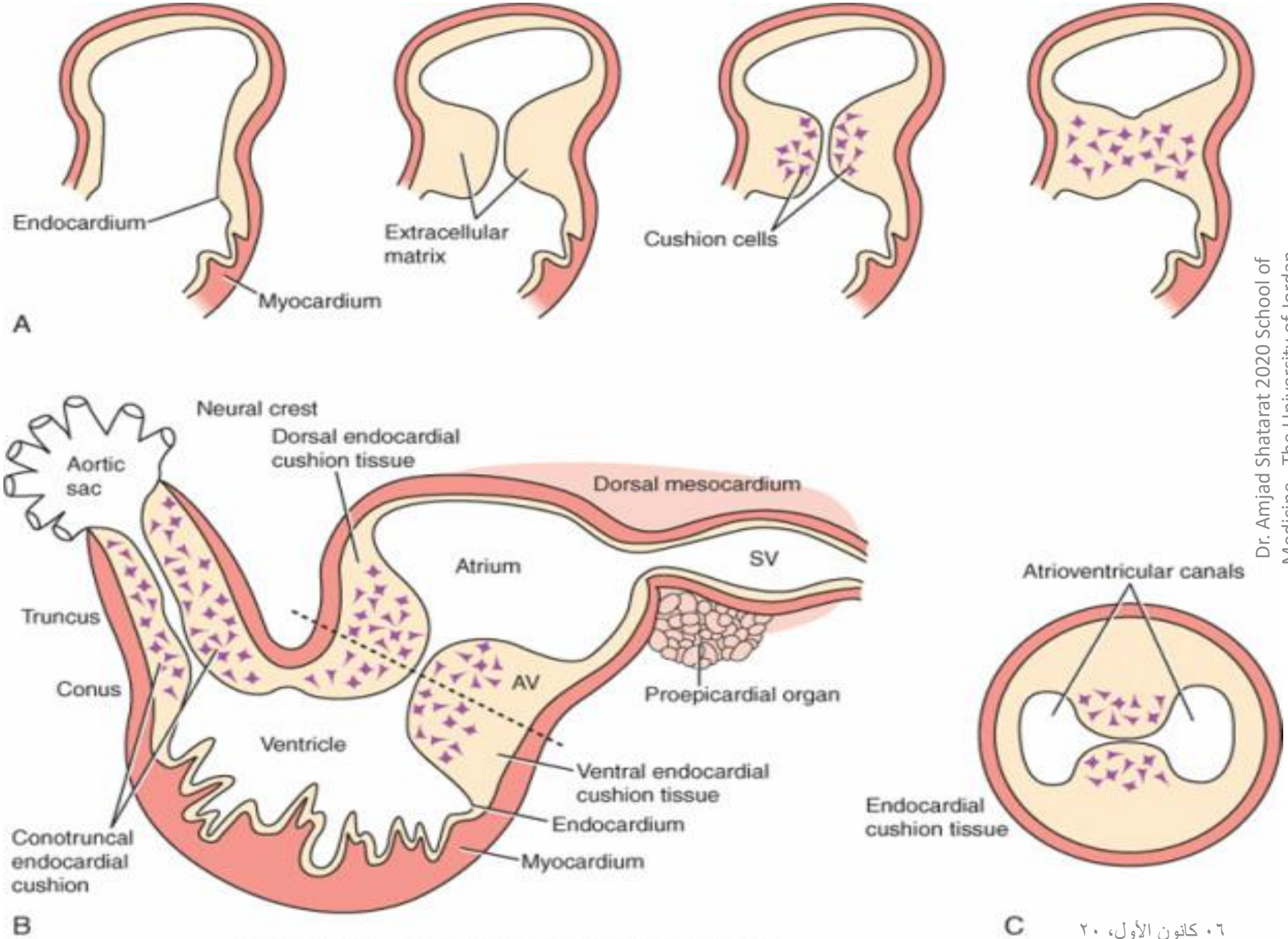

SEPTUM FORMATION IN THE ATRIOVENTRICULAR CANAL

- each atrioventricular orifice is surrounded by **local proliferations of mesenchymal tissue derived from the endocardinal cushions**.

- when the blood stream hollows the surface of these proliferations, the mesenchymal tissue becomes fibrous and forms ***the valves*** which remain attached to the ventricular wall by muscular cords which will degenerate and being replaced by dense connective tissue → **chordae tendineae.**

Note: Recent evidence shows that **neural crest cells** contribute to formation of semilunar cusps

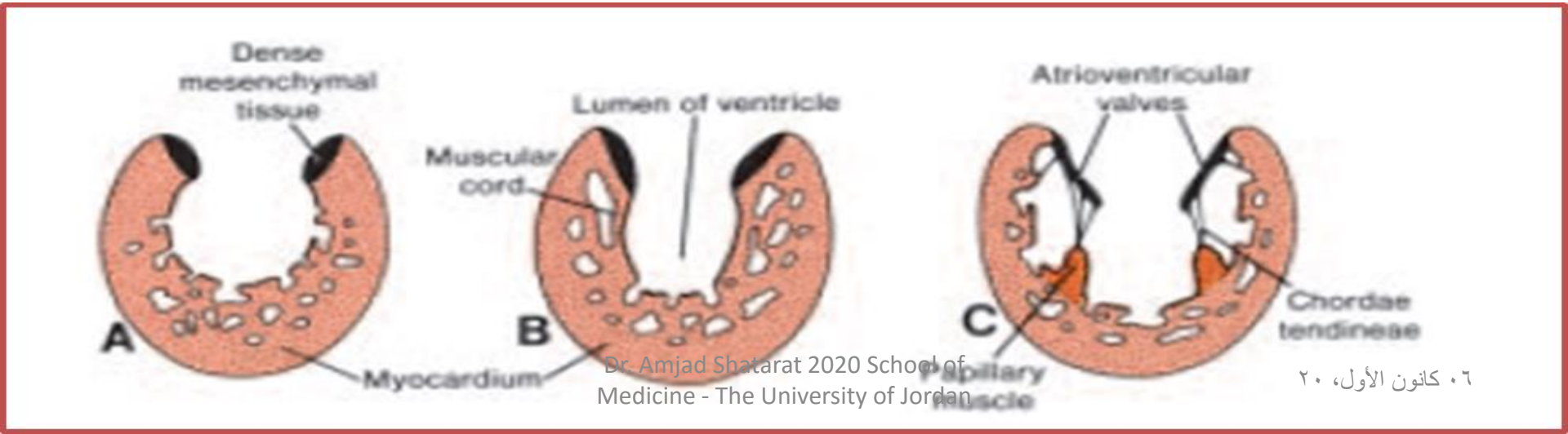

the tow AV canals are being smaller with their boundaries made of edocardial cushions as the blood flow through these cushions it would sculpt the valve,cordae tendineae and papillary muscles.

they developed from neural Crest which was migrating anteriocrainially to reach the heart. so it is not derived from endocardial cells.

It should be noted that the ***endocardinal cushions developing in the atrioventricular region or conotruncal region are derived from***

neural crest cells migrating from the cranial neural folds to the outflow tract region.

in some pathological cases the neural Crest cells will be arrested during their migration so would not reach the heart so the septum premium would not be completed.

Formation of the interatrial septum

Atrial septation

until now the heart is pumping as one unit ,where common chambers -atria and ventricle- opened to each other and they communicate with each other . the blood comes already oxygenated from placenta by inferior vena cava to right atrium then is shunted directly to left atrium(no need to go from right atrium to lung hence it is already oxygenated and the lungs still non functioning yet).

the challenge now is the atrial septation is necessary as preparation for future life,at the same time we need to maintain the tow atria connected for embryonic life .
if we bild a completed septum it would prevent blood shunting in embryo life . and if we leave it opened the newly born baby will suffer from mixing of oxygenated and non oxygenated blood .

THE SEPTUM PRIMUM → because it is the first one to appear.
which is sickle-shaped or (crescent-shaped) septum appears and extends from the roof down to and fusing with the endocardinal cushions **(septum intermedium)**

As this curtain-like septum (the septum primum) develops, **a large opening** forms between its free edge and the endocardial cushions

This opening is called

The foramen primum

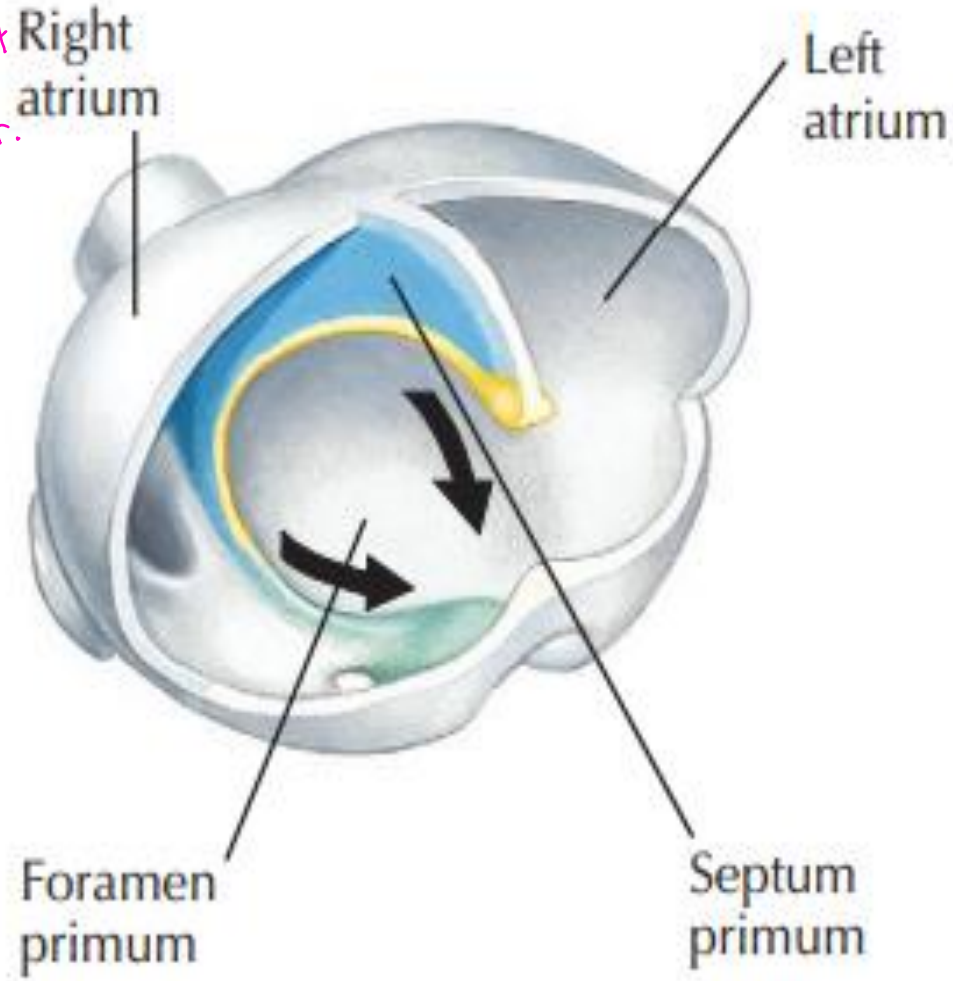

- The foramen allows **shunting of oxygenated blood from the right to the left atrium**.
- The foramen becomes progressively ***smaller and disappears as the septum primum fuses with the endocardial cushions***

Before the foramen primum disappears, the **upper part** the septum primum breaks down (perforations, produced by **apoptosis** (**programmed cell death**), to form the foramen secundum **(ostium secundum).**

Thus, a new channel for right-to-left shunting opens before the old one closes

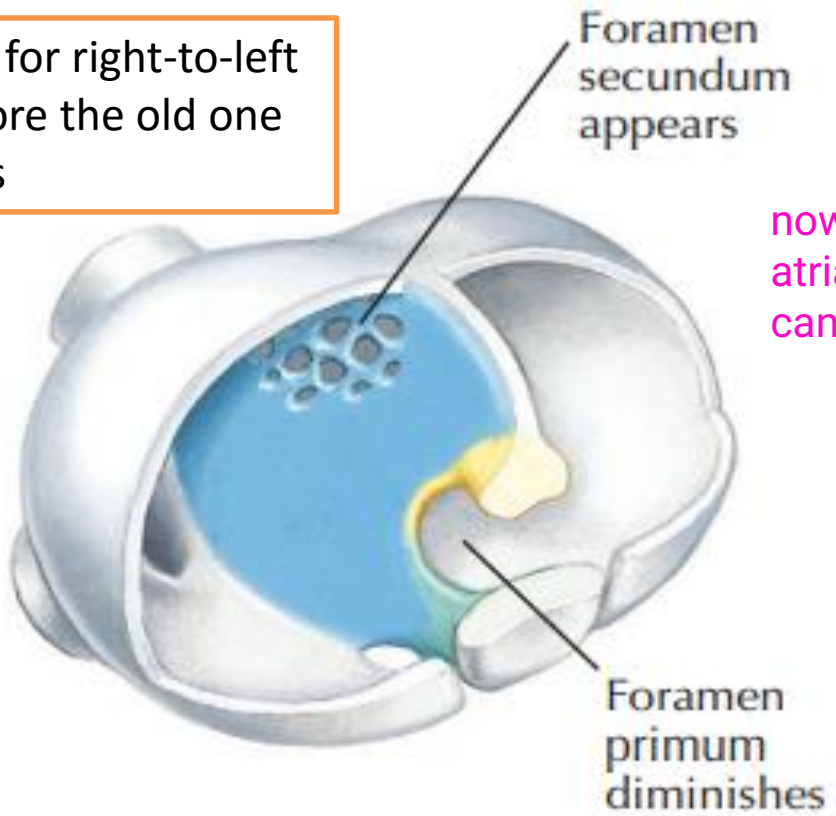

now we bild a septum between tow atria ,at the same time we leave a canal for blood shunting.

<u>The foramen primum</u>

Disappears as the septum primum fuses with the endocardial cushions (septum intermedium)

Septum secundum, grows from the ventrocranial wall of the atrium, immediately to the right of the septum primum

The lower edge of the septum secundum is thick and firm

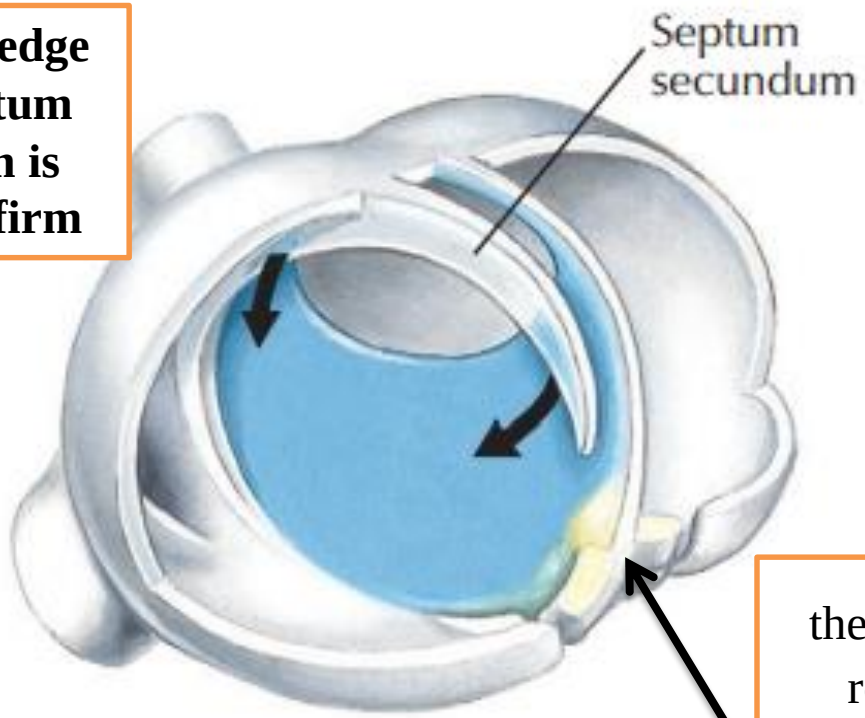

the septum secundum **does not** reach the endocardinal cushions (septum intermedium)

it gradually overlaps the **foramen secundum** in the septum primum

Therefore, throughout the rest of fetal development, (blood) that shunts from the right atrium to the left atrium passes through two openings: the ***foramen ovale near the floor of the right atrium***, and the ***foramen secundum*** near ***the roof of the left atrium***

comes from IVC toward right atrium

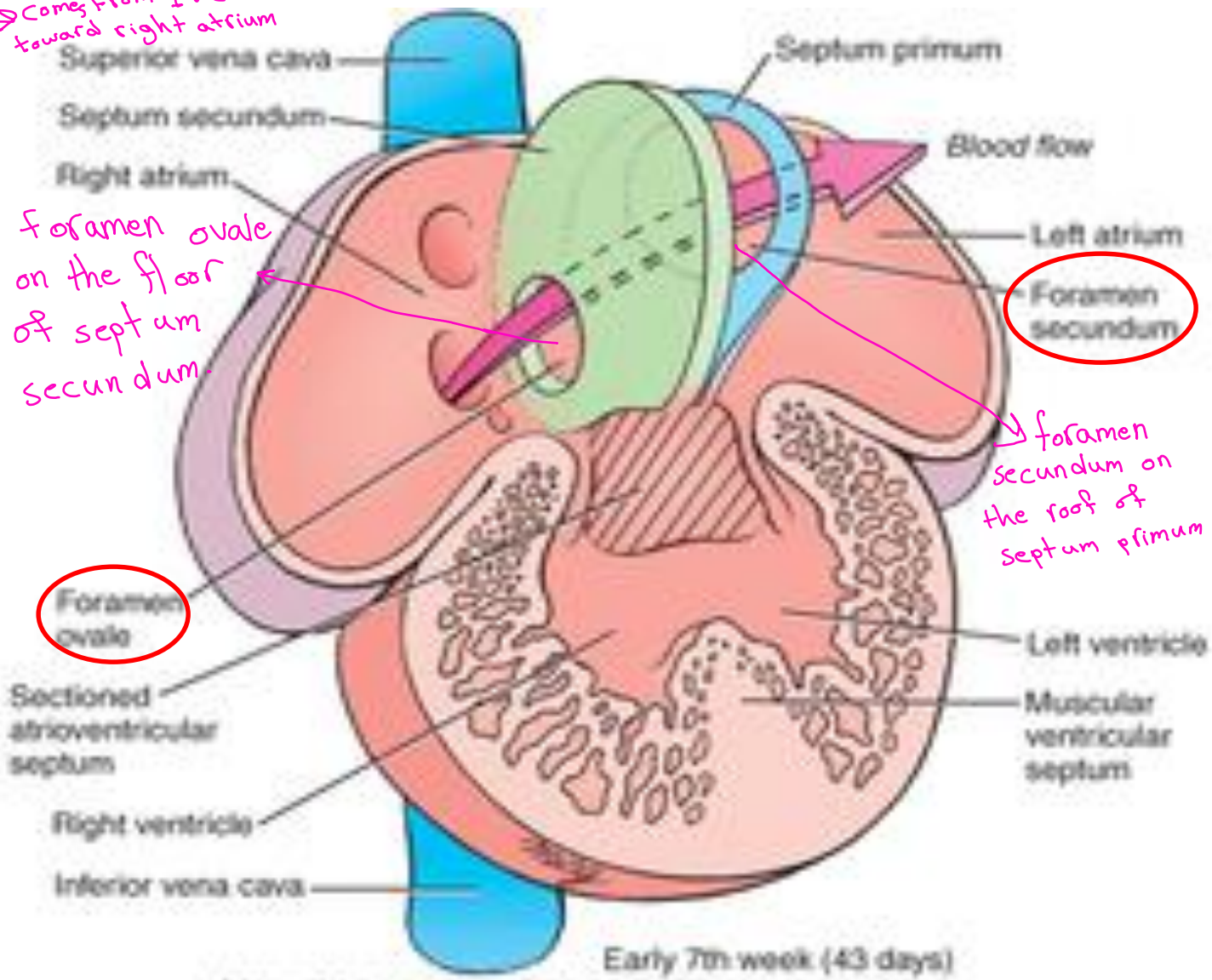

foramen ovale on the floor of septum secundum

foramen secundum on the roof of septum primum

The opening between
septum secundum and the septum primum
Is called
also

(foramen ovale)

which persist throughout fetal life

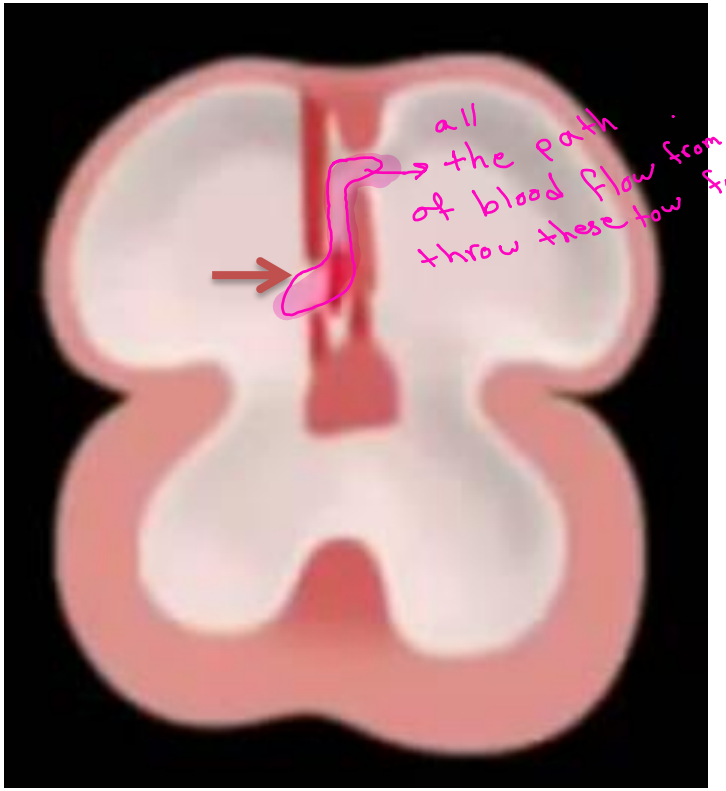

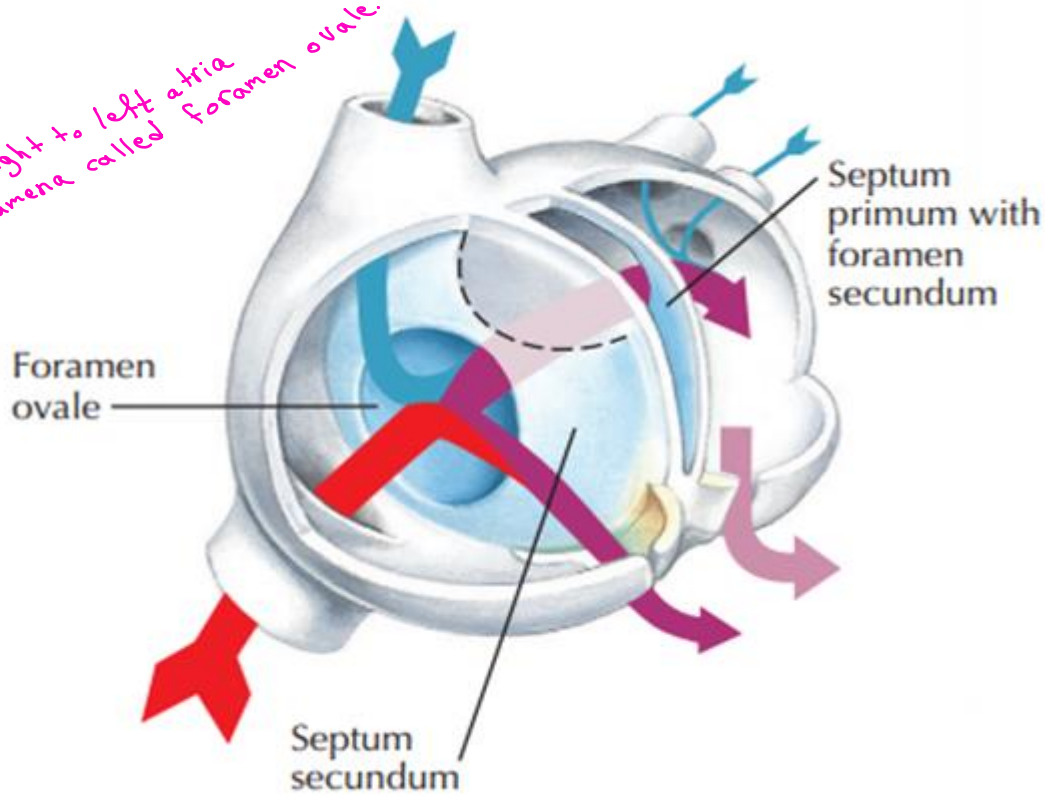

The cranial part of the septum primum gradually disappears

The remaining part of the septum primum, attached to the endocardial cushions, forms the **valve of the oval foramen**

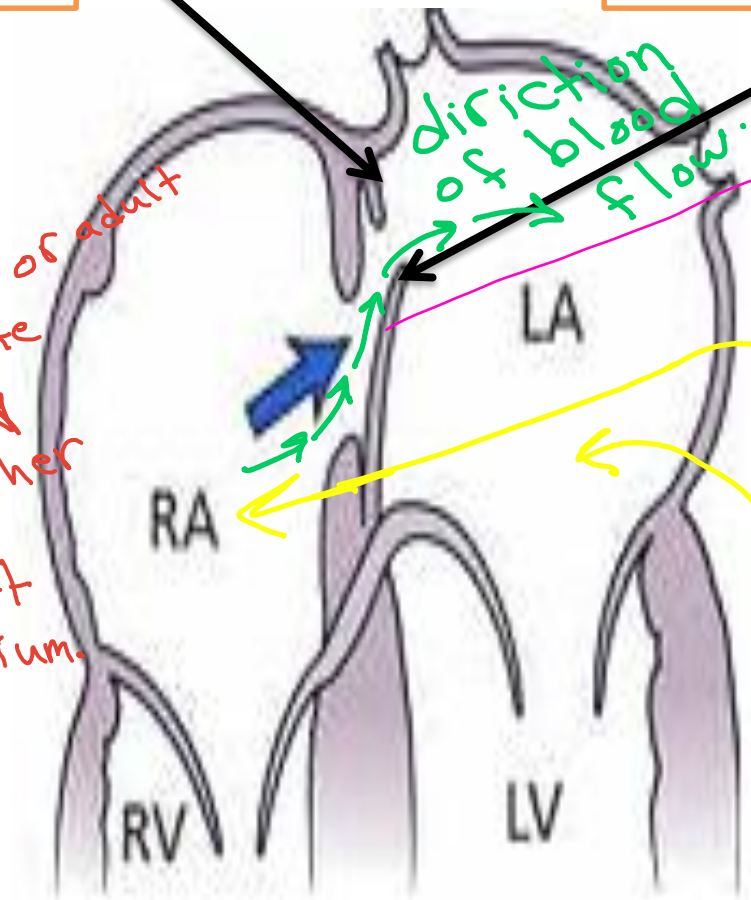

diriction of blood flow.

this part is acting as a flap; when the blood of high prussure comes from right atrium will push so open this flap to continue its path for the left atrium.

note: the prussure of blood is

fetal life → higher in right atrium

baby or adult life → higher in left atrium.

- The lower edge of the septum secundum is thick and firm. In contrast, the edge of the septum primum that forms the lower boundary of the foramen secundum is thin and mobile like a flap.

characterized by mobility, (it is not rigid)

- When blood tends to flow from the right to the left atrium, this thin flap moves away and there is no obstruction to blood flow.

- however, when there is a tendency for blood to flow from left to right this flap comes into apposition with the septum secundum and closes the opening.

by this mechanism we permit the unidirictional blood flow.

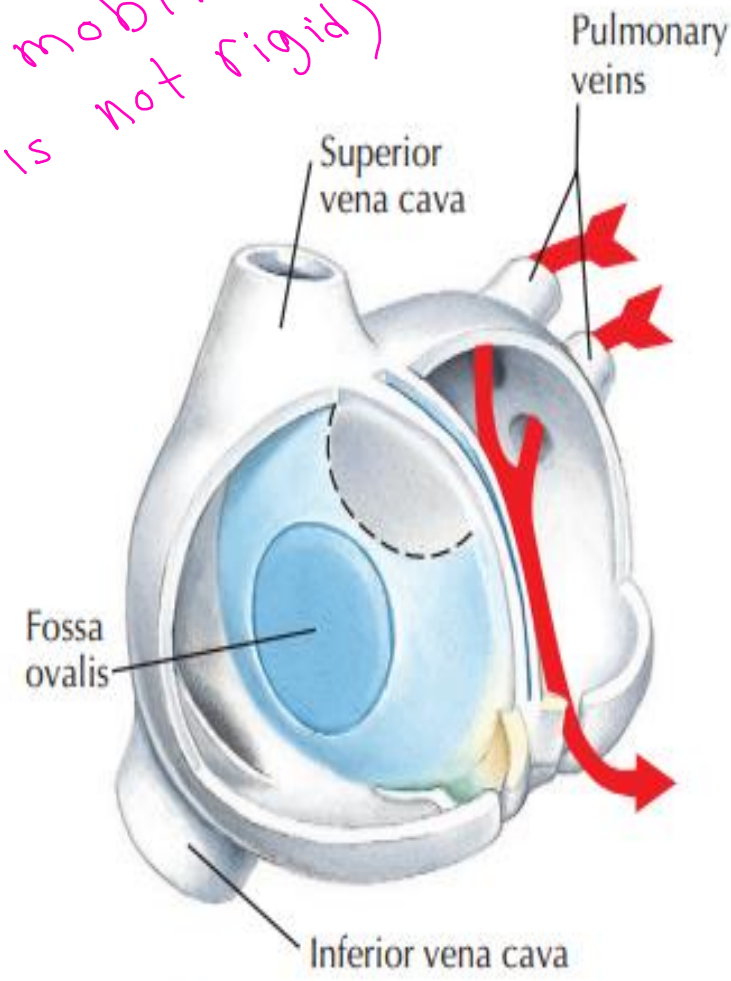

Foramen ovale closed after birth with increased pulmonary flow

After birth, when lung circulation begins and pressure in the left atrium increases, the valve of the oval foramen is pressed against the septum secundum, obliterating the oval foramen and separating the right and left atria.

its embryonic origin is the free edge of septum secondum.

* when the doctor ask you to put your finger in foramen ovale, you would touch the floor of foramen ovale wich represents septum primum.

Annulus ovalis represents lower free edge of the septum secundum.

Floor of fossa ovalis represents the septum primum.

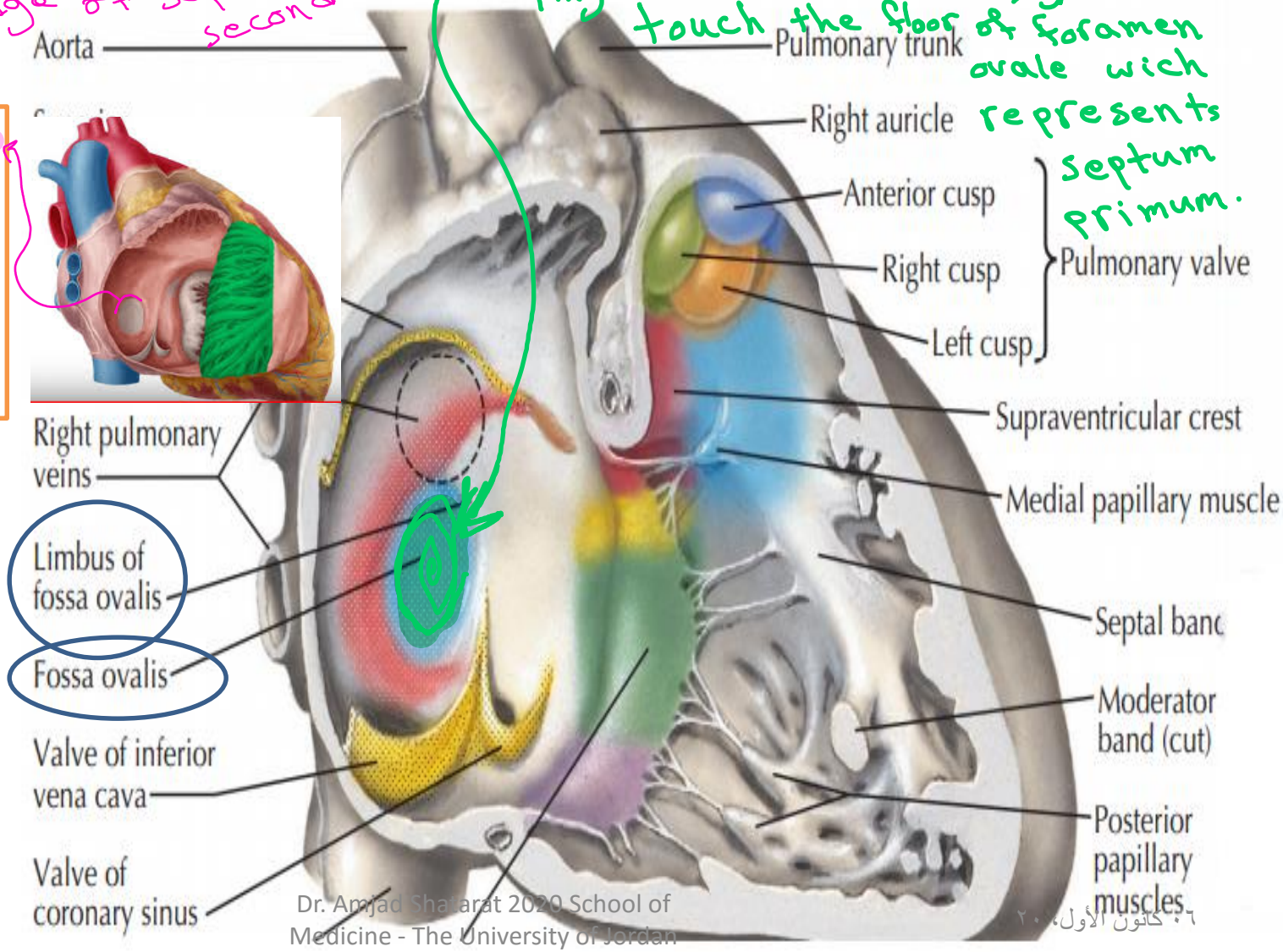

Separation of the ventricles

is not complicated in term of blood flow.
because we don't neet the ventricles to communicate
after birth. at the same time inside the embryo we
don't have a challenge because the blood already does not come
to right ventricle, so we don't need to shunt it to the
left ventricle.

⇒ so we just separate it during the
fetal life as preparation for
after birth.

* note: the bild of all septum is simultaneously
① septum intermedium
② inter atrial septum
③ ventricular septum.

- The ***ventricular septum begins*** its development as a projection from the base or the inferior wall of the ventricle.

ventricular septum.

- As it enlarges, the septum forms two horns which reach up to the corresponding (a-v endocardinal cushions)

septum intermedium.

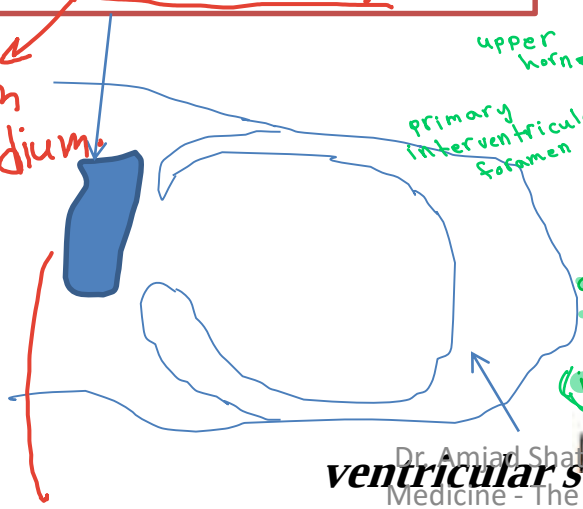

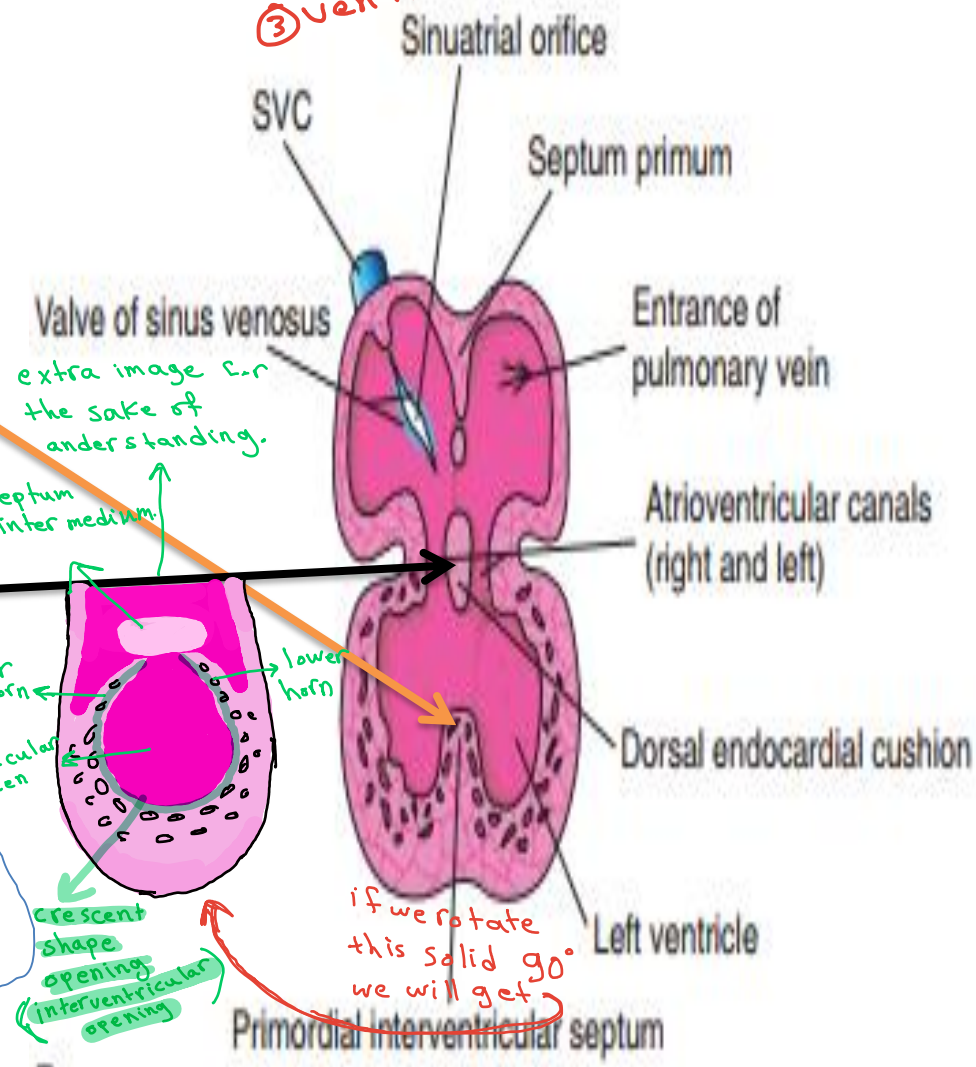

ventricular septum

- The upper cresentric border of the septum bounds a temporary connection between the two ventricles called ***the interventricular foramen***

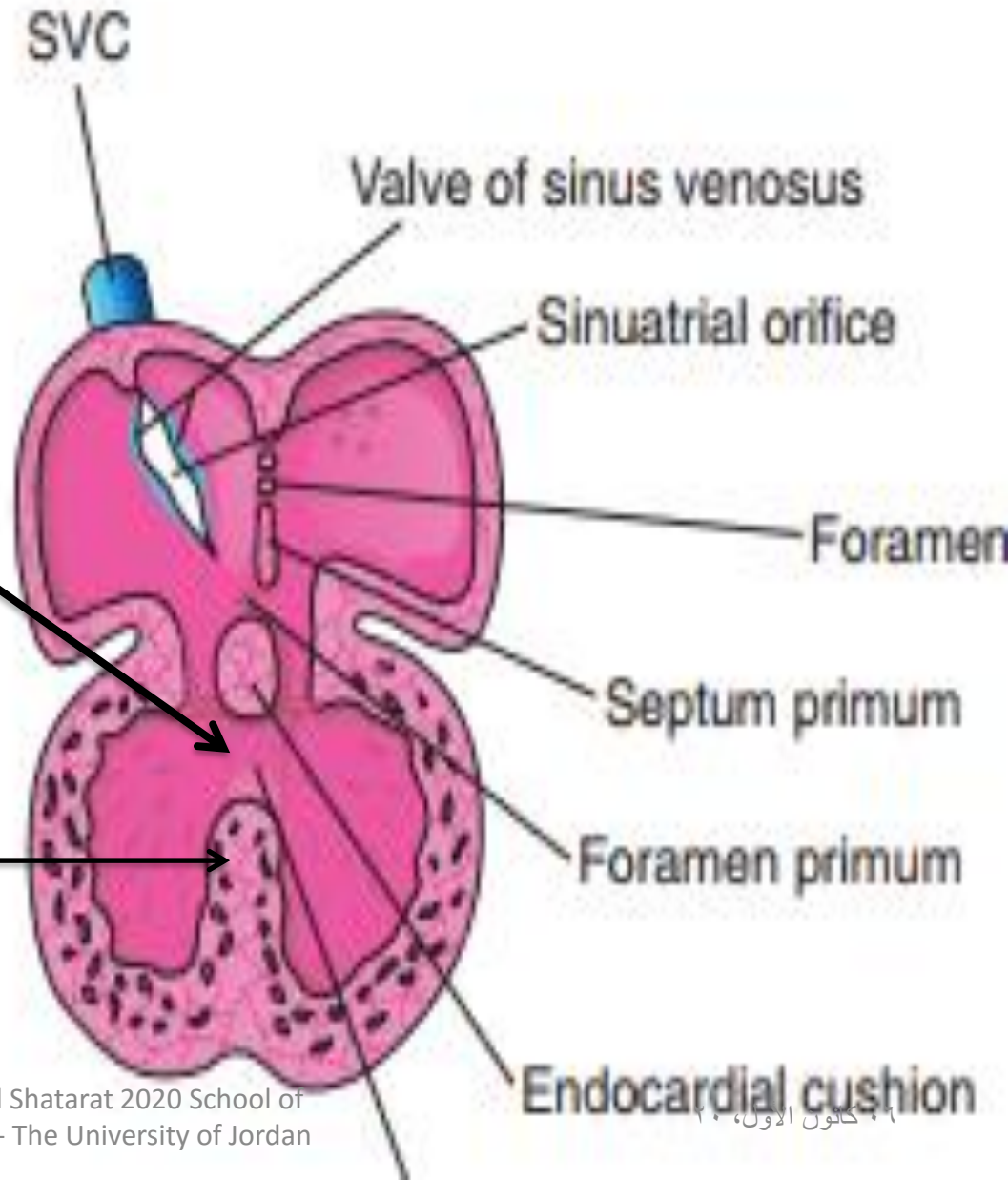

<u>The ventricular septum</u> forms **<u>the muscular part</u>** of the *<u>interventricular septum</u>*

* we said the ventricular septum has an ① anterior $\frac{2}{3}$ muscular part and ② posterior $\frac{1}{3}$ membranous part.

Until the seventh week, there is a crescent-shaped opening (IV foramen) between the free edge of the IV septum and the fused endocardial cushions.
The IV foramen permits communication between the right and left ventricles

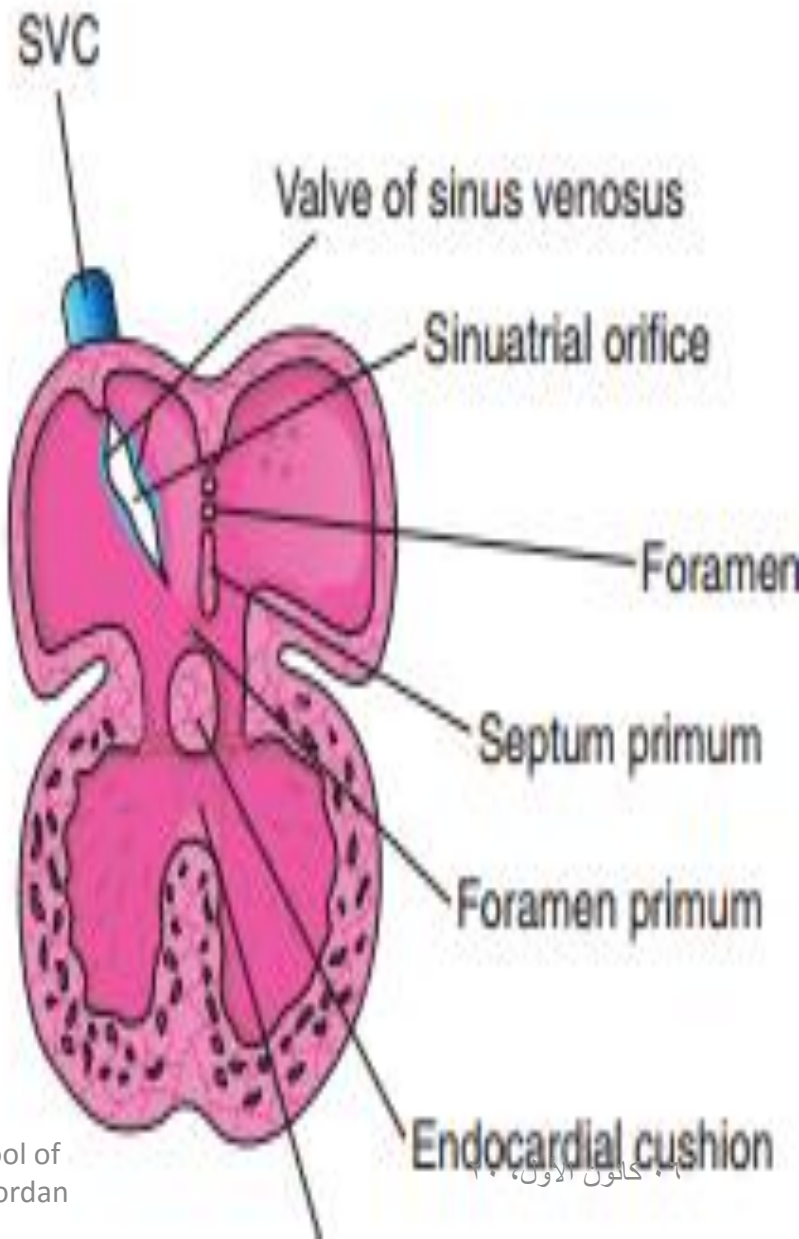

- At the end of the seventh week, a downward **extension occurs from the right margins of the a-v endocardial** septum (septum intermedium) to close the interventricular foramen.

endocardial cushion.

- This extension forms

<u>The Membranous Part</u>

of the interventricular septum

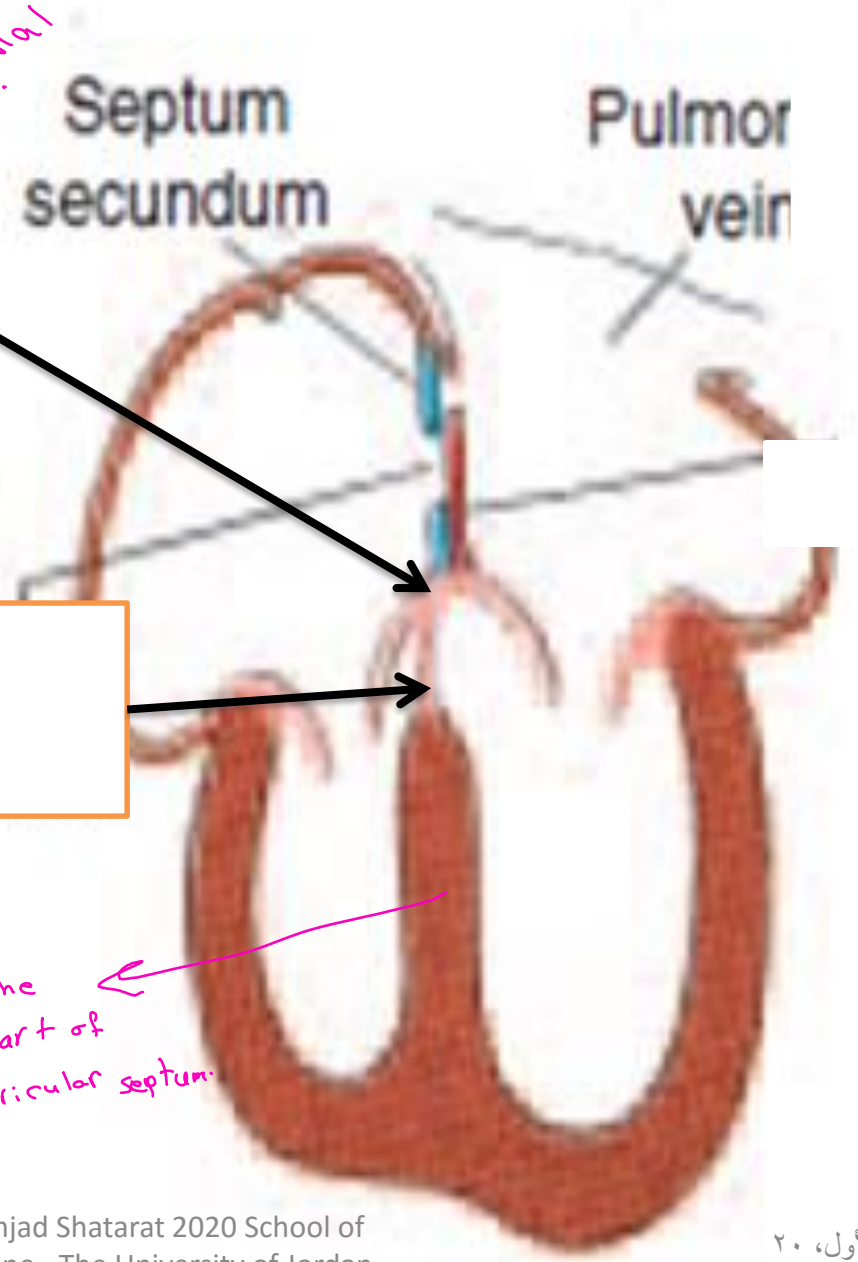

this is the muscular part of inter ventricular septum.

- The proximal bulbar septum develops as two ridges which fuse together they share in closing the interventricular foramen.

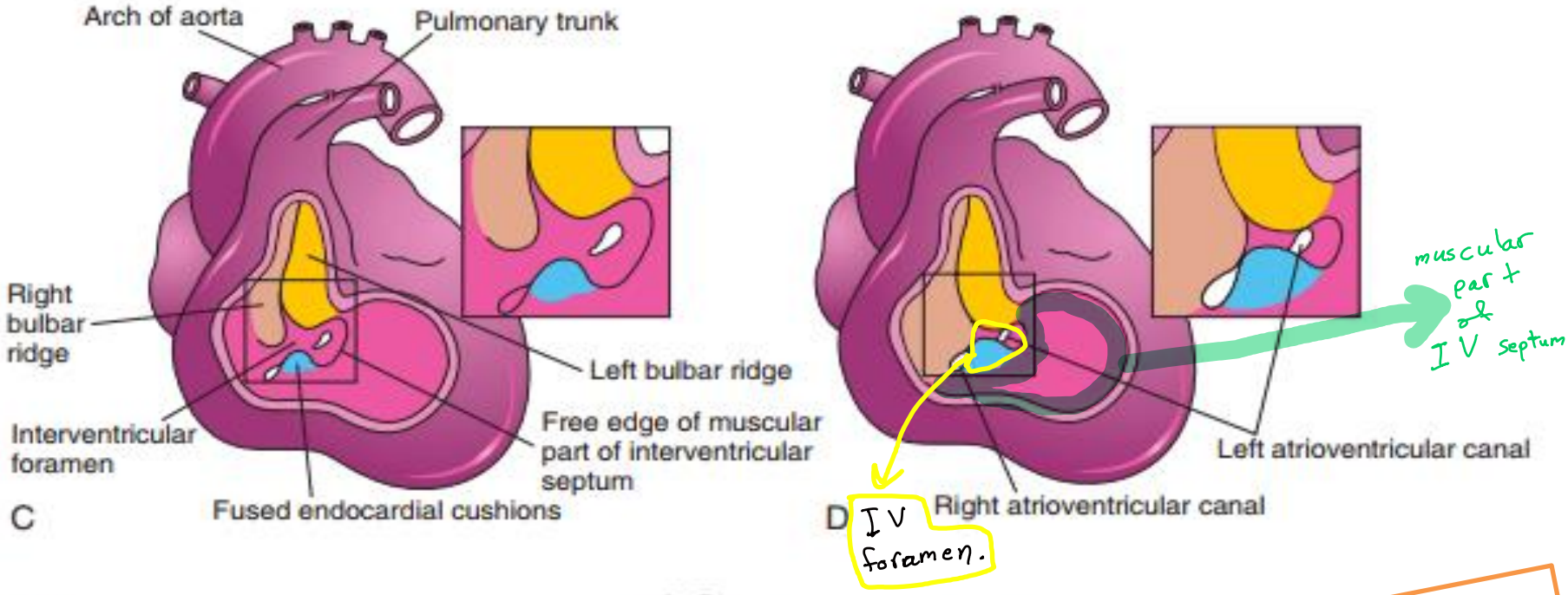

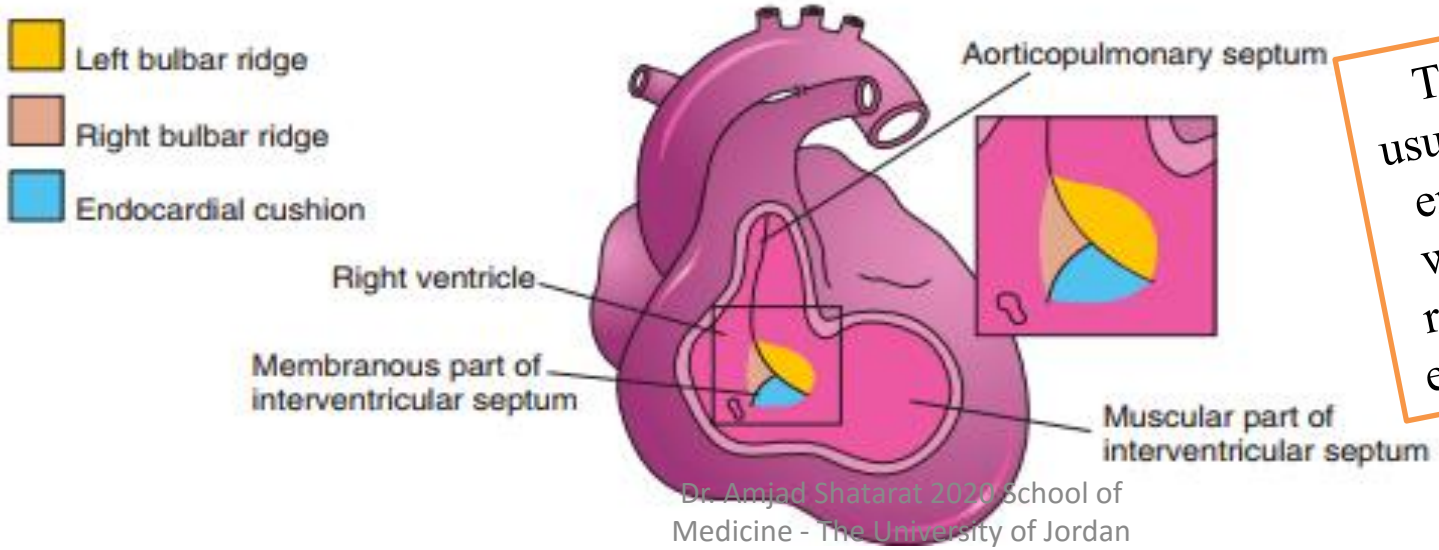

The IV foramen usually closes by the end of the seventh week as the bulbar ridges fuse with the endocardial cushion

in fact the formation of membranous part of IV septum is more complicated than this .
we already know that the IV septum is an out growth of inferior wall of ventricle growing up with its upper and lower horns approaching the endocardial cushion. and the endocardial cushion also participate in the closure of iv foramen by membranous part .put this is not enough, the foramen is superior in this wall and therefor an extension from the bulbous cordis called proximal bulbar septum will also participate in the closure of IV foramen. therefore you can see that the ventricular septum has 3 components one muscular and tow membranous the first from endocardial cushion and the second from proximal bulbar septum. don't you ever forget that we are talking about an coiled tube so the ventricles are continuous with bulbous cordis and with truncus arteriosus so for this septation to be completed we need the pulmonary trunk to exit from the right ventricle and we need ascending aorta to exit from the left ventricle and therefore our story will be continued in the next lecture.

Three distinct structures contribute to the formation of the postnatal ventricular septum:

1-The muscular ventricular septum

2-The proximal parts of the outflow cushions (spiral septum or the proximal bulbar septum)

3-The atrioventricular endocardial cushions.

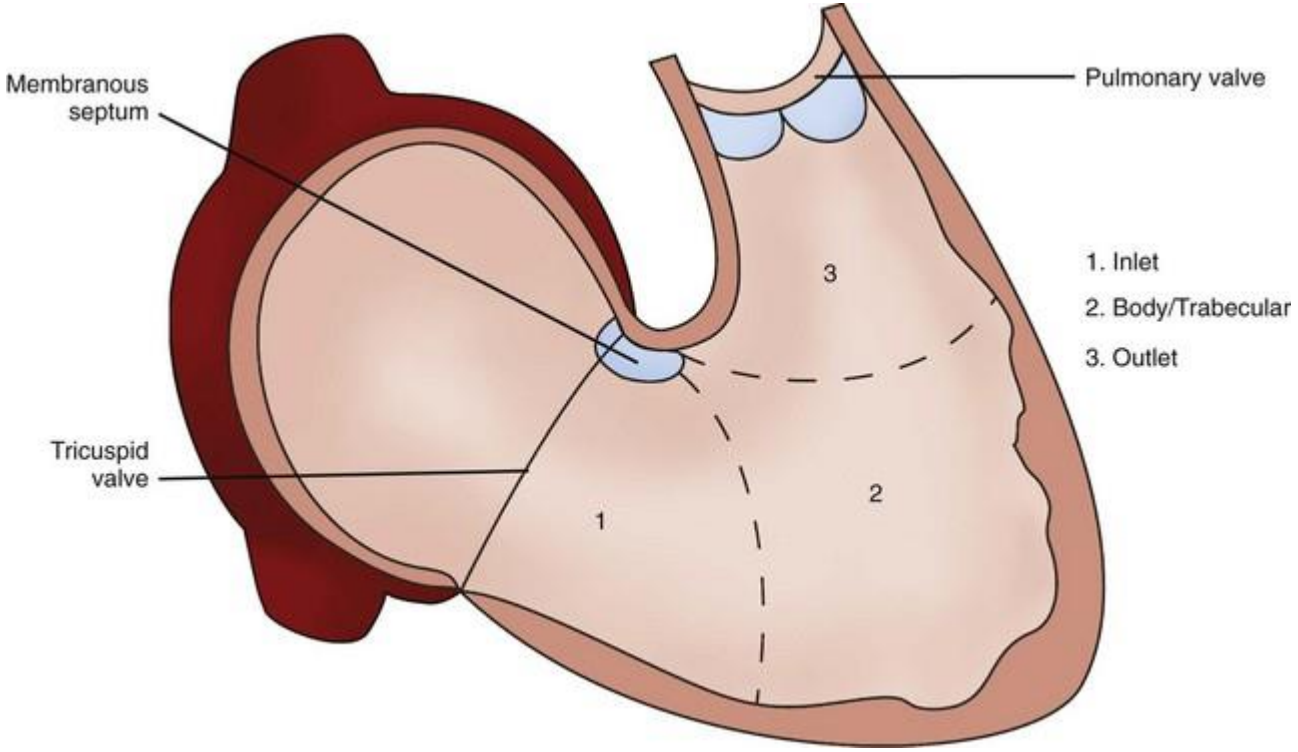

Membranous septal defects are the most common heart defect (25% of all congenital heart defects), partly because three basic primordia (**interventricular septum**, **spiral septum**, **endocardial cushions**) are required to fuse in an area of very dynamic blood flow. There is considerable opportunity for a failure of fusion of these elements at the location of **the membranous interventricular septum**

its a common rule im embryology if we take about any structure that made out of the union of more than tow structures the possibility that some of them would not meet the others is higher than we take about to structures meeting each other to form one another new structure.
Thats why membranous septal defect are the most common heart defect. 25% of all congenital heart defect.

Cyanosis is defined as a bluish discoloration of the skin and mucous membranes, due to excessive concentration of deoxyhemoglobin

Postnatal Shunts

we will take about the apperence of newly born babies.

Right-to-left shunts are **cyanotic conditions**

When the deoxygenated blood coming from the right chamber to the oxegynated blood on left chamber. the outcome is cyanosis.

Left-to-right shunts are non-cyanotic conditions

when The oxygenated blood from left chamber going to te deoxygenated blood of right chamber

Atrial Septal Defects Atrial septal defect (ASD)

- is one of several congenital heart defects
- It is more common in female births than in male
- Postnatally, ASDs result in ***left-to-right shunting*** and are ***non-cyanotic conditions***.

why is it left to right ?!

because After birth the pressure of left atrium is more than right atrium.

Two clinically important ASDs are the secundum and primum types

We sayed that after birth, When the pressure of left atrium increase, both septa (primum and secondum) woud close. here it would not !!

- Secundum-type ASD is the most common ASD
- It is caused by either an excessive resorption of the SP or an underdevelopment and reduced size of the SS or both.
- This ASD results in variable openings between the right and left atria in the central part of the atrial septum **above the limbus**.
- If the ASD is small, clinical symptoms may be delayed as late as age 30

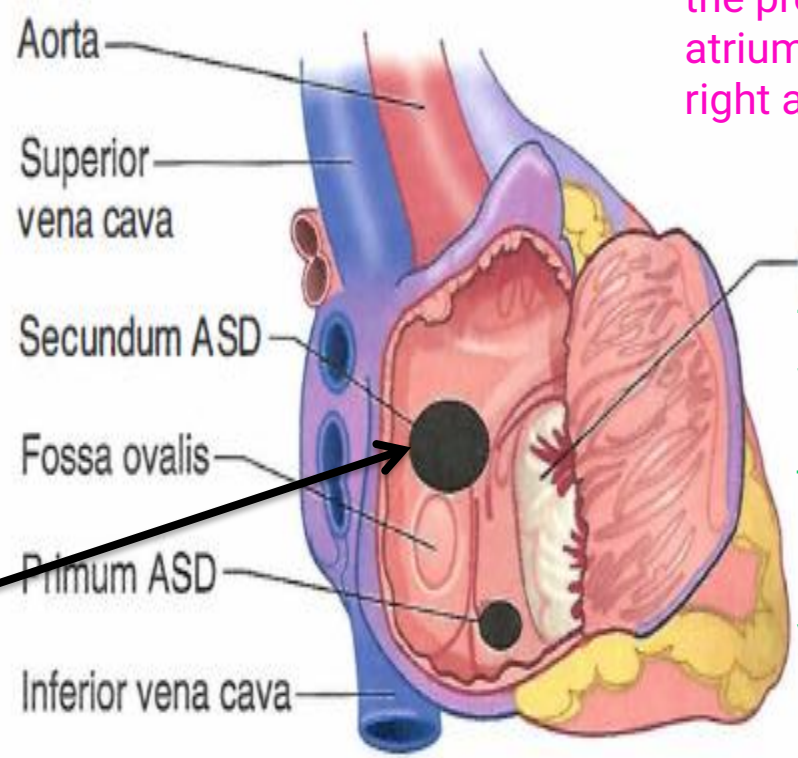

This mean you will not notice any difference in the external apperence of baby to alarm you that there is an opening between the tow atria.

Figure III-2-15 Secundum and Primum Atrial Septal Defect

In about 20% of cases, fusion of the septum primum and septum secundum is incomplete, and a narrow oblique cleft remains between the two atria.
This condition is called

probe patency

of the oval foramen; it does not allow intracardiac shunting of blood.

It is harmless

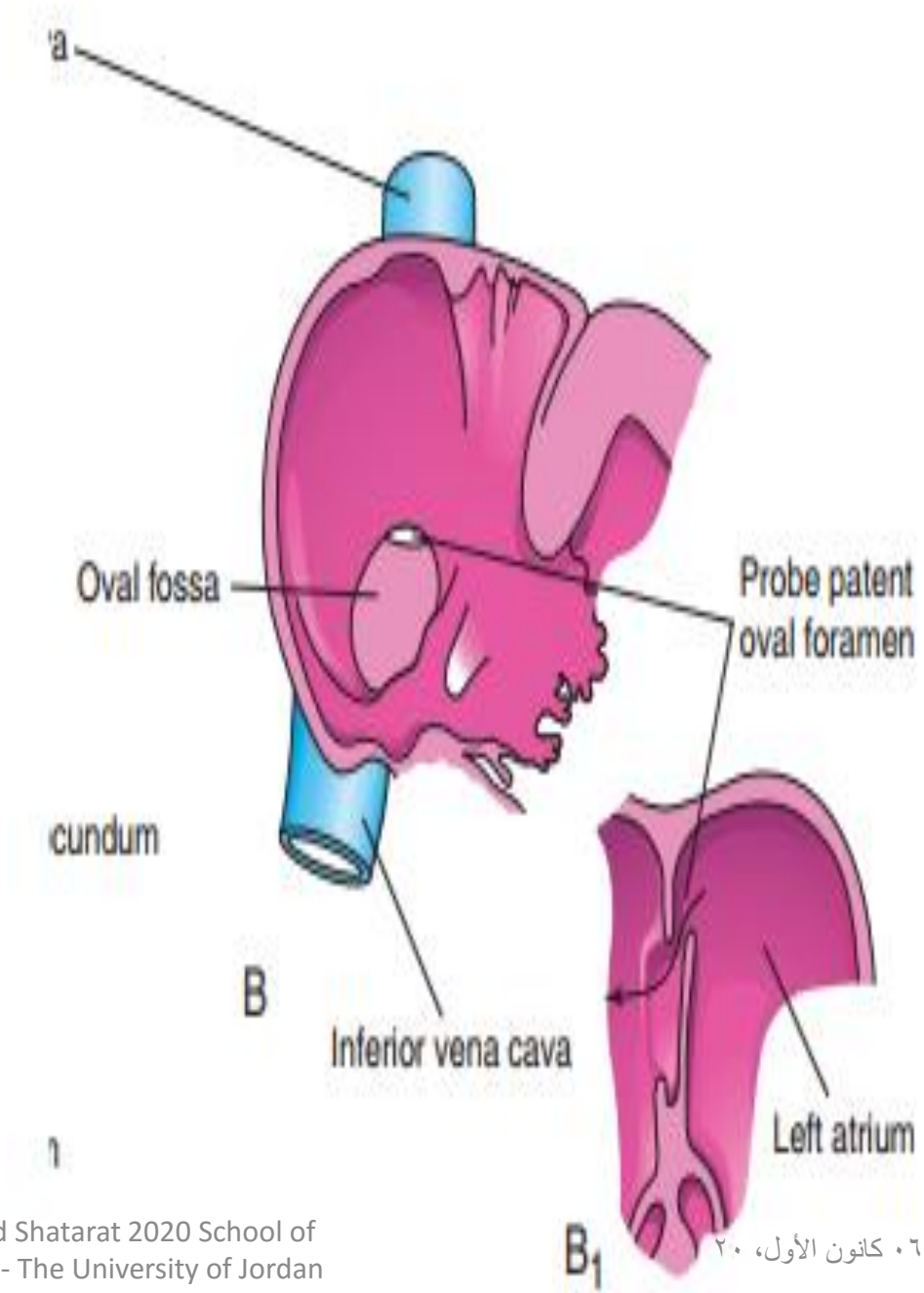

Ventricular septal defect (VSD)

- It is the most common of the congenital heart defects
- Being more common ***in males than in females***
- The most common **VSD is a membranous ventricular** septal defect, associated with the failure ***of neural crest cells*** to migrate into the endocardial cushions.

Ventricular septal defect (VSD)

- It results in **left-to-right shunting** of blood through the IV foramen.
- Patients with left-to-right shunting complain of excessive fatigue upon exertion.
- Left-to-right shunting of blood is

noncyanotic

- but causes increased blood flow and pressure to the lungs (pulmonary hypertension).
- Pulmonary hypertension causes marked proliferation of the tunica intima and media of pulmonary muscular arteries and arterioles.

Ultimately, the pulmonary resistance becomes higher than systemic resistance and causes right-to-left shunting of blood and late cyanosis. At this stage, the condition is called **Eisenmenger complex**

VSD have tow periods:

1. The first : is left to right wich is non cyanotic.
2. The second : is later if the condition is not treated. the shund would become right to left as the pressure of pulmonary system in the right overcome the systymatic pressure on the left. So we will see cyanosis

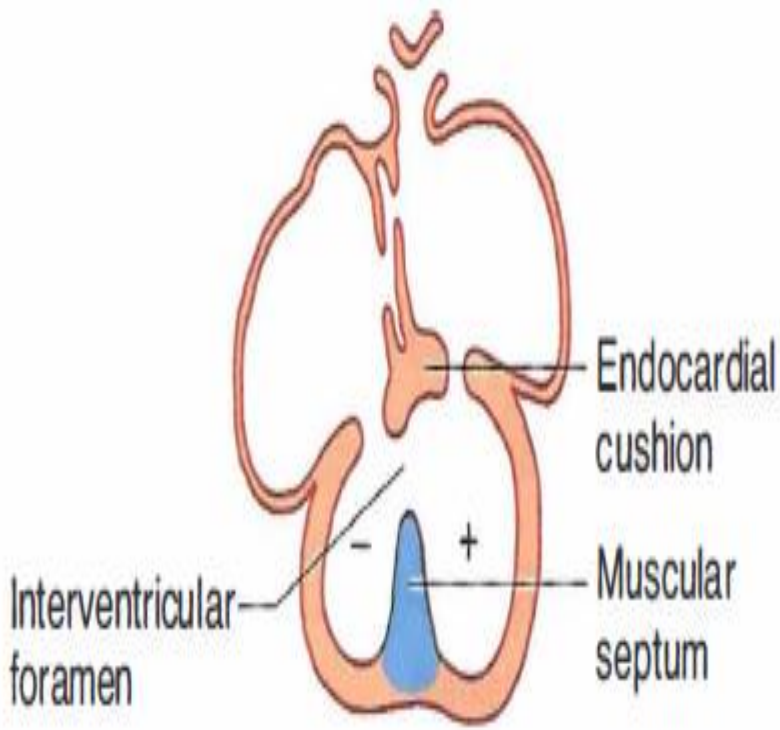

A

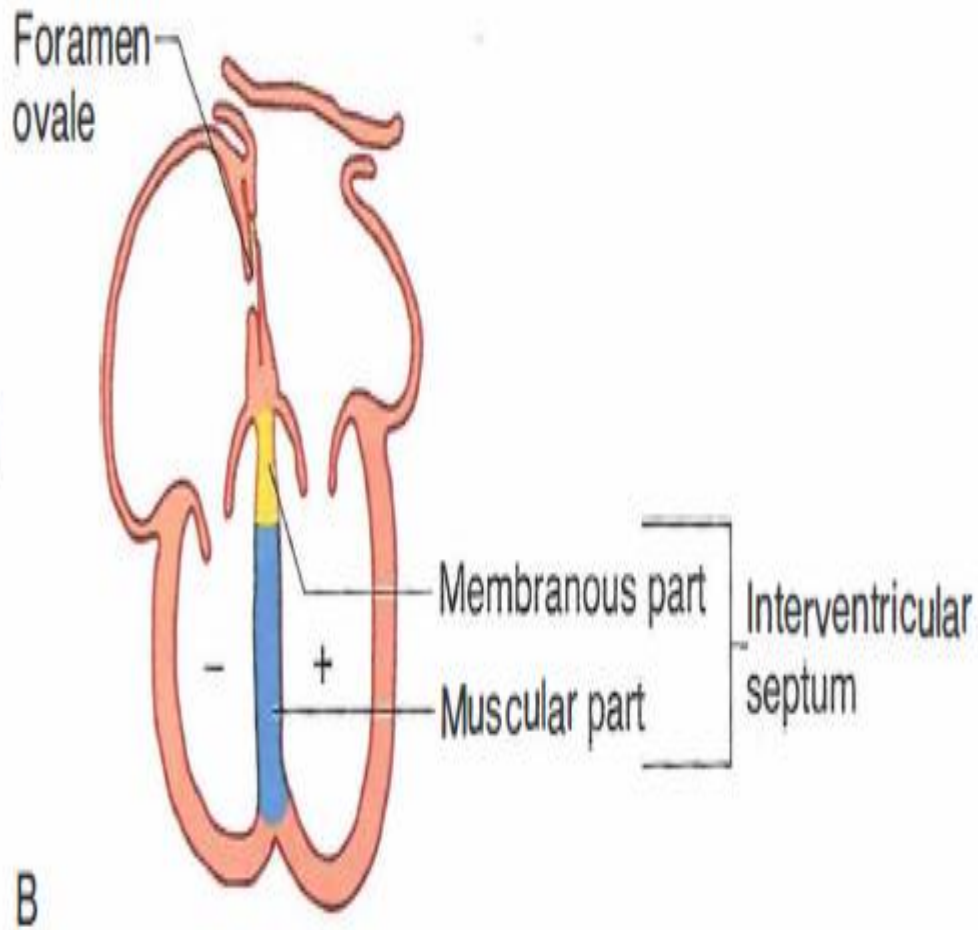

B