The heart B

Done by : Reham Badayneh

2- The right ventricle

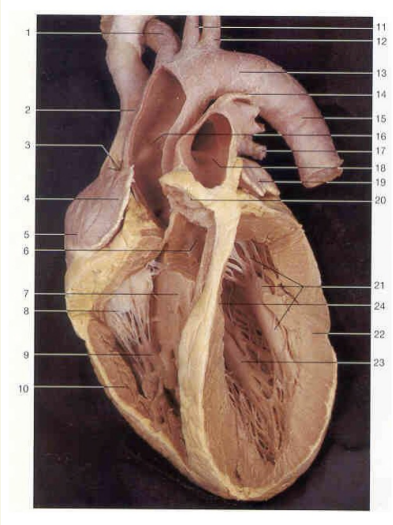

1:Brachiocephalic Trunk;
2:Superior Vena Cava;
4:Right Auricle;
5:Right Atrium;
6:Aortic Valve;
8:Tricuspid Valve;
9:Papillary Muscles;
10:Myocardium of Right Ventricle;
11:Left Common Carotid Artery;
12:Left Subclavian Artery;
13:Aortic Arch;
14:Ligamentum Arteriosum;
17:Pulmonary Vein;
18:Pulmonary Trunk;
19:Left Auricle;
20:Pulmonic Semilunar Valve;
21:Papillary Muscles;
22:Myocardium of Left Ventricle;
23:Papillary Muscles;
24:Interventricular Septum;

The right ventricle

1.

communicates with **the right atrium** through ***THE RIGHT ATRIOVENTRICULAR ORIFICE*** and with **the pulmonary trunk** through **THE PULMONARY ORIFICE**

2.

Entrance

Exit

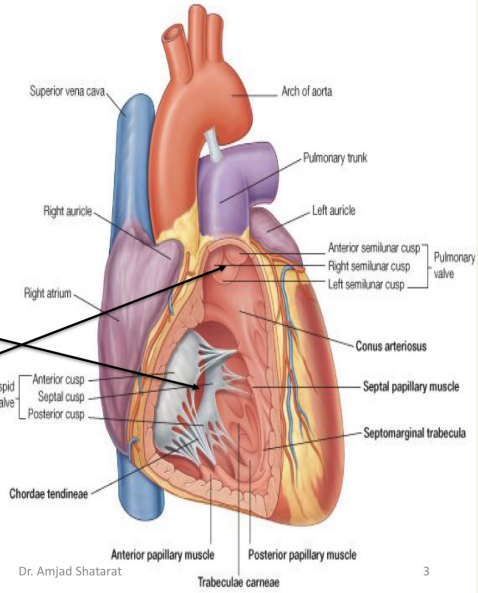

The tricuspid valve guards the right atrioventricular orifice and consists of ***three cusps*** formed by a fold of **endocardium** with **some connective tissue**

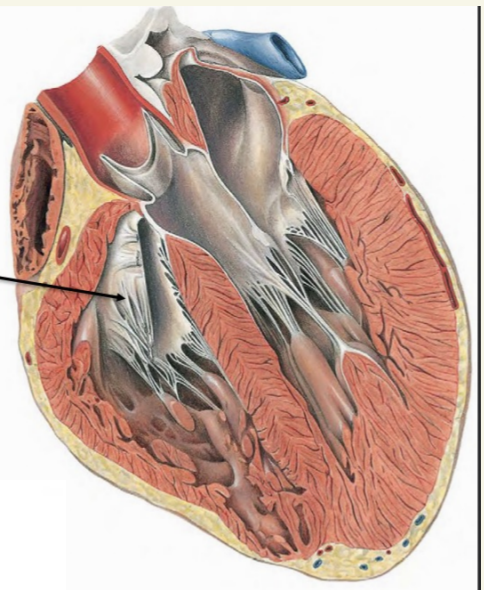

1- **inflow portion,** containing the tricuspid valve,

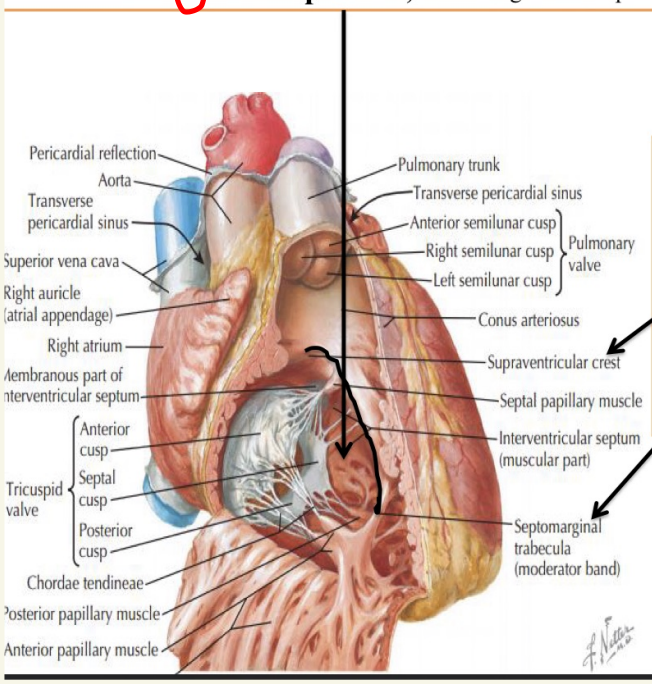

These two parts are separated by prominent muscular bands, including the parietal band the supraventricular crest **(crista supraventricularis)**

The septal band

The moderator band.

Inflow portion

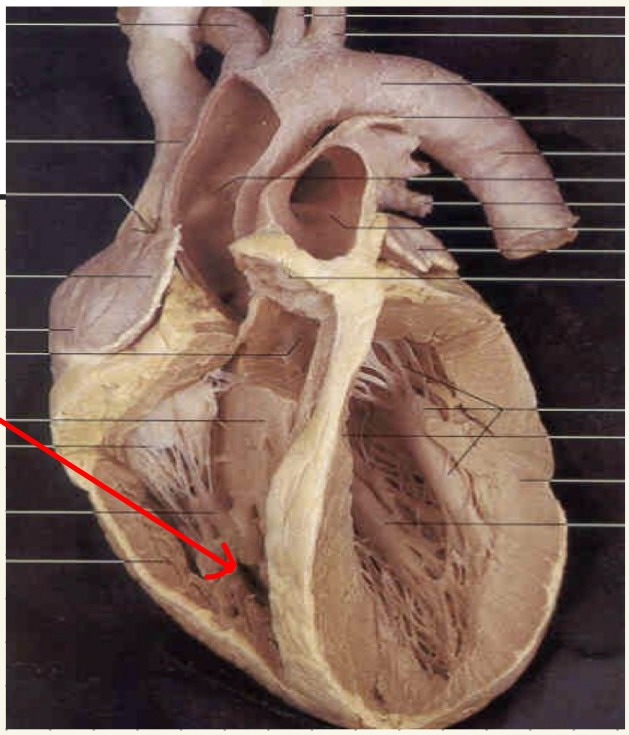

The walls of the inflow portion of the right ventricle have numerous muscular, irregular structures called **trabeculae carneae**

1- Prominent ***RIDGES*** attached to the ventricular walls throughout their length.

2-Attached at both ends, **forming BRIDGES**

3-The **PAPILLARY** muscles

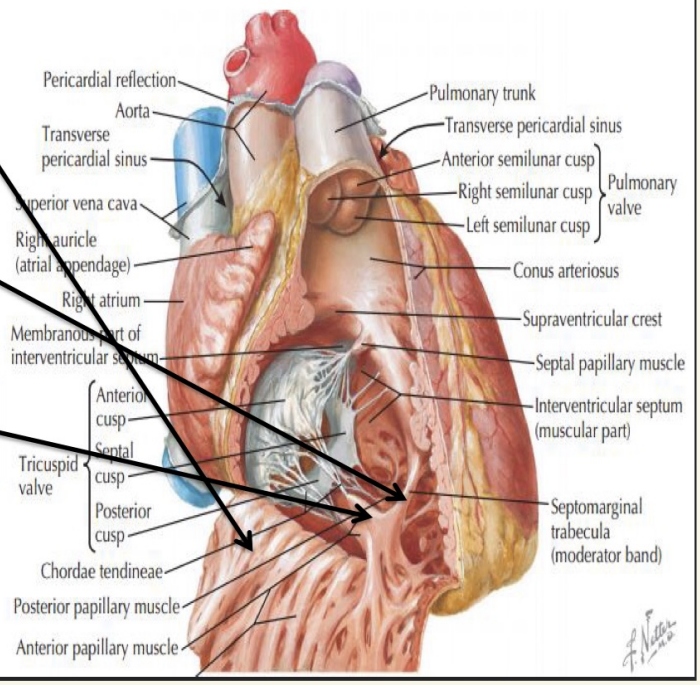

2-The outflow tract of the right ventricle, which leads to the pulmonary trunk, is the Conus arteriosus (infundibulum)

This area has smooth walls and derives from the embryonic bulbus cordis ; so , the two portions have different embryogenic origins .

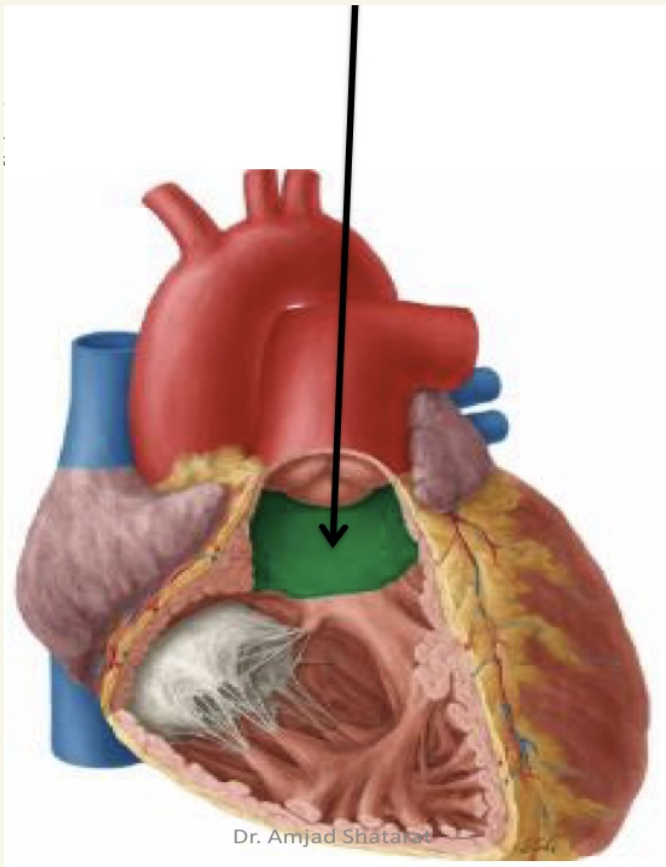

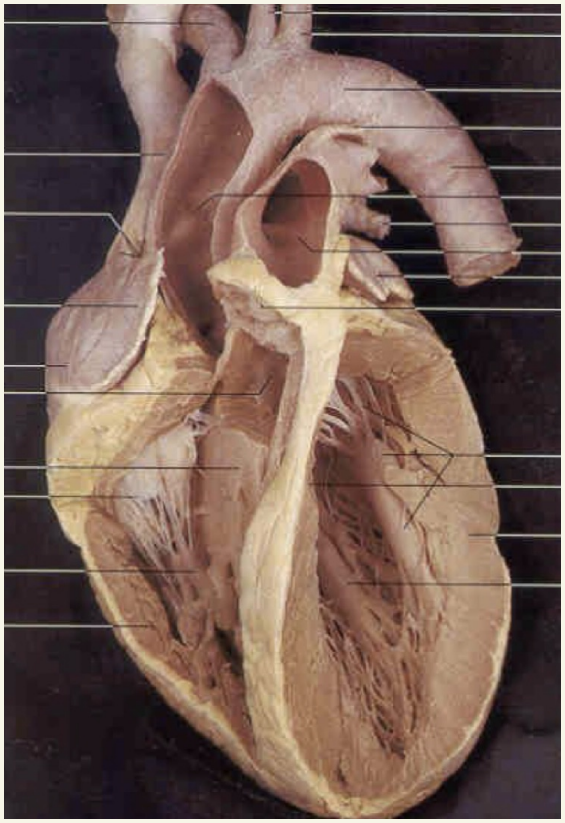

So the right atrium's job is only to collect the blood and then contracts to push the blood into the right ventricle whereas , the right ventricle's job is to maintain the blood flow in one direction (From the right ventricle towards the pulmonary trunk) .

Why it is important to have two rooms (two portions) of the right ventricle ??

This is because if we have one room for the blood to move in the right ventricle , the blood will re enter the right atrium (as shown below)

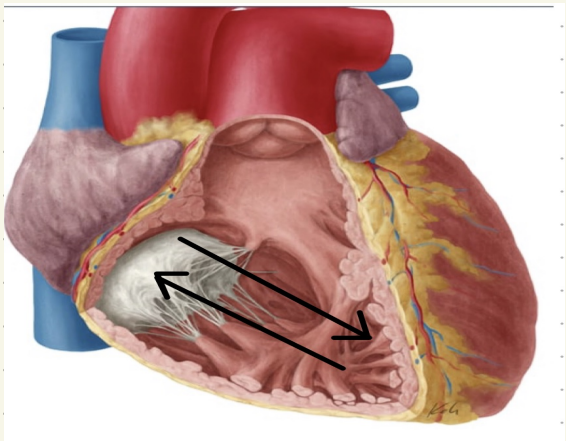

But , instead we have two rooms , so that the blood enter the inflow portion (from the right atrium to the right ventricle) and then it passes to the second outflow portion(From the right ventricle to the pulmonary trunk) . How is this possible ?? By means of the muscular bands that separate the two portions .

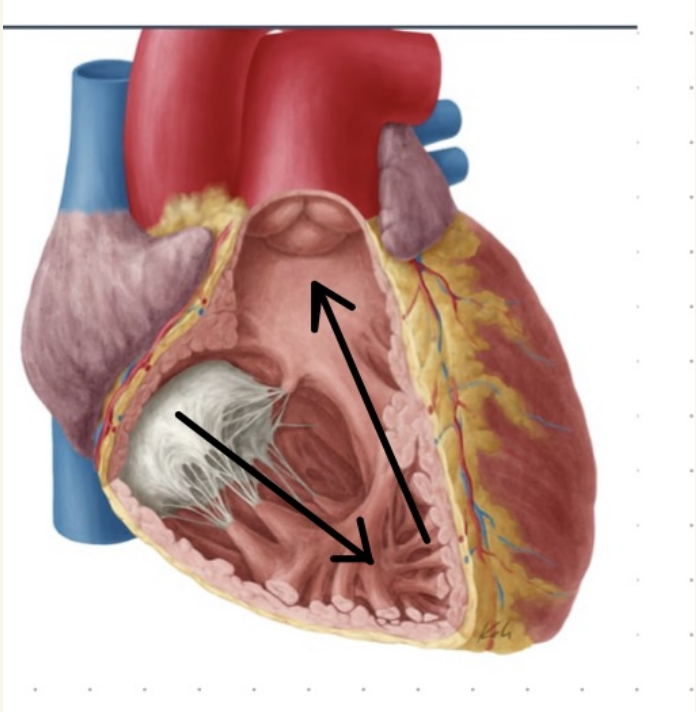

It is VERY important to know the directions of the papillary muscles

There are three papillary muscles in the right ventricle. Named relative to their point of origin on the ventricular surface, they are the
ANTERIOR, POSTERIOR, AND SEPTAL PAPILLARY MUSCLES

1. THE **ANTERIOR PAPILLARY muscle** is *the largest and most constant* papillary muscle, and arises from the anterior wall of the ventricle

It is also called the inferior papillary muscle

2. **The POSTERIOR PAPILLARY MUSCLE** ***may consist of one, two, or three structures,*** with some chordae tendineae arising directly from the ventricular wall

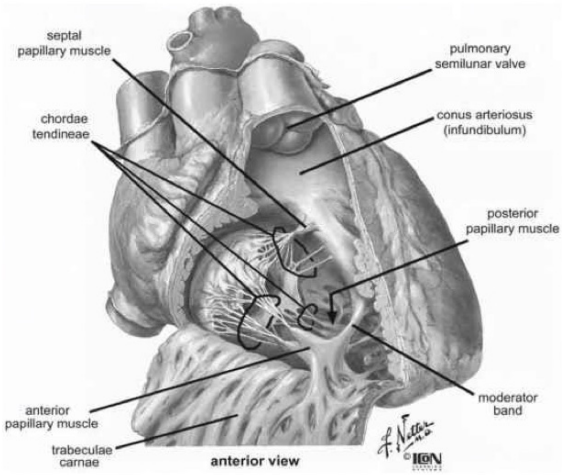

3. THE **septal papillary muscle** is the most inconsistent papillary muscle, being either small or absent, with chordae tendineae emerging directly ***from the septal wall***.

A single specialized trabeculum, the **septomarginal trabecula (moderator band)**, forms a bridge between the lower portion of the **interventricular septum** and the base of **the anterior papillary muscle**.

The septomarginal trabeculum carries a portion of the cardiac conduction system, **RIGHT BUNDLE OF THE ATRIOVENTRICULAR BUNDLE**, to the anterior wall of the right ventricle

This "shortcut" across the chamber seems to facilitate conduction time, allowing coordinated contraction of the anterior papillary muscle

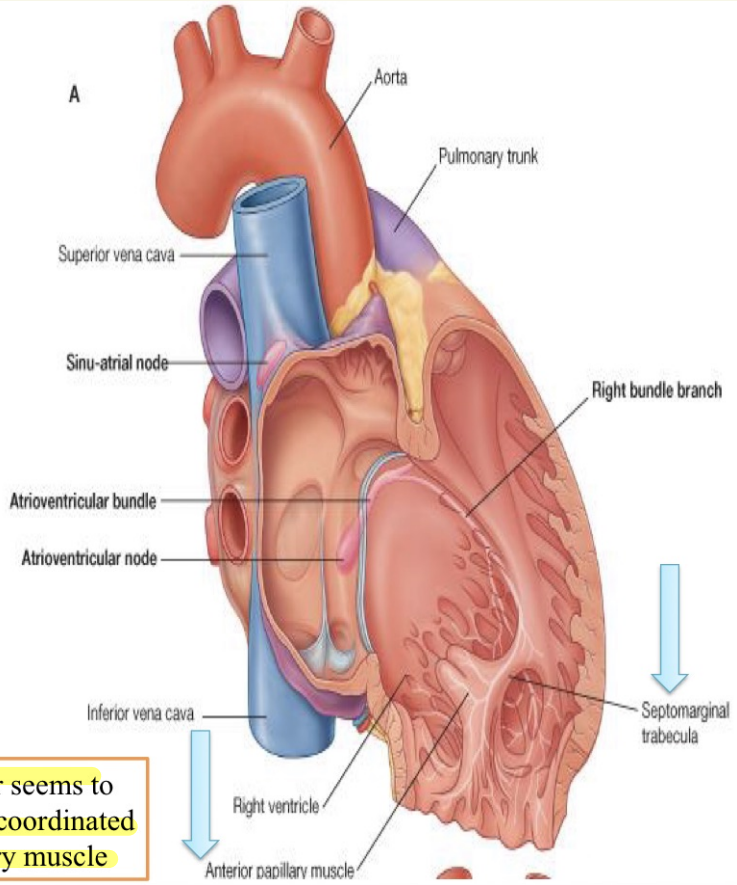

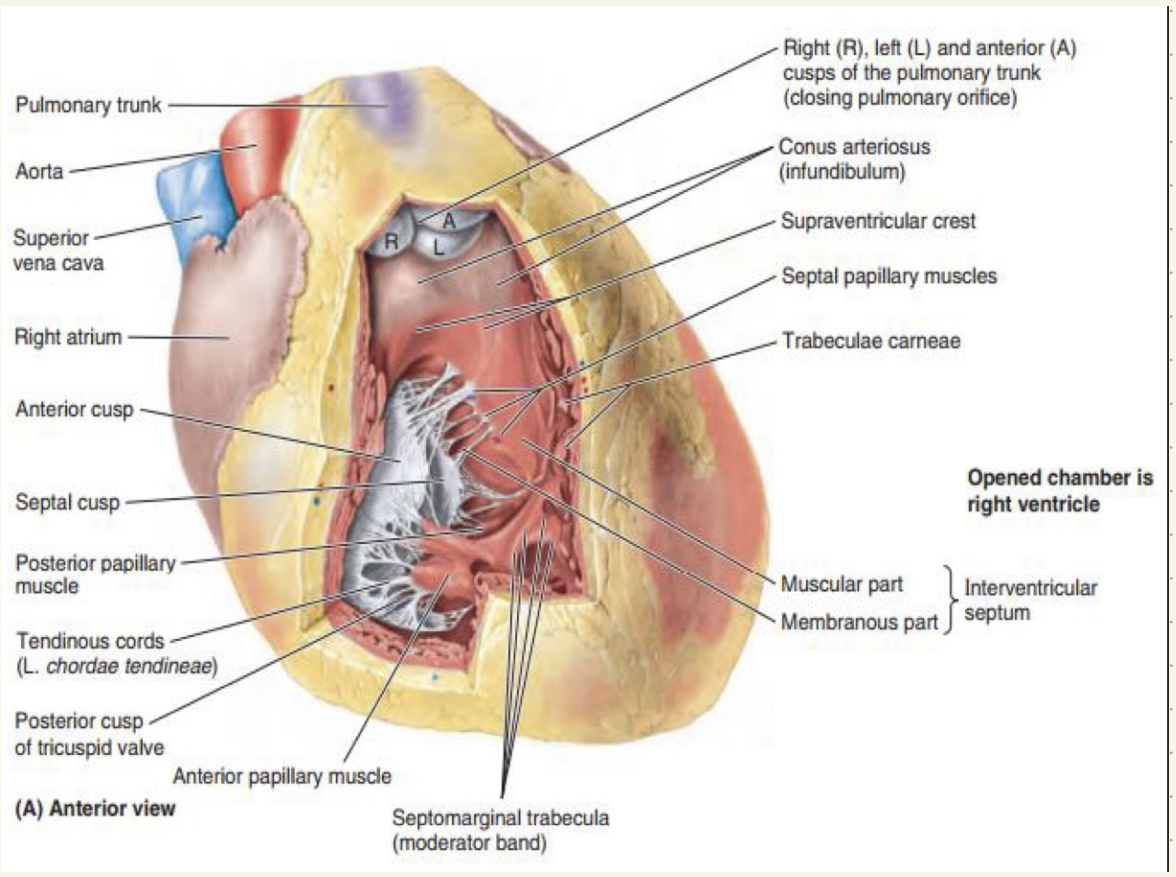

1 ➢ The right atrium contracts when the right ventricle is relaxed

2 ➢ Thus blood is forced into the right ventricle, pushing the cusps of the tricuspid valve aside ***like curtains***

3 ❖ The inflow of blood into the right ventricle **(inflow tract)** enters **posteriorly** and when the ventricle contracts, the outflow of blood into the pulmonary trunk **(outflow tract)** **superiorly and to the left**

4 ❖ Consequently, the blood takes a **U-shaped path** through the right ventricle, changing direction about 140°.

❖ This change in direction is accommodated by: ***the supraventricular crest***, which deflects the incoming flow into the main cavity of the ventricle, and the outgoing **flow into the conus arteriosus** toward the **pulmonary orifice.**

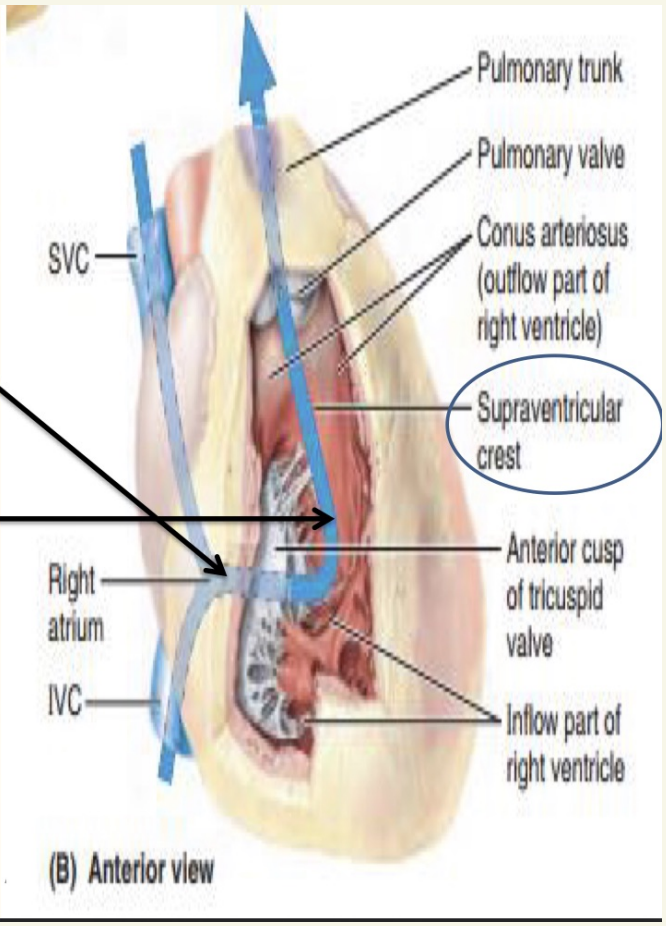

* **Remember that the right atrium lies posterior to the Right ventricle**

The interventricular or ventricular septum

septum (IVS) composed of :-
MUSCULAR & MEMBRANOUS parts

- is a strong, obliquely placed partition between the right and left ventricles
forming part of the walls of each. Because of the much higher blood pressure in the left ventricle,
the muscular part of the IVS, which forms the majority of the septum, has
the thickness of the remainder of the wall of the left ventricle (two to three times as thick as the wall of the right ventricle ;
This is because the right ventricle pupms the blood to the lungs , while the left ventricle pumps the blood to the whole body tissues)

-bulges into the cavity of the right ventricle.

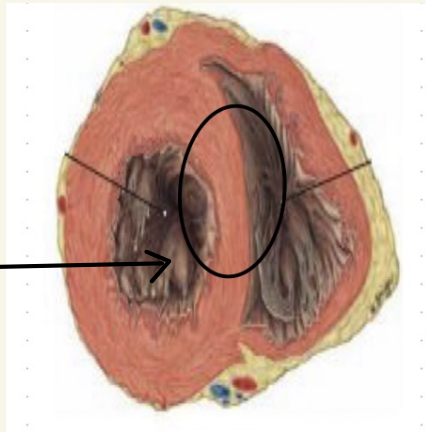

So in a cross section of the ventricles you can differentiate between the right ventricle and the left ventricle according to :-

1- The thickness of the wall of the ventricle :
The left is thicker than the right

2- The shape of the ventricle's cavity :
The left has circular-shaped cavity and the right has almost a pyramidal-shaped cavity

3- The bulging of the ventricular septum is into the cavity of the right ventricle .

We can say towards the atrium

Superiorly and posteriorly, a thin membrane, part of the fibrous skeleton of the heart forms the much smaller membranous part of the IVS.

On the right side, the septal cusp of the tricuspid valve is attached to the middle of this membranous part of the fibrous skeleton.

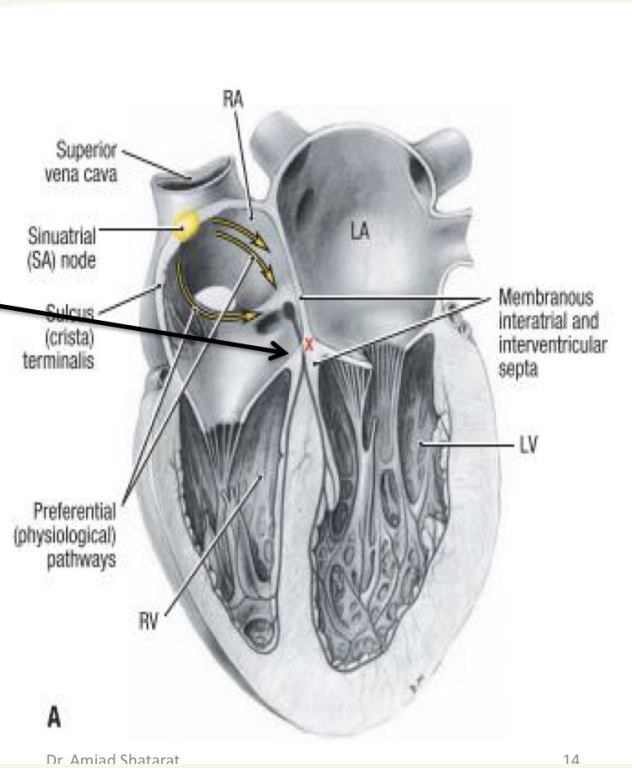

The majority of defects in the heart happen in the membranous part of the ineratrial and interventricular septa .

A.

This means that inferior to the septal cusp of the tricuspid valve ,

the **membranous part of the IVS is interventricular septum** (between the right and left ventricles)

B.

However, superior to the septal cusp of the tricuspid valve

it is

an **atrioventricular septum**

separating the right atrium from the left ventricle

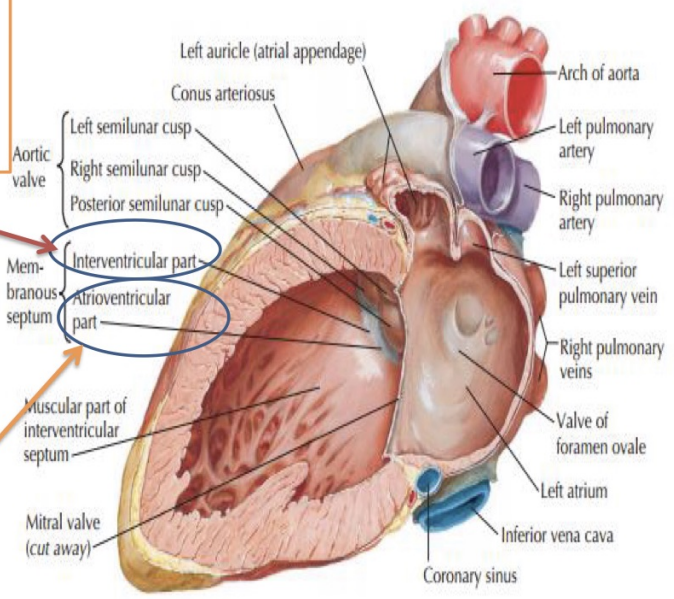

Section through left atrium and ventricle with mitral valve cut away

VIP

If we have a defect in the inferior part we will have a blood shunt from the left ventricle (high pressure) to the right ventricle (Low pressure) , but if we have a defect in the superior part we will have a blood shunt form the left ventricle to the right atrium .

3- Left Atrium

Left Atrium

consists of a main cavity and a left auricle.

Behind it lies the fibrous pericardium separates it from the esophagus (***remember that the esophagus has a close relationship with the left atrium)***

Remember that we can reach the heart through the esophagus , without surgery or opening of the thorax

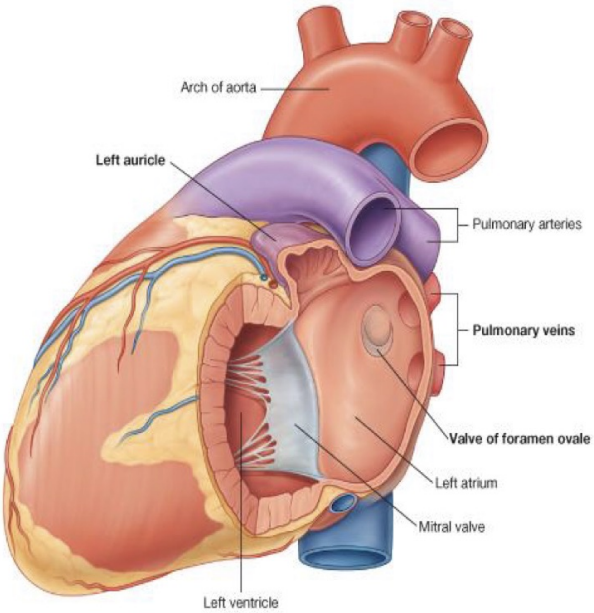

Remember we don't have the trachea here since it bifurcated and ended in the plane between the superior and inferior mediastinum

Remember that we have on the left of the esophagus we have the descending aorta .

The left atrium forms most of the base of the heart

- Although smaller in volume than the right, the left atrium has thicker walls (3 mm on average).

The left atrium is roughly cuboidal and extends behind the right atrium, separated from it by the obliquely positioned septum,
Thus the right atrium is in front and anterolateral to the right part of the left atrium.

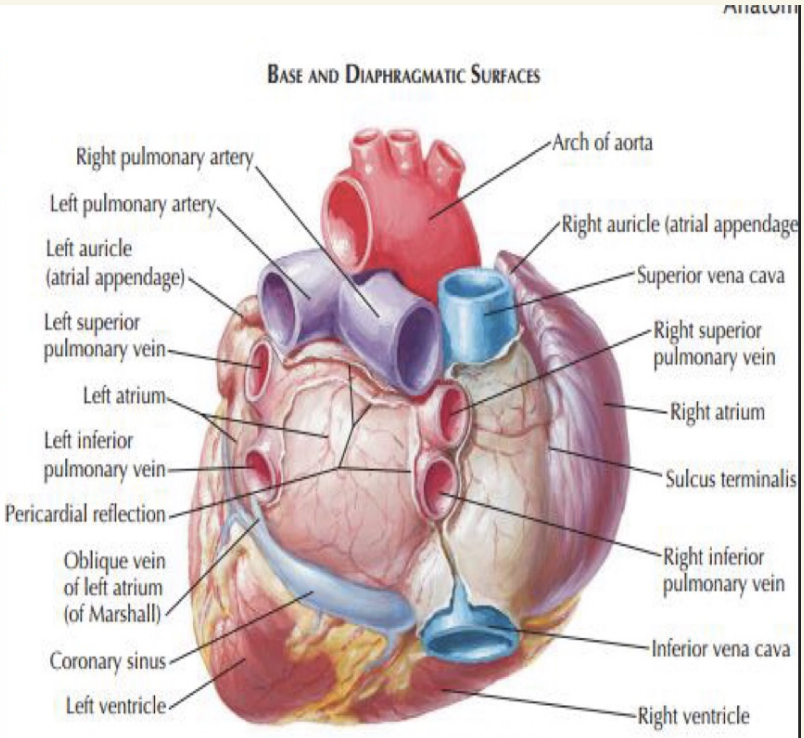

Base of heart: posterior view

Rough part

The left auricle, it represents the remains of the left part of the primordial atrium and therfore, its wall trabeculated with pectinate muscles

A larger smooth-walled part and a smaller muscular auricle containing pectinate muscles

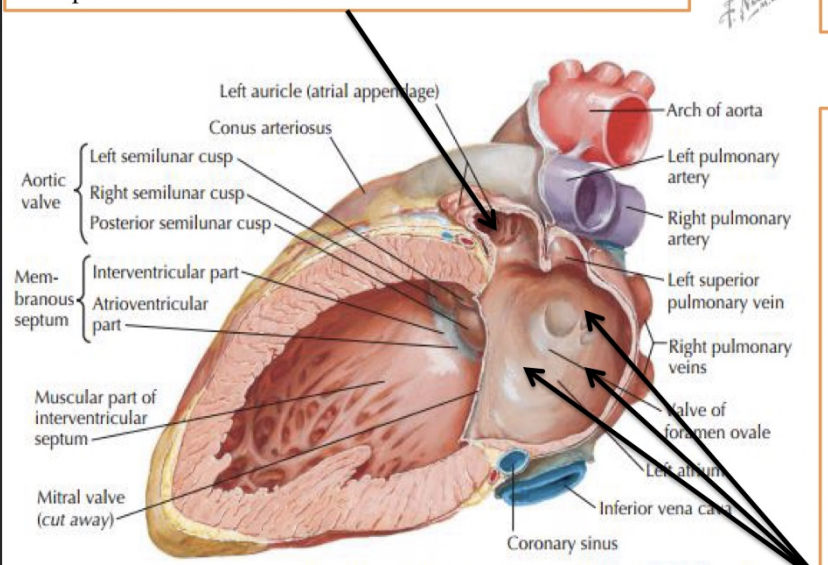

Section through left atrium and ventricle with mitral valve cut away

Smooth part

In the embryo, there is only **one common pulmonary vein** with **four tributaries** (the future 4 pulmonary veins)
The walls of these veins were incorporated into the wall of the left atrium
(in the same way that the sinus venosus was incorporated into the right atrium) therefore, **this part is smooth.**

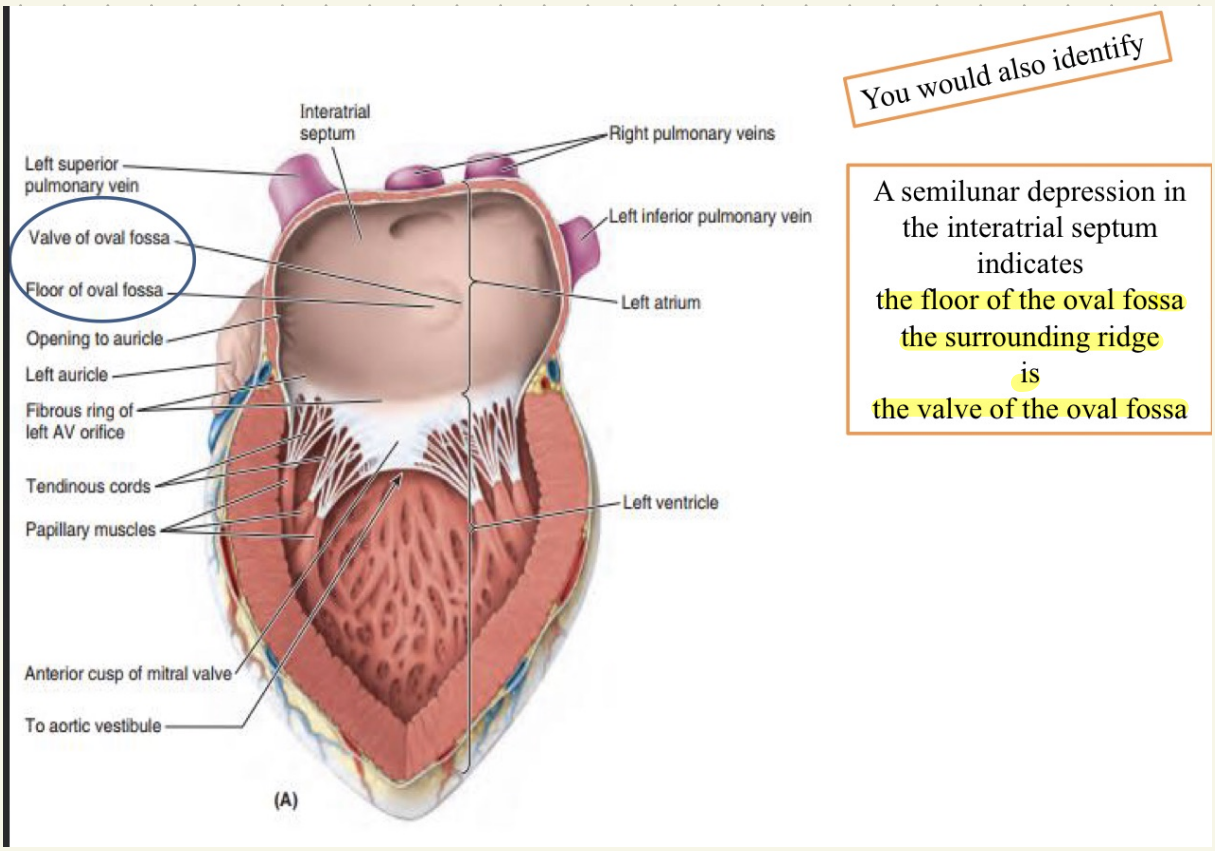

You would also identify

A semilunar depression in the interatrial septum indicates
the floor of the oval fossa
the surrounding ridge
is
the valve of the oval fossa

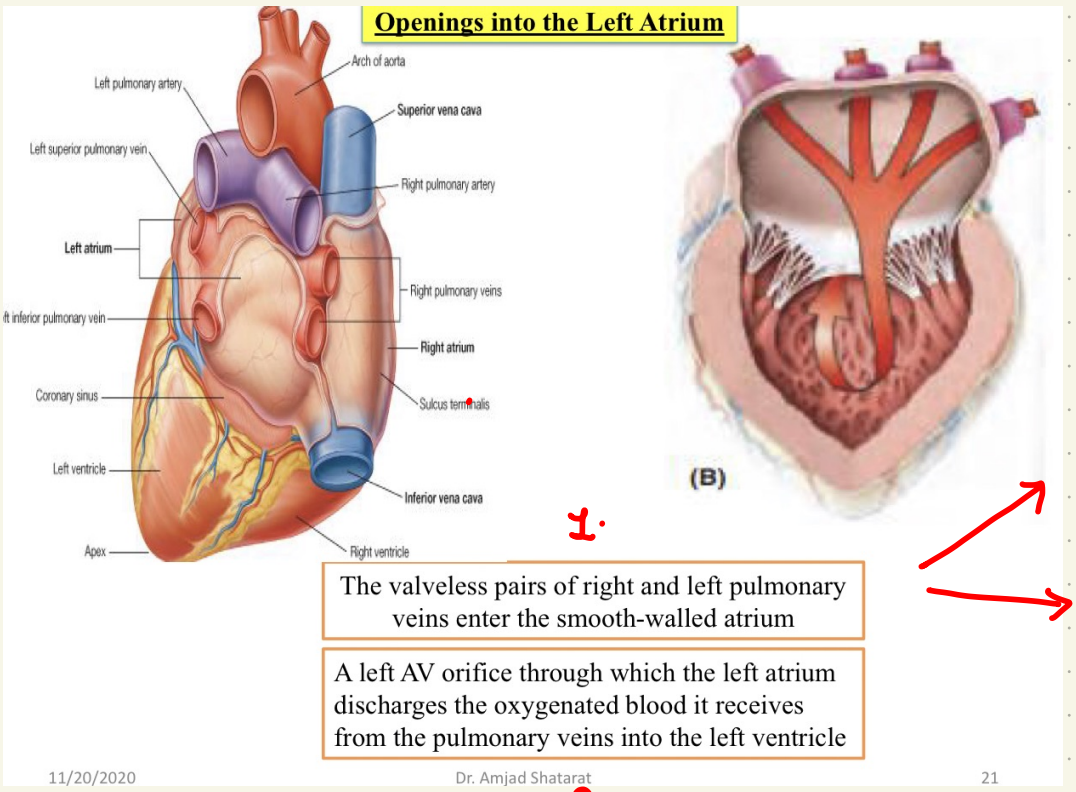

Superior right and superior left

Inferior right and inferior left

2.

Why we called them veins , why ??
Because it carries blood to the heart
Artery : a vessel carrying blood (regardless if it is oxygenated or deoxygenated) towards the heart
Vein : a vessel carrying blood (regardless if it is oxygenated or deoxygenated) away from the heart

4- The left ventricle

The left ventricle has:

1-**An inlet region, guarded by the mitral valve (ostium venosum)**

2-An outlet region, guarded by the aortic valve (ostium arteriosum)

3-An apical trabecular component.

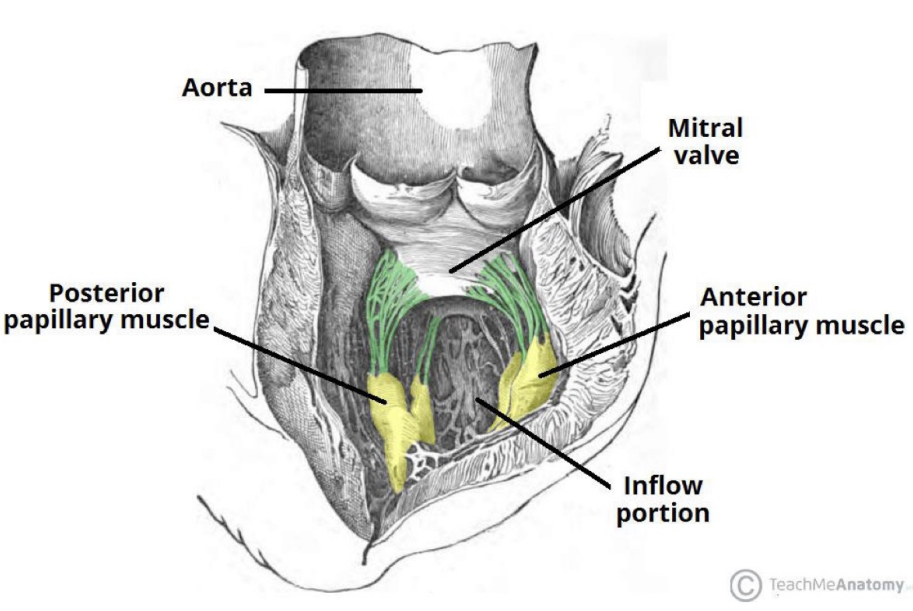

The higher the pressure the thicker the wall

- The left ventricle forms the apex of the heart, nearly all its left (pulmonary) surface and border, and most of the diaphragmatic surface

The walls of the left ventricle ***are three times thicker than those of the right ventricle***. (The left intraventricular blood pressure is six times higher than that inside the right ventricle.)

The left ventricle is a conical cavity that is longer than that of the right ventricle

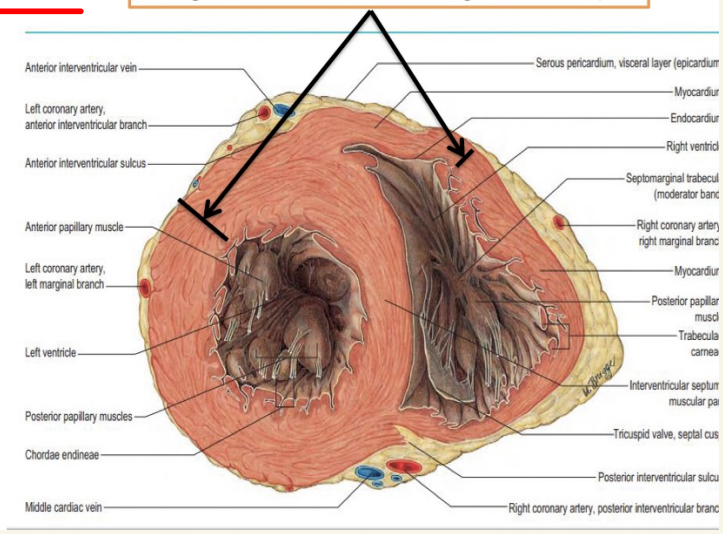

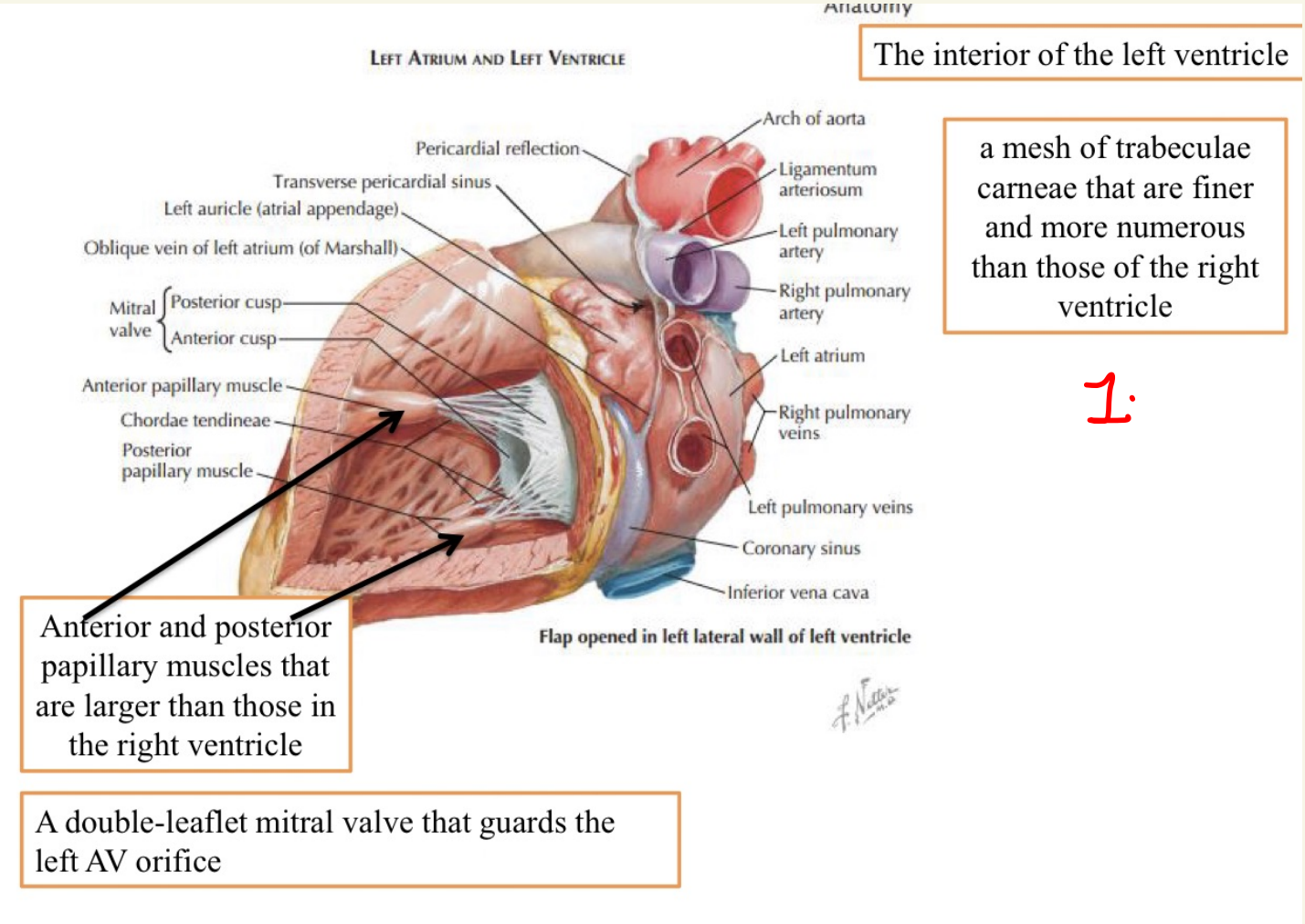

Remember that we have in the right ventricle 3 papillary muscles (anterior , posterior or inferior and septal and we said that some of them could be inconsistent such as the septal one and to a lesser extent the posterior and the most consistent is the anterior one .

But in the left ventricle due to the higher pressure you would expect to see 4-5 papillary muscle , but surprisingly we only have two papillary muscles BUT these muscles are much larger than those of the right ventricle , so the number here is compensated by the size of the papillary muscles .

You would ask here also why do we have only 2 not more ??
It is not about the number its about the thickness , the design....etc .
You would appreciate why we have only 2 not 3 if we follow the blood flow inside the left ventricle . If we need another cusp we would take from the septum , if we do so we will close the entrance of the blood to the aorta , this is why it is BICUSPID valve not TRICUSPID valve .

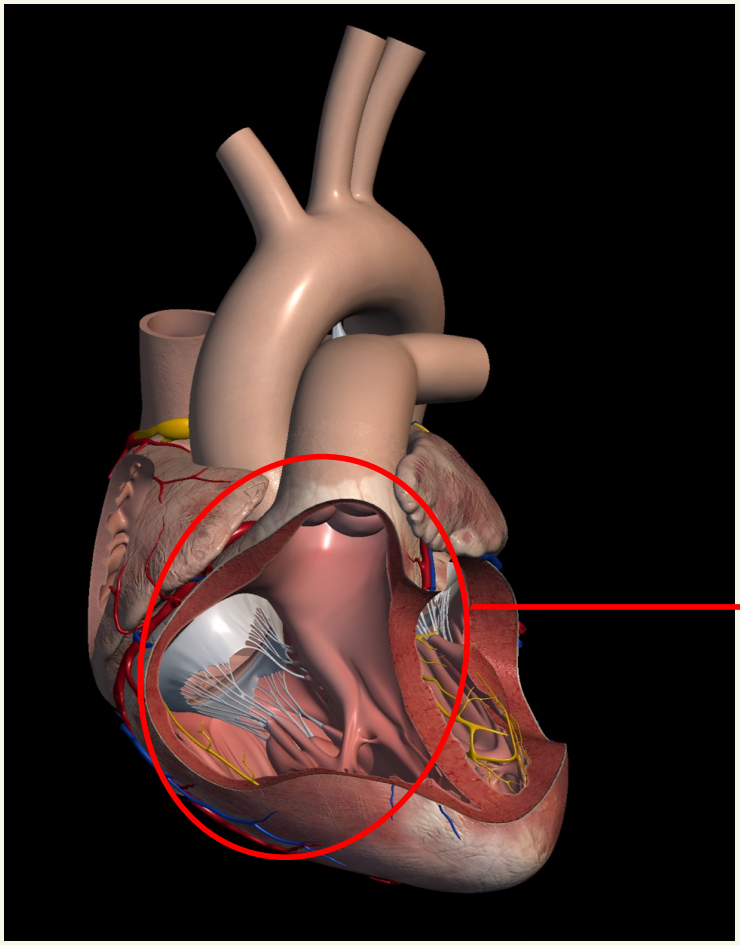

In the right ventricle , we can see the rough and the smooth part of the ventricle

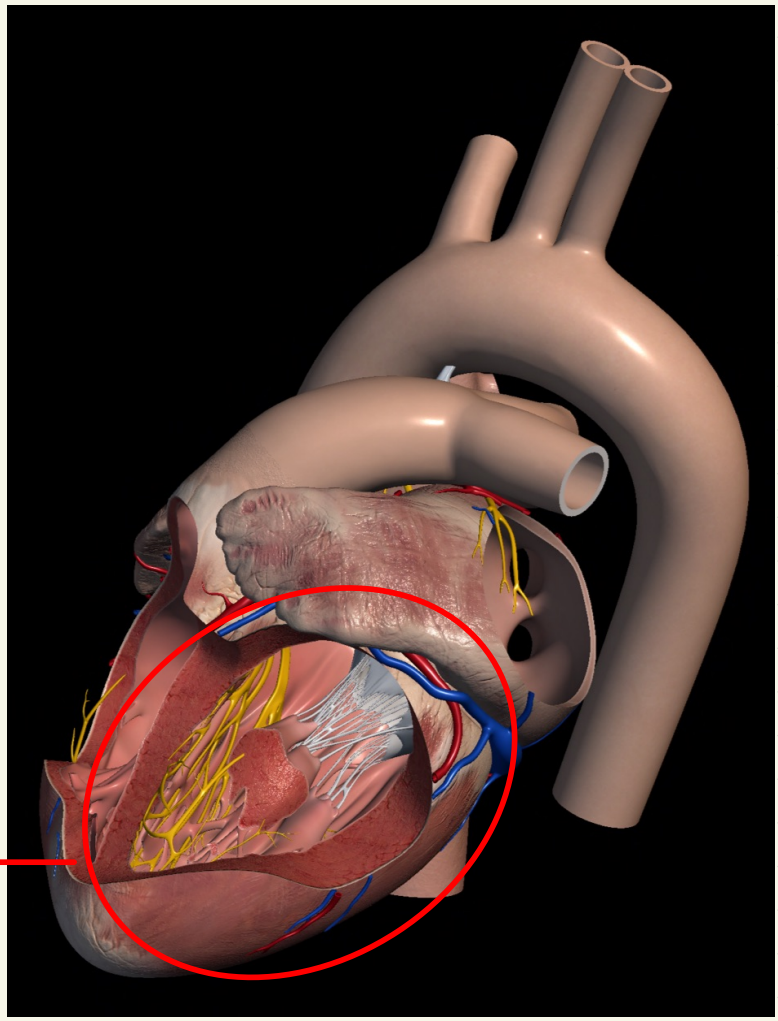

But in the left ventricle , we can see the rough part only and we need to open more in order to see the smooth part

2.

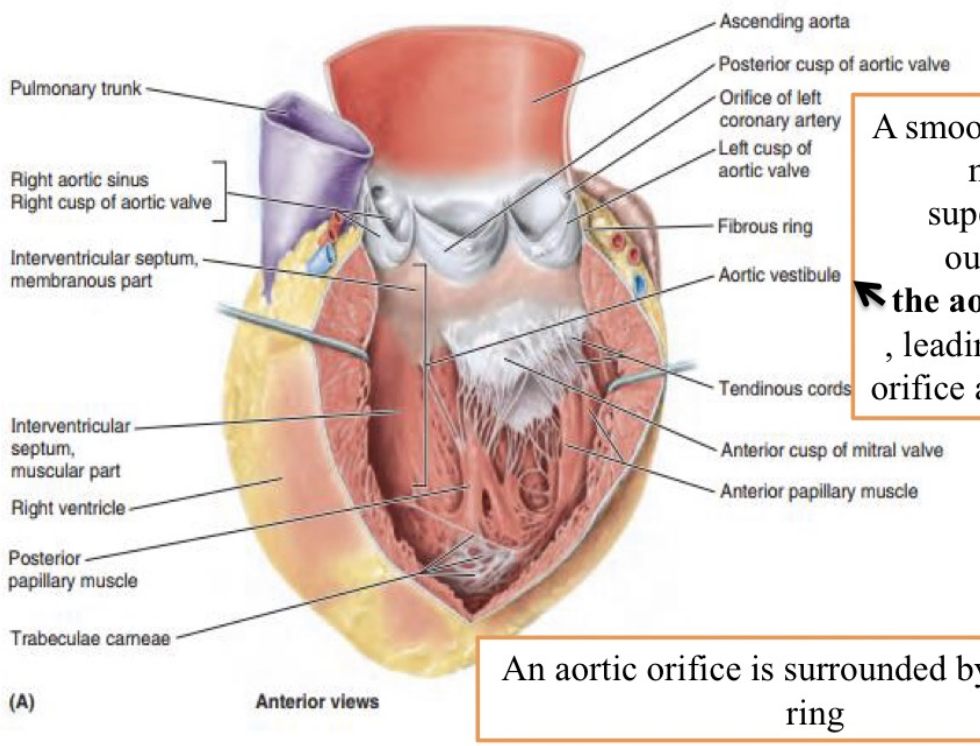

A smooth-walled, non-muscular, supero-anterior outflow part, **the aortic vestibule**, leading to the aortic orifice and aortic valve

An aortic orifice is surrounded by a fibrous ring

- The left atrioventricular orifice admits atrial blood during diastole, flow being towards the cardiac apex.
- After closure of the mitral cusps, and throughout the ejection phase of systole, blood is expelled from the apex through the aortic orifice

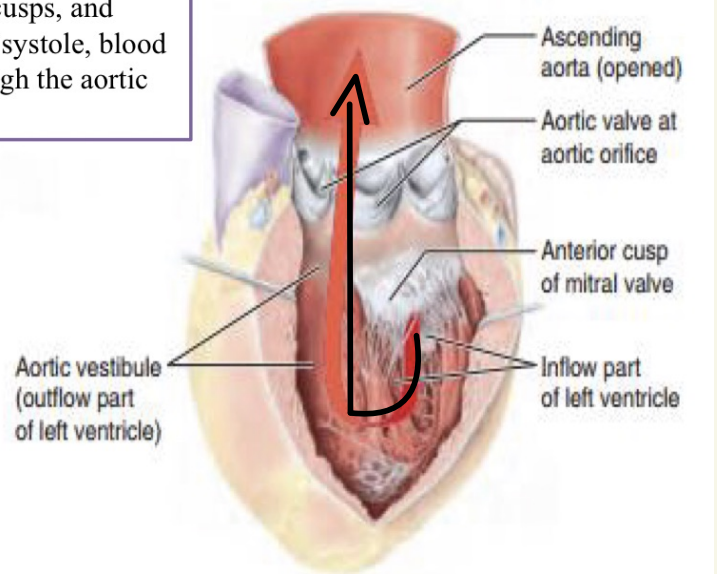

The bloodstream undergoes two right angle turns, which together result in a 180° change in direction. This reversal of flow takes place around **the anterior cusp of the mitral valve**

VIP this cusp is subjected to two blood currents : the inflow current and the outflow current .
And this cusp is more subjected to mitral valve diseases unless it is congenital (if it is congenital the anterior or posterior cusp could be affected)

Watch this video to illustrate the blood flow in the heart

https://youtu.be/qmpd82mpVO4

The entrance and the exit in the left ventricle are close to each other and this is also due to the blood current in this ventricle

The entrance and the exit in the right ventricle are far away from each other , this is due to the blood current

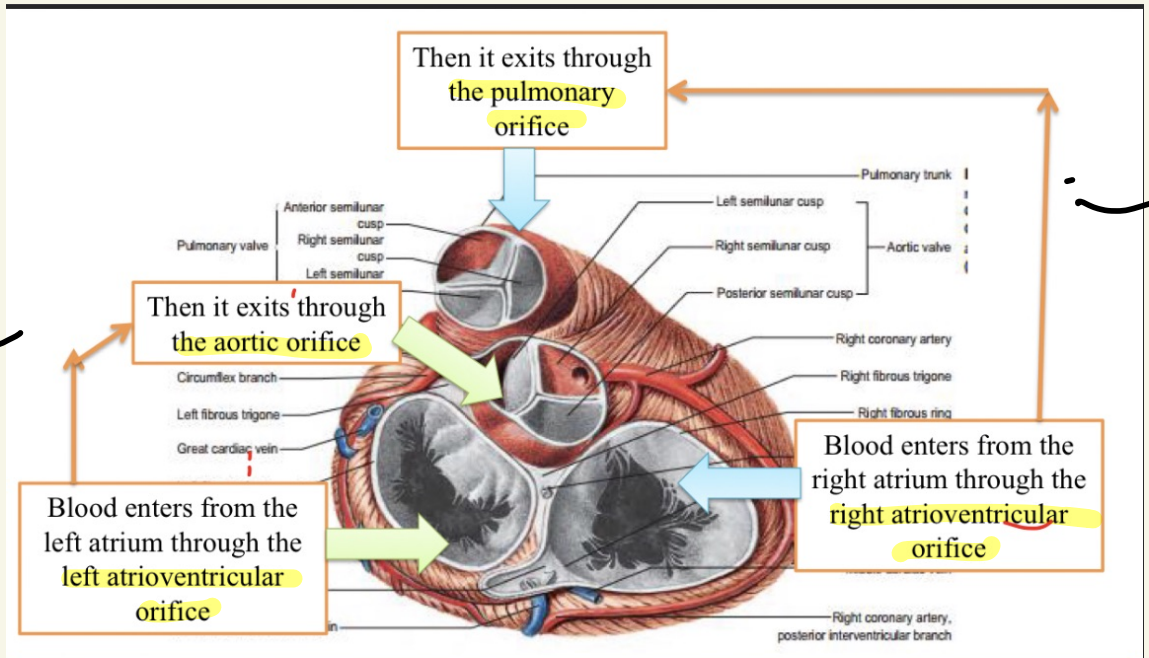

In contrast to the orifices within the right ventricle, those of the left ventricle are in close contact, with fibrous continuity between the cusps of the aortic and mitral valves

the subaortic curtain The inlet and outlet turn sharply round this

FIBROUS CURTAIN

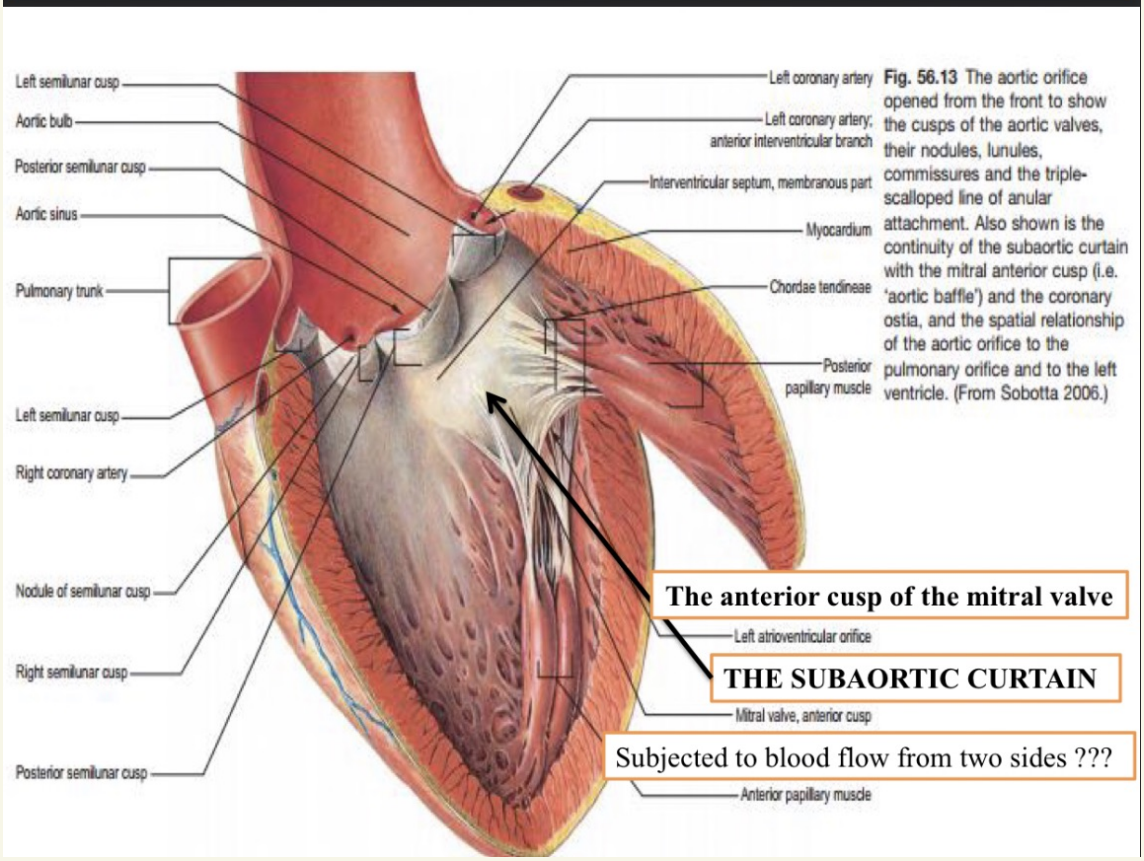

Fig. 56.13 The aortic orifice opened from the front to show the cusps of the aortic valves, their nodules, lunules, commissures and the triple-scalloped line of anular attachment. Also shown is the continuity of the subaortic curtain with the mitral anterior cusp (i.e. 'aortic baffle') and the coronary ostia, and the spatial relationship of the aortic orifice to the pulmonary orifice and to the left ventricle. (From Sobotta 2006.)