hydrophobic amino acid

SICKLE CELL ANEMIA

- Most common familial hemolytic anemia worldwide
- Common in Africa, Middle East, Saudi Arabia, African Americans
- Resistant to malaria falciparum infection
- Autosomal recessive
- Caused by single amino acid substitution (glutamic acid → valine) in β-chain
- In sickle cell disease (homozygous), Hg electrophoresis shows HgS and absent HgA
- In sickle cell carrier (heterozygous), Hg electrophoresis shows both HgA and HgS bands

could occur inside the blood stream or in the spleen

PATHOGENESIS

- In deoxygentated case, HgS tends to polymerize in a longitudinal pattern, distorting cell shape and creating sickle shape
- The change is reversible by re-oxygenation, however, with repeated sicklings, cell membrane is damaged and hemolysis occurs
- The presence of normal HgA (carrier) and increased HgF (newborn) inhibits HgS polymerization
- Increased HgS concentration inside RBC promotes sickling (dehydration, acidosis), while the presence of additional α-thal decreases sickling

because there is less hemoglobin to be sickled

these situations occur usually in infection

PDF-XChange Editor
Click to BUY NOW!
www.tracker-software.com

PATHOGENESIS

- Sickle-shaped RBCs take a longer time to pass through capillaries
- Removed by macrophages in spleen (extravascular hemolysis)
- Also adhere to endothelial cells, may create a thrombus

hypoxia triggers new blood vessels formation, making retina less transparent

CLINICAL SYMPTOMS OF SSA

- Chronic moderate-severe hemolytic anemia, manifesting after the age of 6-months (dependent on fraction of sickled cells). The chronic course is interrupted by repeated sudden attacks of worsening anemia
- Vaso-occlusive crisis (independent on fraction of sickled cells), results in organ infarction. Commonly associated with systemic infection, inflammation, dehydration and acidosis.
- Hand-foot syndrome, acute chest syndrome, stroke, myocardial infarction, retinopathy, autosplenectomy
- Aplastic-crisis: infection by Parvovirus B19, causing worsening anemia, self-limited
- Susceptibility for encapsulated bacteria (pneumococcus, salmonella) because spleen is removed
- Sickle cell carrier: asymptomatic

they have NO spleen, because spleen is infarcted and removed

DIAGNOSIS

like iron deficiency anemia and thalasemia

- Routine blood smear: presence of sickle cells, target cells
- Sickling test: adding hypoxic agent to RBCs promote sickling
- Hemoglobin electrophoresis
- DNA testing

detect both carrier and true patient

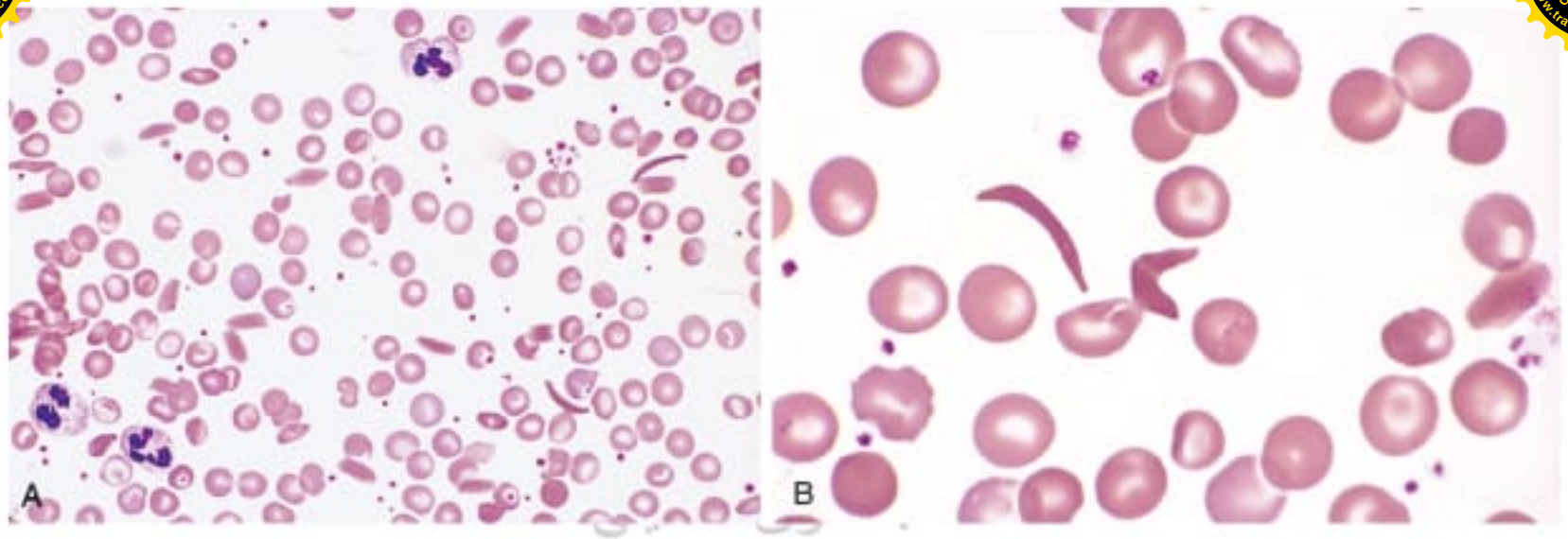

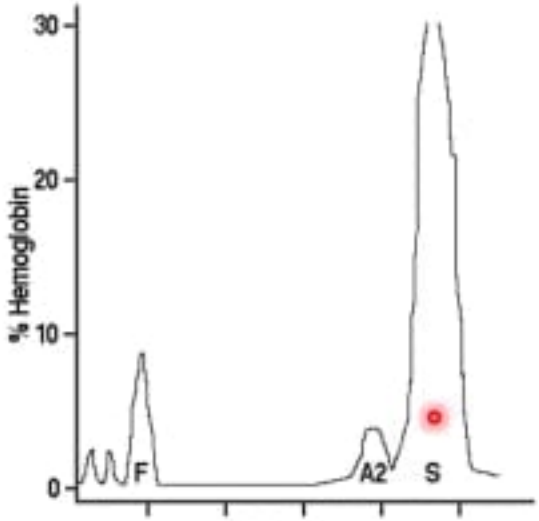

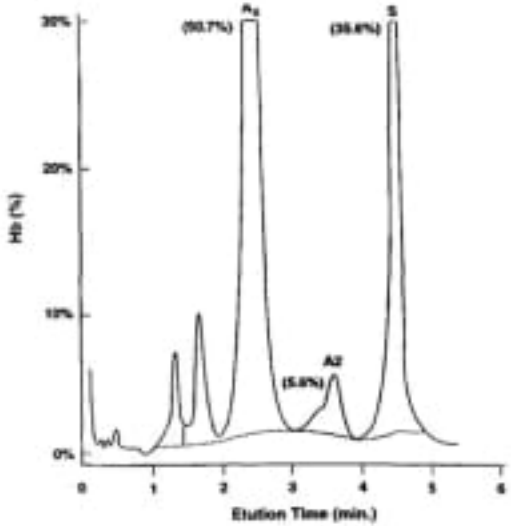

This picture for G6FD deficiency

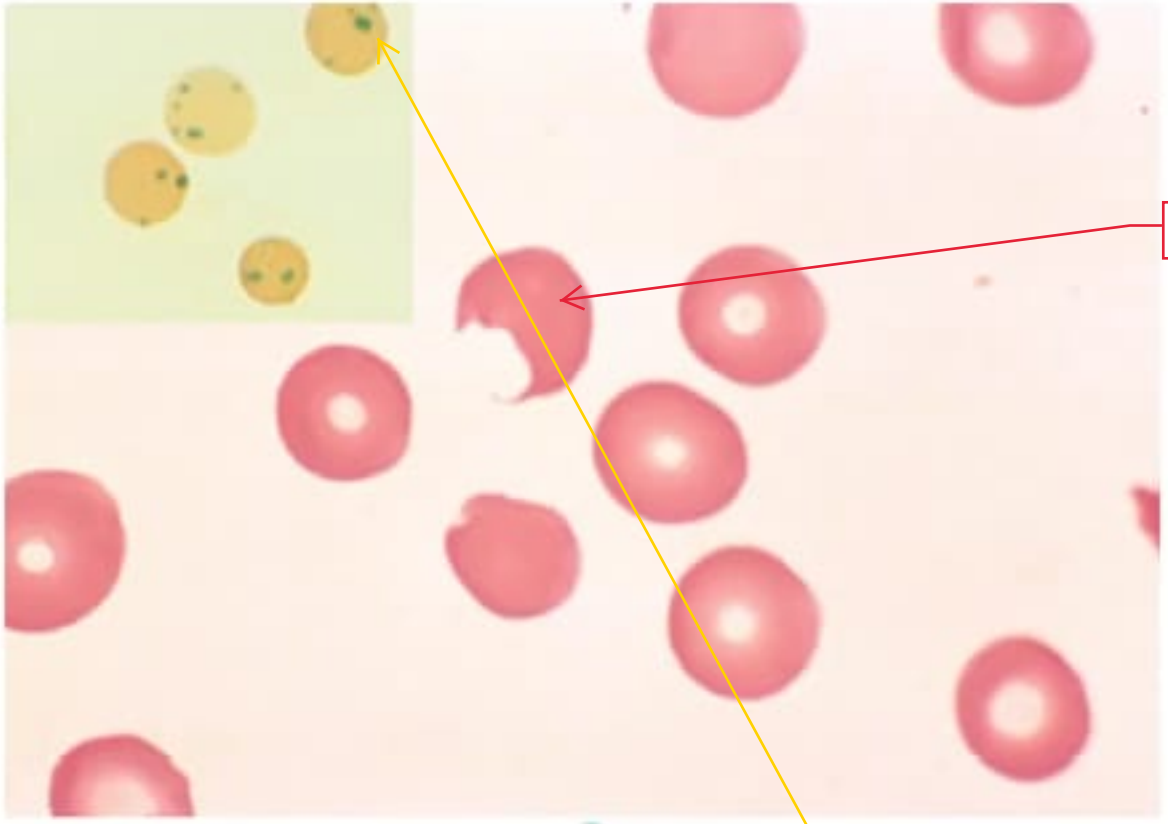

Faculty of Medicine

- Diagnosis: blood film, supravital stain (Heinz bodies), enzyme assay

PDF-XChange Editor
Click to BUY NOW!
www.tracker-software.com

G6PD DEFICIENCY

- Glucose 6-phosphate dehydrogenase deficiency
- X-linked inheritance
- Recurrent, transient episodes of intravascular hemolysis

TRIGGERS OF HEMOLYSIS

can be seen with a special stain (supravital stain)

- Infection most important
- Certain drugs: sulfonamides, nitrofurantoin, large dose of aspirin, vitamin K, primaquine(anti-malaria drug)
- Fava beans (contain vicine and convicine)
- In all, large amount of oxidants are generated, G6PD canno neutralize them, causing hemoglobin denaturation and precipitate (Heinz bodies), damaging cell membrane and massive hemolysis of RBCs, 2-3 days after trigger
- Other cells lose demorfmability and partially phagocytosed inside spleen (bite cells)

the spleen cut out the heinz body part only so the cell looks like it has been bitten

other triggers like naphthaline and certain food coloring like (anline dye)

CLINICAL SYMPTOMS

- Symptoms of intravascular hemolysis (general fatigue and dark urine)
- G6PD-A type: decreased amount of G6PD, bone marrow compensate by producing new RBCs
- G6PD-Mediterranian: qualitative defect of enzyme (low function), more severe symptoms
- Females: can have symptoms if random inactivation affects the normal X-chromosome

PDF-XChange Editor
Click to BUY NOW!
www.tracker-software.com

IMMUNE HEMOLYTIC ANEMIA (IHA)

- The presence of auto-antibody against RBC membrane protein
- These antibodies are detected by Coombs test
- Direct Coombs test: RBCs of patient are incubated with antibodies that target normal human antibodies (RBCs will agglutinate) agglutination can be seen as a blood clot with naked eyes
- Indirect Coombs test: patients serum is added to "test RBCs" that have certain surface proteins (identify the type of antigen)

WARM TYPE IHA

- High affinity auto-antibody (mostly IgG type)
- Binding occurs in core circulation (37°C)
- Removed by macrophages in spleen
- spherocytes develop, then destroyed by spleen (extravascular hemolysis)
- 60% are idiopathic, 25% associated with systemic lupus erythematosus, 15% by drugs (α-methyldopa, penicillin) coat RBCs
- Severity of anemia is variable, most patients have mild chronic anemia and splenomegaly and reticulocytosis

COLD TYPE IHA

- Low-affinity autoantibody (IgM)
- Binding occur in peripheral areas of body (<30°C)
- After IgM binding, few C3b molecules bind RBCs
- When RBCs return to core circulation, IgM dissociates, but C3b stays, identified by splenic macrophages and removed
- IgM binds 5 RBCs, thus creating in vivo agglutination, might block small capillaries in fingers and toes causing Raynaud phenomenon
- Transient forms of cold-IHA occur in recovery of infections by mycoplasma pneumonia and infectious mononucleosis (mild, self-limited)
- Chronic persistent form occur in B-cell lymphoma or idiopathic

means inside the body

can bind RBCs at the same time

pain and skin blue discoloration specially in digits. also cold fingers

means acute

caused by epstin barr virus

b cells are the cells that produce antibodies

NO pale in the center

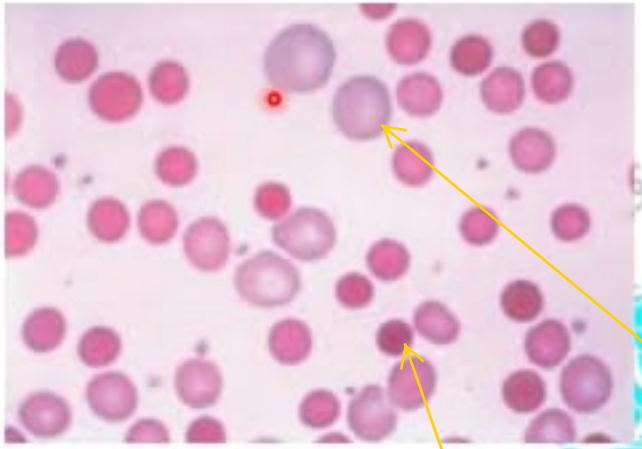

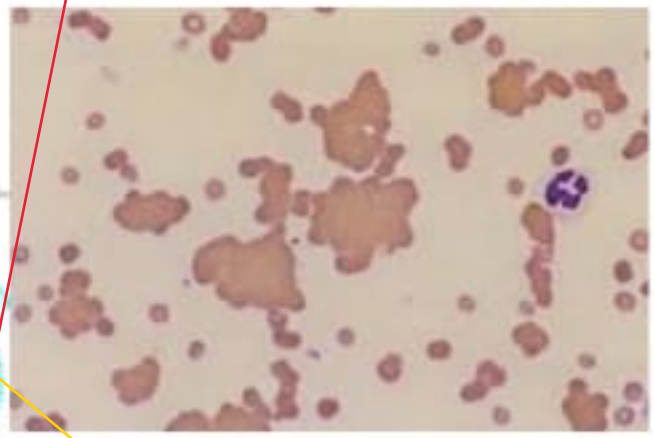

- Left: warm type IHA: spherocytes and polychromasia
- Right: cold type IHA: RBCs agglutination

there are bluish reticulocytes

HEREDITARY SPHEROCYTOSIS

- Autosomal dominant, sometimes autosomal recessive
- Mutation in RBC cell membrane skeleton
- Most commonly affects ankyrin, band 3 or spectrin
- Cell membrane is unstable, keeps losing parts of it as the RBC age
- Little cytoplasm is lost
- With decreasing surface area, the RBC loses its biconcave morphology and becomes a smaller sphere

PATHOGENESIS

Can transfer O2 normally, but spleen degrade it

- Spherocytes are nondeformable
- Entrapped in small vessels in spleen, engulfed by histiocytes and destroyed (extravascular hemolysis)
- If spleen is removed, spherocytes persist in peripheral blood, thus, anemia is corrected
- Degree of anemia is variable (depends on type of mutation)
- Some patients are asymptomatic, others have severe hemolysis

DIAGNOSIS

- Demonstration of spherocytes in peripheral blood
- Spherocytes are small in size (low MCV)
- Little cytoplasm is lost, MCH is normal because Hb is the same
- Thus, MCHC is increased
- Spherocytes show increased fragility when put in hypotonic solution (osmotic fragility test) (bursed easily when are put in a hypotonic solution) NOT a specific test.

it is MHC/MCV
It's a characteristic of spherocytes and sickle cells

Remember: In sickle cell also the number of Hb is normal

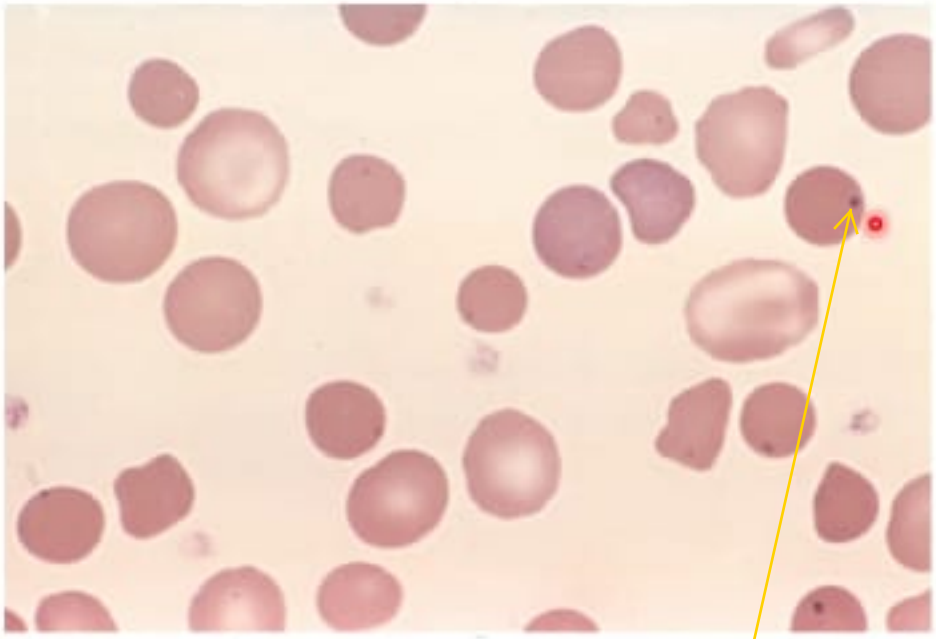

- This blood smear is taken from a patient with hereditary spherocytosis. The presence of small black dots (Howel-Jolley bodies) indicate splenectomy

means sudden

PAROXYSMAL NOCTURNAL HEMOGLOBINURIA

- Rare, acquired disease
- Mutation in PIGA gene, results in deficiency in phosphatidylinositol glycan (PIG), a structural protein on cell membrane that anchors many other proteins
- Mutation occurs in bone marrow stem cell (leukocytes, RBCs and platelets are all affected)

PATHOGENESIS (NO PIG = NO CD59 and CD55)

- Complement system: circulating proteins that are part of immune system. They are activated (C5b-C9) and attack cell membrane to create pores, causing lysis
- Blood cells protect themselves by membrane proteins CD55 and CD59, that are normally attached to PIG
- RBCs, and to a lesser degree WBCs and platelets, are spontaneously lysed inside blood
- During sleep, ↑CO2, ↓ blood PH, more active complement system, more hemolysis
- Thrombosis is common

why inspect of platelets are low? because platelets lyse and empty their contents inside the blood.

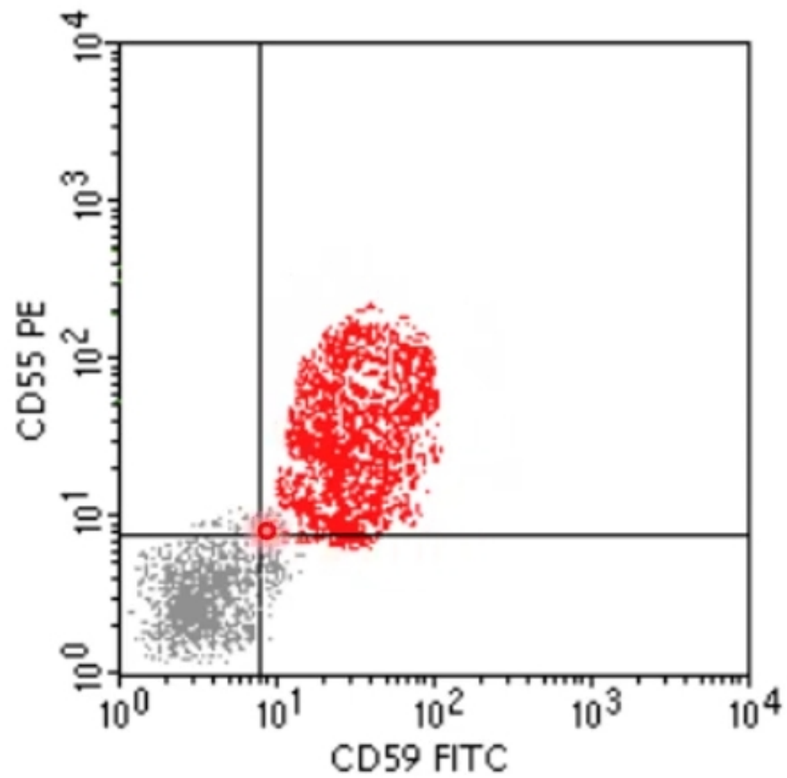

- Flow cytometry study: the red population shows expression of CD55 and CD59, while the gray one is negative for both (PNH clone)

TRAUMATIC HEMOLYSIS

- Direct physical force, or turbulence causing lysis of RBCs
- Prosthetic heart valves
- Repetitive physical pounding (marathon, boxing, marching)
- Disseminated thrombi (microangiopathic hemolytic anemia)
- Hallmark of traumatic hemolysis: schistocytes

most important one

POLYCYTHEMIA

neoplasm in the bone marrow

- Increase in total RBC mass
- Erythrocytosis: increased RBCs number
- Relative polycythemia: secondary to decreased plasma volume (water deprivation, severe diarrhea, diuretics)
- Absolute polycythemia: true increase in RBC mass, secondary to increased BM production (primary or secondary)
- Primary: polycythemia vera (low erythropoietin, splenomegaly)
- Secondary: adaptive (high altitude, cyanotic heart disease), paraneoplastc (renal cancer), surreptitious (endurance athletes). Erythropoietin in high, no splenomegaly

means hidden

other cause is alcoholism because they have hypoxia and acidosis

more common

PDF-XChange Editor
Click to BUY NOW!
www.tracker-software.com

The blood film is very crowded with RBCs