Some basic concepts in general histology

Edited by ➡️🧕🏼 Shaimaa zaben

Chromatin

Formed of **DNA**.

- **2 Forms:**
  - **Euchromatin**: extended active chromatin (pale). electron losent
  - **Heterochromatin:** condensed inactive chromatin (dark) electron dense

It's forms condensation at the peripheral part of the nucleus

Nucleolus

- It is a spherical dark mass not surrounded by a membrane.
- Usually one. Or more
- **Function:** formation and assembly of ribosomal RNA (rRNA), which is responsible for protein synthesis in the cytoplasm

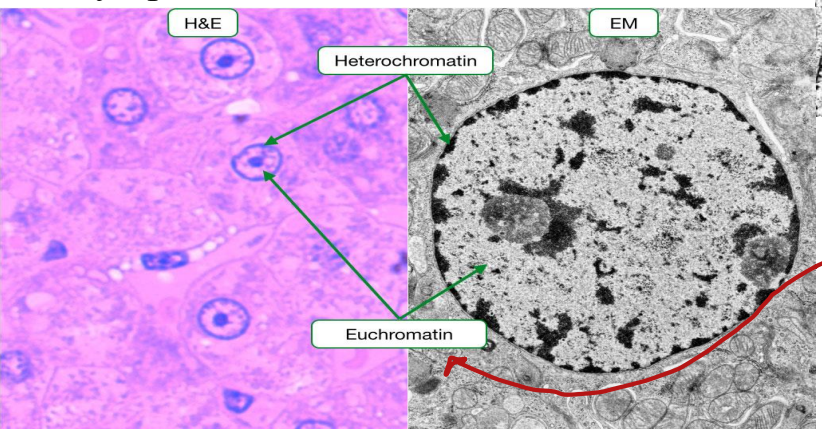

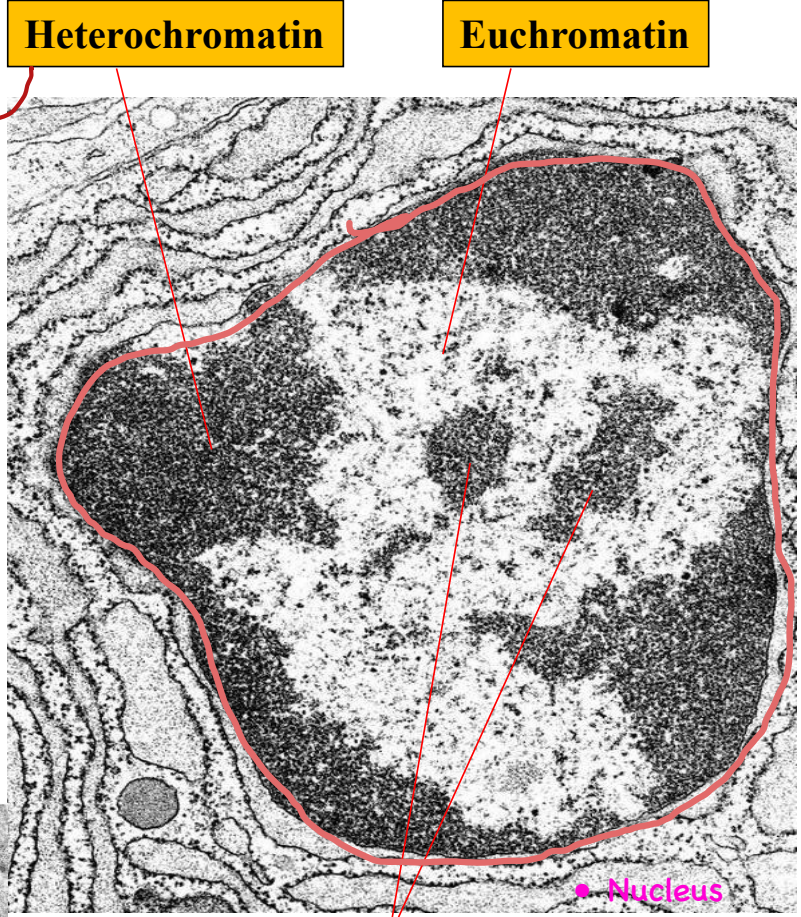

Nucleoli It's electron dense

- dispersed form of DNA because it allows transcription into mRNA
- aprominent nucleoli this indicates the protein synthetic activity of this cell

Dr. Heba Kalbouneh

if the nucleus has more darkly stained heterochromatin it appears dark blue in color but when the nucleus has more euchromatin dispersed form of DNA it appears light blue in color ....

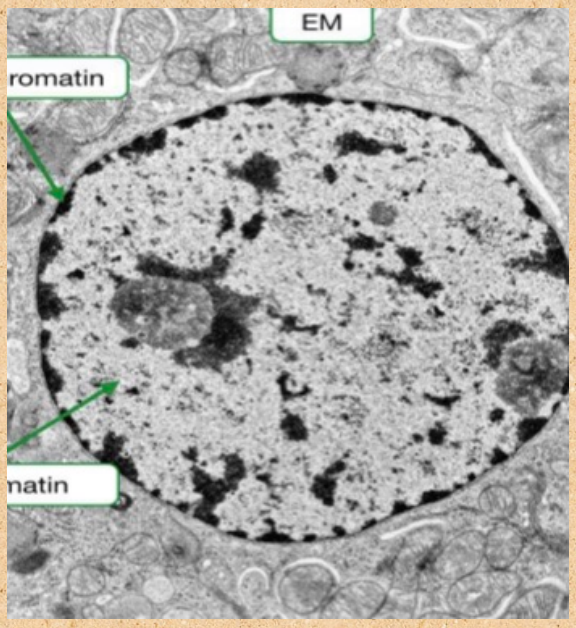

here this is a nucleus and it's Lightly stained and this is indication that this nucleus has more euchromatin as also inside the nucleus we identify here a basophilic dot that Indicates nucleolus and this indicates that this cell is active in protein synthesis

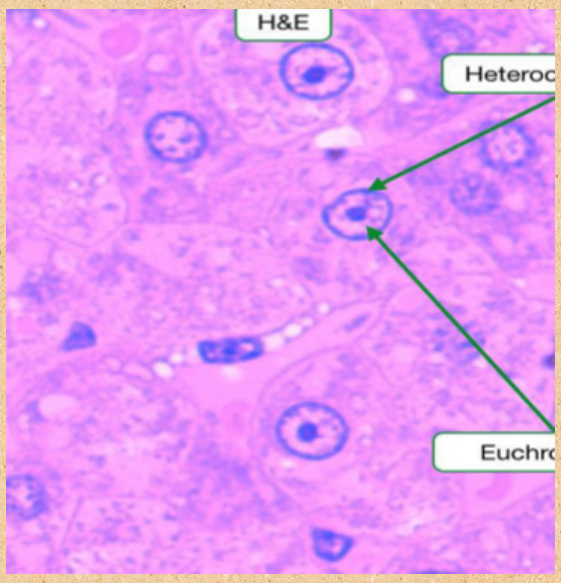

Under light microscope using H and E ...The cytoplasm is pink in color its stained with eosin the nucleus is blue in color And it's stained with hematoxylin

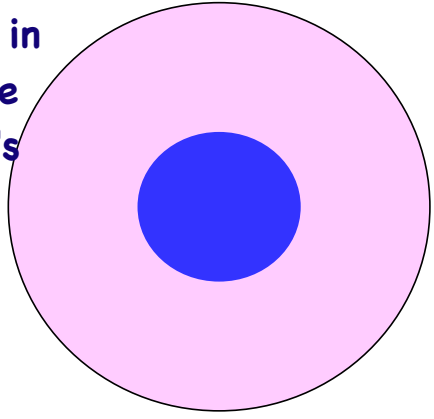

H & E

it's Light blue in color ➡️ basophilic and it has two prominent nucleoli...we call it open nucleus or euchromatic

Active nucleus

this nucleus is small in size and it's darkly stained ➡️ we call it hetrochromatic nucleus

Inactive nucleus

Nucleolus is a spherical dark basophilic mass



Note:

The nucleus stains blue (basophilic) using H&E

Lightly basophilic: active
With prominent nucleolus

Deeply basophilic and small: inactive

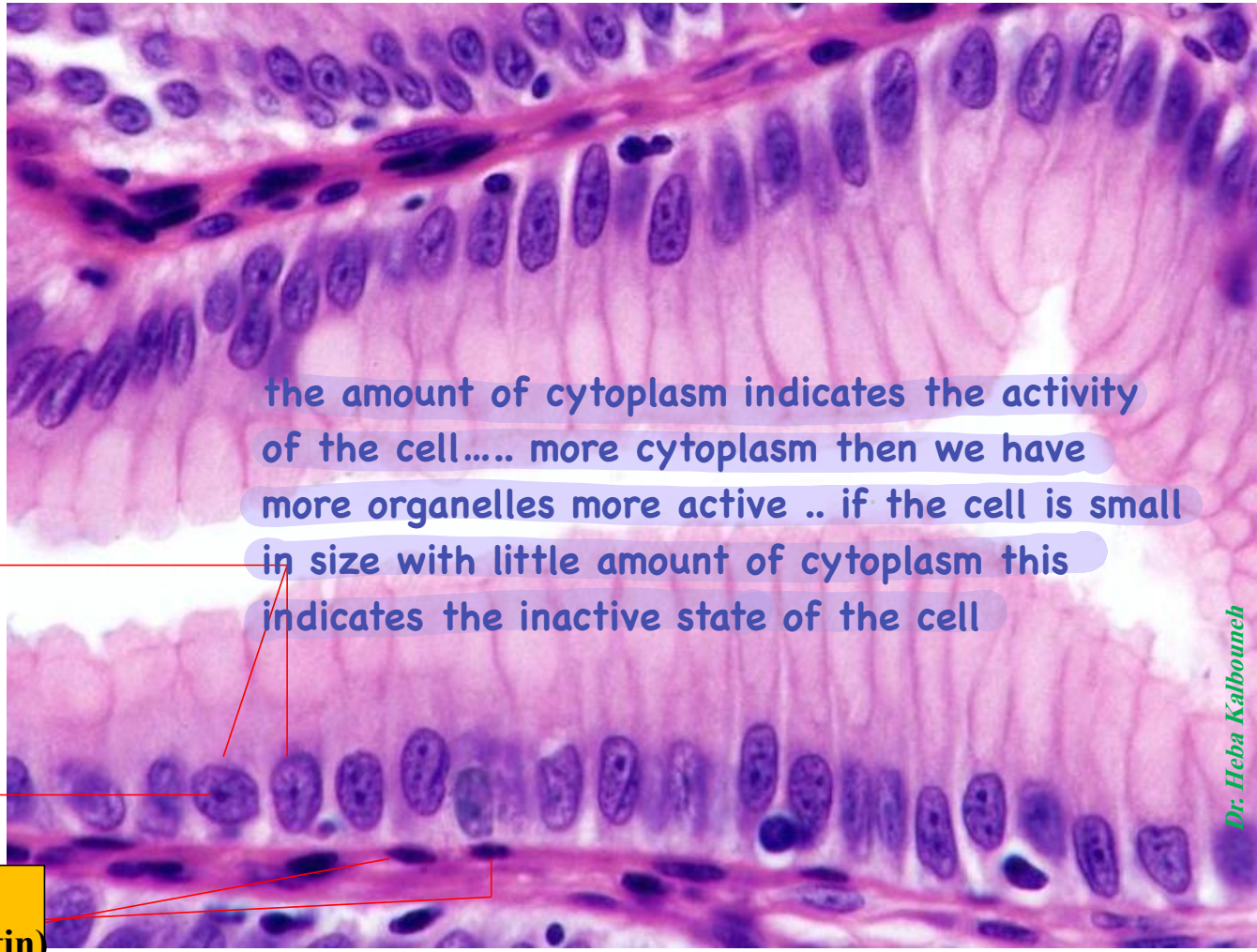

Active nucleus (Euchromatin)

Nucleolus

Inactive nuclei (Heterochromatin)

Note:

The cytoplasm stains pink/red (acidophilic) using H&E

The organelle (when prominent) that produces basophilia in the cytoplasm is the ribosome

negatively charged so it's stained with the basic die H

Usually ribosomes form Polyribosomes or polysomes ..why because we have a group of ribosomes connected by mRNA chain…

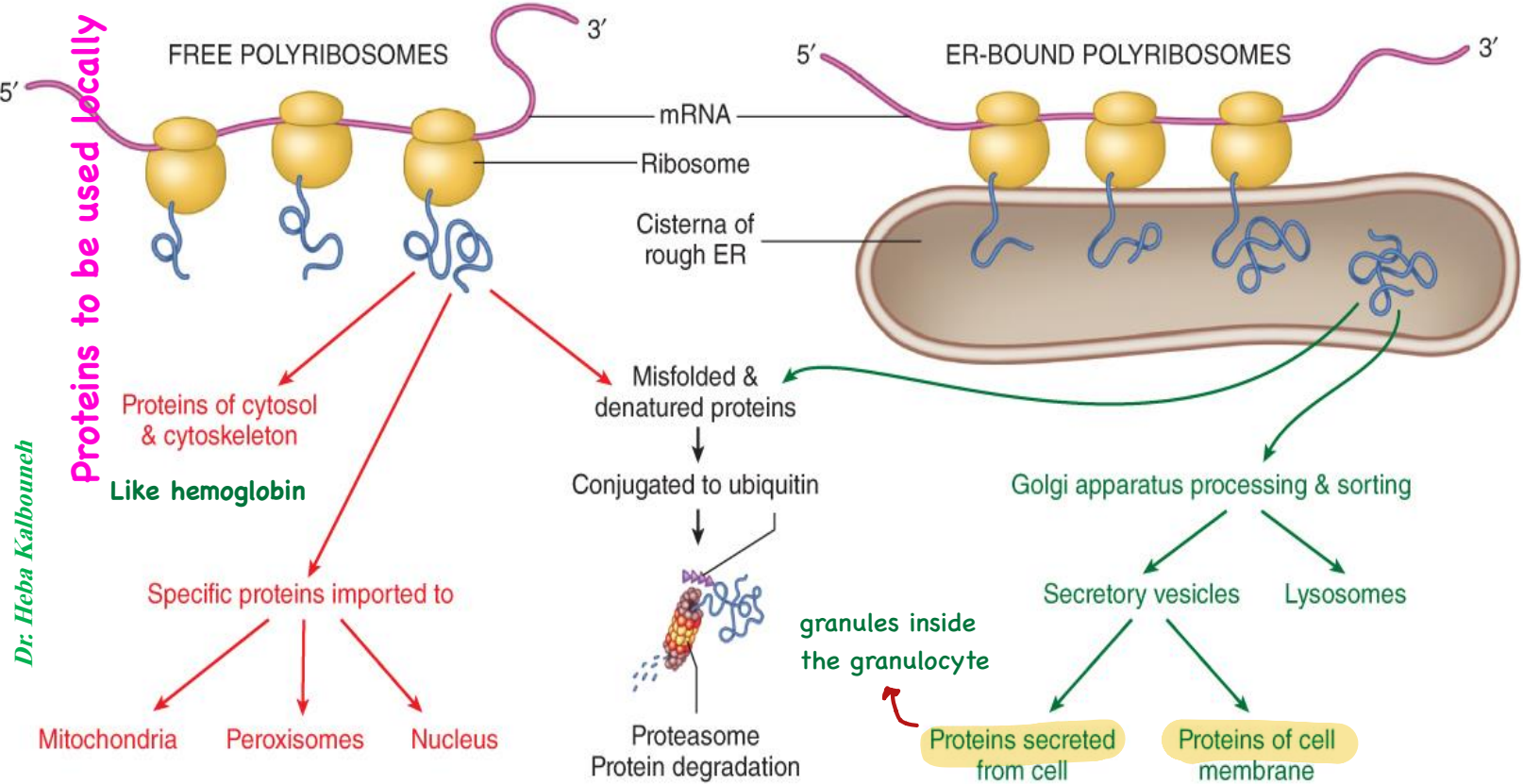

Dr. Heba Kalbouneh

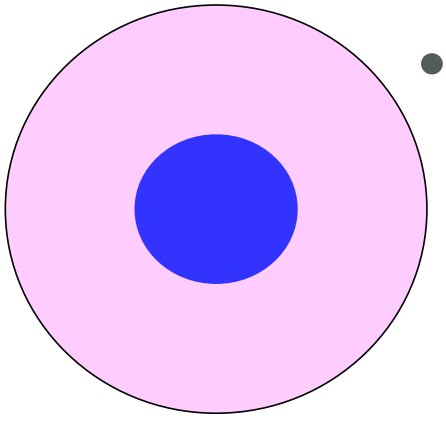

H & E

- The only organ which produces basophilia within the cytoplasm is ribosomes

Free Ribosomes

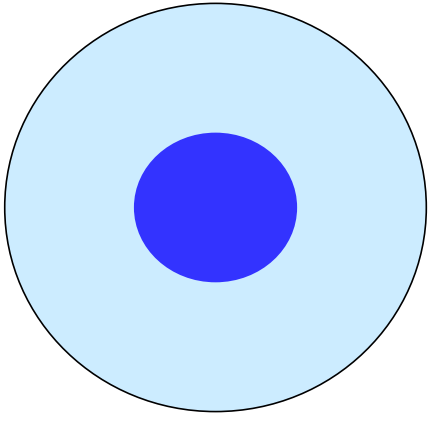

Attached Ribosomes (RER)

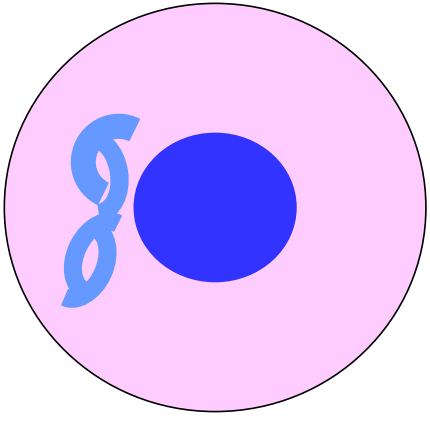

Connective tissue proper is classified :

dense and loose type of connective tissue

- loose type ➡️ has cells, fibers and ground substance in almost same proportions
- dense collagenous type of connective tissue ➡️ is mainly composed of collagen type one fibers (fibers are more than the cells and ground substance so since this tissue is dense with fibers we call it dense collagenous connective tissue)

dense connective tissue is again classified into regular and irregular according to the orientation of collagen type one fibers if we have irregular haphazard orientation of these fibers it's irregular type and if we have parallel fibers with regular orientation we call it dense regular type

Dense irregular connective tissue

- ✓ Bundles of collagen fibers are randomly interwoven with no definite orientation
- ✓ Provides resistance to stress from all directions
- ✓ Dermis of skin (deeper layer), **organ capsules**, submucosa

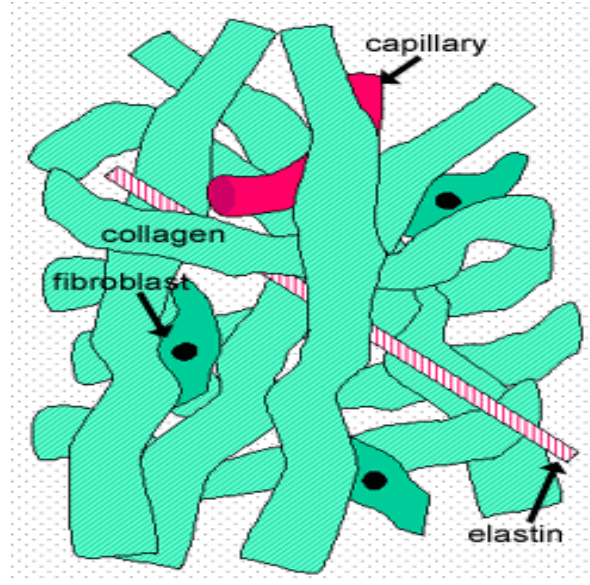

Dense regular connective tissue

✓Parallel Bundles of collagen fibers with few fibrocytes aligned with collagen and separated by very little ground substance

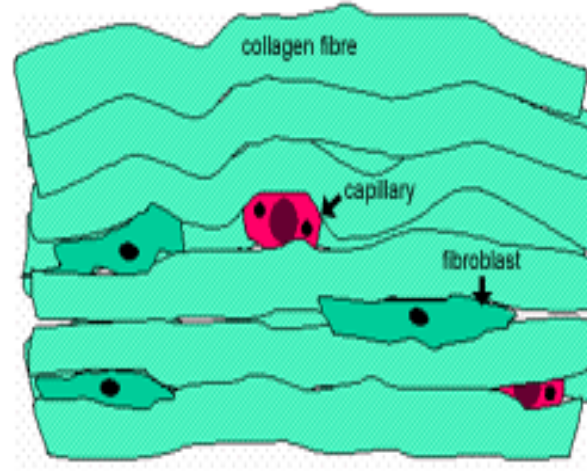

Dr. Heba Kalbouneh

Stroma means bed

Parenchyma / Stroma:

The parenchyma of an organ consists of that tissue which conducts the specific function of the organ and which usually comprises the bulk of the organ. Stroma is everything else -- connective tissue, blood vessels, nerves, ducts. It is made up of all the parts without specific functions of the organ

For Example:

The *parenchyma* of the heart is muscle tissue (cardiac muscle cells). The nerves, intrinsic blood vessels, and connective tissue of the heart comprise the *stroma*.

in each organ we have parenchyma producing the main function of the organ and we have stroma forming the supporting tissue

Dr. Heba Kalbouneh

Reticular connective tissue

Remember that reticular fibers are type 3 collagen

- Consists of reticular cells (modified fibroblasts) and the network of reticular fibers formed by them
- Forms the structural framework (stroma) in which the cells of the organ are suspended
- In the liver, bone marrow, lymph nodes and the spleen **(Reticulo-Endothelial organs)** Why?

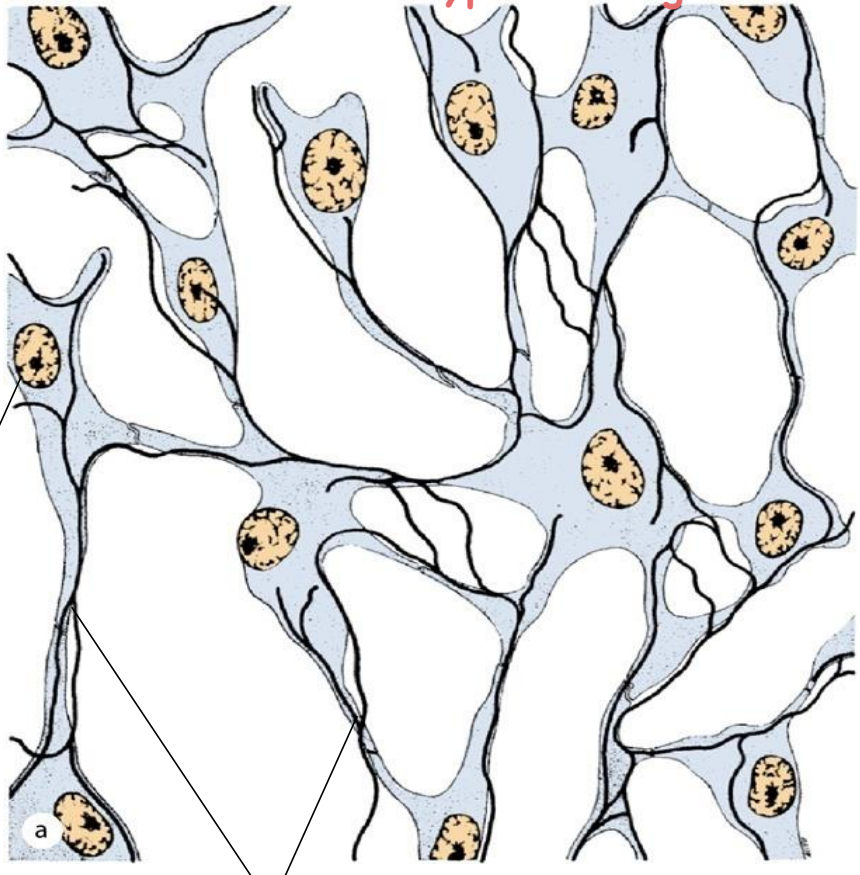

Reticular cell

Reticular fibers are thin and branching forming a network

with wide spaces to permit movement of large molecules or cells

these organs contain wide spaces filled with blood or even lemph and these wide spaces are lined with endothelium and supported by a reticular tissue

Types of capillaries

- Capillary: is a single layer of endothelial cells supported by basement membrane which is surrounded by a thin layer of loose type of connective tissue

Continuous capillaries

- Are most common
- Endothelium forms solid lining
- Adjacent cells are held together with tight junctions
- Found in most organs

Supported by continuous layer of basement membrane

Fenestrated capillaries

- Endothelium contains pores (fenestrations) Fenestration means window
- Found wherever active capillary absorption or filtrate formation occurs
- Found in endocrine glands, small intestine, and kidney

Sinusoidal capillaries

- Exhibit wide diameters with wide gaps between endothelial cells
- Basement membrane incomplete or absent
- Allow large molecules (proteins and blood cells) to pass between the blood and surrounding tissues
- Found in liver, spleen, and bone marrow

supported by a discontinuous layer of basement membrane

no smooth muscle inside the capillary

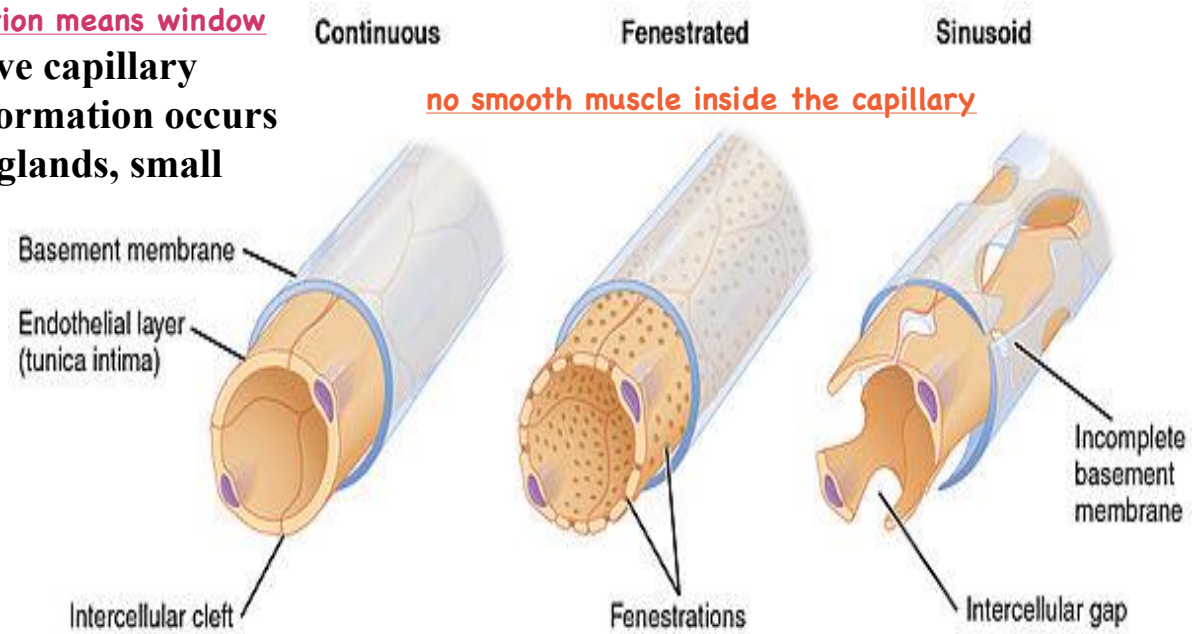

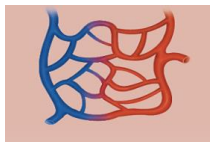

Dr. Heba Kalbouneh

More info about Fenestrated capillary ➡️

Where we found it and why ?

1. small intestine ➡️ to permit the movement of the absorbed nutrients from the lumen of small intestine into the bloodstream
2. the kidney ➡️ we have the same concept we have absorption of material from blood into kidney tubules and also we have reabsorption of materials from kidney tubules back into the bloodstream
3. endocrine glands ➡️ to permit the movement by of hormones from the endocrine gland into the bloodstream

More info about sinusoidal capillary

Where we found it and why ?

inside the bone marrow ➡️ because the bone marrow is the side for production of blood cells and once these blood cells are ready they have to pass through these clefts to enter the bloodstream

inside liver ➡️ to permit the movement of these large plasma proteins from hepatocytes into bloodstream

Hematopoiesis

Dr. Heba Kalbouneh
Associate Professor of Anatomy and Histology

Blood Cell Formation (Hematopoiesis)

Mature blood cells have a relatively short life span and must be continuously replaced with new cells from precursors developing during hemopoiesis/ hematopoiesis (Gr. haima, blood + poiesis, a making).

- when hematopoiesis takes place inside the red bone marrow we call it medullary hematopoiesis
- when hematopoiesis takes place inside the liver or spleen or lymph nodes or even the yolk SAC we call it extra medullary hematopoiesis

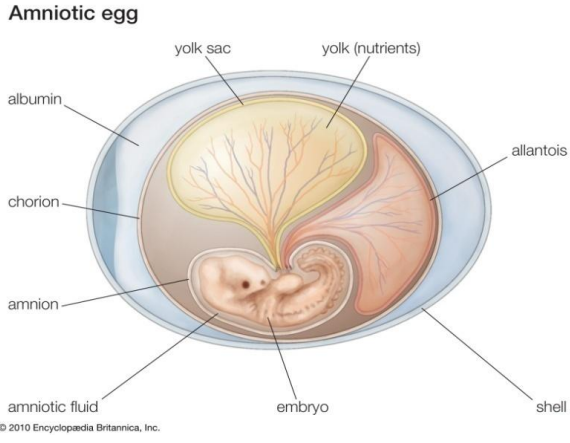

Early embryo
Yolk sac mesoderm

Second trimester
Developing liver and spleen

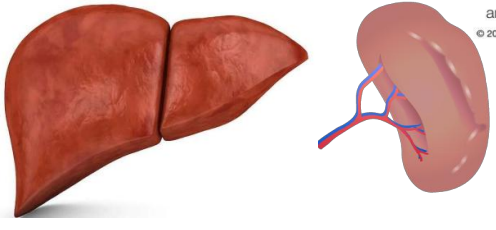

Third trimester
Bone marrow

- Stem cells are populated from you sac to the liver at the third month, so it becomes larger

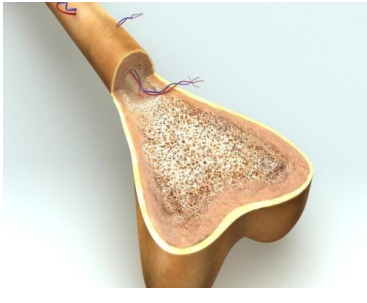

After birth, all blood cells originate in bone marrow

Bone marrow

The red bone marrow is a highly cellular structure that is located in the medullary cavities of the bone

It consists of:

Hemopoietic stem cells (the origin of different blood cells) surrounded by numerous macrophages and sinusoidal capillaries and supported by a reticular tissue.

As the individual ages and becomes an adult, the red marrow is found primarily in the axial skeleton (flat bones of the skull, sternum and ribs, vertebrae, and pelvic Bones). The remaining bones, primarily the long bones in the limbs of the body, gradually accumulate fat, and their marrow becomes yellow. Consequently, they lose the hemopoietic functions.

- inside The red bone marrow we can see small number of adipocytes
- we can find small number of hematopoietic stem cells inside the yellow bone marrow

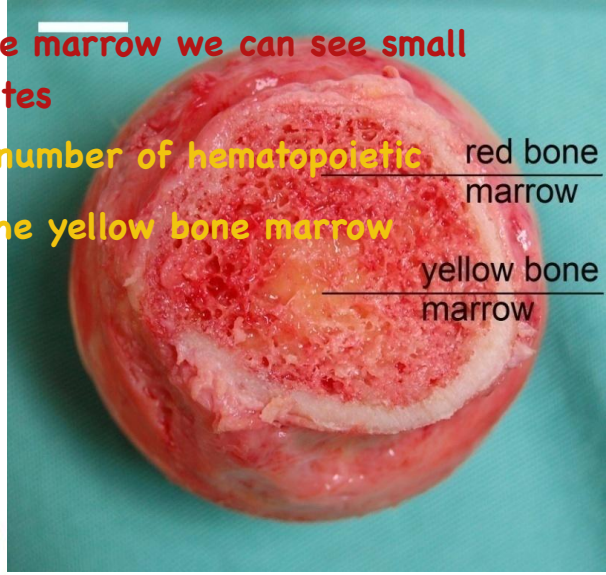

Under certain conditions (severe bleeding or hypoxia), yellow marrow reverts to red

Dr. Heba Kalbouneh

After birth all our bones contain the active form of bone marrow (red bone marrow) but after age the peripheral bones start to accumulate fat so the red bone marrow is converted to yellow bone marrow.... in adult red bone marrow is restricted to the axial bones

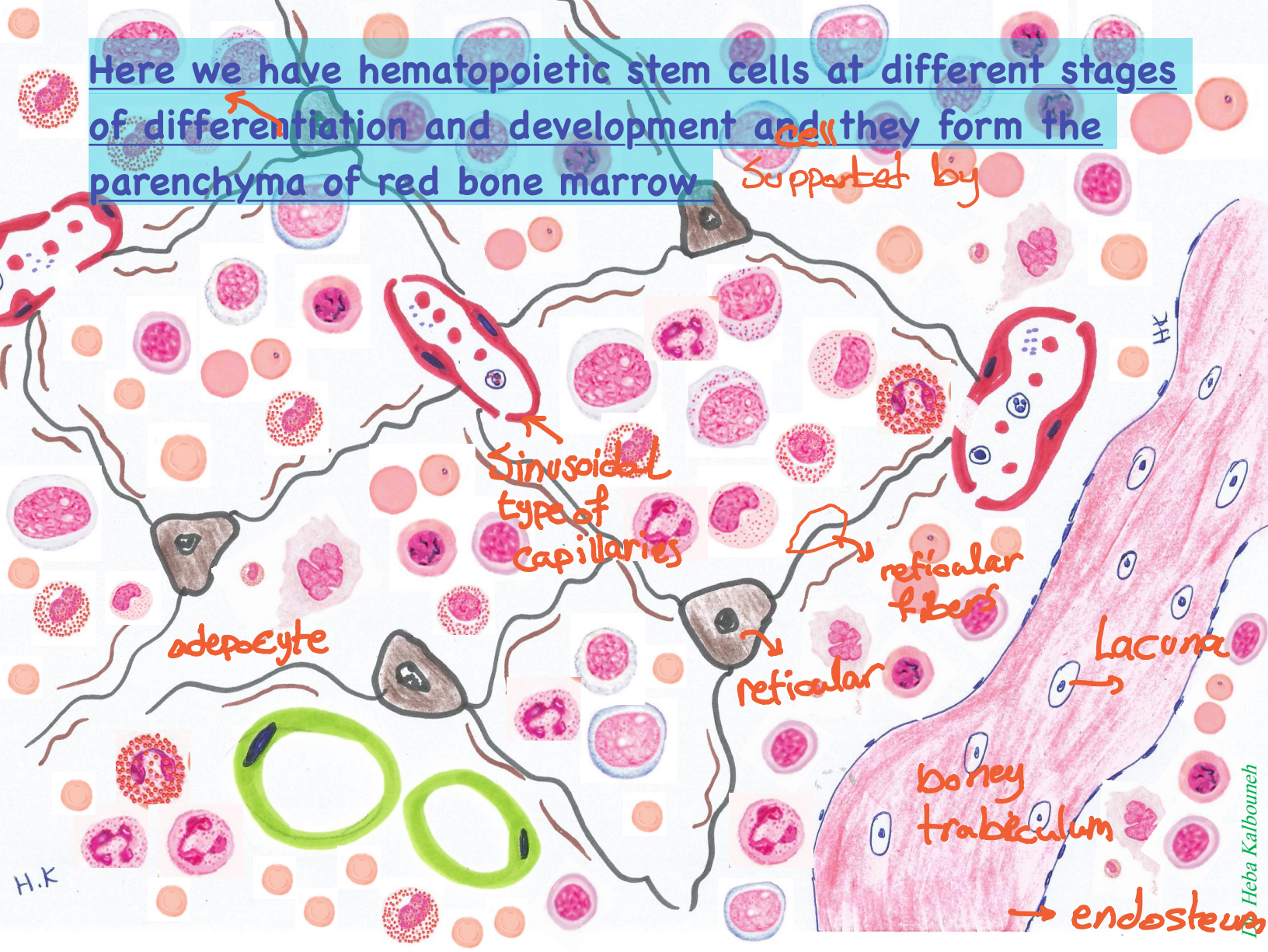
Here we have hematopoietic stem cells at different stages of differentiation and development and they form the parenchyma of red bone marrow
cell
Supported by
Sinusoidal type of capillaries
reticular fibers
adipocyte
reticular
Lacuna
bony trabeculum
endosteum
H.K
H.K
Dr. Heba Kalbouneh

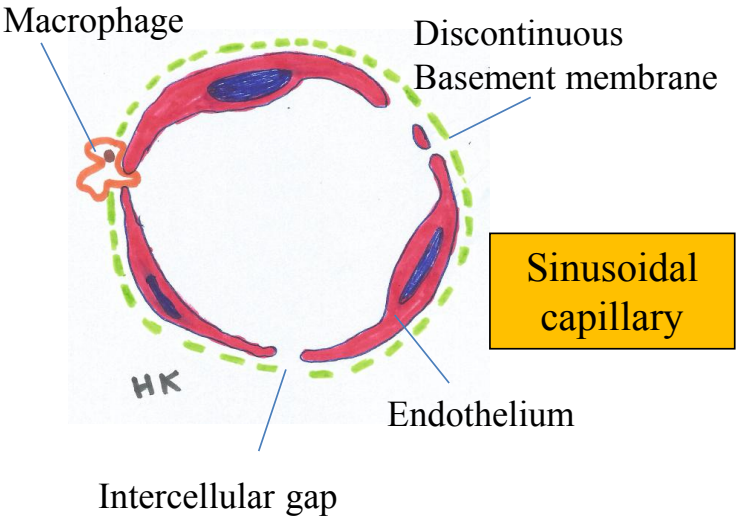

Continuous capillary

Reticular tissue forming the stroma of the bone marrow

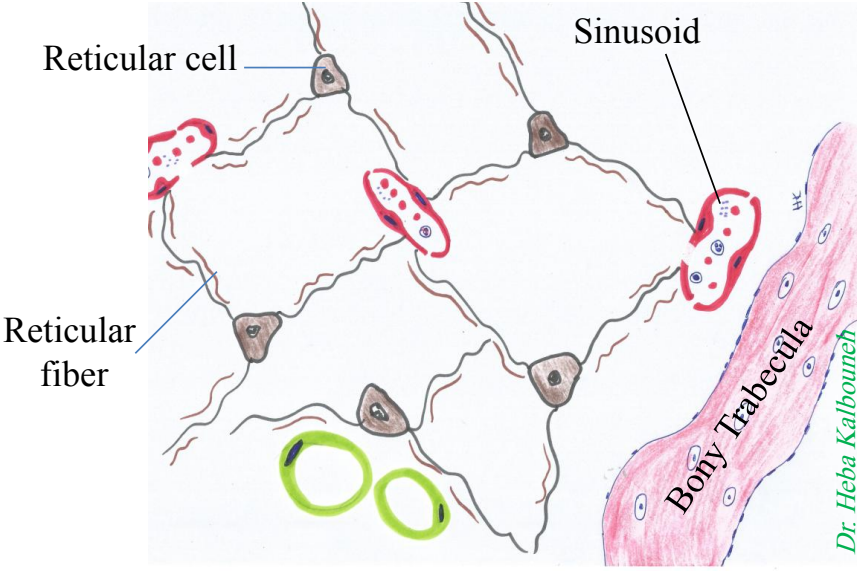

associated with the sinusoid we have macrophages (these resident cells are located here in the tissue surrounding the sinusoid we call it perisinusoidal connective tissue... and it's simply a loose type of connective tissue surrounding all capillary)
this macrophage extends its process into the lumen of the sinusoid .., why? 🤔
to identify any abnormal or old red blood cells

Between the hematopoitetic cells run the **sinusoids,** which have discontinuous endothelium, through which newly differentiated blood cells and platelets enter the circulation

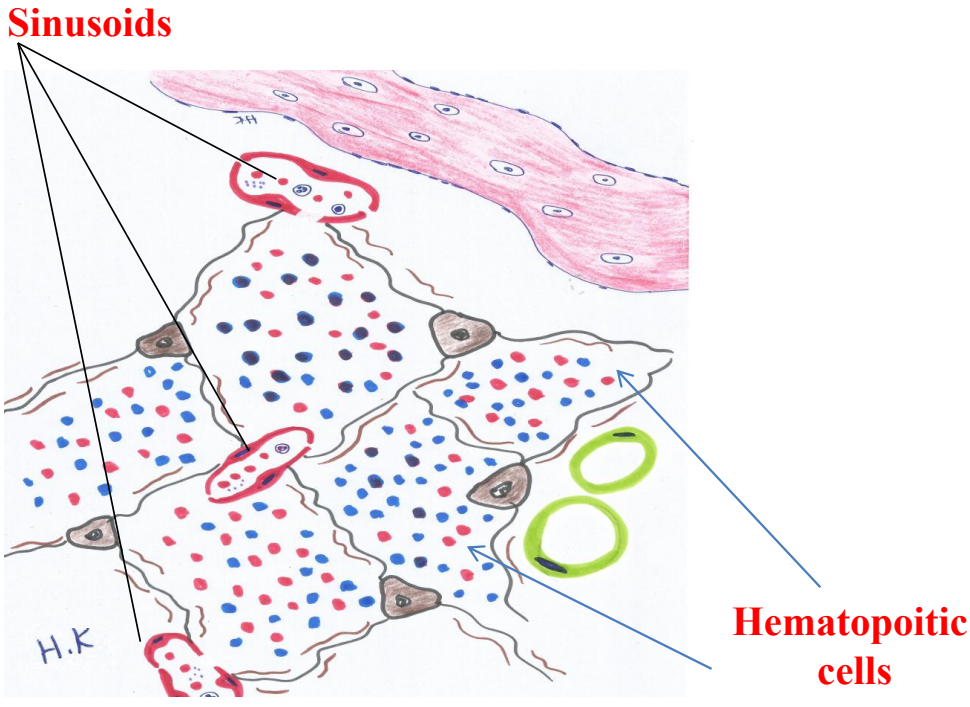

Red marrow is also a site where older, defective erythrocytes undergo phagocytosis by macrophages, which then reprocess heme-bound iron for delivery to the differentiating erythrocytes.

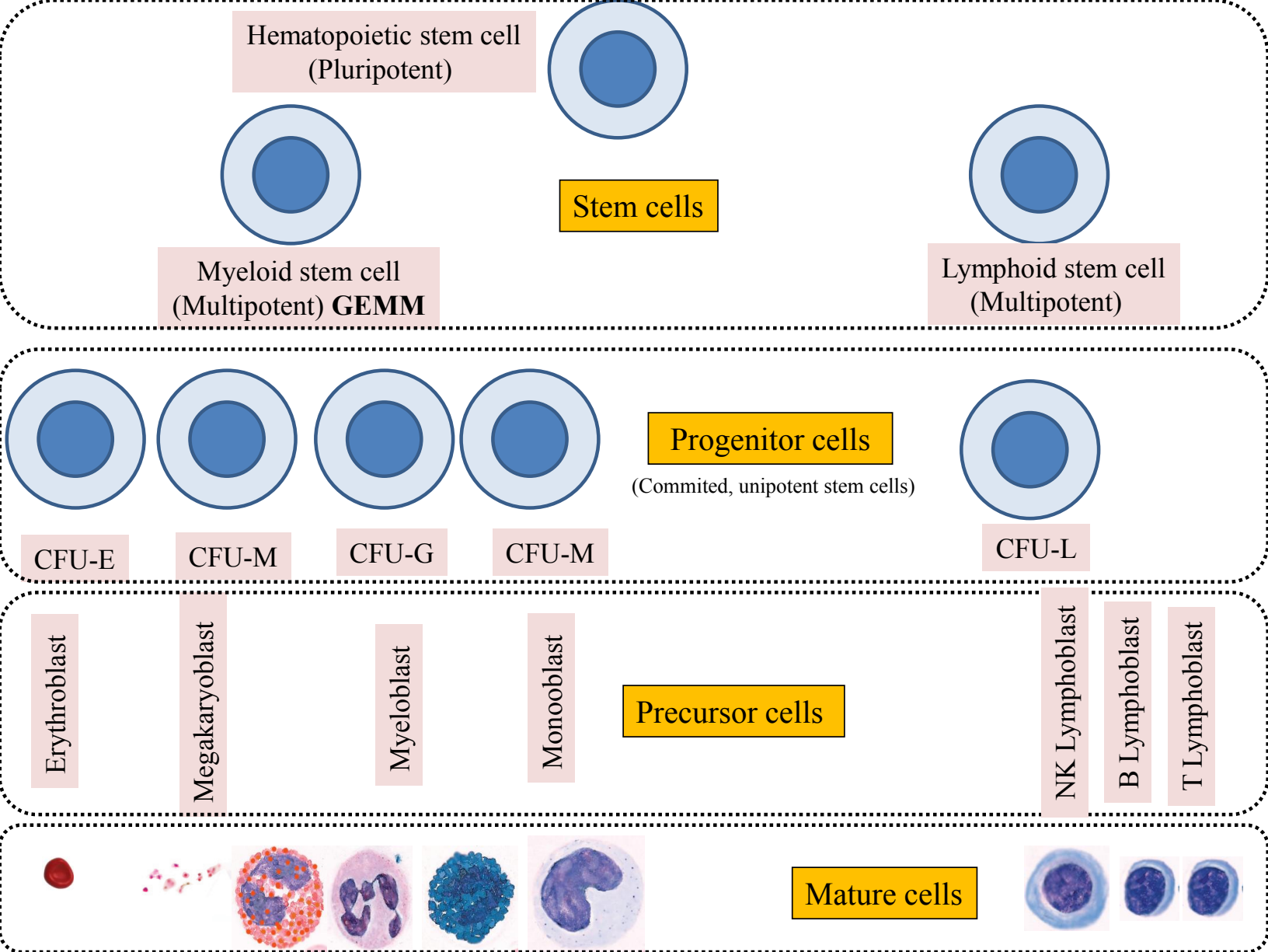
Hematopoietic stem cell
(Pluripotent)
Stem cells
Myeloid stem cell
(Multipotent) GEMM
Lymphoid stem cell
(Multipotent)
Progenitor cells
(Commited, unipotent stem cells)
CFU-E
CFU-M
CFU-G
CFU-M
CFU-L
Erythroblast
Megakaryoblast
Myeloblast
Monoblast
Precursor cells
NK Lymphoblast
B Lymphoblast
T Lymphoblast
Mature cells

in hematopoiesis we are going to start with the mother cell -the cell which produces all types of blood cells- ➡️ hematopoietic stem cell (pluripotent)..
-pluri means (all) potent means (potential)

Whats stem cell?
It's the Undifferentiated cell.. when it divides it produces two cells one cell will undergo the different stages of differentiation and development to end up with the mature products the other cell will add to the original population to maintain the number of these stem cells inside the bone marrow this property of stem cells is called self renewal

What's the meaning of multi potent stem cell?
multi means (many) potent (potential) so these give many types of blood cells but not all

Progenitor cells:

- these cells are committed to produce a certain type of mature blood cells.

- we call these cells colony forming units because when we culture the progenitor cells inside a culture dish these progenitor cells are going to form a colony of the product they are committed to form, even if you have a histological section from a bone marrow we will see that these progenitor cells tend to form colonies inside the red bone marrow

- for Further clarification If myloid stem cell divides and differentiates To produce four types of a progenitor cell (PCG,PCE,PCM,PCM)Each each progenitor cell is a stem cell so the colony forming unit granulocyte produces only granulocytes ..... the colony forming unit thrombocytes produces only thrombocyte

Notice that ➡️

- we have a small pool of stem cells Comparing to the large pool of progenitor cells and precursor cells

- Another difference between these different stages is the property of self renewal .... stem cells are able to divide and to maintain original number such as pluripotent or multi potent or even the unipotent but precursor cell don't have the property of self renewal

Stem cells are capable of asymmetric division and self-renewal.

Stem cells can maintain the original population

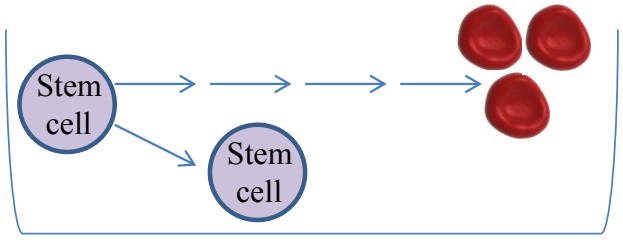

Every time the stem cell multiplies, it will give two cells, one differentiate into mature RBCs and the other cell add to the original population

Precursor cells produce only mature blood cells

Erythroblasts are precursor cells

All Erythroblasts multiply and differentiate into mature RBCs (erythrocytes) and **no** erythroblasts are left in the end

Dr. Heba Kalbouneh

Hematopoietic pluripotent stem cells

Note:

Stem cells and progenitor cells cannot be morphologically distinguished and resemble **lymphocytes**

Myeloid stem cells



Lymphoid stem cells

Rate of cell division:
Slow in **Stem cells**
Rapid in **progenitor and precursor cells**

Progenitor cells/ CFUs

All progenitor cells (CFUs) produce precursor cells (or blasts)

Precursor cells/ Blasts

Selected precursors of different blood cells

Precursor cells gradually assume the morphologic characteristics of the mature, functional cell types they will become

Dr. Heba Kalbouneh

Pluripotent hematopoietic stem cells

All blood cells arise from a single type of stem cell in the bone marrow called pluripotent stem cell
It can produce ALL BLOOD CELL TYPES

It proliferates and forms two major cell linages

Myeloid stem cells

Progenitor and precursor cells

Granulocytes
-Neutrophils
-Basophils
-Eosinophils
Erythrocytes
Megakaryocytes
Monocytes

Note: pre T-cells (precursor T cells, T lymphoblasts) migrate to the thymus where they proliferate and differentiate.

Lymphoid stem cells

Progenitor and precursor cells

T lymphocyte
B lymphocyte
Natural killer cells

Dr. Heba Kalbouneh

Pluripotent hematopoietic stem cells

Myeloid stem cells

Progenitor cells/ CFUs

- CFU Erythrocyte **CFU-E**
- CFU Granulocyte-Monocyte **CFU-GM**
  - CFU Monocyte **CFU-M**
  - CFU Granulocyte **CFU-G**
- CFU Megakaryocyte **CFU-M**

Lymphoid stem cells

- CFU Lymphocyte **CFU-L**

The progenitor cells for blood cells are often called **colony forming units** (CFUs), because they give rise to colonies of only one cell type when cultured in vitro or injected into a spleen.

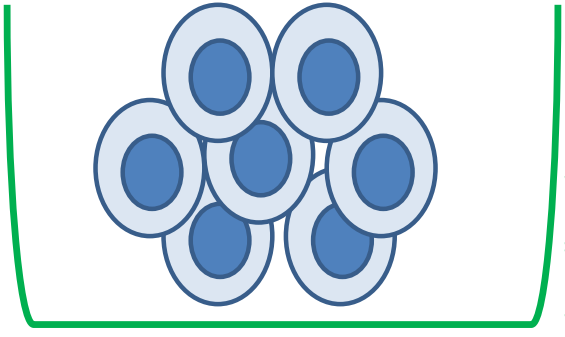

Dr. Heba Kalbouneh

Blood Cell Formation (Hematopoiesis)

Throughout childhood and adult life, erythrocytes, granulocytes, monocytes, and platelets continue to form from stem cells located in bone marrow

Important & required

Erythropoiesis: the process which produces erythrocytes
Granulopoiesis: the process which produces granulocytes
Thrombopoiesis: the process which produces thrombocytes
Lymphopoiesis: the process which produces lymphocytes
Monocytopoiesis: the process which produces monocytes

Remember
Lymphopoiesis occurs in the marrow and in the lymphoid organs to which precursor cells migrate from marrow.

Dr. Heba Kalbouneh

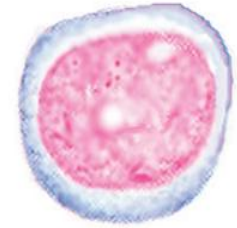

Proerythroblast

Basophilic erythroblast

Polychromatophilic erythroblast

Normoblast

Reticulocyte

Erythrocyte

Nuclear maturation

Cytoplasmic maturation

Erythropoiesis (red cell formation)

✓ Takes about 1 week

✓ Rate is controled by the hormone erythropoietin (secreted by the kidney cells) and the availability of iron, folic acid, vitamen B12, protein precursors

Stages of differentiation are characterized by:

1- Decreasing cell size

2- Progressive loss of organelles

Presence of free ribosomes at early stages

↓

Accounts for the marked cytoplasmic basophilia **(blue)**

3- Progressive increase in hemoglobin content

↓

Accounts for increasing eosinophilia **(pink/red)**

Dr. Heba Kalbouneh

the nucleus gets smaller in size it condenses until it completely disappears and we call this nuclear maturation

we have cytoplasmic changes (basophilic cytoplasm has to be converted into acidophilic cytoplasm) how?
by the Synthesis of hemoglobin ➡️ hemoglobin is a basic protein- cytoplasm will be converted into an Acidophilic cytoplasm and we call this cytoplasmic maturation...

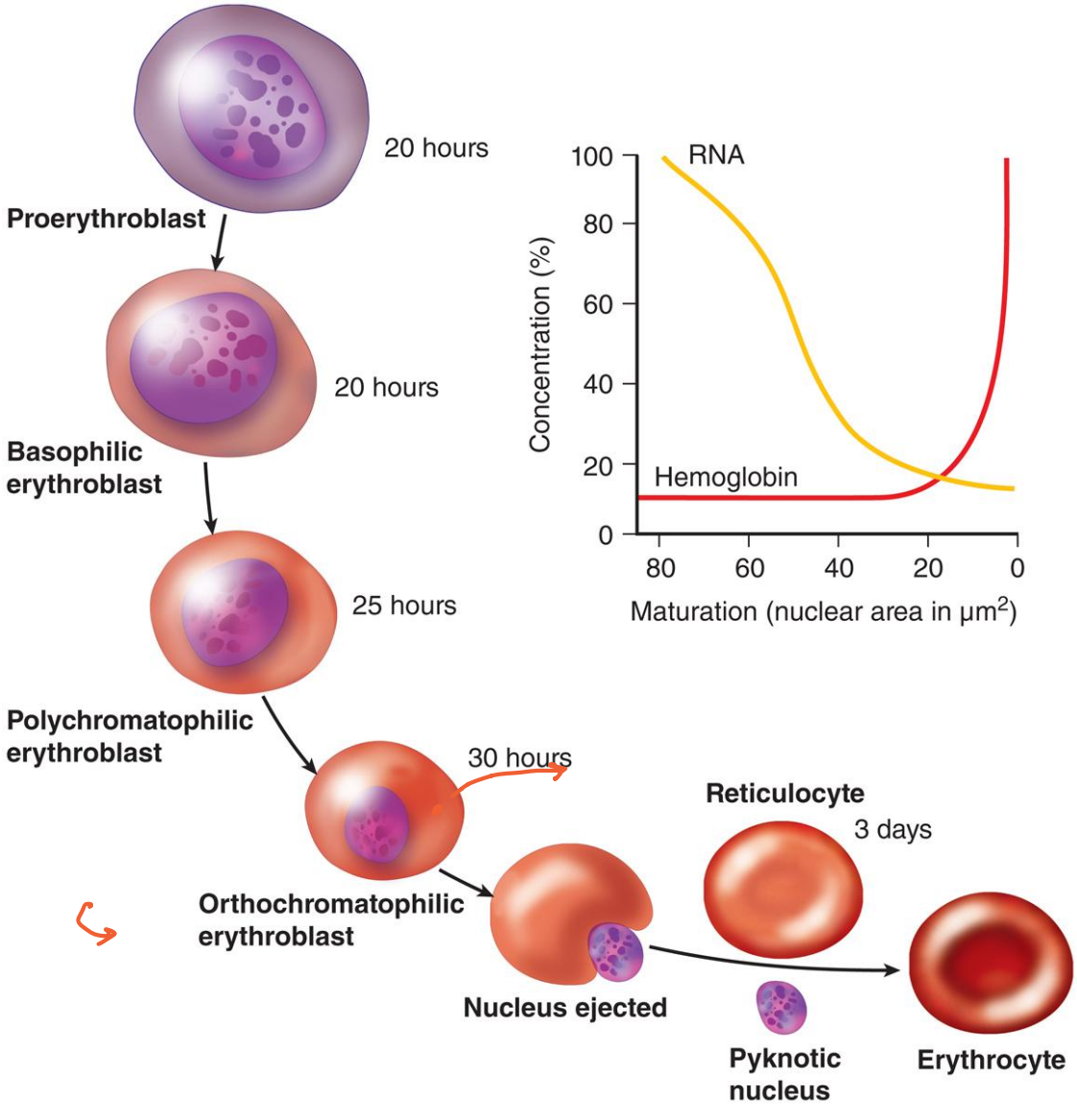
20 hours
Proerythroblast
20 hours
Basophilic erythroblast
25 hours
Polychromatophilic erythroblast
30 hours
Orthochromatophilic erythroblast
Nucleus ejected
Reticulocyte
3 days
Pyknotic nucleus
Erythrocyte
RNA
Hemoglobin
Concentration (%)
100
80
60
40
20
0
80
60
40
20
0
Maturation (nuclear area in μm²)

(in each cell of the of the precursor cells we have about 2 micrometer

Decrease in the cell size)

H.K

Proerythroblast

- ✓The first recognizable erythrocyte precursor
- ✓Largest cell (17um)
- ✓Large pale nucleus with prominent nucleolus
- ✓Pale basophilic cytoplasm Because it's synthesising ribosomes

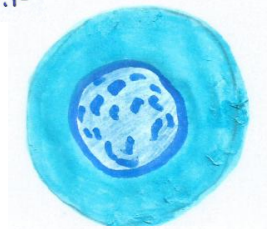

Basophilic erythroblast

- ✓The cell becomes smaller (15um)
- ✓Nucleus: smaller and darker becomes more condensed
- ✓Deeply basophilic cytoplasm (high in ribosomes)

ribosomes are going to start synthesizing hemoglobin which is acidophilic so in the next cell we are going to see acidophilia

Multiple color (red +blue)



Polychromatophilic erythroblast

- ✓The cell becomes smaller (13um)
- ✓Nucleus: smaller and darker
- ✓Cytoplasm becomes violet
- ✓(takes basic (ribosomes) and acidic stains (Hb)

normal color for the future mature erythrocytes

Normoblast (Acidophilic erythroblast!!!)

- ✓The cell becomes smaller (11um)
- ✓Nucleus: smaller, darker and eccentric to be expelled outside
- ✓Cytoplasm is acidophilic (Hb) ⬆️Hb....⬇️Ribosomes

The nucleus is extruded at this stage

Orthochromatophilic مستقيم

Reticulocyte

- ✓Immature erythrocyte but slightly larger (9um)
- ✓No nucleus
- ✓Cytoplasm is acidophilic (Hb) but contains remnants of ribosomes forming reticulum
- ✓Can be stained by supravital stains (brilliant cresyl blue)

Erythrocyte

Dr. Heba Kalbouneh

Reticulocytes

Very important

- Are immature red blood cells (last stage)
- The cell has extruded its nucleus, but is still capable of producing hemoglobin
- Supravital dye: precipitation of reticulum in the cytoplasm (brilliant cresyl blue)
- Normally, only about 1% of all red blood cells in the bloodstream are reticulocytes
- They circulate for about 1-2 days before developing into mature red blood cells
- An increase in reticulocytes >2% ---- blood loss (hemorrhage)

why ?🤔

because losing blood activates bone marrow to synthesize more red blood cell

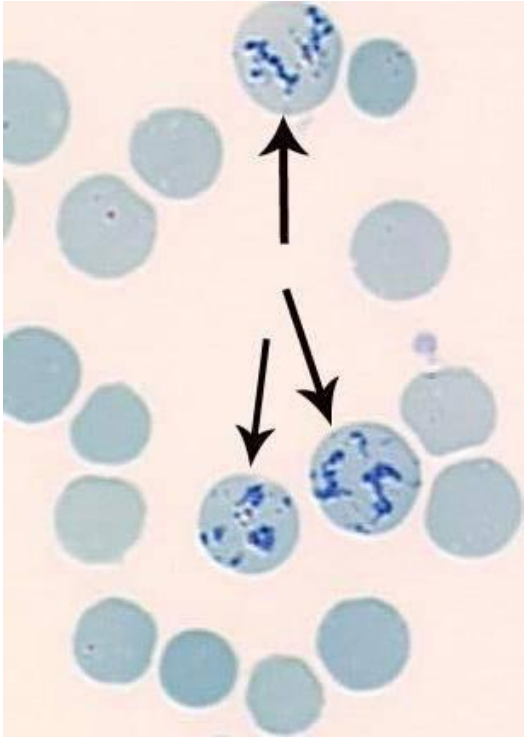

More info➡️🕵🏻

Vital stain means to stain living cells inside the living animal (injection of this Stan into the blood of an animal for example you inject Indian ink) and as this dye is circulating inside the blood it's going to be encountered by the resident macrophages in different locations and this macrophages will consider this stain as a foreign exogenous material so they are going to phagocytose this stain and when you take section from this animal you will find that the macrophages at different locations they are pigmented with the same dye you have used

we have another type of stain called supravital stain which means to stain in living cells but outside the body (you bring a test tube and you take let's say about 2 millimeter of fresh blood so you have living cells but outside the body then you apply your stain which called Berlin blue
we have the mature red blood cell) reticular site matures more it loses the remanence of the ribosomes within the cytoplasm to end up with a smaller cell with an average diameter of seven micrometer in diameter and this is the mature red blood cell)