Hematopoiesis -2

{ Lecture 5 }

Edited by: Rua'a Nader

Dr. Heba Kalbouneh
Associate Professor of Anatomy and Histology

Granulopoiesis (Neutrophils, Eosinophils and Basophils formation)

✓ Takes about 2 weeks

Stages of differentiation are characterized by:

1- Cytoplasmic changes dominated by synthesis of azurophilic granules and specific granules.

First, formation of the azurophilic granules (similar in all three types of granulocytes)

Second, formation of the specific granules (differ in each of the three types of granulocytes)

* Nuclear changes

2- Condensation, indentation and segmentation of the nucleus

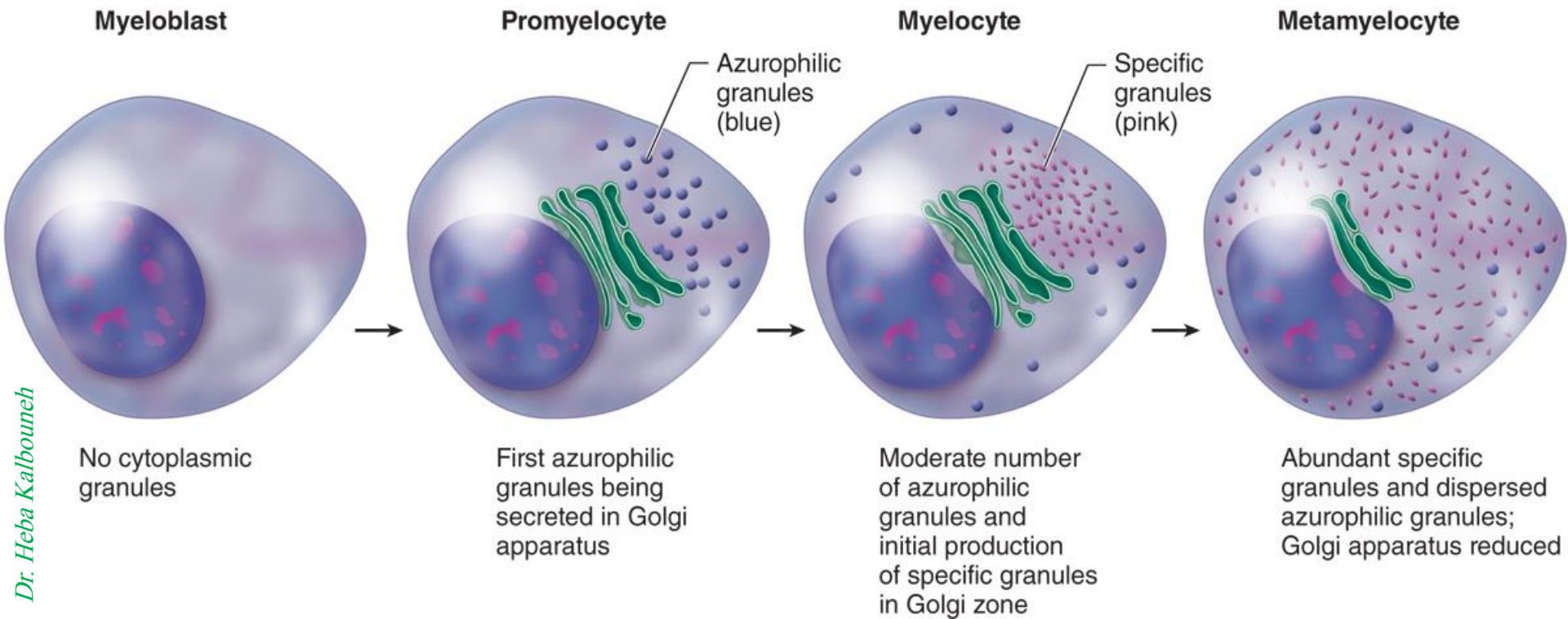

Dr. Heba Kalbouneh

* Nucleoli give us indication of ribosomes synthesis (for non-specific & specific granules).

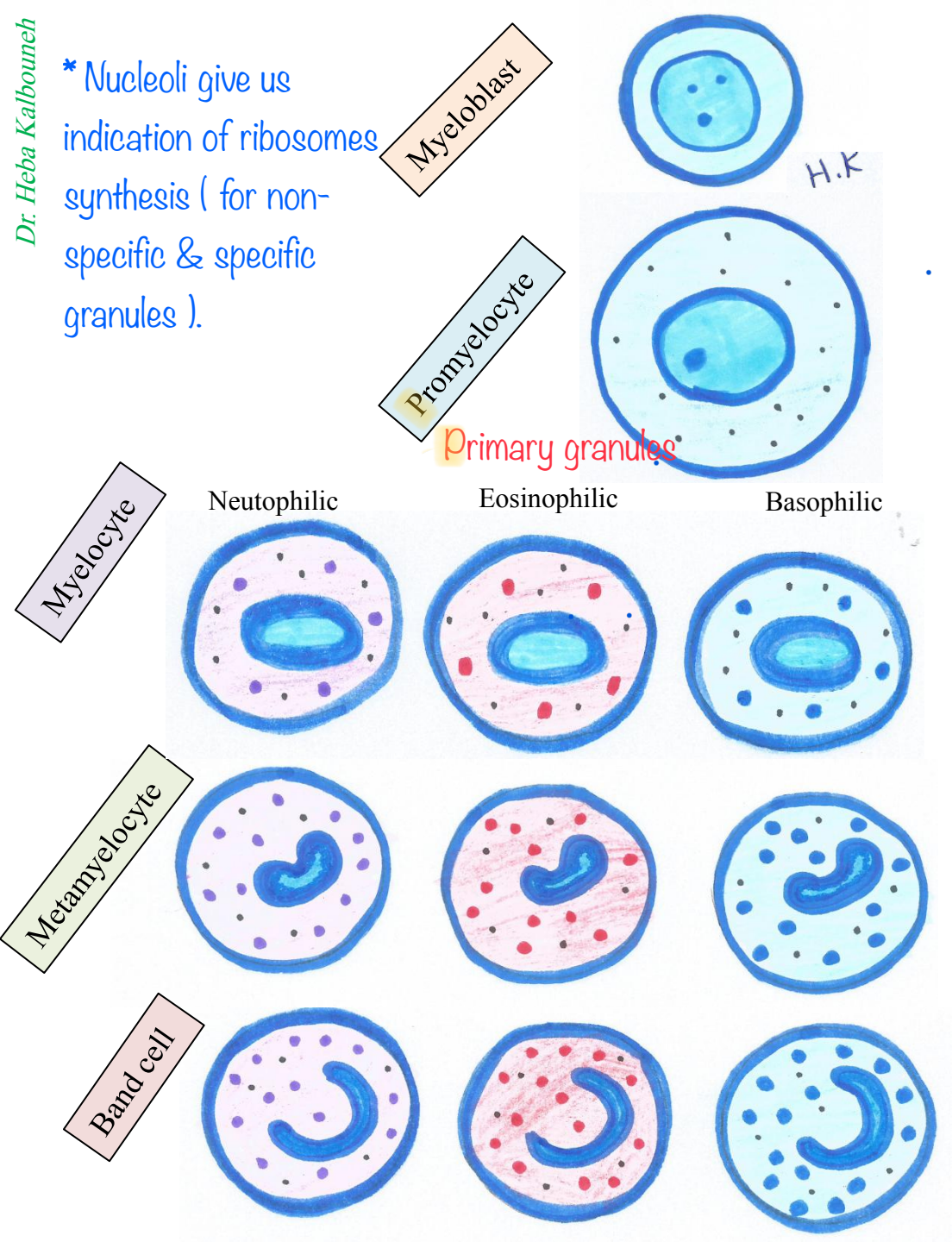

Myeloblast

✓The first recognizable precursor

Promyelocyte

✓The largest (20um)
✓Azurophilic granules start to appear

Myelocyte

✓3 types
✓The cell becomes smaller
✓ The nucleus becomes smaller and darker
✓ Specific granules start to appear

Metamyelocyte

✓3 types
✓Cannot divide
✓Undergoes metamorphosis
✓Nucleus becomes indented (kidney shaped)
✓Specific granules increase in number

Band cell (stab cell)

✓3 types
✓Nucleus becomes curved rod in shape

* Promyelocyte gives 3 types of myelocyte ??

It has activation of different genes and expression of diff. proteins resulting in formation of 3 diff. myelocytes .

* Nuclear Condensation means : more Heterochromatin and less Euchromatin .

* Metamyelocytes : do not undergo mitosis only morphological changes , but myeloblasts , promyelocytes & myelocytes are mitotic cells (they divide).

* for ex. If you culture one promyelocyte and you supply it with factors necessary to promote its differentiation and mitosis , this cell will produce many granulocytes at the end of differentiation. And if you culture a single neutrophilic myelocyte , we are going to have many neutrophils and so on.. but if you culture a single neutrophilic metamyelocyte , it will end up with only one Neutrophil (it does not divide).

* What is the last stage of granulopoiesis where the precursor cells can divide?

Ans. Myelocytes.

Neutrophilic band cells (important)

Their percentage does not exceed 5% in peripheral blood

The appearance of large numbers of immature neutrophils (band cells) in the blood, sometimes called a "shift to the left," is clinically significant, usually indicating **a bacterial infection**.

This means that the bone marrow has been signaled to release more neutrophils and increase production of neutrophils

Band cell is almost a mature neutrophil, just doesn't have a segmented nucleus yet

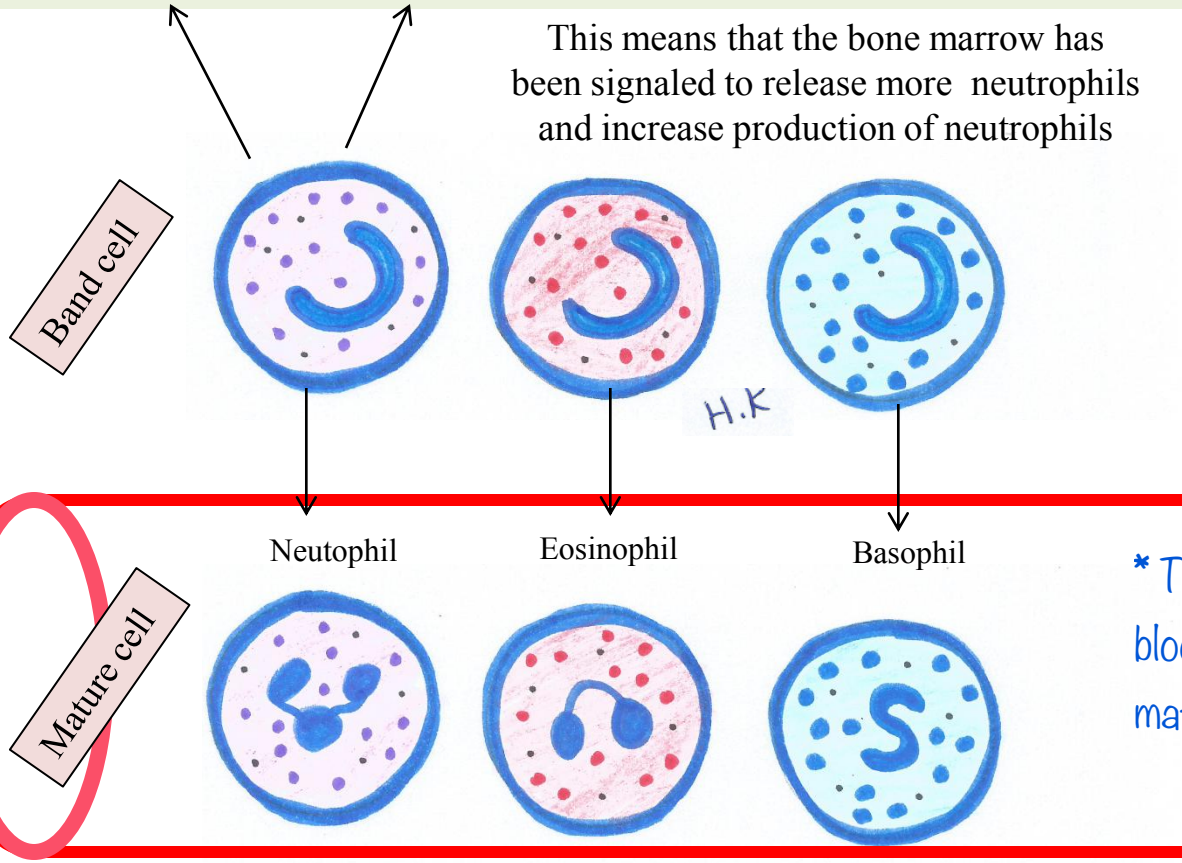

* They called Band cells , bcz they have band (C-shaped) nuclei .

* These band cells can be released into blood stream to complete their nuclear maturation inside blood .

Dr. Heba Kalbouneh

Bone marrow pool

Myloblast
Promyloctye
Mylocyte
Metamylocyte
Band cell
Neutrophil

Granulopoietic pool

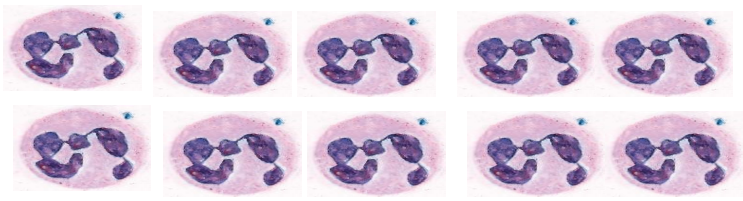

Storage pool

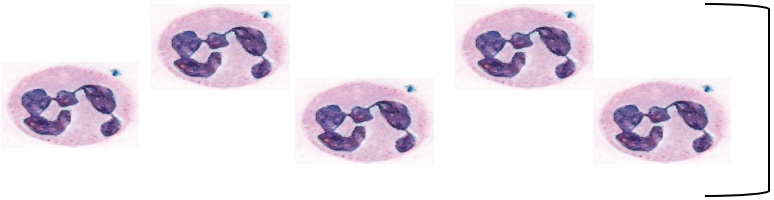

Circulating pool

* (Moving within central area with blood flow)

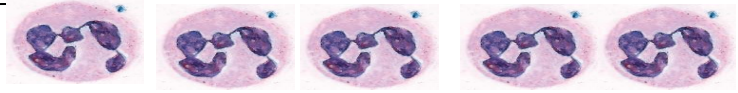

Marginating pool

Dr. Heba Kalbouneh

Developing and mature neutrophils exist in four functionally and anatomically defined compartments:

(1) The granulopoietic compartment in active marrow
(2) Storage as mature cells in marrow until release
(3) The circulating population
(4) A population undergoing margination

Margination is a process in which neutrophils adhere loosely and accumulate transiently along the endothelial surface in venules and small veins.

Note: Margination of neutrophils in some organs can persist for several hours and is not always followed by the cells' emigration from the microvasculature.

Dr. Heba Kalbouneh

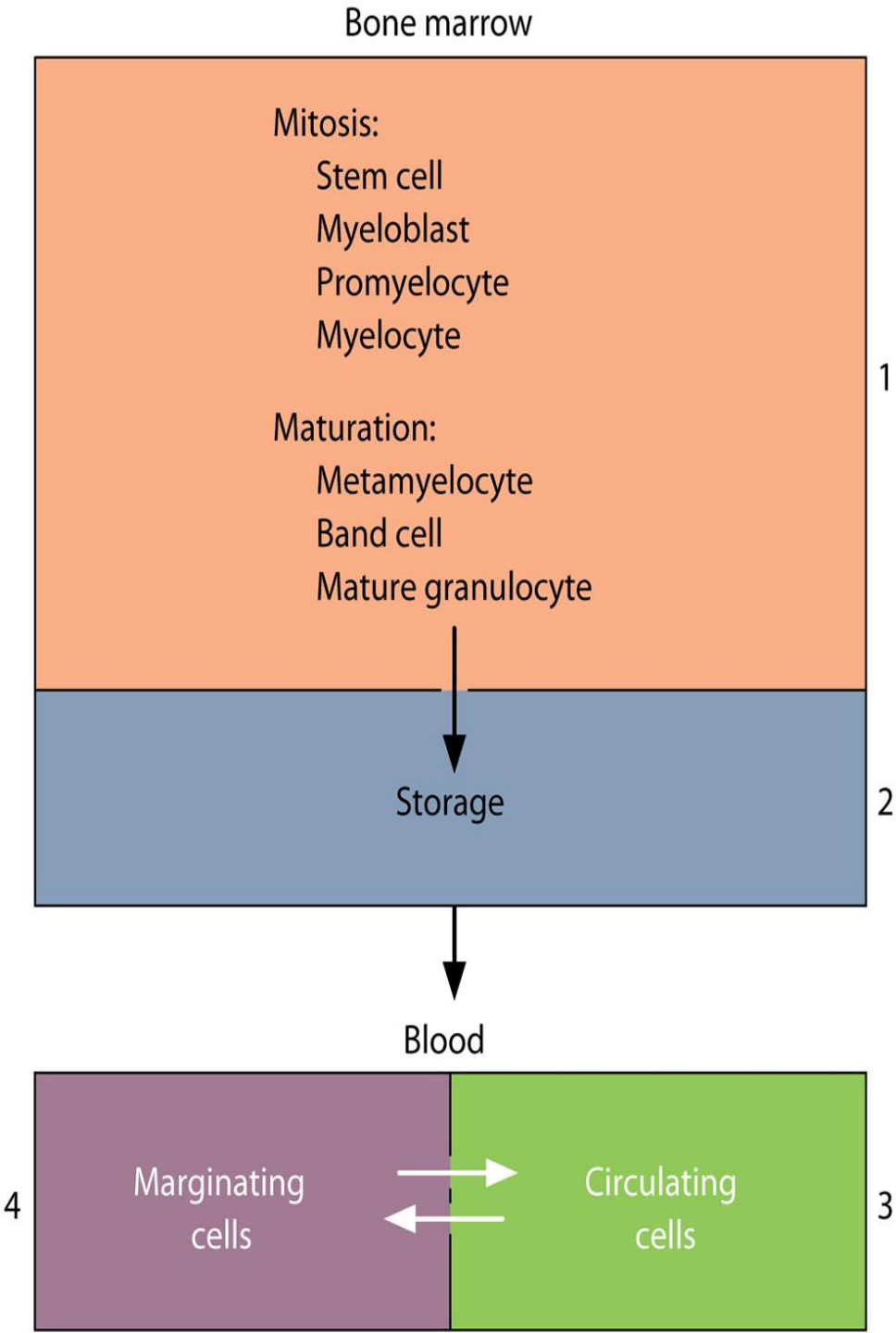

At sites of injury or infection, neutrophils and other granulocytes enter the connective tissues by migrating through intercellular junctions between endothelial cells of postcapillary venules in diapedesis.

Inflamed connective tissues thus form a fifth terminal compartment for neutrophils, where the cells reside for a few days and then die by apoptosis, regardless of whether they have performed their major function of bacterial phagocytosis.

Changes in the number of neutrophils in the blood must be evaluated by taking all their compartments into consideration.

Thus, neutrophilia (an increase in the number of circulating neutrophils) does not necessarily imply an increase in granulopoiesis.

Intense muscular activity or the administration of epinephrine can cause neutrophils in the marginating compartment to move into the circulating compartment, producing neutrophilia even though granulopoiesis has not increased. However, glucocorticoids (adrenal hormones) such as cortisone increase the mitotic activity of neutrophil precursors and this also increases the blood count of neutrophils.

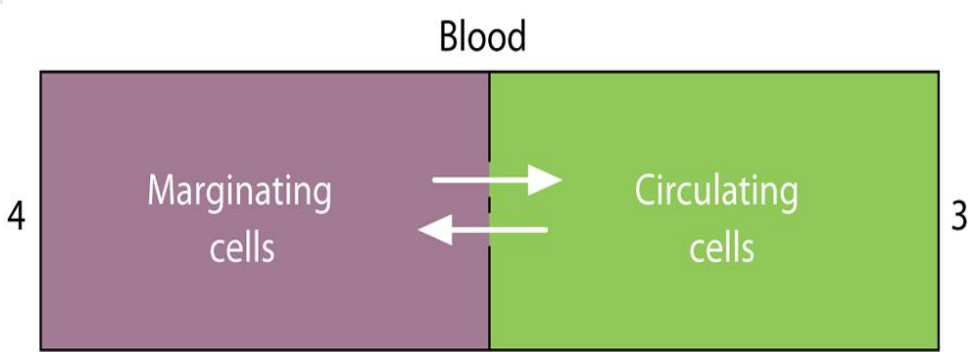

* If we do not have infection, neutrophils live few hours inside the blood and they die by apoptosis and will be phagocytosed by macrophages inside liver , spleen & BM

How many RBCs are in 1 ul of peripheral blood?

5 million/ul

How many WBCs are in 1 ul of peripheral blood?

4500-11000/ul

* Why we call the precursor cells for granulocytes myeloblasts and myelocytes... ??
- bcz most of precursor cells inside Bone Marrow are precursor cells for granulocytes.

But in the bone marrow (myeloid tissue)!!!

Myeloid: Erythroid

3:1

* Myeloid cells have shorter life span , so we need more precursor cells inside bone marrow to produce high number of these cells (to compensate for their shorter life span.

Remember the life span!!!!!

White blood cell abnormalities

Increased numbers of white cells appear in the peripheral blood in a variety of disorders and provide a useful clue to the underlying disease.

A considerable and sustained increase of circulating **neutrophils** in **bacterial infection**

An increase of circulating **eosinophils** **in parasitic infection and some allergies**

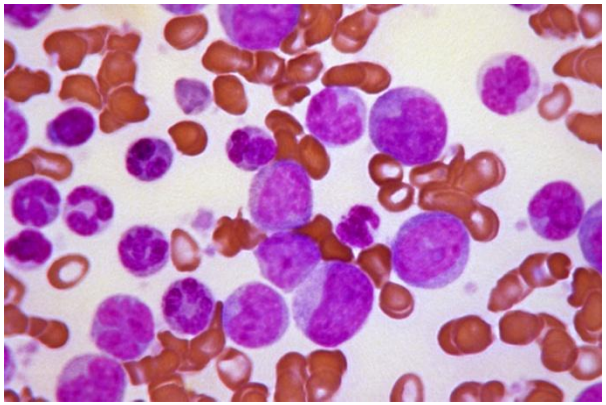

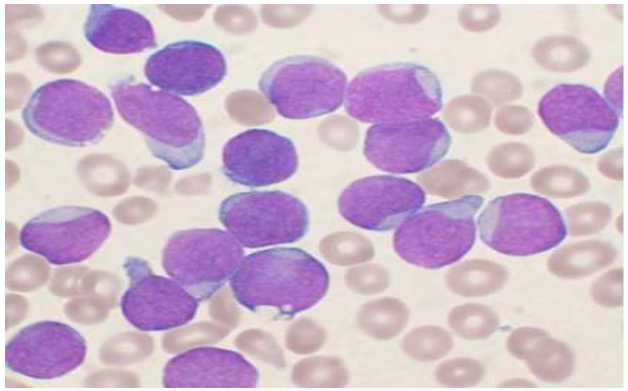

Leukemia is a malignant proliferation of white cell precursors in the bone marrow

Vast number of white cells and their precursors (many of which spell over into the blood)

Leukemia is classified according to the cell line involved (granulocytic, monocytic, lymphocytic)

Dr. Heba Kalbouneh

* 2 main conditions that affect the bone marrow :

1- Aplastic anemia or (Pancytopenia) : the cells inside bone marrow can be destroyed by radiation or chemotherapy or autoimmune diseases (like T-cells attack these cells resulting in a condition (Hypoplastic or Aplastic cells) , it means that there's suppression of the activity of these cells, so they can't divide at enough speed to maintain the number of blood cells.

2- Leukemia : Cells inside bone marrow have malignant proliferation and neoplastic changes, so we can see in a blood film abnormal precursor cells in the peripheral blood, and we should take bone marrow aspirate or biopsy.

Bone marrow Apirate or biobsy
Needed to diagnose disorders like aplastic anemia or leukemia

* BM Aspirate: place a needle to take sample of BM and replace it on a glass slide and stain it .
* BM biopsy: you take red bone marrow along with surrounding bone.

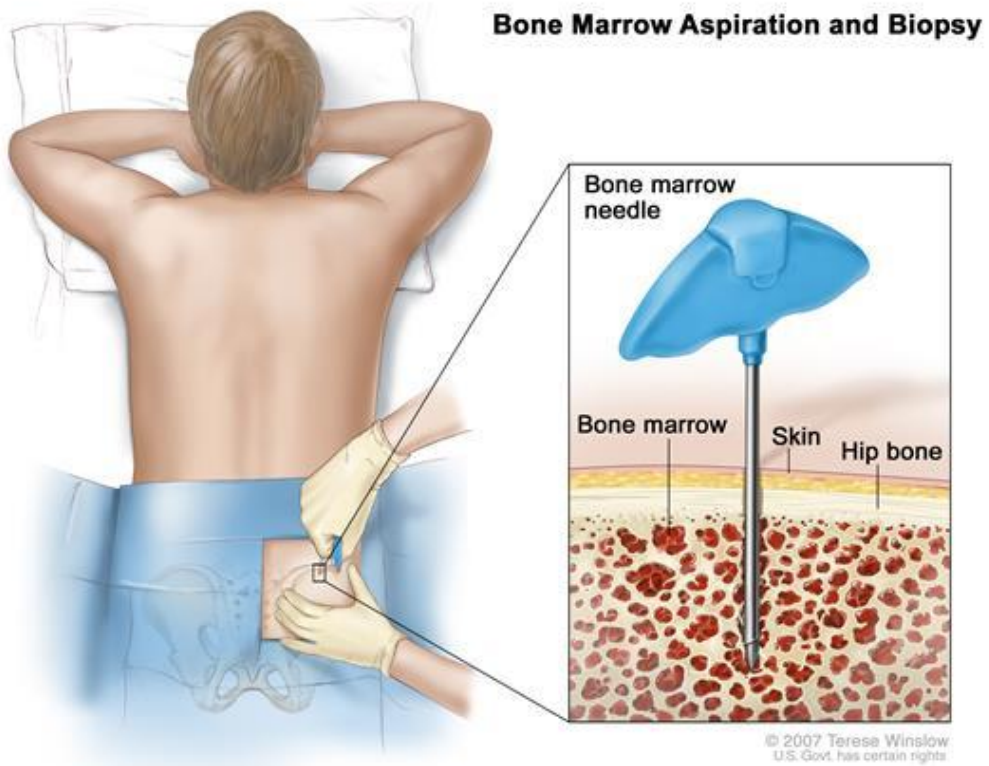

Bone marrow transplantation
In bone marrow diseases like leukemia, hematopoietic stem cells taken from a donor are infused into the same or another person

* We take hematopoietic stem cells from donor and inject them to a patient, these cells will circulate inside blood until they settle down inside bone marrow and they divide and differentiate to produce normal blood cells.
Why in bone marrow?? bcz of stroma of BM composed of reticular C.T and reticular cells have specific adhesion molecules that attract these cells to settle down inside BM.

Thrombopoiesis

Hematopoietic pluripotent stem cell

↓

Myeloid stem cell

↓

Colony forming unit- megakaryocyte

↓

Megakaryoblast

↓

Promegakaryocyte

↓

Megakaryocyte

* Nucleus is large, because it goes many rounds of DNA replication without division of nucleus (polypoid nucleus) .

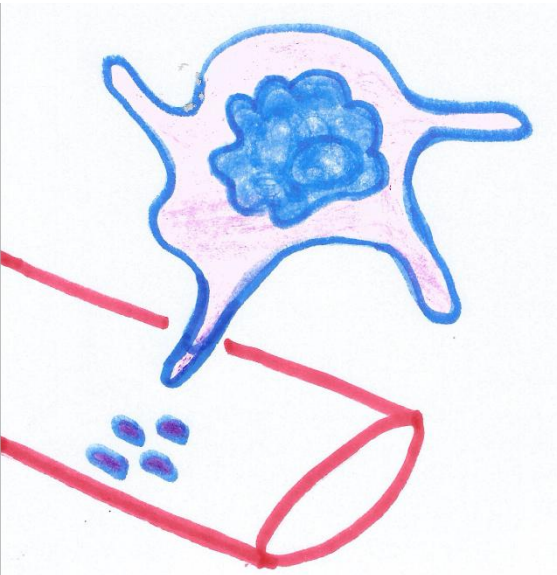



Dr. Heba Kalbouneh

Monocytopoiesis

Hematopoietic pluripotent stem cell



Myeloid stem cell

Colony forming unit- monocyte



Monoblast



Promonocyte

Monocyte

Dr. Heba Kalbouneh

Lymphopoiesis

Hematopoietic pluripotent stem cell

↓

Lymphoid stem cell

↓

Lymphocyte colony forming cell

↓

Lymphoblast

- Thymus → T Lymphocyte
- BM → B Lymphocyte
- Directly into blood → Natural killer lymphocyte

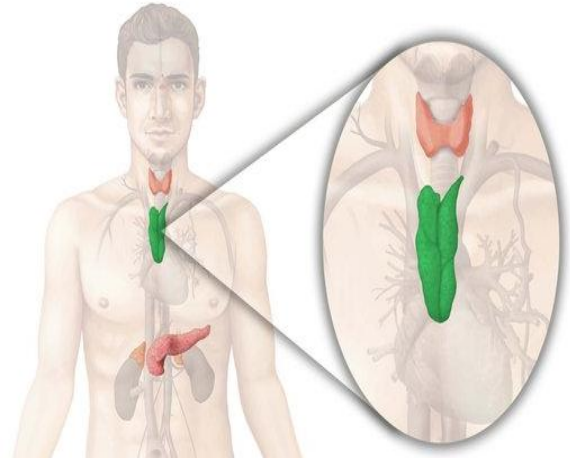



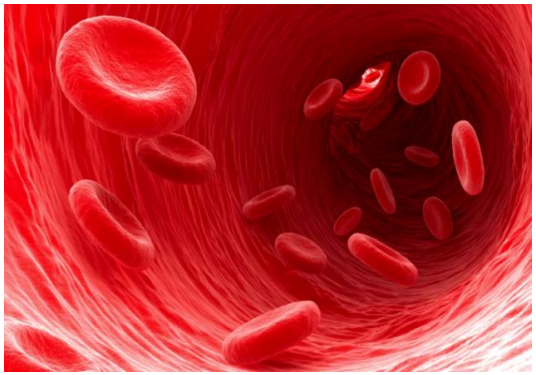

Dr. Heba Kalbouneh

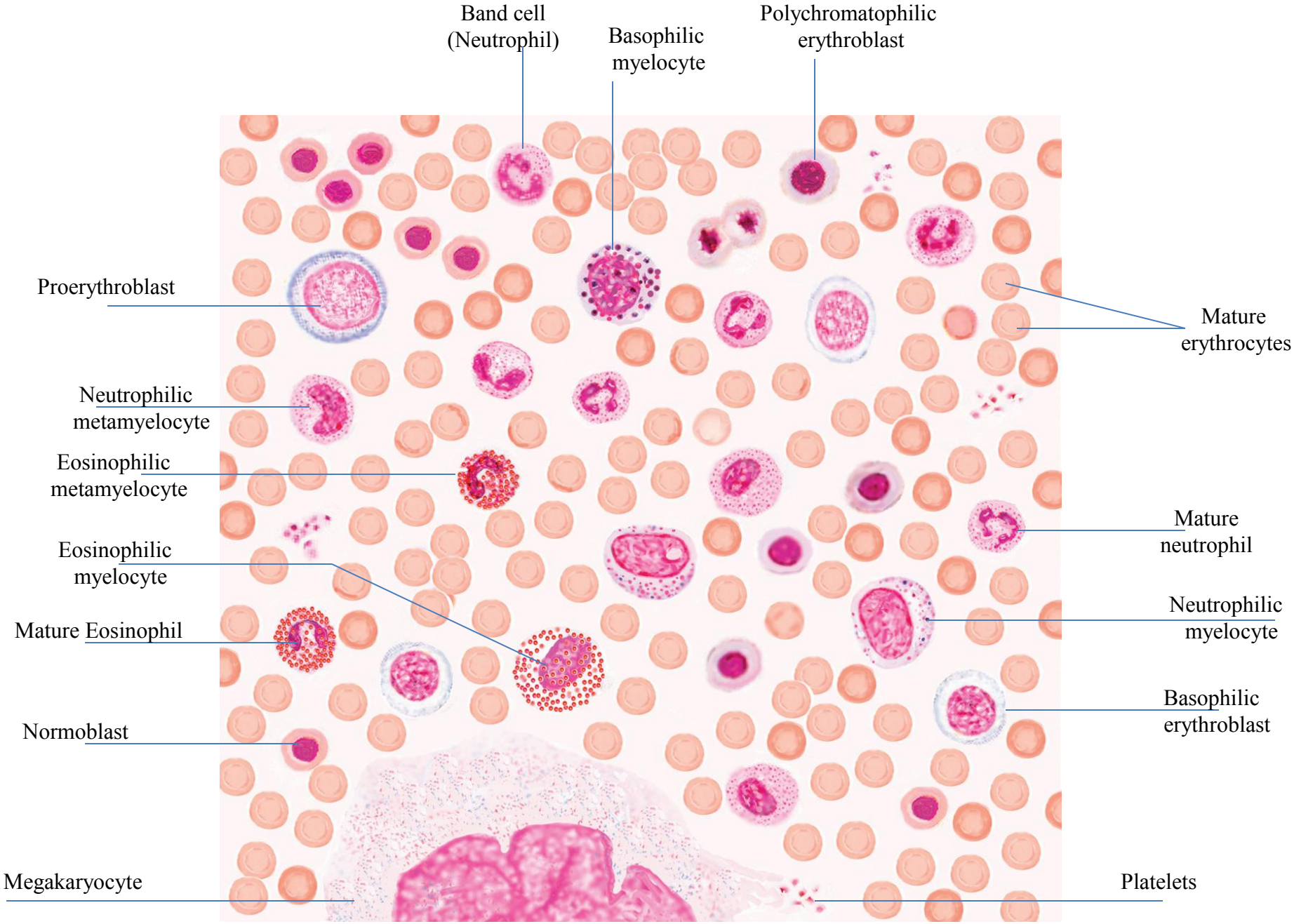

Bone marrow (Giemsa stain)

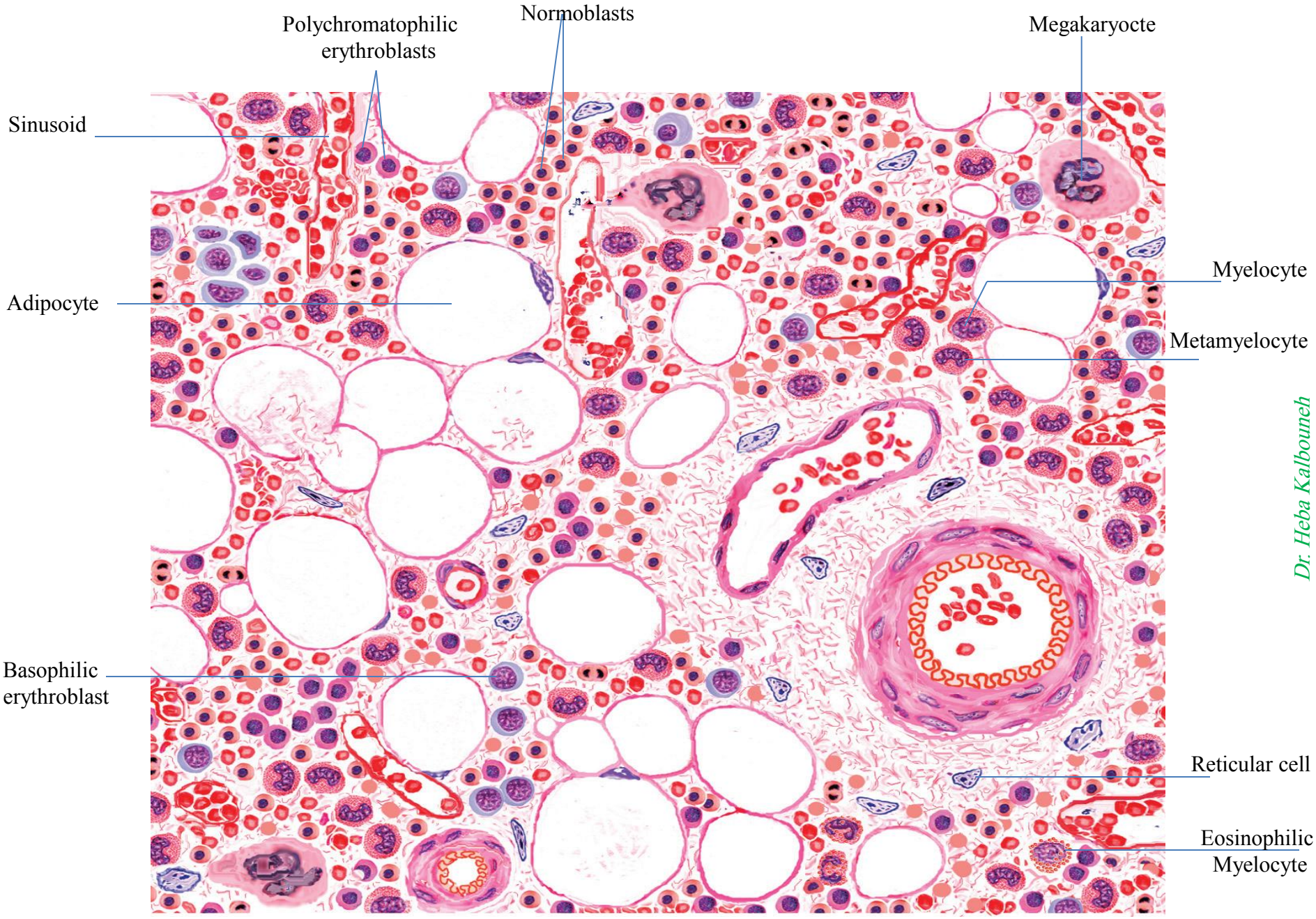

Bone marrow (H&E)

Hemopoietic growth factors (colony stimulating factors (CSF) or cytokines) are glycoproteins that stimulate proliferation of progenitor and precursor cells and promote cell differentiation and maturation within specific lineages.

Erythropoiten

Thrombopoiten

For granulocytes CSF-G

Cloning of the genes for several important hematopoietic growth factors has significantly advanced study of blood formation and permitted the production of clinically useful factors for patients with hemopoietic disorders.

* Patient with Renal failure —> erythropoietin deficiency —> Anemia, so if we give the patient erythropoietin, we gonna stimulate production of RBC's inside BM and erythropoiesis process takes one week , so we have to wait at least one week to see a significant increase of the number of RBCs in peripheral blood.

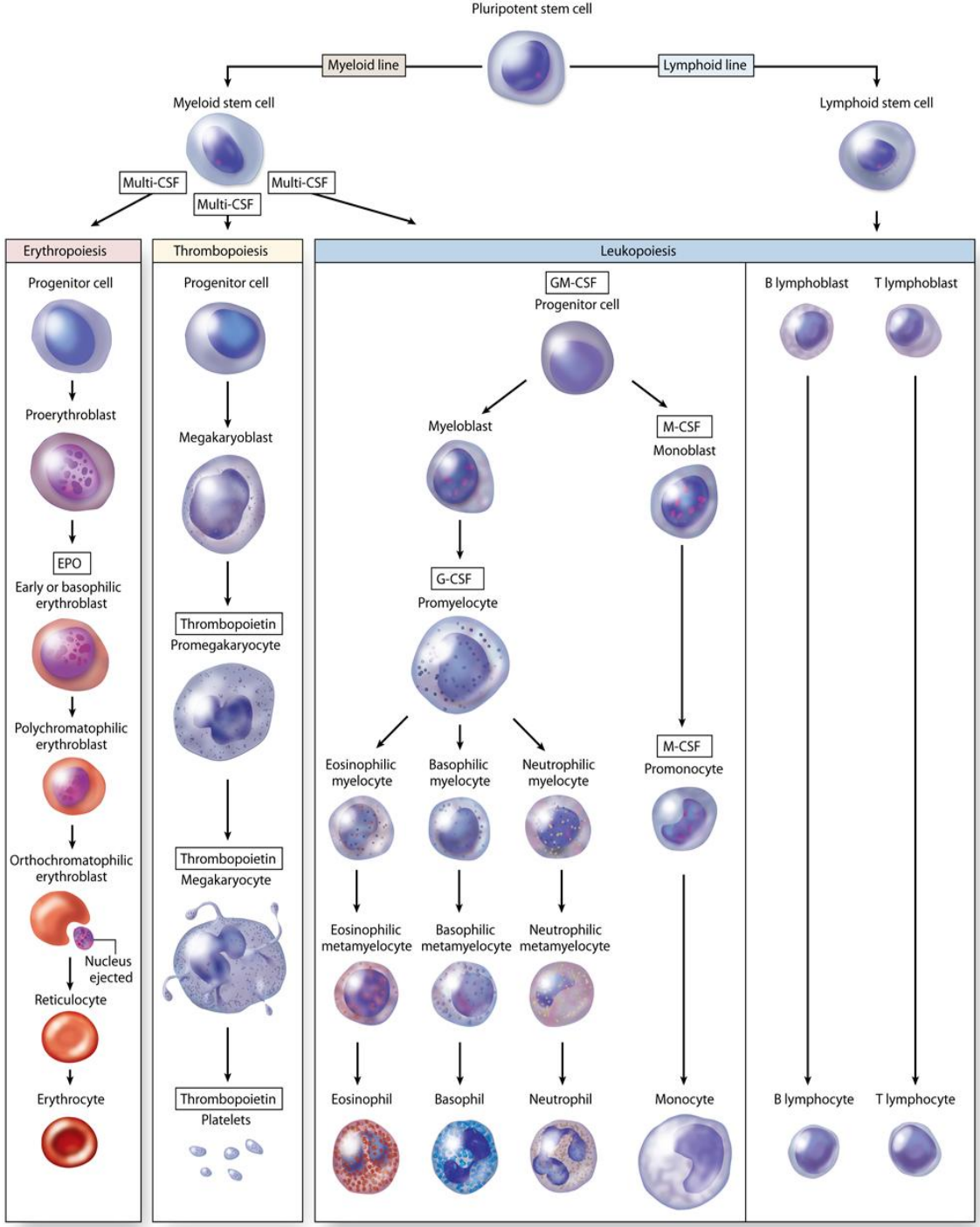
Pluripotent stem cell
Myeloid line
Lymphoid line
Myeloid stem cell
Lymphoid stem cell
Multi-CSF
Multi-CSF
Multi-CSF
Erythropoiesis
Thrombopoiesis
Leukopoiesis
Progenitor cell
Proerythroblast
EPO
Early or basophilic erythroblast
Polychromatophilic erythroblast
Orthochromatophilic erythroblast
Nucleus ejected
Reticulocyte
Erythrocyte
Progenitor cell
Megakaryoblast
Thrombopoietin
Promegakaryocyte
Thrombopoietin
Megakaryocyte
Thrombopoietin
Platelets
GM-CSF
Progenitor cell
Myeloblast
M-CSF
Monoblast
G-CSF
Promyelocyte
Eosinophilic myelocyte
Basophilic myelocyte
Neutrophilic myelocyte
M-CSF
Promonocyte
Eosinophilic metamyelocyte
Basophilic metamyelocyte
Neutrophilic metamyelocyte
Eosinophil
Basophil
Neutrophil
Monocyte
B lymphoblast
T lymphoblast
B lymphocyte
T lymphocyte

Shortly after her birth a baby is diagnosed with a mutation in the erythropoietin receptor gene which leads to familial erythrocytosis (familial polycythemia). During the seventh to ninth months of fetal development, the primary effect on her red blood cell production was in which of the following?

a. Liver
b. Yolk sac
c. Spleen
d. Thymus
e. Bone marrow

A 54-year-old man presents with recurrent breathlessness and chronic fatigue. After routine tests followed by a bone marrow biopsy he is diagnosed with lymphocytic leukemia. Chemotherapy is administered to remove the cancerous cells, which also destroys the precursor cells of erythrocytes. To reestablish the erythrocytic lineage, which of the following cells should be transplanted?

a. Reticulocytes
b. Orthochromatophilic erythroblasts
c. Megakaryoblasts
d. Basophilic erythroblasts
e. Metamyelocytes

A smear of blood from a 70-year-old leukemia patient reveals a larger than normal population of cells that have large, round nuclei with 1 or 2 nucleoli. The cytoplasm of these cells shows azurophilic granules. Which of the following forms of leukemia would you suspect?

a. Promyelocytic leukemia
b. Basophilic leukemia
c. Lymphoblastic leukemia
d. Stem cell leukemia
e. Eosinophilic leukemia