Department of Anatomy and Histology

School of Medicine

The University of Jordan

Endocrine system

Edited by:
Batool Bdour.

by Dr. Amjad Shatarat

2020

Objectives

1. **Recognize and understand the main parts of the pituitary gland and their locations, relations and connections.**

2. **Comprehend the blood supply of the pituitary gland and its portal circulation.**
3. **Understand the embryological origins of the pituitary gland.**

4. **Grasp the clinical correlations of the pituitary gland on anatomical basis and its surgical approach.**

5. **Recognize and understand imaging of the pituitary gland.**

6. **Grasp the histological structure of the pituitary gland and its cells under light and electron microscopes.**

7. **Recognize and understand the location, simple structure of** the hypothalamus and its connections

The hypothalamus

consists of only 4 cm, 0.3% of the total brain

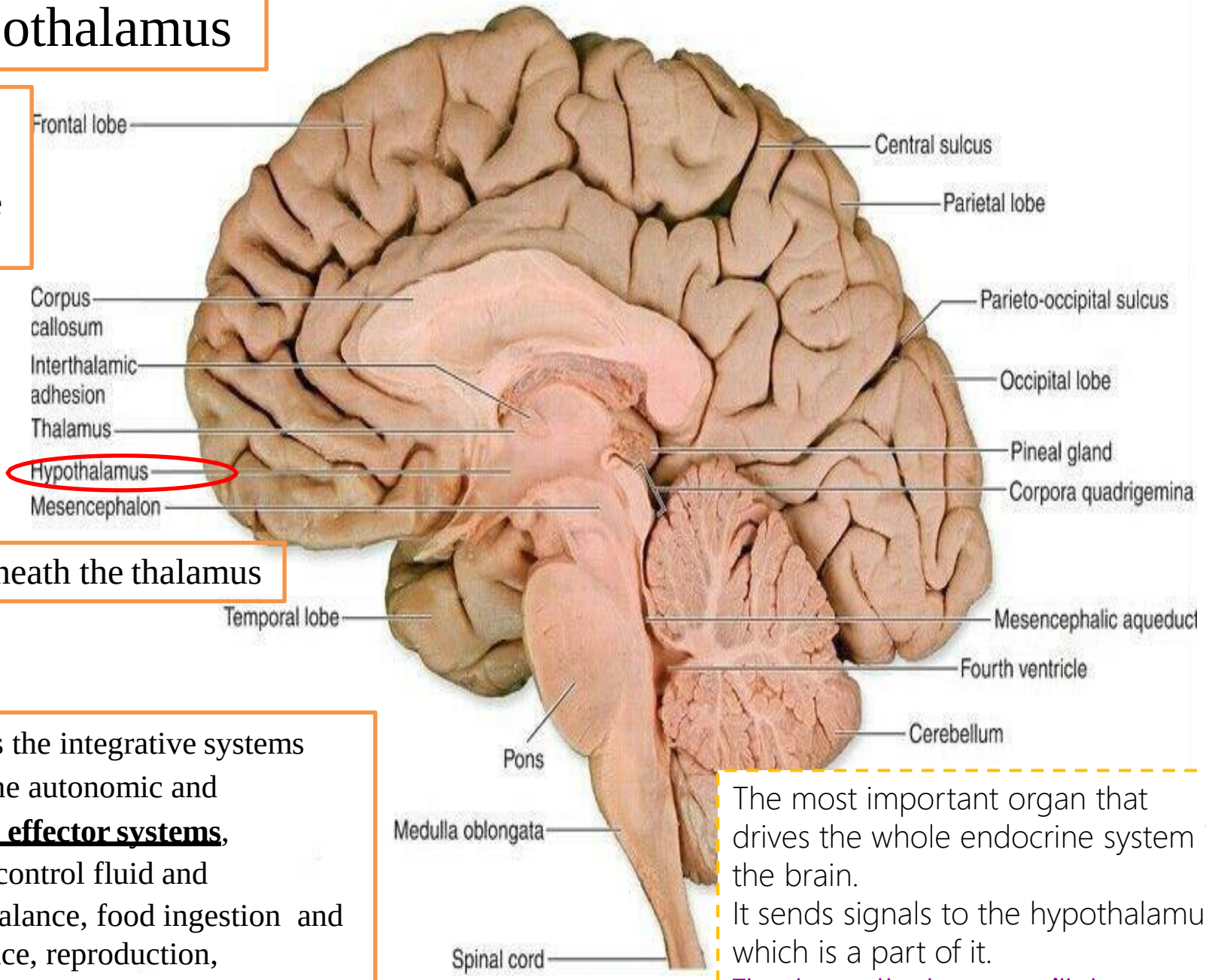

- It lies beneath the thalamus

- It contains the integrative systems that, via the autonomic and **endocrine effector systems**, control fluid and electrolyte balance, food ingestion and energy balance, reproduction, thermoregulation, and immune and many emotional responses

The most important organ that drives the whole endocrine system is the brain.
It sends signals to the hypothalamus, which is a part of it.
The hypothalamus will be discussed in the CNS not here.

The hypothalamus contains a number of neuronal groups called **nuclei**

Just know that these nuclei are the main players in the function of the hypothalamus

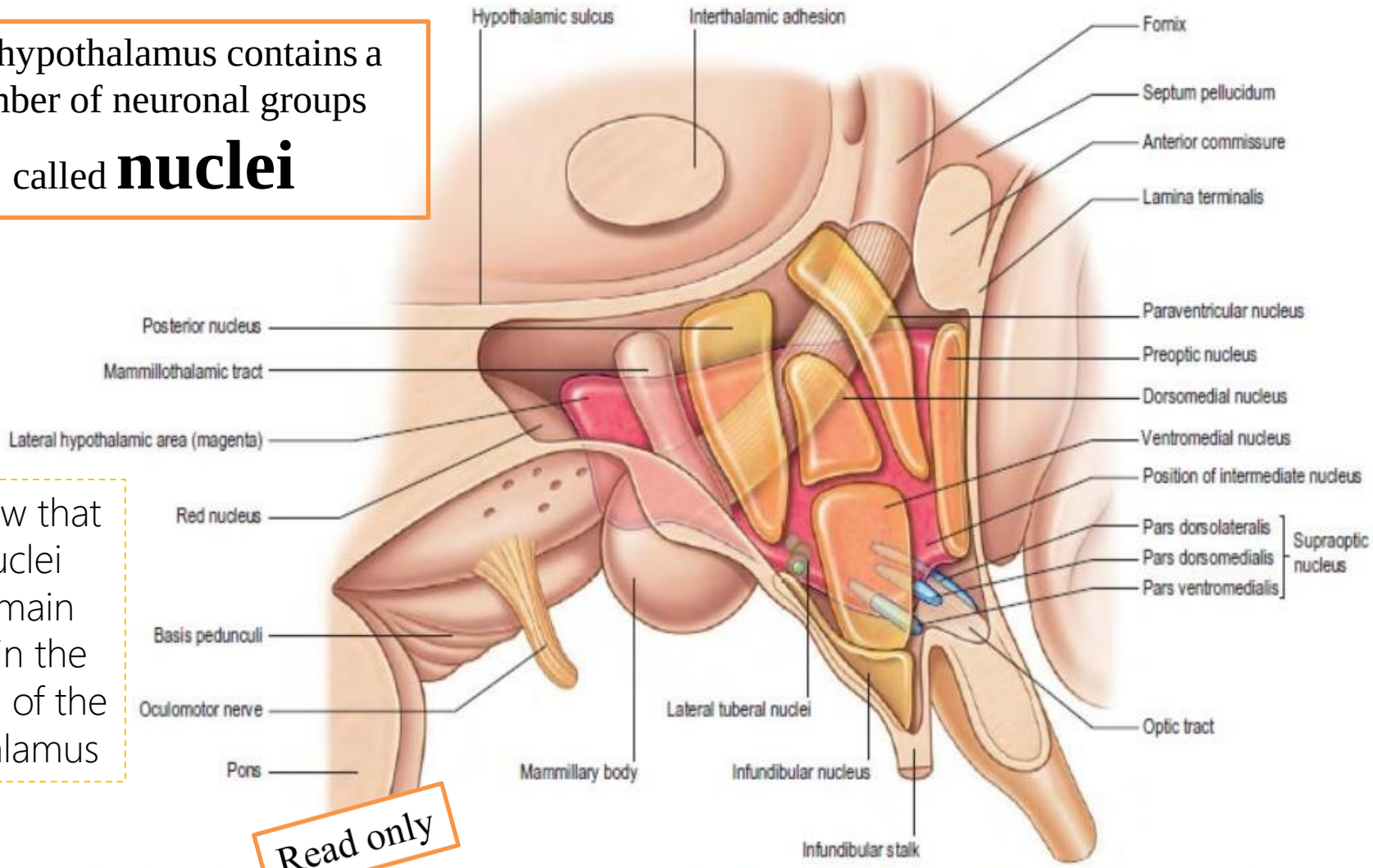

Read only

Fig. 21.8 The hypothalamic region of the left cerebral hemisphere viewed from the medial aspect and dissected to display the major hypothalamic nuclei. In the upper diagram the medially placed nuclear groups have been removed; in the lower diagram both lateral and medial groups are included. Lateral to the fornix and the mammillothalamic tract is the lateral hypothalamic region, in which the tuberomammillary nucleus is situated posteriorly, and the lateral preoptic nucleus rostrally. Surrounding the fornix is the perifornical nucleus, which joins the lateral hypothalamic area with the posterior hypothalamic nucleus. The medially placed nuclei (yellow) fill in much of the region between the mammillothalamic tract and the lamina terminalis, but also project caudal to the tract. The lateral tuberal nuclei are situated ventrally, largely in the lateral hypothalamic area. The supraoptic nucleus may form three rather separate parts. The intermediate nuclei form three groups between the supraoptic and paraventricular nuclei. (Modified from Nauta WJH, Haymaker W 1969 Hypothalamic nuclei and fibre connections. In: Haymaker W, Anderson E, Nauta WJH (eds) The Hypothalamus, by permission of Charles C Thomas Publisher, Ltd, Springfield, Illinois.)

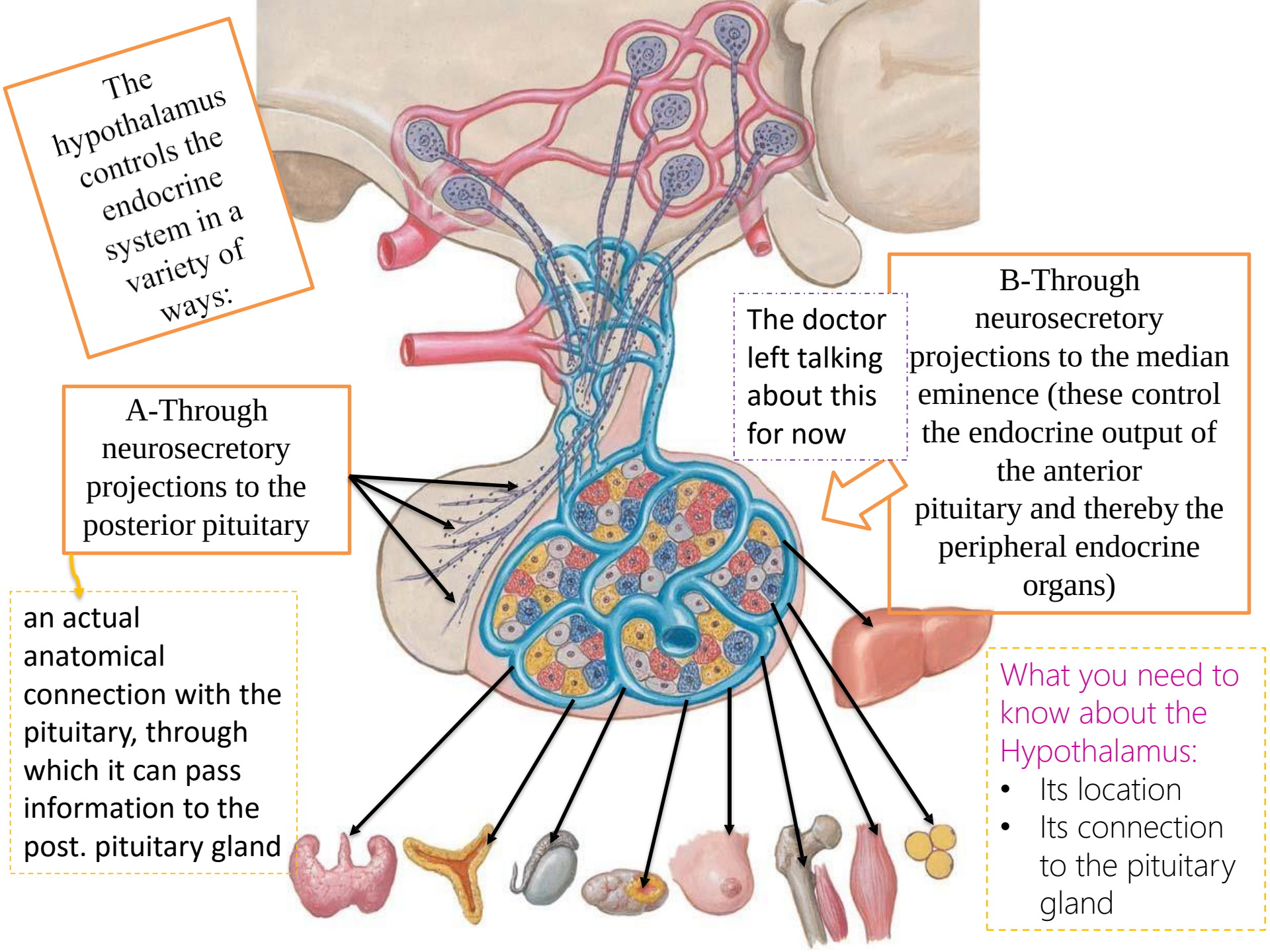
The hypothalamus controls the endocrine system in a variety of ways:
A-Through neurosecretory projections to the posterior pituitary
an actual anatomical connection with the pituitary, through which it can pass information to the post. pituitary gland
The doctor left talking about this for now
B-Through neurosecretory projections to the median eminence (these control the endocrine output of the anterior pituitary and thereby the peripheral endocrine organs)
What you need to know about the Hypothalamus:
• Its location
• Its connection to the pituitary gland

THE PITUITARY GLAND

Different names

also known as the HYPOPHYSIS

So there's an epiphysis

Master organ????

➲ Because It secretes hormones that **regulate the functions** of other glands in the system

الغدة النخامية

The pituitary

- It is a pea-sized
- Weighs 0.5 g in males and 1.5 g in multiparous women

location

- It is centrally located at the base of the brain, where it lies in a **saddle-shaped depression** of the sphenoid bone called

THE SELLA TURCICA

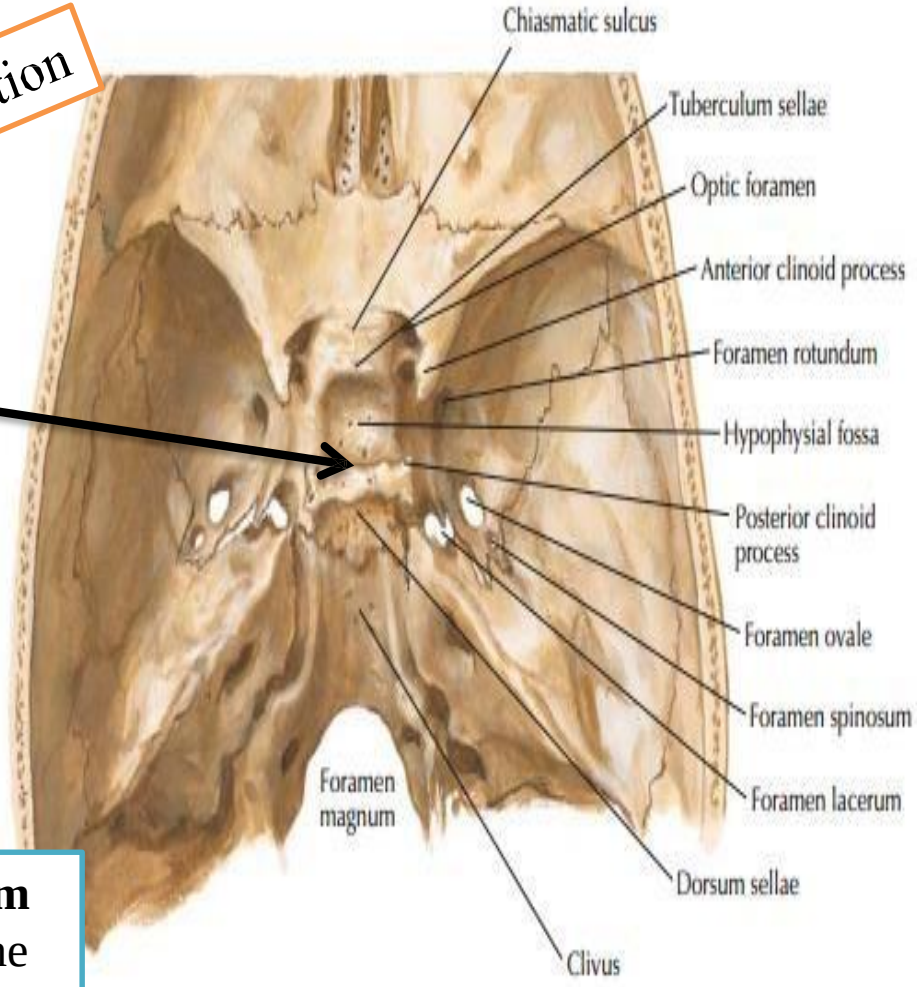

It's well protected in our brain in its own cavity, on the sella turcica

- A short stalk, the **infundibulum** connects the pituitary gland to the hypothalamus.

Gross Anatomy

relations

- A circular fold of dura mater, the

diaphragma sellae

forms the roof of this fossa

The diaphragma sellae separates the pituitary gland from the overlying optic chiasma

Superiorly

- The diaphragma sellae is pierced by a small central aperture through which the pituitary stalk passes, and it separates **the anterior part of the upper surface of the gland from**

The optic chiasma.

when we talk about their function, glands are targeted by tumors, especially the endocrine glands (which are mostly epithelial) and cancer is all about invading the nearby structures, and when we talk about the invasion, we need to understand the relations

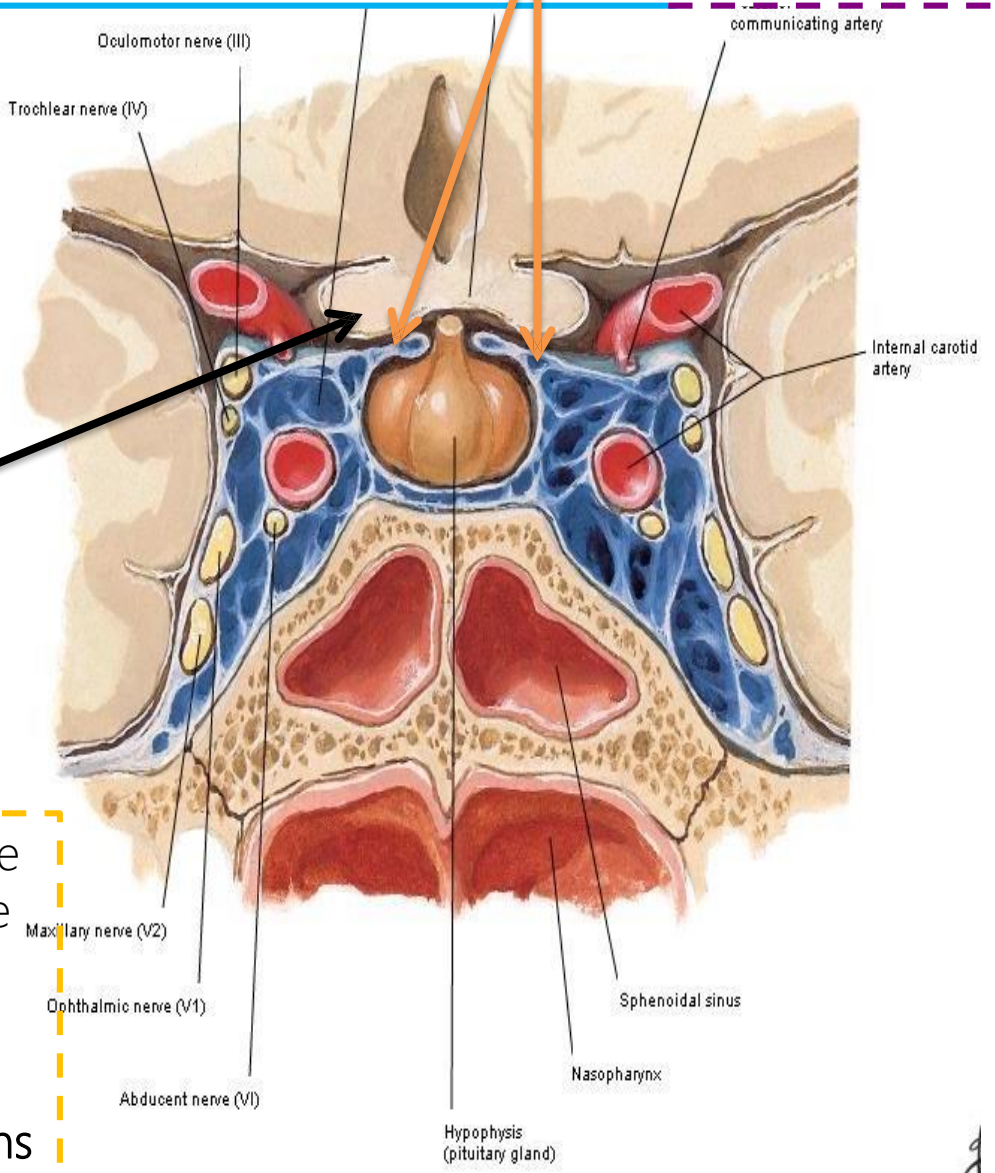

The pituitary gland is set in its own cavity,
above its closed by diaphragma sellae which is a fold of the dura mater septa.

The stalk that pierces the diaphragma sellae is the infundibulum, which connects the pituitary to the hypothalamus.

So the relation superiorly is the diaphragma sellae separating the pituitary gland from the optic chiasma.
Optic chiasma being the most important structure located superiorly

Laterally

- The hypophysis is bound on each side by **The cavernous sinuses** and the structures that they contain.

The cavernous sinus is there to **drain** the orbit and other nearby veins, into the jugular vein through other sinuses.
It's one of the most complicated sinuses in the cranial cavity, it lies under the brain
➲Used to be called no man's land because it was so hard to operate on and reach this sinus before.
It lies in the patheway of many structures coming from the brain strem towards the orbit (you know that), the temporal lobes limit the passage laterally, so there's no other option but to cross it. Which gives the sinus its clinical importance.

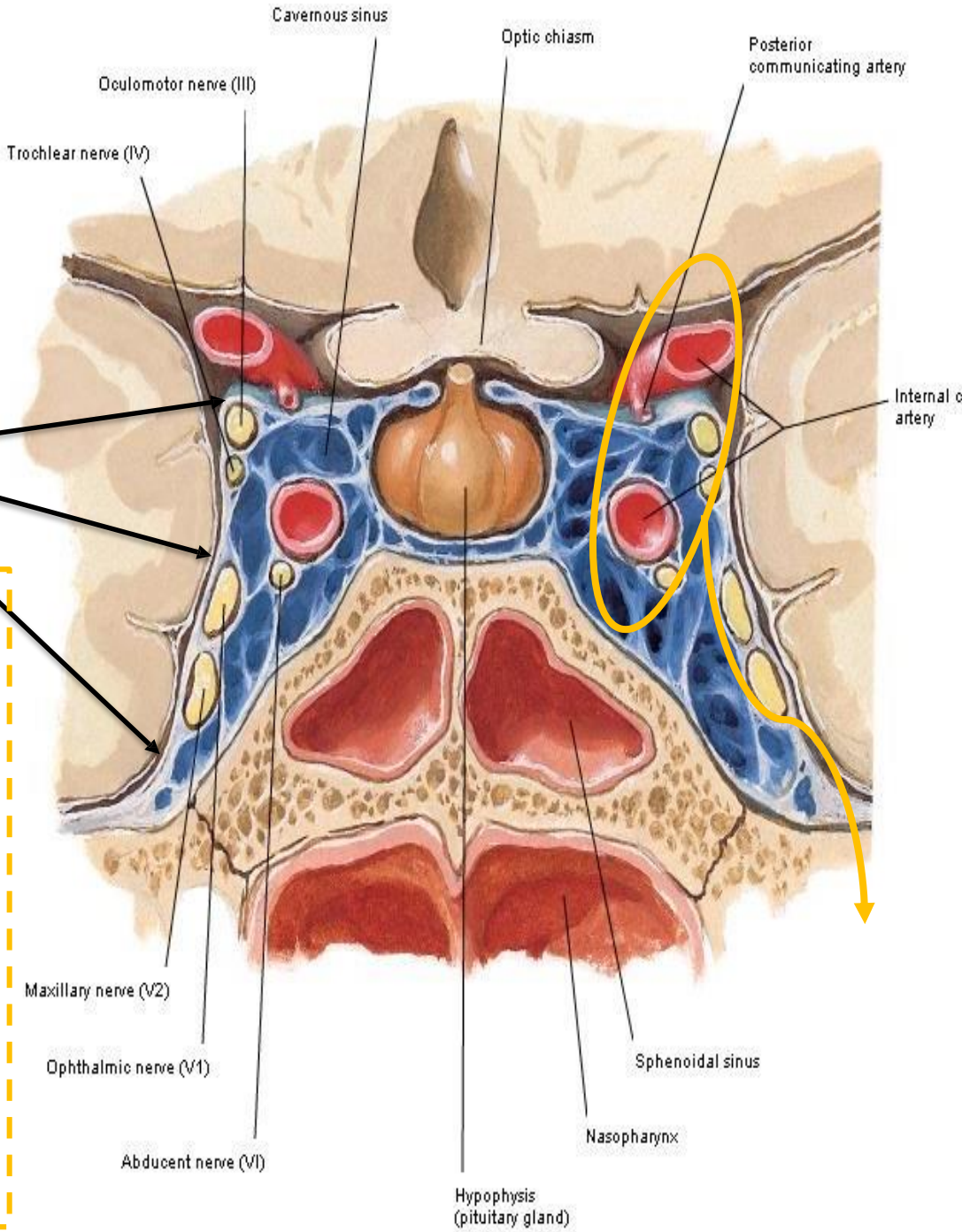

The cavernous sinuses

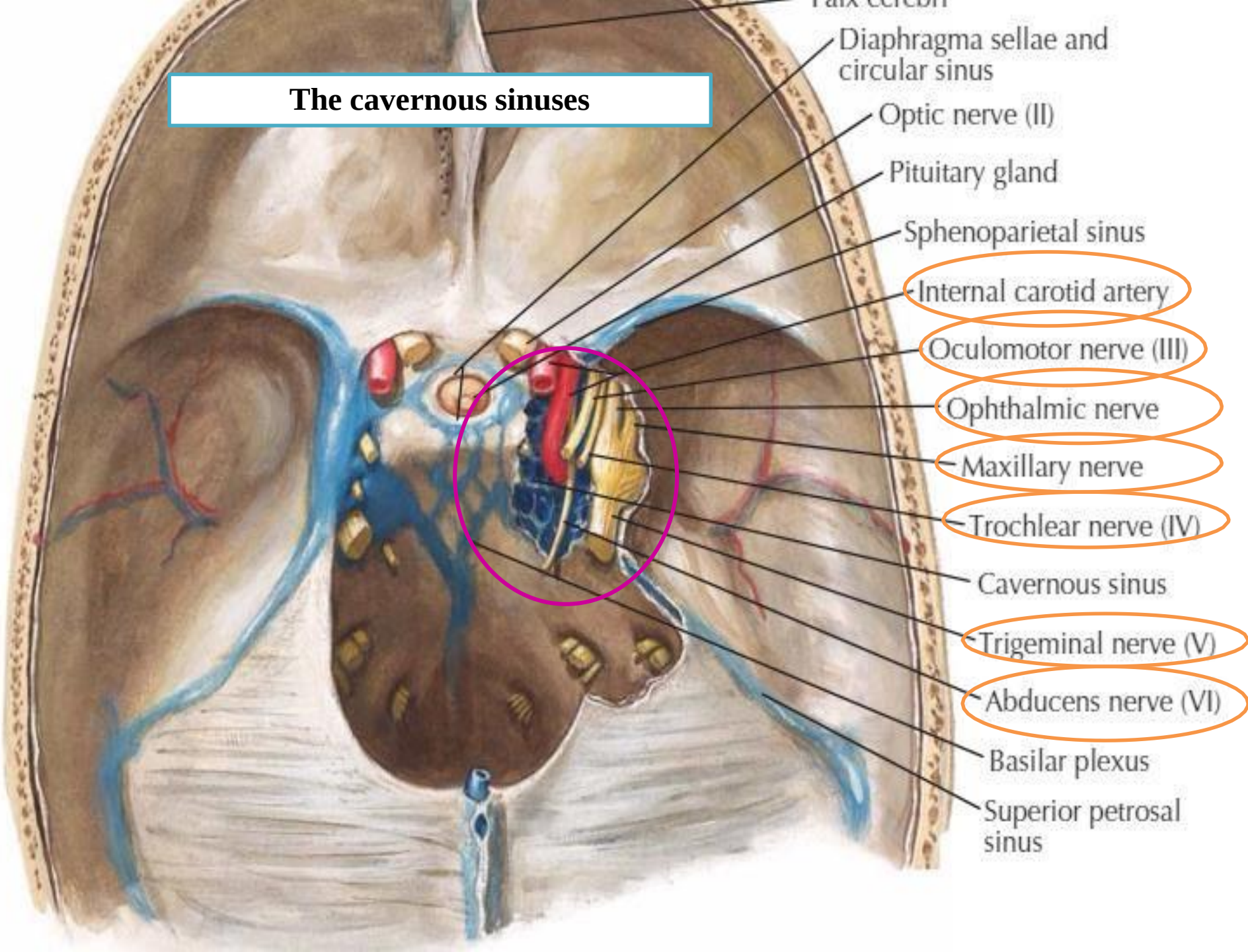

Structures Passing on lateral wall of the cavernous sinus

Cranial nerve number (3) oculomotor nerve

Cranial nerve number (4) Trochlear nerve

Divisions of Cranial nerve number (5) trigeminal nerve

Ophthalmic nerve

Maxillary nerve

Cavernous sinus is basically a pocket with walls, the lateral wall hosting many important cranial nerves

How about the mandibular nerve?

You don't see it because it immediately passes through foramen ovale

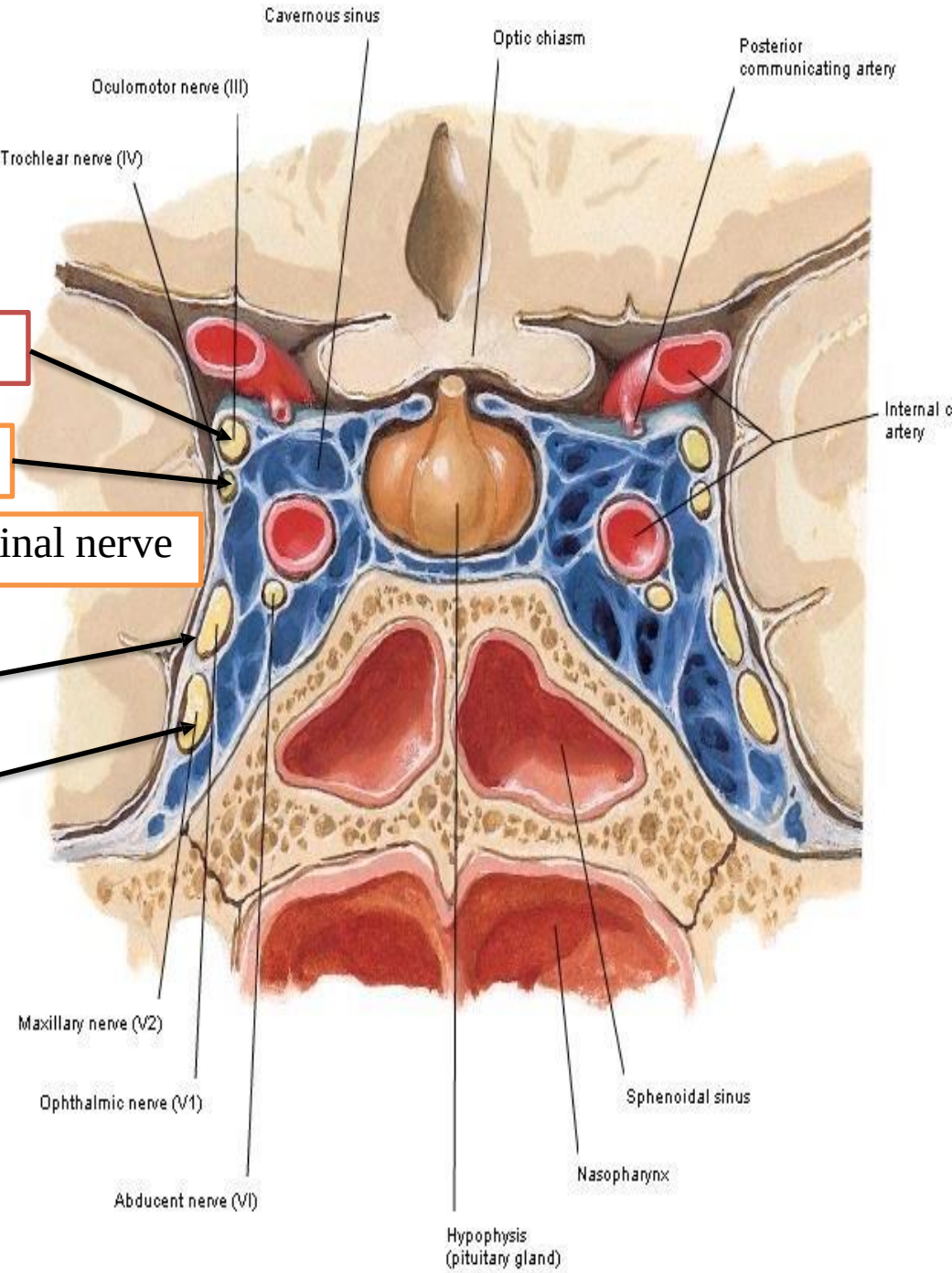

Structures inside the cavernous sinus

The internal carotid artery

The cranial nerve number (6) abducent nerve

It's more central than the other nerves

➲When we say **lateral**, it's important to appreciate the sinus AND what's passing through it

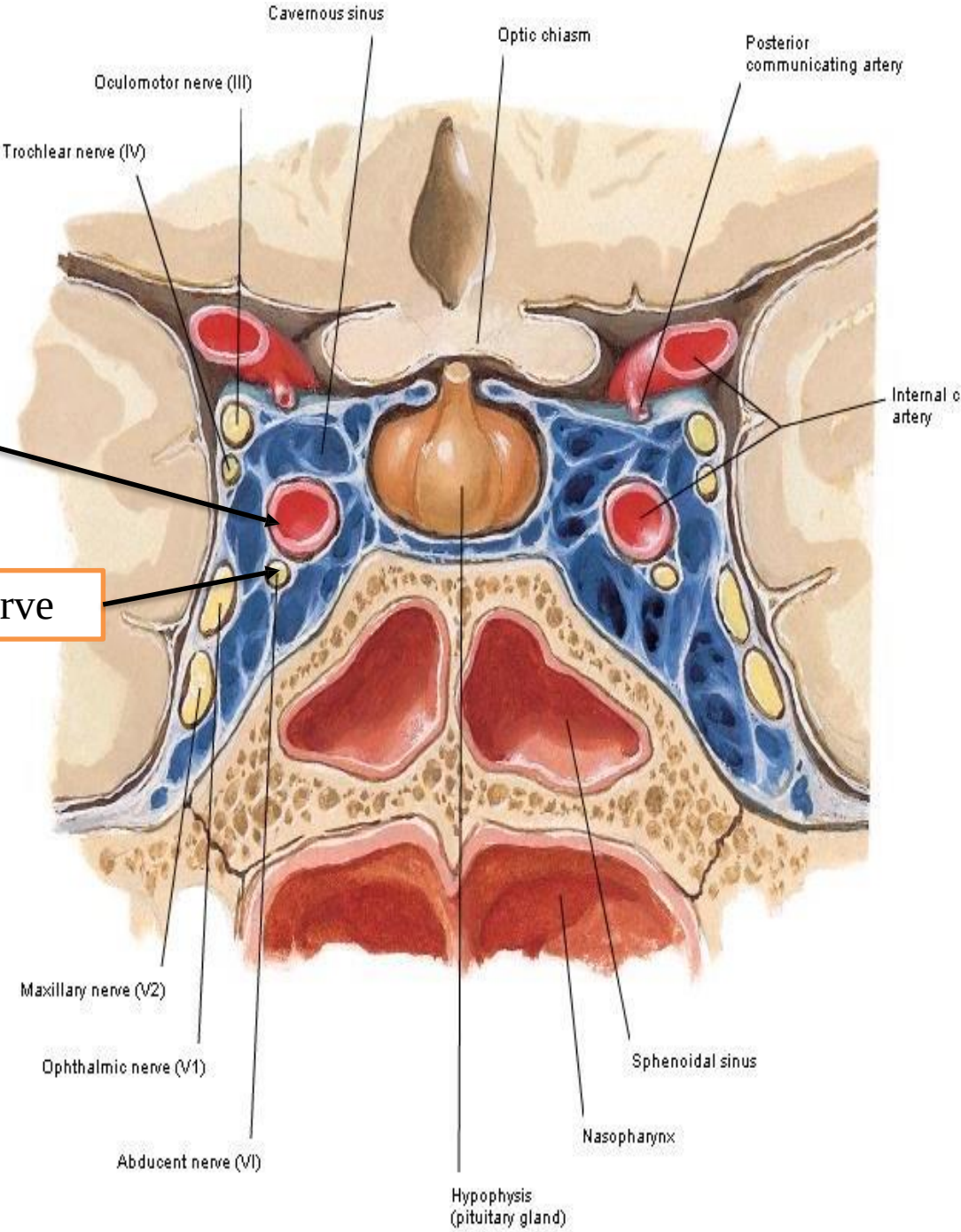

Inferiorly

- it is separated from the floor of the fossa by a large, partially vacuolated **venous sinus**

Although we said it sits on the sella turcica, the pituitary actually has a cushion made up by venous sinuses

The sphenoid air sinus

endoscopic transnasal applications in many pituitary surgical centers!!!!!

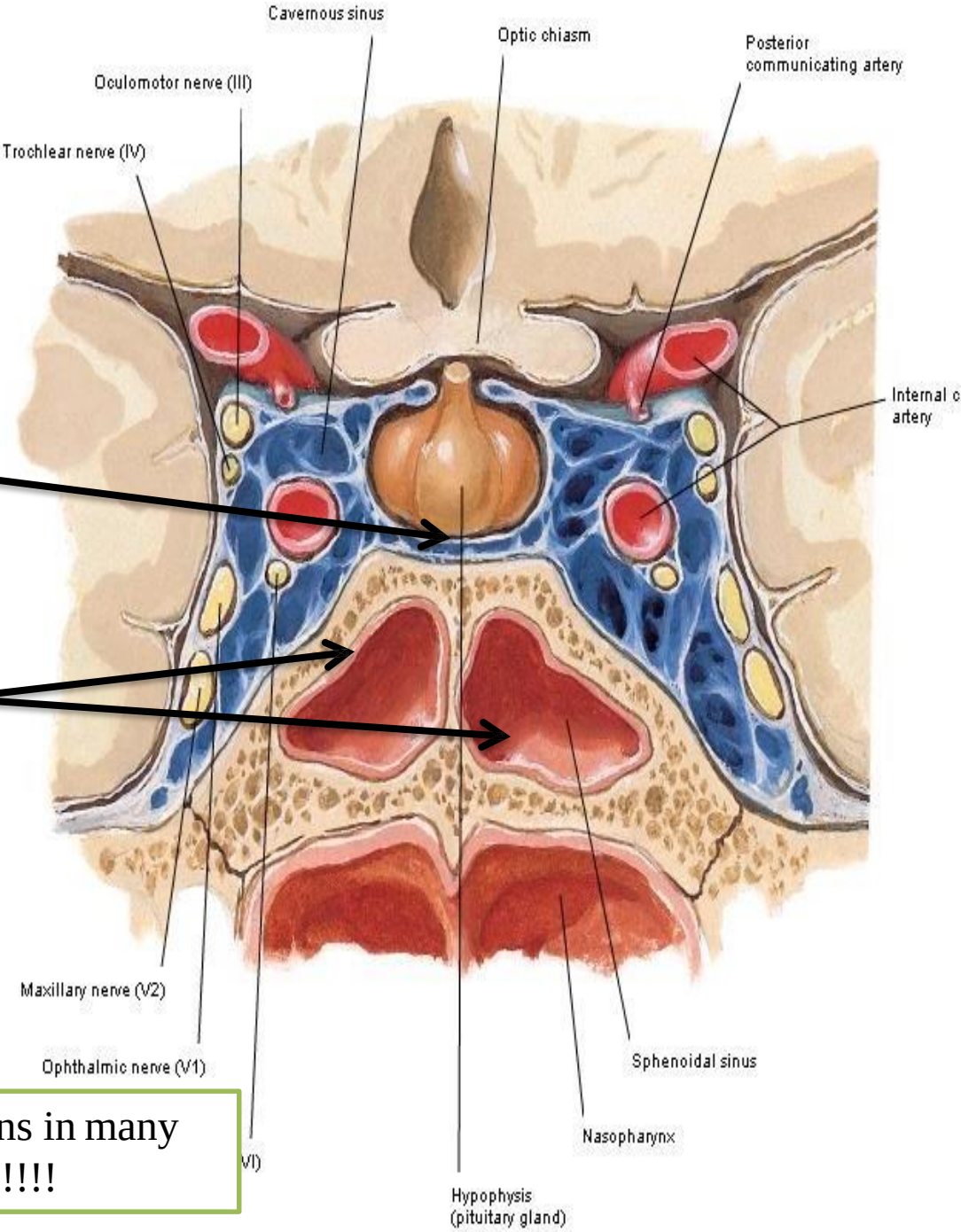

➲The pituitary gland is really delicate, so it's surrounded by diaphragma sellae, cavernous sinus and venous sinuses under it

However, bellow the venous sinus there is nothing but hard sphenoidal bone, which is the sella turcica (hypophysial fossa), the sphenoidal bone has sphenoidal air sinuses inside which we'll discuss next year in the RS.

So understand the location of the pituitary:

Above it's covered by soft structure (diaphragma sellae) and the optic chiasma of the brain

Below it's cushioned by the venous sinus and the sphenoidal sella turcica and air sinuses

Radiology

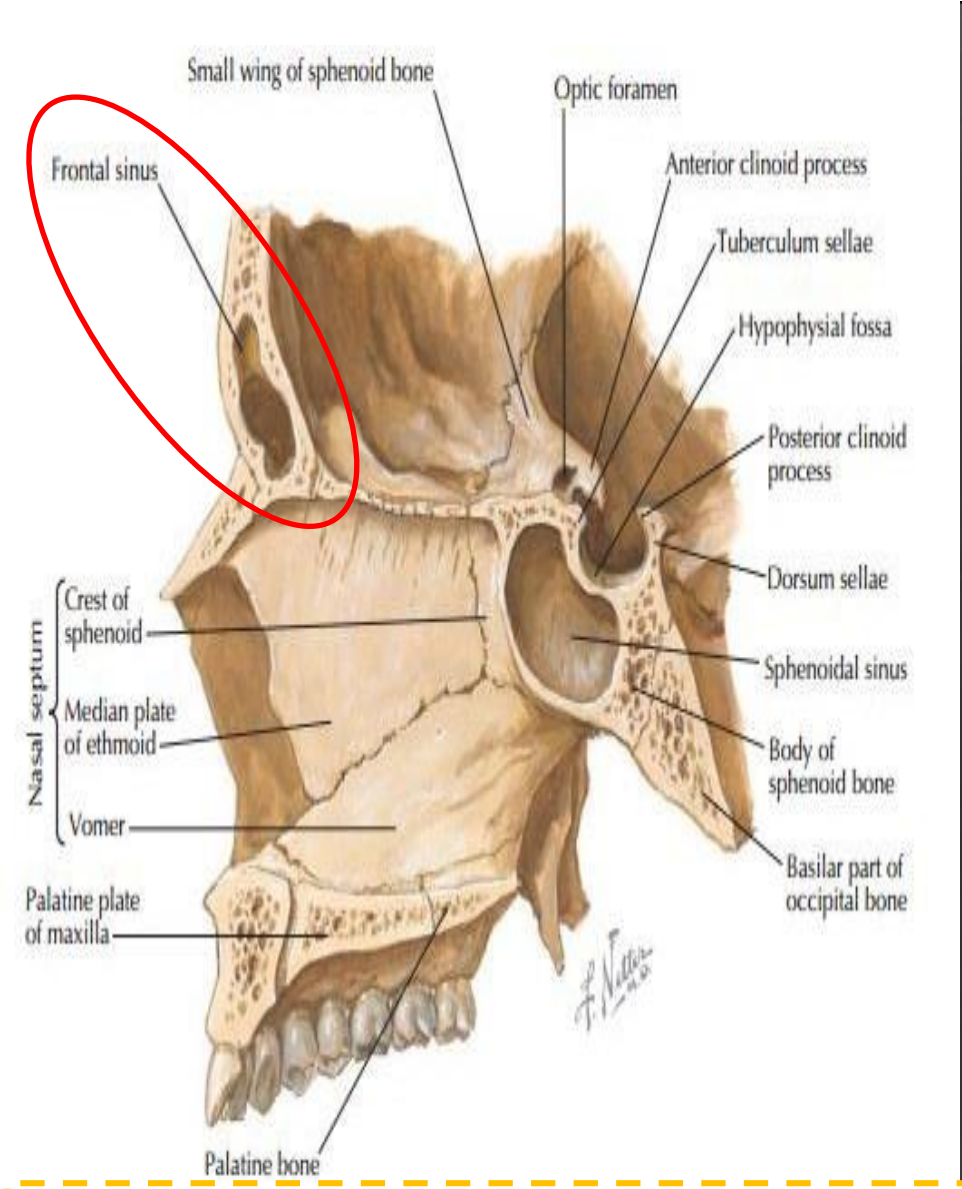

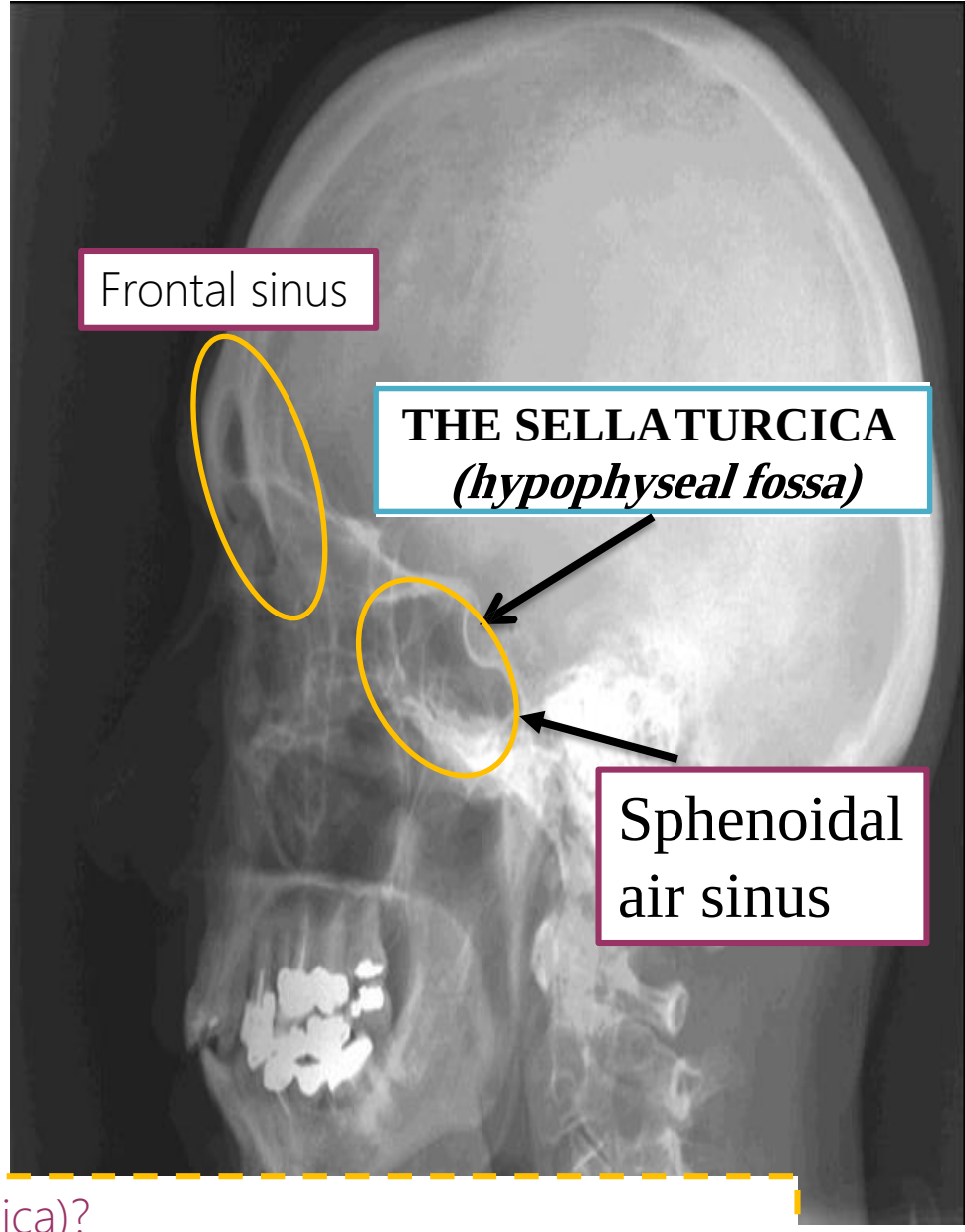

How to locate the hypophysial fossa (sella turcica)?

You locate the sphenoidal air sinus underneath it which would have a darker colour

The pituitary gland can commonly be affected by tumors, so its size and location (on the hypophysial fossa) should be appreciated.

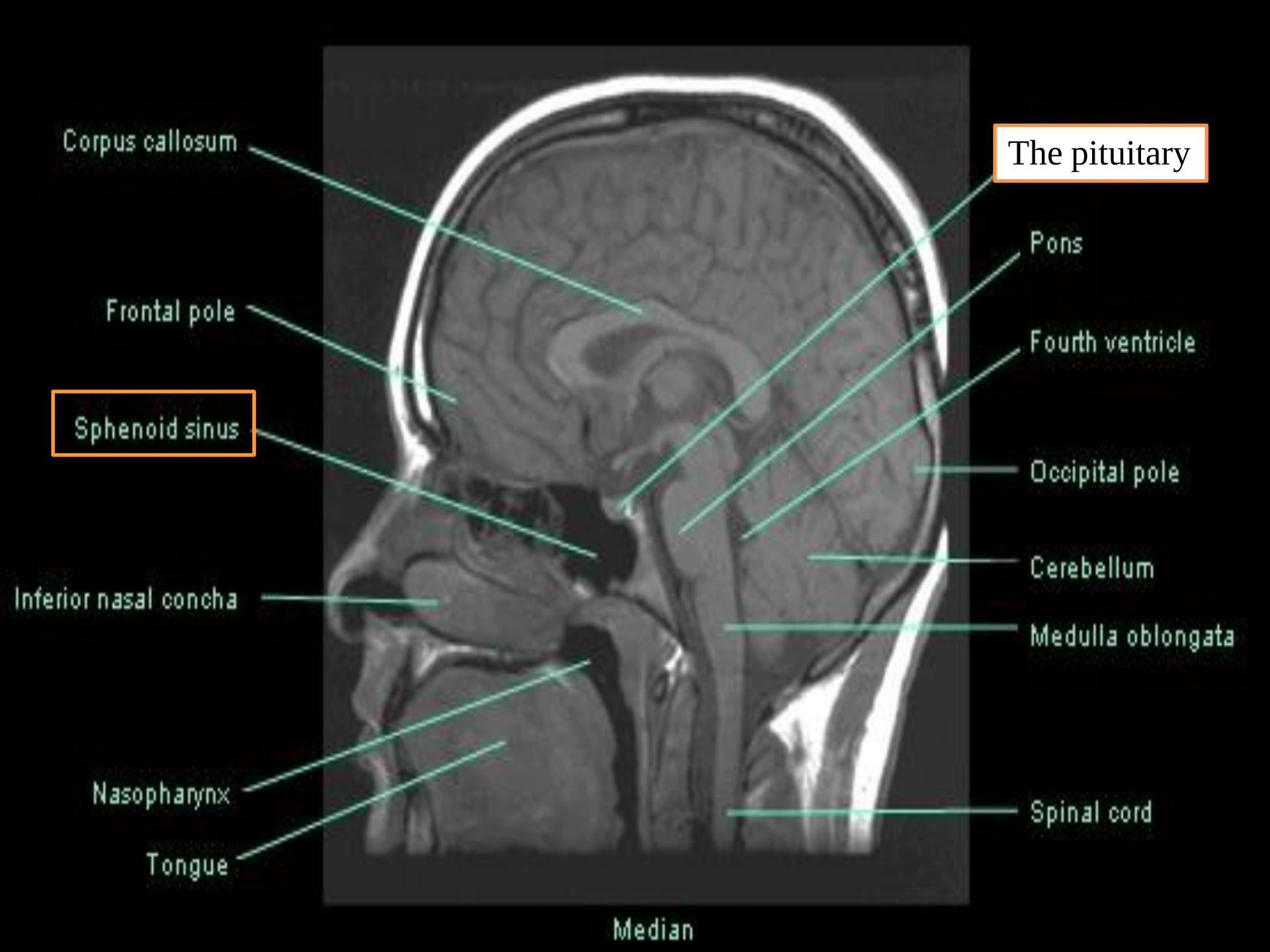
Corpus callosum
Frontal pole
Sphenoid sinus
Inferior nasal concha
Nasopharynx
Tongue
The pituitary
Pons
Fourth ventricle
Occipital pole
Cerebellum
Medulla oblongata
Spinal cord
Median

Trans-nasal surgery

Surgical approach

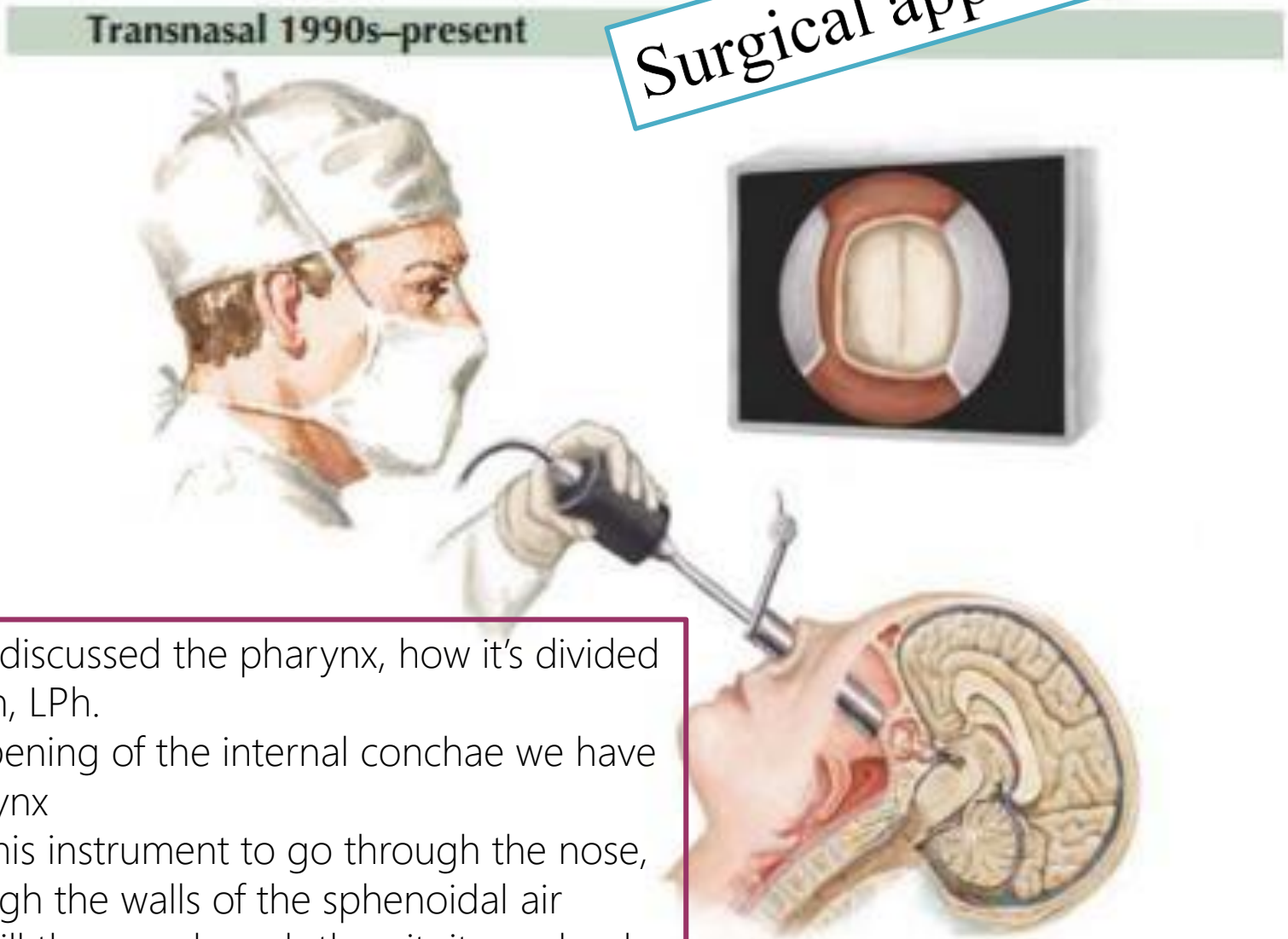

In the GIS we discussed the pharynx, how it's divided into NPh, OPh, LPh.
Behind the opening of the internal conchae we have the nasopharynx
So if we use this instrument to go through the nose, we'd go through the walls of the sphenoidal air sinuses, we drill there and reach the pituitary gland
This is the genius method that allowed us to reach that tiny area under the brain, the pituitary gland.

The pituitary gland is composed of two functional tissues

Neural (secretory) tissue
Posterior lobe
(**Neurohypophysis**)

Glandular epithelial tissue
The Anterior lobe
(**Adenohypophysis**)

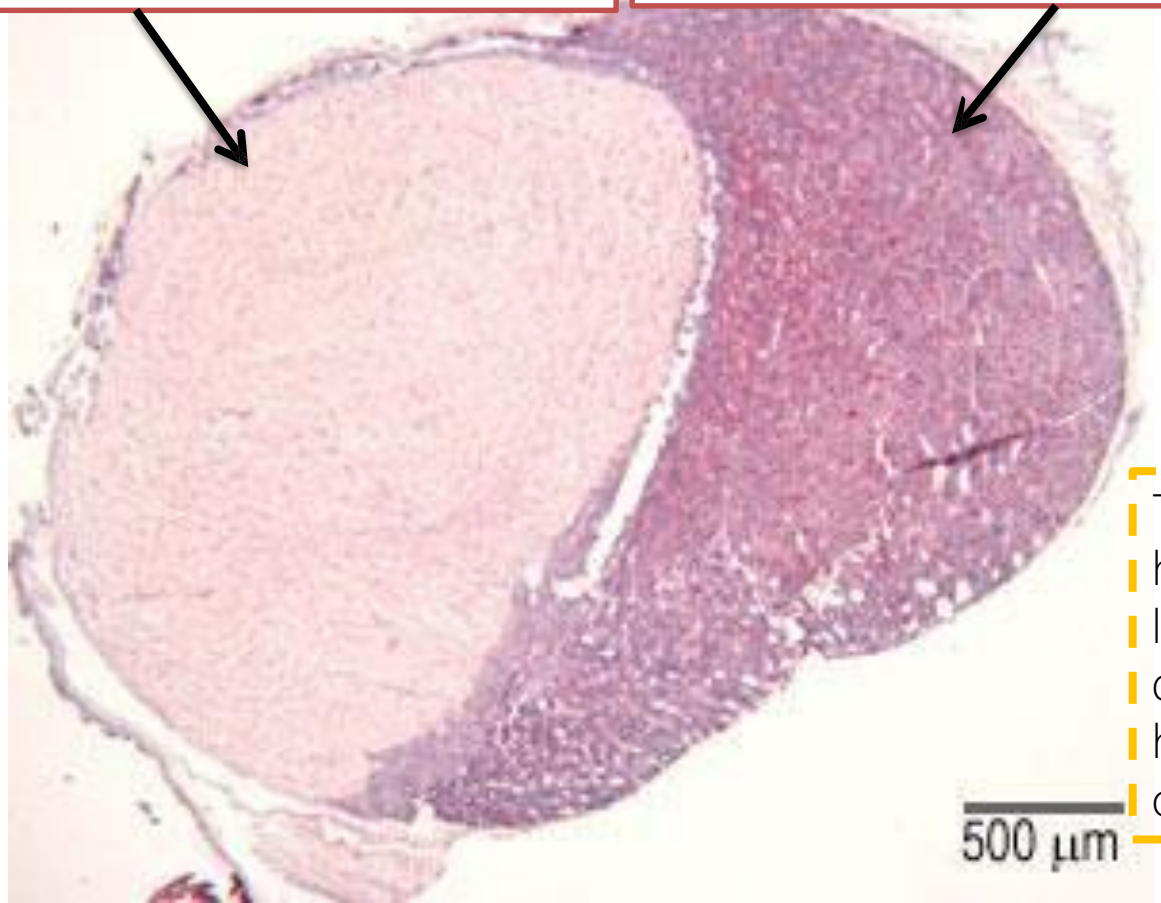

The pituitary has 2 distinct lobes that differ in histology and origin

Embryology

Important

Each endocrine gland has
<u>two different</u>
Embryological origins

And the pituitary gland is no exception, it has 2 different origins in terms of embryology

The two portions are of different embryologic origin

The anterior lobe of the pituitary gland is derived from an evagination of the **ectoderm** of the oropharynx toward the brain (superiorly, upgrowth)

we call it Rathke's pouch

The posterior lobe of the pituitaryis derived from **a downgrowth (the future infundibulum)**

neuroectoderm of the floor of the third ventricle (the diencephalon) of the developing brain

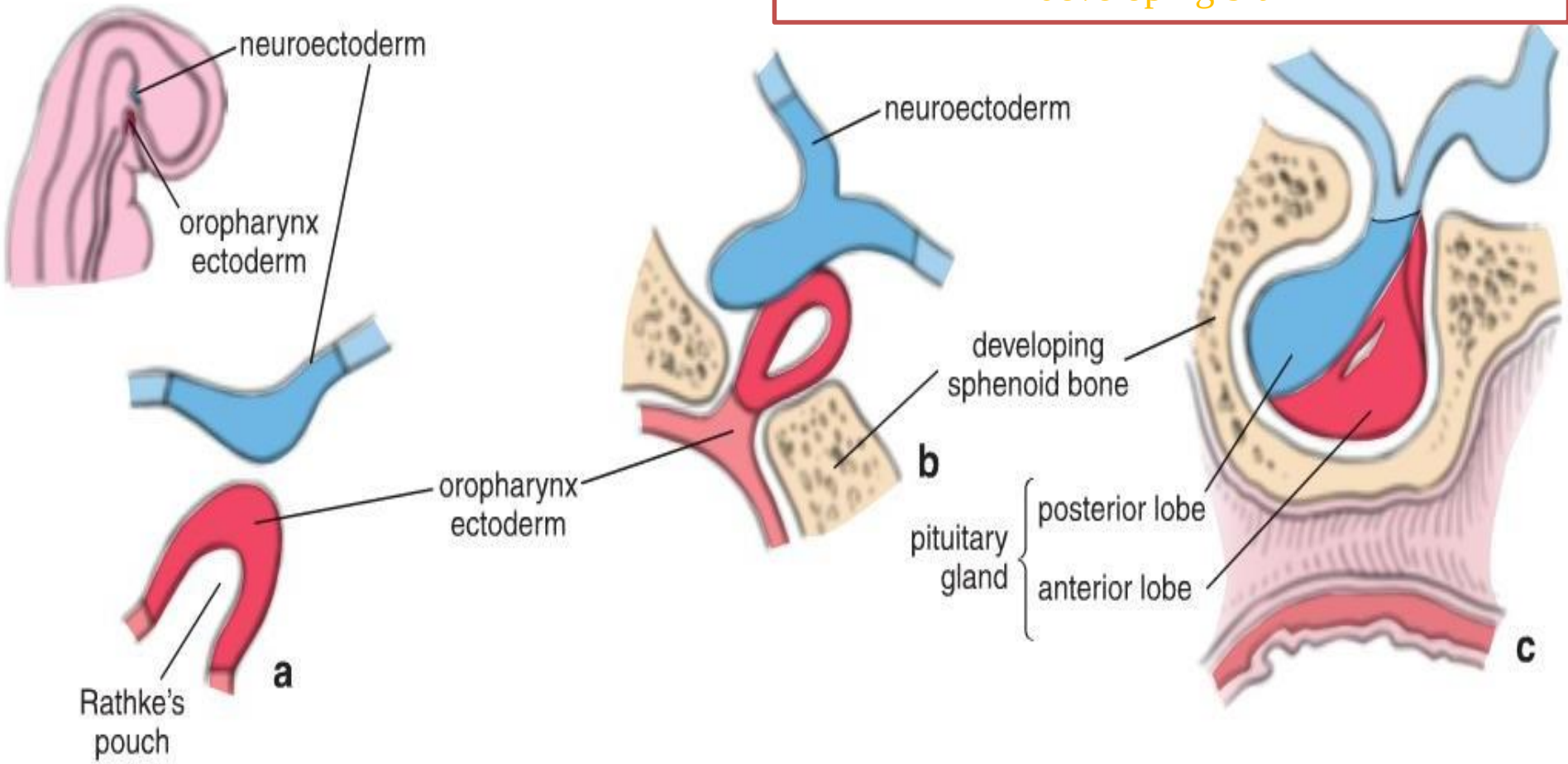

Origin of the neuorohypophysis?
Floor of the encephalon, neuroectoderm going down w/ no interruption

The posterior lobe,
From neuroectoderm of the embryonic infundibulum
neurohypophysis is related to our brain, it's part of it, and derived from the **downgrowth of the floor of the 3rd ventricle of the brain**
The posterior part never loses its connection with the hypothalamus. Anatomically, they're continuous.

Origin of the adenohypophysis?
Rathke's pouch,
Ectoderm from the oropharynx going up

The anterior lobe, adenohypophysis is epithelial in its characteristics, therefore it's derived from the ectoderm of the oropharynx in the embryo,
upgrowth of it
The anterior part (rathke's pouch) gets separated from the origin (Oph) by the fusion of the floor of the hypophysial fossa

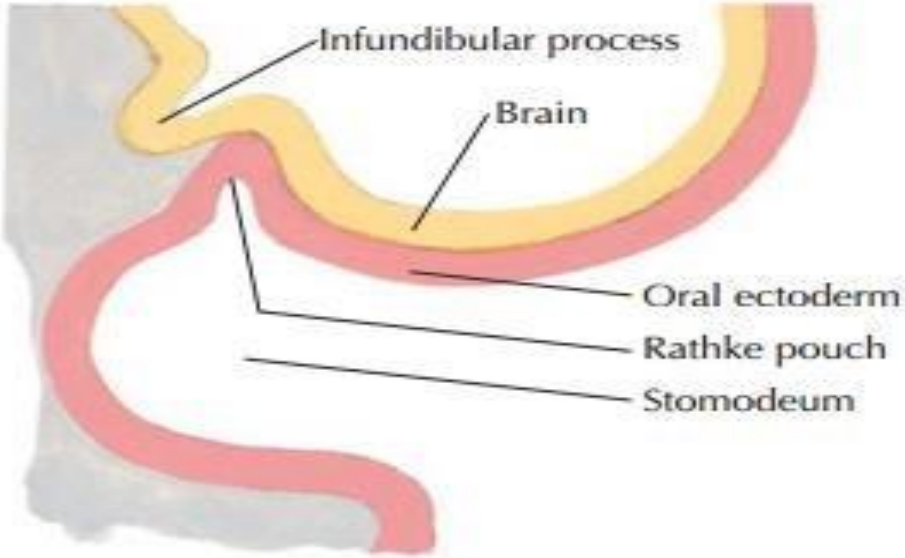

1. Beginning formation of Rathke pouch and infundibular process

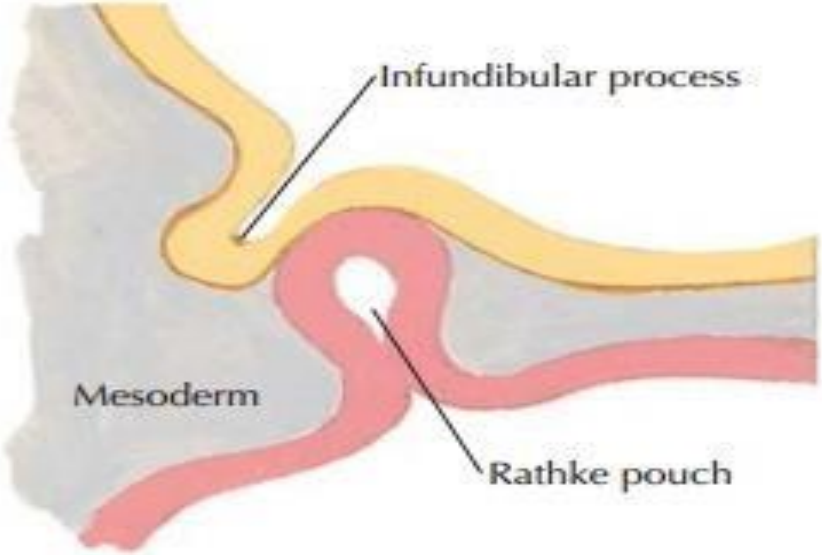

2. Neck of Rathke pouch constricted by growth of mesoderm

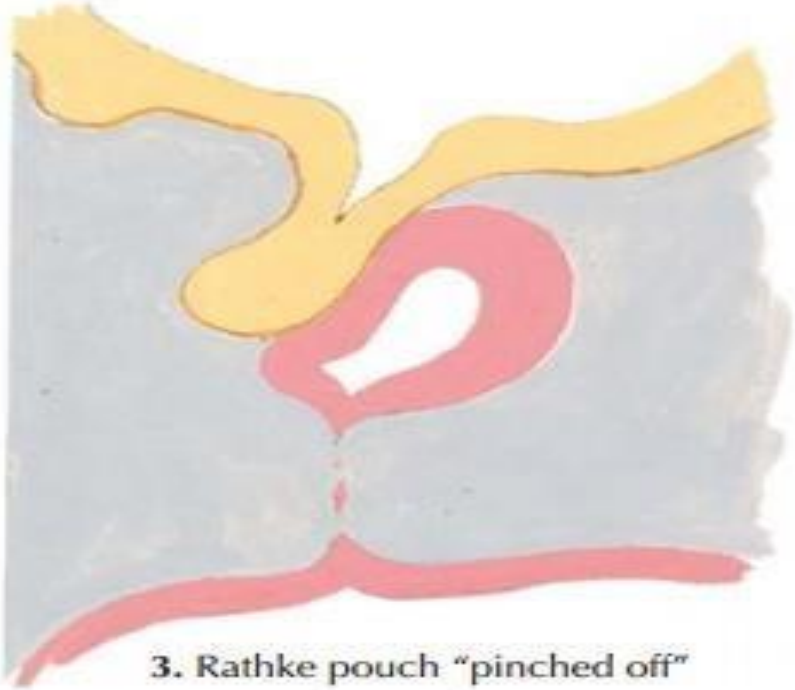

3. Rathke pouch "pinched off"

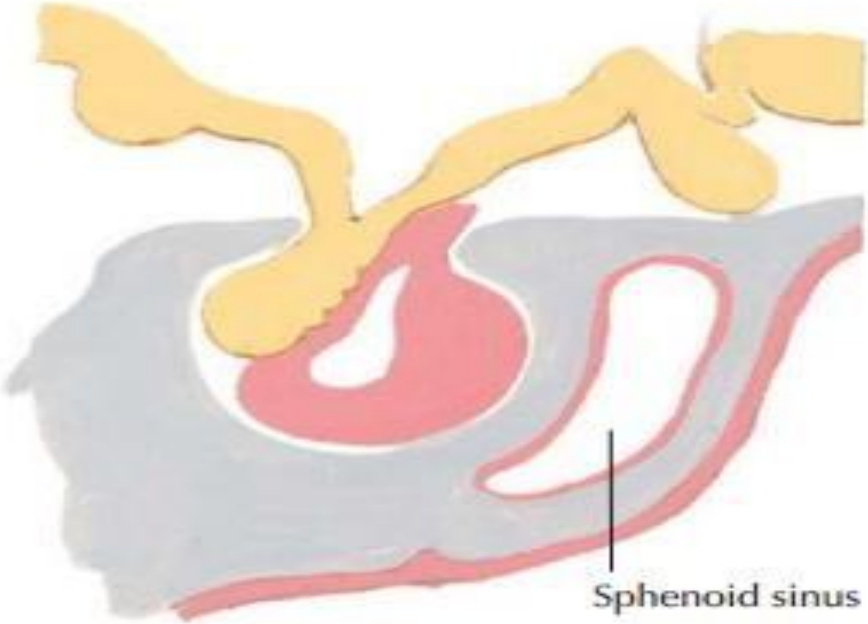

4. "Pinched off" segment conforms to neural process, forming pars distalis, pars intermedia, and pars tuberalis

Rathke's pouch surrounds the stalk of the pituitary gland here

5. Pars tuberalis encircles infundibular stalk (lateral surface view)

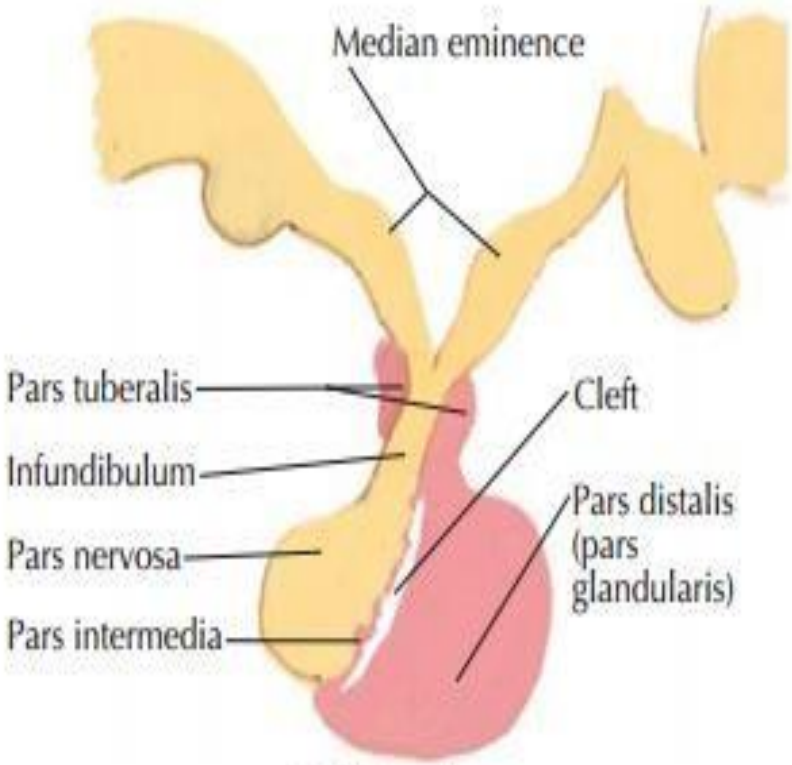

6. Mature form

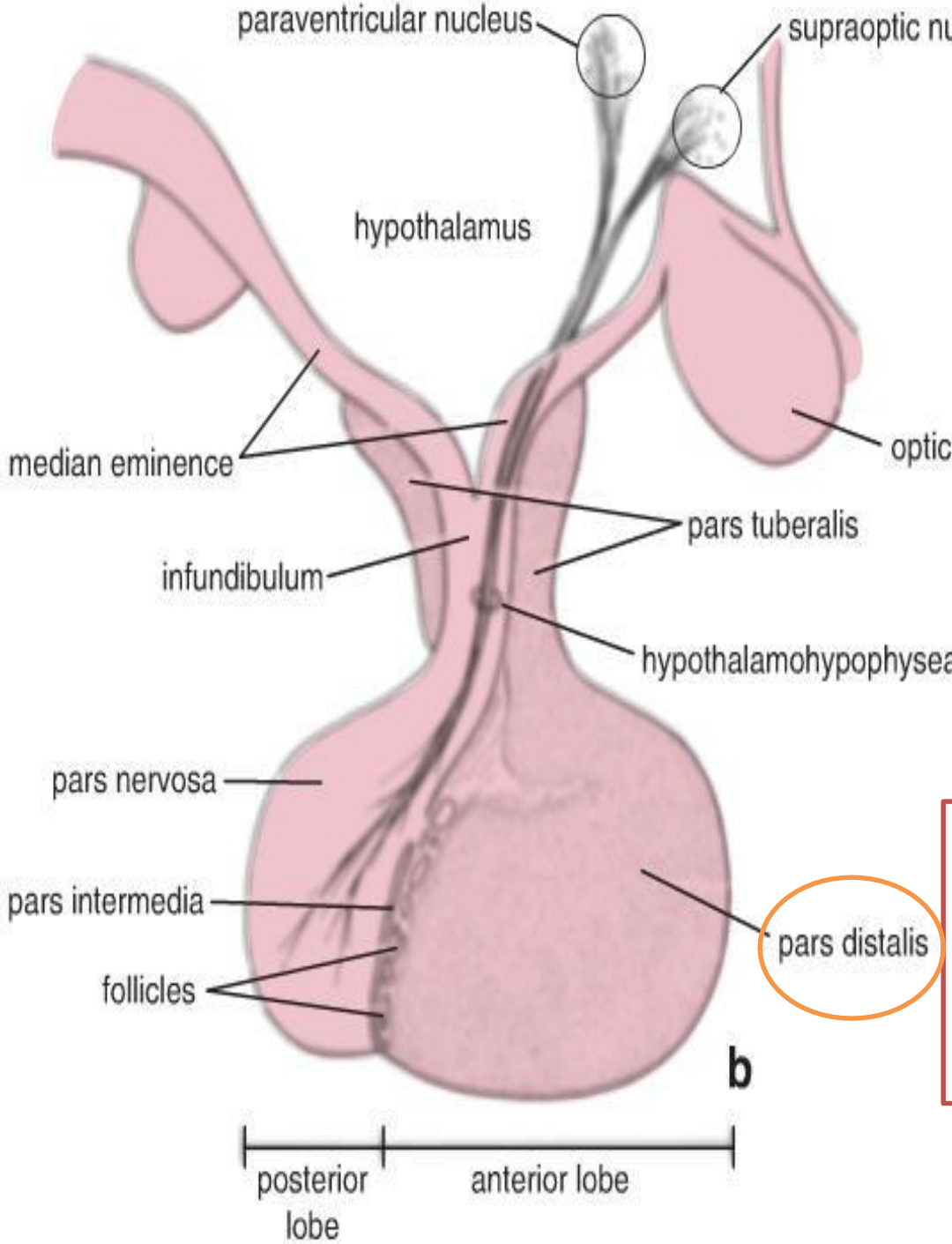

The anterior lobe (adenohypophysis) of the pituitary gland consists of three derivatives of

Rathke's pouch:

1-Pars distalis

which comprises the bulk of the anterior lobe of the pituitary gland and arises from the thickened anterior wall of the pouch

It **is not part** of the pituitary gland

The **median eminence** is part of the **hypothalamus** from which regulatory hormones are released

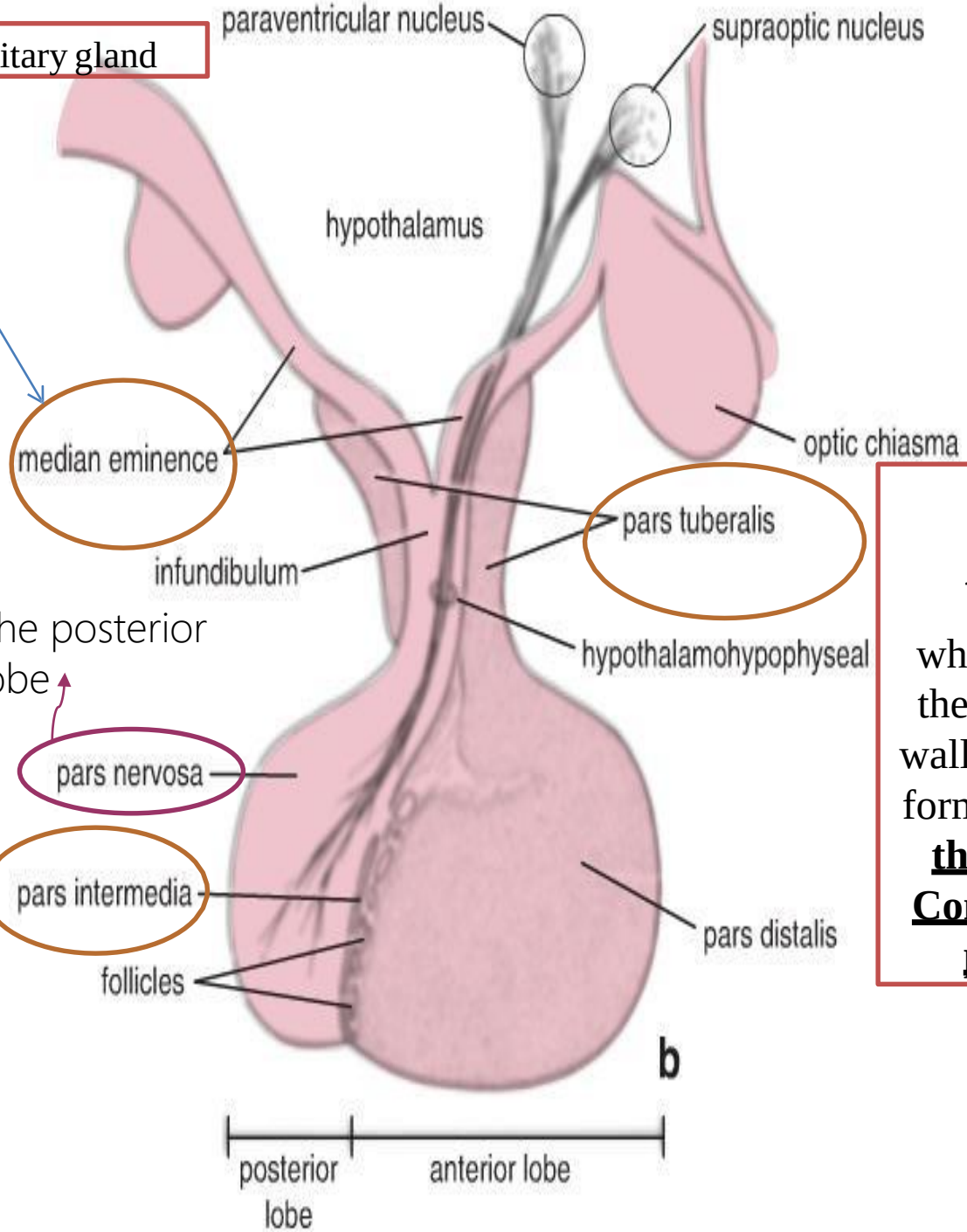

The posterior lobe

2-Pars intermedia
a thin remnant of the posterior wall of the pouch

3-Pars tuberalis
which develops from the thickened lateral walls of the pouch and forms a sheath around **the infundibulum**
Coming towards the posterior part

From the floor of the dienecephalon the **embryonic infundibulum** emerges and gives rise to **the posterior lobe** of the pituitary gland

Infundibulum, which is a continuation of the median eminence and contains the **neurosecretory axons forming the**

hypothalamohypophyseal tracts

There's an anatomical connection between the medial eminence of the hypothalamus and the posterior lobe, permeating the delivery of signals from the hypothalamus to the pituitary

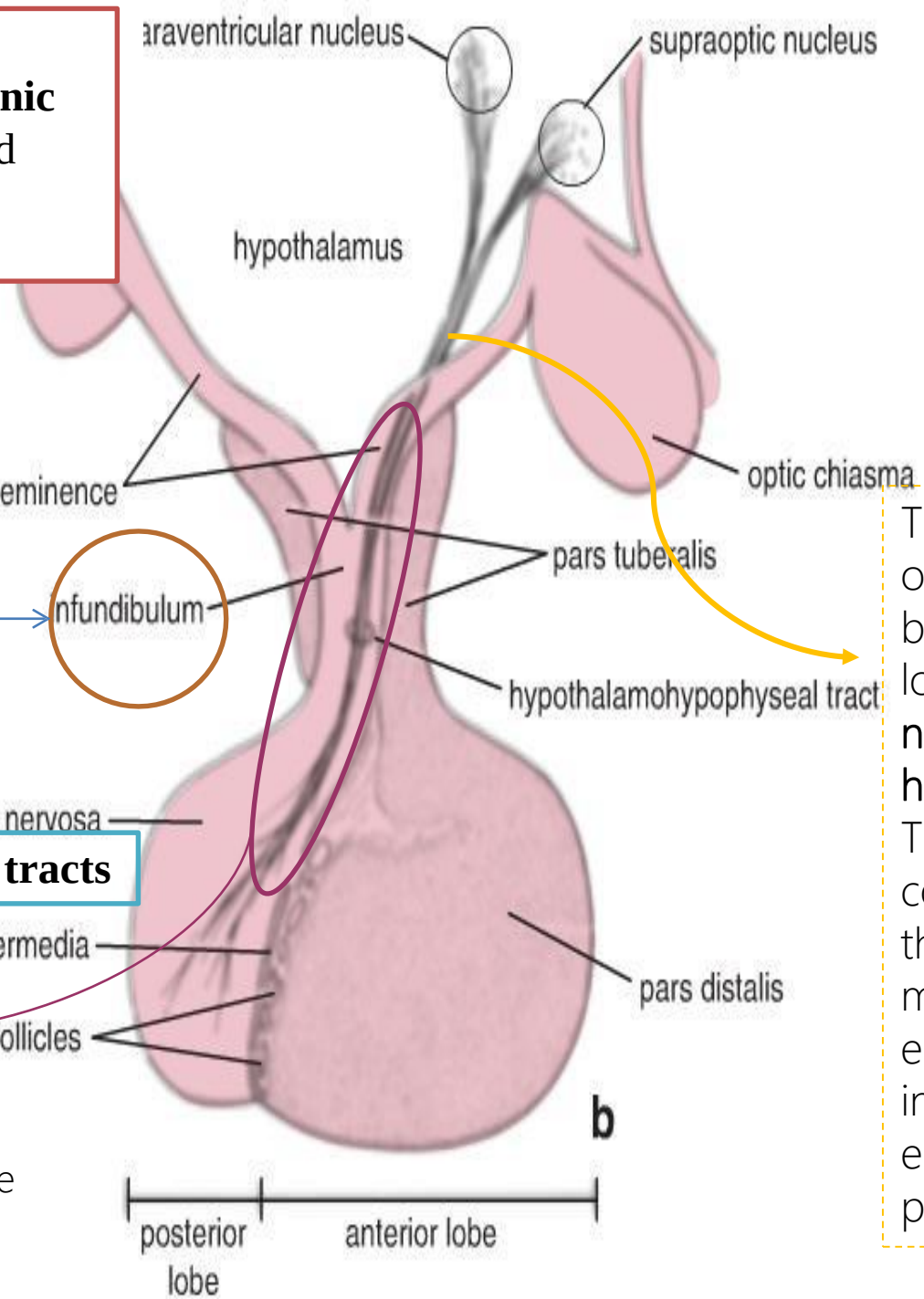

These are axons, of cells whose bodies are located in the **nuclei of the hypothalamus**. These axons are continuous through the median eminence, the infundibulum, ending in the posterior lobe

<u>The posterior lobe</u> consists of the following:

- **Pars nervosa,** which contains neurosecretory axons and their endings

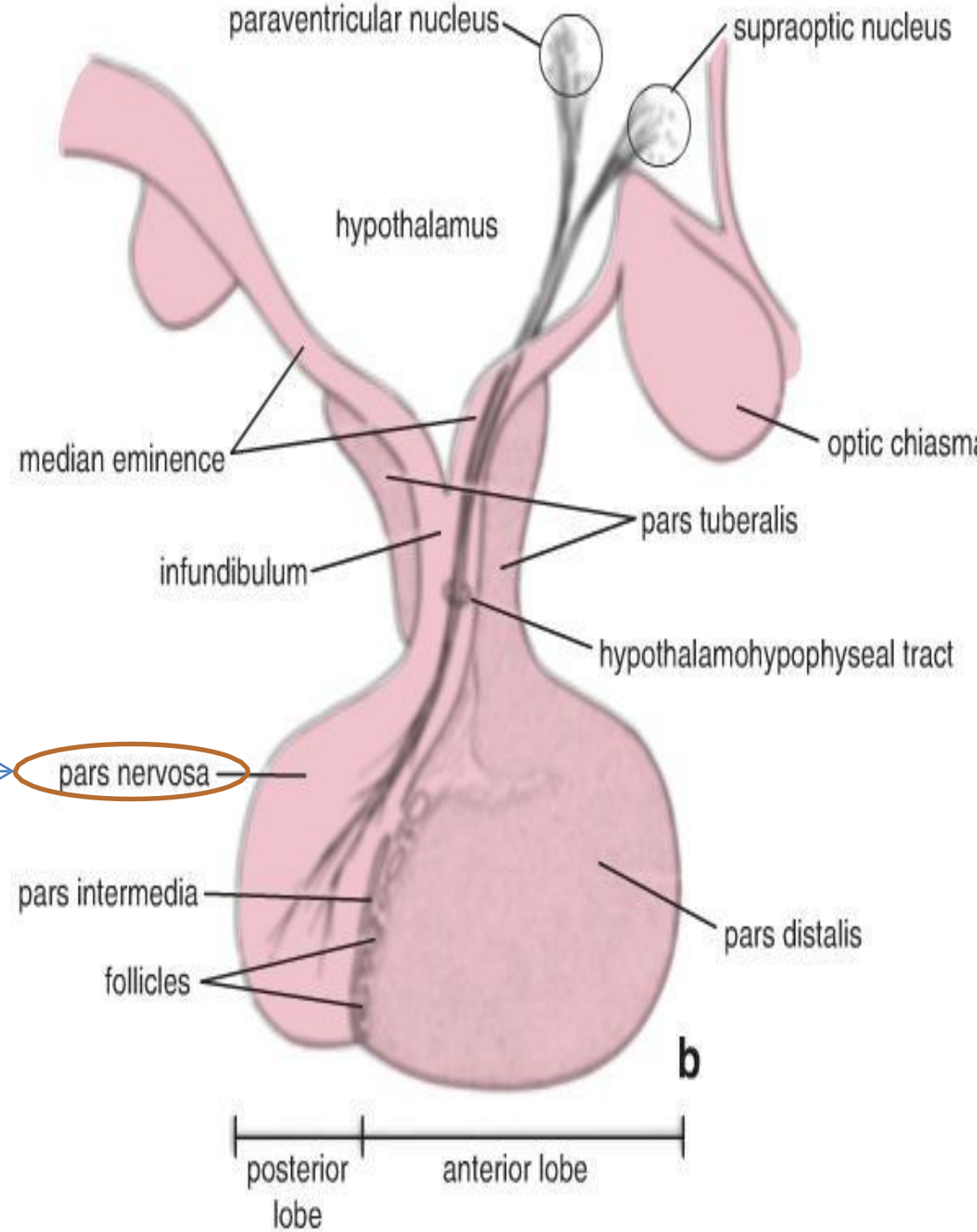

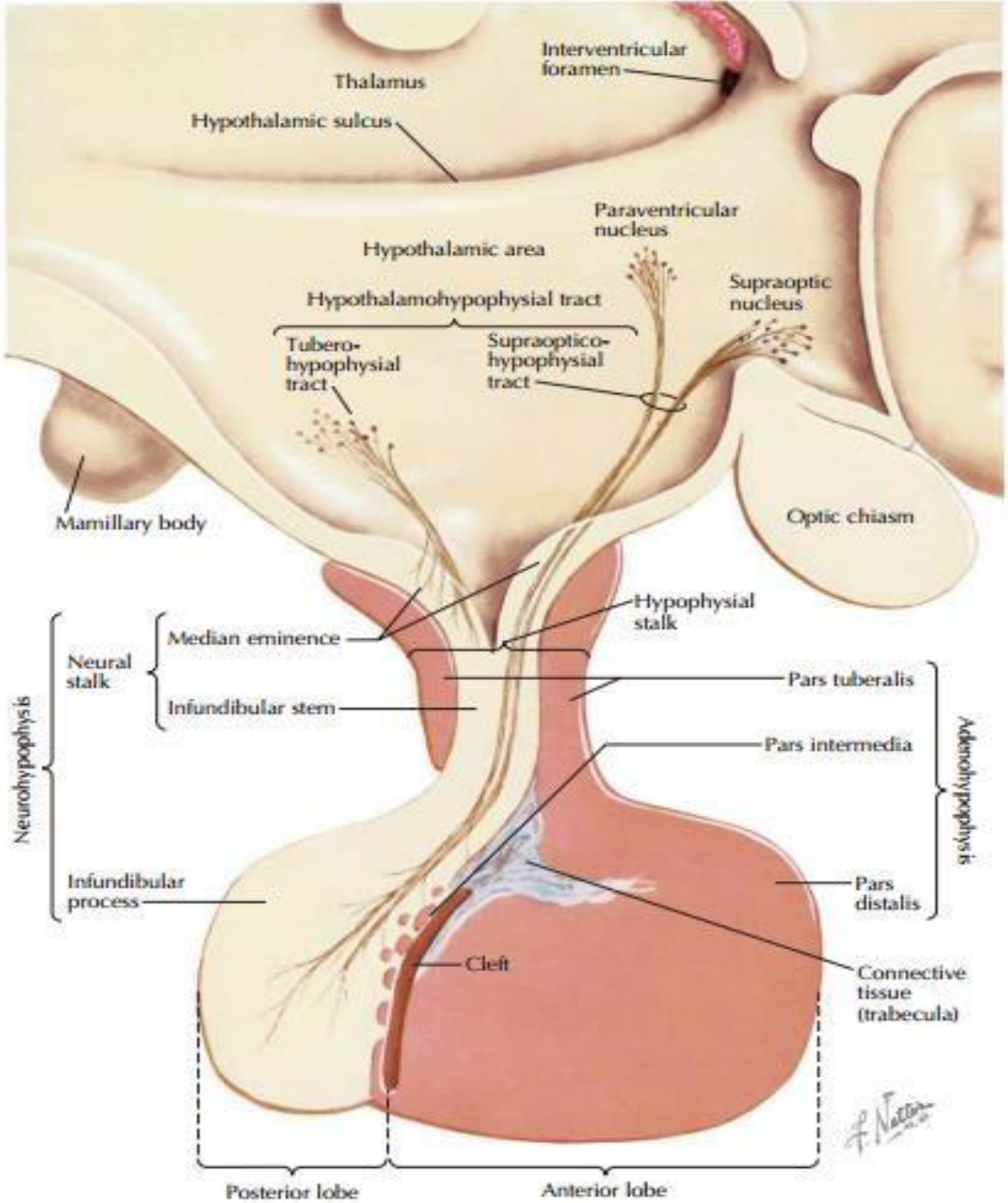
Interventricular foramen
Thalamus
Hypothalamic sulcus
Paraventricular nucleus
Hypothalamic area
Supraoptic nucleus
Hypothalamohypophysial tract
Tubero-hypophysial tract
Supraoptico-hypophysial tract
Mamillary body
Optic chiasm
Hypophysial stalk
Median eminence
Neural stalk
Infundibular stem
Pars tuberalis
Pars intermedia
Neurohypophysis
Adenohypophysis
Infundibular process
Pars distalis
Cleft
Connective tissue (trabecula)
Posterior lobe
Anterior lobe