

Endocrine PATHOLOGY

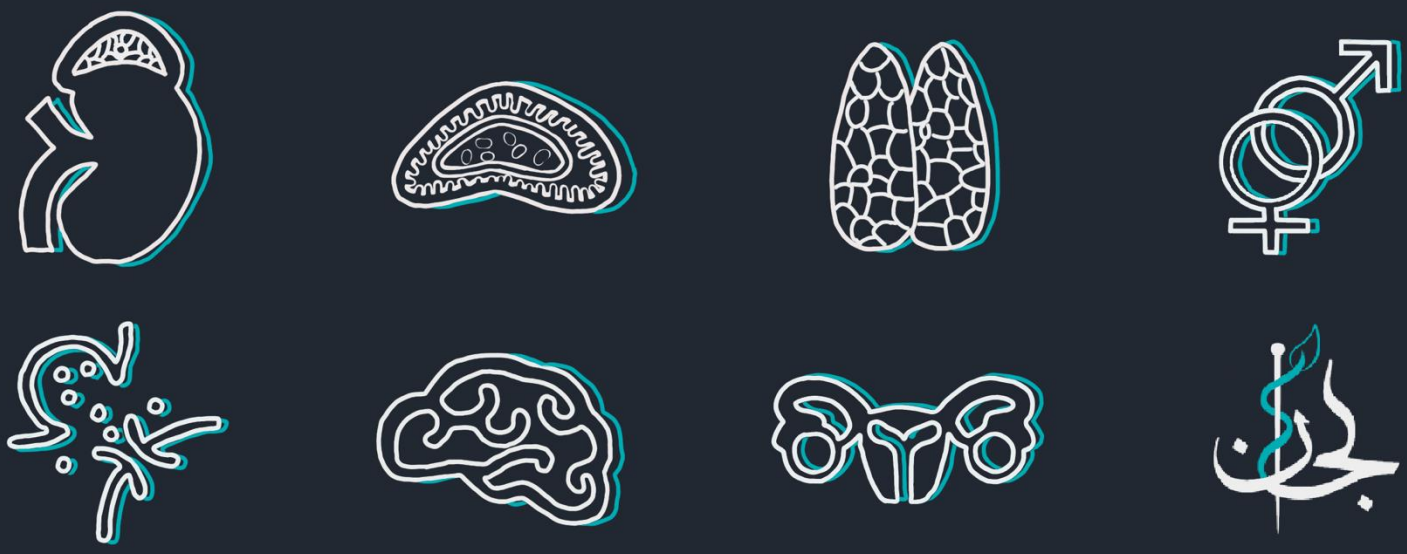

Title: Sheet 1 – Diseases of the Pituitary Gland: Part 1

Writer: Dena Kofahi and Bita Bakhtyar

Science: Sara Rahhal

Grammar: Lana Mango

Doctor: Dr. Fatima Obeidat

The endocrine system is made of highly integrated and widely distributed organs called endocrine glands. The goal of theses glands is to reach a metabolic state of equilibrium and they do so by secreting hormones.

General Principles of Endocrine System Diseases (1:00-2:46)

1) Mass effect

Mass effect means an enlargement of the gland which can compress adjacent structures. For example, pituitary gland diseases, like pituitary adenomas (benign), might compress adjacent normal tissue and cause a decrease in its hormonal secretion. This condition is called hypopituitarism.

Mass effect can be due to:

1. Neoplastic conditions: such as adenomas (benign) and carcinomas (malignant).
2. Non-neoplastic conditions: such as hyperplasia. Hyperplasia is characterized by an increased number of cells in a particular organ.

2) End organ resistance

End organ resistance is another endocrine disease. End organ resistance means that the gland is secreting the normal amount of hormone, but the target organ is not responding to it. As the name suggests, the end organ has resistance to the hormone. For example, the endocrine gland of the pancreas secretes insulin but the target tissues (adipose cells and skeletal muscle cells) are unresponsive to insulin. This occurs in type 2 diabetes, leading to hyperglycemia.

Now that we have an idea about the general principle let's get more specific:

The Pituitary Gland (2:47-3:54 and 4:39-5:53) (الْغُدَّة النُّخَامِيَّة)

The pituitary gland is also called the orchestra maestro, as it controls the levels of hormones secreted from all other endocrine glands. The pituitary gland is a small, bean shaped structure that lies at the base of the brain within the sella turcica. Examples of hormones secreted from the pituitary gland include the thyroid stimulating hormone and growth hormones.

WHAT IS THE SELLA TURCICA? (اَلسَّرْجُ التُّرْكِيُّ)

The sella turcica (latin for turkish seat) is the pitutary fossa and is a saddle-shaped depression in the body of the sphenoid bone of the skull. (blue arrow in the picture below)

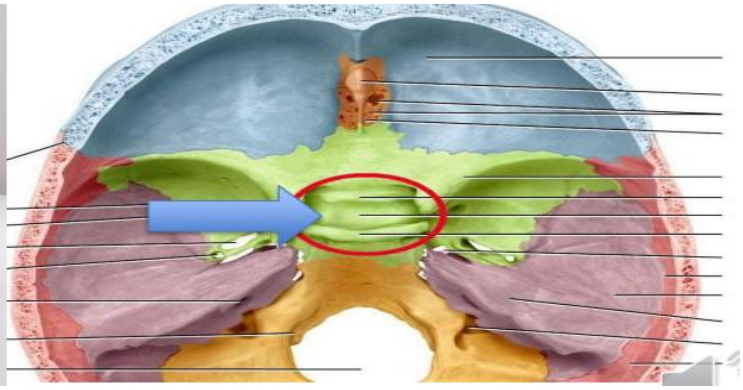

The question is what controls the pituitary gland? The hypothalamus!

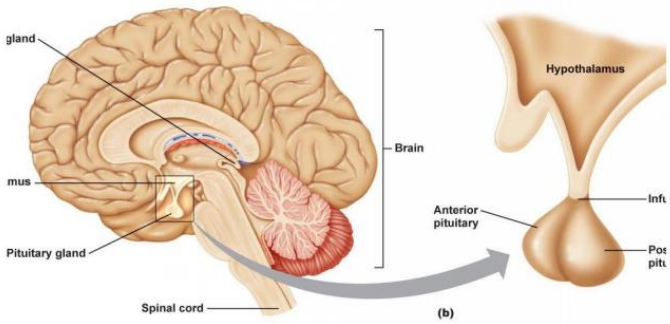

The Hypothalamus (3:55-4:39 and 5:54-7:01) (تحت المهاد)

The hypothalamus is located above the pituitary gland. It controls the secretions of the pituitary gland (either the anterior or posterior lobe). The hypothalamus secretes hormones like the corticotropin releasing hormone which controls the secretion of the adrenocorticotropic hormone (ACTH) from the anterior lobe. Additionally, the hypothalamus synthesizes hormones such as ADH and oxytocin which are stored in the posterior pituitary gland.

How does the hypothalamus control the pituitary gland?

The production of most pituitary hormones is controlled by

1. Positively acting factors – An example is corticotropin releasing hormone which increases the release of ACTH.
2. Negatively acting factors - Dopamine inhibits the secretion of prolactin from the anterior pituitary gland.

These factors are carried to the anterior pituitary gland by a portal vascular system.

The Pituitary Gland (continued) (7:02-12:50)

The pituitary gland is composed of two morphologically and functionally distinct components:

1. **The Anterior Lobe (Adenohypophysis)**

- The anterior lobe is known as the adenohypophysis because it is made of epithelial cells.
- The function of the anterior pituitary gland is synthesizing and releasing trophic hormones such as TSH, FSH, ACTH, PRL, and GH.
- The anterior lobe constitutes about 80% of the pituitary gland.
- It is composed of three different types of epithelial cells:
    - Acidophilic cells - Have pink cytoplasm.
    - Basophilic cells – Have blue cytoplasm.
    - Chromophobe cells – The cytoplasm's color is between blue and pink.

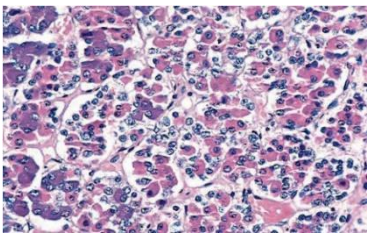

2. **The Posterior Lobe (Neurohypophysis)**

- The posterior lobe is called the neurohypophysis because its histology is similar to that of the brain. It consists of modified glial cells (pituicytes) (similar to those in the brain) and axonal processes extending from the hypothalamus through the pituitary stalk to the posterior lobe (axon terminals).
- It is derived from the neural crest.
- The posterior pituitary stores and secretes oxytocin and antidiuretic hormone (ADH, also called vasopressin).
- These hormones are actually synthesized in the hypothalamus and stored within the axon terminals of the posterior pituitary gland.

<u>Anterior vs. Posterior Pituitary Lobes</u>

	Anterior pituitary	**Posterior pituitary**
Histology	**Epithelial cells**	**Glial cells (pituicytes) and neural axons**
Embryological origin	**Derived from Oral mucosa**	**Derived from Neural crest**
Hormones secreted	**TSH, PRL, ACTH, GH, FSH, LH**	**ADH and oxytocin (synthesized in hypothalamus but stored in the posterior pituitary.**

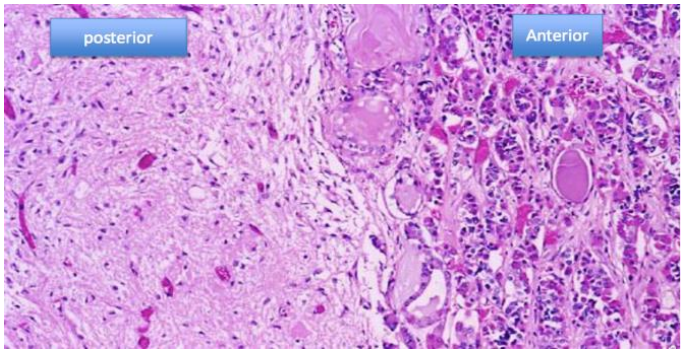

Diseases of the Anterior Pituitary Gland

Masses and the Mass Effect (12:51 – 14:16)

- The mass effect can be produced by masses that affect the pituitary gland: adenomas or carcinomas.
    - i. Adenomas are benign tumors – More common than carcinomas.
    - ii. Carcinomas are malignant tumors – Rare and usually non-secretory.
- Adenomas can be secretory (they secrete one of the anterior pituitary hormones). In this case the level of that hormone will increase causing hyperpituitarism.
- Some adenomas are non-secretory, so the level of pituitary hormones is unaffected (normal hormonal levels).
- However, in rare cases, if a non-secretory adenoma enlarges to the extent it compresses the surrounding normal pituitary tissue, then the level of hormone secretion from the normal tissue will decrease, resulting in hypopituitarism.

Signs and Symptoms (14:17 – 15:54)

1. Radiographic abnormalities of the sella turcica:
    a. Sellar expansion – Occurs if the pituitary neoplasm is large.
    b. Bony erosions – Erosions of the sphenoid bone might occur, especially in malignant tumors (carcinomas).
2. The adenomas and carcinomas may compress the optic chiasm (an X-shaped structure formed at the point below the brain where the two optic nerves cross over each other) resulting in visual field abnormalities.
3. If the pituitary tumor is large it may cause elevated intracranial pressure with manifestations of headache, nausea, and vomiting.
    a. Note: Any mass in the cranium (inside the skull) can cause increased intracranial pressure.
4. Seizures
5. Cranial Nerve Palsies – Abnormalities in the functions of the cranial nerves.
6. Pituitary Apoplexy – To be discussed more on the next page.

More on the Optic Chiasm: (15:55-16:42)

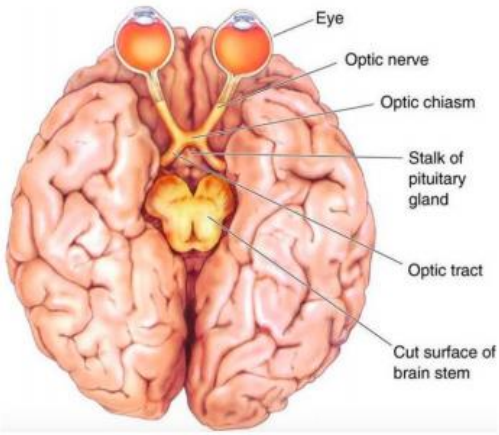

The optic chiasm is the X-shaped structure formed by cross-over of the optic nerves at the base of the brain. The pituitary gland is very close to this chiasm. So, a mass in the pituitary can compress the chiasm, which will affect vision. Note that because of this cross over, the right optic nerve supplies the left eye and vice versa. So, a defect in the right optic nerve will cause visual field defects in the left eye (the contralateral eye).

Pituitary Apoplexy (16:43 – 17:16) (السكتة النخامية**)**

- Characterized by an acute hemorrhage into a pituitary lesion, especially an adenoma. This causes rapid enlargement of the lesion, which will result in decreased consciousness.
- This is an acute neurosurgical emergency as it can cause sudden death.
- The word apoplexy means anger or rage.

Pituitary Adenomas (17:17-End)

- Functional or non-functional (also known as secretory or non-secretory).
- Functional: Usually composed of one cell type and produces only one hormone.

Classification

Adenomas are classified according to the hormones they produce:

- Prolactinomas: Prolactin secreting adenoma – 20%-30% of pituitary adenomas – The most common.
- Null cell adenomas: Non-secretory – 20% of pituitary adenomas.
  - As they are non-secretory, they will not present with any hormonal manifestations. However, if the adenoma enlarges and compresses the normal tissue, it will cause hypopituitarism.
- ACTH cell adenomas: 10%-15%
- TSH cell adenomas: 1% – Least common.
  - These adenomas are very rare. So, if you have a patient who presents with hyperthyroidism (increase in the function of the thyroid gland), it will be very rare that the cause of this disease is related to the pituitary gland. Usual the issue is within the thyroid gland itself.
- Pleurihormonal adenomas: 15%
  - They secrete more than one hormone.

    - The clinical manifestations (or symptoms) are related to the hormones secreted.
- In clinical practice, 10% of intracranial neoplasms are pituitary adenomas.
- However, pituitary adenomas can be an incidental finding in 25% of autopsies.
- The peak is in the 4th to 6th decades.
- They are mostly single lesions (solitary).
- Can be dived into microadenomas and macroadenomas according to size. The cut-off point is 1 centimeter.
  - If the diameter of the adenoma is less than 1 cm, then it is a microadenoma.
  - If the diameter of the adenoma is greater than 1 cm, then it is a macroadenoma.

Macroscopic Appearance:

Gross Features of Pituitary Adenomas:

The usual adenoma is a well-circumscribed lesion that, if small, is confined to the sella turcica. In 30% of cases, the adenomas are non-encapsulated, large, and can infiltrate adjacent bone, dura, and the brain.

This coronal section of brain tissue shows a very large pituitary tumor. Clearly, the diameter exceeds one centimeter, so it is a macroadenoma. Additionally, it is not an encapsulated tumor.