GIS ANATOMY *

Done by: Osama Alkhatib

Scientific Correction: Sarah Basel

Gramatical Correction: Sarah Basel

Doctor: Mohammad Almuhtaseb

Stomach

- The stomach is the dilated portion of the alimentary canal and has three main functions
  - It stores food (in adults it has a capacity of about 1500 ml).
  - It mixes the food with gastric secretions to form a semifluid "chyme".
  - It controls the rate of delivery of the chyme to the small intestine so that efficient digestion can take place.

- **Location**

  - The stomach is situated in the upper part of the abdomen extending from beneath the left costal margin region into the epigastric and umbilical regions (it occupies the left upper quadrant **mainly in the epigastric region** between the oesophagus and the small intestine).

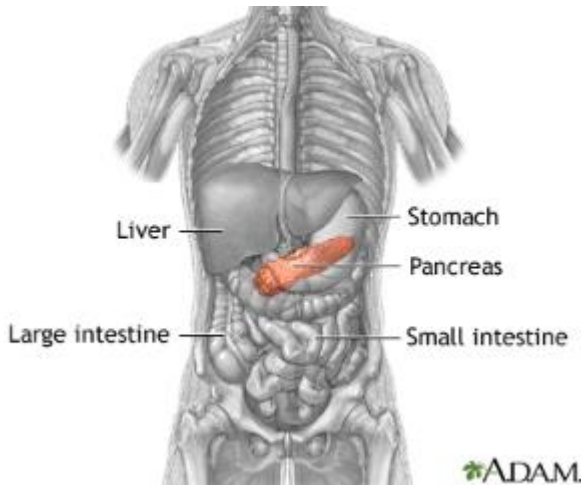

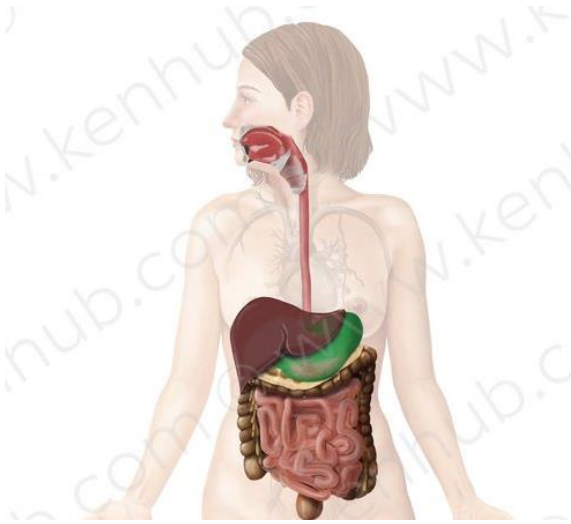

- The stomach is relatively fixed at both ends but is very mobile in between, it tends to be high and transversely arranged in the short obese person (**steer-horn stomach**), and elongated vertically in the tall and thin person (**J-shaped stomach**).
- **Shape of the stomach:**
  - The stomach is roughly J-shaped and it has:
    1. Two orifices (cardiac and pyloric).
    2. Two curvatures (greater and lesser).
    3. Two surfaces (anterior and posterior).

- The shape of the stomach undergoes considerable variation in the same person and that depends on:
  - The volume of its contents (when it is filled with large meals three times a day, the distentibility increases just like how your biceps get bigger after a workout).
  - The position of the body.
  - The phase of respiration.

- **Parts of the stomach:**

The stomach is divided into 3 parts (Fundus, body, pyloric region).

- **Fundus:** It is dome-shaped and projects upward and to the left of the cardiac orifice, it is usually full of gas.
- **Body:** It extends from the level of the cardiac orifice to the level of the incisura angularis (a constant notch in the lower part of the lesser curvature).
- **The pyloric region,** which is divided into:
  - **Pyloric antrum** it extends from the incisura angularis to the pylorus.
  - **Pylorus**, **the most tubular part of the stomach**.

- the cavity of the pylorus is called the **pyloric canal** which regulates entry of food from the stomach into the duodenum.
- The contents of the pyloric canal enter into the duodenum via the pyloric orifice, the opening and closing of which are controlled by the **pyloric sphincter, a circular layer of smooth muscle,** this thick muscular part plays an important role in digestion by acting as a valve to control the flow of partially digested food from the stomach to the small intestine.

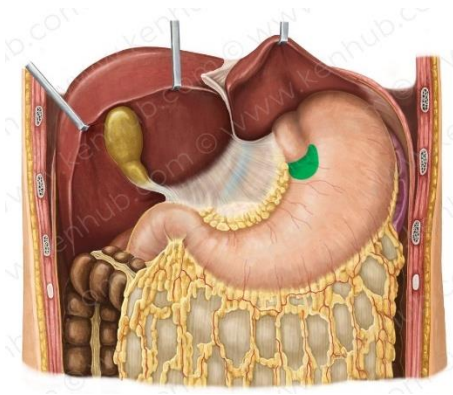

Cardia of stomach(Cardia)

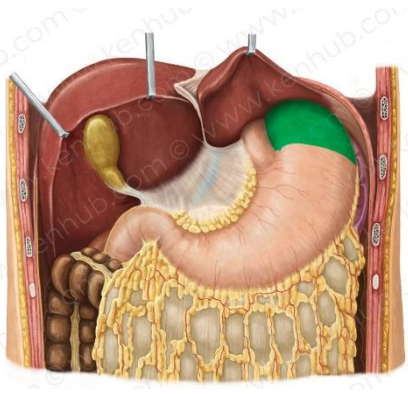

Fundus of stomach

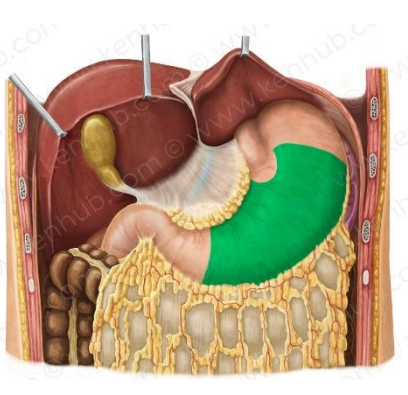

Body of stomach

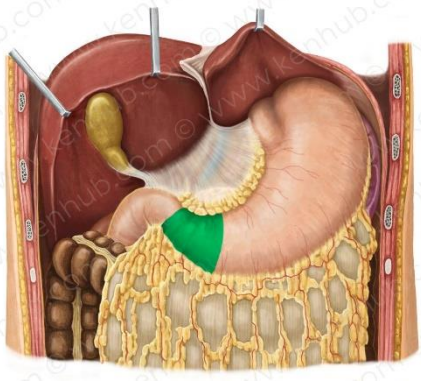

Pyloric part of stomach

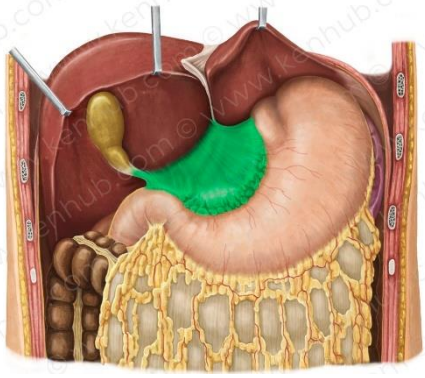

Lesser omentum

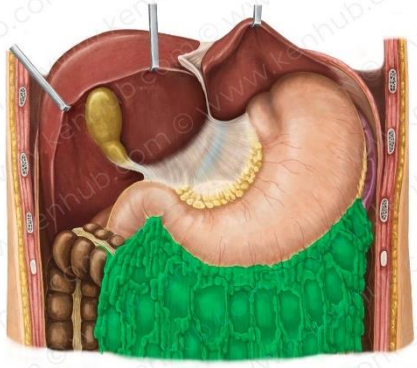

Greater omentum

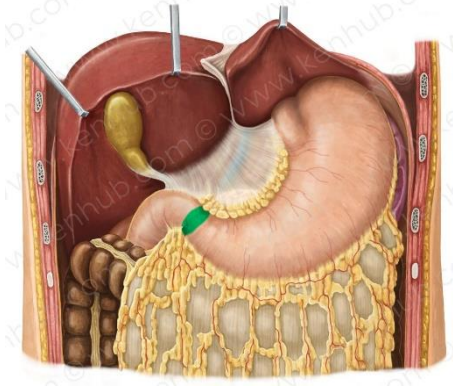

Pylorus

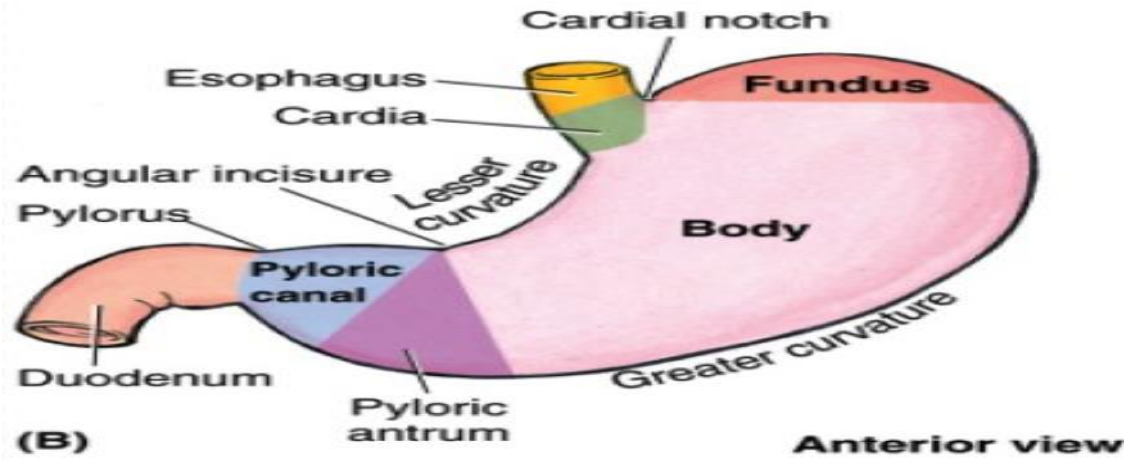

- As you might notice in the stomach diagram illustrated above, the organ has a characteristic J-shape created by two unequal curvatures:
  - **lesser curvature** is short and concave, it forms the right border of the stomach and extends from the cardiac orifice (opening) to the pylorus and it is suspended from the liver by the lesser omentum, it contains a small notch called the **angular incisure** which marks the line of intersection between the body and pyloric part of the stomach.

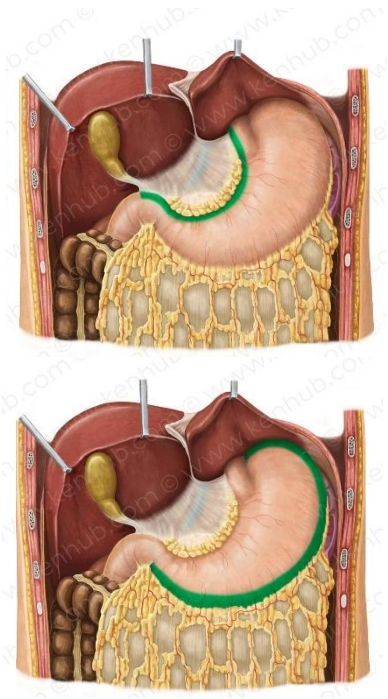

  - The **greater curvature** is convex and much longer than the lesser curvature, it extends from the left of the cardiac orifice, over the dome of the fundus, and along the left border of the stomach to the pylorus.

    - An easy way to remember the parts of the stomach: '**C**ows **F**ind **B**ulls **P**assionate', which stands for:
      - Cardium.
      - Fundus.
      - Body.
      - Pylorus.
- The **gastrosplenic ligament** extends from the upper part of the greater curvature to the spleen.

- The **greater omentum** extends from the lower part of the greater curvature to the transverse colon.

- The **lesser omentum** extends from the liver to the lesser curvature of the stomach.

- **Orifices of the stomach:**
  - **Cardiac orifice**, it is the opening by which the esophagus communicates with the stomach. It is located at the 7th left costal cartilage 1 inch to left of the midline, **no anatomic sphincters can be demonstrated here,** a physiological mechanism exists that prevents regurgitation of stomach contents into the esophagus which can cause some pathologic conditions such as GERD.
  - **Pyloric orifice**, the pyloric canal ends as the Pyloric orifice which marks the junction between the stomach and the duodenum on the level of L1, 1 inch to the right of the midline
  - The circular muscle coat of the stomach is **much thicker** here and it forms the anatomic and physiologic **pyloric sphincter,** its position is recognized by a slight constriction on the surface of the stomach.

The pyloric sphincter:

- The pyloric sphincter controls the outflow of gastric contents into the duodenum, it receives:
  - Motor fibers → sympathetic system (specifically the celiac ganglion from T6-T9)
  - Inhibitory fibers that promote its relaxation→ parasympathetic system (**vagus nerve**).

- The pylorus is controlled by local nervous and hormonal influences from the stomach and duodenal walls. For example, the stretching of the stomach (duo to filling) will stimulate the myenteric nerve plexus which leads to the relaxation of the sphincter.

- **Histology of the stomach:**

  - The stomach consists of four histological layers called, from interior to exterior, **mucosa, submucosa, muscularis externa, and serosa.**

- **Mucosa:**
  - The mucosa is thick, vascular and has a wrinkled aspect, consisting of ridges called **gastric folds, or rugae**. During distension of the organ, the gastric folds disappear (flatten out).
    - Along the lesser curvature of the stomach, a longitudinal fold called **gastric canal** is formed between the gastric folds. This facilitates the passage of saliva and fluids during swallowing.
    - The mucosa is lined by **simple columnar epithelium** which is covered by a protective, alkaline **mucous layer**. The epithelial layer contains numerous invaginations, called **gastric pits**, that extend deeper into structures called **gastric glands**, these glands are located in different regions of the stomach, cardiac glands, fundic glands, pyloric glands and their main function is to secrete gastric juice and its digestive enzymes.
    - Depending on the part of the stomach, these glands consist of various cell types.

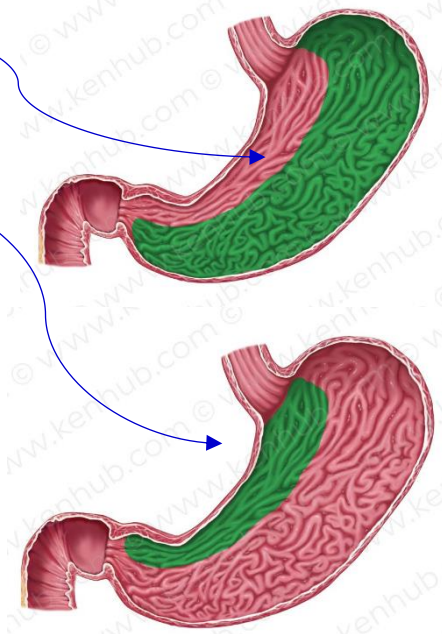

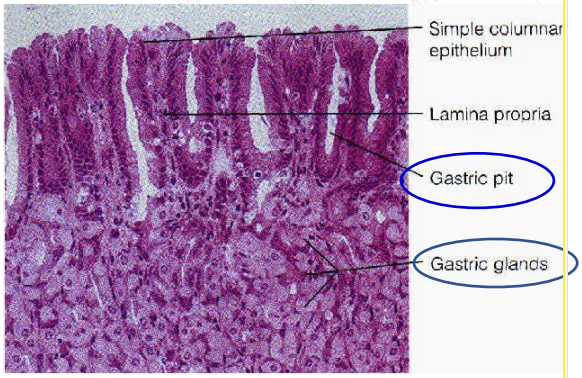

1. **Mucous neck cells:** produce the mucous layer.
2. **parietal cells:** secrete hydrochloric acid.
3. **Chief cells:** release pepsinogen.
4. **neuroendocrine cells:** release various hormones.

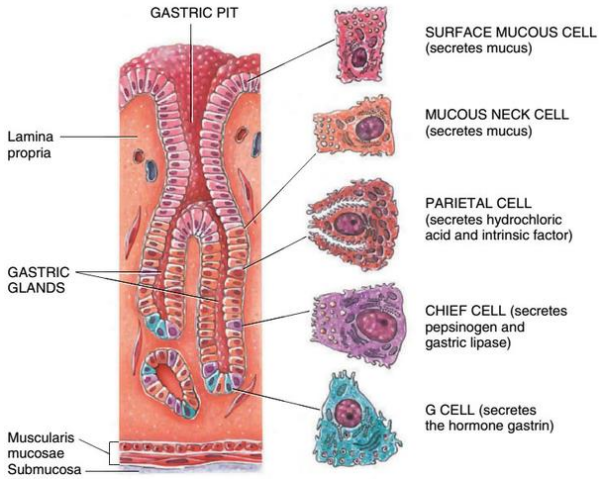

- The next layer is the **submucosa**. It consists of dense irregular or loose connective tissue containing blood vessels and nerves.
- The third layer is called **muscularis externa** and consists of three smooth muscle sub-layers. From internal to external, they are called **inner oblique, middle circular** (plays an important role in forming the pyloric sphincter)**, and external longitudinal** (run along the lesser and greater curvature).

Longitudinal layer of muscular coat of stomach

Circular layer of muscular coat of stomach

Inner Oblique fibers

- The **serosa** consists of the visceral peritoneum that covers the stomach.

- **Peritoneum of the stomach:**

Parietal peritoneum

Visceral peritoneum

- The peritoneum (visceral peritoneum) completely surrounds the stomach.
- The stomach is an intraperitoneal organ (completely wrapped by visceral peritoneum).

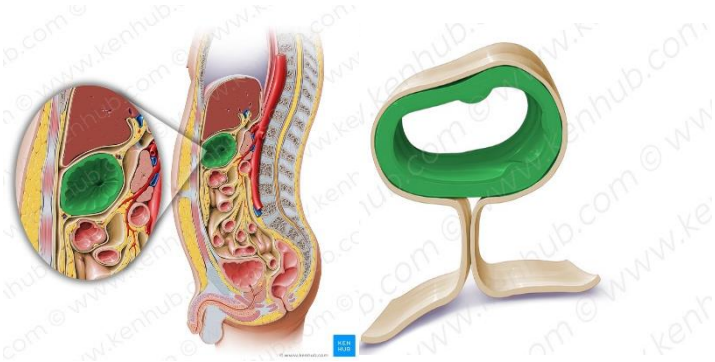

Intraperitoneal organ

Retroperitoneal organ

- The visceral peritoneum leaves the lesser curvature as the lesser omentum, the lesser curvature is suspended from the liver by the lesser omentum .

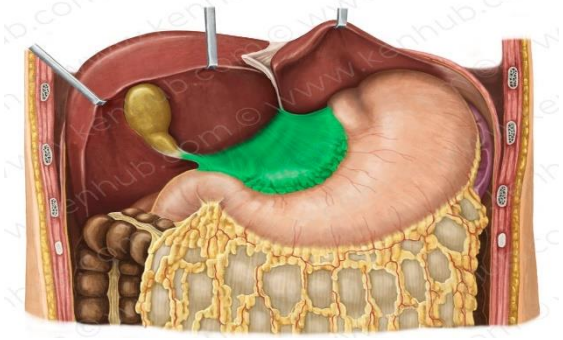

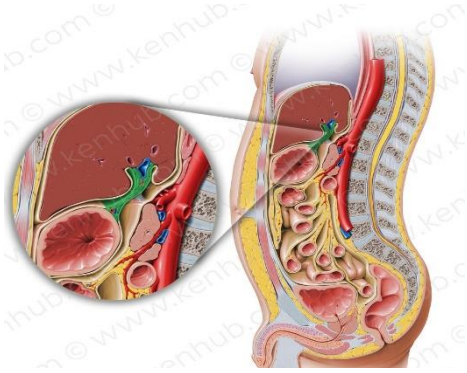

- And leaves the greater curvature as the gastrosplenic ligament and the greater omentum.

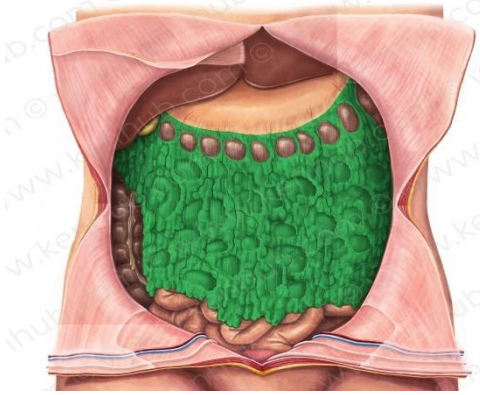

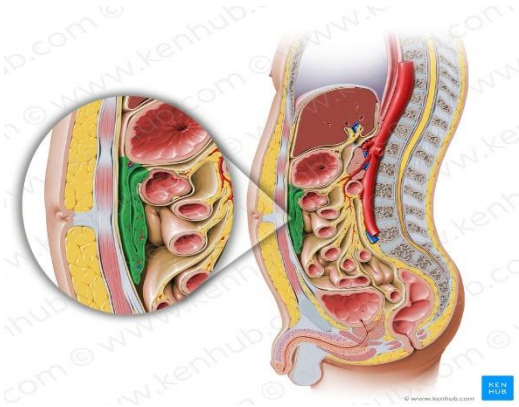

- The gastrosplenic ligament extends from the upper part of the greater curvature to the spleen, and the greater omentum extends from the lower part of the greater curvature to the transverse colon.

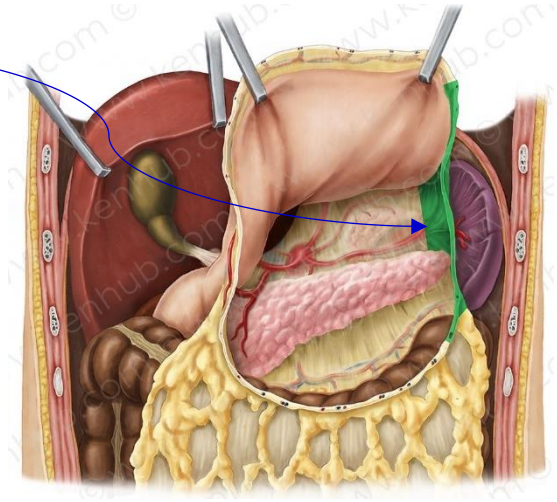

- Gastrophrenic ligament between the fundus and the diaphragm.

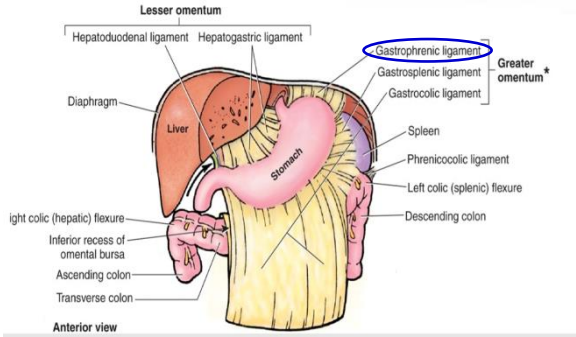

- **The relations of the stomach:**

Anteriorly	Posteriorly
-The anterior abdominal wall. -The left costal margins. -The left pleura. -The lung. -The diaphragm. -The left lobe of the liver.	-The lesser sac. -The left crus of diaphragm. -The spleen. -The left suprarenal gland. -The upper part of the left kidney. -The splenic artery. -The body of pancreas. -The transverse mesocolon. -The transverse colon.

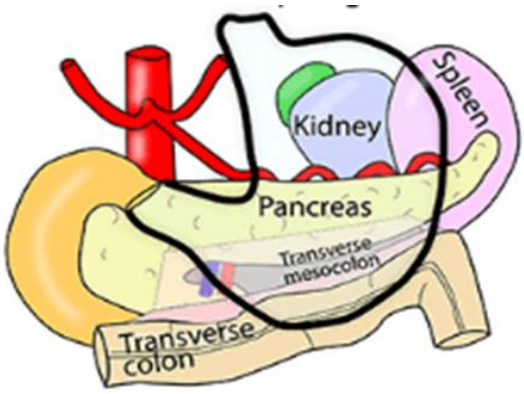

- **Blood Supply of the stomach:**

- The overall blood supply of the stomach originates from the abdominal aorta.
- The **celiac trunk** is a major artery that supplies the foregut of the gastrointestinal tract. It arises from the abdominal aorta at the level of T12 to L1 above the pancreas, it is 1cm long. It gives off three major branches called **left gastric, common hepatic and splenic arteries.**
- **Relations of celiac artery:**
  1. On each side: celiac ganglia, within these ganglia sympathetic autonomic fibers synapse, and postganglionic fibers then emerge to proceed and innervate components of the GIT + lymphatic nodes.
  2. Crus of diaphragm and lumbar nerves, the diaphragm has multiple bony attachments, such as the lumbar vertebrae, which give rise to the right and left crura of the diaphragm. As they ascend, they are related to the aorta (on both sides), and since the celiac trunk emerges from the aorta, it is also related to them.
  3. Its Branches for foregut.

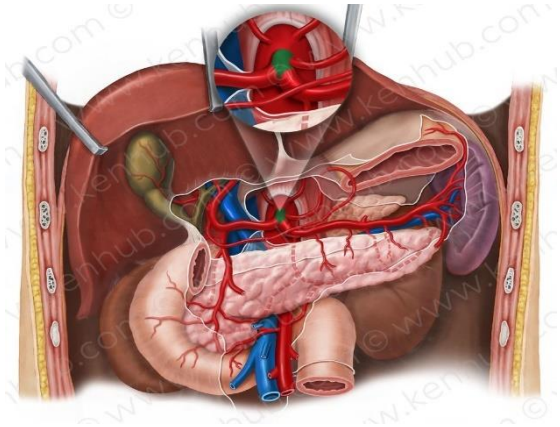

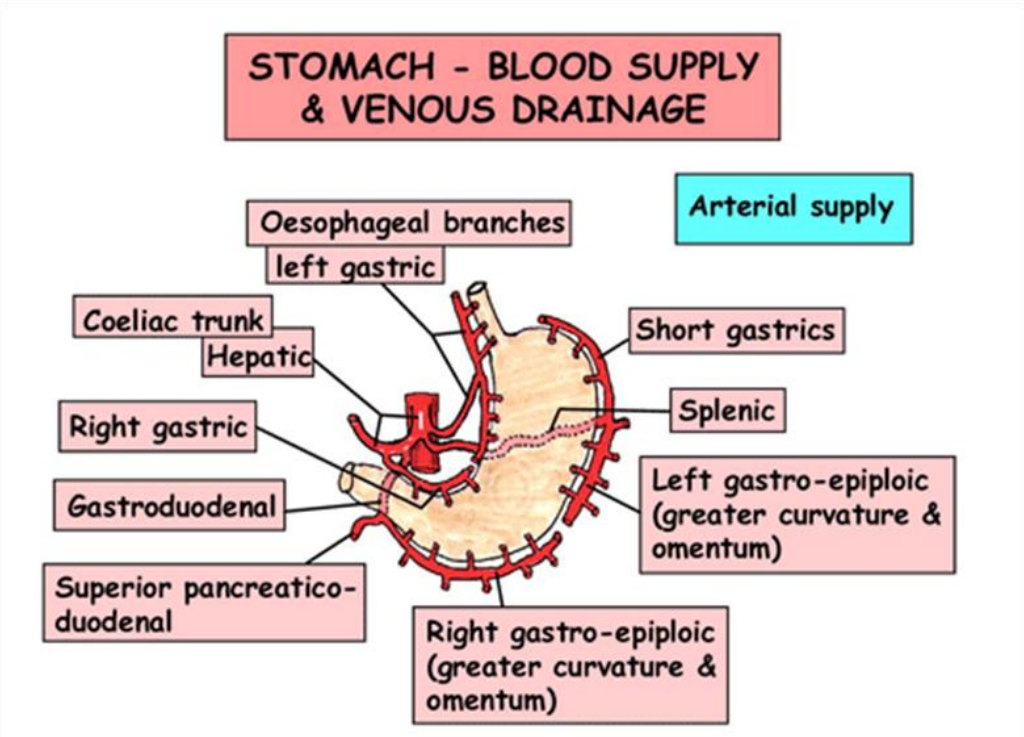

The left gastric artery: arises from the celiac artery. It passes upward and to the left to reach the esophagus and then descends along the lesser curvature of the stomach. It supplies the lower third of the esophagus and the upper right part of the stomach.	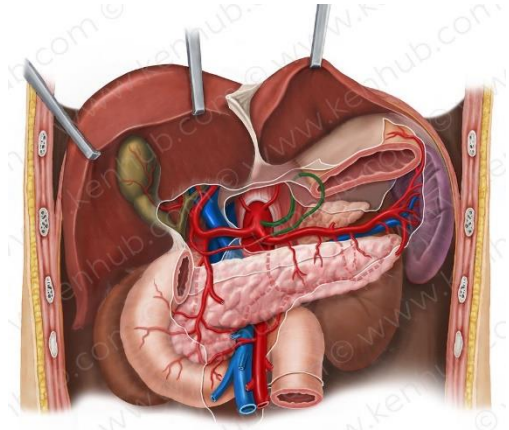
The right gastric artery: It arises from the hepatic artery at the upper border of the pylorus and runs to the left along the lesser curvature. It supplies the lower right part of the stomach. **Hepatic artery** **The right gastroepiploic artery:** It arises from the gastroduodenal branch of the hepatic artery. It passes to the left and supplies the stomach along the lower part of the greater curvature.	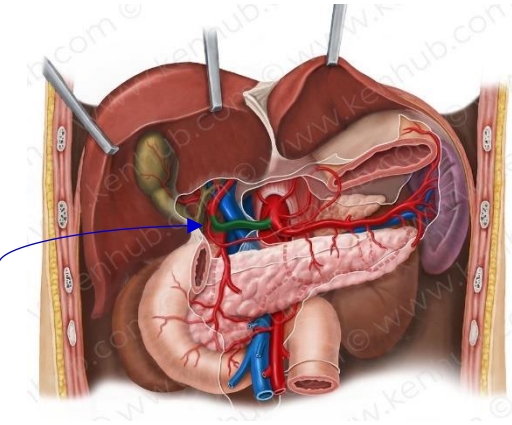
The short gastric artery: It arises from the splenic artery at the hilum of the spleen and pass forward in the gastrosplenic omentum to supply the fundus. **Splenic artery** **The left gastroepiploic artery:** It arises from the splenic artery at the hilum of the spleen and passes forward in the gastrosplenic omentum to supply the stomach along the upper part of the greater curvature.	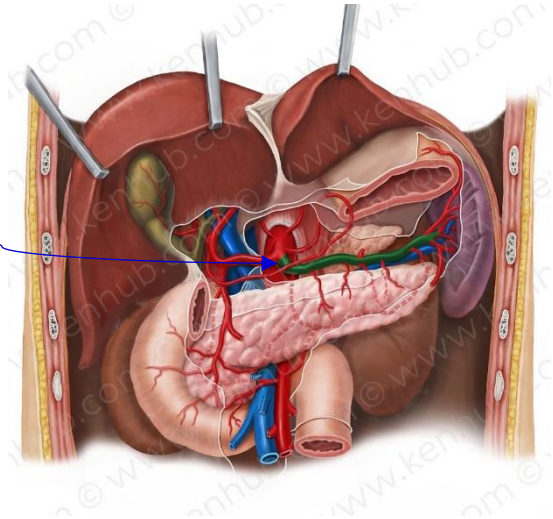

Artery	Branch from	Supplied parts
• Left gastric artery	Celiac artery	lower third part of the esophagus and the upper right part of the stomach.
• Right gastric artery	Hepatic artery	lower right part of the stomach
• short gastric artery	Splenic artery	Fundus of the stomach
• left gastroepiploic artery	Splenic artery	The stomach along the upper part of the greater curvature
• The right gastroepiploic artery	The gastroduodenal branch of the hepatic artery	The stomach along the lower part of the greater curvature

- **Venous Drainage:**

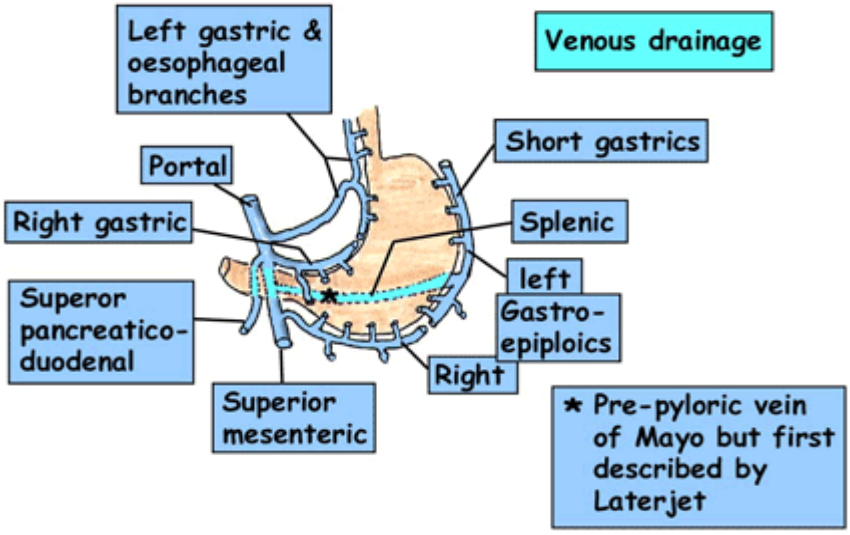

- The veins draining the stomach follow the course and nomenclature of the arteries very closely. They ultimately drain into three large vessels called the **hepatic portal, splenic, and superior mesenteric veins.**
  - The veins drain into the **portal circulation**.
  - The left and right gastric veins drain directly into the portal vein.
  - The short gastric veins and the left gastroepiploic veins join the splenic vein.

- The right gastroepiploic vein joins the superior mesenteric vein (which meet the splenic vein behind the neck of pancreas to form the portal vein).

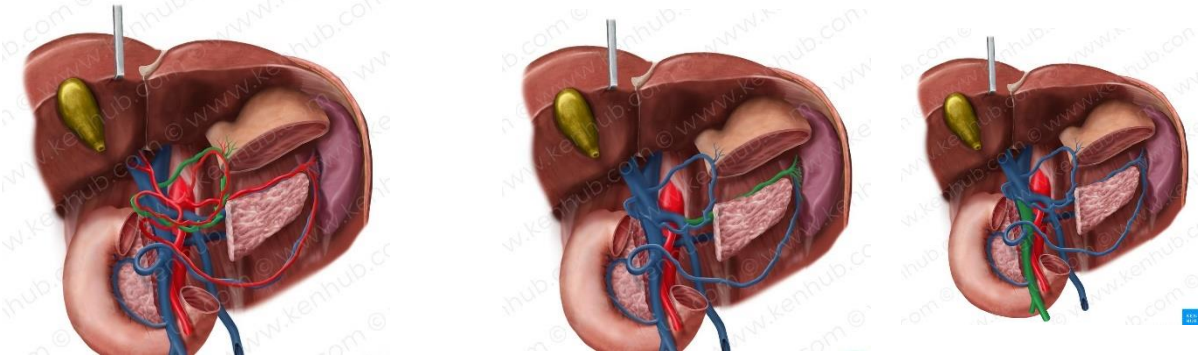

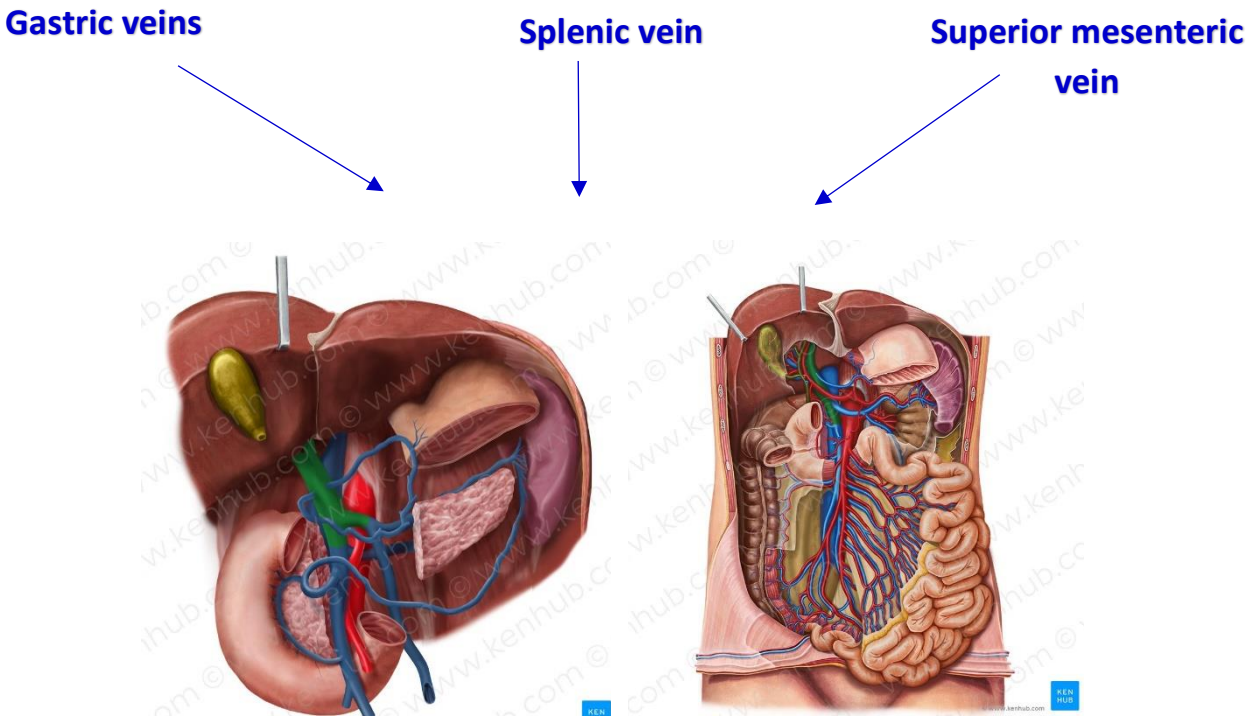

Hepatic portal vein

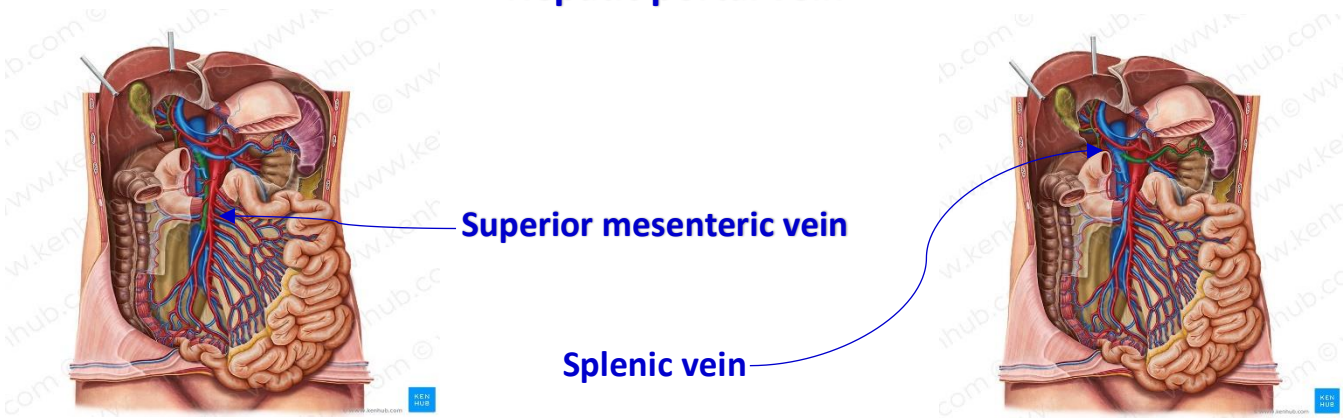

- After passing through the portal circulation, the venous blood from the digestive system empties into the inferior vena cava through hepatic vein, and returns to the heart to be distributed throughout the body.
- **Lymphatic drainage:**

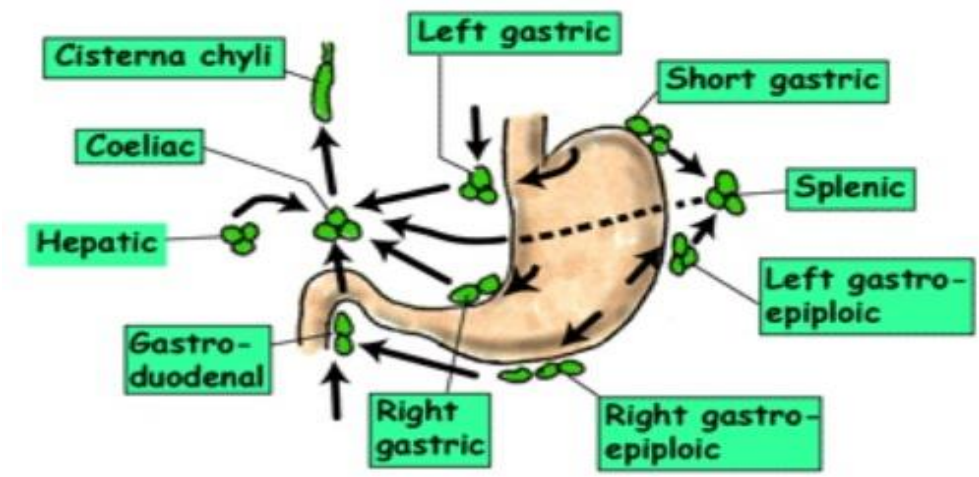

Lymphatic Drainage of Stomach

- Follow the arteries of stomach.
- Lymph is drained from the stomach by lymph vessels that empty into the **right** and **left gastric lymph nodes**.
- The **left** and **right gastroepiploic nodes**.
- The **short gastric nodes.**
- The pyloric part is drained by the **superior** and **inferior pyloric lymph nodes**.
- Subsequently, lymph vessels drain these sets of lymph nodes into the **celiac lymph nodes**, which are located around celiac trunk on the posterior abdominal wall.

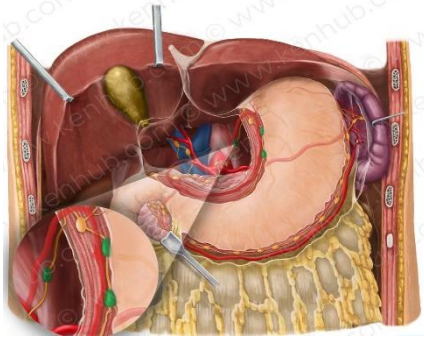

left gastric lymph nodes

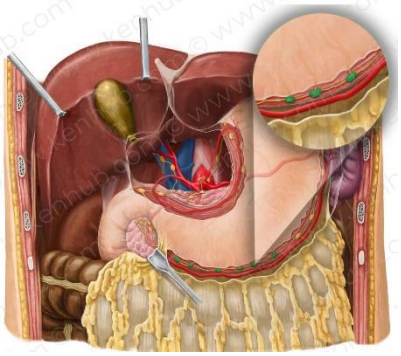

right gastroepiploic nodes

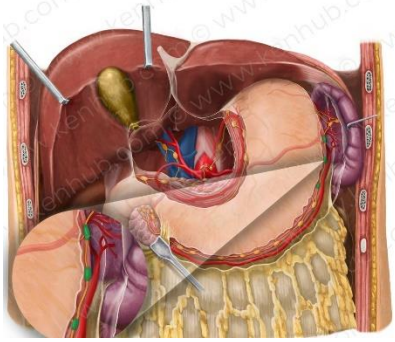

Left gastroepiploic nodes

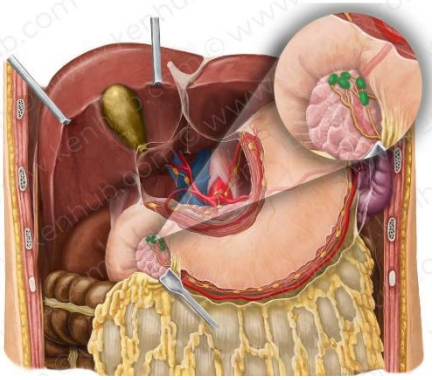

Subpyloric lymph nodes

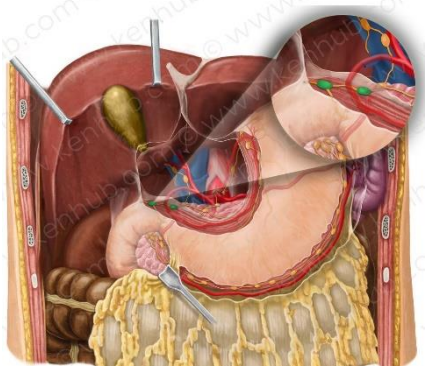

Suprapyloric lymph nodes

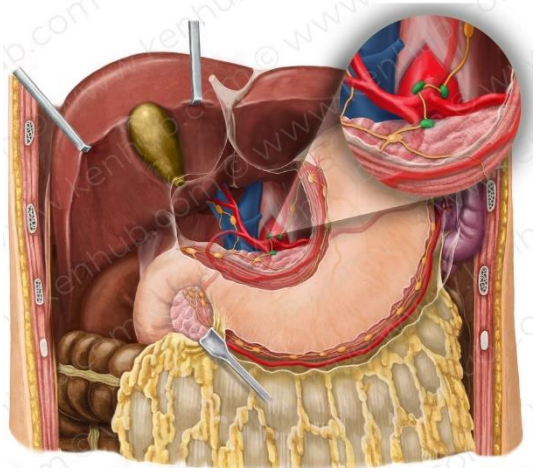

Celiac lymph nodes

- **Nerve supply of the stomach:**
  - The stomach receives involuntary innervation by the autonomic nervous system (ANS).

Parasympathetic Innervation:	originates from the anterior and posterior vagal trunks, which stem from the left and right vagus nerves (CN X), respectively. Parasympathetic innervation is responsible for inducing gastric secretion and motility, as well as relaxation of the pyloric sphincter during gastric emptying. The parasympathetic vagal fibers are **secreto-motor** to the gastric glands and motor to the muscular wall of the stomach (peristaltic movement).
Notes:	The branches of the **right vagus** nerve forms the **posterior gastric nerve** (on the posterior surface of the stomach), while the branches of the **left vagus** nerve forms the **anterior gastric nerve** (on the anterior surface of the stomach).
Anterior vagal trunk:	mainly supplies a portion of the anterior surface of the stomach. The anterior vagal trunk also gives off the **hepatic branch** of the vagus nerve which in turn provides most of the nerve fibers to the hepatic plexus (**passes up to the liver**). **ANT. Nerve of Latarjet** is also a branch of the anterior vagal trunk which **supplies the pylorus**. It functions by increasing peristalsis and relaxing the sphincter, thus **draining the contents of the stomach** into the first part of the duodenum.
Posterior vagal trunk:	innervates the remaining anterior surface (anterior wall of the body of the stomach), as well as the entire posterior surface. **Celiac branch** innervates the small intestine as far as to splenic flexure+ pancreas. **Posterior Nerve of Latarjet** which again innervates the pylorus.

- Sympathetic innervation is provided by the **celiac plexus** around the celiac trunk (branch of abdominal aorta). The nerve impulses originate from thoracic spinal nerves and travel to the celiac plexus. Sympathetic innervation is responsible for **inhibiting gastric motility and constricting the pyloric sphincter, thus preventing gastric emptying.**
- The sympathetic innervation of the stomach carries a proportion of **pain sensation**.
- The pyloric sphincter receives motor fibers from the sympathetic system and inhibitory fibers from the vagus nerve.

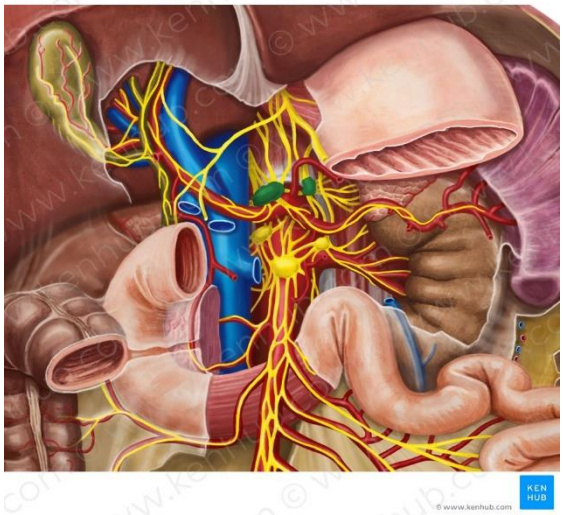

Celiac ganglia

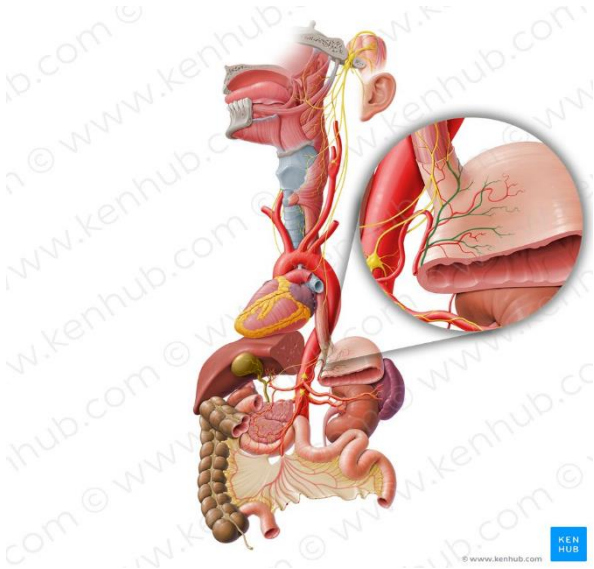

Anterior gastric branches of anterior vagal trunk

- **Clinical notes:**

› **Gastric ulcers**: They are usually caused by H.pylori or (NSAIDS) which can break the stomach's defence against the acid it produces to digest food causing an ulcer to form.

› **Trunkal vagotomy**: A vagotomy is performed when acid production of the stomach should be reduced, trunkal vagotomy is done by sectioning the vagus nerve below the diaphragm around the esophagus, (vagus nerve stimulates parasympathetic nervous system in the stomach which in turn stimulates gastric secretions via parietal and G cells).

- **Highly selective vagotomy**: this type involves cutting all branches of the vagus nerve except Latarjet nerve (to ensure the emptying function of the stomach remains intact).
- **Peptic ulcer**: peptic ulcer disease usually involves the mucosal lining of stomach or duodenum, one of the commonest causes of both gastric and duodenal ulcers is Helicobacter Pylori (H pylori) infection. However, it can also be due to gastric acid overproduction.
- **Gastroscopy:** It is a procedure where a thin, flexible tube called an endoscope is used to look inside the esophagus, stomach and the duodenum.
- **Pyloroplasty:** It is a surgery to widen the pylorus so that stomach contents can empty into the small intestine (duodenum).

Good Luck