GIS 11

ANATOMY

Done by: Tarteel sabrah

Scientific Correction:

Gramatical Correction:

Doctor:

Pancreas

In general

- **Retroperitoneal organ** lies in the posterior abdominal wall
- **Mixed gland**
  - Endocrine (Insulin, glucagon and somatostatin)
  - Exocrine (Pancreatic juice)
- **Extends from spleen to the concavity of duodenum**

  Duodenum receives secretions from gallbladder and pancreas through :
  - **Main pancreatic duct** :
    - Begins in the tail and runs the length of the gland
    - Receiving numerous tributaries on the way .
    - Opens in the 2nd part of duodenum at about its middle **in the major duodenal papilla** with **common bile duct** which pierces the head and opens with main pancreatic duct.

  - **Accessory duct** sometimes present and sometimes absent
    - if accessory pancreatic duct exists, it opens in **the minor duodenal papilla** one inch above **major duodenal papilla**
    - Drains the upper part of the head
    - Frequently communicates with the main duct

Clinical note : If accessory duct exists that means we have secretions come from it which help us in case of pancreatitis and obstructions | in ultrasounds it appears clearly - report from radiology will tell you whether it exists or not .

- **Lies behind the stomach so it considers from stomach bed**
- **It has anatomical relation to the transverse colon and mesocolon**

Parts of the pancreas (body, head, neck,tail)

Tail

- Exist in **Splenorenal ligament "lienorenal ligament"**
- Reaches hilum and does impression

Body

- Runs upward and to the left across the midline
- It is somewhat triangular in cross section
- **Posterior to it**
  - **Splenic vein**
  - Origin of **Superior mesenteric artery** from abdominal aorta.

- **3 SURFACES** (anterior /posterior/inferior)
  - **Anterior surface**
    - **Covered by peritoneum of post. Wall of LESSER SAC**
    - **Tuber omental** : where the ant. surface of pancreas join the neck

  - **Posterior surface**:
    - We find **SPLENIC VEIN** behind it
    - Since pancreas is a retroperitoneal organ so its posterior surface lies in the posterior abdominal wall with no peritoneum covering it " ***devoid of peritoneum***"
    - **IN CONTACT WITH**
      - ∞ Aorta
      - ∞ Splenic vein
      - ∞ Left kidney and its vessels
      - ∞ Left suprarenal gland
      - ∞ Origin of the superior mesenteric artery
      - ∞ The crura of the diaphragm
  - **Inferior surface**
    - Narrow on the right but broader on the left
    - Covered by peritoneum of **GREATER OMENTUM**
    - lies upon the **duodenojejunal flexure**
    - Some **coils of the jejunum**
    - Its **left** extremity rests on **the left colic flexure**
- **3 BORDERS** (superior/ anterior /inferior)
  - **Superior border**
    - Blunt and flat to the right
    - Narrow and sharp to the left near the tail
    - It commences on the right in the omental tuberosity
    - In relation with
      - ∞ Celiac artery
      - ∞ Hepatic artery
      - ∞ Splenic artery runs toward the left in a groove along this border.

  - **Anterior border**
    - Separates the anterior surface from the inferior surface
    - Along this border the two layers of the transverse mesocolon diverge from one another one passing upward over the anterior surface, the other backward over the inferior surface.

Side note : GREATER OMENTUM descends as 2 layers from the greater curvature then ascend as two layers and after that, it covers the transverse colon (inferior and superior surface) then it continues as 2 layers to the anterior border of the pancreas/ other books state that greater omentum ends on the transverse colon just covers the upper and lower surface of the transverse colon, then from anterior border of pancreas appear two layers when these two layers reach transverse colon they blend with greater omentum, no matter what is the true theory , the most important conclusion is that transverse colon is an intraperitoneal organ covered completely by peritoneum and gave extension called mesocolon and mesocolon reaches the anterior border of the pancreas so the two theories complete each other .

- **Inferior border**
  - Separates the posterior from the inferior surface
  - Superior mesenteric vessels (from abdominal aorta) emerge under its right extremity

Neck

- Constricted portion of the pancreas
- Connects the head to the body
- It lies in front of the beginning of the portal vein (portal vein "*which formed by the union of superior mesenteric vein and splenic vein* " starts there and ends in the liver)

Clinical note : Tumor in the neck / body of pancreas mainly affects portal vein it causes pressure on it | "pressure word" indicates portal hypertension or invagination (tumour pierces blood vessels and causes bleeding)

keep in mind this is common case and you may see it a lot

Head

- It is **disc shaped**
- **Lies within the concavity** of the duodenum
- **Inferior vena cava** behind it

Clinical note : Tumor in the head of pancreas affects common bile duct and pancreatic duct "*which will cause Obstructive jaundice***" and IVC** – according to doctor explanation not the slides

Uncinate process :

- Extension from the head to the left side
- **Superior mesenteric vessels** *(artery and vien)* in front of it
- abdominal aorta passes posterior to it

unicate process sandwiched between abdominal aorta behind and superior mesenteric in front

Anatomical position of pancreas

- **Epigastric**
- **Left upper hypochondrium region**

Common relations of pancreas

- **Anterior**
  - Transverse colon
  - Transvers mesocolon
  - Lesser sac
  - Stomach
- **Posterior** what is behind pancreas " remember pancreas retroperitoneal exists in the posterior abdominal wall"
  - Bile duct and portal vein pierce the head and open in the 2nd part of the duodenum
  - Splenic vein runs in the posterior surface of the pancreas
  - IVC
  - Aorta
  - Origin of Sup.mesentric.a behind the body
  - Lt.Psoas muscle
  - Lt.Suprarenal gland o Left kidney
  - Hilum of the spleen at pancreas end

Important question mentioned by the doctor : **all of the following lies posterior to pancreas except one**

Posterior view of duodenum/pancreas

We can notice from the picture :

- **Head of the pancreas**
- **Some lymph node on the head of pancreas "pancreatic lymph nodes"**
- **Common bile duct** pierces the head and opens in the ampulla of Vater bulge
- **Portal vein** behind the neck of pancreas comes from splenic and superior mesenteric vein
- **Celiac trunk** it lies above the body of pancreas and gives three branches splenic artery tortious and runs in the upper border of pancreas
  ** ***Celiac trunk*** : first branch of the abdominal aorta and appears from the anterior surface of the aorta | celiac trunk gives three branches 1- hepatic 2- left gastric 3- splenic artery

Pay attention !! **splenic artery in the upper border but splenic vein in the posterior surface that's why when we talked about stomach bed that splenic artery exists there but vein doesn't because it lies behind the pancreas**

More about **splenic artery**

Splenic artery is one of three of the tortuous vessels we have like facial artery in the face and uterine artery in the uterus. The most important one is the uterine artery in the uterus because uterus in female in case of pregnancy it becomes very big so uterine artery becomes elongated.

Histology of pancreas if we take a section from pancreas "

- Mixed gland previously mentioned
- Endocrine→Islets of Langerhans that consist of
  - [α cells : large cells and usually in the periphery of islets]
  - [β cells : small cells usually in the center of Islets of Langerhans]

What is the difference between them?

- **Alpha cells secrete glucagon** – which increases glucose level in the blood when we need it? For example when a student uses his mental abilities in the exam so he needs glucose for brain →glucagon converts fat into glucose so glucose concentration increases in the blood
- Opposite to **beta cells which secrete insulin** !" that decreases glucose concentration in blood " | when someone eats ***knafeh*** for example immediately insulin is secreted and glucose concentration decreases in the blood

CLINICAL NOTE : Now if we take a sample of blood from any one and we test glucose concentration we will find it between (70-90) mg/dL if he eats a lot of sugar and sweets the concentration remains between (70-90)mg/dL if he goes to the exam and com back , the concentration also stays the same *During this period , hormones secreted and these hormones keep the concentration normal in healthy person * so healthy person always his glucose concentration is between (70-90)mg/dL* if raised or decreased immediately these cells α and β have something like sensors when blood comes * Cells know that glucose is elevated so immediately secrete insulin and vice versa . * so the body controls itself by itself doesn't need anything and that is one of the miracles of the creator in his creation !! all of the things inside you are organized and controlled automatically without you feel ! One of the common diseases in our region is *diabetes mellitus* | Weakness in beta cells islets therefore insufficient amount of insulin| so when you eat a lot of sugar your glucose level will not return to its normal level and remains high

CLINICAL NOTE :Any patient we expect to have diabetes we advise him to make fasting blood sugar test, fasting all night and the day after in the morning do the test. | If glucose level is high it may, unfortunately, indicates that our patient have diabetes more than 90mg/dL for example 120 or 200or 300mg/dL and sometimes 400!– treatment will be mentioned later inshallah in the endocrine system

Blood Supply of pancreas

Arteries

IN GENERAL

- Splenic.a
- Superior PancreaticoDuodenal .
- Inferior PancreaticoDuodenal arteries.

MORE EXPLANATION

Remember we have talked about duodenum **which the upper half follows foregut and receives its blood supply from celiac trunk** and the **lower half follows midgut and receives its blood supply from superior mesenteric artery →Pancreas the same thing**

- Tail , body, neck and the upper half of the head follow foregut so they receive blood supply from → gastroduodenal artery from →hepatic artery
- Gastroduodenal divides into →anterior and posterior **superior pancreaticoduodenal artery**
- So superior pancreaticoduodenal anterior and posterior from the gastroduodenal artery of hepatic
- hepatic artery as you know it comes from celiac trunk
- In regard to the lower part of the head with uncinate process receives a branch from superior mesenteric which is → **inferior pancreaticoduodenal artery**

Veins

- The corresponding veins drain into the portal system
- The upper part [body and tail go to the splenic vein]
- [head goes to the superior mesenteric vein] and after that, they meet and make the portal vein so all venous drainage go to the portal vein

Lymphatic drainage of pancreas

Lymph nodes are situated along the arteries that supply the gland. The efferent vessels ultimately drain into

- Celiac lymph nodes **(around celiac trunk)**
- Superior mesenteric lymph nodes **(around the origin of superior mesenteric artery)**

Side note : There is a connection with the splenic lymph node Together we called them pancreaticosplenic lymph nodes

Nerve supply of pancreas

Sympathetic

- celiac ganglia around the celiac trunk
- superior mesenteric ganglia around the origin of the superior mesenteric artery

Parasympathetic chain

- Parasympathetic = vagus nerve

Some scientific published papers discuss the innervation of pancreas previous papers said that vagus (parasympathetic) goes mainly to the exocrine parts = pancreatic acini responsible for the secretion of enzymes which go to the pancreatic duct and duodenum and sympathetic responsible for the endocrine part especially blood vessels of endocrine and hormones that theory was rejected and now we have researchs that state on both sympathetic and parasympathetic responsible for both endocrine and exocrine portions of the pancreas and enteric plexus of nerves exists in the wall of pancreas which does direct response especially when glucose elevates immediate response produced to increase secretion of insulin to decrease glucose level this direct reflex doesn't wait until reaching the center so we have something called enteric plexus in the wall of pancreas and it works both sympathetic and parasympathetic and this was improved and now we have a lot of researches regarding it

Congenital defects of pancreas & pancreatitis

Annular Pancreas (pancreas encircles duodenum) (rare)

- because it comes from two buds and these two buds meet each other and make→ head ,neck ,body and tail
- so it surrounds duodenum and causes obstruction which causes complications and need a solution

Ectopic Pancreas (very common)= Outside the gastrointestinal tract either endocrine or exocrine in an abnormal site

Acute pancreatitis= inflammation of pancreas here we use **ERCP** endoscope retrogradely which helps in the treatment of acute pancreatitis in cases of **obstructed jaundice** **(stones present or mud (thick secretions) and causes obstructions)**

Spleen

Description of spleen

Reddish & oval shaped

largest single mass of lymphoid tissue in the body.

What is the type of spleen between organs? Lymphatic or lymphoid tissue if we remove it like when we remove the appendix for example we have another lymphatic tissue that can do the function and compensate **but the main function of the spleen is to **break down of RBCs and WBCs** and we have a disease that manifested by bluish coloration in the place of minor trauma of the hand, leg, anywhere in the body due to the sudden breaking of platelets and this blue color indicates that there is no coagulation due to the decrease in platelets and when the patient goes to test his blood the normal range (250 - 500000)per microliter (µL) of blood he finds the concentration 4000µL or 5000µLr even 6000µL and that prevents coagulation which is very dangerous and may someone has a trauma in his head which causes severe bleeding and finally death { when doctors do the test they may find spleen is the causative agent for the broken blood cells so they proceed to do **splenectomy** and then patient becomes well again so the spleen is very important and it is lymphoid tissue ***Why do we study it in the GI system?*** **| Because it exists in the abdomen and | receives splenic vessels (arteries and viens) | lymphatic drainage on GI**

In splenectomy we must keep the tail of pancreas intact because any trauma can causes peritonitis due to secretion leakage

Has a notched anterior border

Peritoneum

- The spleen is completely covered with peritoneum " intraperitoneal organ"
- Two ligaments
  1. **Gastrosplenic omentum** (ligament)
     - between the spleen & the greater curvature of the stomach *(most upper part of greater omentum)*
     - carrying 5-7 **short gastric vessels** (artery and veins) branches from the splenic artery
     - **left gastroepiploic** vessels (artery and vein) the artery is a branch of splenic artery located in greater omentum, at the beginning, they appear in this ligament and then continue to the greater omentum giving blood and venous supply to the stomach
  2. **Splenicorenal ligament or lienorenal ligament**
     - between spleen & left kidney
     - carrying the splenic vessels and the tail of the pancreas
- It lies above the phrenicocolic ligament "sleeps on the phrenicocolic ligament"| Phrenicocolic ligament separates it from the lower compartment therefore prevents infection to go upward .

Size → 1 inch
Thick → 3 inch
Broad → 5 inch long
Weight → 7 ounce
Shape → **variable**
2 **Ends** 2 **Borders** 2 **Surfaces**

Notched [Due to lobulation in embryo]

2 Surfaces (Diaphragmatic surface / Visceral surface)

1. **Diaphragmatic surface**
   - Has Post- lat.relation
   - Convex
   - Smooth
   - Diaphragm separates it from - Pleura & lung –
   - Ribs 9,10 ,11

Clinical note : The axis of spleen is parallel to the 10th rib (run with it) so any trauma in the left side that causes fractures in ribs . 9 , 10 , 11 immediately we expect ***rupture of spleen*** since it is a reservoir of blood -full of blood مملوء بالدم - so easy to rupture

2. Visceral surface

- Has Ant- med. Relations
- It is divided by a ridge into
  - An anterior or gastric
  - A posterior or renal portion.
- Lower extremity has
  - Colic surface
  - Pancreatic surface (generally in contact with the tail of the pancreas)
  - It is flat
  - Triangular in shape
  - Rests upon left flexure of the colon and the phrenicocolic ligament
- Gastric surface
  - Extends forward, upward, and medialward
  - Broad and concave
  - Related to stomach
- Renal surface
  - Directed medialward and downward.
  - It is somewhat flattened
  - Related to Lt.kidney Spleen
- Hilum of spleen
  - Splenic . A anterior
  - Splenic . v posterior
  - Tail of pancreas "under splenic artery and splenic vein inside lienorenal ligament"

Intraperitoneal or Intraperitoneal ? The answer is intraperitoneal which means completely covered by peritoneum except for the hilum and the hilum is very small and surrounded by 2 layers of peritoneum that form ligament-like ***gastrosplenic and lienorenal ligament*** so it considered as intraperitoneal interperitonuim like liver there is a bare area clearly appears and not covered. so we consider spleen as intraperitoneal because hilumis very small and blood vessels enter between 2 layers (ligament)

Impressions on the visceral surface

1. Gastric Impression -related to stomach
   - impression between upper/anterior/superior border and hilum
2. Renal Impression- related to left kidney
   - below hilum
3. Colic Impression Or Splenic -for left colic flexure
4. Tail Of Pancreas Impression

Borders of spleen

1. sup. Border
   - It is free
   - Sharp
   - Thin
   - Often notched (sup.notch) very clear notch !! , especially below *When spleen formed at the beginning it appears like lobules later on it leaves remnants on the upper border*
   - It separates the diaphragmatic surface from the gastric surface Spleen
2. Inferior border **/ lower border below renal area**
   - More rounded and blunter
   - Separates the renal from the diaphragmatic surface
   - It corresponds to the lower border of the eleventh rib
   - lies between the diaphragm and left kidney.

Intermediate margin

- is the ridge which separates the renal and gastric surfaces.

Internal border

- separates the diaphragmatic from the colic surface.

2 Ends

- Med.end
  - up & back
  - 4cm away from mid line post. (we have an anterior mid-sagittal line and posterior mid-sagittal near the dorsal spine of vertebra)
- Lat.end lower end
  - in left mid axillary line (from the apex of axilla downward in the middle)

Location of pancreas

- Lt hypochondrium
- It lies just beneath the left half of the diaphragm
- under the 9th, 10th, and 11th ribs.
- Its long axis parallel to the 10th rib
- Medial end is 4 cm away from mid line post
- Lat.end is in left mid axillary line

Blood supply of spleen

- The large splenic artery is the largest branch of the celiac artery.
- It has a tortuous course
- It runs along the upper border of the pancreas
- The splenic artery then divides into about six branches, which enter the spleen at the hilum



Venous drainage of spleen

- The splenic vein leaves the hilum receives 5-6 tributaries and runs behind the tail and the body of the pancreas.
- Behind the neck of the pancreas, the splenic vein joins the superior mesenteric vein to form the portal vein

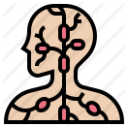

Lymphatic Drainage of spleen mixed

- The lymph vessels emerge from the hilum and pass through a few lymph nodes along the course of the splenic artery and then drain into the celiac nodes.
- Splenic lymph node → pancreatic lymph node → pancreaticosplenic lymph node → superior mesenteric lymph node → then celiac lymph nodes

Nerve Supply of spleen

- The nerves accompany the splenic artery and are derived from the celiac plexus
- Sympathetic and parasympathetic through celiac plexus which goes with blood vessels to the target organ

Sorry for mistakes good luck
No pictures to make it as short as possible
You can go back to the slides
Link for extra pictures I collect from kenhub
https://drive.google.com/file/d/1CTHGnrFVpzwe_O1aPaRAy_gPILetSPnK/view?usp=sharing