




# GIS 5

## ANATOMY



**Done by:** Manar Saddam

**Scientific Correction:** Taima Bader

**Gramatical Correction:** Taima Bader

**Doctor:** Mohammad Al-Muhtasib

## Quick revision:

In the last lecture we talked about inguinal triangle. we mentioned that there are 2 types of hernias:

- 1) **Direct Hernia:** Usually caused due to weakening of abdominal muscles in elderly.
- 2) **Indirect Hernia:** Not caused by weakened abdominal muscles. Instead, it occurs because the deep inguinal ring fails to close up.

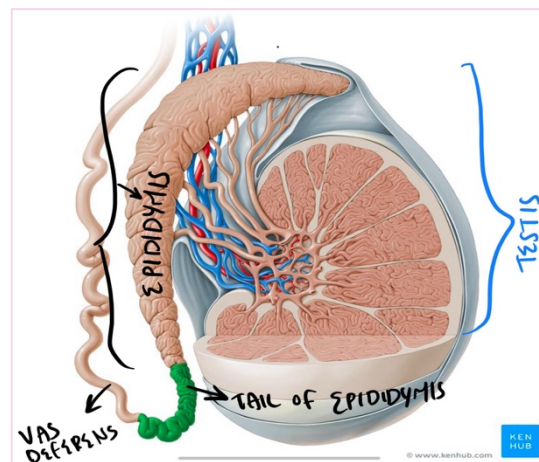
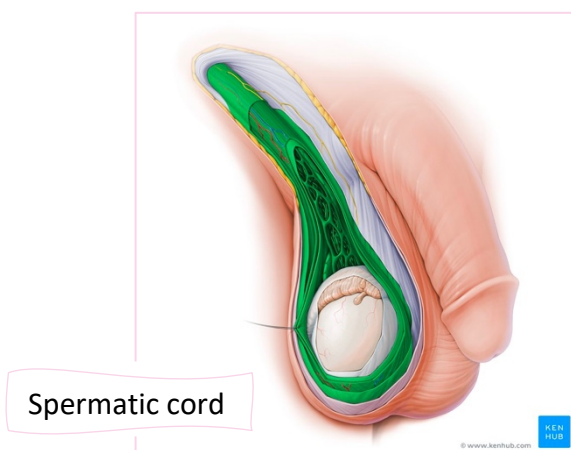
## Spermatic cord:

Collection of structures that pass through the inguinal canal to and from the testis, begins at deep inguinal ring lateral to the inferior epigastric artery and ends at the testis.

⇒ The function of **testis** is formation of **sperms**, which then go to **epididymis**, located on top of testis, and their maturation takes place there.

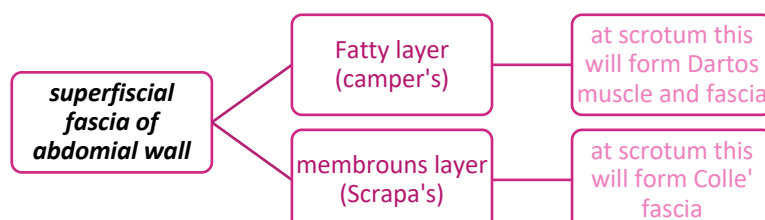
⇒ From the tail of epididymis, **Vas deferens** continues as a 45cm long muscular tube, which then moves inside the spermatic cord toward the superficial inguinal ring → inguinal canal → deep inguinal ring. When it reaches behind urinary bladder it ends in **seminal vesicles**.

⇒ Sperms continue inside right and left **ejaculatory ducts** → those ducts open in prostatic urethra → sperms get outside the body in preparation for ejaculation.



## Covering of spermatic cord:

The covering of spermatic cord consists of three concentric layers of fascia derived from the layers of the anterior abdominal wall; each layer is acquired as the Processus vaginalis descends through the layers of abdominal wall into the scrotum.



Skin and superficial fascia of anterior abdominal wall will continue to give skin and superficial fascia of scrotum and covering of testis.

### Scrotum and coverings of testis:

#### 1-Skin

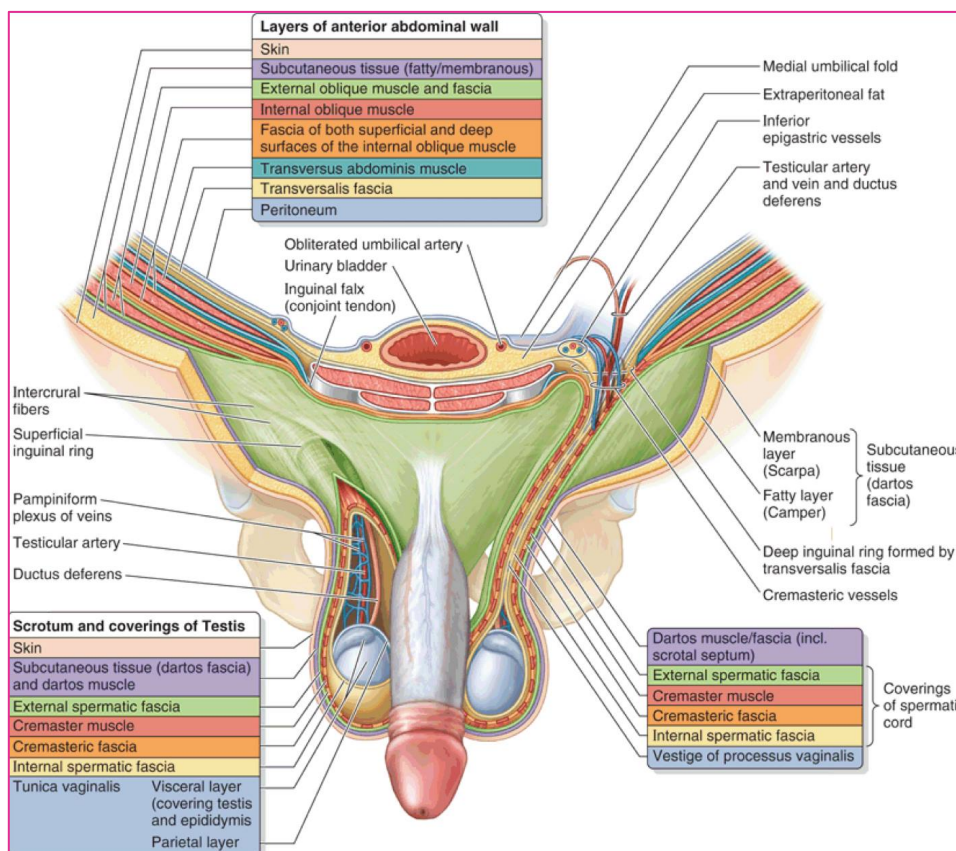
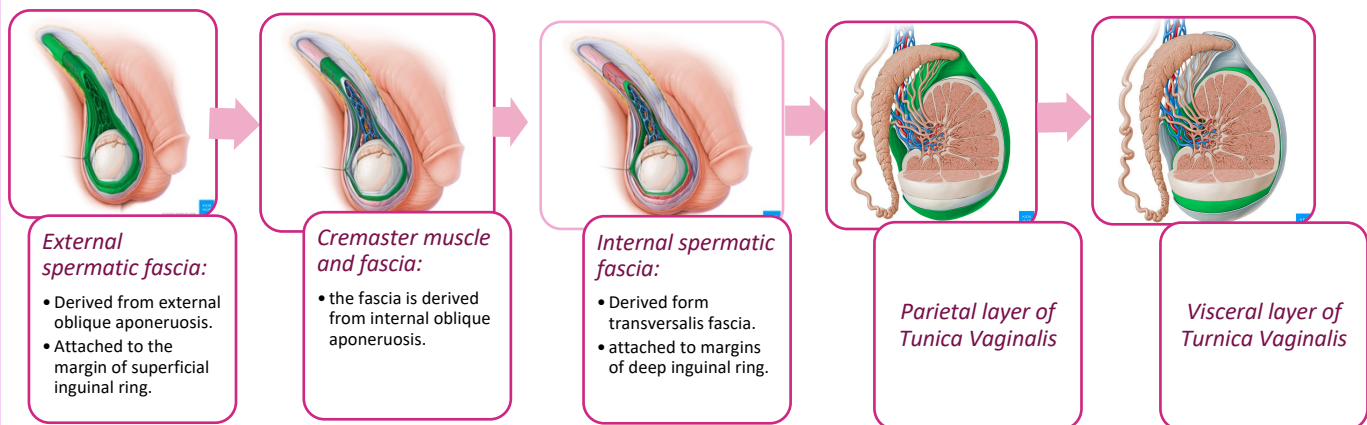
#### 2- Dartos muscle and fascia [this is what causes wrinkling of skin of scrotum]

#### 3- Colles' fascia [innervated by sympathetic fibers around testicular artery]

#### 4-External spermatic fascia 5-Cremasteric muscle and fascia

#### 6- Internal spermatic fascia

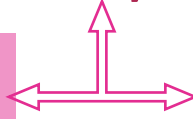
7-Tunica Vaginalis: A) parietal layer B) Visceral layer (covers epididymis and the anterior, medial and lateral surfaces of each testis). We know that Processus Vaginalis undergoes obliteration, but the distal part of it forms Tunica vaginalis.



## Contents of Spermatic Cord:

- 1) **Testicular Artery:** branch of abdominal aorta (L2) → moves through deep inguinal ring → Inguinal Canal → Superficial Inguinal ring → supplies Testis and Epididymis
- 2) Vein that drains Testis and epididymis → then forms Pampiniform Plexus in spermatic cord → superficial inguinal ring → Inguinal Canal → at level of Deep Inguinal ring it becomes one vein [**Testicular Vein**].

At the right side it ascends obliquely to drain into **Inferior Vena Cava**.



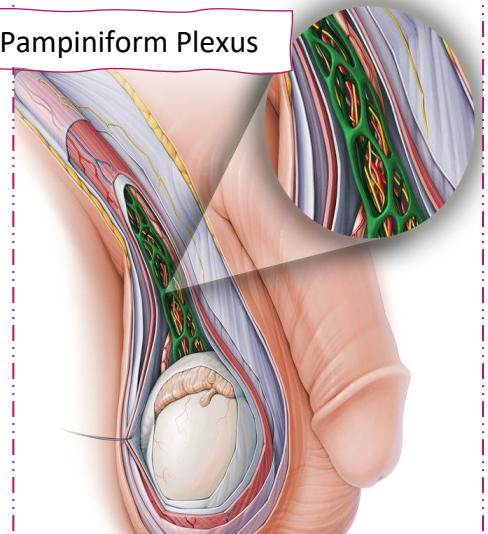
At the left side it ascends perpendicularly to drain into **Left Renal Vein**.

### **Clinical Note:**

Sperms formation in Testis occurs at **2-3 degrees** below body temperature, that's why Testis is outside the body in the Scrotum. Because left Testis is shorter, and Left Testicular Vein ascends perpendicularly to left Renal Vein → **Higher blood pressure** → **Varicoceles** [Enlargement of Vein] are much more common in left side than right side → Varicoceles leads to **increased temperature** → Low sperms production → **Infertility**.  
By surgical removal of varicoceles patient is fertile again.

- 3) **Sympathetic fibers** run with Testicular artery  
From renal or aortic sympathetic plexus  
→ Vasomotor and sensory → Innervates superficial fascia of scrotum [Dartos and Colles' Fascia]/ Tunica Vaginalis/ Cremasteric muscle.
- 4) **Processus Vaginalis:** An out pouching of peritoneum in the fetus which is responsible for the formation of inguinal canal.

Pampiniform Plexus



### **Embryology:**

- Testes and ovaries develop in posterior abdominal wall at level of L1 → at 8 months of pregnancy Processus Vaginalis pulls testis downward to Deep Inguinal Ring → Inguinal Canal → Superficial Inguinal Ring → scrotum.
- In females → ovaries are pulled to ovarian fossa in pelvis.

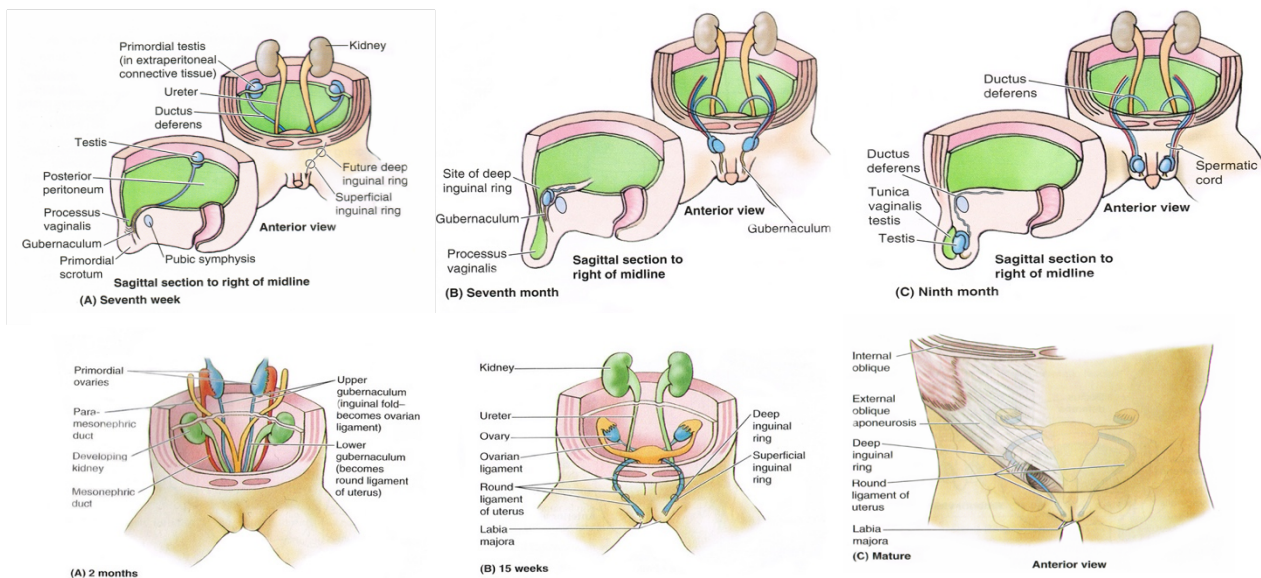
At birth, Doctor checks if Testis is placed in scrotum, if not surgery must be done to put them back in place.

Once testis reach Scrotum, Processus Vaginalis undergoes obliteration and fibrosis, to close up the Deep Inguinal Ring, if this process fails → Congenital Indirect Hernia.

### **Note:**

Pictures below are about developing of Processus Vaginalis and how does it form Inguinal canal, the Doctor said read them. So, here's a link that explains it in case you want to read about it.

<http://inguinalhernias.weebly.com/2-development-of-the-inguinal-canal.html>



## 5) Vas Deferens

## 6) Artery of vas Deferens.

## 7) Cremasteric Artery: supplies cremasteric muscle.

## 8) Genital Branch of genitofemoral Nerve [ L1 / L2]:

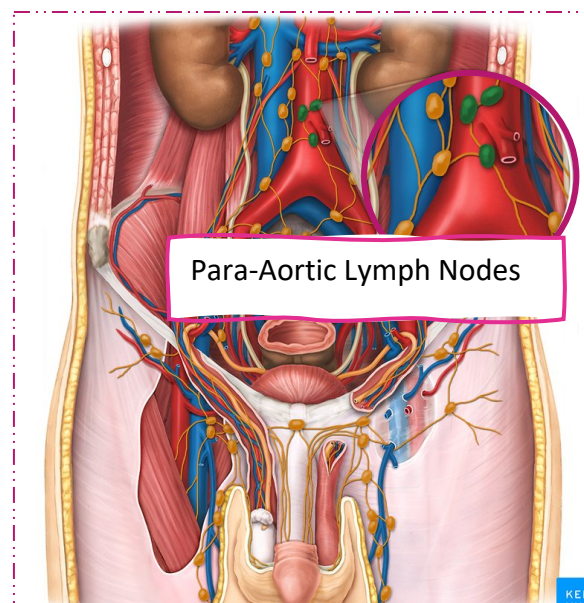
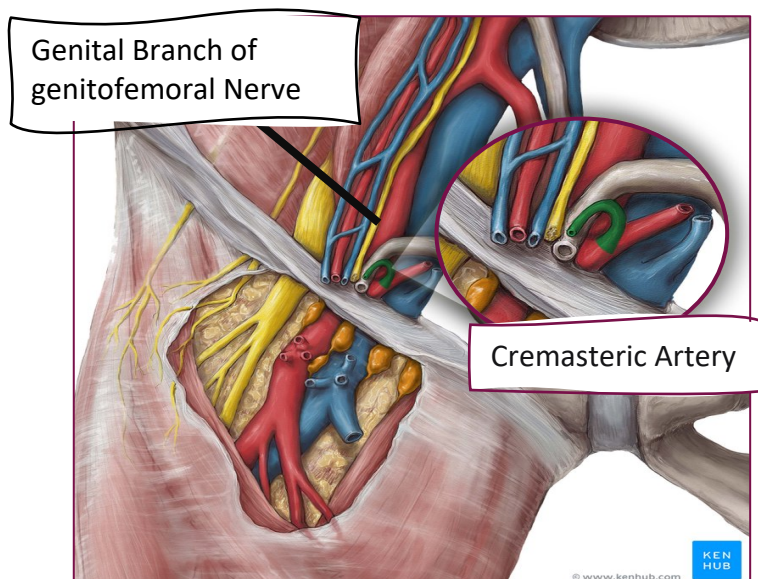
This nerve supplies cremasteric muscle which when contracts elevates testis especially in cold weather. In contrast, this muscle relaxes in hot weather to push testicles farther from the body to cool off.

There's something known as Cremasteric Reflex, itching of upper medial side of the thigh leads to contraction of cremasteric muscle and elevation of testis, How?

Itching → Femoral branch of genitofemoral nerve → reach spinal cord → then returns by genital branch of genitofemoral → Contraction of Cremasteric muscle.

## 9) Testicular Lymph Vessels:

- Drain lymphatics from testis and epididymis → Ascends through inguinal canal → passes up over the posterior abdominal wall → Lumbar Para-Aortic Lymph Nodes (L1)
- Lymphatic drainage of skin of scrotum → Inguinal Lymph Nodes in femoral triangle.

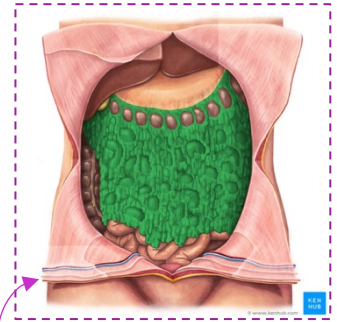
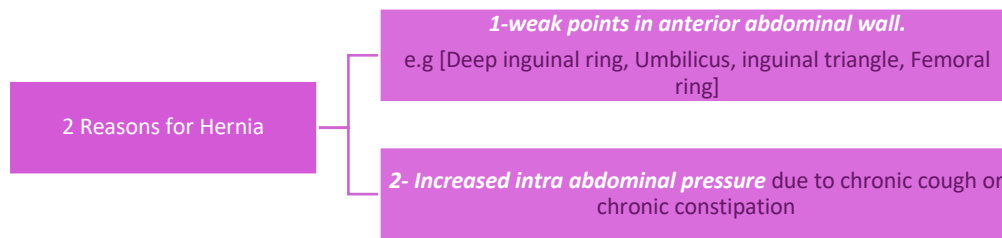


The end of lecture 4

Now let's start with lecture 5,

## Hernia:

A hernia is protrusion of part of peritoneum and abdominal viscera beyond the normal confines of the abdominal wall.



Hernia consists of 3 parts:

- **The Sac:** Pouch [Diverticulum] of peritoneum.
- **Contents of the Sac:** Small intestine or greater Omentum (a fold of visceral peritoneum that hangs down from stomach).
- **Covering of the Sac:** Derived from layers of anterior abdominal wall which the hernial sac passes.

### Indirect Inguinal Hernia:

*The most common form of Hernia, it is of congenital origin, also it's more common at right side than left side? Because of delayed descent of the right testicle.*

*The Hernia moves through deep inguinal ring lateral to inferior epigastric vessels → Inguinal canal → may stay along inguinal canal or extend as far as superficial inguinal ring.*

#### Causes:

- A) Fail in the obliteration of Processus Vaginalis → **Congenital Indirect inguinal hernia, and it's usually bilateral.**
- B) Increased intrabdominal pressure like in chronic smokers → chronic cough → Deep inguinal Ring opens because peritoneum and abdominal viscera **put pressure on it** → when small intestine pass through this opening → Hernia, this hernia will continue to grow if untreated. Also, chronic constipation raises the intrabdominal pressure.
- C) In females it's very **rare** to happen, but if it did then the sac will move through deep inguinal ring → inguinal canal → **Labia majora**.

**The hernia of this type either:** → Moves at sides of spermatic cord.

→ Or enters between structures(contents) of spermatic cord.

If surgery done to treat hernia that's inside the spermatic cord cautions must be taken because **Vas deferens** is there and any cut will lead to infertility.

Some people do this in purpose for male sterilization or permanent contraception in process called Vasectomy in which Vas deferens is cut and tied to prevent sperms transportation to urethra.

→ **Relations: Indirect Hernia passes laterally to inferior epigastric artery**

→ Since Indirect Inguinal Hernia descends downward/forward/Medially, then we can push it back (reduction) upward/backward/laterally.

## Direct Inguinal Hernia:

*Happens in Inguinal Triangle, it reaches Superficial Inguinal Ring without passing through Deep Inguinal Ring* → Direction: Forward only, so retraction is backward.

### *Common scenario:*

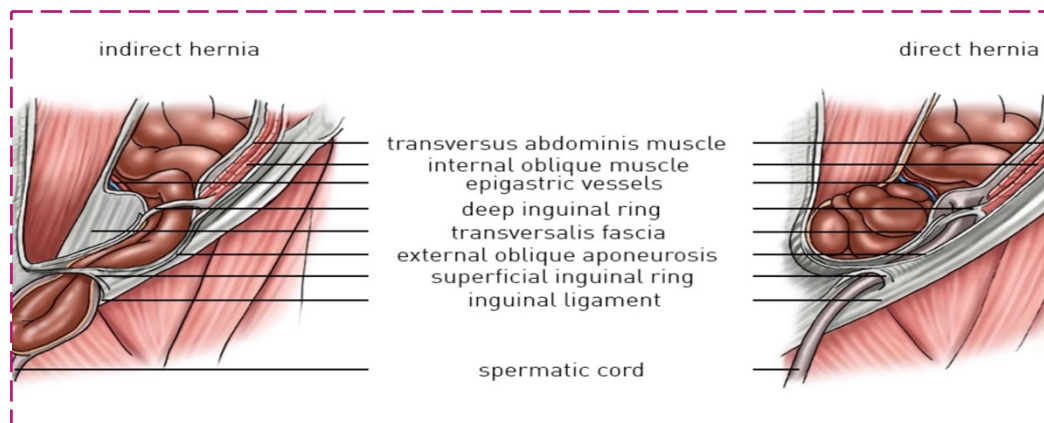
Old male patient (rare in women) → his abdominal muscles are weak due to old age → he also has chronic constipation → Increased intrabdominal pressure → Hernia.

### *Relations:*

- Posterior to Inguinal Canal
- Medial to inferior epigastric artery

### *Note:*

Neck of Direct hernia is wider than neck of Indirect form? Because the neck of indirect hernia is at level of Deep ring, which is narrow. While the neck of direct hernia is at inguinal triangle which is wide area.



### *Comparison between Direct and Indirect Inguinal Hernia:*

	Direct Inguinal Hernia	Indirect Inguinal Hernia
<b>Age</b>	Common in old	young
<b>Bilaterally</b>	Usually bilateral	If acquired: unilateral If congenital: bilateral
<b>Shape</b>	Hemispherical	Oval
<b>Reaches scrotum</b>	Never	Can reach the scrotum
<b>Direction of descent</b>	Forwards	Downwards/Forwards/Medially
<b>Reduction</b>	Backwards	Upwards/Backwards/Laterally
<b>Relation to Inf.epigastric artery</b>	Medially	laterally
<b>Superficial ring test</b>	Feel impulse on the side of finger	Feel impulse on the tip of finger
<b>Deep ring test</b>	If pts coughs, hernia will reoccur after reduction	If pts coughs, hernia won't appear after reduction

### Notes concerning the table above:

Superficial and Deep inguinal rings tests used to differentiate between direct and indirect Hernias:

#### ⇒ Superficial Ring test:

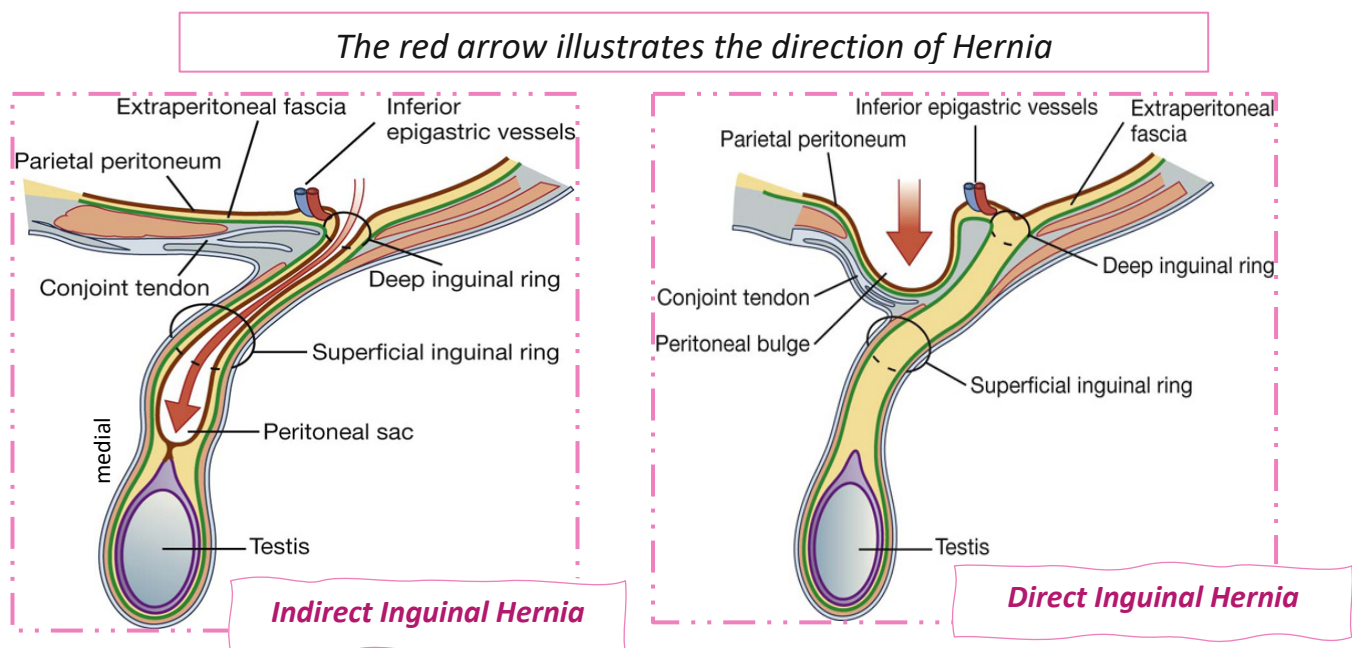
When you reduce the Direct hernia backward you will feel the pulse of the inferior epigastric artery at sides of your finger.

But when you reduce the Indirect hernia upwards/backwards/laterally you will feel the pulse at the tip of your finger.

#### ⇒ Deep Ring test:

This test is more specific, depends on the fact that Indirect hernia pass through the deep ring while Direct hernia doesn't. After reduction of hernia put pressure using your finger on the deep ring to close it **[1 finger above the pulse of femoral artery]**, then ask the pts to cough, if hernia occurs again → this indicates that hernia originates from another opening and the pressure you exerted on deep ring is useless → Direct hernia.

If pts coughs and Hernia doesn't appear then → Indirect hernia.



### Scrotum:

Is an outpouching of the lower part of anterior abdominal wall.

Contents: **1**- Testis              **2**-Epididymis              **3**-lower end of spermatic cord and its contents

#### **As we mentioned before the scrotum wall has the following layers:**

Skin → Dartos muscle and fascia [this what causes wrinkling of scrotum and gives colour of skin due to presence of melanocytes] → Colle's fascia → 3 layers that covers the spermatic cord, External spermatic fascia, cremasteric muscle and fascia, Internal spermatic fascia → Tunica Vaginalis [ parietal layer → Visceral layer]

**Note:** A ridge in the midline indicates the line of fusion of the two lateral labioscrotal swellings.

### Pathology:

Hydroceles: Accumulation of fluid between 2 layers of Tunica Vaginalis the parietal and visceral layer, which will cause enlargement of scrotum.

### Causes:

-Happens due to abnormalities in **Processus Vaginalis**, recall that the distal part of it forms Tunica Vaginalis, so if it gets narrowed → congenital hydrocele. If both the lower and upper part get obliterated while the mid part remains open → Encysted hydrocele.

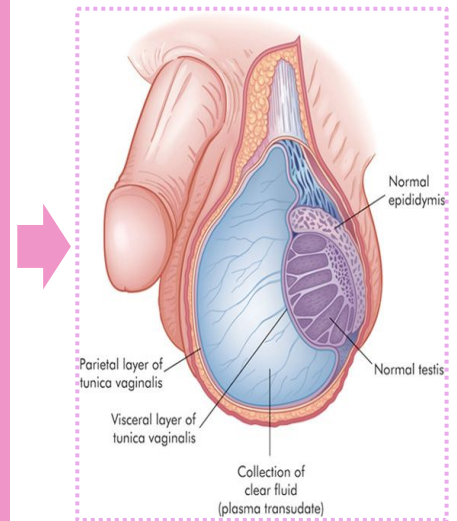
-inflammatory      -idiopathic

### Clinical examination:

There will be enlargement of scrotum, if you used a torch and directed the light on scrotum you will notice transparency, which indicates presence of fluid [Extra: no light transmission indicates tumor].

### Treatment:

Aspiration, the needle will penetrate all the layers to reach the fluid, Except Visceral layer of Tunica Vaginalis.

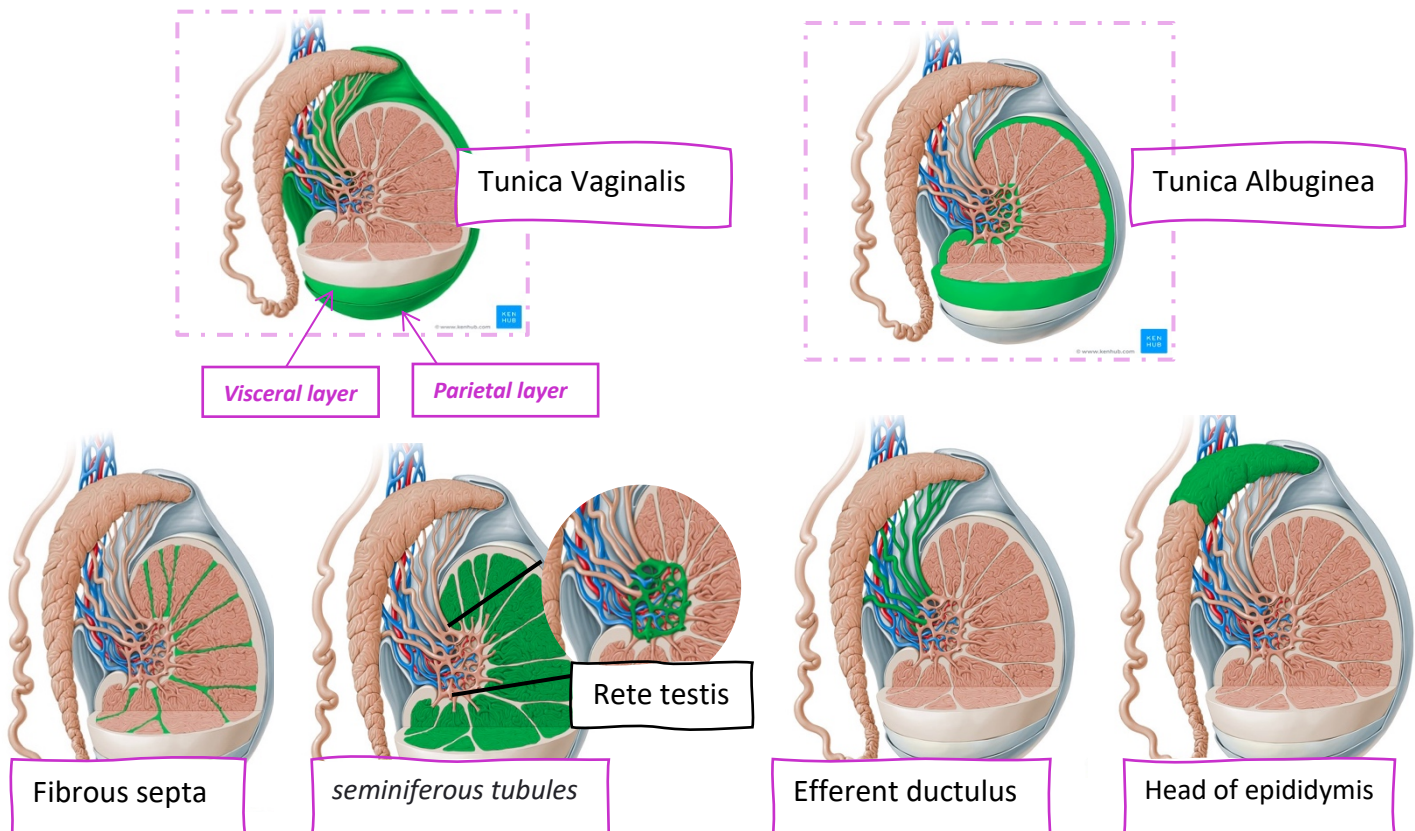


## Testes:

Testes are **firm, mobile** organs within the **scrotum**, **2 in number** separated by a **septum** formed by **superficial fascia** (*Dartos muscle and Colle's fascia*). **Left** testis usually lies at a **lower level** than the **right** testis, and it descends earlier also.

Following the visceral layer of Tunica Vaginalis → The testes are surrounded by a **tough fibrous** capsule **Tunica Albuginea** → It sends a series of **fibrous septa** dividing the interior of the testis into **lobules** → In each **lobule**, there are 1-3 coiled **seminiferous** tubules → Tubules open into a network of channels called the **rete testis** → Small **efferent ductulus** connect the rete testis to the head of the epididymis.

Check figures below for more explanation:



### Structures inside the testes:

**1- Seminiferous tubules:** Thin, highly coiled structures where **sperm production** occurs.

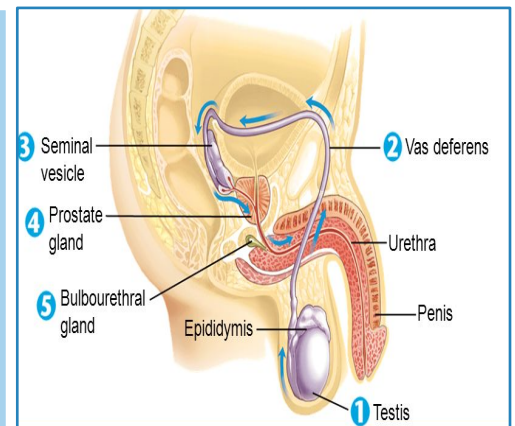
**2- Interstitial cells:** Major source of **androgens [Male hormones]** located between seminiferous tubules.

**3- Epididymis:** Site of sperm **maturation** (10-14 days), It has a head, body, and tail where vas deferens begins.

**4- Vas deferens:** carries mature sperms. It starts from tail of epididymis and ends in urethra (*seminal vesicle*). And travels through the spermatic cord.

### Sperms pathway:

*Seminiferous tubules* produce spermatozoa → collected in *Rete testis* → *Efferent ductulus* → *epididymis* [Maturation] → *Vas deferens* → *seminal vesicle* → right and left *ejaculatory ducts* → *prostatic urethra* → Semen travels through membranous urethra → penile urethra → outside the body



### Blood supply and venous drainage of testes:

- I. **Blood supply** → Testicular artery [on each side], branch of abdominal aorta [L2].
- II. **Venous drainage** → Pampiniform plexus → Testicular vein, right side drains into Inferior Vena Cava, while left side drains into left Renal Vein.

### Nerve supply:

- I. **Testes** → Sympathetic fibers around Testicular Artery [Vasomotor/sensory]
- II. **Scrotum** → Same **sympathetic fibers** to testes. In addition to **ilioinguinal nerve** [L1] and **genital branch of genitofemoral nerve** [which also supplies cremasteric muscle].

### Lymphatic Drainage:

- I. **Testes:** Drainage follows **testicular arteries** and ends in the lymph nodes on the sides of the aorta at level L1 (**para-aortic nodes**).
- II. **Scrotum + skin:** Lymph drains into the **inguinal lymph nodes** in the femoral triangle.

### **Clinical Note:**

If there's a tumor in the testes → Enlargement will be seen in Para-Aortic Lymph Nodes

If the tumor was in the skin of scrotum → Enlargement of Inguinal Lymph nodes in femoral triangle.

## Congenital abnormalities of the testes:

### 1- Cryptorchidism

*Incomplete descent* of the testis, although it travels down the normal pathway. it may be found in the:

A) abdominal cavity B) inguinal canal C) superficial inguinal ring D) upper part of the scrotum

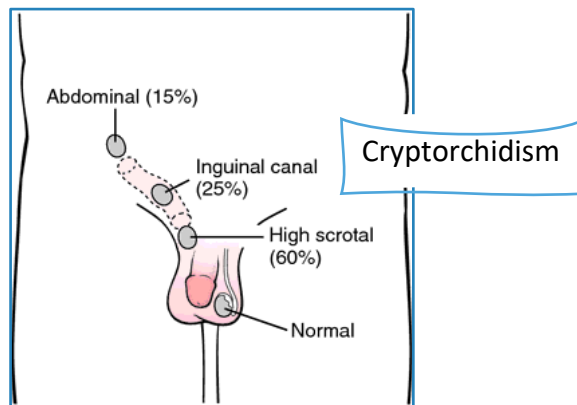
---

### 2- Maldescent

Testes travel down an **abnormal pathway**; it may be found in the:

A) superficial fascia B) the root of the penis C) perineum D) the thigh.

It is *more serious than* Cryptorchidism requiring an immediate operation. If the testis remains in an abnormal position beyond 6 years, this will impair the production of testosterone.



#### Extra info about hydroceles:

During development, each testicle has a naturally occurring sac around it that contains fluid. Normally, this sac closes itself and the body absorbs the fluid inside during the baby's first year, if not → Hydrocele.

Hydroceles can be also acquired later in life → This usually occurs if the channel through which the testicles descend hadn't closed all the way and fluid now enters, or the channel reopens. This can cause fluid to move from the abdomen into the scrotum.

# THE END