GIS 1

HISTOLOGY

Done by: **Mohammed bushnaq**

Scientific Correction: **Mahmoud odeh**

Gramatical Correction: **Mohammad abuhalaweh**

Doctor: **Mohammed Al-muhtaseb**

In this course we will take 3 histology lectures of GI tract, firstly in this lecture we will talk about **salivary glands:**

The most important objective in studying histology of the GI tract is that Histology is important for knowing types of cells in the GI tract and thus enabling us to determine the structure of the different parts/organs, and the key idea is that structure helps us to determine the function (structure-function relationships).

Examples on the Function-Structure Relationship:

- Protection: Hard stool may lead to injury in the anal canal. However, it has stratified lining which means that it has greater ability to undergo mitosis and regeneration (esophagus if injured, its cells can undergo mitosis to replace injured cells, as well as the oral cavity).

- Secretions from glands in both stomach and small intestine (helps in digestion)

- Absorption:
    a. Occurs in small intestine, because of the presence of fingerlike projections (villi), the surface area of absorption is increased.
    b. In duodenum Submucosa, we find Brunner's gland, that helps in protection and in duodenum's function in absorption.
    c. Absorption and protection in large intestine (colon) aided by mucus which is secreted by goblet cells ((mucus for lubrication).

Some clinical problems:
Gastric Ulcer: occurs in stomach, and it is very rare.
Peptic ulcer: (aka duodenal ulcer) it is more common, why? Because the Chyme (digested bolus) that comes from the stomach is very acidic and usually it is being neutralized in the duodenum with alkaline secretions, but hyperacidity can lead to ulcer especially in the first inch of duodenum.

The digestive system consists of the digestive tract—oral cavity, esophagus, stomach, small and large intestines, rectum, and anus—and its associated glands—salivary glands, liver, and pancreas.
• Its function is to obtain the molecules necessary for the maintenance, growth, and energy needed by the body from ingested food.

• Large molecules such as proteins, fats, complex carbohydrates, and nucleic acids are broken down into small molecules that are easily absorbed through the lining of the digestive tract, mostly in the small intestine.
• Water, vitamins, and minerals are also absorbed from ingested food. In addition, the inner layer of the digestive tract is a protective barrier between the content of the tract's lumen and the internal milieu of the body.

Then through portal vein, these molecules will leave the blood and go to the liver, for storage, formation of enzymes and hormones, detoxification, vitamins formation, metabolic pathways or other functions.

The GIT is a hollow tube with a lumen of variable diameter and a wall made up of four main layers: mucosa, submucosa, muscularis (externus) , and serosa.

Histology of upper GI differs from lower GI (structure-function relationship)
- From mouth (the oral cavity) all the way to Esophagus: nonkeratinized stratified squamous tissue.
- Stomach: simple columnar epithelium without goblet cells.
- Small intestine: simple columnar epithelium with goblet cells.
- And as we go lower and lower, the number of goblet cells increases, eg: in colon you can find numerous goblet cells for lubrication.
- Anal canal like oral cavity: nonkeratinized stratified squamous tissue.

1-**Mucosa (mucous membrane):** it divided into 3 sublayers:

A. **epithelial lining**: each part has its own type (ex: stomach has simple columnar epithelium without goblet cell, but from mouth to esophagus is lined by stratified squamous non-keratinized).
B. **lamina propria**: loose areolar connective tissue rich in blood and lymph vessels and smooth muscle cells, sometimes also it contains **glands** (important for secretion) and lymphoid tissue.
   - intestinal glands are called Lieberkühn Crypts.
   - chief cells secrete pepsinogen.
   - parietal cells secrete HCl.
C. **muscularis mucosae**: usually made of a thin inner circular layer and an outer longitudinal layer of smooth muscle. It changes the shape of lumen (helps in peristaltic movement).

2-Submucosa: composed of dense connective tissue with many blood and lymph vessels and a submucosal (Meissner's) nerve plexus (which is located between the submucosa and the external muscle), It may also contain glands and lymphoid tissue.

There are glands in the submucosa of esophagus and duodenum (unlike the mucosa as it contains glands in all the organs),Meaning that both the esophagus and duodenum have glands in their mucosa and submucosa.

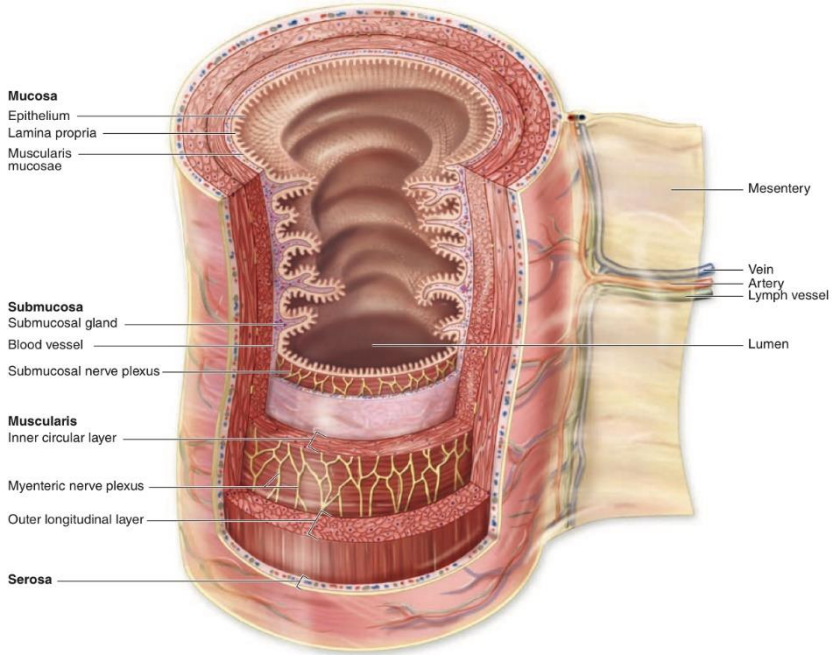

• The submucosal gland of duodenum is known as Brunner's gland, it secretes alkaline secretions to neutralize the acidic chyme of stomach when reaches duodenum (in addition to mucosal glands).
Esophageal cardiac gland in submucosa (there are mucosal esophageal glands, too).

3-Muscularis (Muscularis externa): it is composed of smooth muscle cells organized as two sublayers: in the internal sublayer (close to the lumen), the fiber orientation is generally circular and in the external sublayer it is longitudinal. Also, it contains the myenteric (or Auerbach's) nervous plexus, which lies between the two muscle sublayers.

4-Serosa: also called mesothelium, is a thin layer of loose connective tissue rich in blood and lymph vessels, adipose tissue, and a simple squamous covering epithelium

In the abdominal cavity, the serosa is continuous with the mesenteries (a double fold of peritoneum that attaches the intestine to the posterior abdominal wall) and with the peritoneum. However, In places where the digestive organ is bound to other organs or structures the serosa is replaced by a thick adventitia, consisting of connective tissue containing vessels and nerves, without the mesothelium, example: the oral cavity, thoracic esophagus, ascending colon, descending colon and rectum.

Basic mucosal forms in the GI tract:

• Protective: stratified squamous epithelium that is found in the oral cavity, pharynx, the esophagus and the anal canal
• Secretory: the mucosa consists of a long closely packed tubular glands, found in the stomach.
• Absorptive: the mucosa is arranged in a fingerlike projections called villi with intervening short glands called crypts, that is typical for the small intestine.
In the duodenum some crypts extend from the muscularis mucosa to the submucosa (Brunner's Glands).
• Absorptive/protective: the mucosa is arranged into closely packed tubular glands special for water absorption and mucus secreting goblet cells.
It lines the whole large intestine.

Now let's talk about **oral cavity**:
• The oral cavity is lined with stratified squamous epithelium, keratinized or non-keratinized depending on the region. It has the same layers as the 4 lined layers of the GI tract because it is part of it, after the 4 layers there is a voluntary muscle which is the buccinator (supplied by buccal branch from facial).
• The keratin layer protects the oral mucosa from damage during masticatory function and is present mostly in the gingiva (gum) and hard palate. Lamina propria in these regions has several papillae and rests directly on bony tissue.
• The Non-keratinized squamous epithelium covers the soft palate, lips, cheeks, the floor of the mouth and the cleft (groove) of the papilla. The Lamina propria has papillae similar to those in the dermis of the skin and is continuous with a submucosa containing diffuse small salivary glands.
• The soft palate has a core of skeletal muscle, numerous mucous glands, and lymphoid nodules in its submucosa.

by taking a **lip** section, we can see:
- Outer layer: skin (with sebaceous glands, hair follicles…
- Internal mucous surface has lining mucosa with a thick, non-keratinized epithelium and many minor labial salivary gland.
- Voluntary Orbicularis oris muscle.
- Red region (vermillion/ transitional zone) modified skin with no hair follicles, no sebaceous glands, rich in blood vessels, and highly sensitive (nerve terminals), this is why it occupies large area in the brain, despite its small size.

Tongue: is a mass of striated muscle covered by a mucous membrane whose structure varies according to the region, the muscle fibers cross one another in three planes; they are grouped in bundles, usually separated by connective tissue. Because the connective tissue of the lamina propria penetrates the spaces between the muscular bundles the mucous membrane is strongly adherent to the muscle. The mucous membrane is smooth on the lower (ventral) surface of the tongue.

The Lower surface of the tongue (mucosa, nonkeratinized) and the upper dorsum (parakeratinized: partially keratinized epithelium), The tongue's dorsal surface is irregular, covered anteriorly by a great number of small eminences called papillae. The posterior one-third of the dorsal surface of the tongue is separated from the anterior two-thirds by a V-shaped boundary (sulcus terminalis).

• Behind this boundary, the surface of the tongue shows small bulges composed <u>mainly of two types of small lymphoid aggregations:</u>

- small collections of lymphoid nodules
- the lingual tonsils, where lymphoid nodules aggregate around invaginations (crypts) of the mucous membrane.

Now in the anterior two thirds we have **papillae**:

Papillae are elevations of the oral epithelium and lamina propria that assume various forms and functions. There are four types:

1-Filiform papillae have an elongated conical shape, they are quite numerous and are present over the entire surface of the tongue. Their epithelium, which does not contain taste buds, is keratinized.

2- Fungiform papillae resemble mushrooms; they have a narrow stalk and a smooth-surfaced, dilated upper part, these papillae, which contain scattered taste buds on their upper surfaces, are irregularly interspersed among the filiform papillae.

3- Foliate Papillae: poorly developed in humans, consist of two or more parallel ridges and furrows on the dorsolateral surface of the tongue and contain many taste buds.

4- Circumvallate papillae: (surrounded by circular groove, they are where we find taste buds at medial side of papilla) Circumvallate is circular, but you can see two clefts/ grooves/sulcuses in some sections, they have taste buds at both sides of papilla.

• All of them are innervated by chorda tympani except the circumvallate (by glossopharyngeal).

• They are distributed in the V region in the posterior portion of the tongue.

• Numerous serous (von Ebner's) glands drain their contents into the deep groove that encircles the periphery of each papilla.

• This moatlike arrangement provides a continuous flow of fluid over the great number of taste buds present along the sides of these papillae.
• The glands also secrete a lipase that probably prevents the formation of a hydrophobic layer over the taste buds that would hinder their function.
• This flow of secretions is important in removing food particles from the vicinity of the taste buds so that they can receive and process new gustatory stimuli. Along with this local role, lingual lipase is active in the stomach and can digest up to 30% of dietary triglycerides.
• Other small mucous salivary glands dispersed throughout the lining of the oral cavity act in the same way as the serous glands associated with this type of papillae to prepare the taste buds in other parts of the oral cavity, such as the anterior portion of the tongue to respond to taste stimuli.

• The arrow which says (vallate papilla) from both sides, you can find a groove (named here as the circular sulcus), the part of the vallate which faces the groove is the medial wall of and it is made of parakeratinized BUT the lateral wall of circumvallate (the arrow which says the circular wall) is made of nonkeratinized epithelium because it is deep, and not likely to be injured. (according to sheet 016).

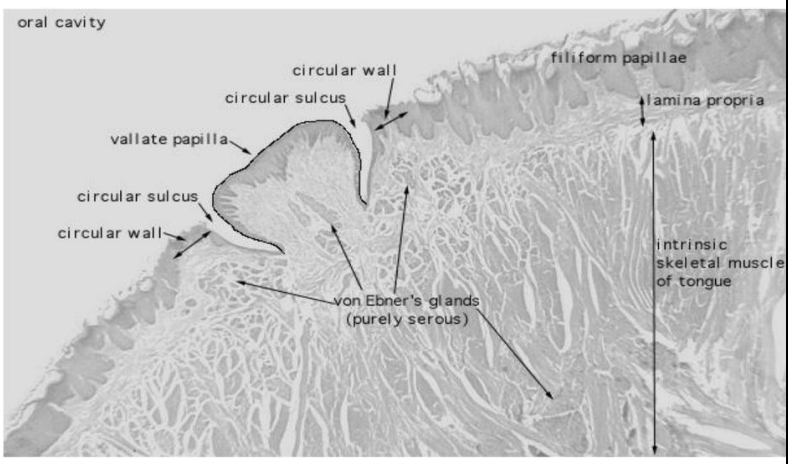

<u>Types of Cells responsible for taste:</u>
- In center (bipolar cell/ gustatory cell): It is known as gustatory microvillus, Microvilli from each taste cell projects into the taste pore and here starts chorda tympani (branch of facial nerve).
- Supporting cells (around the gustatory/ bipolar cells).
- Basal cells (basal stem): active in mitosis to regenerate the two previous cells (gustatory and supporting (according to sheet016).

• Now let's talk about **salivary glands**:
We produce about 8-10 liters of saliva per day.
- Parotid: serous secretion, its duct opens at the vestibule of mouth (at the level of upper second molar).
- Submandibular: mixed, 70% serous and 30% mucous.
- Sublingual: mucous mainly, 10% serous.

In humans, the minor salivary glands secrete 10% of the total volume of saliva, but they account for approximately 70% of the mucus secreted.
Dehydration leads to dryness which leads to growth of bacteria, especially when immunity weakens, we have bacteria everywhere in our body, they are opportunistic waiting for your immunity to weaken (Helicobacter pylori in stomach is normally nonpathogenic unless in cases of immunosuppression, they are activated and may cause gastritis.
The striated ducts of each lobule converge and drain into ducts located in the connective tissue septae separating the lobules, where they become interlobular or excretory ducts.
General histology:
• They are initially lined with pseudostratified or stratified cuboidal epithelium, but the more distal parts of the excretory ducts are lined with stratified columnar epithelium containing a few mucus-secreting cells.
• The main duct of each major salivary gland ultimately empties into the oral cavity and is lined with nonkeratinized-stratified squamous epithelium. Vessels and nerves enter the large salivary glands at the hilum and gradually branch into the lobules.
• A rich vascular and nervous plexus surrounds the secretory and ductal components of each lobule.
• The capillaries surrounding the secretory end pieces are very important for the secretion of saliva, stimulated by the autonomic nervous system.
• Parasympathetic stimulation, usually through the smell or taste of food, promotes vasodilation and a copious watery secretion content. Sympathetic stimulation produces small amounts of viscous saliva, rich in organic material.
• Acinus (many acini) system: is a group of cells acting as one unit draining into ducts (directed into a lumen). Salivary glands are all with secretory acinus which drain into ducts that drain into the oral cavity (acini contains serous, mucous secretory cells or both) as well as myoepithelial cells all surrounded by basement membrane.
(This structure can be thought of as a grape attached to its stem; the stem corresponds to the duct).
-Serous cells: are usually pyramidal in shape, with a broad base resting on the basal lamina and a narrow apical surface with short, irregular microvilli facing the lumen. They exhibit characteristics of polarized protein-secreting cells.

-Mucous cells: are usually cuboidal to columnar in shape, their nuclei are oval and pressed toward the bases of the cells.
They exhibit the characteristics of mucus-secreting cells containing glycoproteins important for the moistening and lubricating functions of the saliva.

Most of these glycoproteins are called mucins and contain70-80% carbohydrate moieties in their structure. Mucous cells are most often organized as tubules consisting of cylindrical arrays of secretory cells surrounding a lumen.

Myoepithelial cells:

• Are found between the basal lamina and the basal plasma membrane of the cells forming secretory end pieces and intercalated ducts (to a lesser extent), which form the initial portion of the duct system.

• Myoepithelial cells surrounding each secretory portion, usually two to three cells per secretory unit, are well developed and branched (and are sometimes called basket cells).

• Whereas those associated with intercalated ducts are spindle shaped and lie parallel to the length of the duct.

• These cells have the ability to divide and differentiate into secretory or ductal cells.

• Intercalated and striated ducts are also called intralobular ducts because of their location within the lobule.

- These cells show several characteristics that resemble smooth muscle cells, including contractility. Also, they establish intercellular junctions among themselves and with secretory cells, such as desmosomes.

- Although the contraction of myoepithelial cells accelerates the secretion of saliva, their main function seems to be the prevention of end piece distention during secretion due to the increase in intraluminal pressure. In the duct system, secretory end pieces empty into the intercalated ducts, lined by cuboidal epithelial cells

• Several of these short intercalated ducts join to form striated ducts characterized by radial striations that extend from the bases of the cells to the level of the central nuclei.

• When viewed in the electron microscope, the striations are seen to consist of infoldings of the basal plasma membrane with numerous elongated mitochondria that are aligned parallel to the infolded membranes; this structure is characteristic of ion-transporting cells

Parotid gland : The parotid gland is a branched acinar gland; its secretory portion is composed exclusively of serous cells

• Containing secretory granules that are rich in proteins and have a high amylase activity which is responsible for most of the hydrolysis of ingested carbohydrates.

• The digestion begins in the mouth and continues for a short time in the stomach, before the gastric juice acidifies the food and thus decreases amylase activity Considerably.

• Intercalated and striated ducts are easily observed within the lobules, due to their length.

• As in other large salivary glands, the connective tissue contains many plasma cells and lymphocytes.
• The plasma cells secrete IgA, which forms a complex with a secretory component synthesized by the serous acinar, intercalated duct, and striated duct cells.
• The IgA-rich secretory complex released into the saliva is resistant to enzymatic digestion and constitutes an immunological defense mechanism against pathogens in the oral cavity.

Submandibular (Submaxillary) **gland**:
The submandibular gland is a branched tubuloacinar gland, its secretory portion contains both mucous and serous cells which are the main component of this gland and are easily distinguished from mucous cells by their rounded nuclei and basophilic cytoplasm.
• Serous cells are responsible for the weak amylolytic activity present in this gland and its saliva
• In humans, 90% of the end pieces of the submandibular gland are serous acinar, whereas 10% consist of mucous tubules with serous demilunes.
• The cells that form the demilunes in the submandibular gland secrete the enzyme lysozyme, whose main activity is to hydrolyze the walls of certain bacteria.
• Some acinar and intercalated duct cells in large salivary glands also secrete lactoferrin, which binds iron, a nutrient necessary for bacterial growth.
• Striated ducts are easily observed in the human submandibular gland, but intercalated ducts are very short.

Sublingual gland:
The sublingual gland, like the submandibular gland, is a branched tubuloacinar gland formed of serous and mucous cells.
• Mucous cells predominate in this gland; serous cells are present almost exclusively on demilunes of mucous tubules.
• As in the submandibular gland, cells that form the demilunes in this gland secrete lysozyme.
• Intralobular ducts are not as well developed as in other major salivary glands.

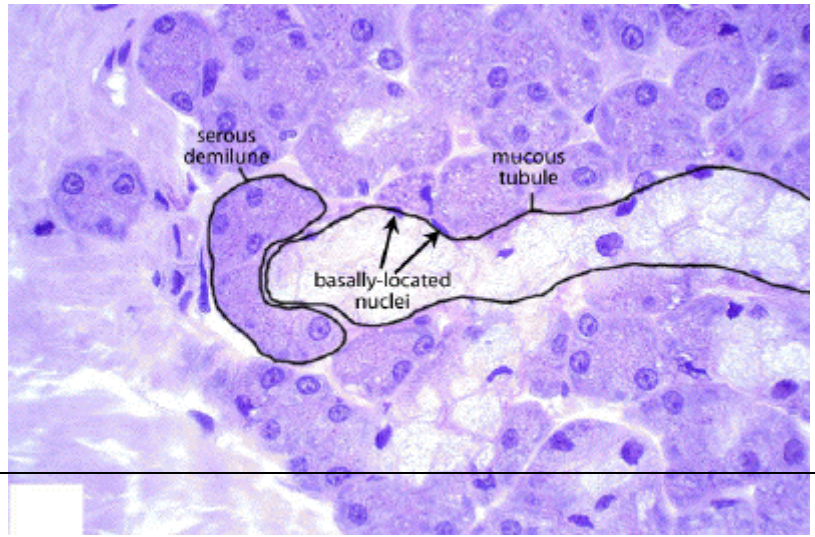

Serous demilunes:are found in both Submandibular and sublingual glands, Serous acini overlies the mucous acini (cap-like), these serous demilunes cannot be seen in the parotid

gland, because it is purely serous.

Minor Salivary Glands: they are numerous, covering the whole oral cavity. (they are mucous, and contributes a lot to the daily 8 salivary liters).
- Labial glands (related to lips).
- Lingual glands (related to tongue).
- Minor salivary glands of palate.

• These non-encapsulated glands are distributed throughout the oral mucosa and submucosa.
• Saliva is produced by small groups of secretory units and is conducted to the oral cavity by short ducts, with little modification of its content.
• Although variations exist, minor salivary glands are usually mucous.
• The small serous glands present in the posterior region of the tongue (von Ebner's glands) are the only exception.
• Lymphocyte agregates are commonly observed within minor salivary glands, associated with IgA secretion.

Note: The mucous glands have a clear, vacuolated, foamy appearance compared to the much more dense, darkly-staining serous glands (because the techniques of preparing the two sections differ)
if you have a parotid gland section, you'll see that it is dark because it is associated with serous acini.
refer to the slides please and see the pictures.
This picture for clarification (lobules and ducts in the gland)