GIS PATHOLOGY 2

Done by: Yasmeen Mahmoud

Scientific Correction: Mohammad Sallam

Gramatical Correction: Dena Kofahi

Doctor: Manar Hajeer

INFECTIOUS ESOPHAGITIS

- It is an esophagitis caused by infectious pathogens. It could be **viral, fungal or bacterial (Bacterial causes are at the bottom of the list, i.e. least common).**
- Mostly in *debilitated* or ***immunosuppressed*** patients.
- Bacterial esophagitis: 10% of cases.
- **Candida** is the most common cause of fungal esophagitis. Mucormycosis & Aspergillosis can also cause fungal esophagitis but much less so than candida.
- Viral esophagitis can be caused by: **HSV or CMV**

CANDIDIASIS

- During endoscopy, you will see in the patient **grayish-white adherent pseudomembranes on the esophagus.** This is the typical presentation.
- In the picture you will see oral thrush in the oral cavity. Candida is part of our normal flora, but it does no harm when the patient is *immunocompetent.* When there is a decrease in the immunity this will cause oral thrush and it can spread down into the esophagus resulting in **fungal esophagitis.** When a biopsy is taken there will be a presence of **inflammation, ulceration, and candida hyphae.** (the hyphae should be present to be able to say it's fungal esophagitis)

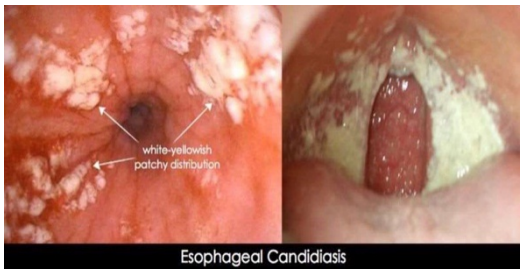

- The patient complains of dysphagia and odynophagia.
- **Treatment:** Antifungal medications

Fungal hyphae

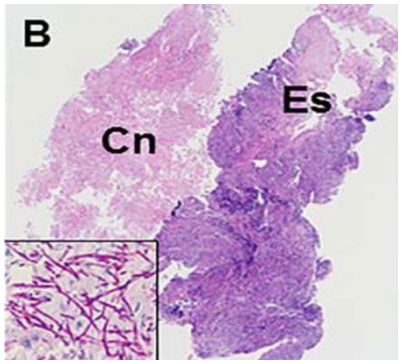

VIRAL ESOPHAGITIS

- The two most important viruses: **HSV & CMV**

HSV (HERPES SIMPLEX VIRUS)
(Herpetic esophagitis)

- Presence of **punched out (deep, heated-up rounded edges) ulcers.**
- When a biopsy is taken, there are certain changes called **viral cytopathic effect.**
- HSV infects the **squamous cells (epithelial cells).**

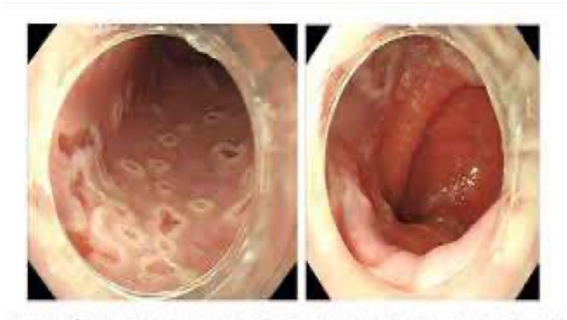

- HSV is characterized by **multi-nucleated giant cells** (the cell has more than one nucleus). Within the nucleus inside, there is a spot called an **intra-nuclear inclusion.** In the nucleus, normally the color of chromatin should be blue, but in HSV the chromatin appears **faint (whitish in color) in the center** and the bluish chromatin is at the edges of nucleus. This is called **ground-glass appearance.**

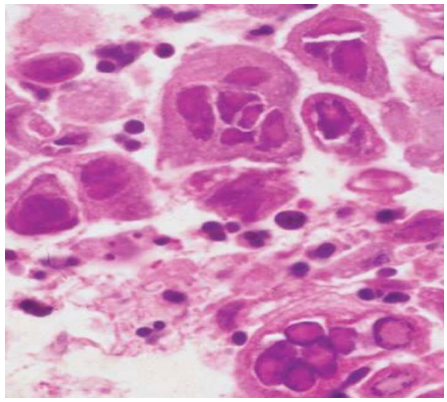

- TO SUMMARIZE: Multi-nucleation, intra-nuclear inclusions, ground-glass appearance of the nuclei and changes in the squamous epithelium are all typical for HSV.

CMV (CYTOMEGALOVIRUS)

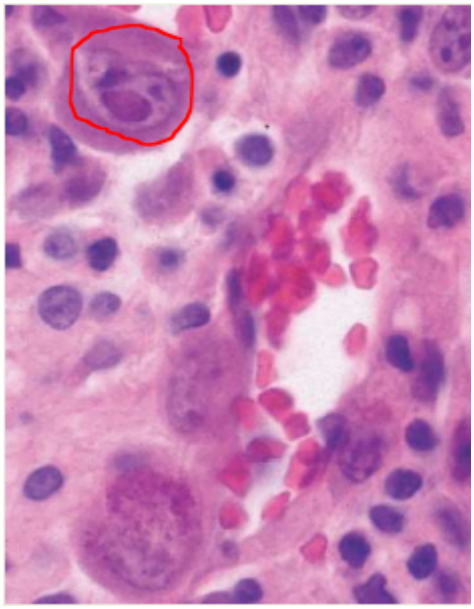

- Cells are ***enlarged.***
- CMV infects **the stromal fibroblasts and the endothelial cells lining the capillaries under the mucosa.**
- Presence of **shallow ulcers** (unlike in HSV they were punched out ulcers).
- Shallow ulcers are *very superficial.*
- Biopsy: nuclear and cytoplasmic inclusions in capillary endothelium and stromal cells.

IMPORTANT NOTES:
1- We can do certain Immunohistochemistry stains to detect HSV or CMV.
2- If you diagnose a patient with fungal or viral esophagitis, you need to check if he is immunocompromised (it mostly affects immunocompromised patients).

REFLUX ESOPHAGITIS

- **Most common cause of esophagitis.**
- Most frequent symptom is **heartburn**. The patient will complain about heartburn in the **epigastric area or the central chest.** The reason for this is the **reflux of the gastric contents into the lower esophagus.** The gastroesophageal sphincter is *relaxed* in this case when it should be closed and this is called **GASTROESOPHAGEAL REFLUX DISEASE (GERD).**
- Squamous epithelium is *sensitive* to acids

QUESTION: What protects the squamous epithelium of the lower esophagus? There are protective factors, for example **mucous and bicarbonate that is produced from submucosal glands.** So, when the patients always have recurrent reflux this protection will *decrease.* Another protection is the **closed sphincter,** anything that causes the sphincter to relax will cause symptoms in the patient.

So why and how it happens? *PATHOGENESIS*:

1. Decreased lower esophageal sphincter tone, the causes are: **CNS depressants, alcohol, and smoking.** (these factors cause the sphincter to be relaxed)
2. Increase abdominal pressure causing reflux of gastric content into the lower esophagus, the causes are: **pregnancy** (enlarged uterus will put pressure onto the stomach which will raise the gastric acidic secretions and the pregnant woman will complain about heartburn), **obesity, hiatal hernia, delayed gastric emptying and increased gastric volume, tumors, ascites and gases (irritable bowel syndrome).**
3. Some cases can be **idiopathic** (relaxed sphincter with an unknown cause).

MORPHOLOGY

- Could be **macroscopic** or **microscopic.**

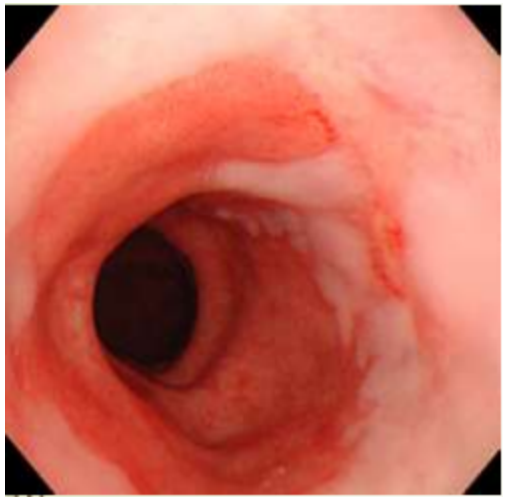

MACROSCOPIC (ENDOSCOPY):

- Redness (because it is an inflammation).
  the pink is the normal mucosa, while the red indicates the inflammation
- Depends on severity (mild symptoms with unremarkable changes, simple hyperemia {redness}).

MICROSCOPIC:

1. EARLIEST FEATURE of reflux esophagitis is the **infiltration of squamous epithelium by *eosinophils***
2. In more severe cases, it is followed by **neutrophils**
3. **Basal zone hyperplasia**
4. **Elongation of lamina propria papillae**

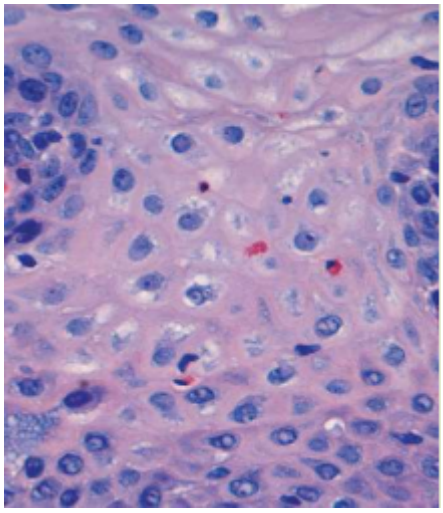

TO DIAGNOSE: Gather all information including patient's symptoms, endoscopy and microscopic findings (one finding is NOT enough, there should be at least 2 microscopic findings).

CLINICAL FEATURES

- **MOST COMMON SYMPTOM: HEARTBURN (حرقة أو حموضة المعدة),** resulting in pain in the center of the chest.
- **IN MORE SEVERE CASES:** dysphasia (difficulty in swallowing)
- Age of patients: Usually it's a disease of adults above the age of 40 but anyone can be affected including *infants and children.*
- Alarming symptoms to notice in infants: crying (from pain of heartburn), regurgitation, vomiting, and failure to thrive (no increase in weight)
- Regurgitation of sour-tasting gastric contents *(it reaches the mouth).*
- RARELY: Severe chest pain which can be mistaken for heart disease.

- Usually in reflux patients, the symptoms are present **at night** because the patient is in a **supine position.**
- **TREATMENT:** proton pump inhibitors (can use Antacids but PPI's are preferred).

COMPLICATIONS

1. Ulceration
2. Hematemesis: vomiting of blood
3. Melena: black colored stool due to upper GI bleeding.

QUESTION: Why upper GI bleeding and not lower GI bleeding? Because if it was lower GI bleeding the stool would have fresh-colored blood. In Melena, the black discoloration is due to the effect of acids and enzymes.

4. Strictures: patient will complain about dysphagia
5. Barrett esophagus: metaplasia which can progress to dysplasia and then carcinoma

EOSINOPHILIC ESOPHAGITIS

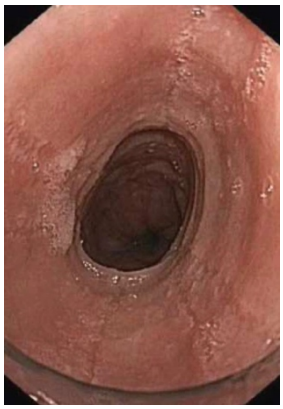

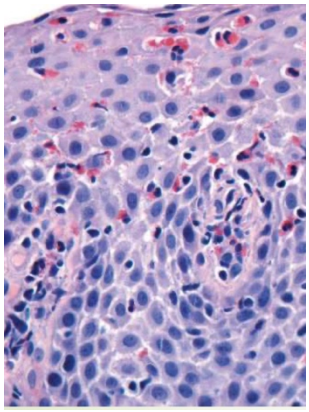

- It is an inflammation of the esophagus, in which microscopically there is a presence of a lot of eosinophils.
- It is a **chronic immune-mediated disorder.**
- Mostly **allergic in nature** due to food that contain soy products.
- Most patients are atopic (atopy refers to the genetic tendency to develop allergic diseases such as atopic dermatitis, allergic rhinitis, and asthma) or have modest peripheral eosinophilia.
- Can happen to infants due to an allergy to milk.

Symptoms:

- The problem is that it has **GERD-like symptoms in children. for example: vomiting, reflux and sometimes heartburn. (but they don't respond to PPI's because the problem here is not acidity)**
- **Dysphagia and food impaction in adults** (feeling that the food is stuck in the esophagus)

MORPHOLOGY:

- **ENDOSCOPY:** constricted **rings** in the **upper and middle** esophagus (remember that reflux esophagitis happens in the lower part)
- **MICROSCOPIC:** numerous eosinophils within epithelium, far from the GEJ (Gastro-esophageal junction) to differentiate it from the reflux type.

- **TREATMENT:** topical or systemic corticosteroids + dietary restrictions (because it is an allergy; cow milk and soy products) + refractory to PPIs

BARRETT ESOPHAGUS

- Complication of *chronic GERD.*
- Simply, it's a metaplasia where the squamous epithelium (which is very fragile and can not handle acidity) transforms into columnar epithelium that is more resistant to acid: **glandular epithelium**. The glandular epithelium can be *gastric* type or *intestinal* type epithelium (defining feature is goblet cells in intestinal type).
- Higher risk if **intestinal epithelium & goblet cells are present.**
- **Only 10% of individuals with GERD will develop Barrett esophagus (Barrett is reversible, but dysplasia and carcinoma aren't).**
- More common in males than females.

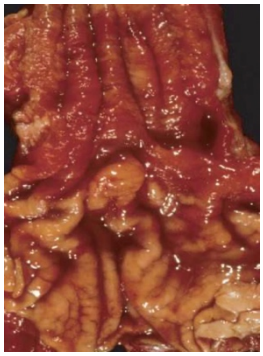

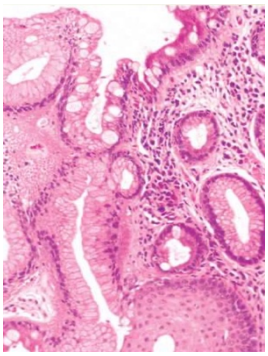

- It's a disease of patients between the ages **40-60 years.**
- The patient *must* have reflux for **years** to be able to develop Barrett,
- Starts from metaplasia —> low grade dysplasia —> high grade dysplasia —> carcinoma
- **Direct precursor of esophageal adenocarcinoma.**
- **Only 0.2 to 1% per year of people with Barrett esophagus progress to dysplasia and adenocarcinoma.**

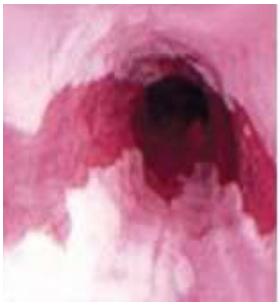

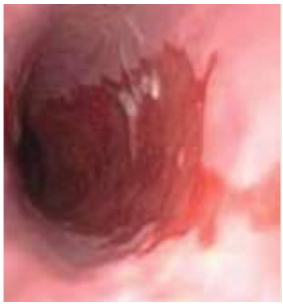

MORPHOLOGY:

- **ENDOSCOPY:** red tongues extending upward from the GEJ
- **HISTOLOGY:**
  - Gastric or intestinal metaplasia
  - Presence of goblet cells (intestinal type)
  - +-Dysplasia: low grade then high grade
  - Intramucosal carcinoma: invasion into the lamina propria

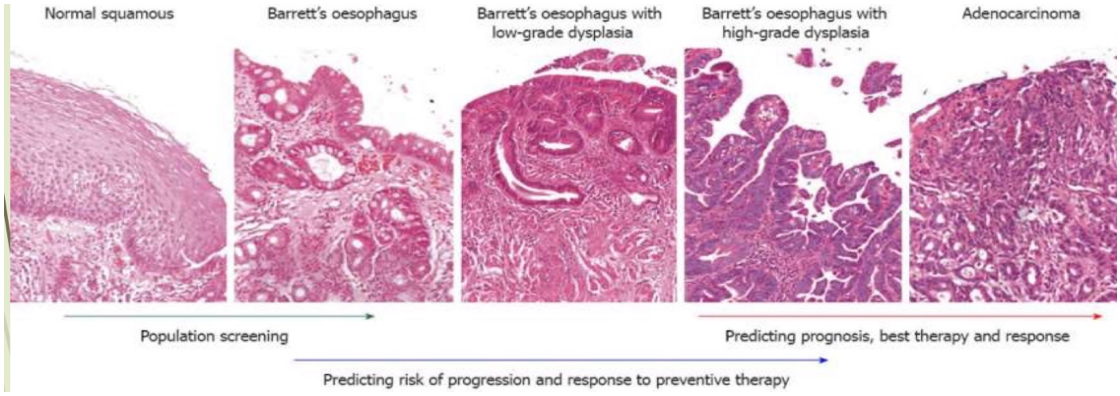

MANAGEMENT OF BARRETT

- Periodic surveillance endoscopy with biopsy to screen for dysplasia (Barrett is metaplasia and can regress with treatment). This is very important to protect the patient from getting carcinoma.
- High grade dysplasia & intramucosal carcinoma needs interventions (surgical resection for example).

.....

ESOPHAGEAL TUMORS

1. Squamous cell carcinoma: most common worldwide.
2. Adenocarcinoma: on the rise. In some areas: half of cases.

BOTH TUMORS ARE MALIGNANT

ADENOCARCINOMA

- **Arises from a background of Barrett.**
- Risk factors: **dysplasia associated Barrett** (causal relationship), smoking, obesity, radiotherapy.
- Male: Female (7:1)
- Geographic & racial variation (developed countries)

➢ **PATHOGENESIS**

- From Barrett —> dysplasia —> adenocarcinoma
- Acquisition of genetic and epigenetic changes.
- Chromosomal abnormalities and **TP53 mutation**. When mutations accumulate, the process becomes **irreversible.**

- **MORPHOLOGY**
  - Distal third of the esophagus
  - EARLY: flat or raised patches
  - LATE: exophytic infiltration masses
  - **MICROSCOPY:** forms glands and mucin

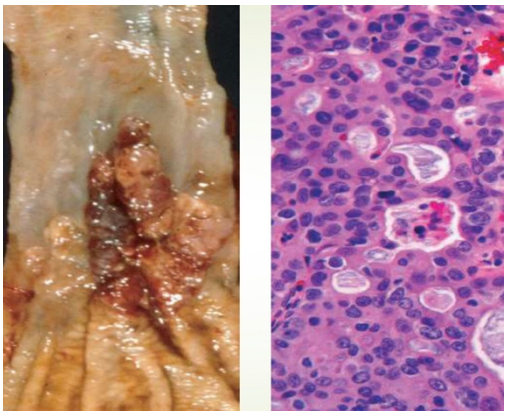

- **CLINICAL FEATURES**
  - Pain or difficulty swallowing
  - Progressive weight loss (**ALARMING SYMPTOM)**
  - Chest pain
  - Vomiting
  - Advanced stage at diagnosis: 5-year survival < 25% (bad prognosis).
  - EARLY STAGE: 5-year survival 80%.

SQUAMOUS CELL CARCINOMA (SCC)

- Not associated with Barrett esophagus.
- Comes from squamous epithelial cells.
- More common in males. Male: Female (4:1)
- More common in **developing countries.**
- Present in **middle esophagus (50% of cases) although it can occur in the lower esophagus.**
- **RISK FACTORS**
  - THE TWO MOST IMPORTANT RISK FACTORS: **alcohol and smoking**
  - Poverty
  - Caustic injury
  - **Achalasia**
  - Plummer-Vinson syndrome: Associated with iron deficiency and anemia
  - Frequent consumption of very hot beverages
  - Previous radiation therapy (Increases risk for many cancers)
- **MORPHOLOGY**
  - Middle third of the esophagus (50% of cases)
  - Polypoid, ulcerated or infiltrative
  - Wall thickening, lumen narrowing
  - It starts as squamous dysplasia which turn into squamous cell in situ (carcinoma in situ) then invasive squamous cell carcinoma that can invade surrounding structures in **advanced stages** (mediastinum, bronchi, pericardium, aorta)

- **PATHOGENESIS**
  - In western countries: alcohol and tobacco use
  - Other areas: polycyclic hydrocarbons, nitrosamines, fungus-contaminated foods
  - HPV infection implemented in high risk regions.

- **MICROSCOPY**
  - You might find next to the squamous cell carcinoma squamous dysplasia or squamous cell in situ (these are precursors of squamous cell carcinoma).
  - Well to moderately differentiated invasive squamous cell carcinoma.
  - You can see SCC at one site, and far away a nodule of SCC, we call this **Intramural tumor nodules**.
  - How to know if it is squamous under the microscope? Certain features such as keratin, inter-cellular bridges, no gland formation and it looks like squamous epithelium.

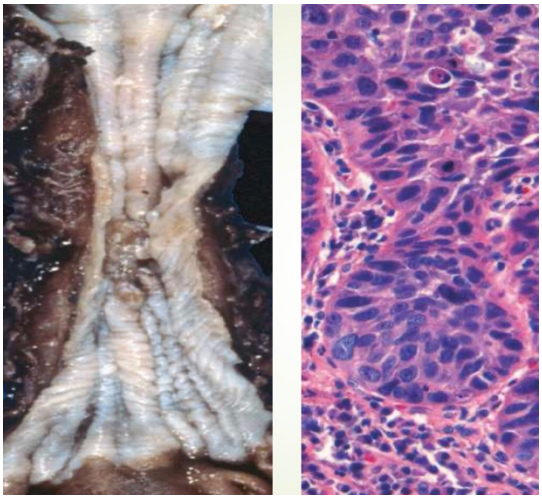

QUESTION: WHERE DO CARCINOMAS USUALLY METASTASIZE? **Lymphatics**

- Upper 1/3 (location of the tumor): cervical lymph nodes
- Middle 1/3: mediastinal, paratracheal and tracheobronchial lymph nodes
- Lower 1/3: gastric and celiac lymph nodes

- **CLINICAL FEATURES**
  - Dysphagia
  - Odynophagia
  - Obstruction
  - **Weight loss** —> very important in cancers
  - Debilitation
  - Impaired nutrition and tumor associated cachexia
  - **Hemorrhage and sepsis** if ulcerated
  - Aspiration via a tracheoesophageal fistula
  - 5-year survival < 9% (bad prognosis)

ALWAYS REMEMBER ESOPHAGEAL CANCERS ARE VERY BAD TUMORS

GOOD LUCK