Skull-2

Norma Basalis Interna

Norma Basalis Externa

Dr. Heba Kalbouneh
Associate Professor of Anatomy and Histology

Edited by: Mahmoud odeh
all red colour notes are from the online video.

Norma basalis interna

Base of the skull- superior view

The interior of the base of the skull is divided into three cranial fossae

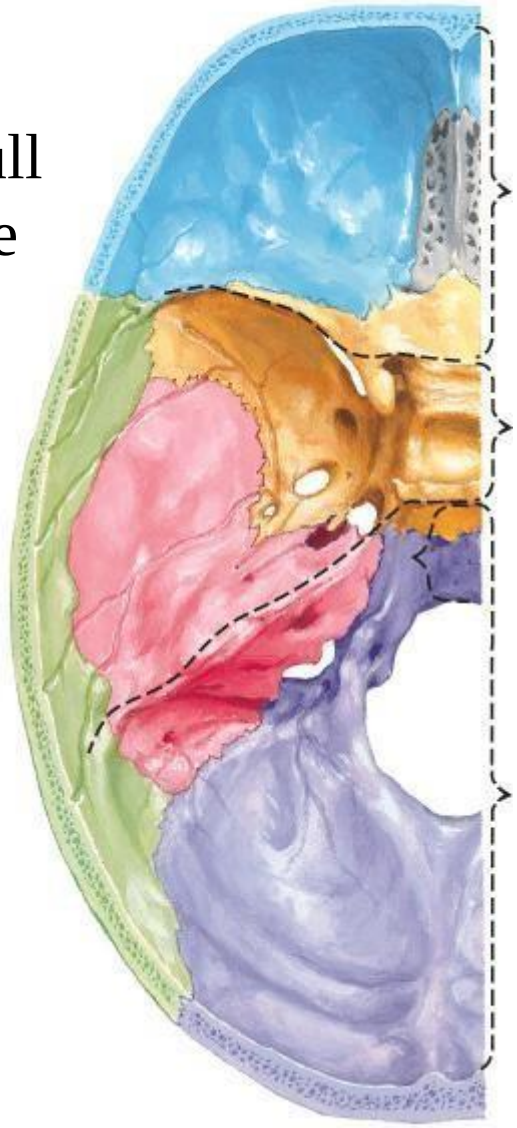

Dr. Heba Kalbouneh

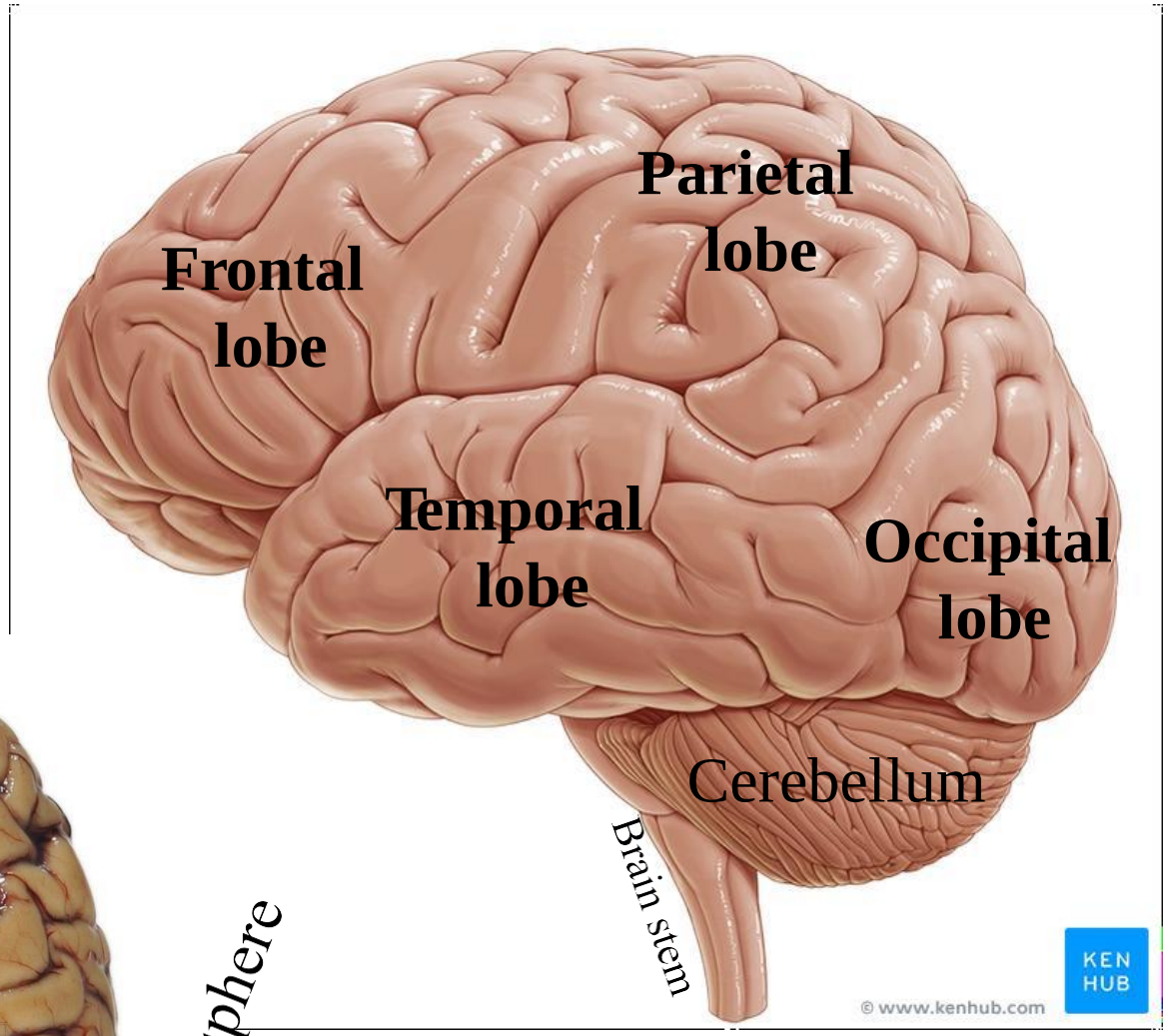
Frontal lobe
Parietal lobe
Temporal lobe
Occipital lobe
Cerebellum
Brain stem
© www.kenhub.com
KEN HUB

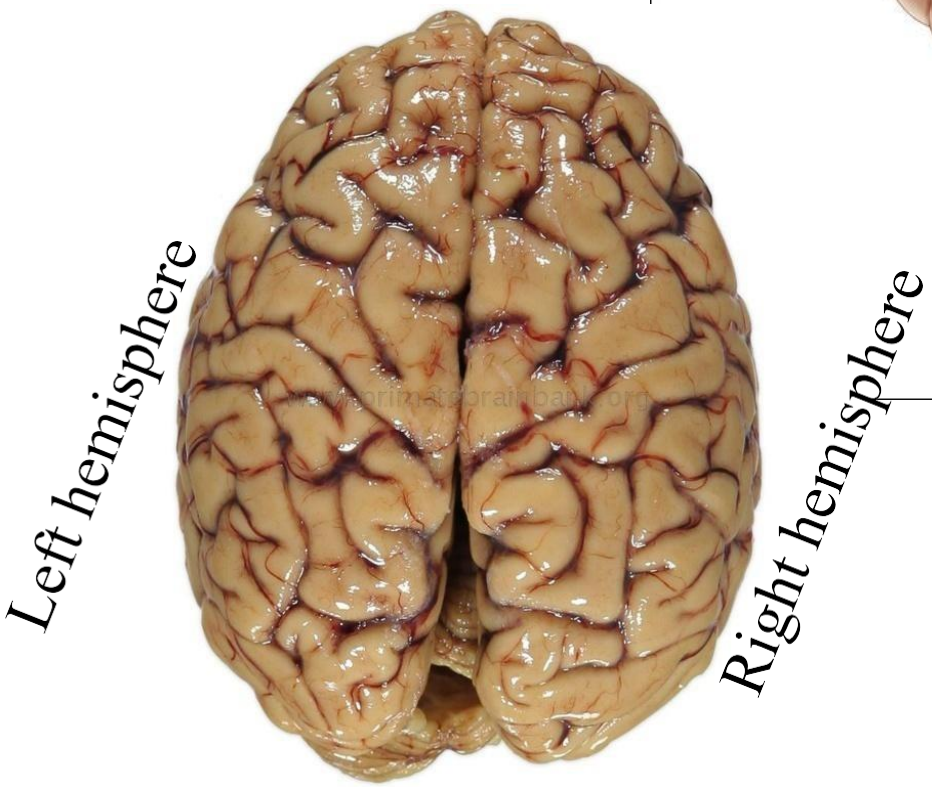
Left hemisphere
Right hemisphere

The brain stem is divided into 3 parts (from superior to inferior):

1- Midbrain

2- Pons

3- Medulla oblongata (which continues as spinal cord)

Anterior cranial fossa

Contains frontal lobes

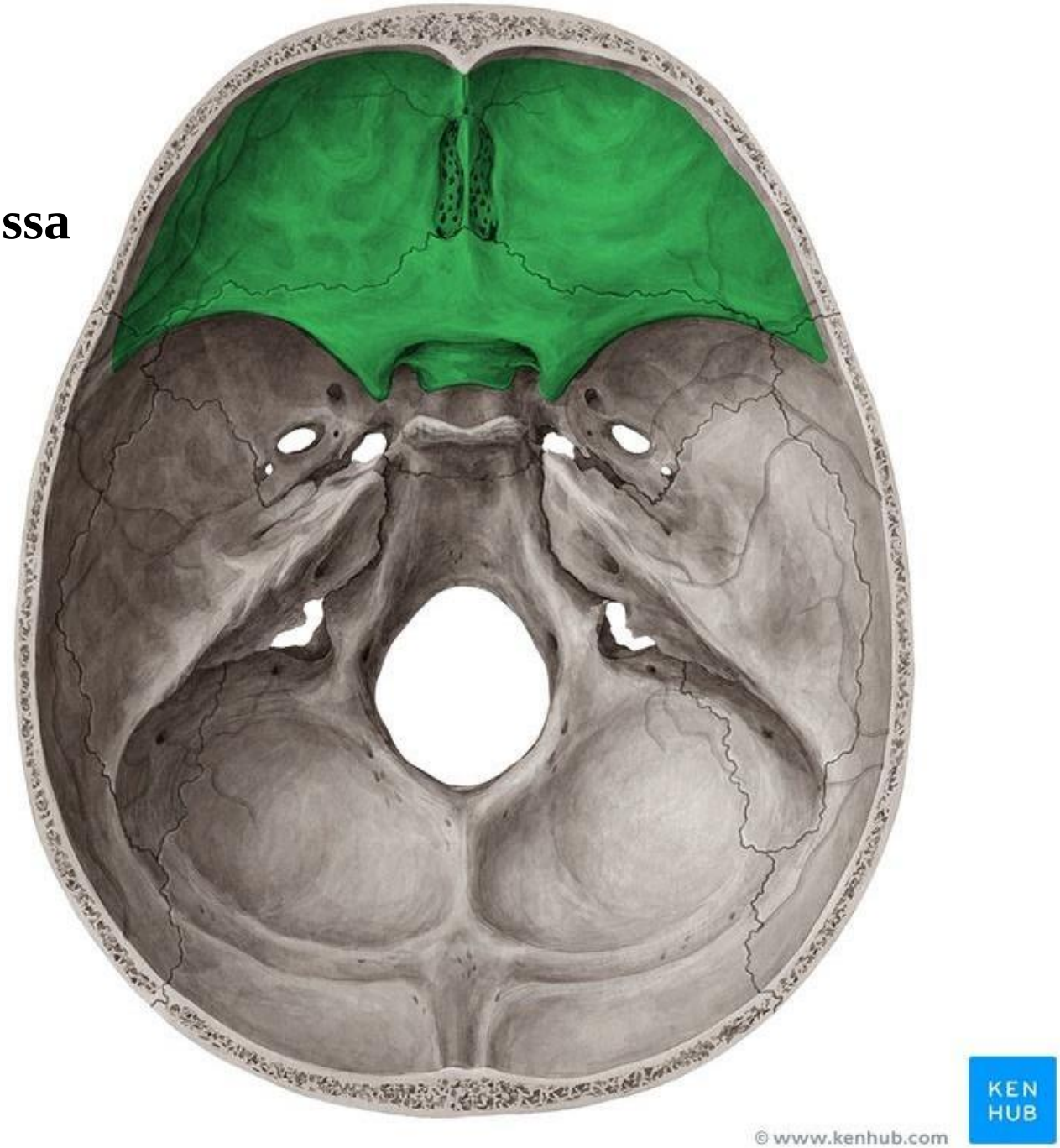

Dr. Heba Kalbouneh

Middle cranial fossa

Contains temporal lobes

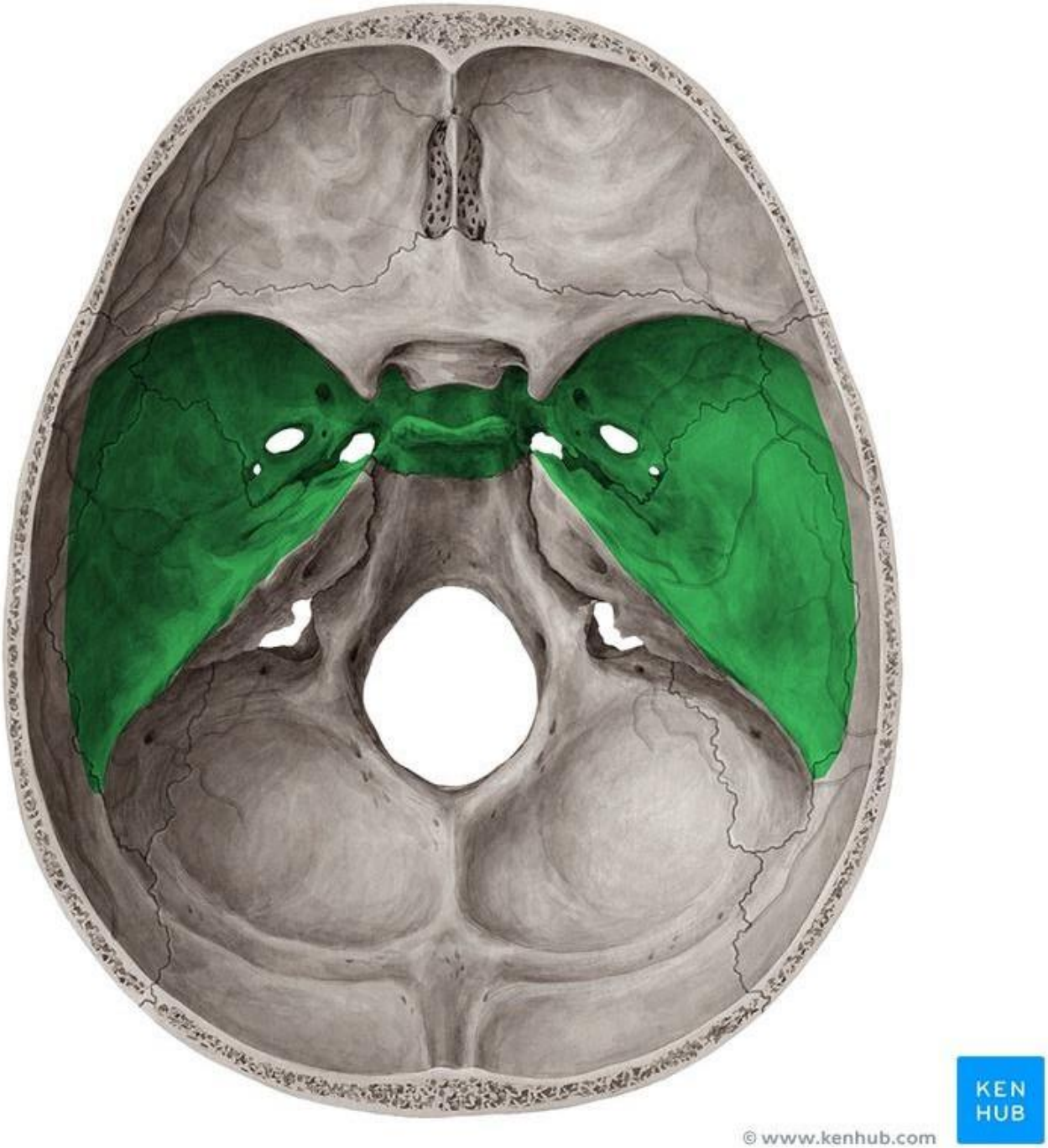

Dr. Heba Kalbouneh

Dr. Heba Kalbouneh

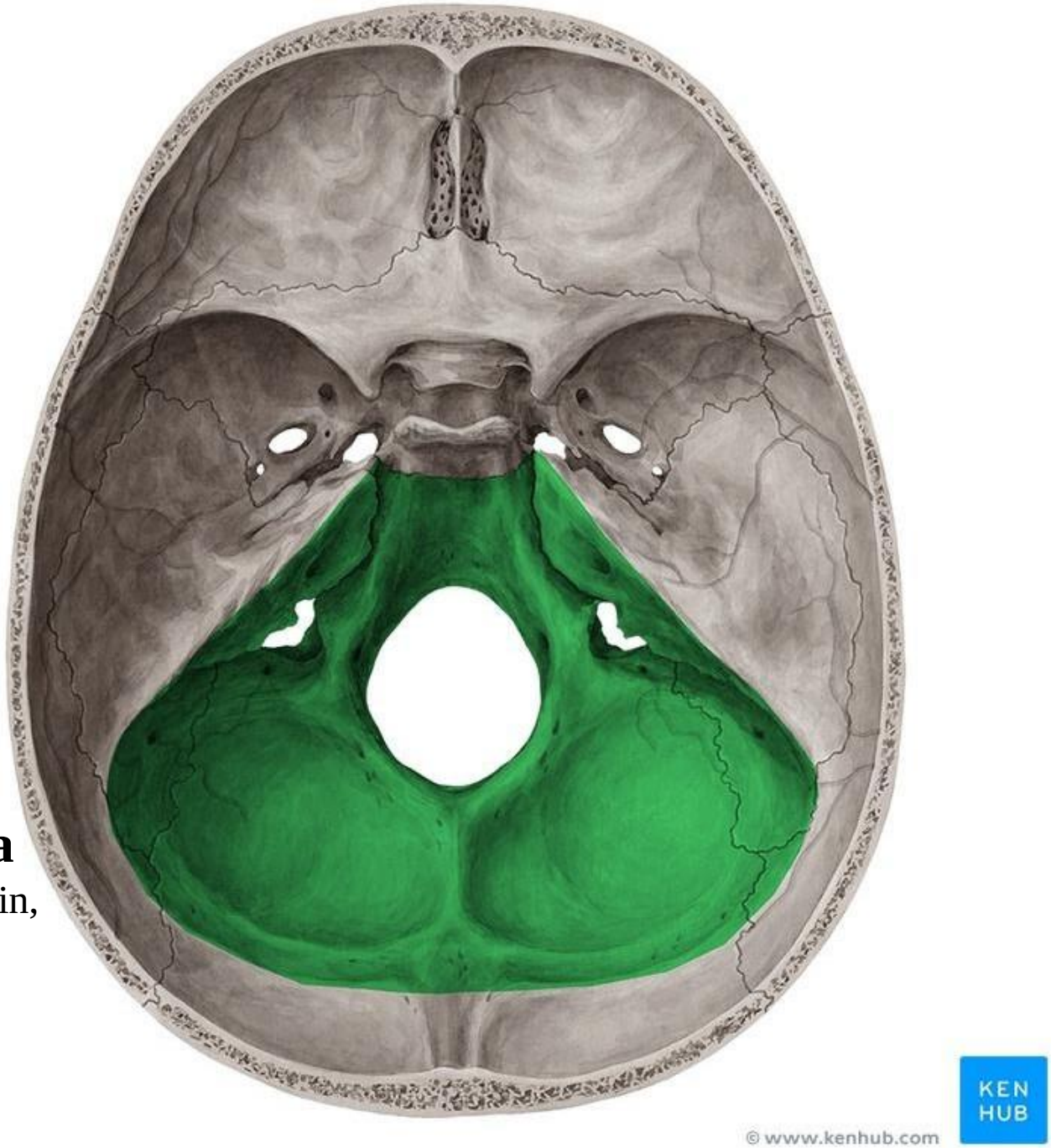

Posterior cranial fossa

Contains the brain stem (midbrain, pons and medulla oblongata) and cerebellum

Cranial Nerves

I	Olfactory
II	Optic
III	Oculomotor
IV	Trochlear
V	Trigeminal
VI	Abducens
VII	Facial
VIII	Vestibulocochlear
IX	Glossopharyngeal
X	Vagus
XI	Accessory
XII	Hypoglossal

These cranial nerves function is moving the eyeball

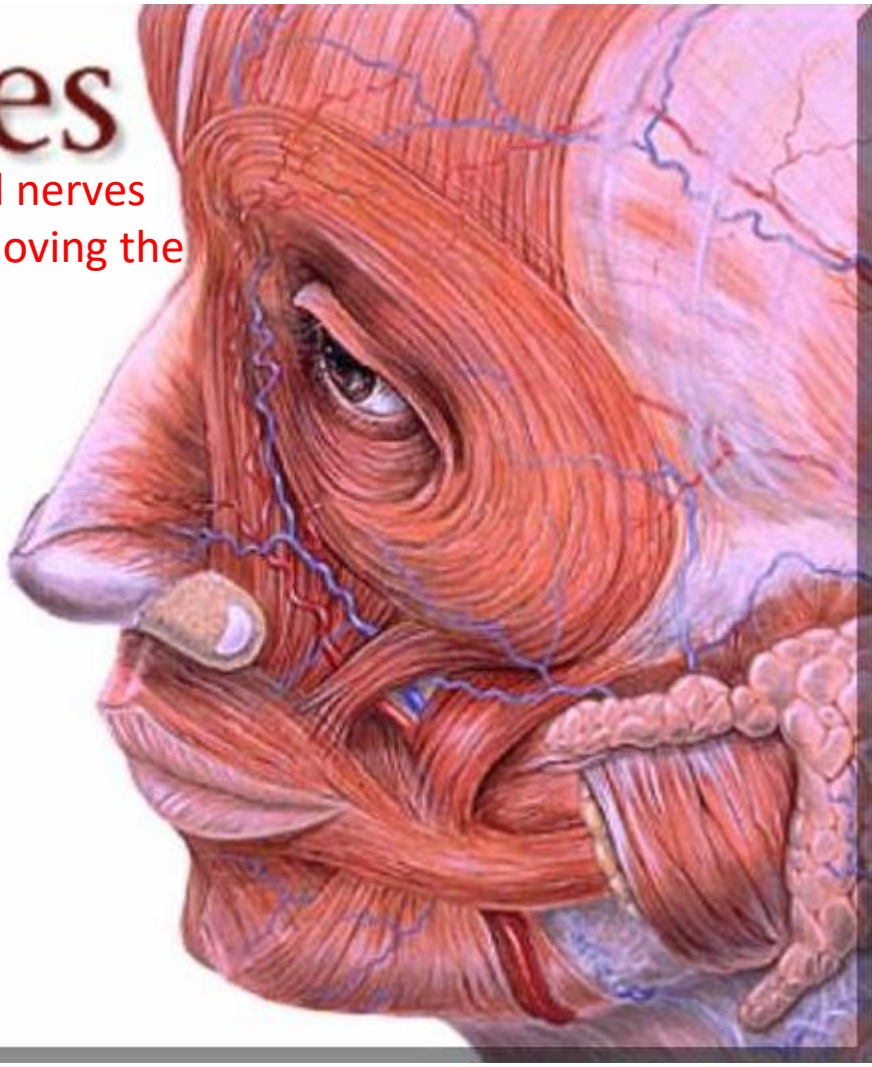

The numbering of the cranial nerves is based on the order in which they emerge from the brain, front to back

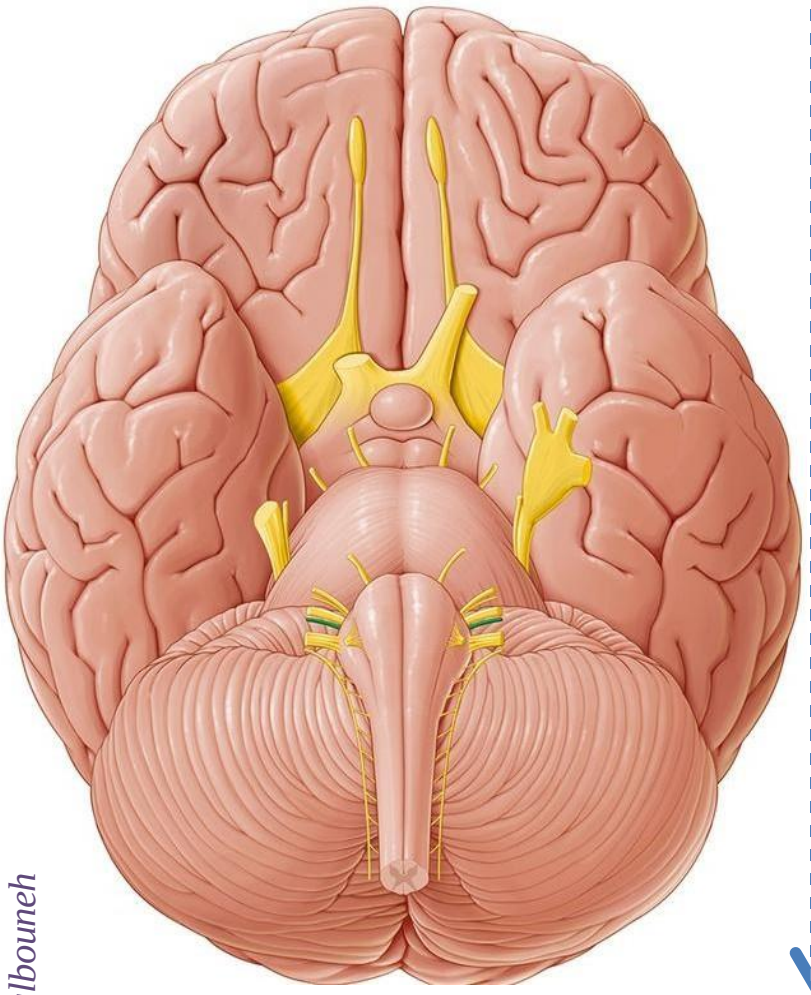

Inferior surface of brain

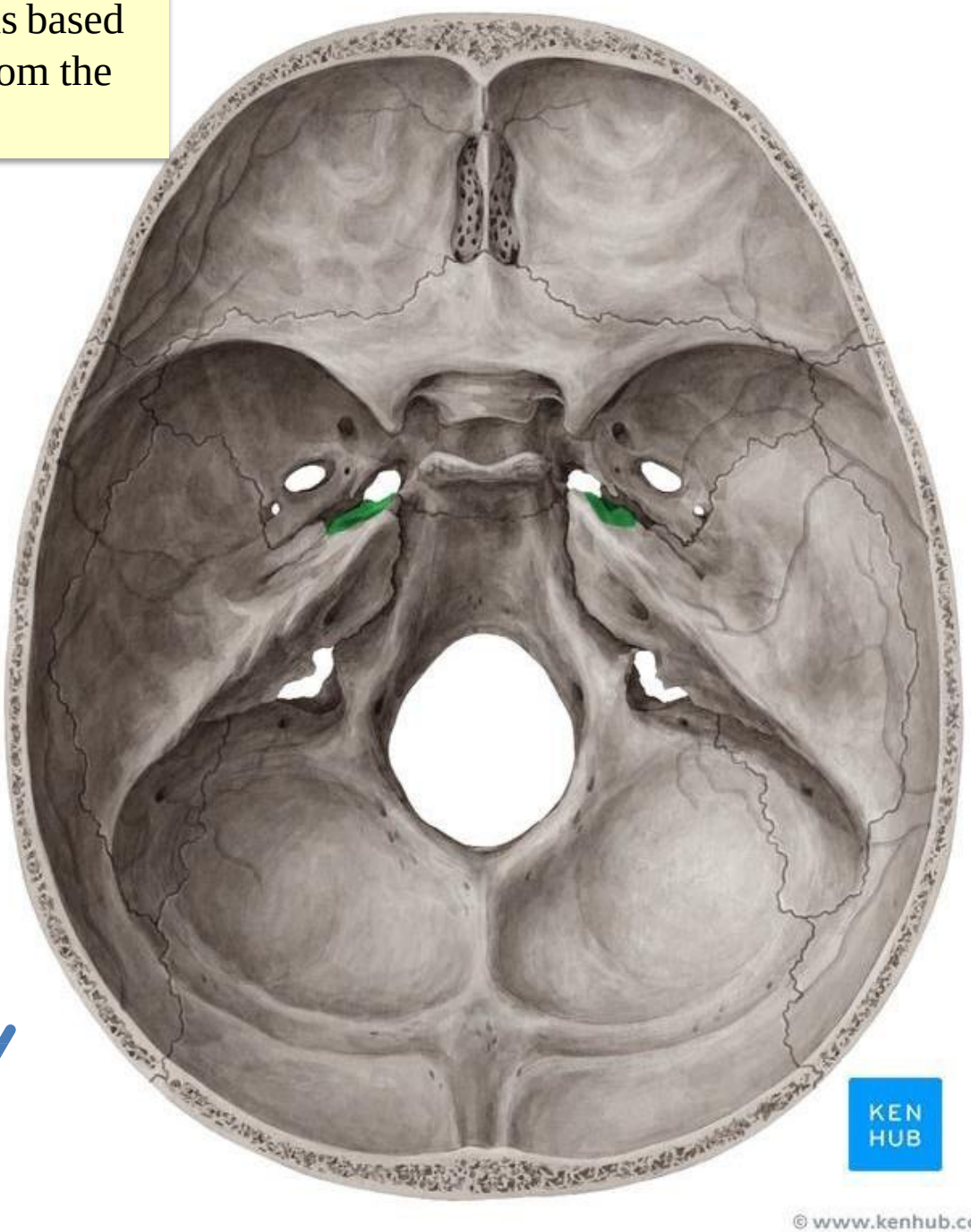

Dr. Heba Kalbouneh

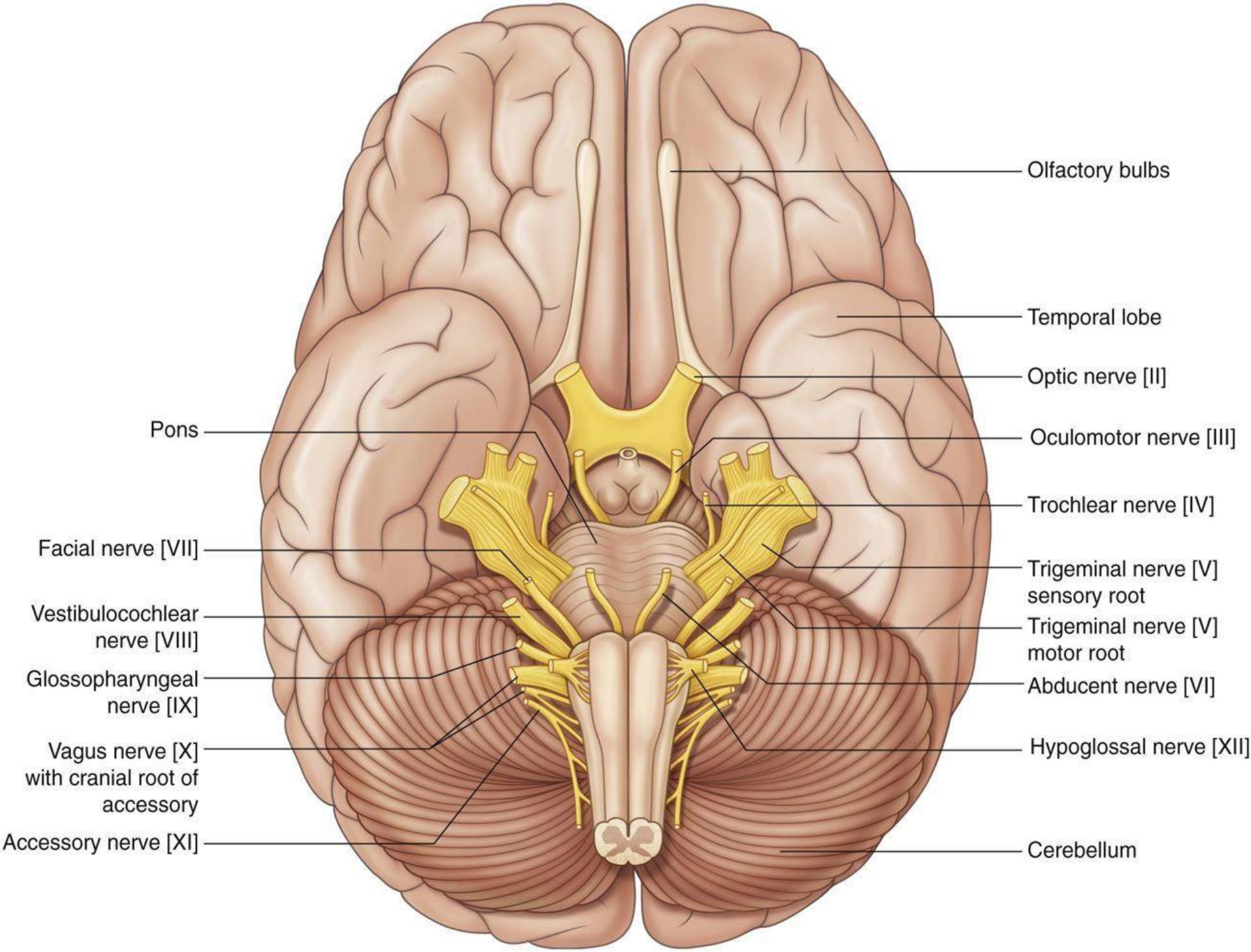
Olfactory bulbs
Temporal lobe
Optic nerve [II]
Oculomotor nerve [III]
Trochlear nerve [IV]
Trigeminal nerve [V] sensory root
Trigeminal nerve [V] motor root
Abducent nerve [VI]
Hypoglossal nerve [XII]
Cerebellum
Pons
Facial nerve [VII]
Vestibulocochlear nerve [VIII]
Glossopharyngeal nerve [IX]
Vagus nerve [X] with cranial root of accessory
Accessory nerve [XI]

Foramina of skull and cranial nerves passing through

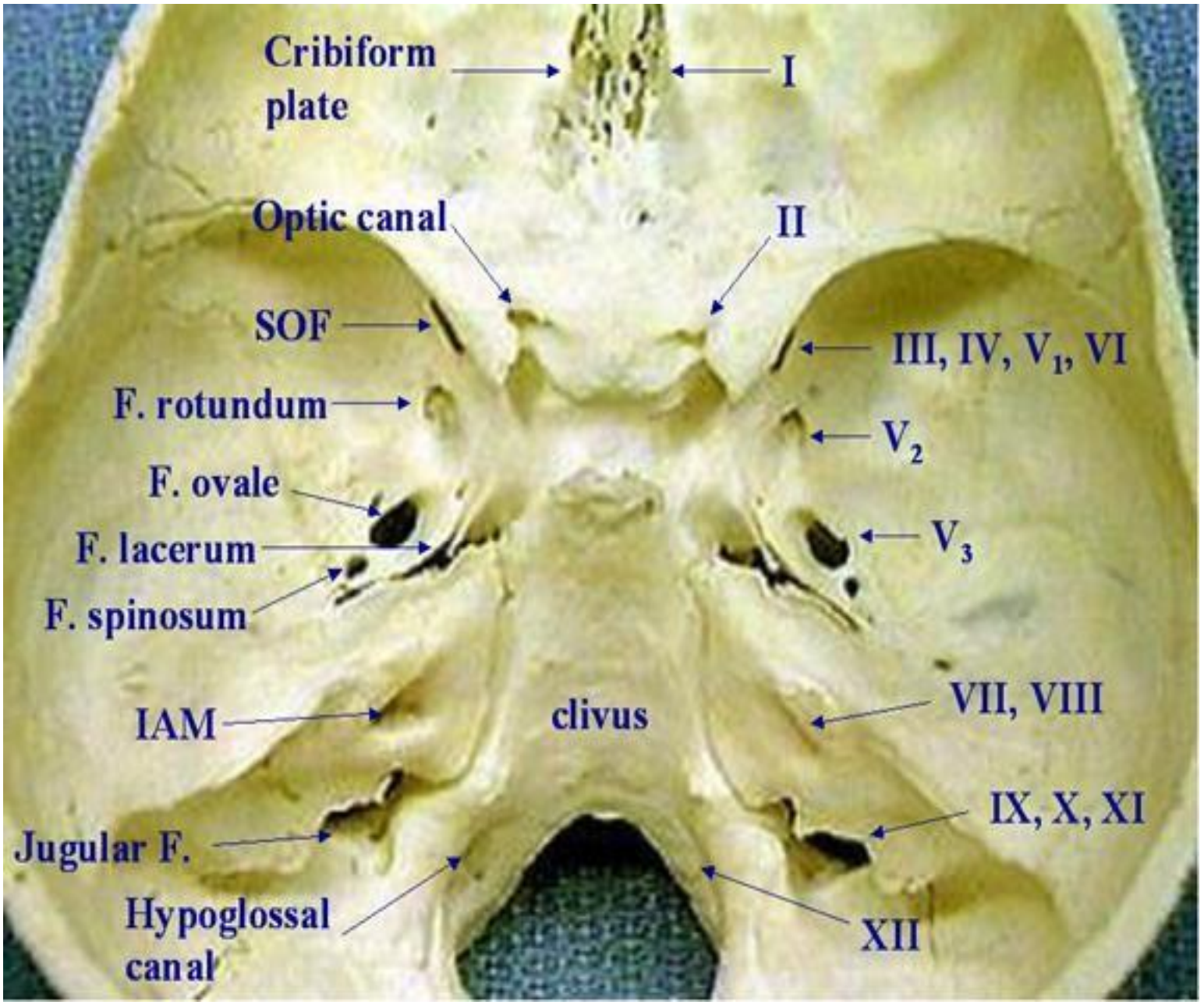

Anterior cranial fossa

Formed by:
1 Frontal bone
2 Ethmoid bone in the midline
3Two parts of the sphenoid bone, the body (midline) and the lesser wings (laterally)

Orbital plates of the frontal bone are thin plates of frontal bone, form the roof of the orbit
Frontal crest is a small crest projects from frontal bone
Crista galli is a sharp upward projection of the ethmoid bone in the midline
Cribriform plate of the ethmoid is a sieve-like structure lateral to crista galli

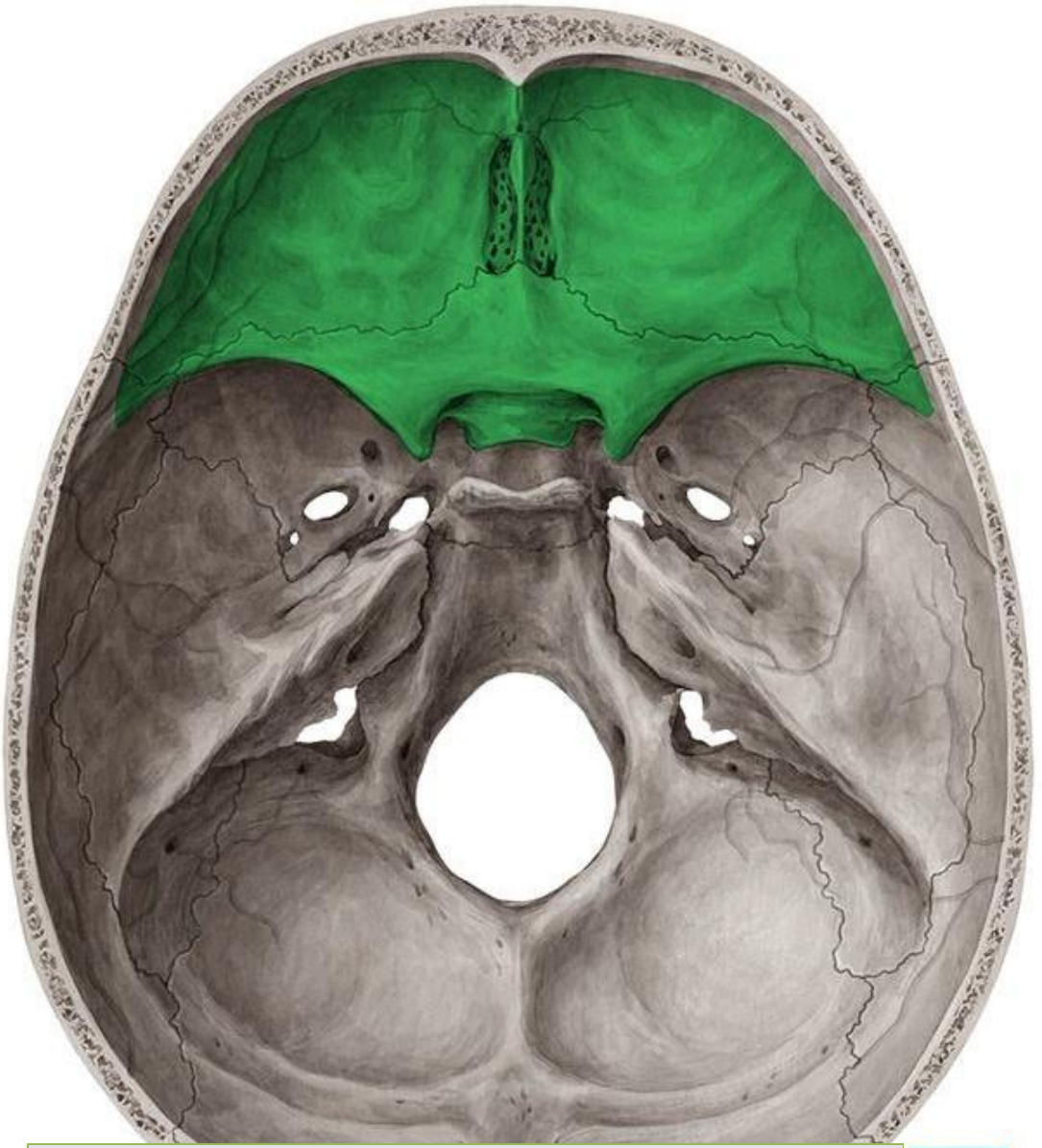

Note the anterior cranial fossa is above the nasal cavity and the orbits

KEN HUB
© www.kenhub.c

Dr. Heba Kalbouneh

Orbital plates of frontal bone

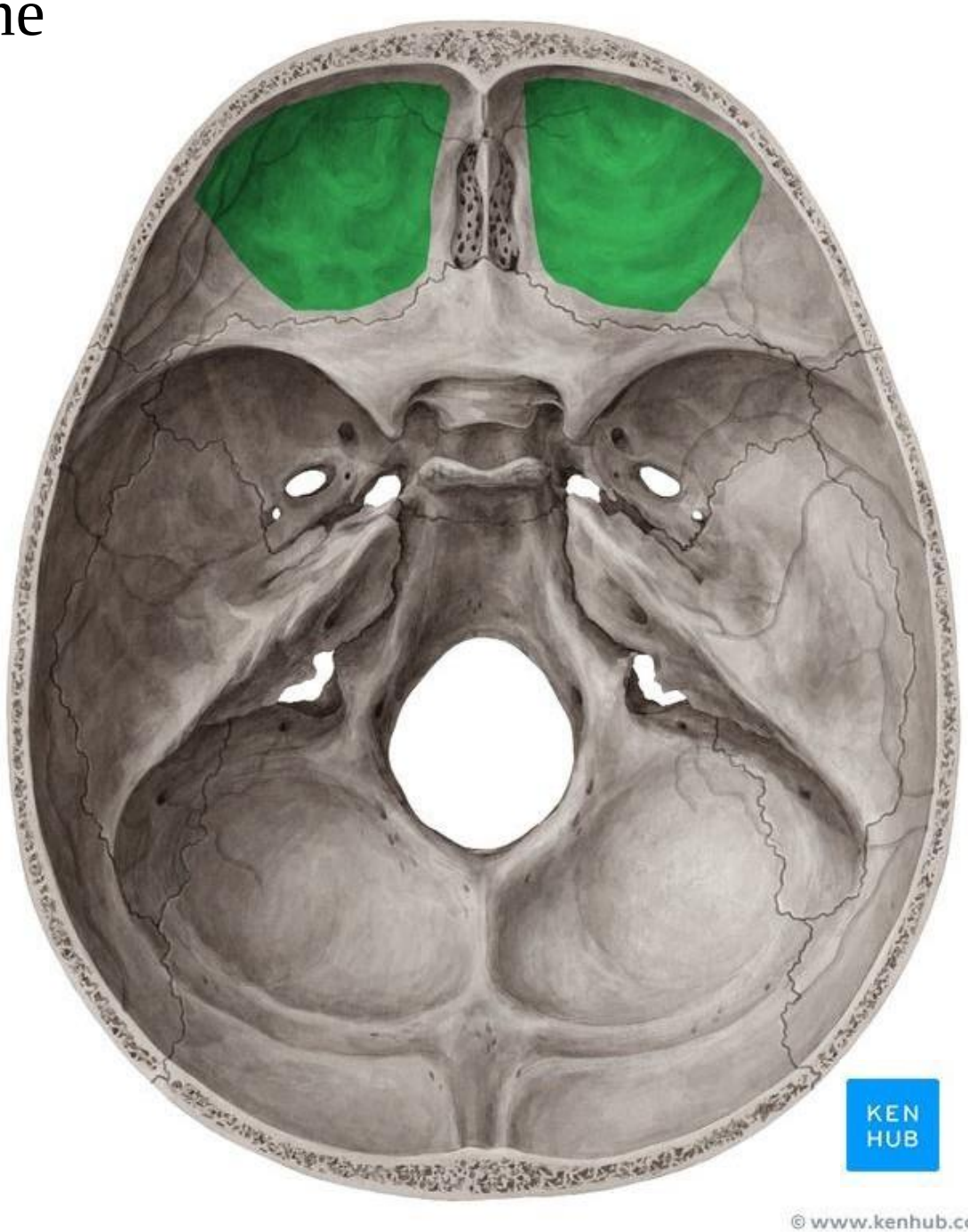

Dr. Heba Kalbouneh

Frontal crest

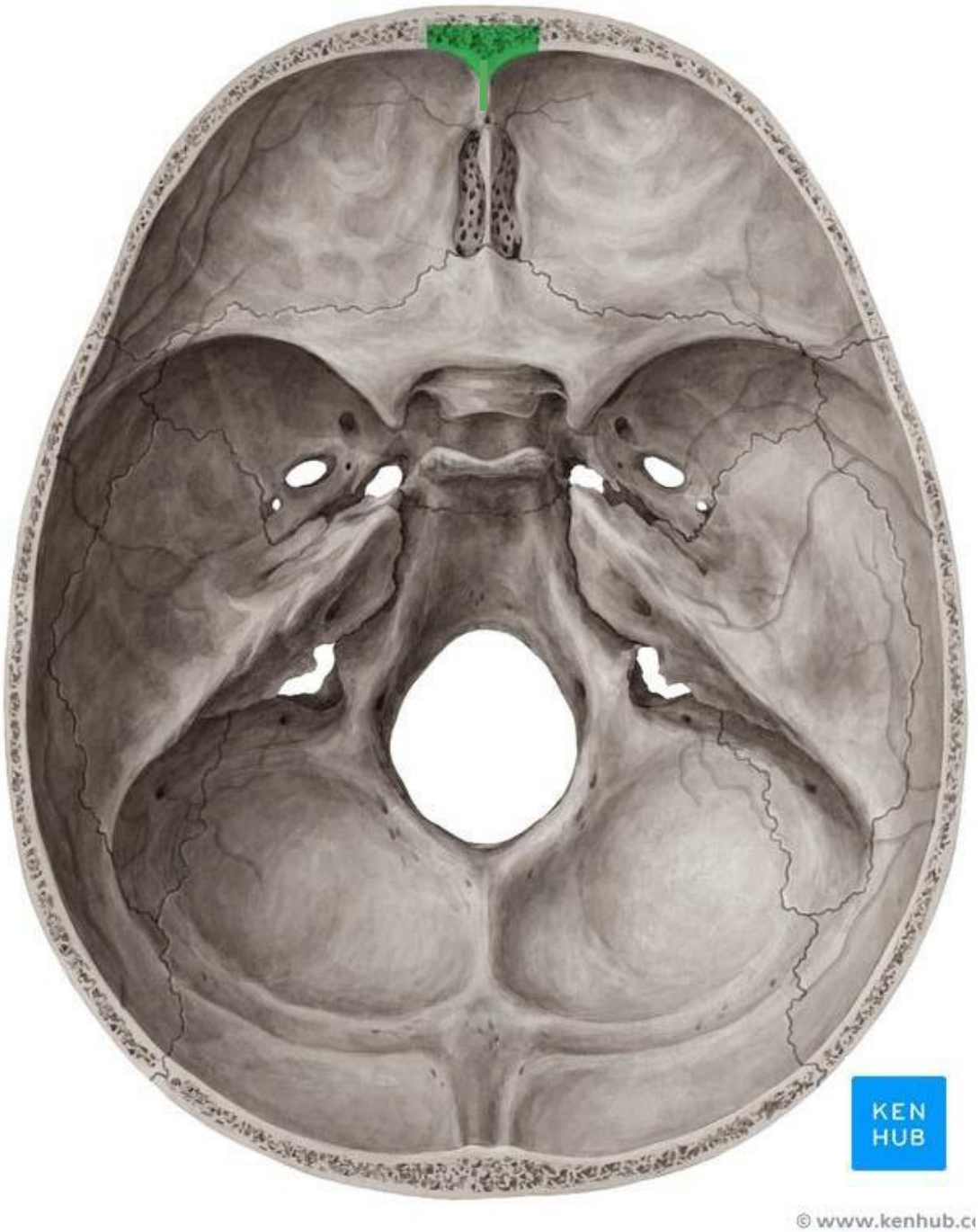

Crista galli of ethmoid

Latin: Crest of the rooster

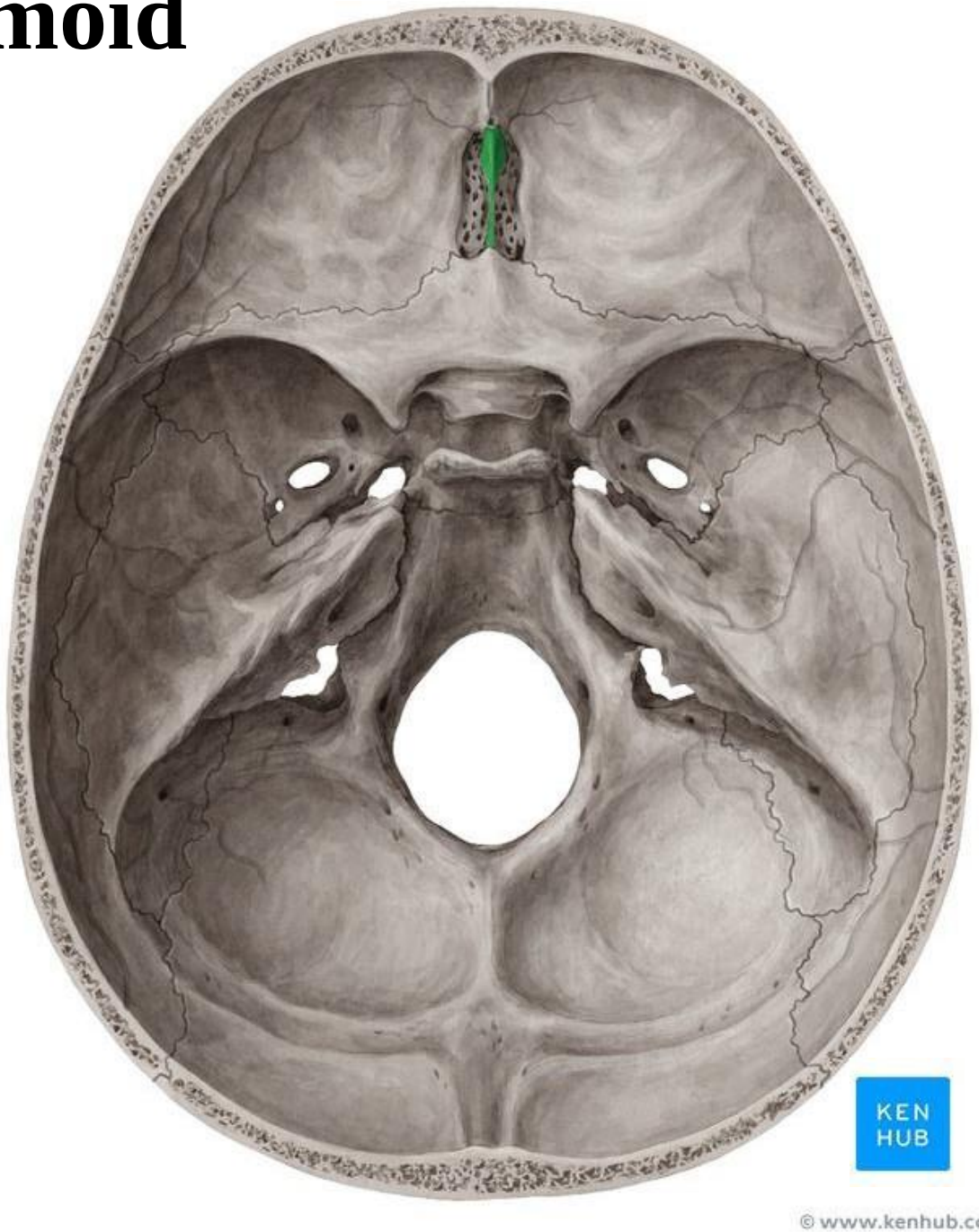

Dr. Heba Kalbouneh

Cribriform plate of ethmoid

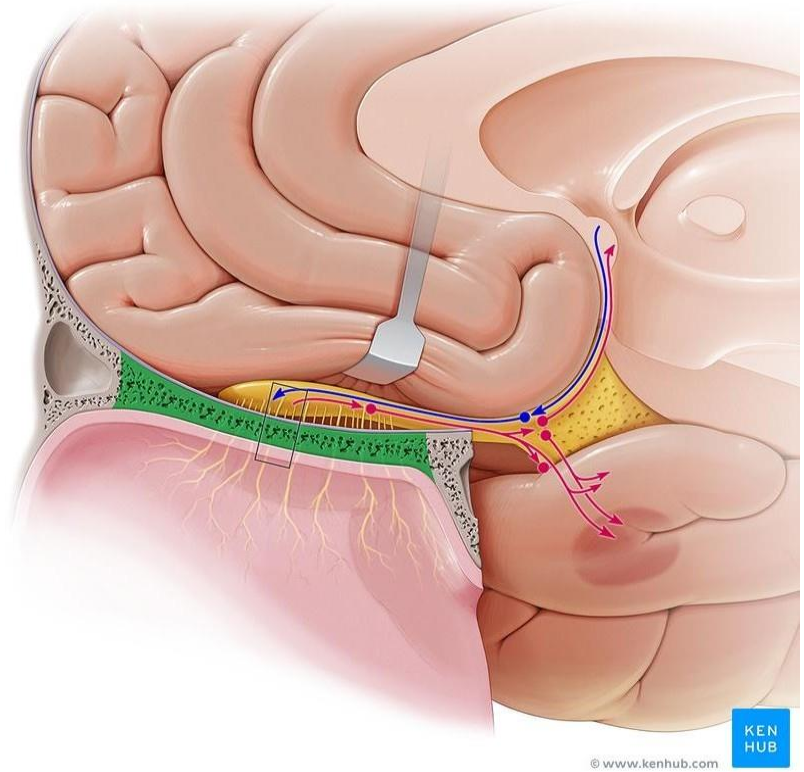

The small perforations in the cribriform plate are for the **olfactory nerves**.

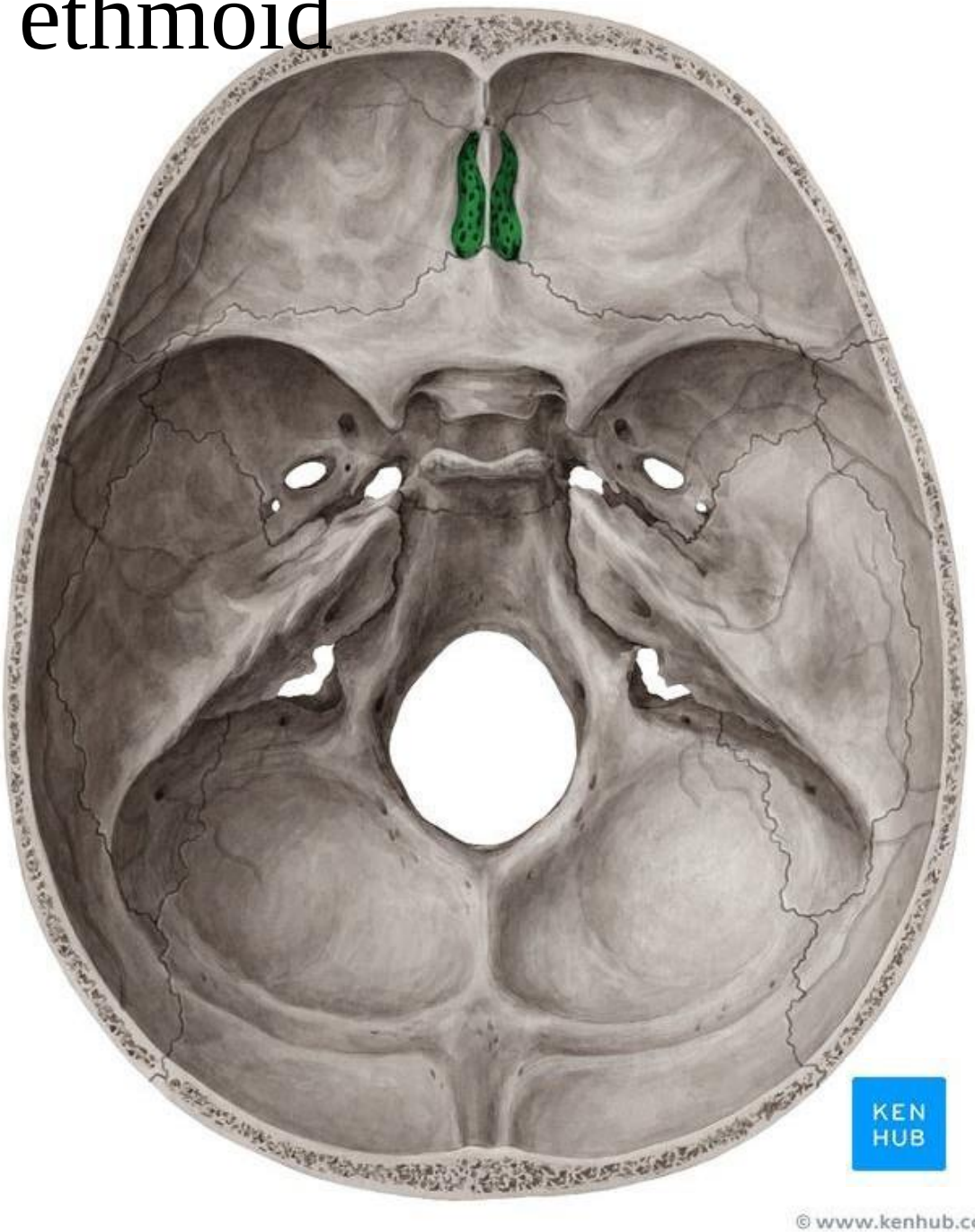

Dr. Heba Kalbouneh

Foramen caecum

Foramen caecum: caecum means closed, some people has it closed normally

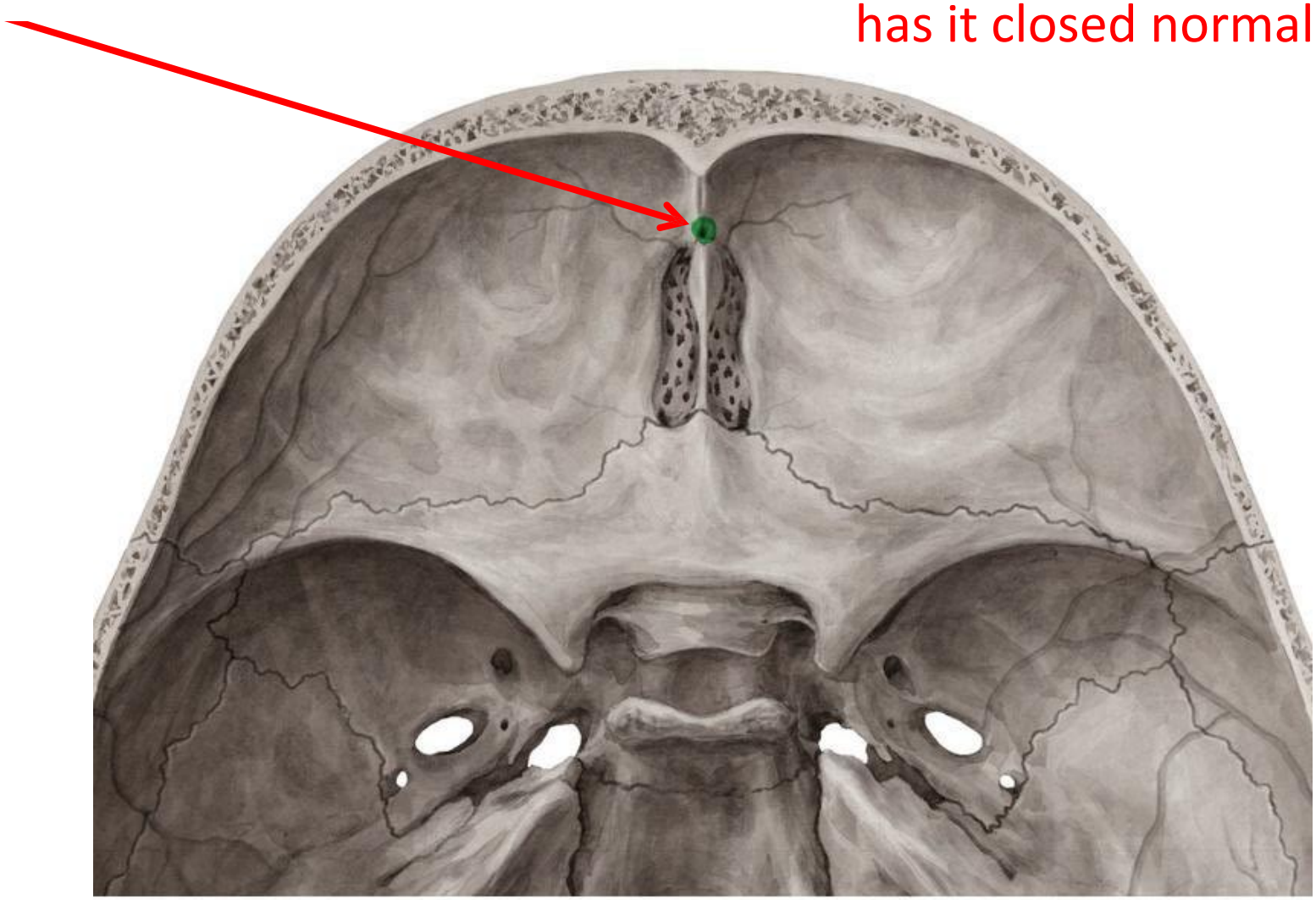

Lesser wing of sphenoid

Norma basalis interna is the best view to see **Lesser wing of sphenoid**

Sphenoid bone like butterfly in shape ☺

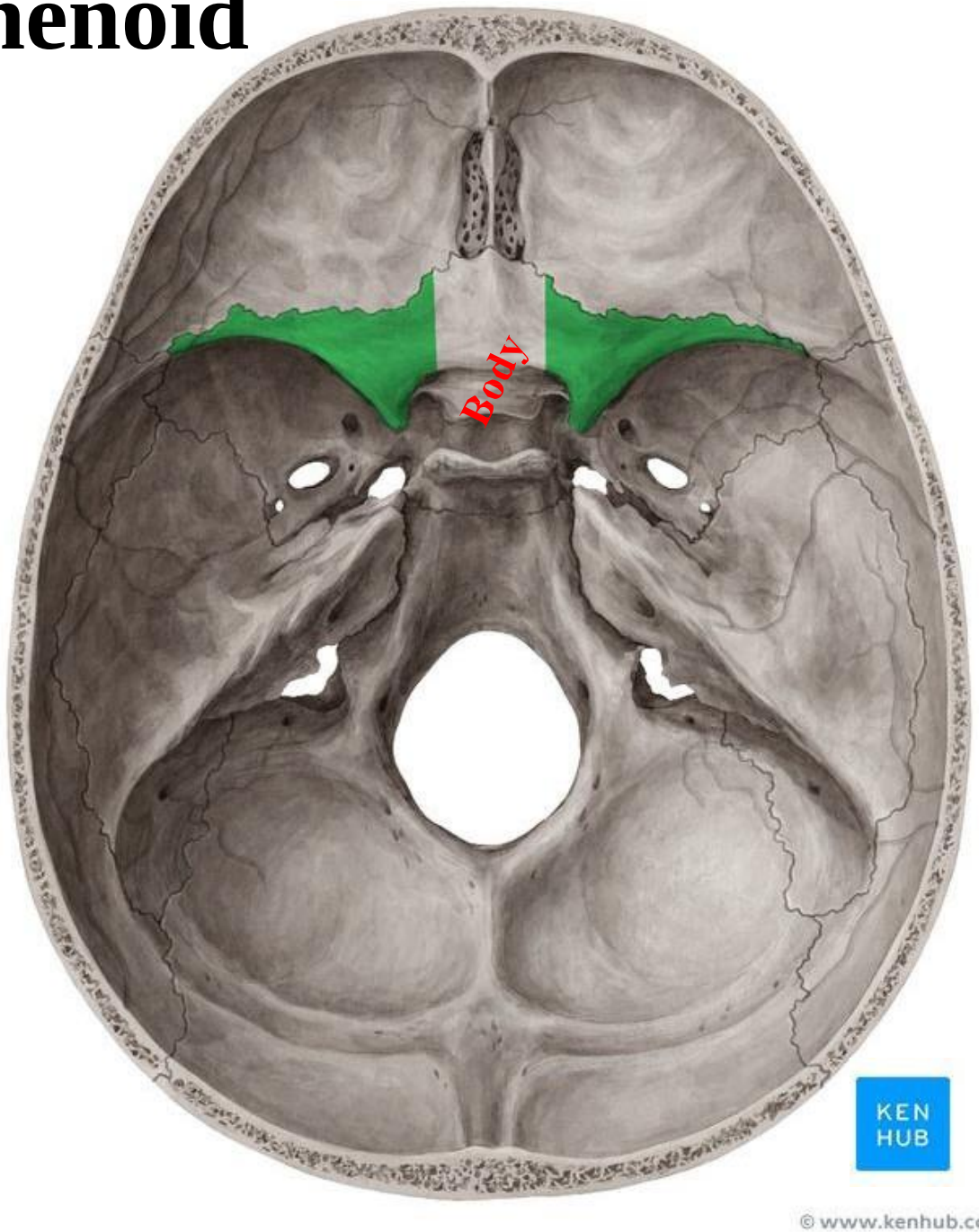

Dr. Heba Kalbouneh

Anterior clinoid process

The medial ends of the lesser wing of the sphenoid form the **anterior clinoid processes**

Note:
Medial to Anterior clinoid process:
Optic canal
Lateral to Anterior clinoid process:
Superior orbital fissure

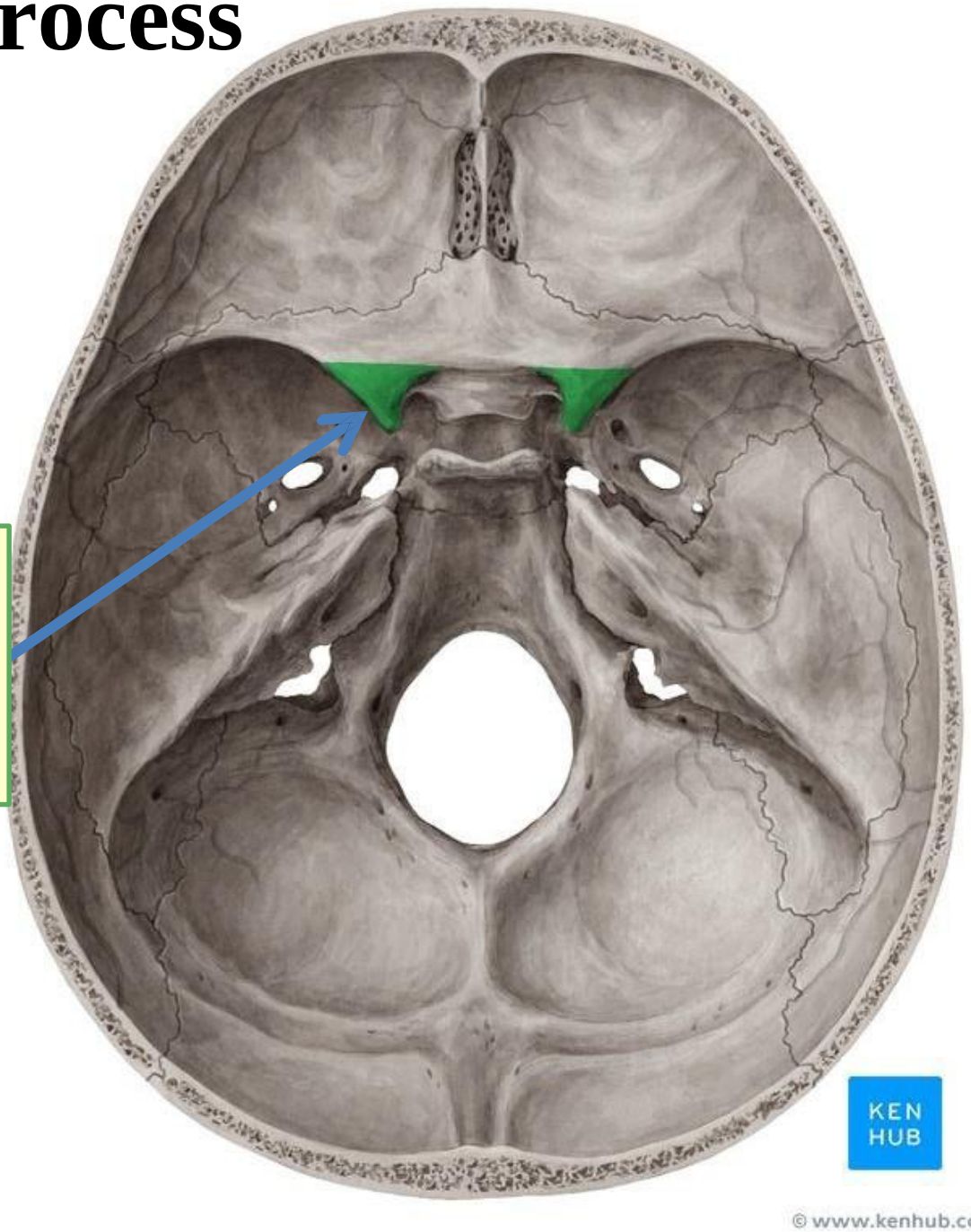

Dr. Heba Kalbouneh

Middle cranial fossa

Formed by:
- Body of sphenoid
- Greater wing of the sphenoid
-Squamous and petrous parts of the temporal bone

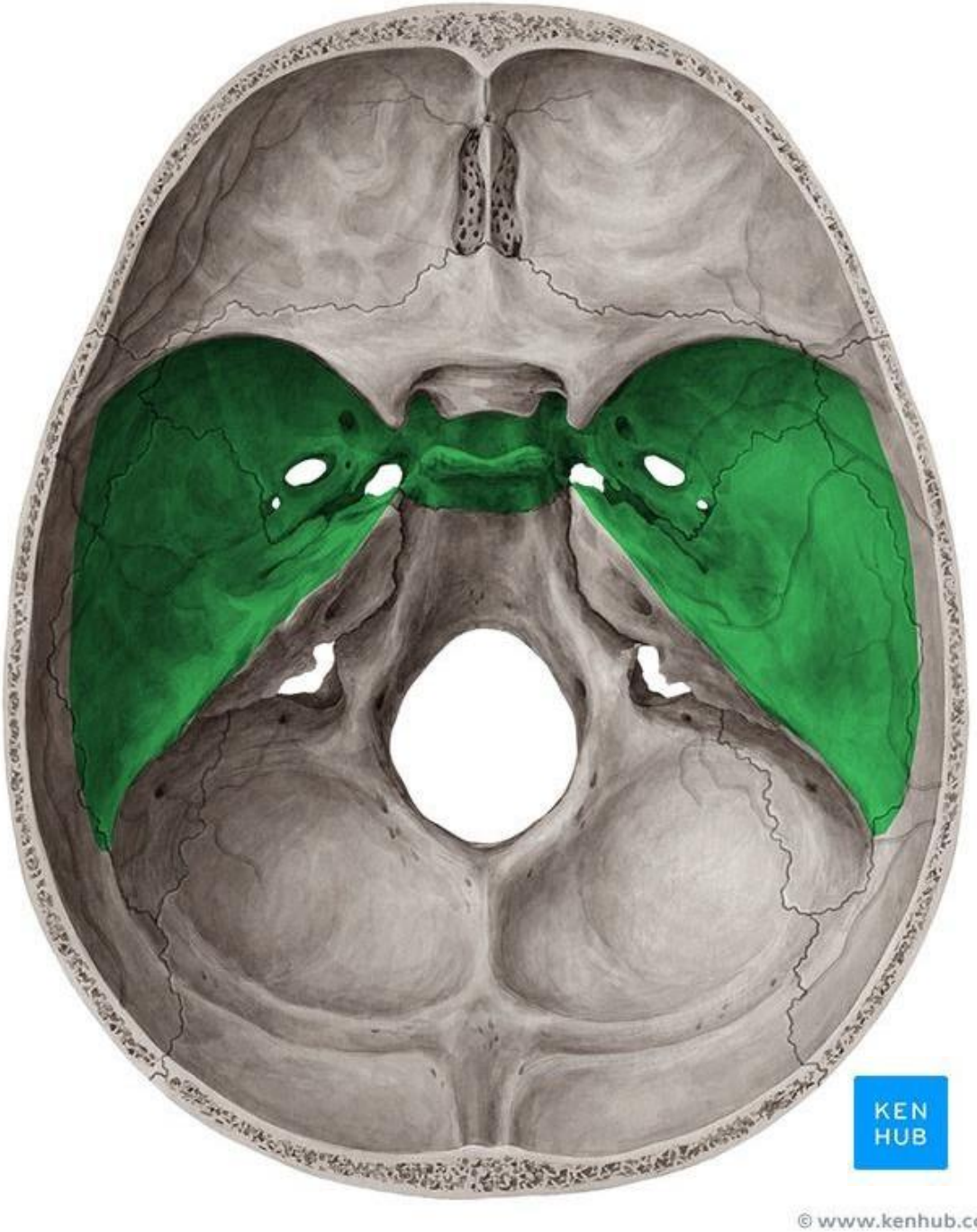

Dr. Heba Kalbouneh

Greater wing of the sphenoid

Body of sphenoid

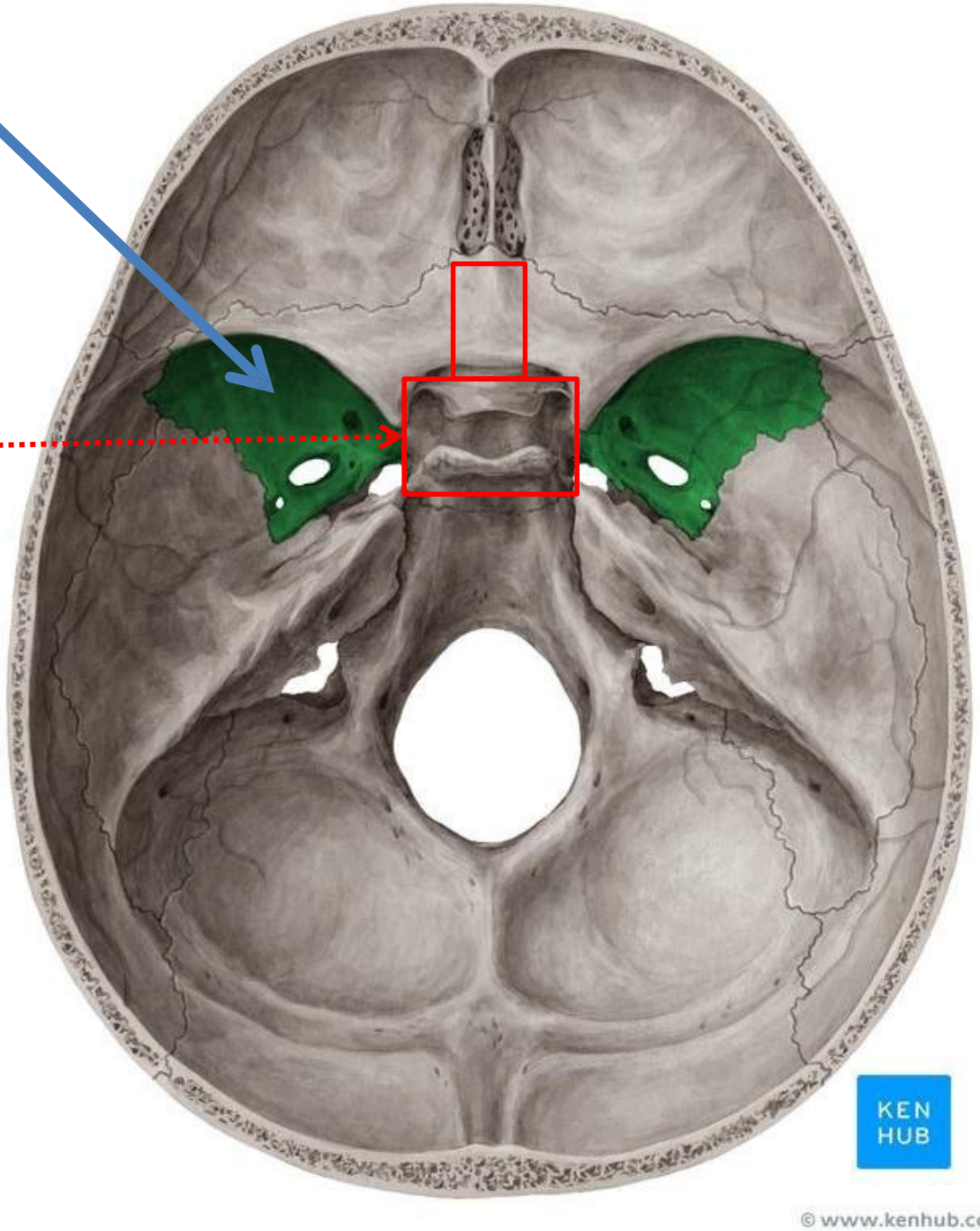

Dr. Heba Kalbouneh

Squamous and petrous parts of the temporal bone

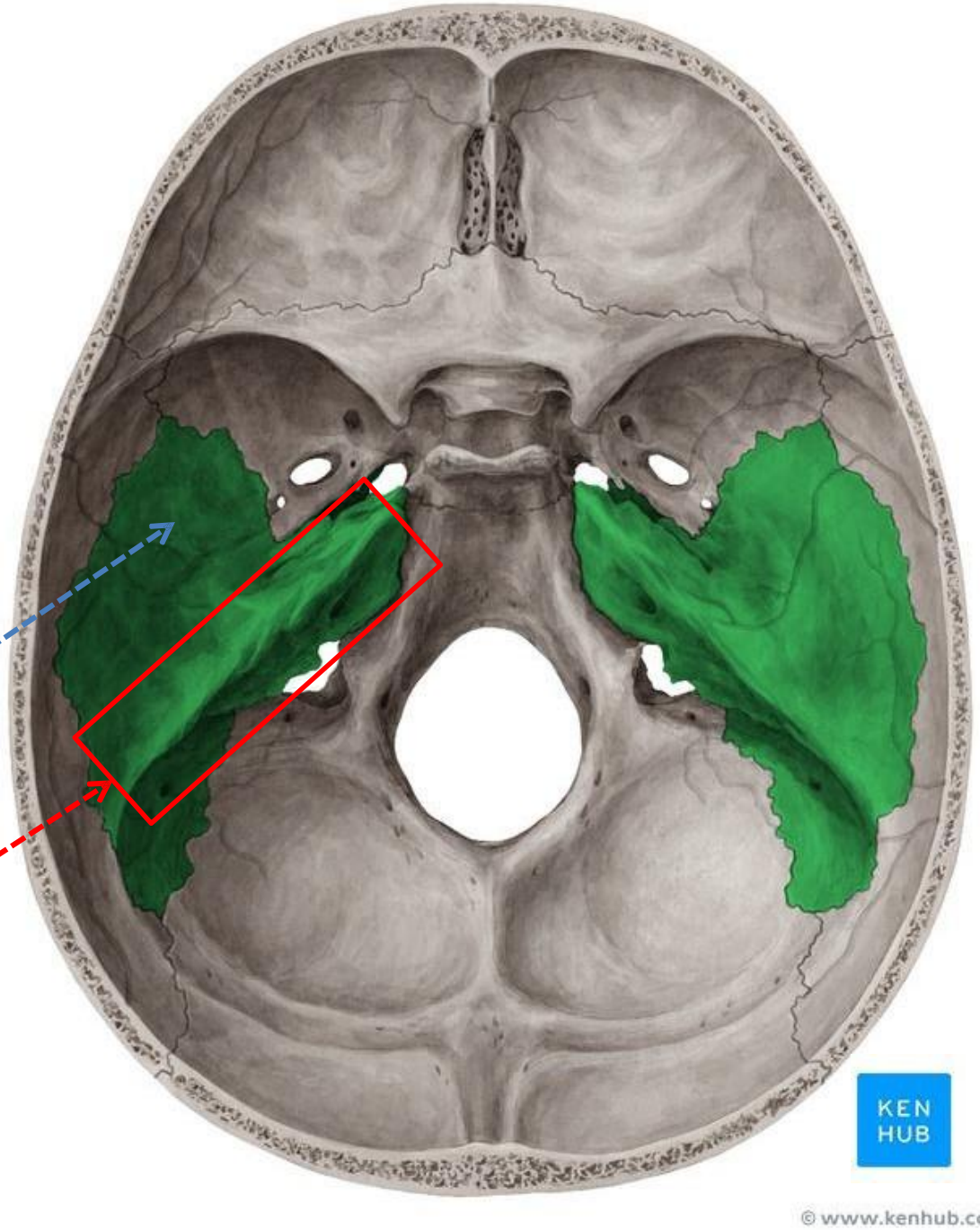

Squamous part

Petrous part

It has 1-apex
2-superior border
3-anterior surface (which part of middle cranial fossa)
4-posterior surface (which part of posterior cranial fossa)

Dr. Heba Kalbouneh

Resembles a bat having a centrally placed body with greater and lesser wings that are outstretched on each side

The **superior orbital fissure** is a slitlike opening between the lesser and greater wings of the sphenoid

The body of the sphenoid: contains the **sphenoid air sinuses**

Sphenoid bone

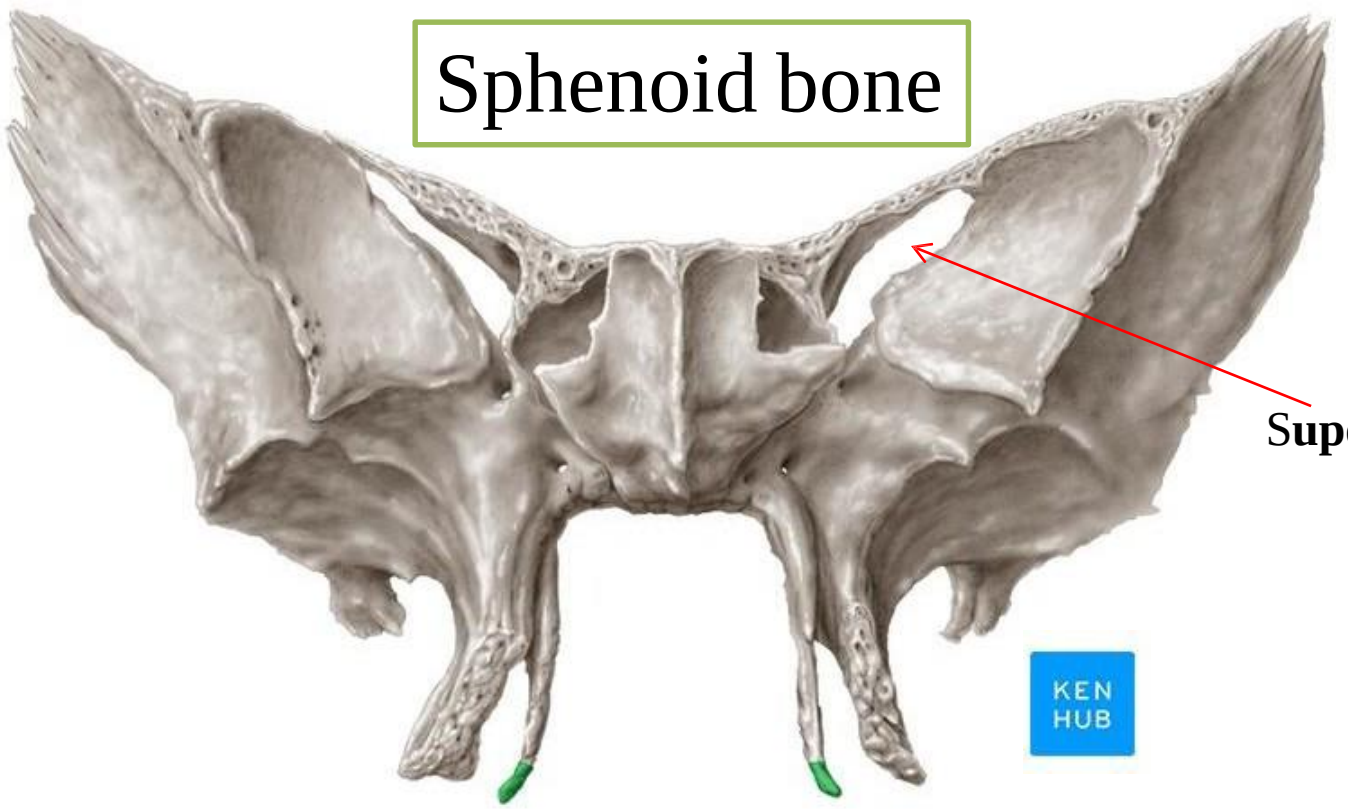

Superior orbital fissure

Dr. Heba Kalbouneh

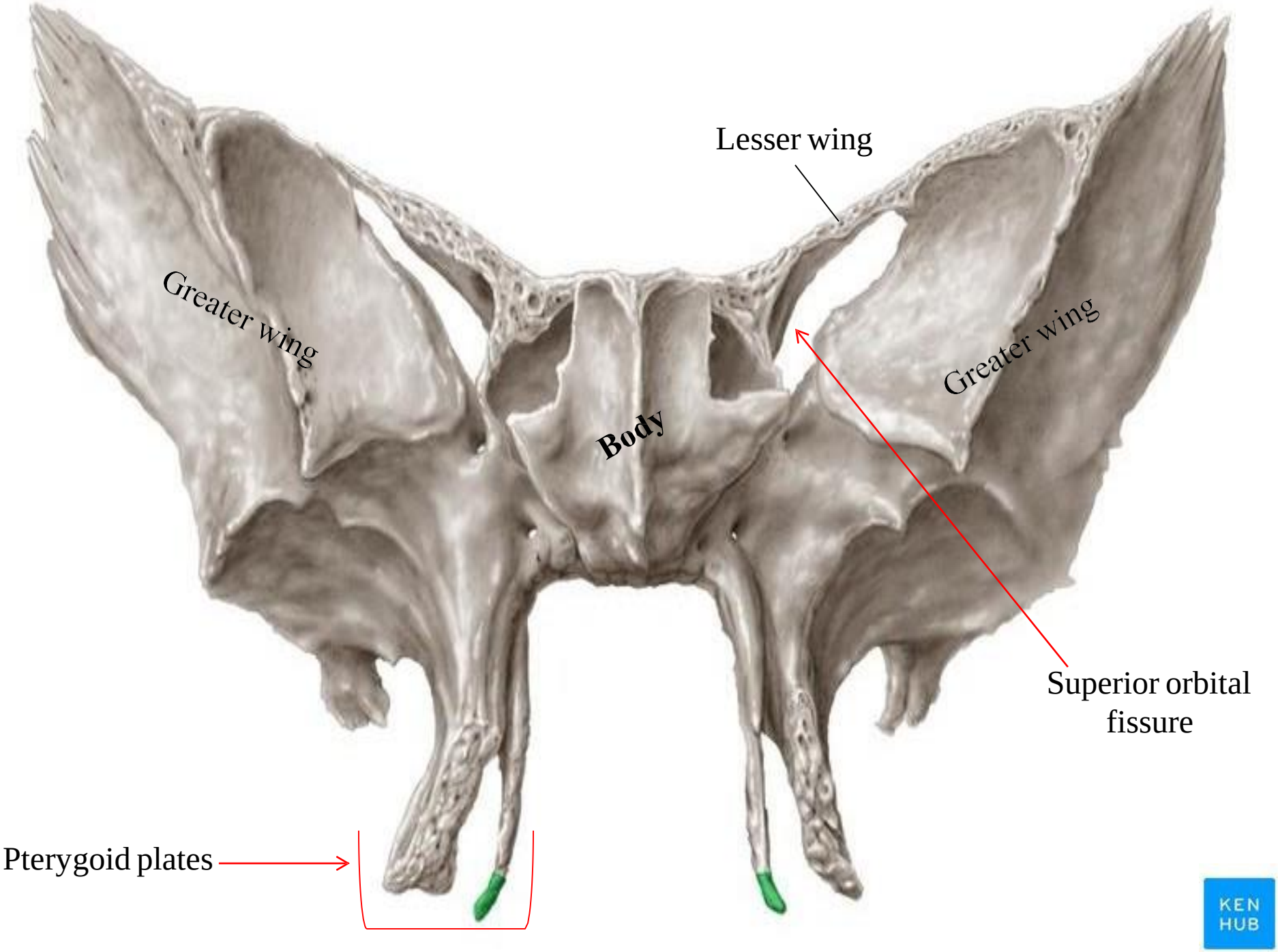
Lesser wing
Greater wing
Greater wing
Body
Superior orbital fissure
Pterygoid plates
KEN HUB

Sphenoid bone

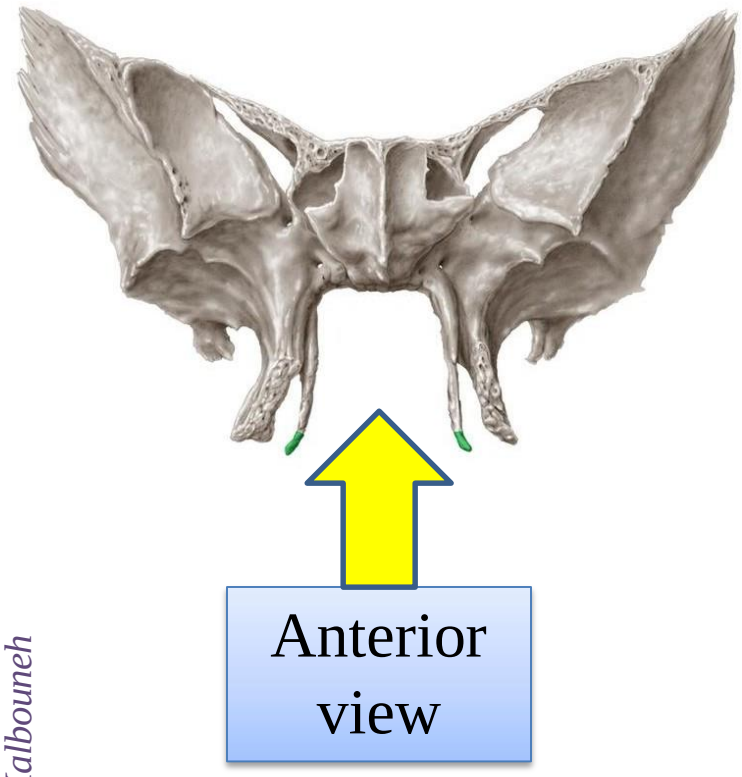

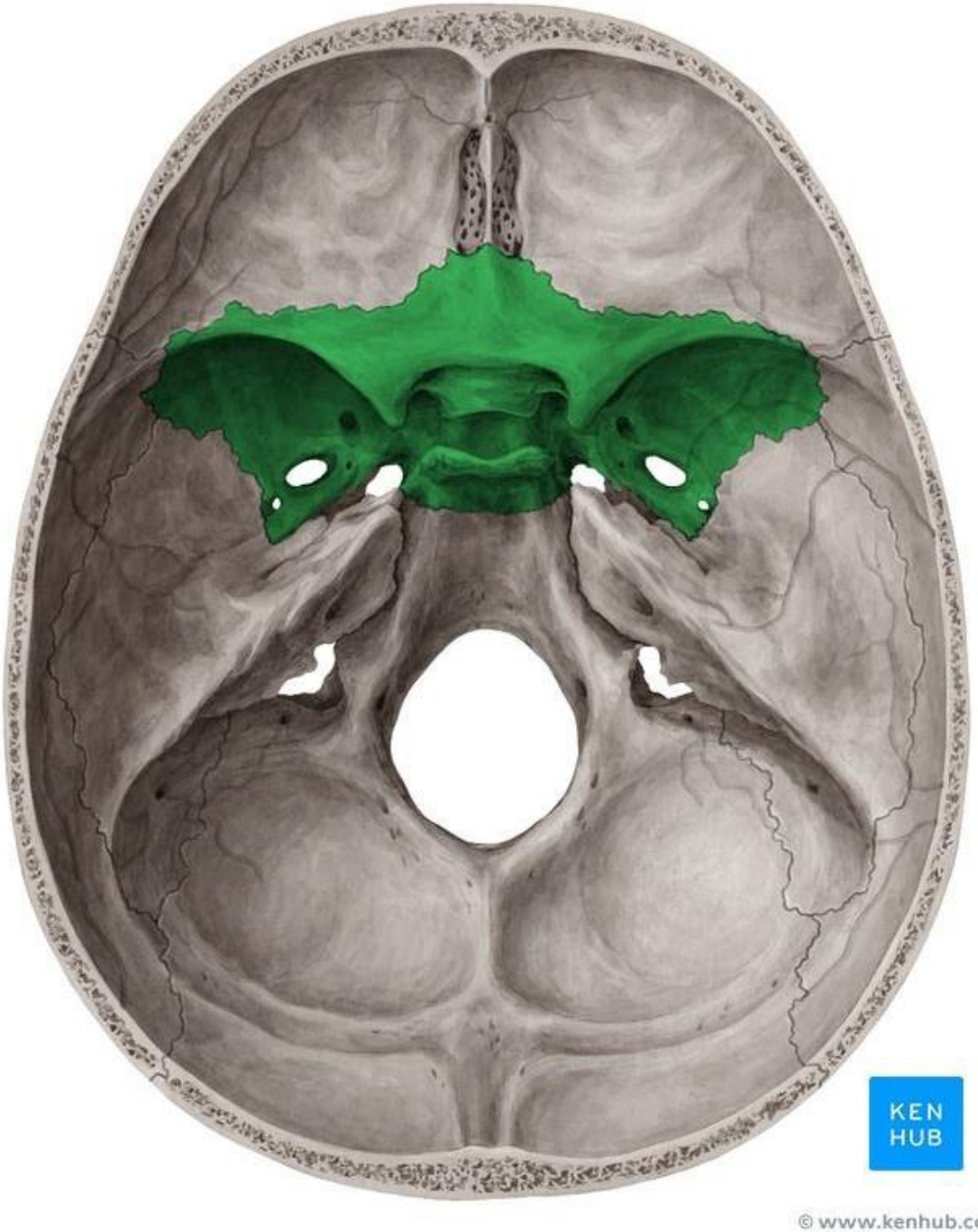

Dr. Heba Kalbouneh

Body of Sphenoid bone

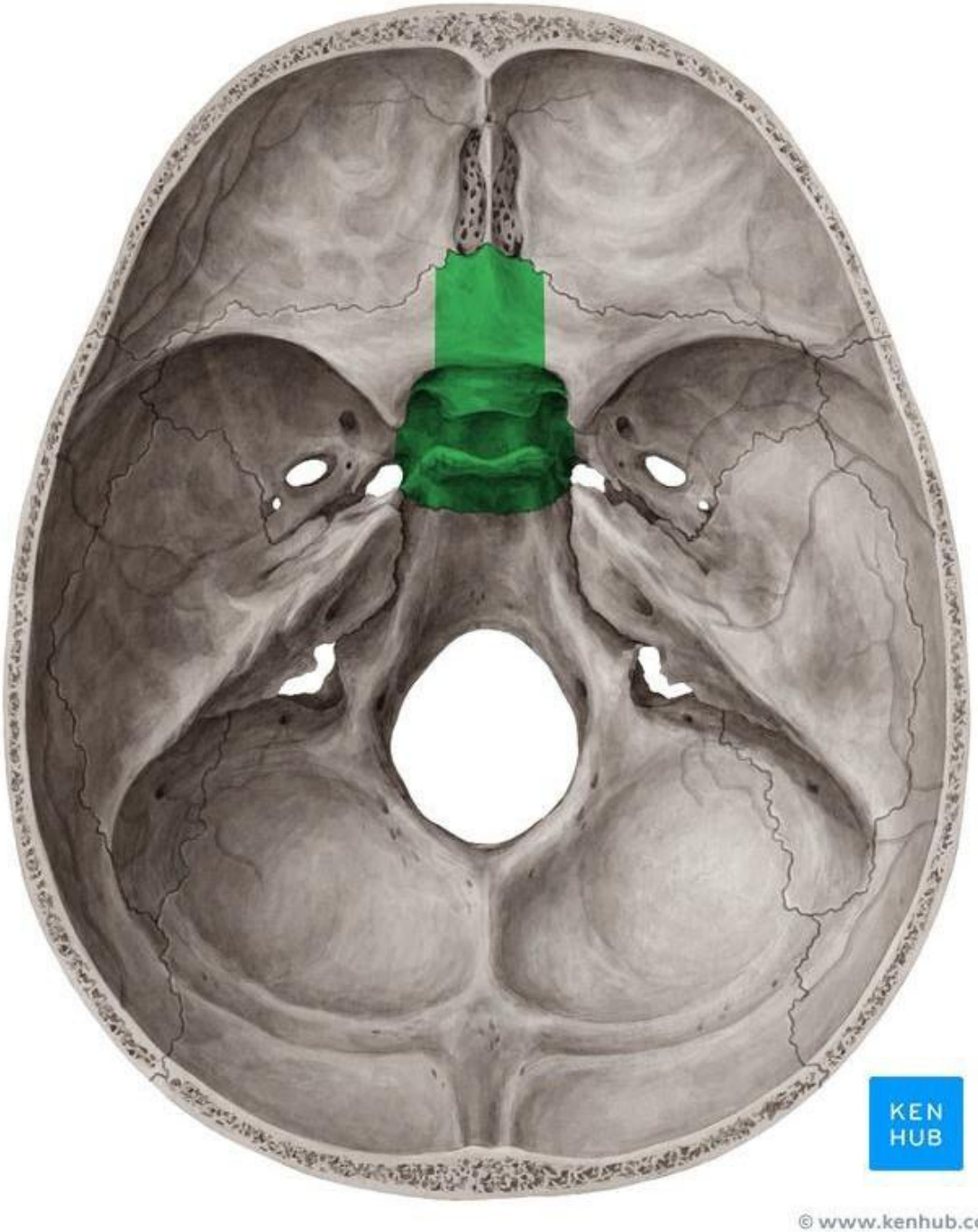

Dr. Heba Kalbouneh

Greater wing of Sphenoid bone

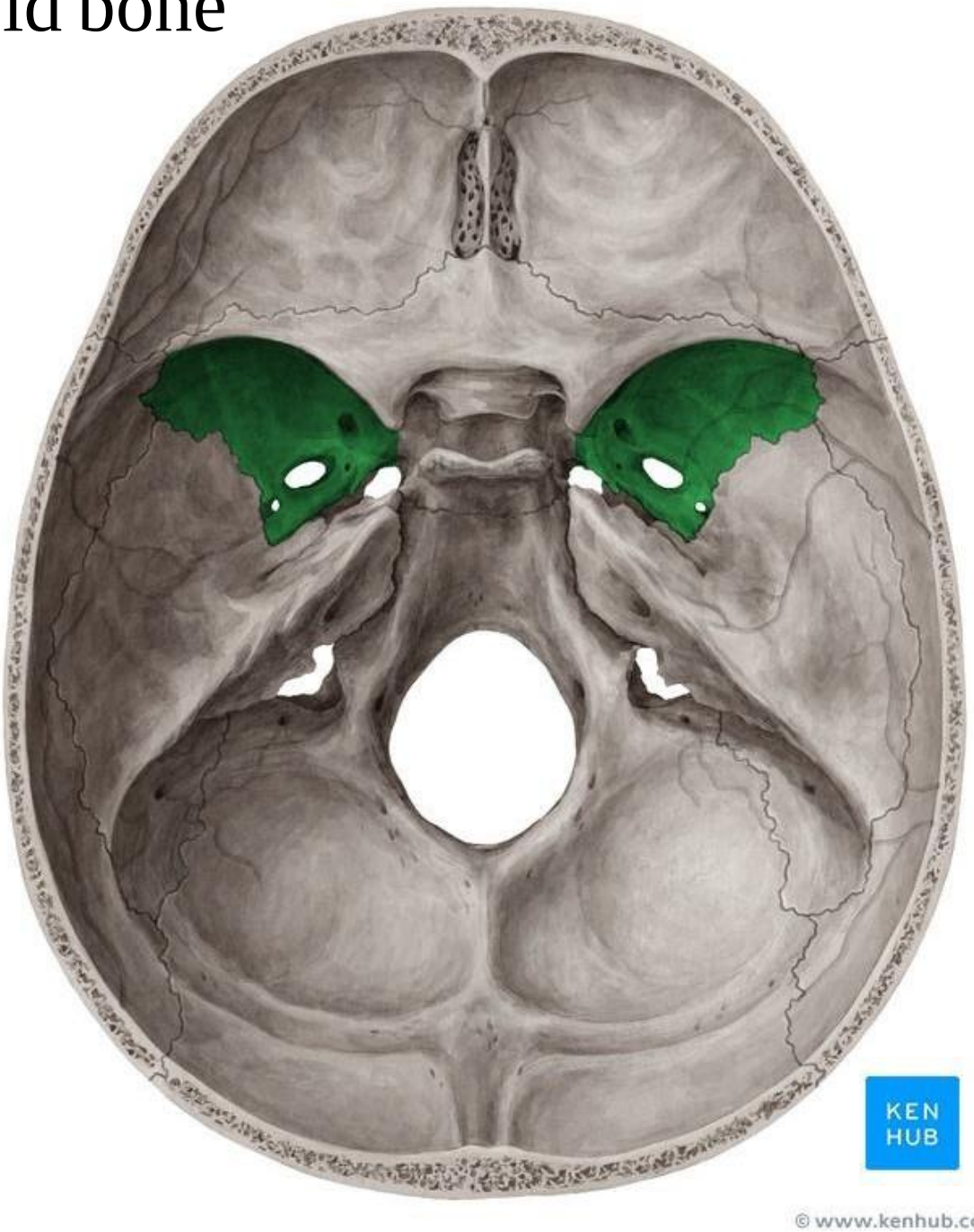

Dr. Heba Kalbouneh

Lesser wing of Sphenoid bone

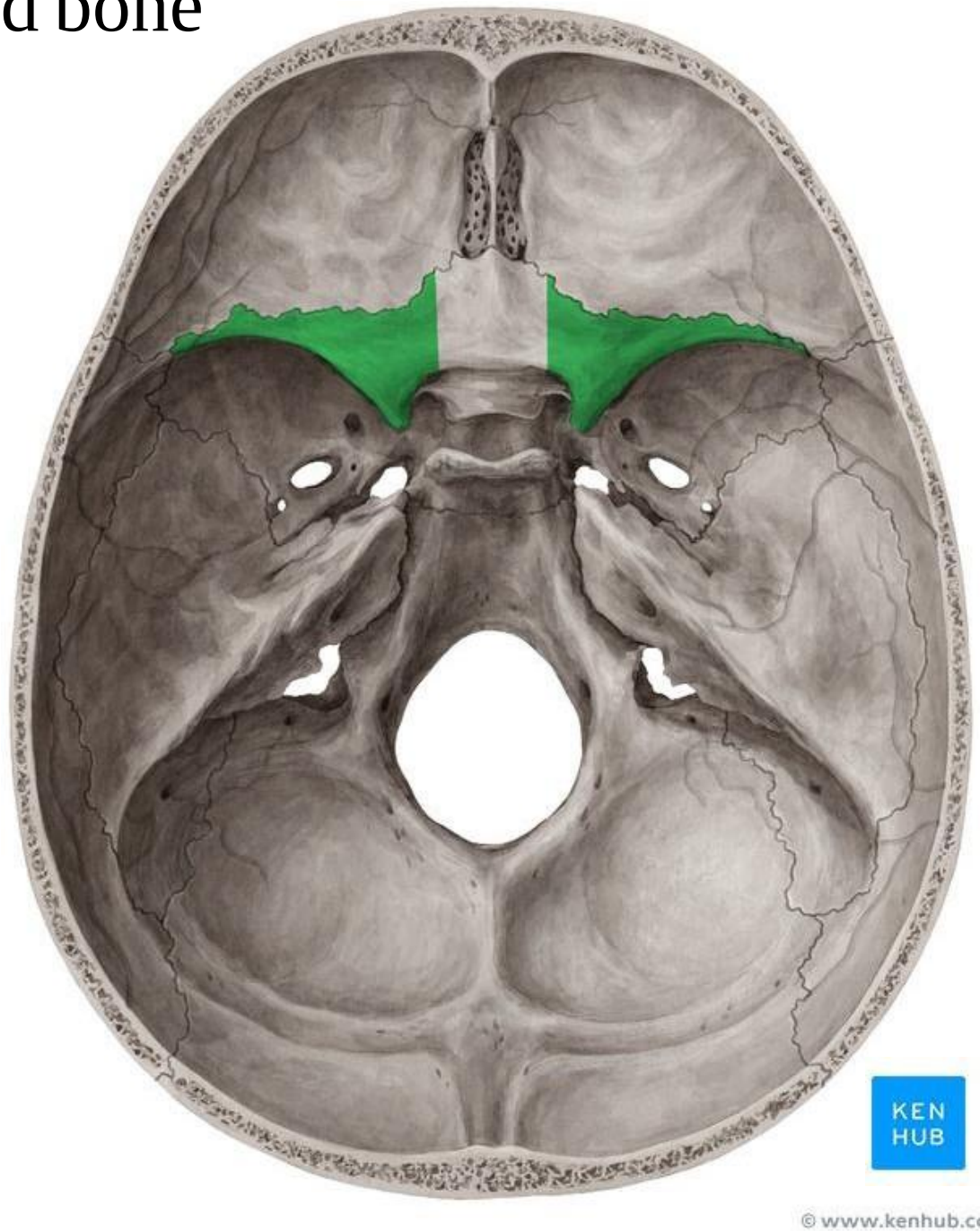

Dr. Heba Kalbouneh

Pterygoid plates

Foramen rotundum: situated behind the medial end of the superior orbital fissure. Transmits the maxillary nerve

Foramen ovale: lies posterolateral to the foramen rotundum transmits the mandibular nerve

Foramen spinosum (small) lies posterolateral to the foramen ovale. Transmits the middle meningeal artery

Carotid canal: Transmits the internal carotid artery

Foramen lacerum lies at the apex of the petrous part of the temporal bone . In life is filled by cartilage and fibrous tissue, and only small blood vessels pass through this tissue

Meckl's cave: impression on the apex of the petrous part of the temporal bone for the trigeminal ganglion

Dr. Heba Kalbouneh

KEN HUB

Dr. Heba Kalbouneh

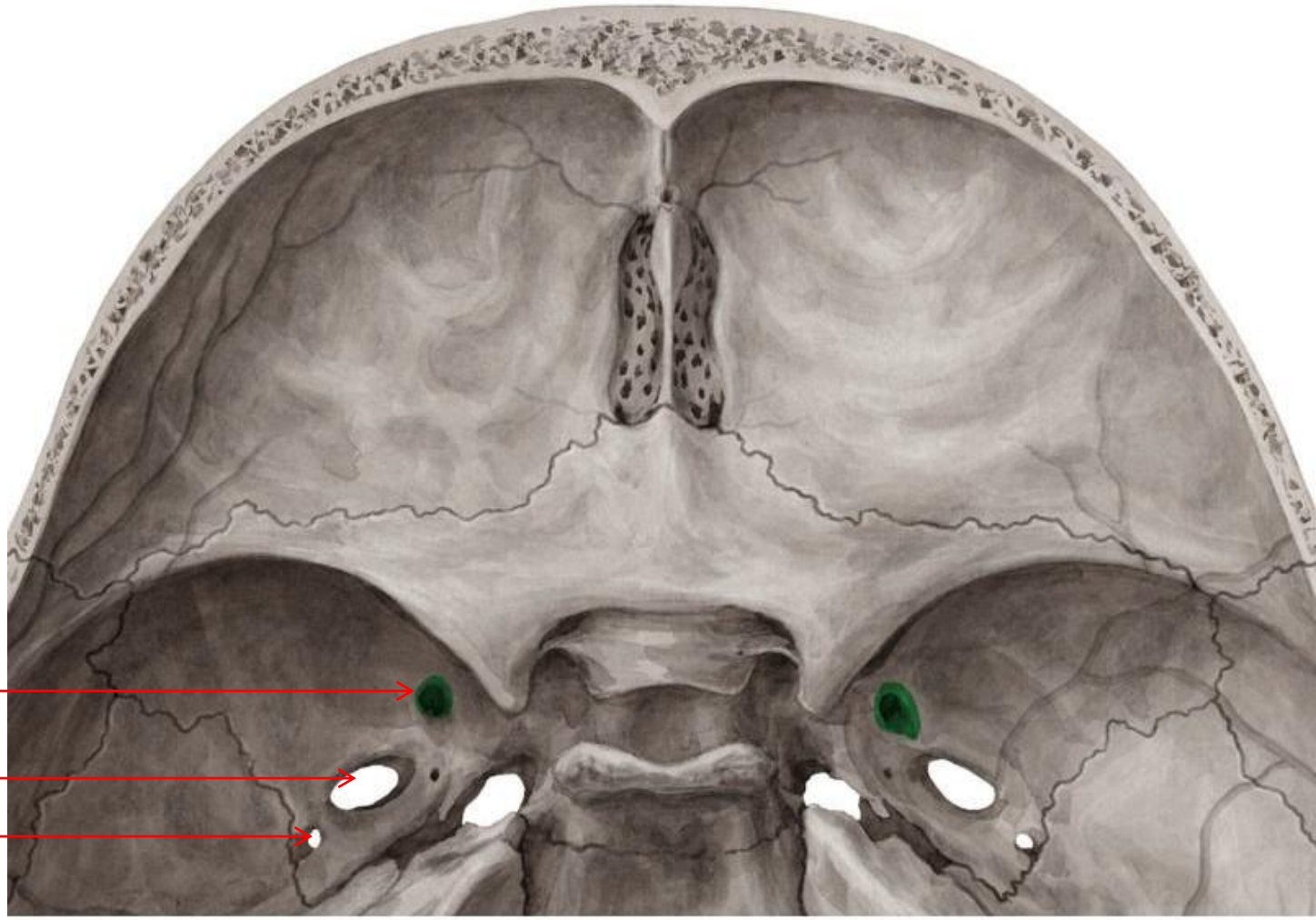

© www.kenhub.com
KEN HUB

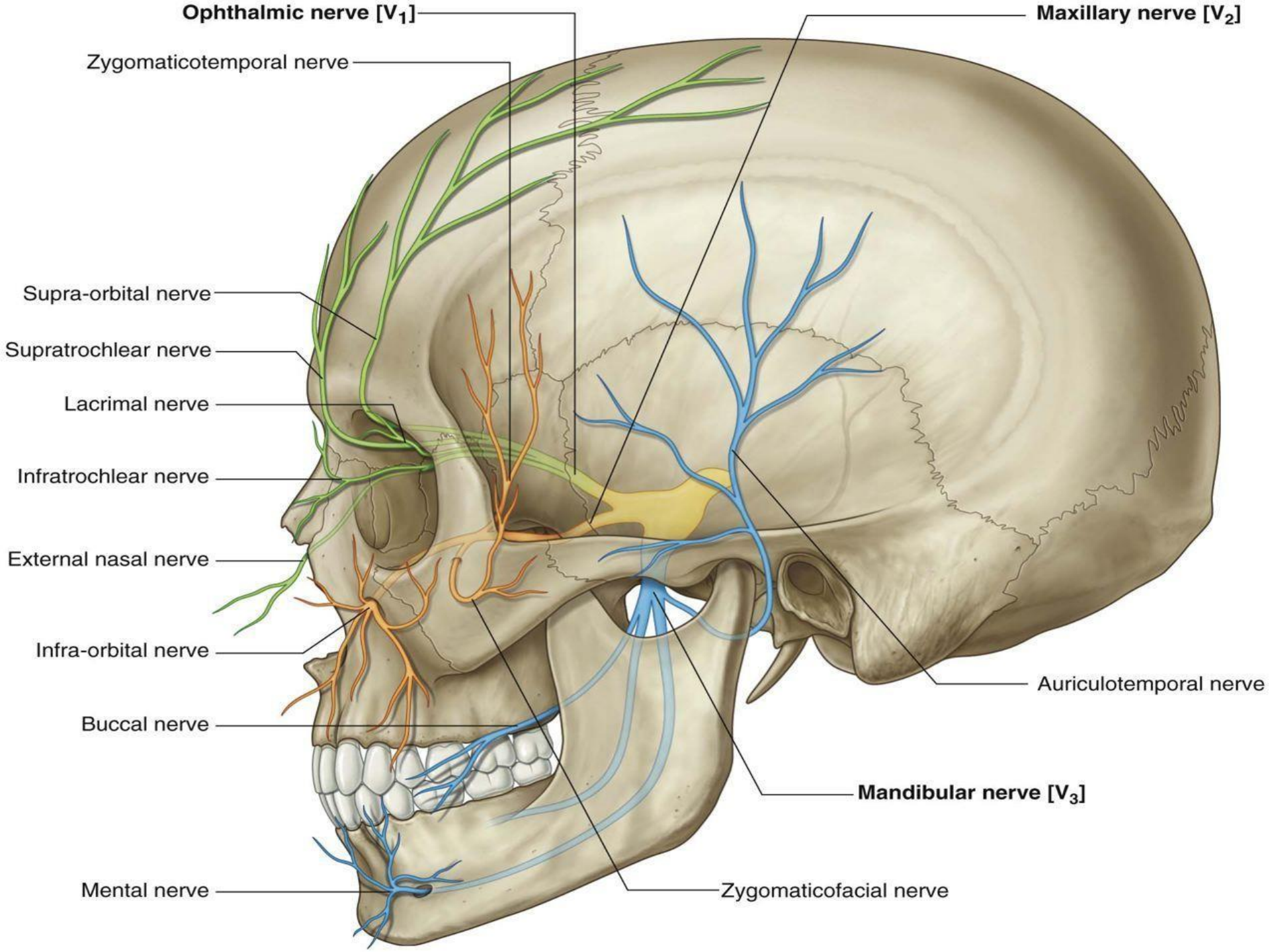
Ophthalmic nerve [V_1]
Maxillary nerve [V_2]
Zygomaticotemporal nerve
Supra-orbital nerve
Supratrochlear nerve
Lacrimal nerve
Infratrochlear nerve
External nasal nerve
Infra-orbital nerve
Buccal nerve
Mental nerve
Auriculotemporal nerve
Mandibular nerve [V_3]
Zygomaticofacial nerve

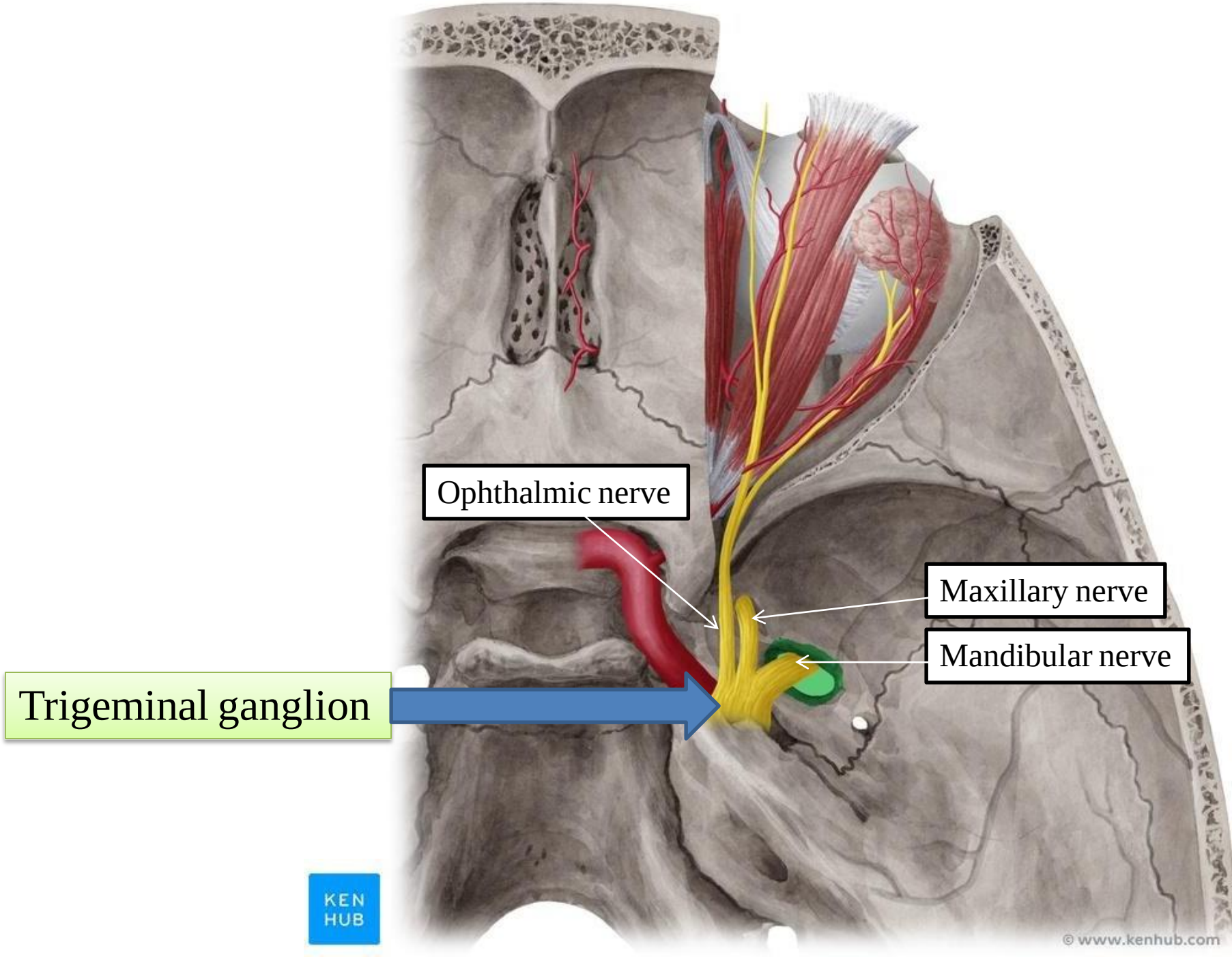

Dr. Heba Kalbouneh

in living subjects it closed by a fibrocartilage

Foramen lacerum

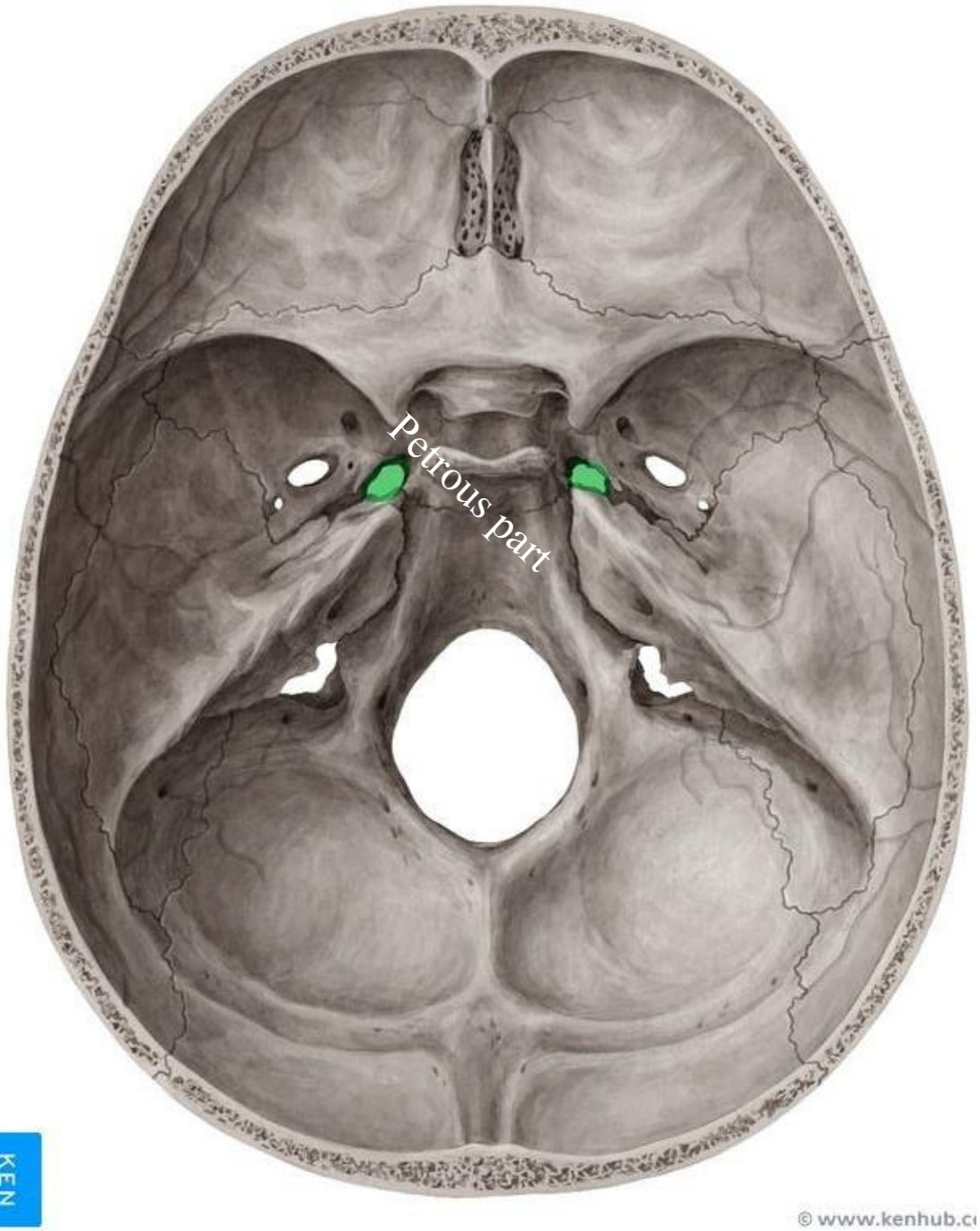

Meckl's cave
(Trigeminal impression)

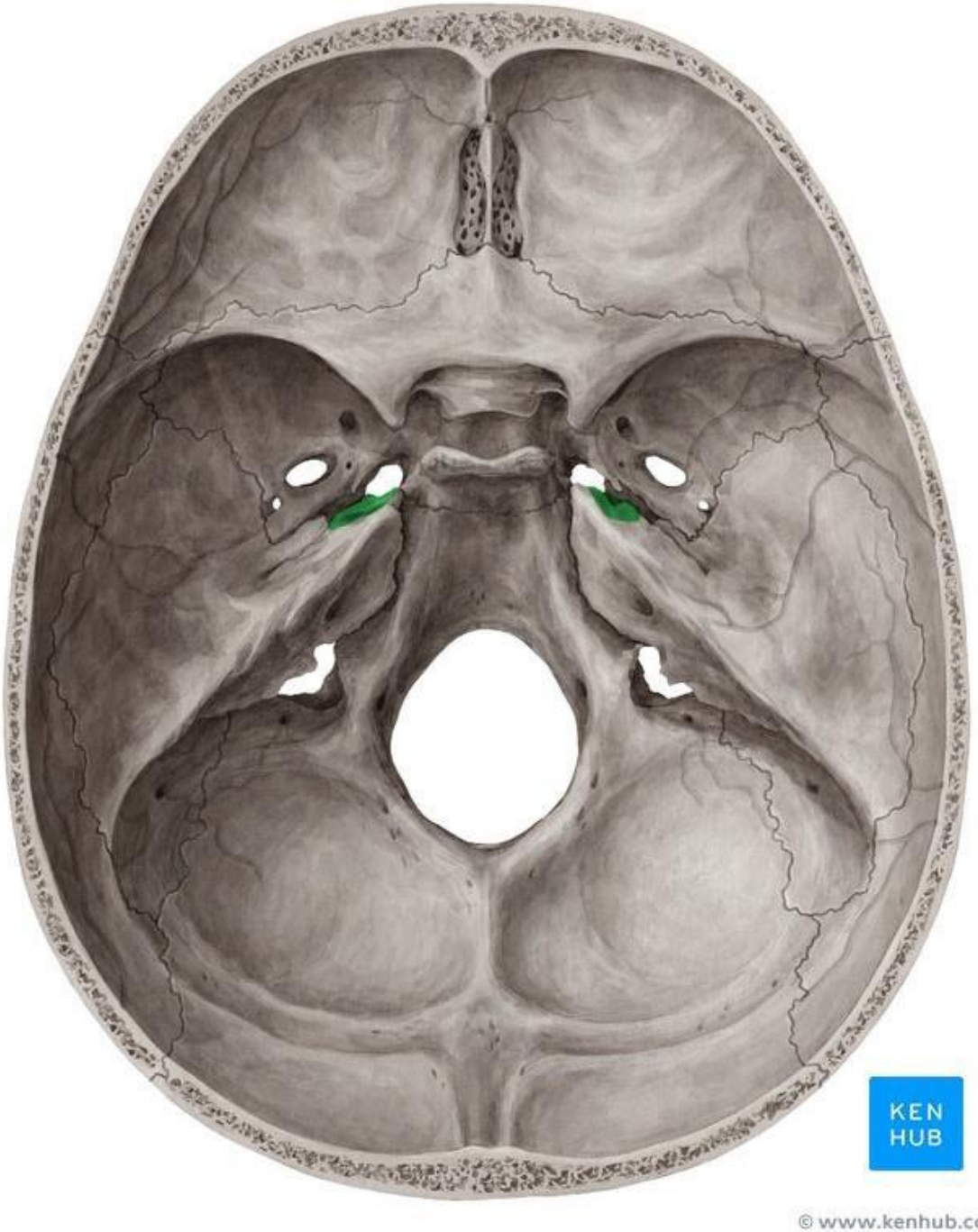

Dr. Heba Kalbouneh

Carotid canal

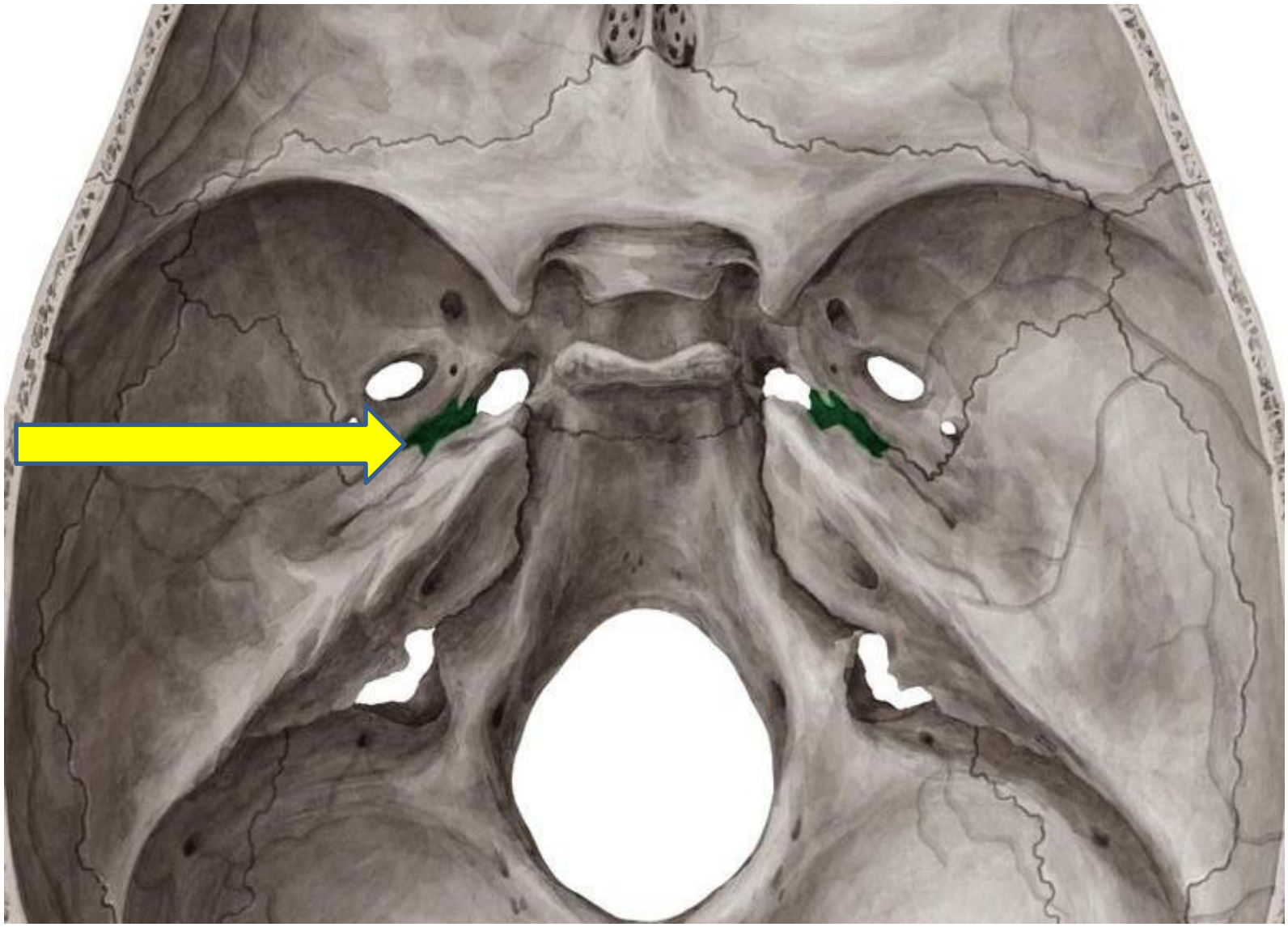

KEN HUB

The median part of the middle cranial fossa is formed by the **body of the sphenoid**

Sulcus chiasmaticus (chiasmatic groove) is related to the optic chiasma and leads laterally to the **Optic canal**

On the superior aspect of the body is a depression called the **Sella turcica** which contains the pituitary gland **(hypophyseal fossa)**

Posterior to the hypophyseal fossa is the **Dorsum sellae**

The superior angles of the dorsum sellae have two tubercles called the **Posterior clinoid processes**

In front of the hypophyseal fossa is the **Tuberculum sellae**

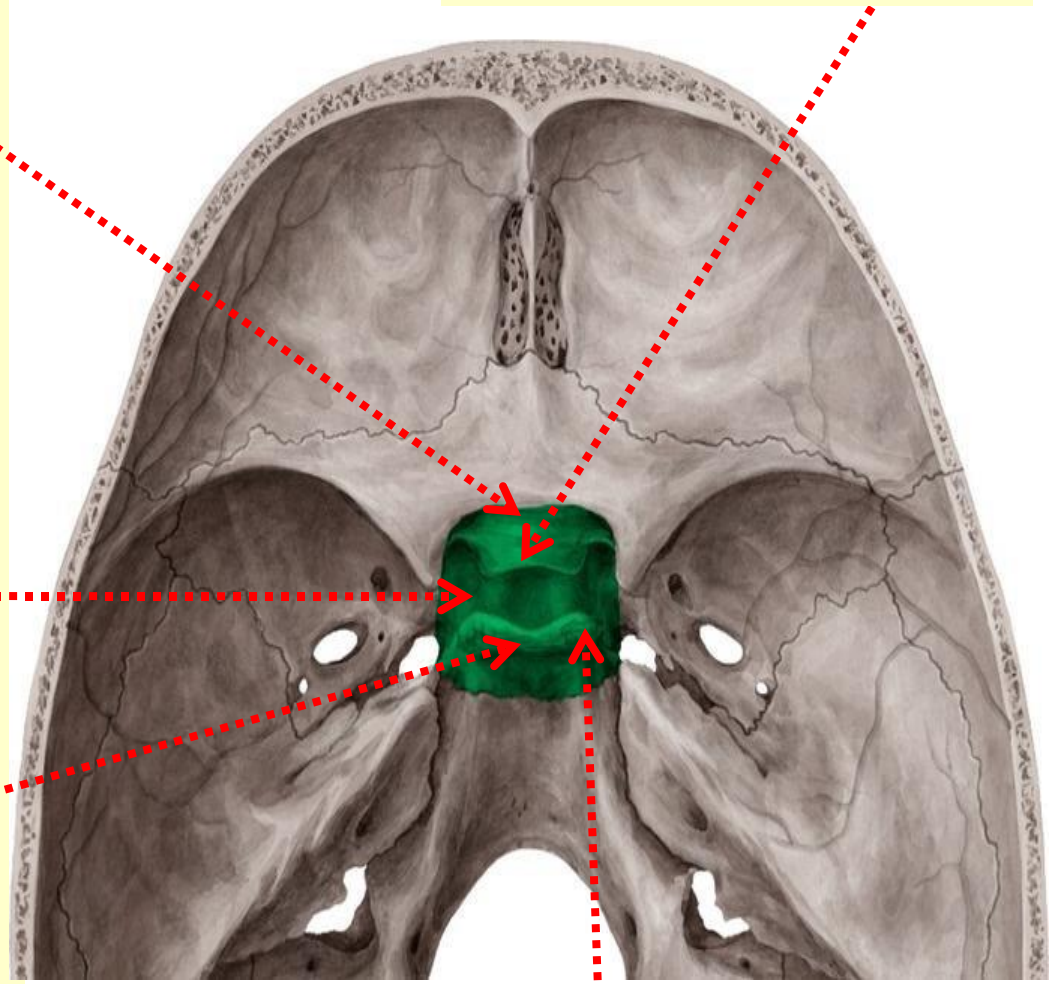

Dr. Heba Kalbouneh

The **sella turcica** (hypophyseal fossa) which CONTAINS THE **PITUITARY GLAND**

Dr. Heba Kalbouneh

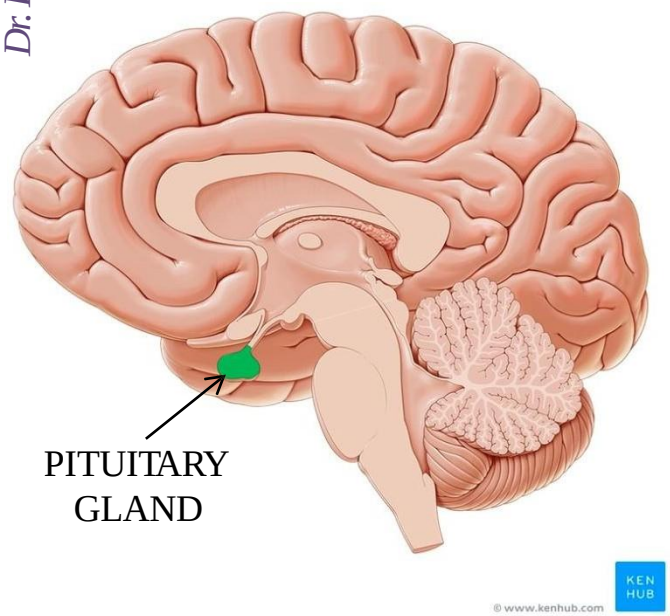

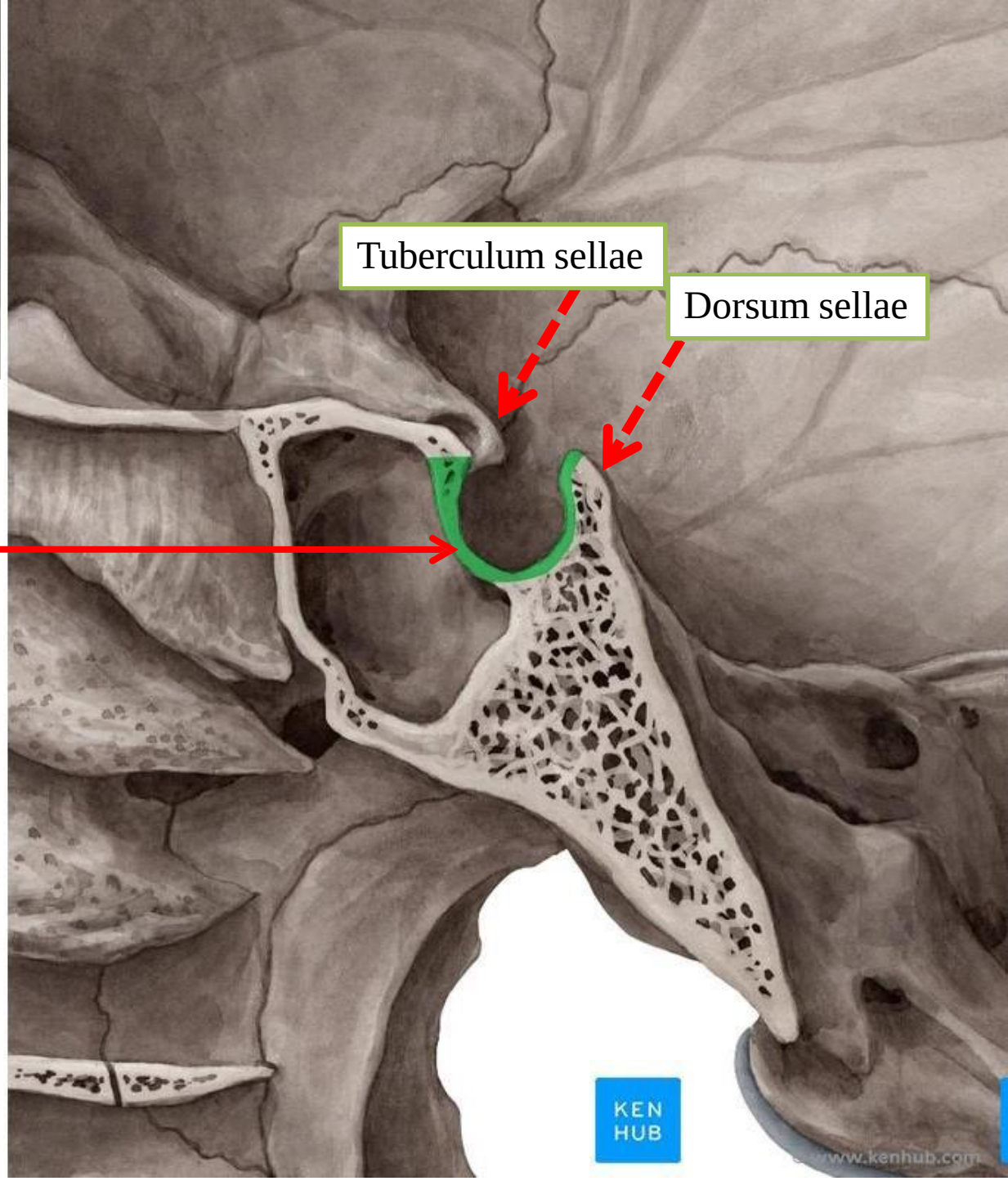

The other name for pituitary gland is hypophysis

Optic canals

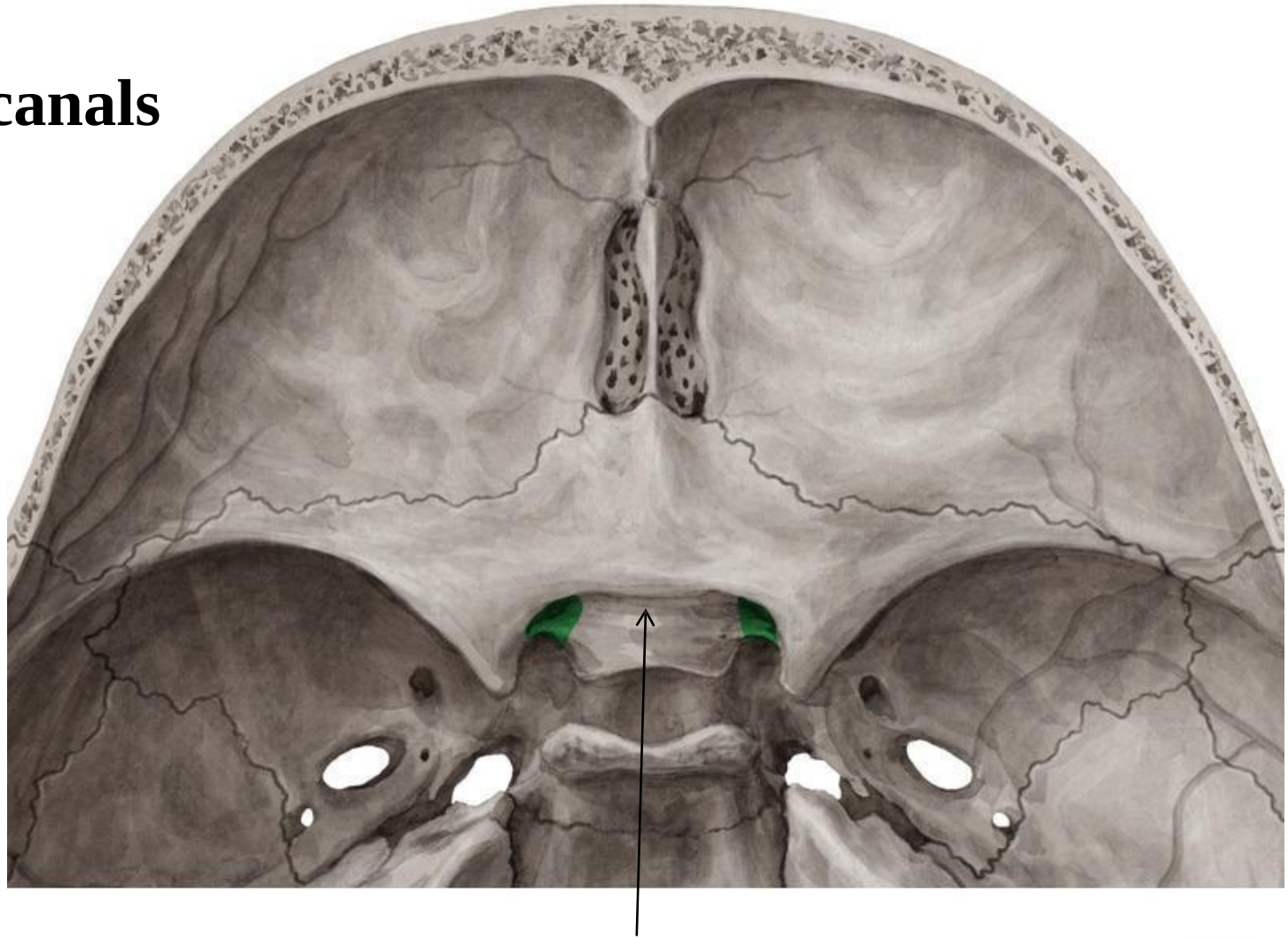

Sulcus chiasmaticus
(chiasmatic groove)

© www.kenhub.com

Is the groove between the optic canals

Dr. Heba Kalbouneh

Dr. Heba Kalbouneh

Optic canal transmits the optic nerve and the ophthalmic artery

Remember:
Ophthalmic artery is a branch from **internal carotid artery**

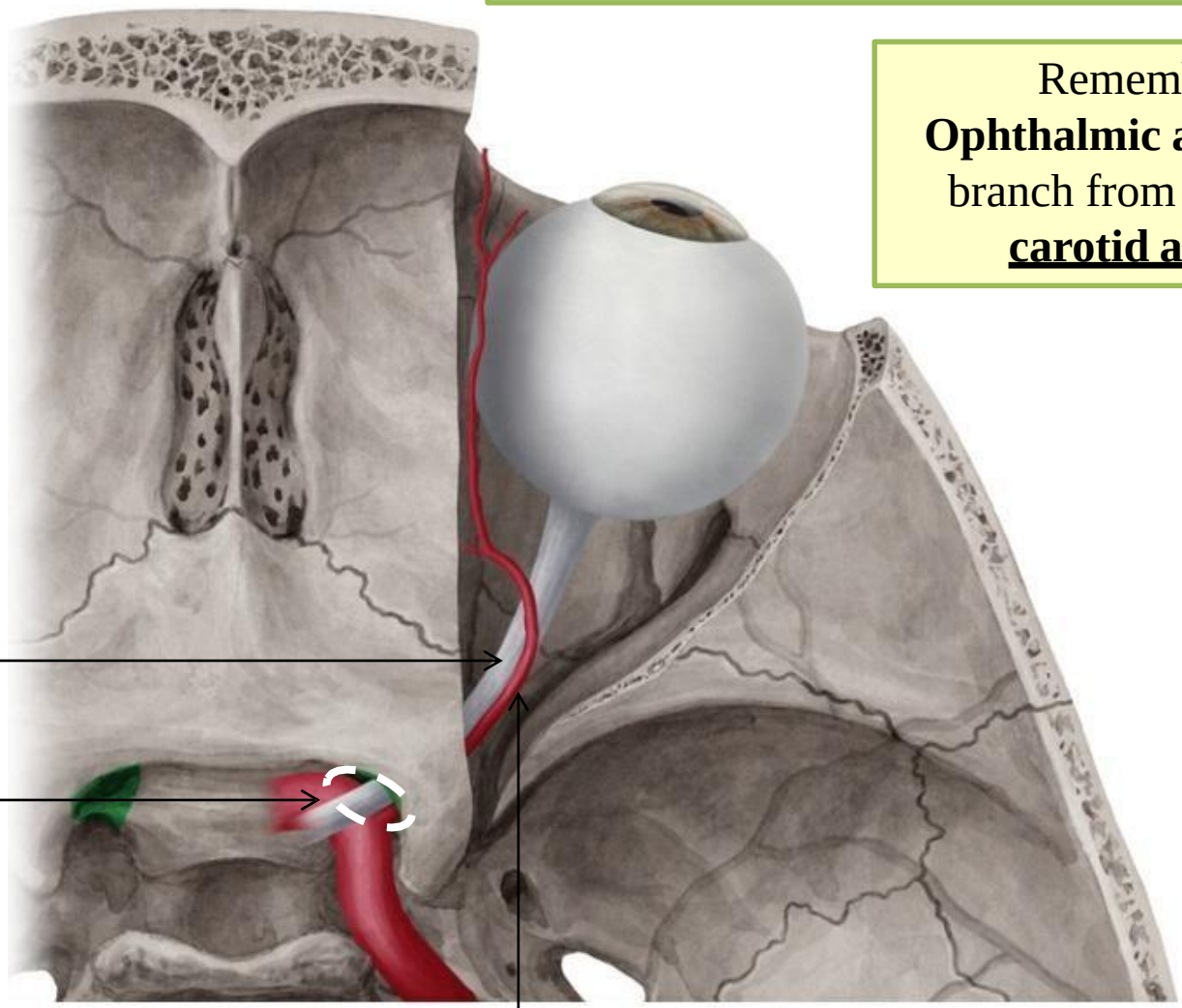

© www.kenhub.com
KEN HUB

Posterior cranial fossa

Formed mostly by parts of temporal and occipital bones

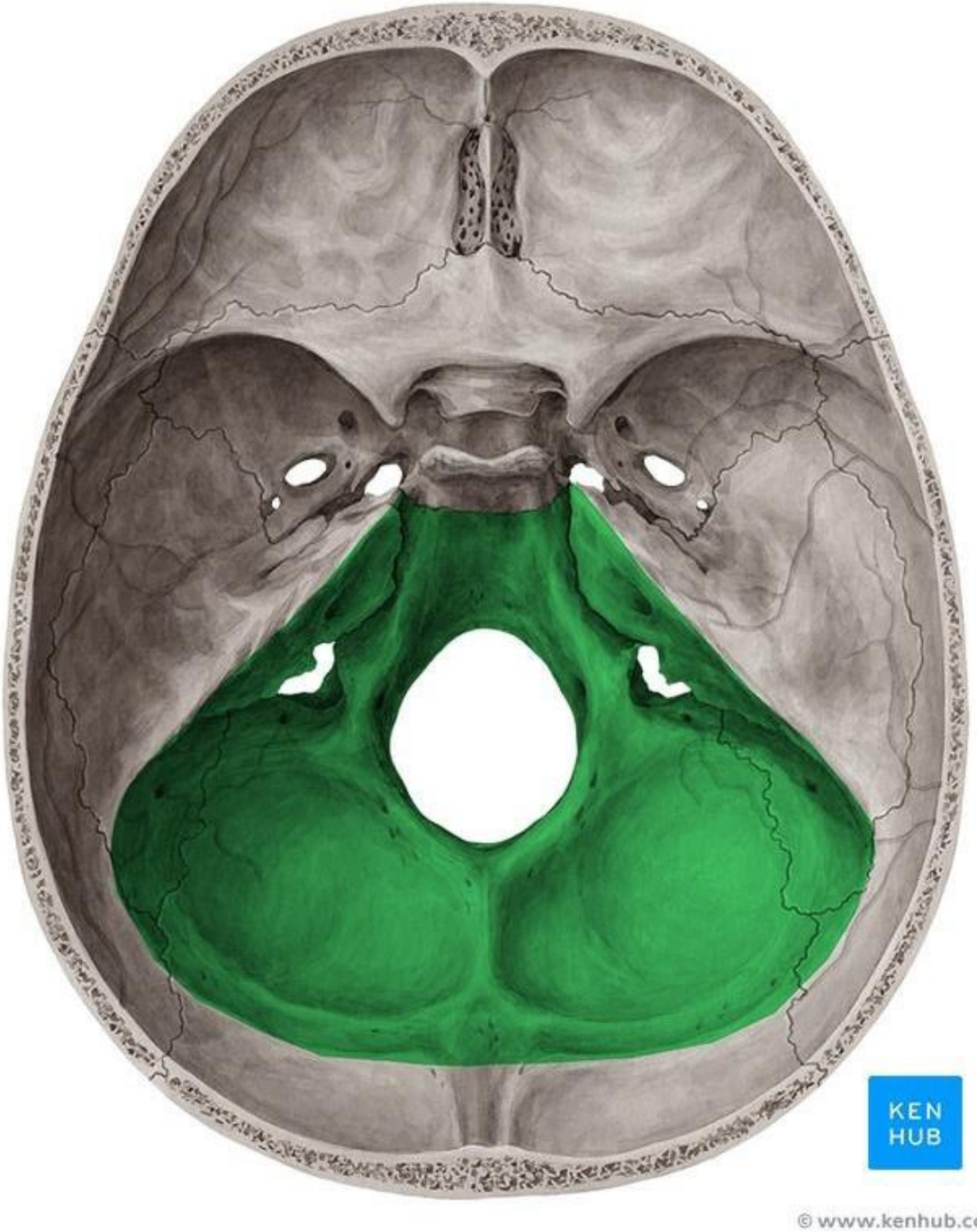

Dr. Heba Kalbouneh

The foramen magnum transmits

1- Medulla oblongata and its surrounding meninges

2- Spinal roots of the accessory nerves

3- Two vertebral arteries.

The **hypoglo˙ ssal canal** is situated above the anterolateral boundary of the foramen magnum and transmits the **hypoglossal nerve**

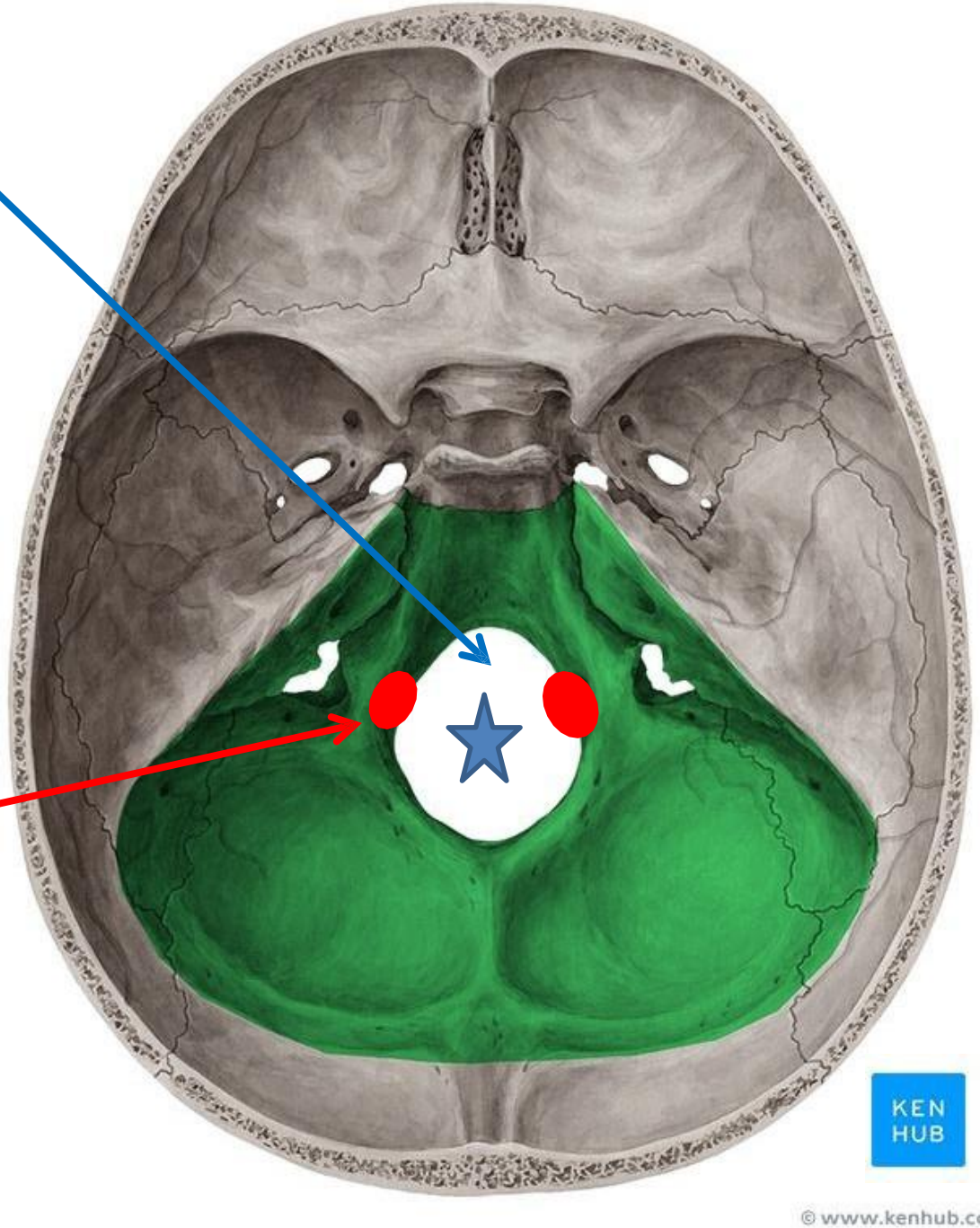

Dr. Heba Kalbouneh

The **jugular foramen** lies between the petrous part of the temporal bone and the occipital bone.

It transmits the following structures
Anterior part: the inferior petrosal sinus
Middle part: the 9th, 10th, and 11th cranial nerves
Posterior part: the large sigmoid sinus. The sigmoid sinus turns down through the foramen to become the internal jugular vein.

The internal acoustic meatus (on the posterior surface of the petrous part of the temporal bone): transmits the vestibulocochlear nerve and the facial nerve (7th and 8th cranial nerves)

The internal occipital crest runs upward in the midline posteriorly from the foramen magnum to the **internal occipital protuberance**

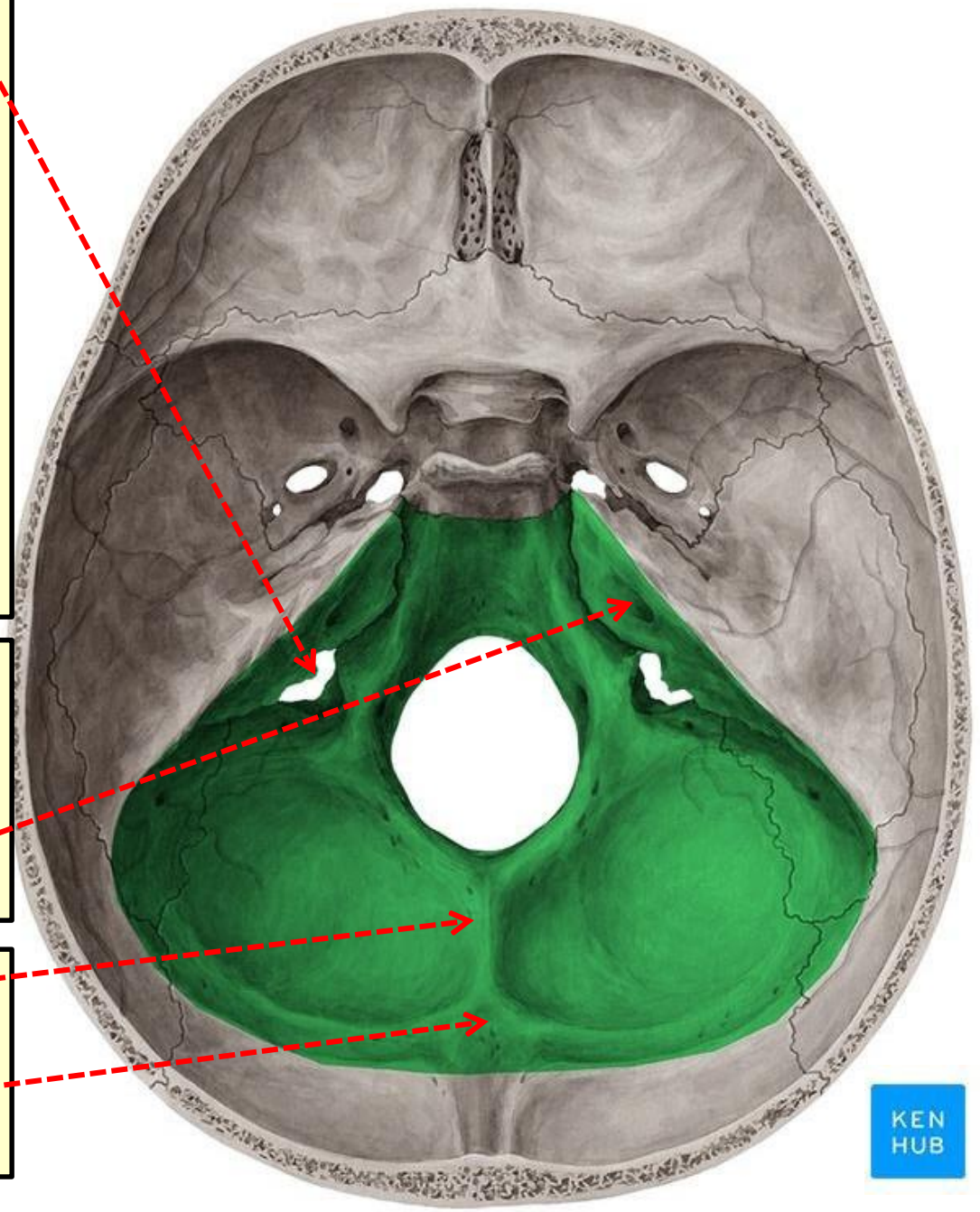

© www.kenhub.c

Dr. Heba Kalbouneh

Occipital bone

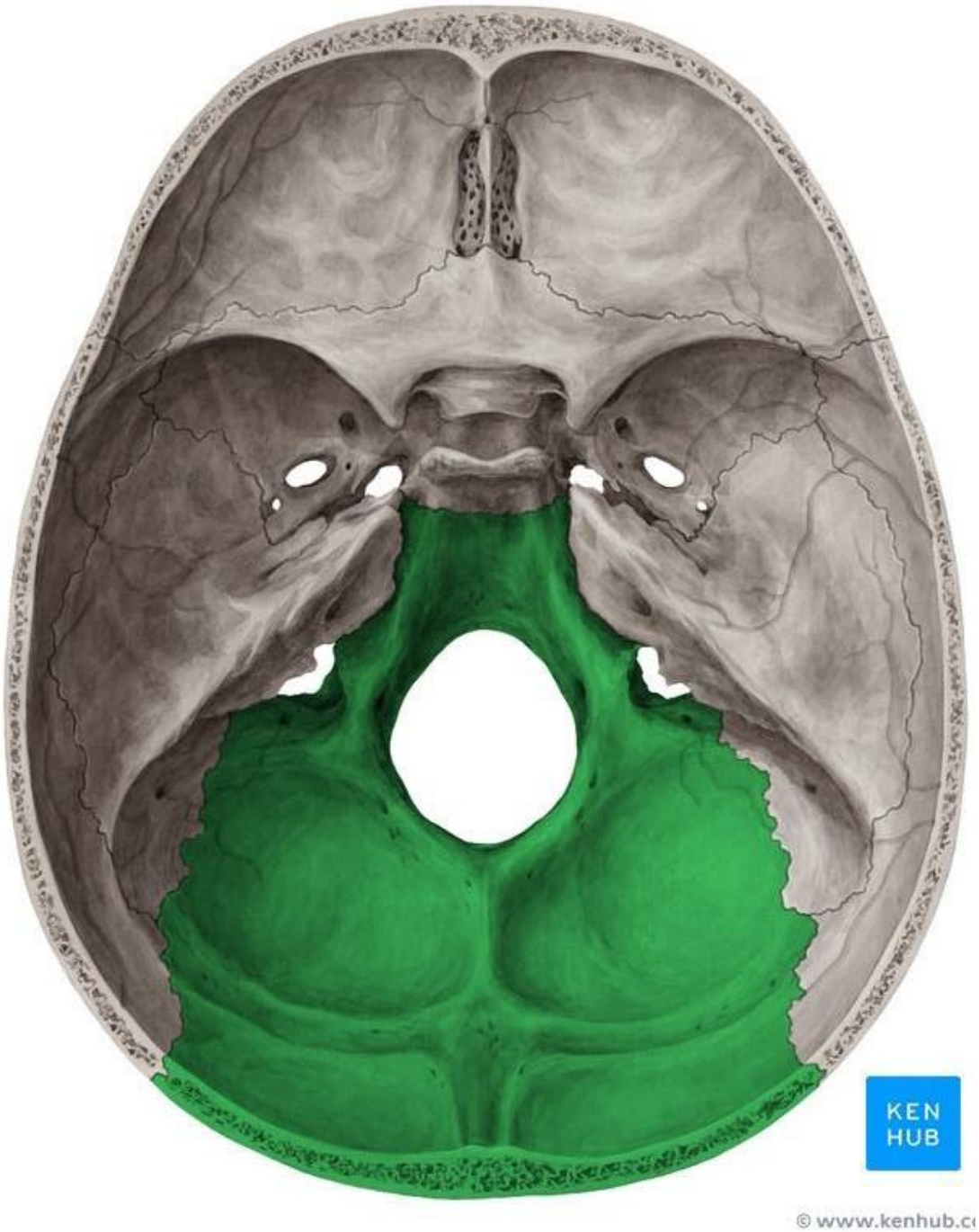

Clivus

is the sloping midline surface of the occipital bone anterior to the foramen magnum

Clivus: Slope

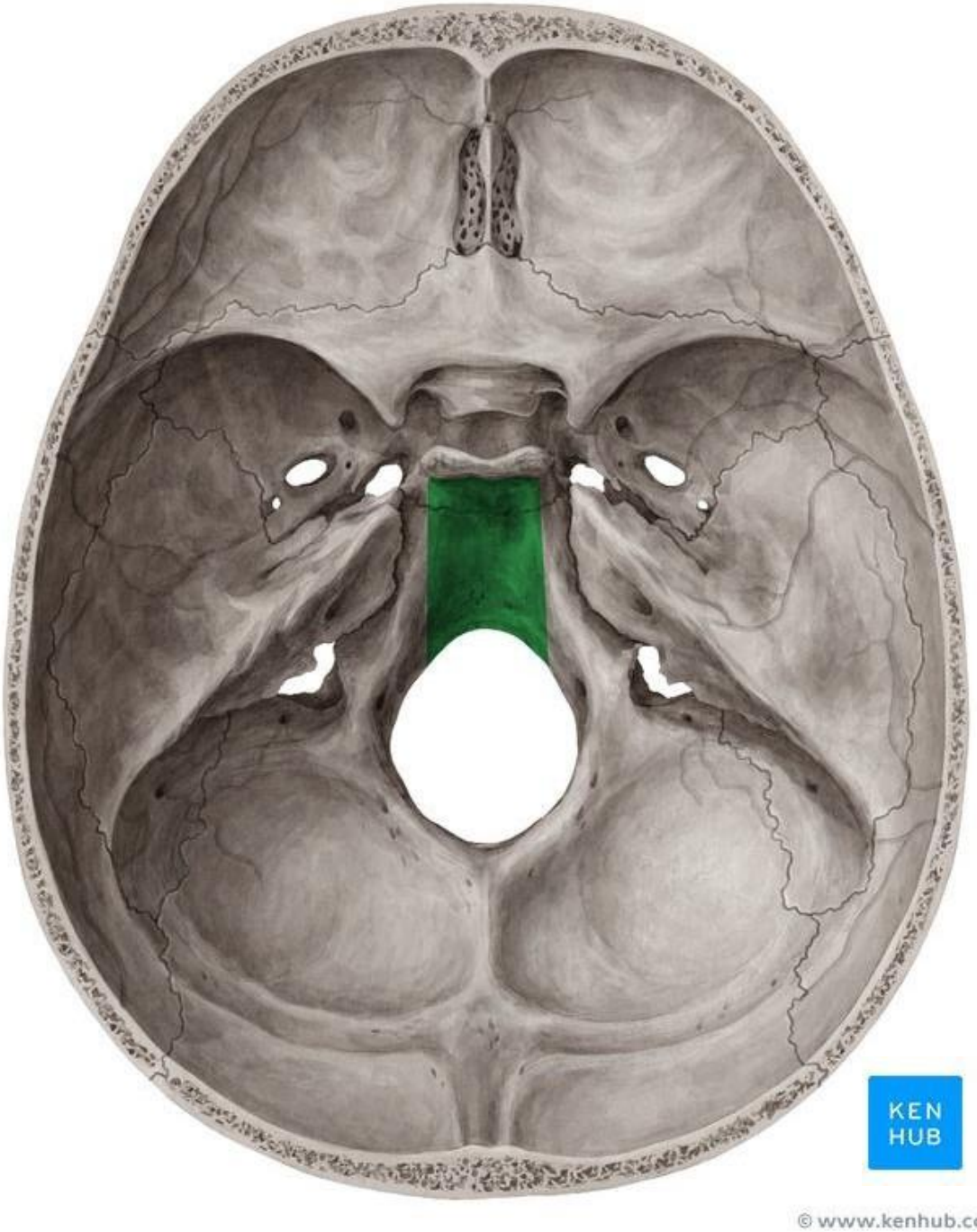

Dr. Heba Kalbouneh

Internal acoustic meatus

Transmits the vestibulocochlear nerve and the facial nerve (7th and 8th cranial nerves)

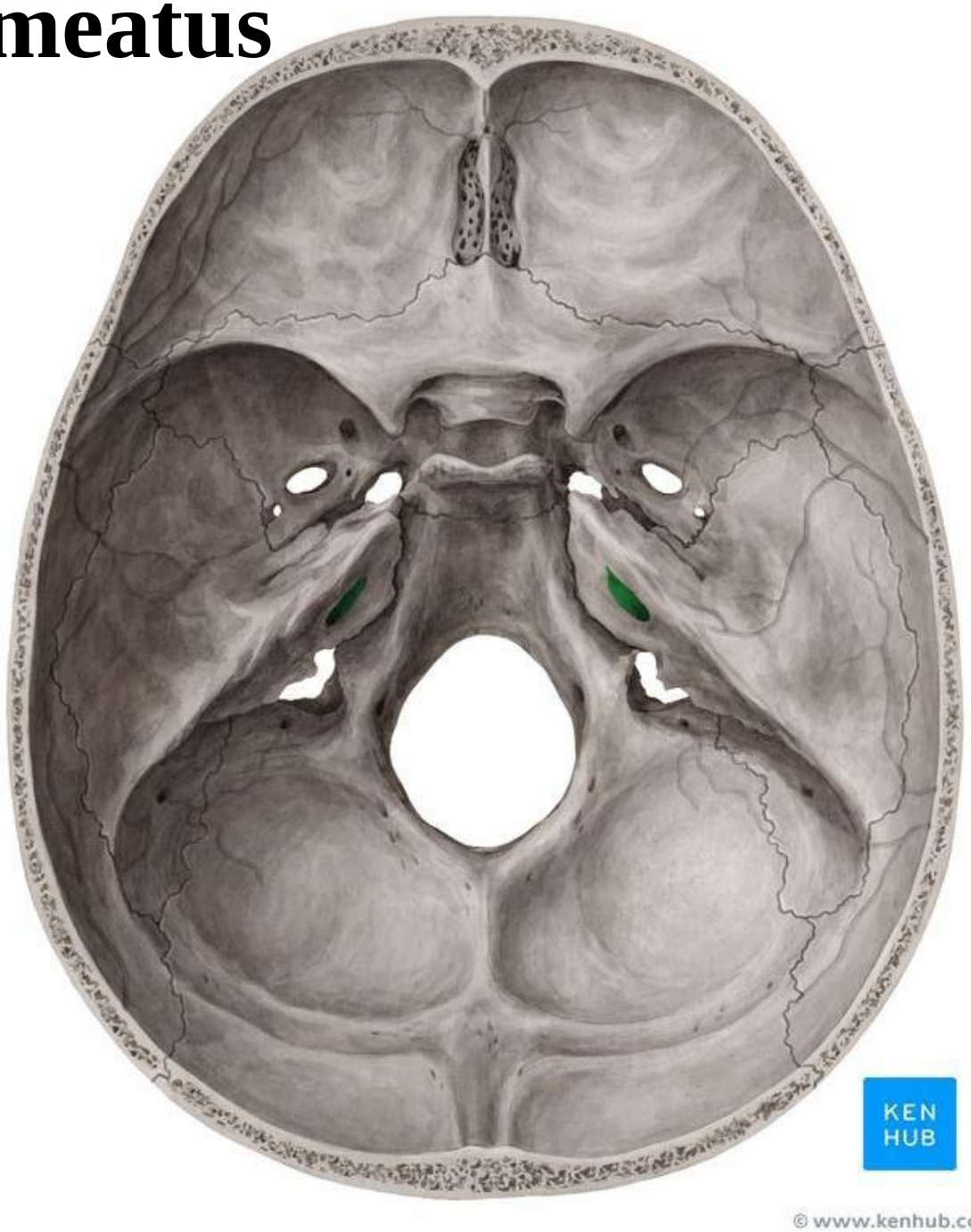

Dr. Heba Kalbouneh

Cerebellar fossa

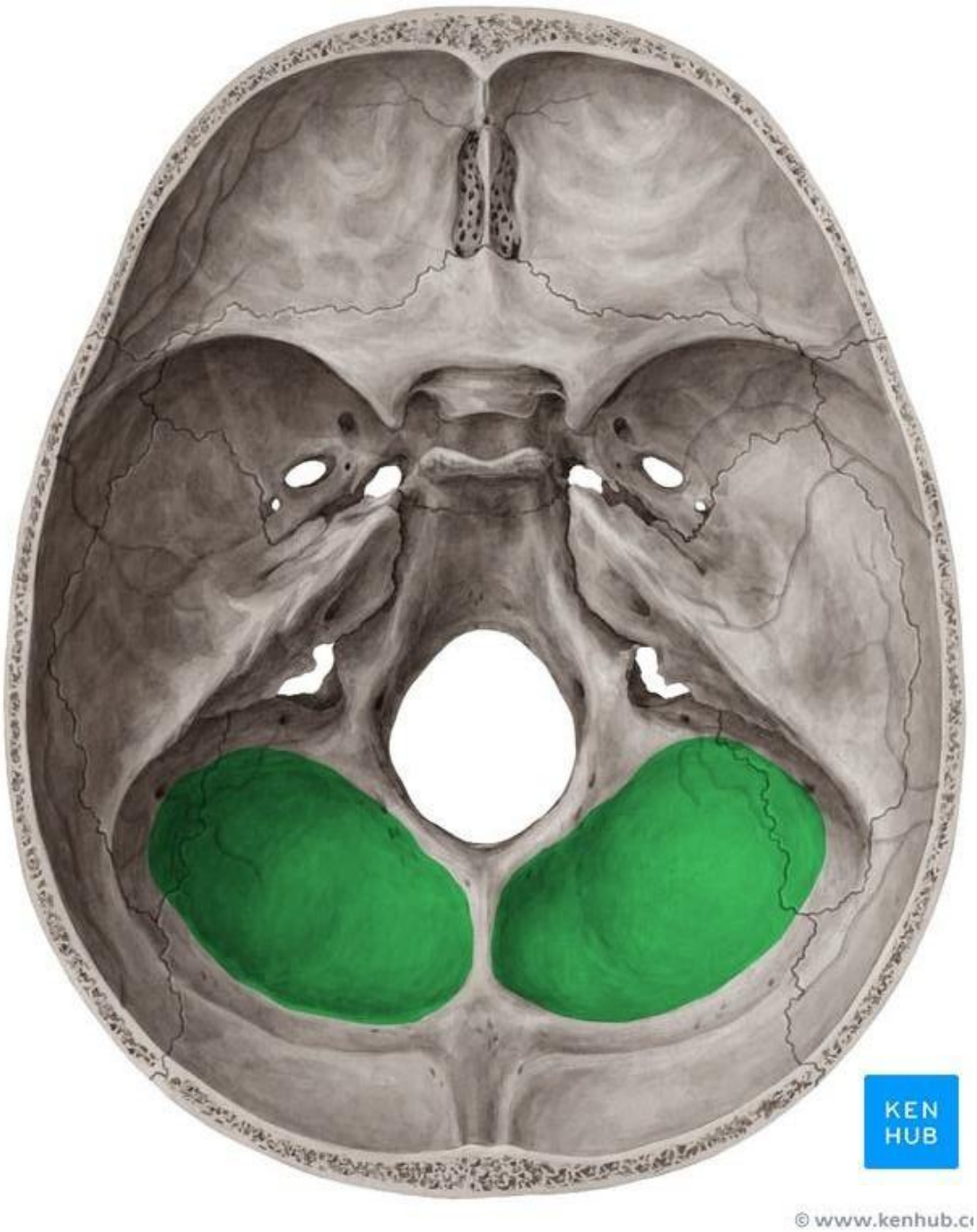

Ethmoid bone

Delicate bone located between the two orbits

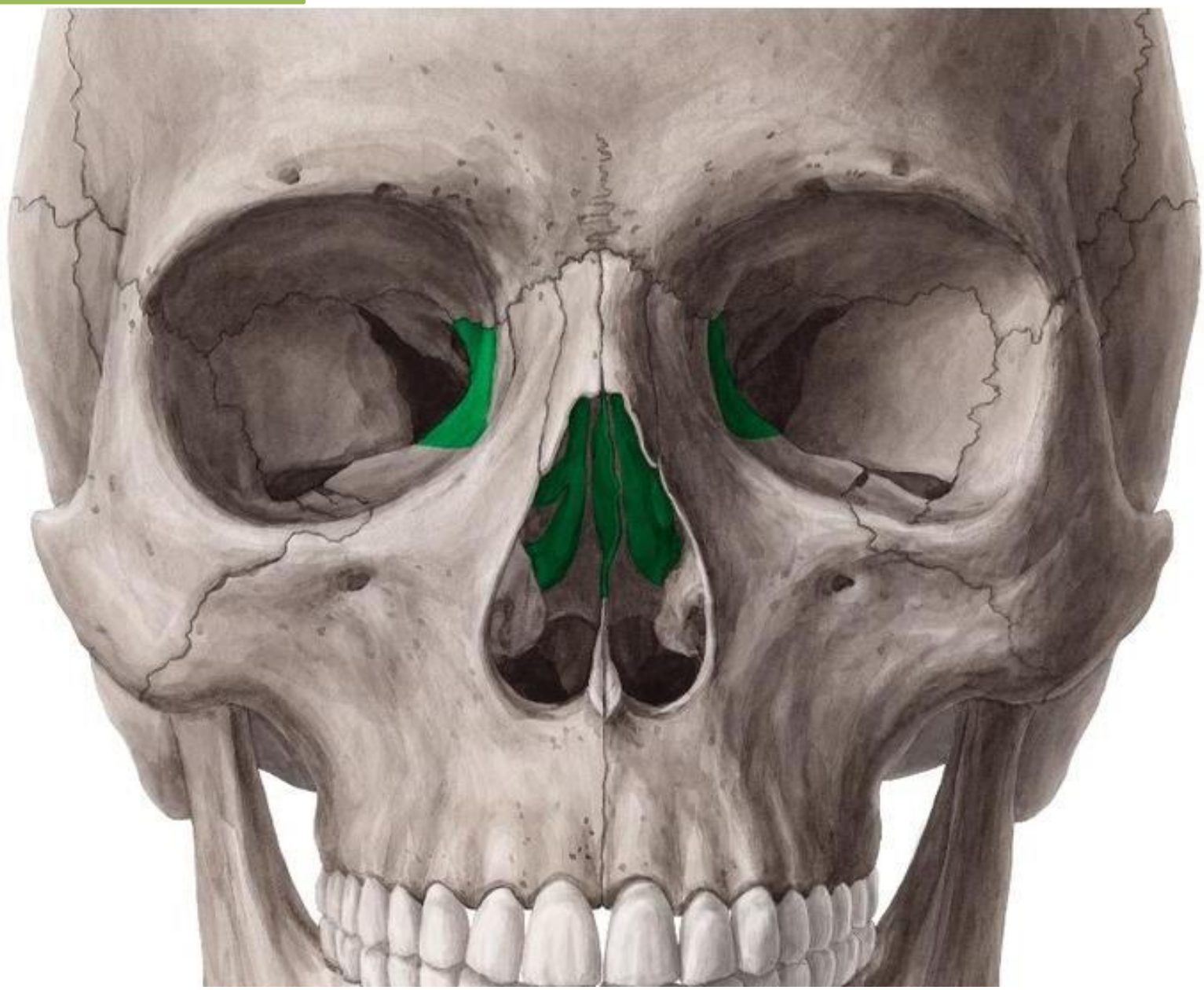

Dr. Heba Kalbouneh

KEN HUB

This bone forms parts of the medial wall of the orbit + the lateral nasal bons + roof of the nasal cavity

Ethmoid bone

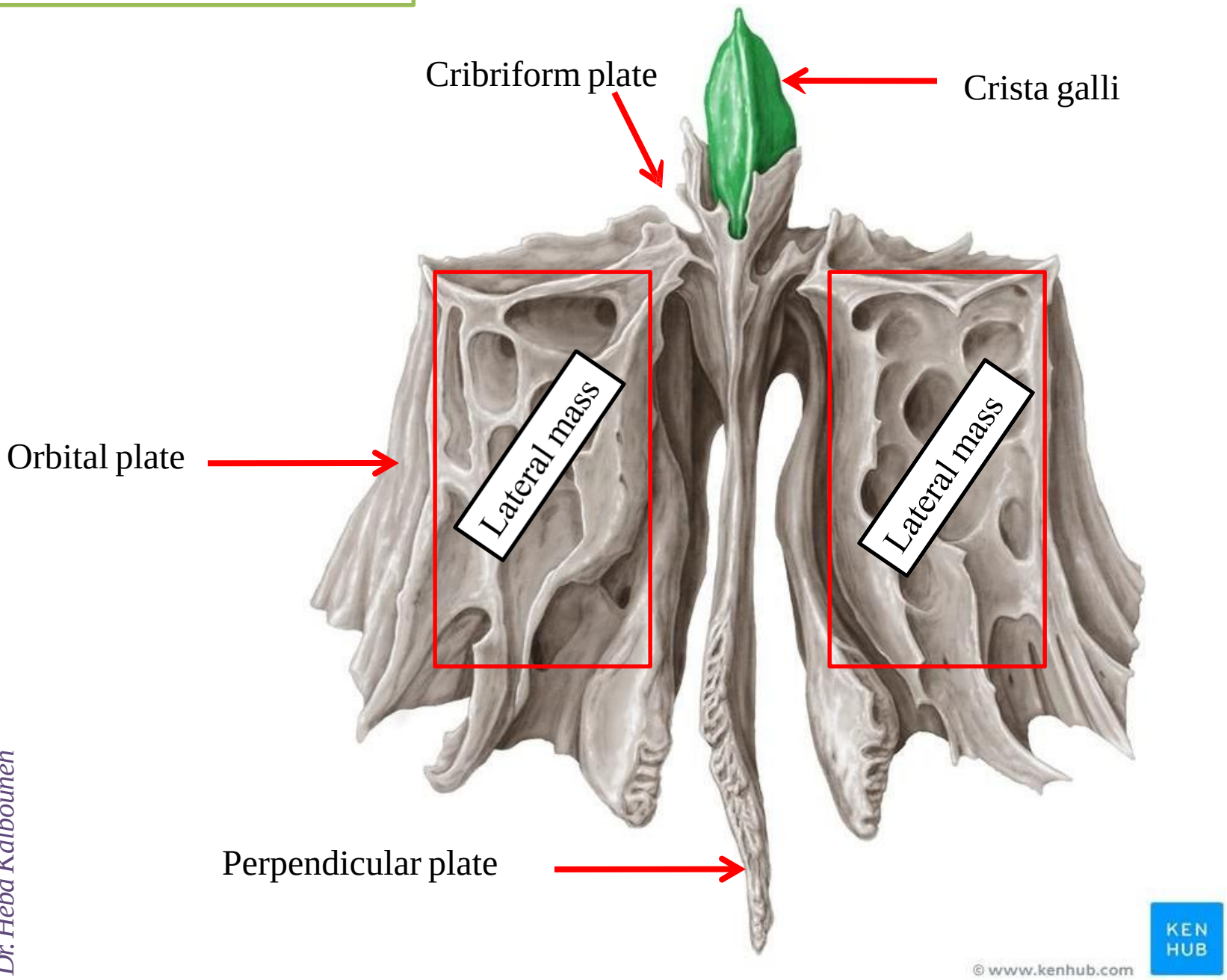

Dr. Heba Kalbouneh

Norma Basalis Externa

Maxilla

Palatine process of maxilla

Dr. Heba Kalbouneh

Palatine bone (horizontal plate)

Dr. Heba Kalbouneh

For respiratory system

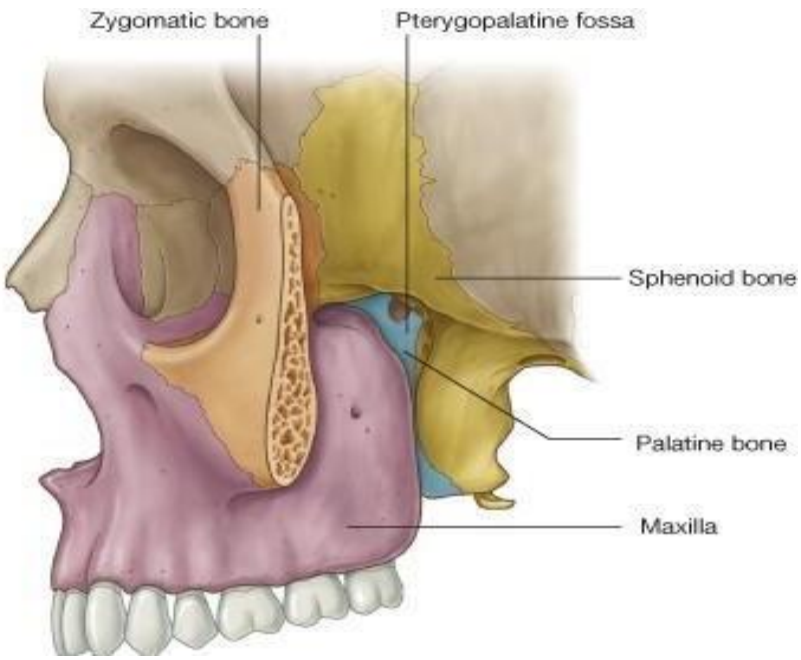

Vertical plate of palatine bone forms the medial wall of pterygopalatine fossa: it locates under the apex of the orbit

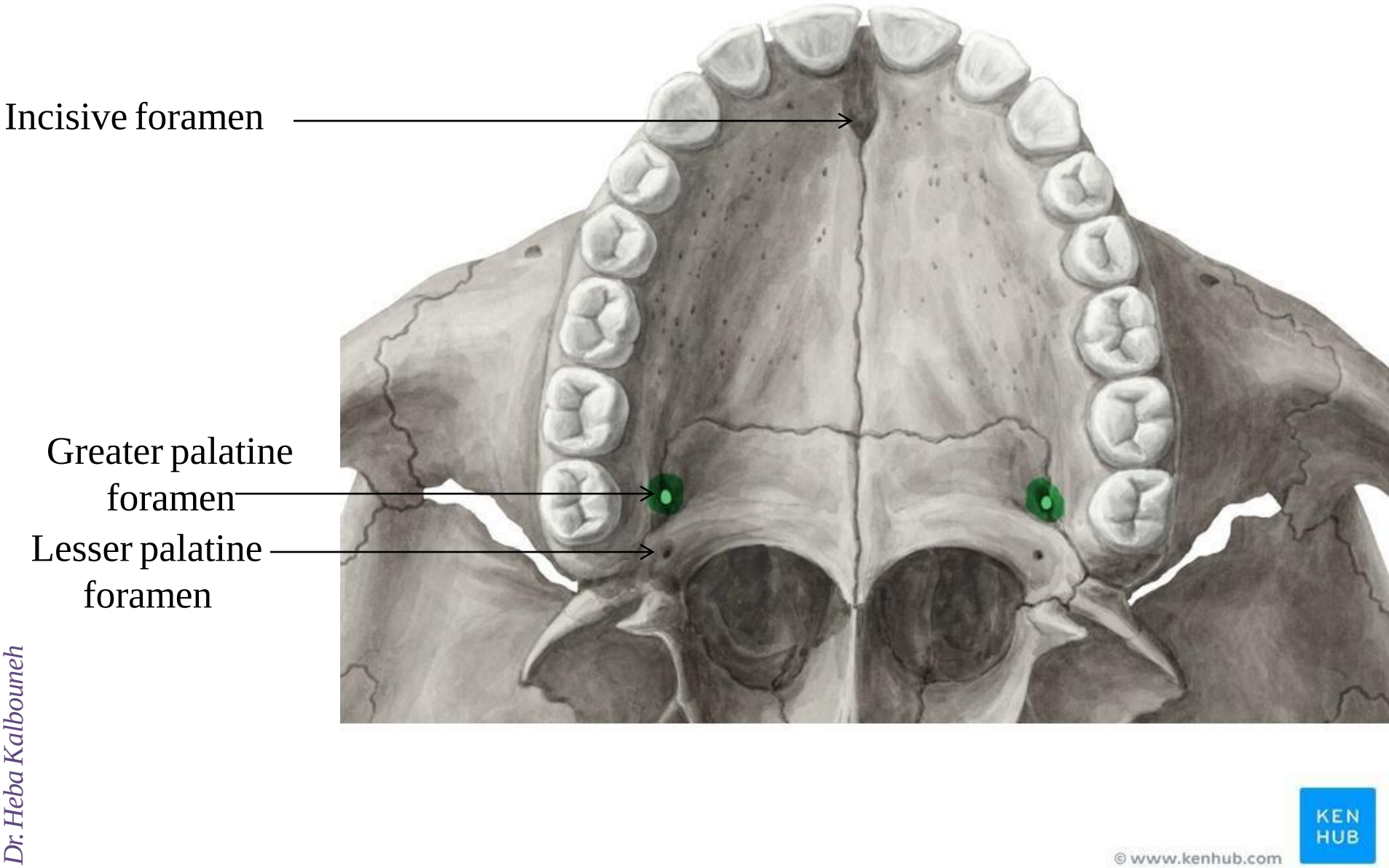

Dr. Heba Kalbouneh

The vomer

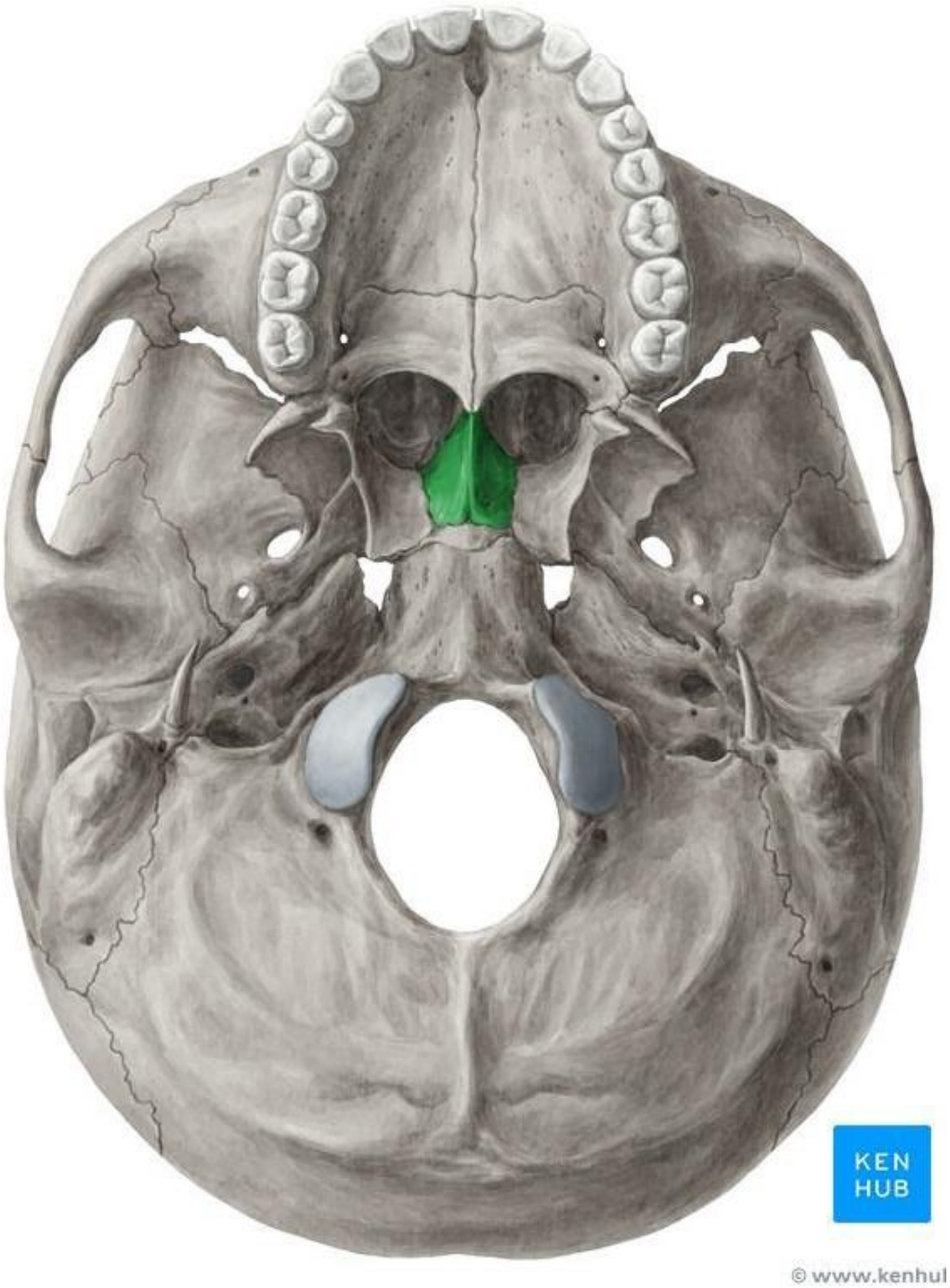

Sphenoid bone
(greater wing and pterygoid plates)

Dr. Heba Kalbouneh

Lateral pterygoid plates of sphenoid

Dr. Heba Kalbouneh

Medial pterygoid plates of sphenoid

Hamulus of Medial pterygoid plate of sphenoid

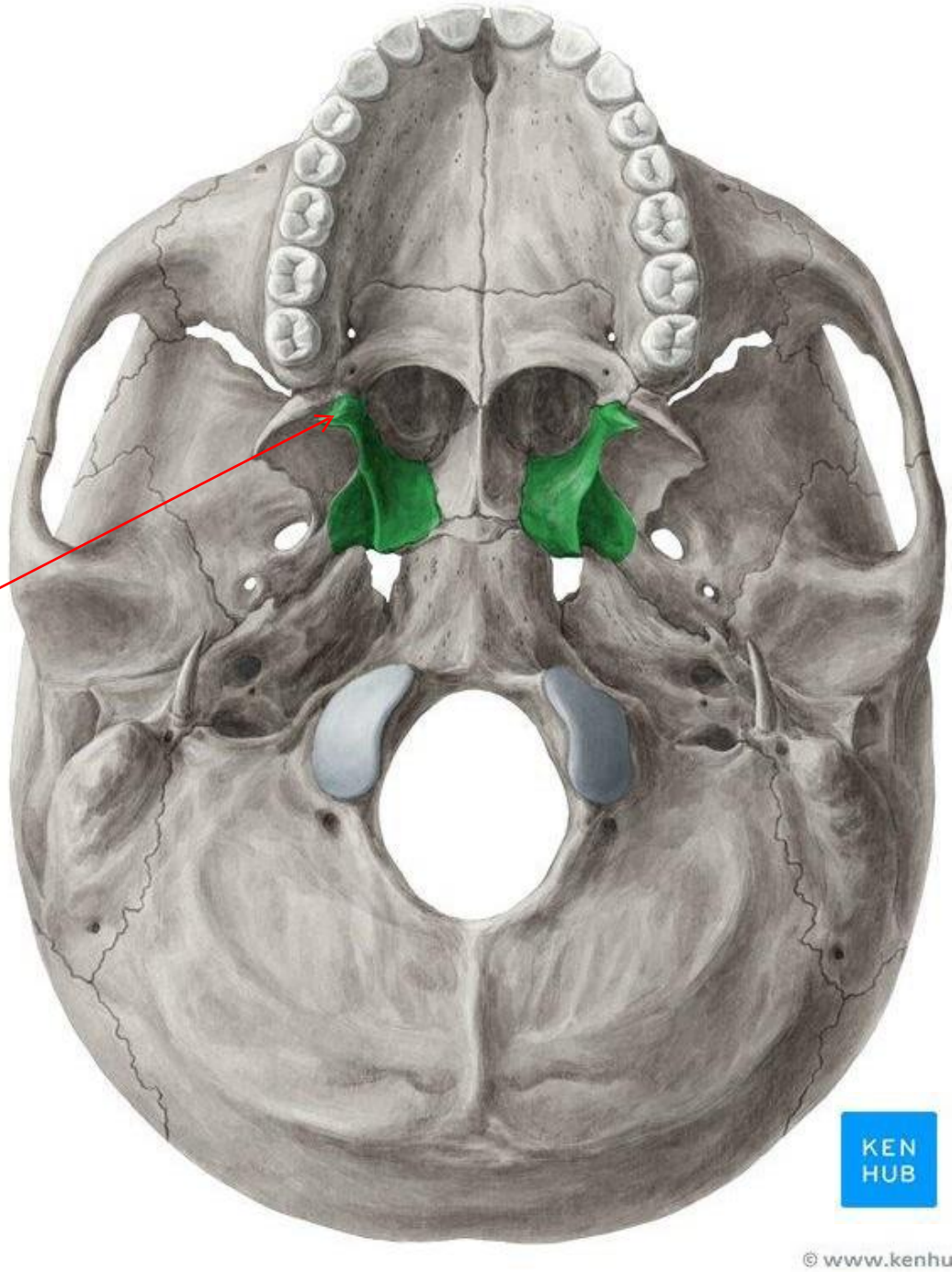

Dr. Heba Kalbouneh

Inferior orbital fissure

It is formed between the greater wing of sphenoid bone and maxilla

Zygomatic arch

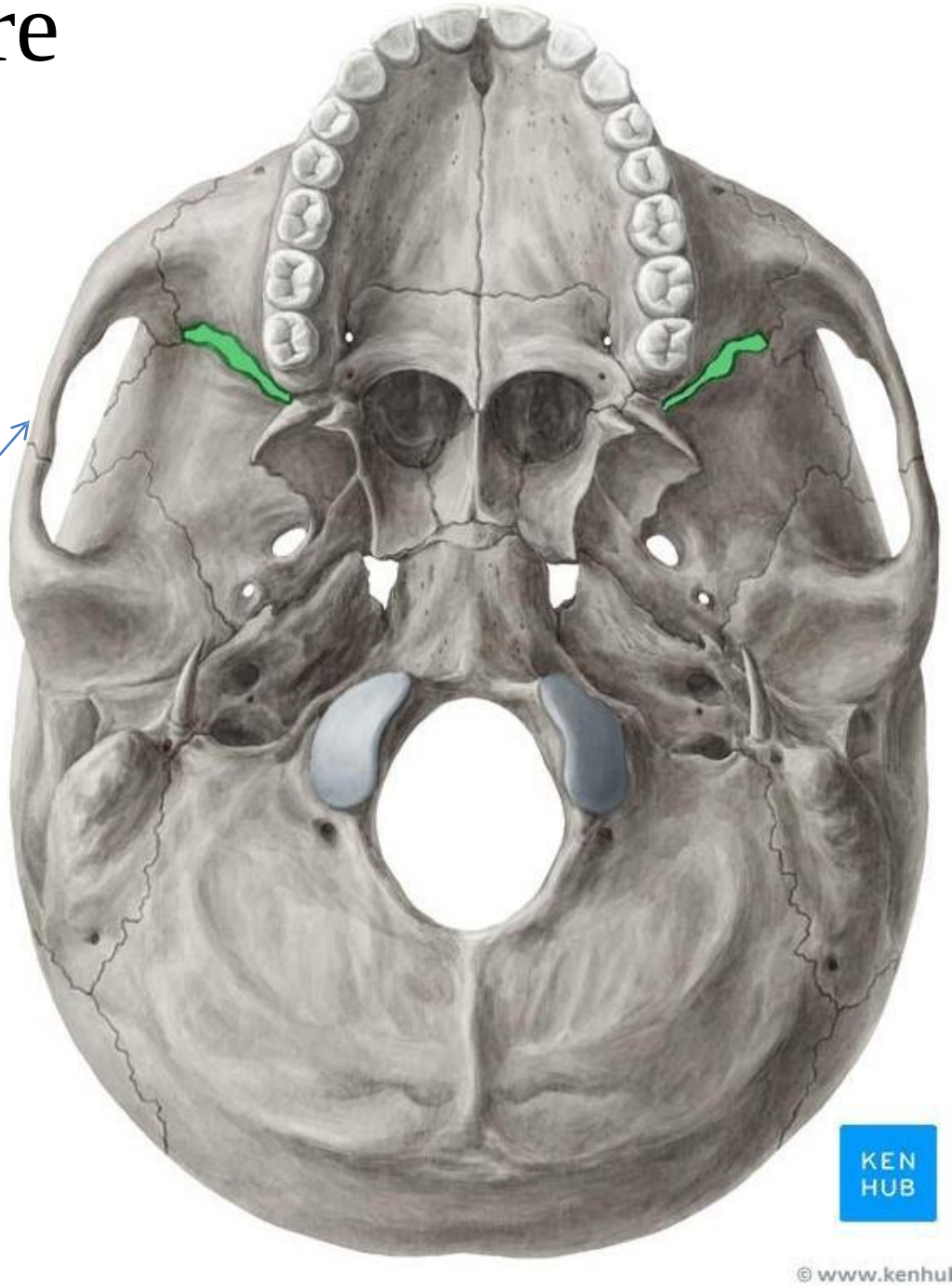

Dr. Heba Kalbouneh

Temporal bone

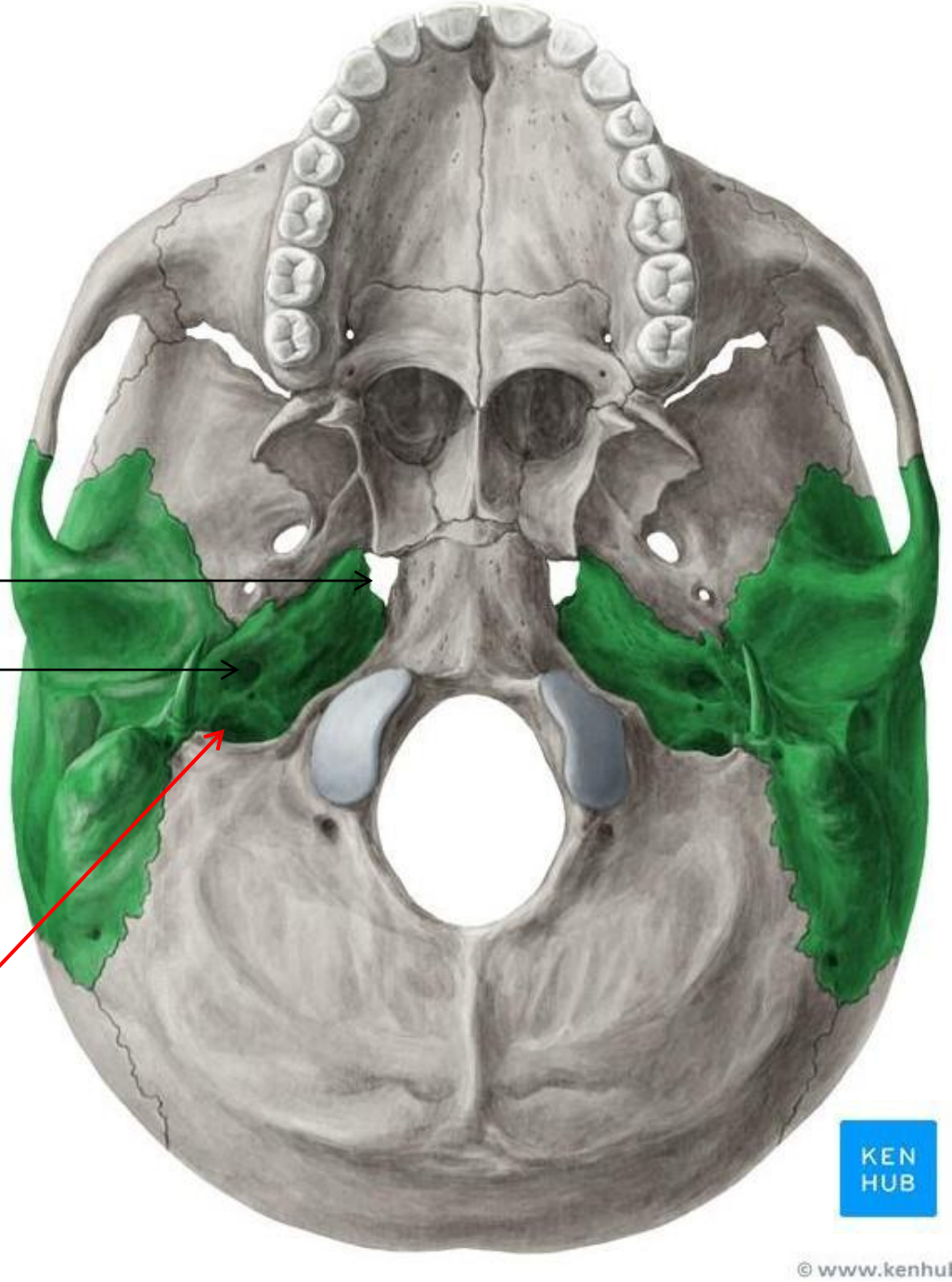

Foramen lacerum

Opening of the carotid canal

Jugular foramen
Is located behind the carotid canal

Dr. Heba Kalbouneh

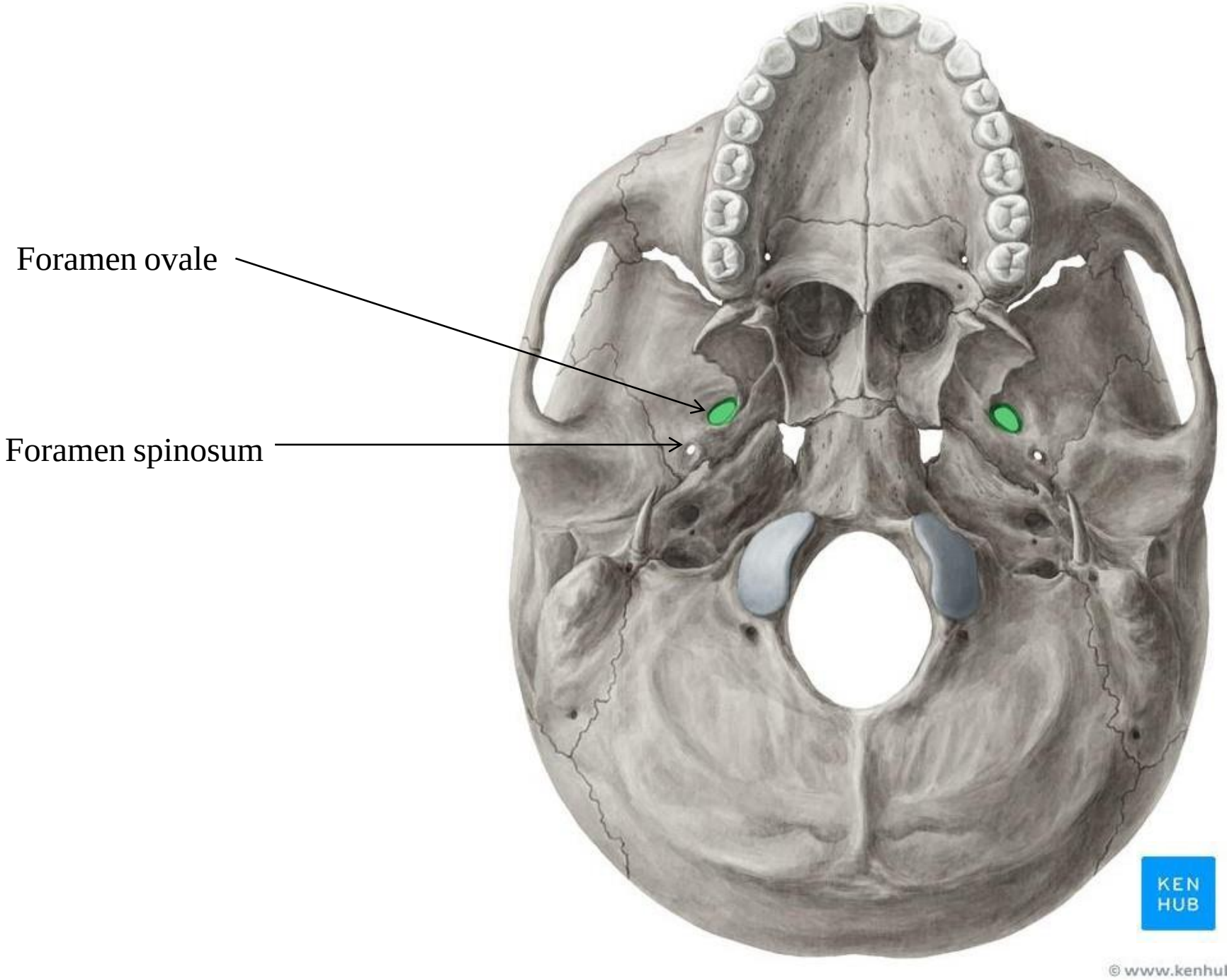

We can not see foramen rotundum in this view

Dr. Heba Kalbouneh

Choanae (posterior nasal aperture)

The mandibular fossa of the temporal bone and the articular tubercle form the upper articular surfaces for the temporomandibular joint.

External auditory meatus

Anterior nasal aperture

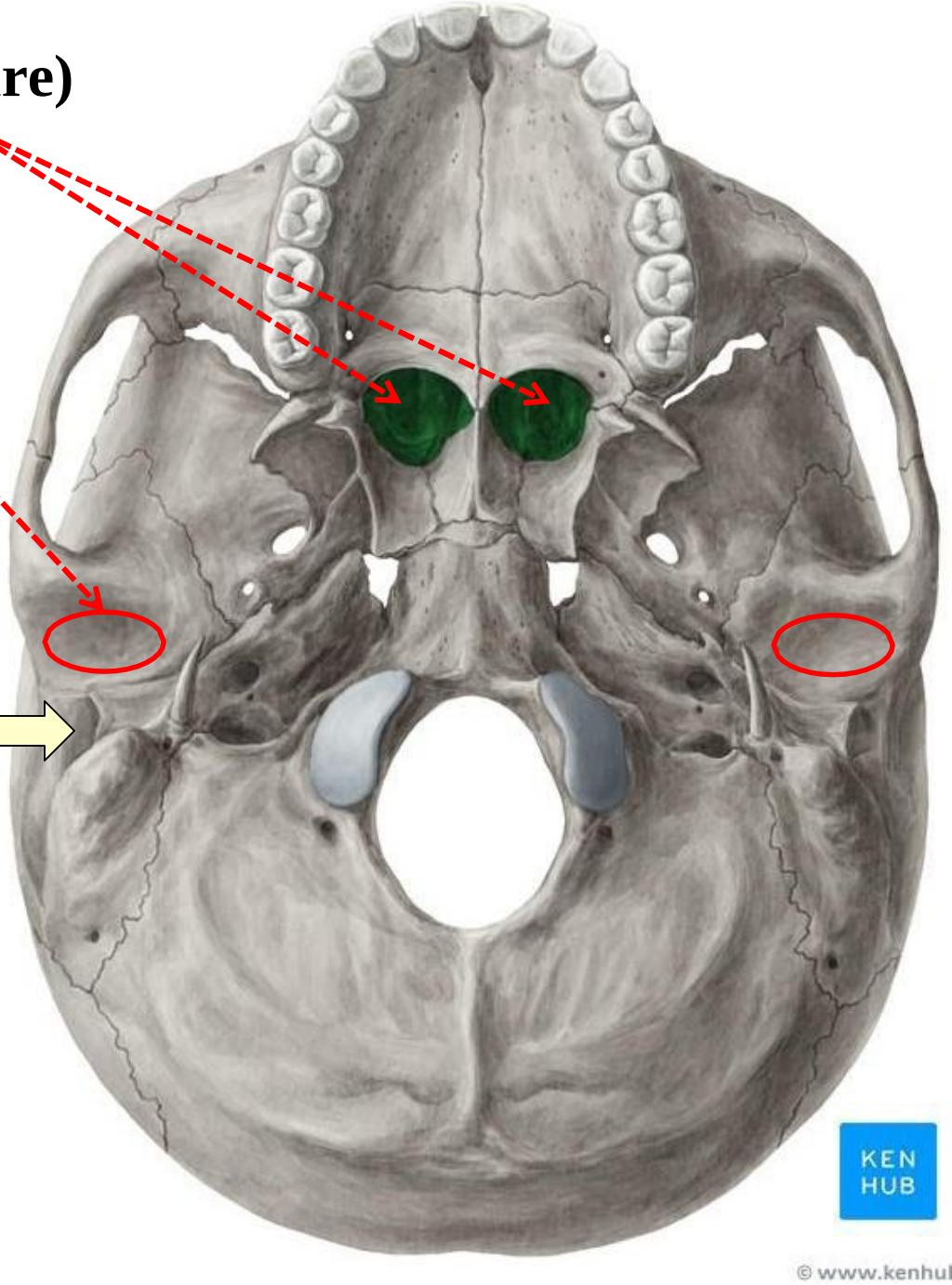

Dr. Heba Kalbouneh

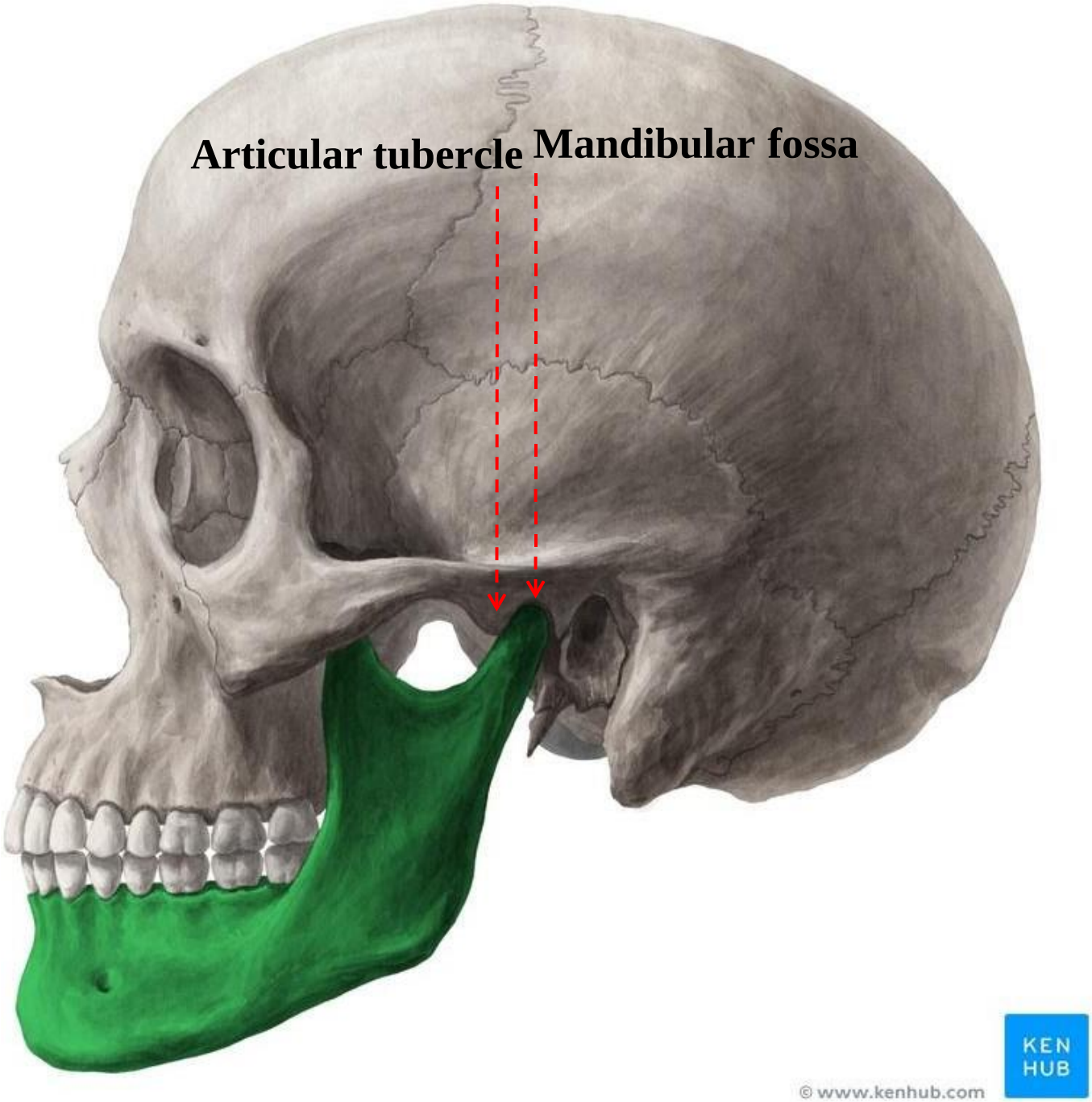

Dr. Heba Kalbouneh

Occipital bone

Foramen magnum

Dr. Heba Kalbouneh

Chondyles of occipital bone (articulate with C1 vertebra)

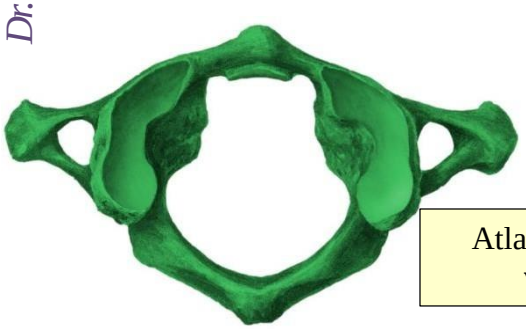

Atlas (**1st cervical vertebra)**

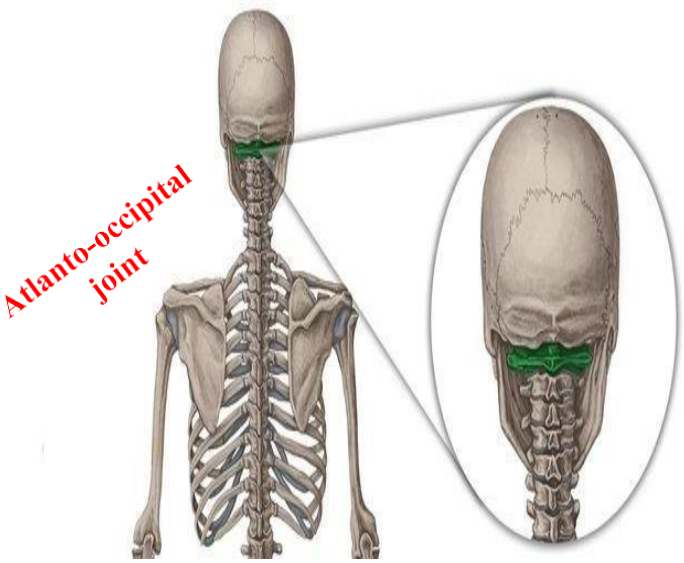

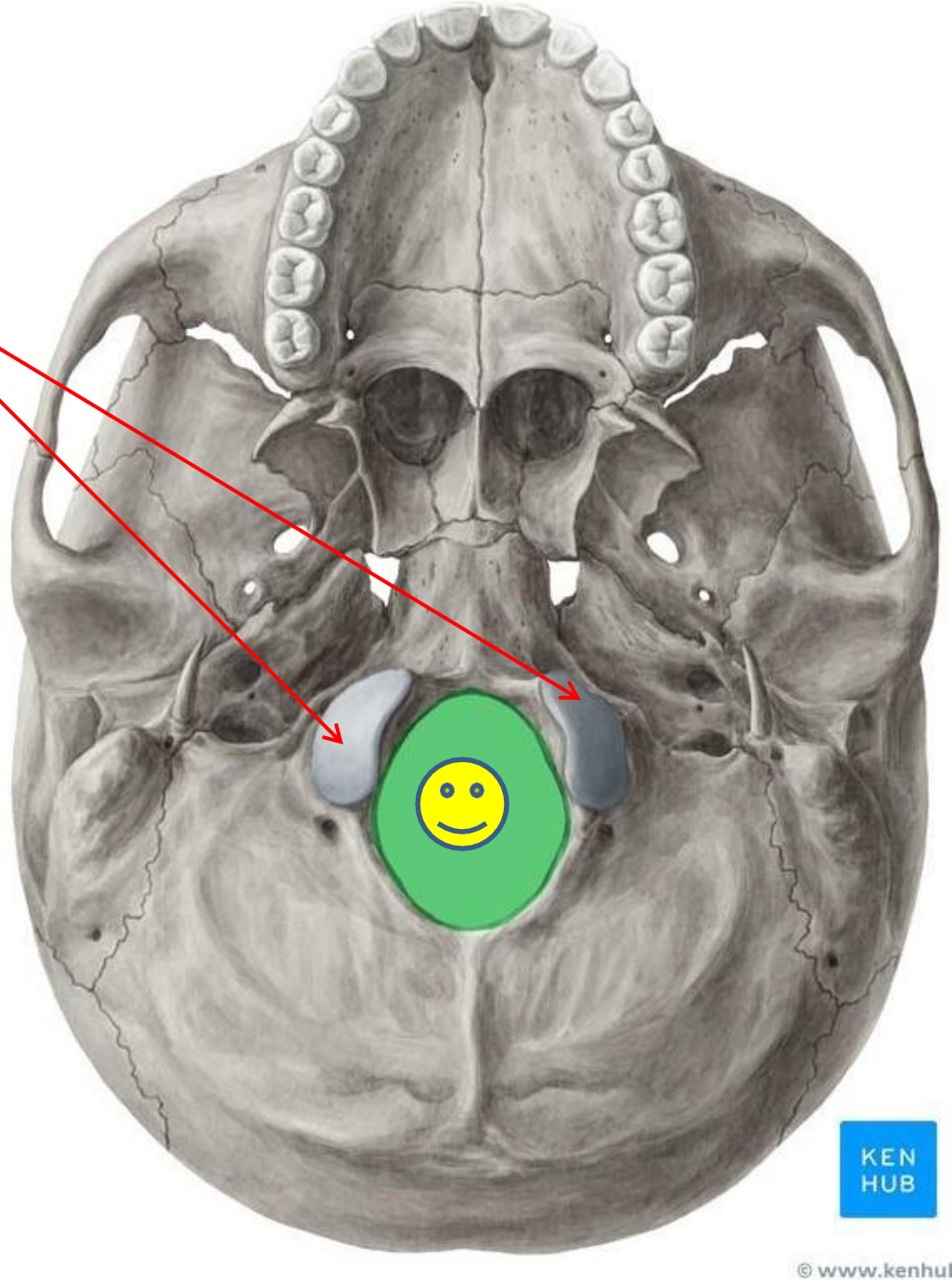

Parts of occipital bone:

1: Basilar part (in front the foramen magnum)
2: Occipital chondyles (sides of foramen magnum)
3: Squamous part (behind the foramen magnum)

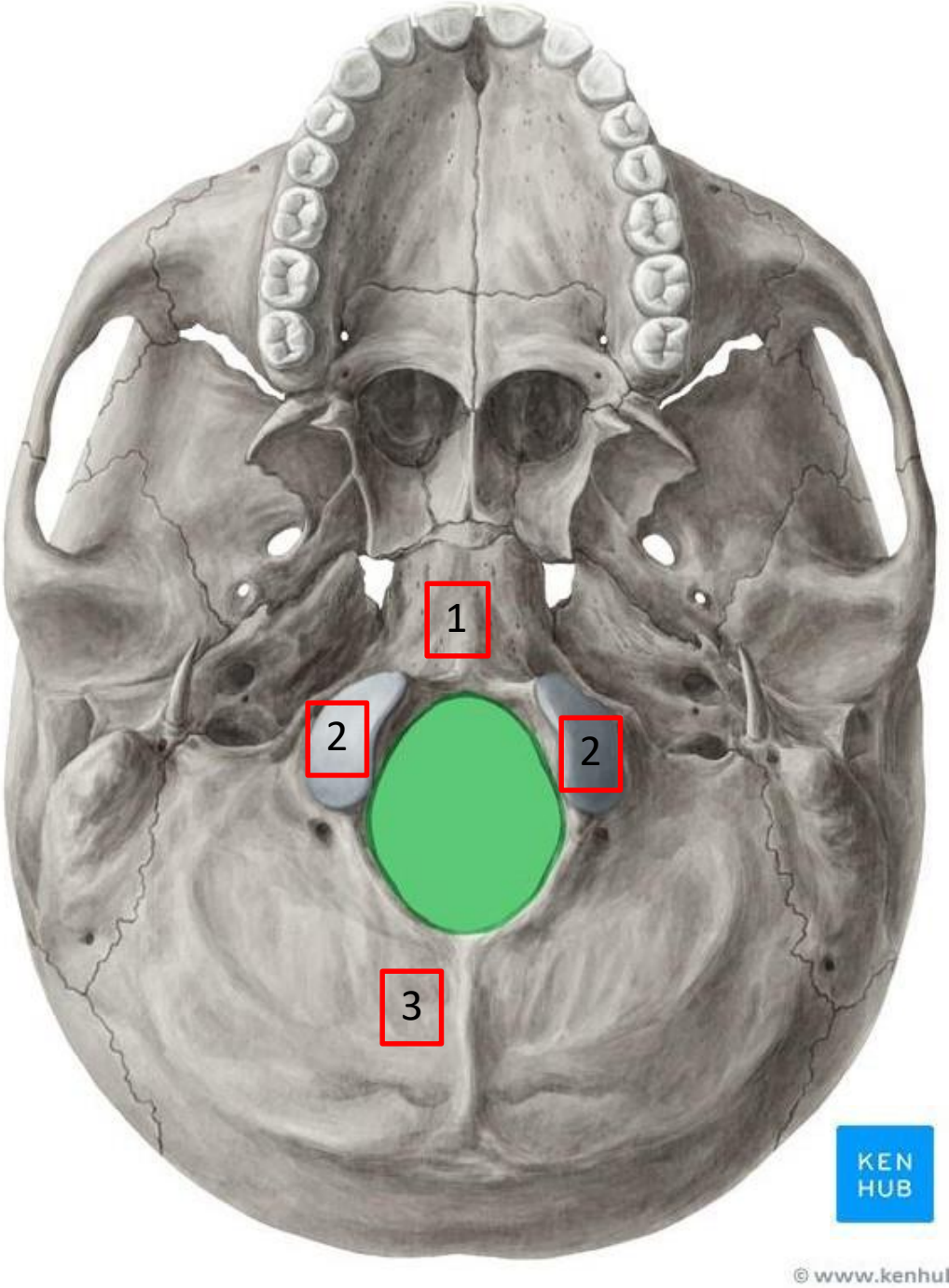

Dr. Heba Kalbouneh

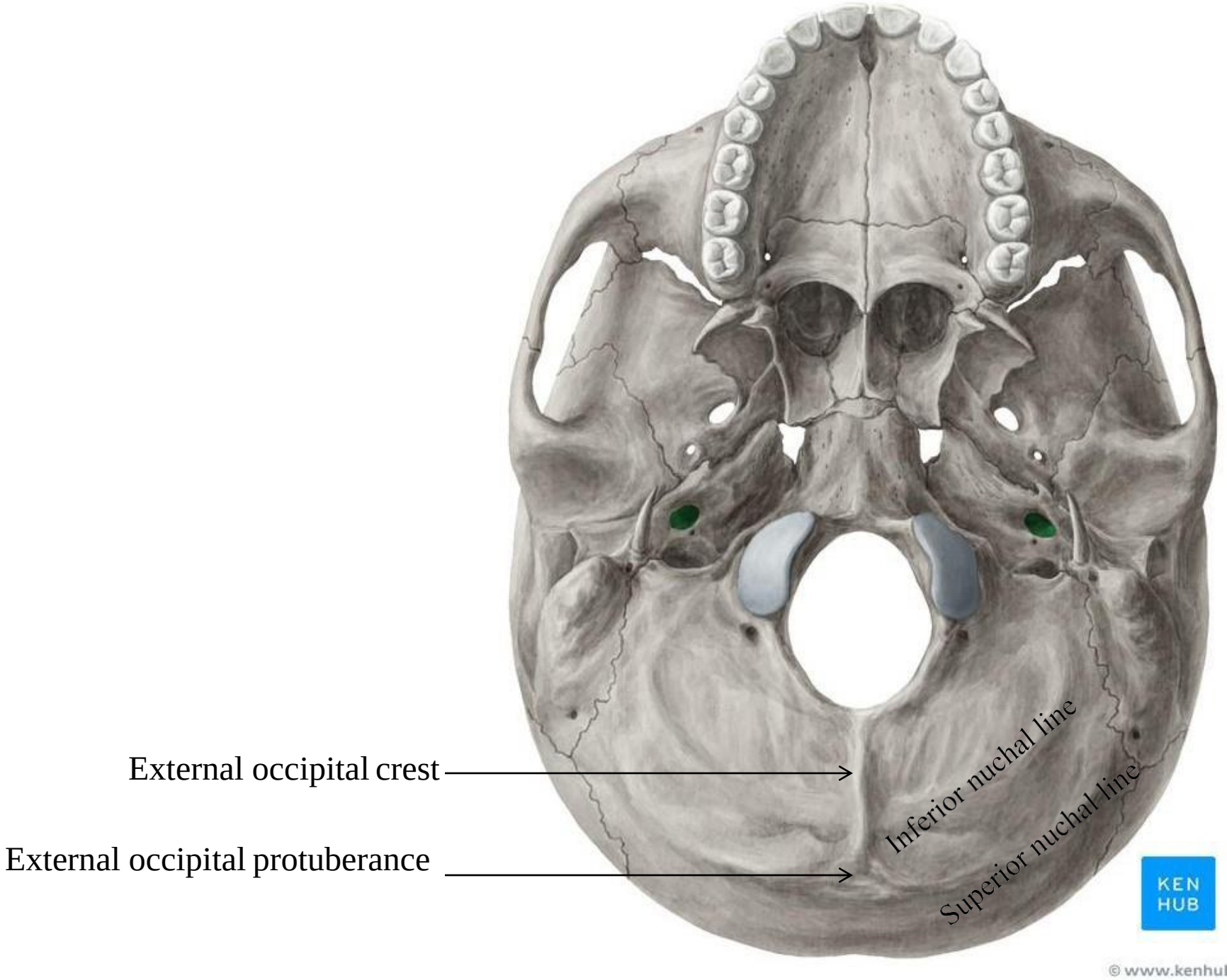

Dr. Heba Kalbouneh

Jugular foramen

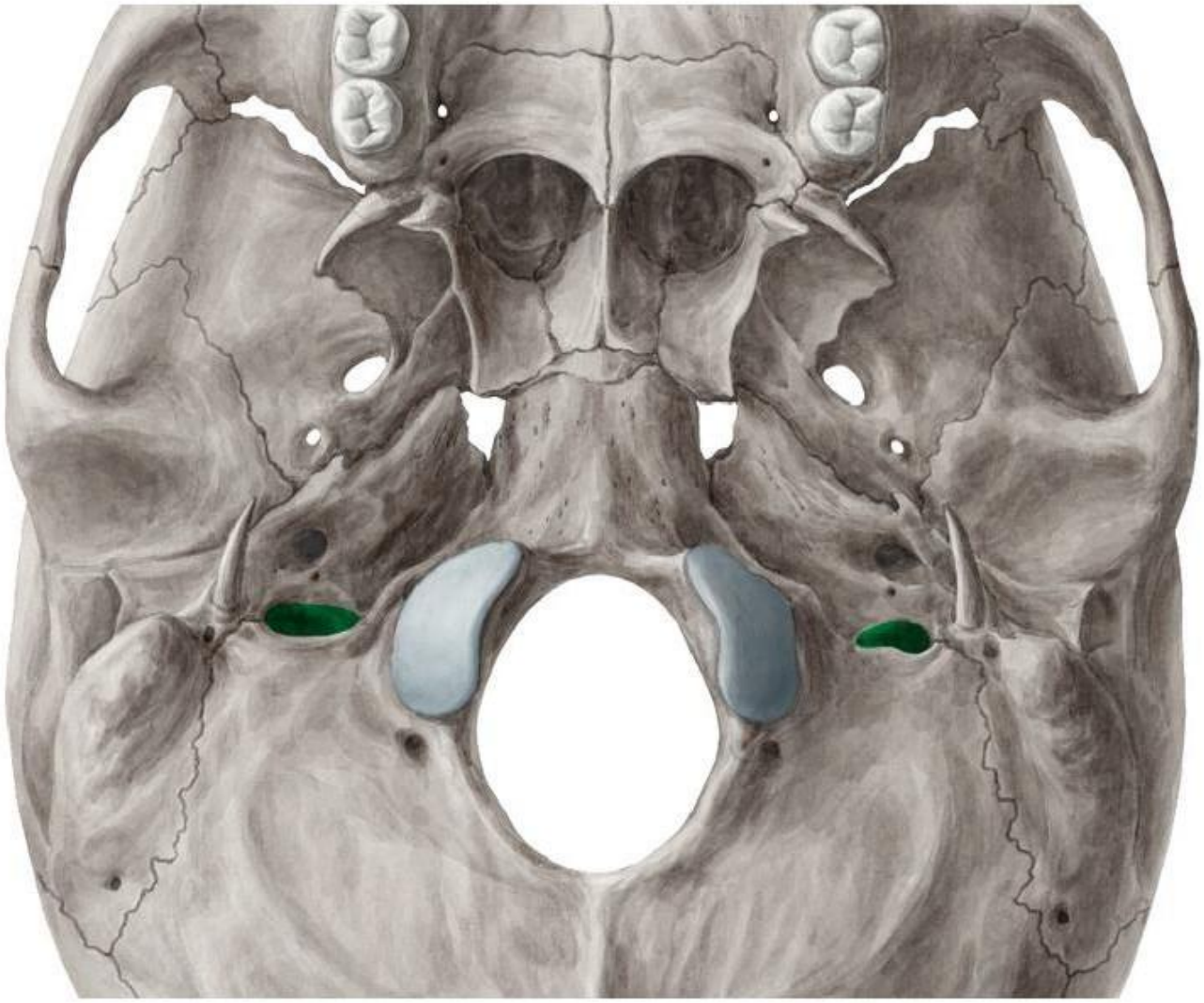

It always posterior to the carotid canal

© www.kenhub.com

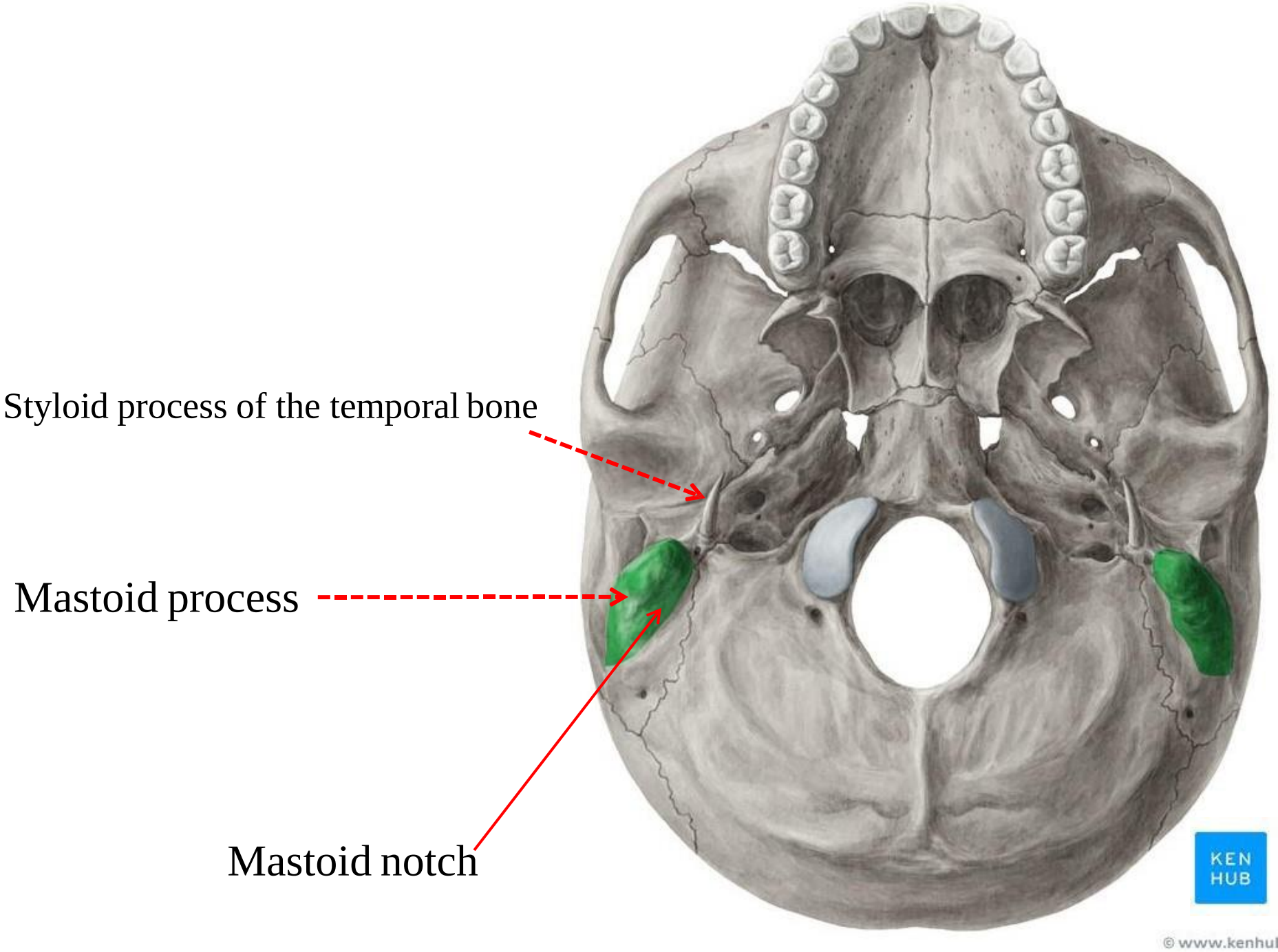

Dr. Heba Kalbouneh

The **stylomastoid foramen**

In the interval between the styloid and mastoid processes

Transmits the facial nerve

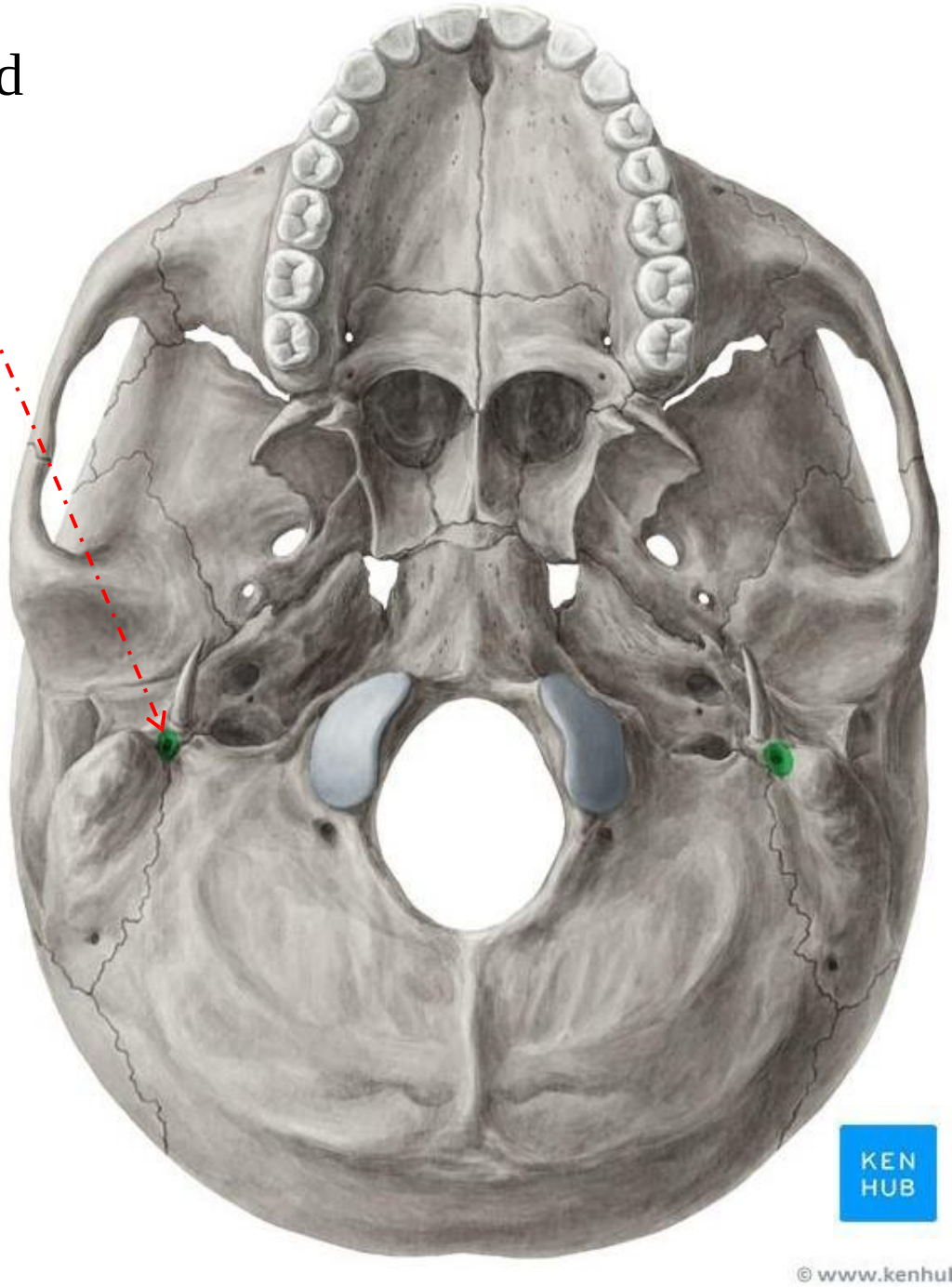

Dr. Heba Kalbouneh

Infra temporal fossa

Boundaries

Anterior wall: back of the maxilla
Medial wall: lateral pterygoid plate
Roof: greater wing of sphenoid bone
Lateral wall: ramus of mandible

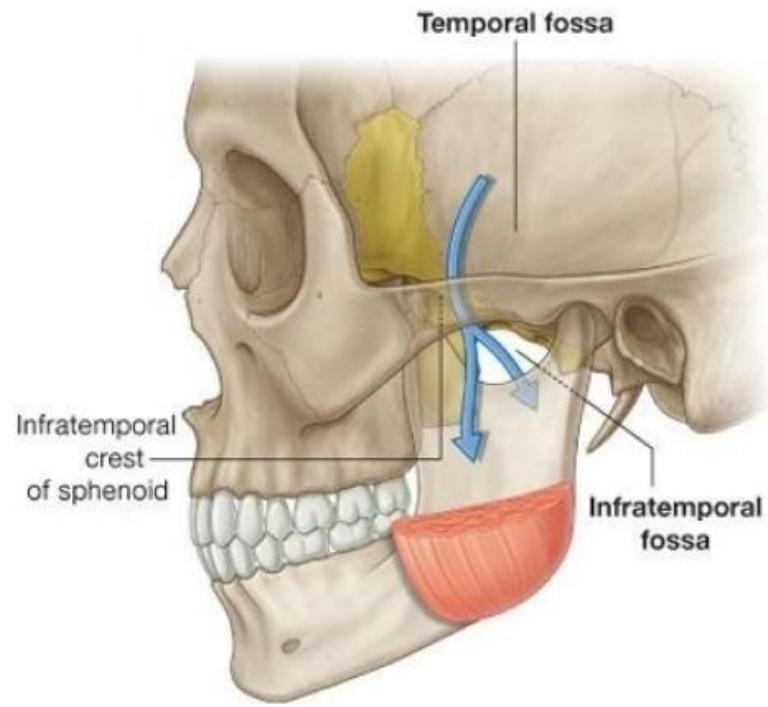

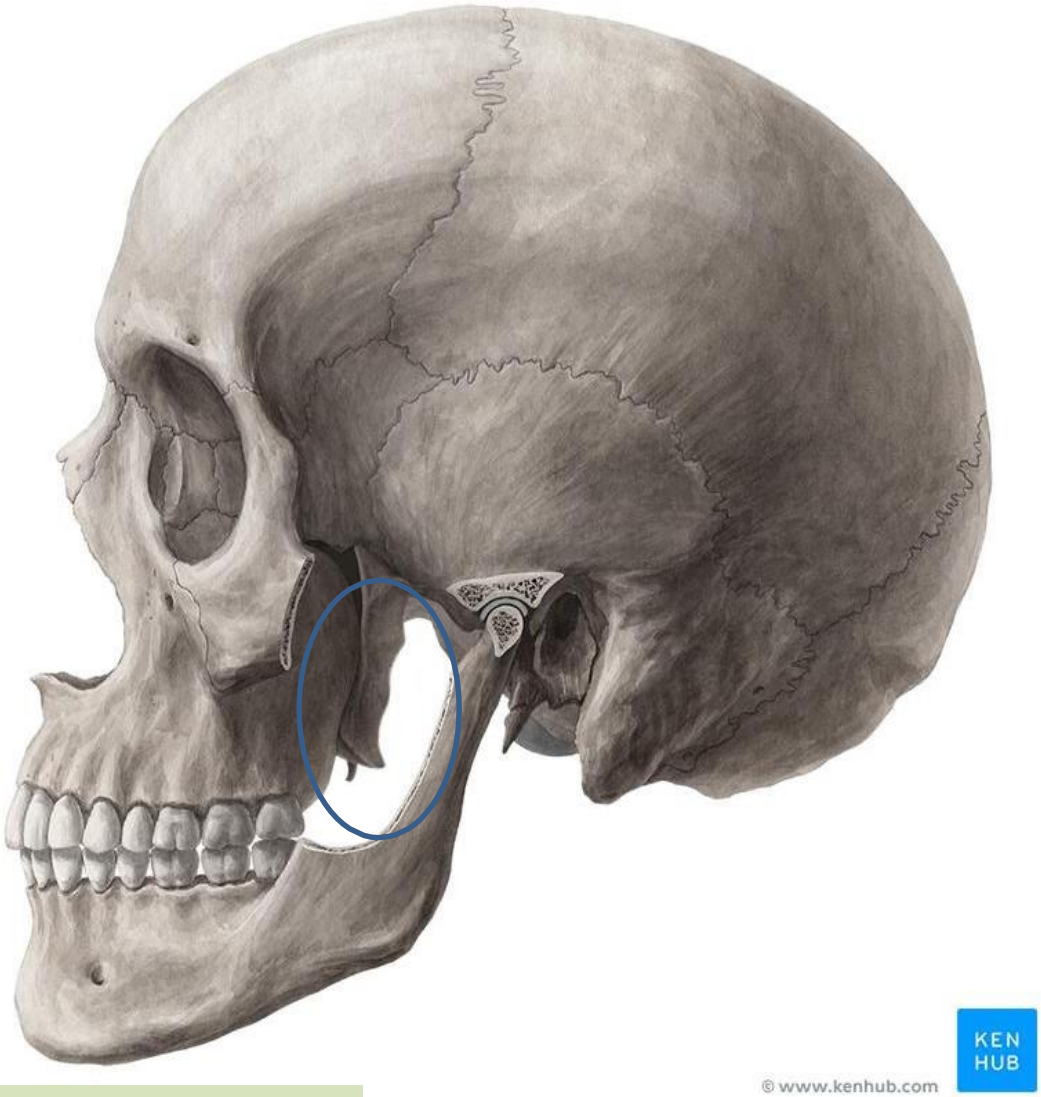

Communications

Temporal fossa: through the gap deep to the zygomatic arch
Orbit: through the inferior orbital fissure
Pterygo-palatine fossa: through the pterygo-maxillary fissure
Middle cranial fossa: through foramen ovale and spinosum

Dr. Heba Kalbouneh

Temporal and infratemporal fossae are interconnected spaces on the lateral side of the head

Temporal fossa is superior to the infratemporal fossa above the zygomatic arch

Pterygo-palatine fossa

Lies below the apex of the orbit

Dr. Heba Kalbouneh

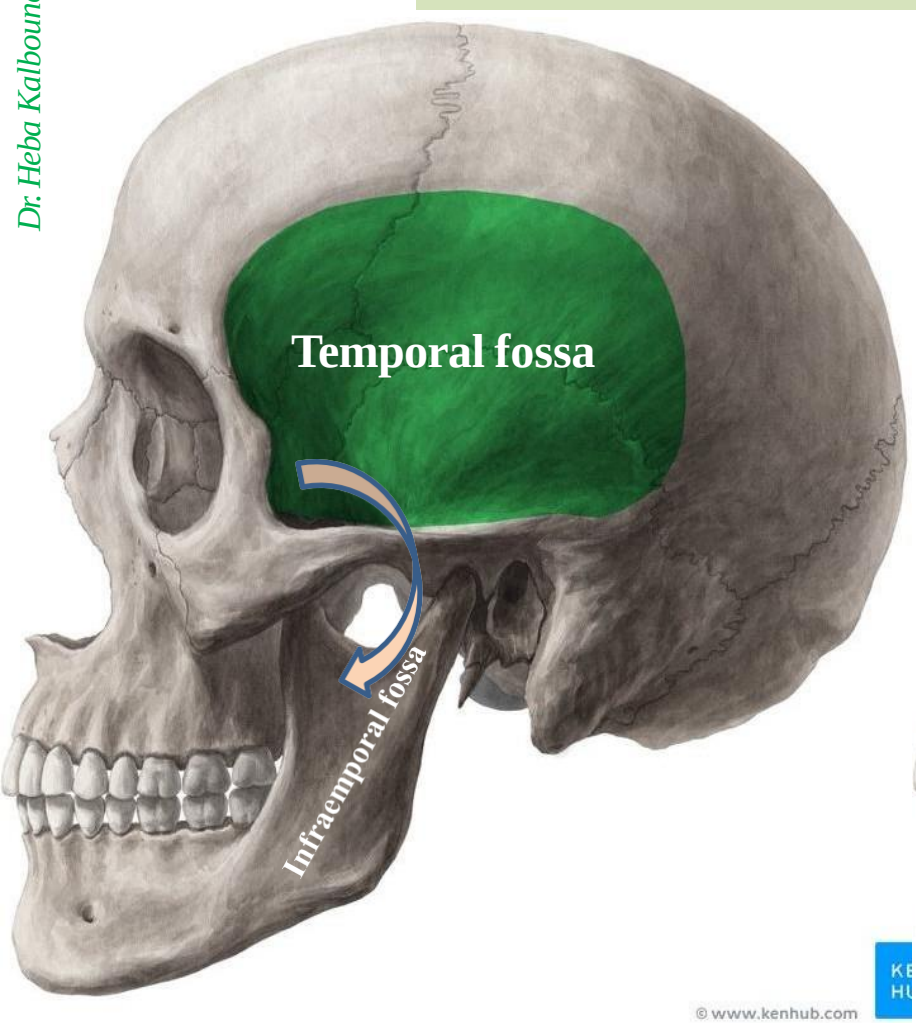

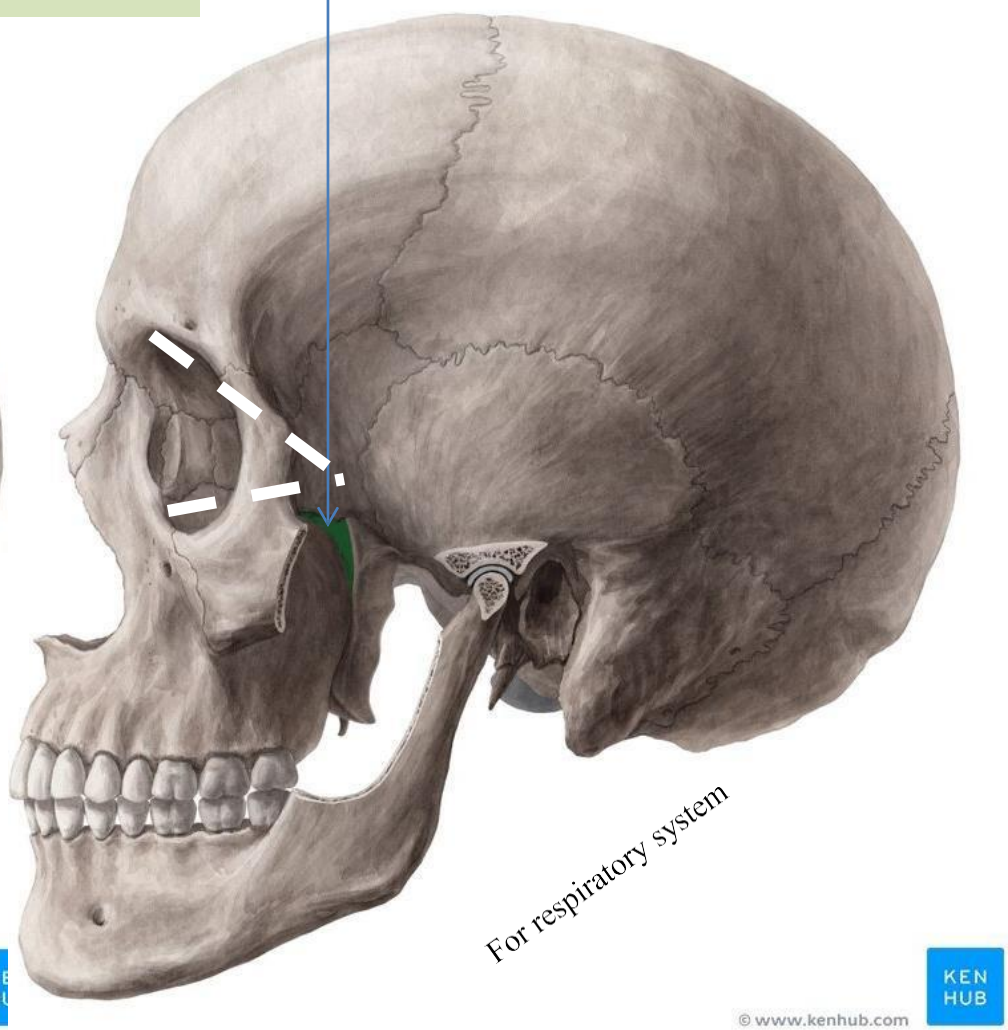

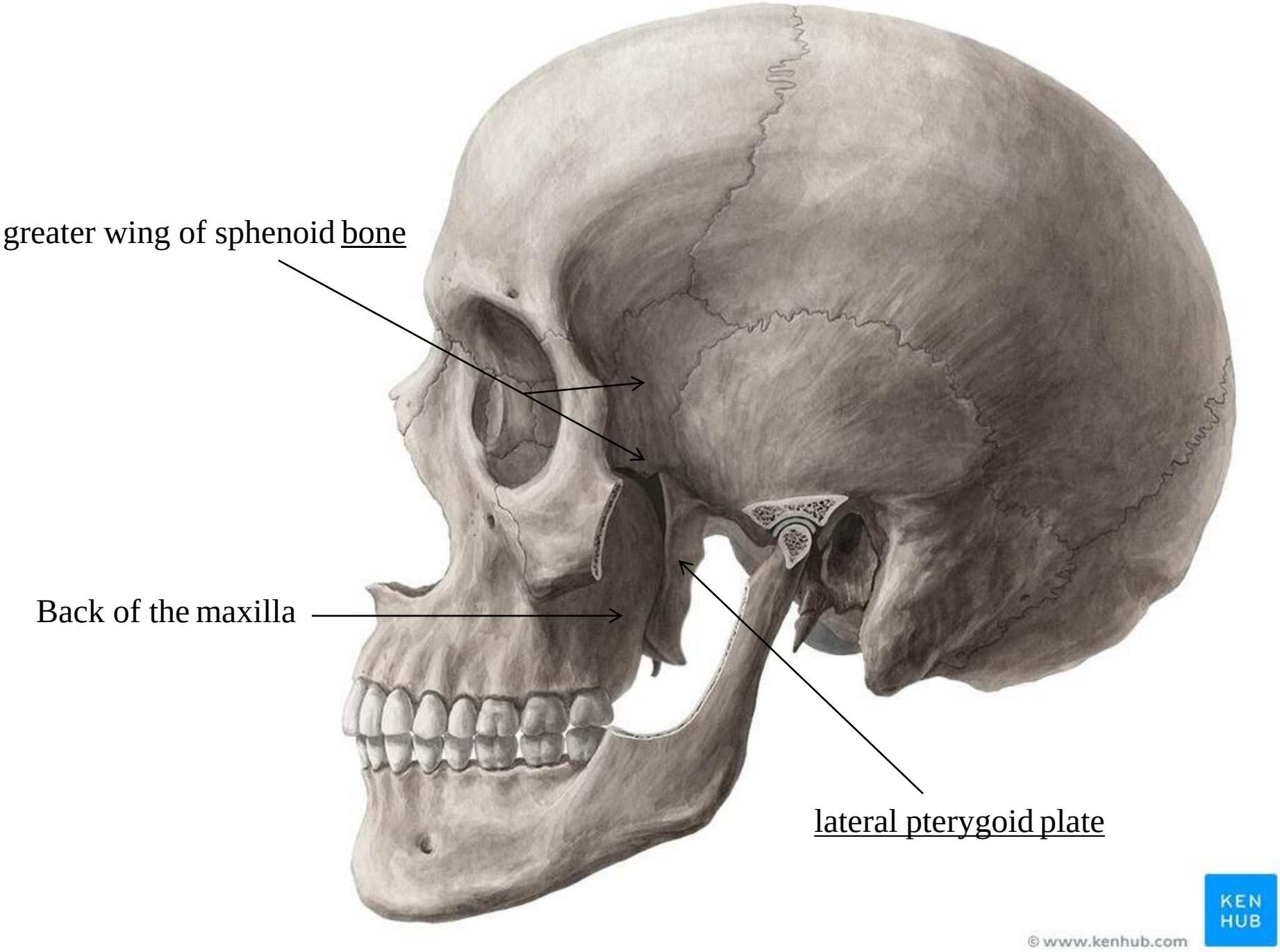

Dr. Heba Kalbouneh

The roof of Infratemporal fossa
Inferior view of the skull

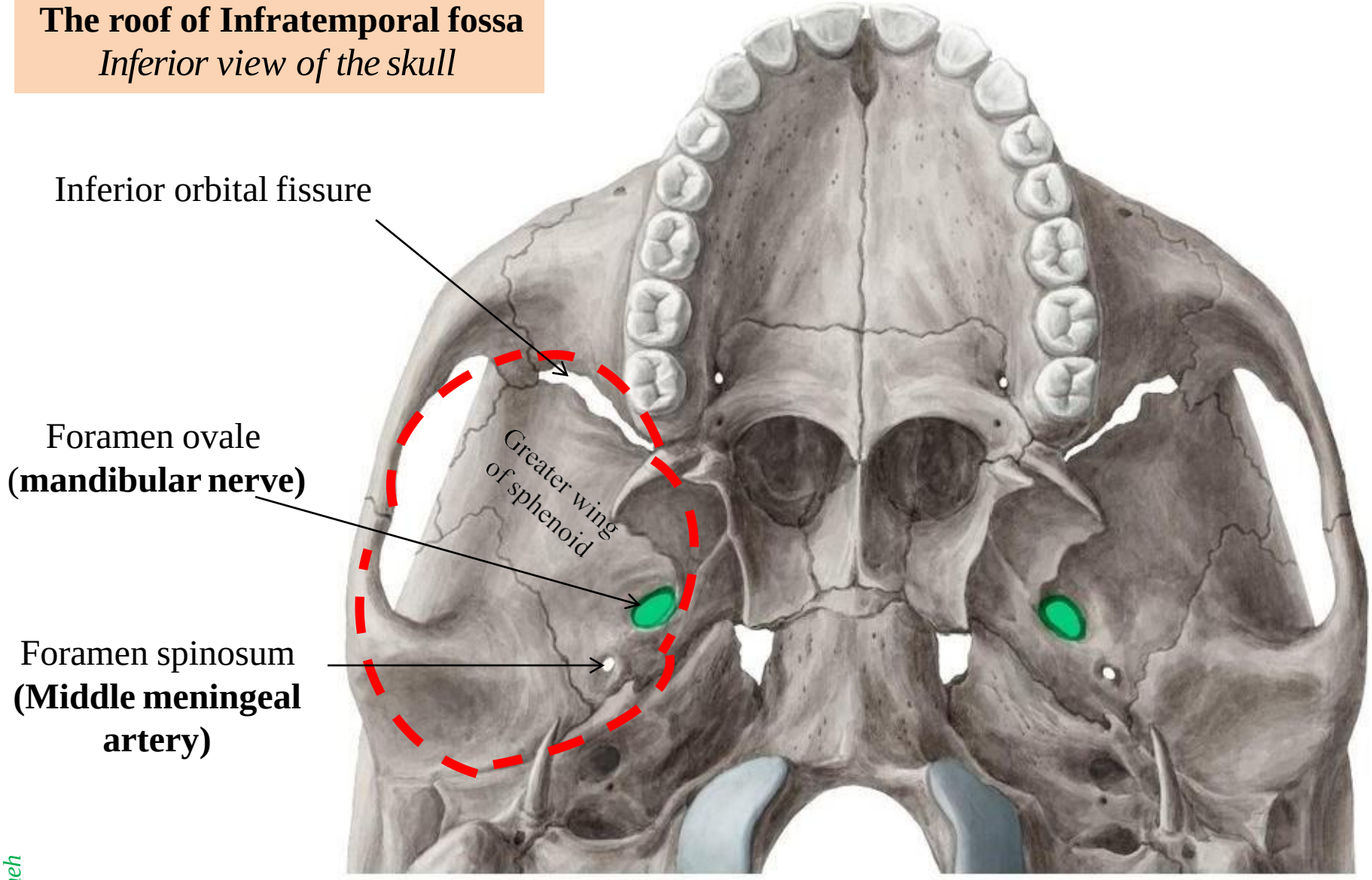

Note:
The foramen ovale and foramen spinosum open on its roof

© www.kenhub.com
KEN HUB

Dr. Heba Kalbouneh

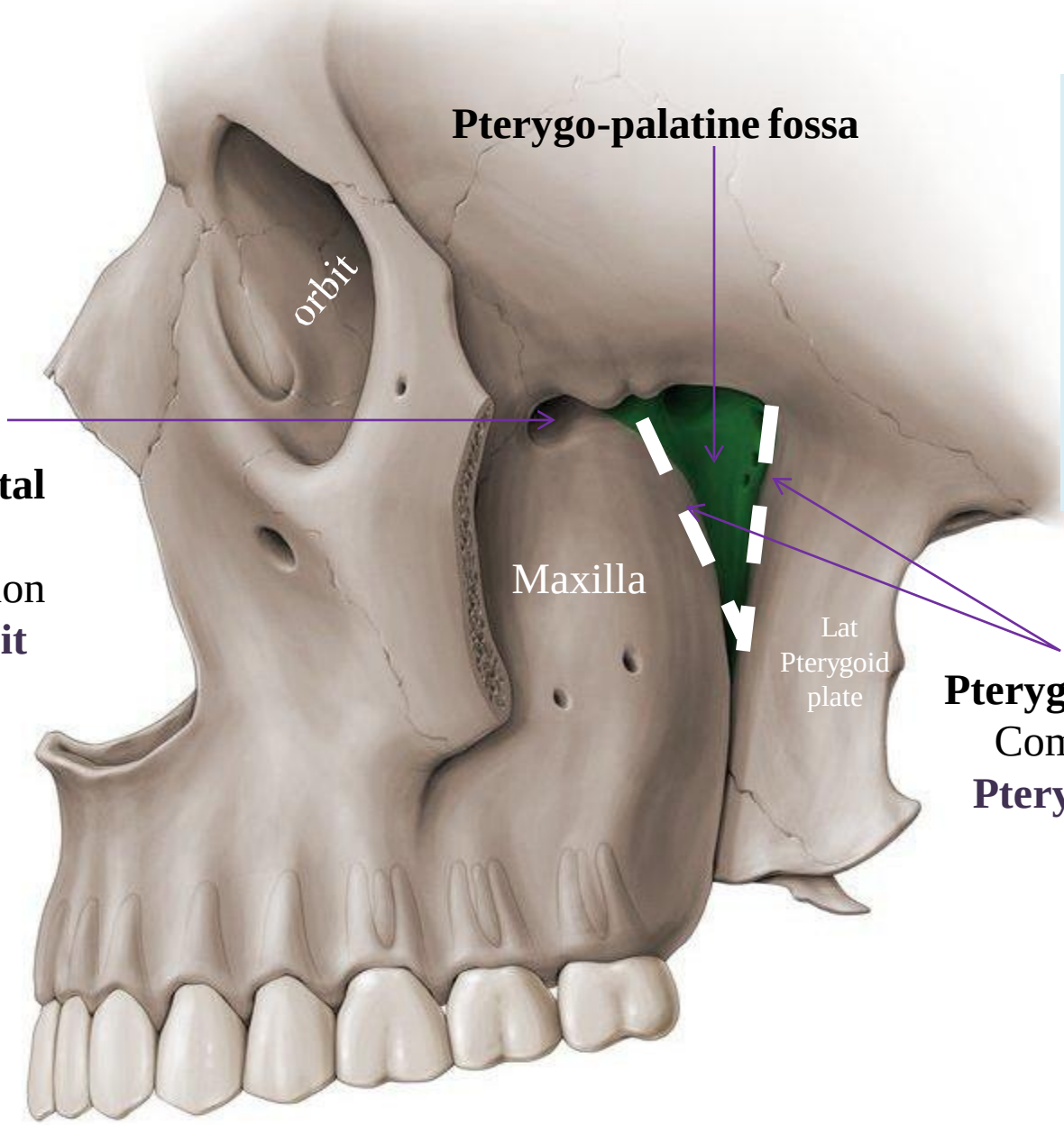

Pterygomaxillary fissure is a vertical fissure between the pterygoid plate and back of the maxilla. It leads medially into the pterygopalatine fossa

Inferior orbital fissure
Communication with the **orbit**

Pterygo-maxillary fissure
Communication with **Pterygo-palatine fossa**

The medial and anterior walls of Infratemporal fossa

© www.kenhub.com
KEN HUB

Dr. Heba Kalbouneh

Norma basalis externa

Base of the skull- inferior view

The **hard palate** which is made of:

A-The palatal processes of the maxillae

B-The horizontal plates of the palatine bones

The choanae (posterior nasal apertures)

The vomer

Medial and lateral pterygoid plates of the sphenoid bone

Occipital chondyles

External occipital crest

External occipital protuberance

Superior nuchal line

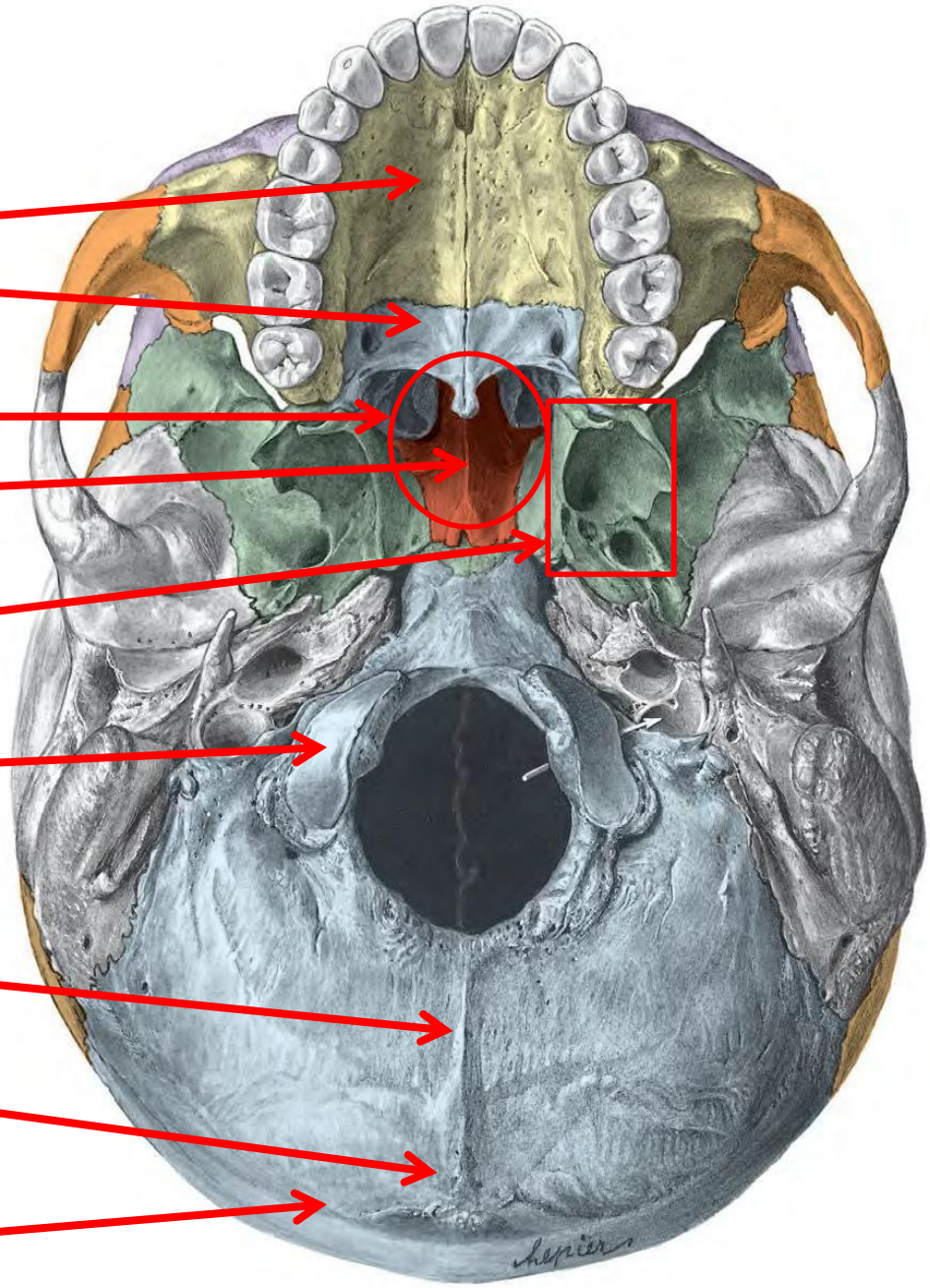

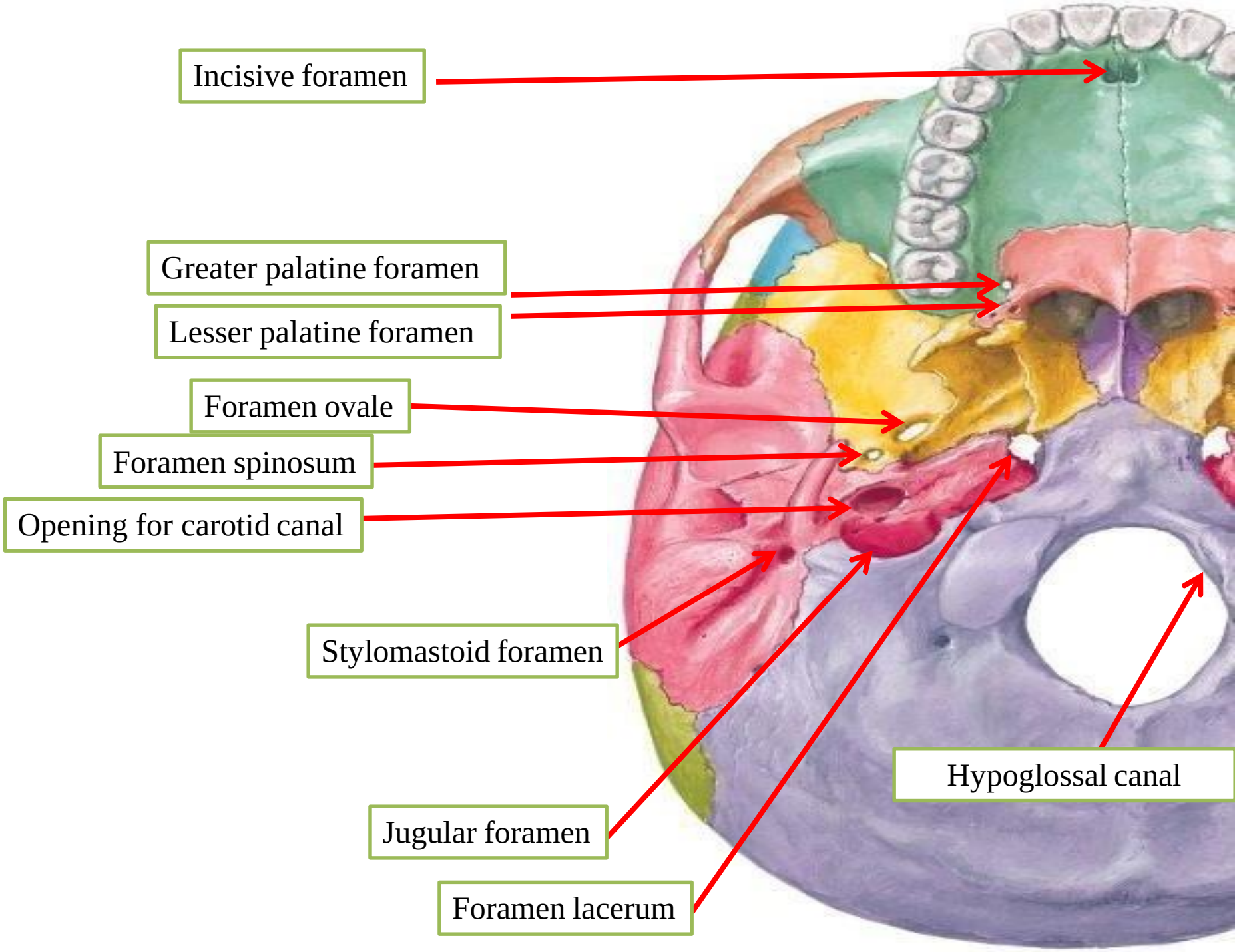
Incisive foramen
Greater palatine foramen
Lesser palatine foramen
Foramen ovale
Foramen spinosum
Opening for carotid canal
Stylomastoid foramen
Hypoglossal canal
Jugular foramen
Foramen lacerum