1

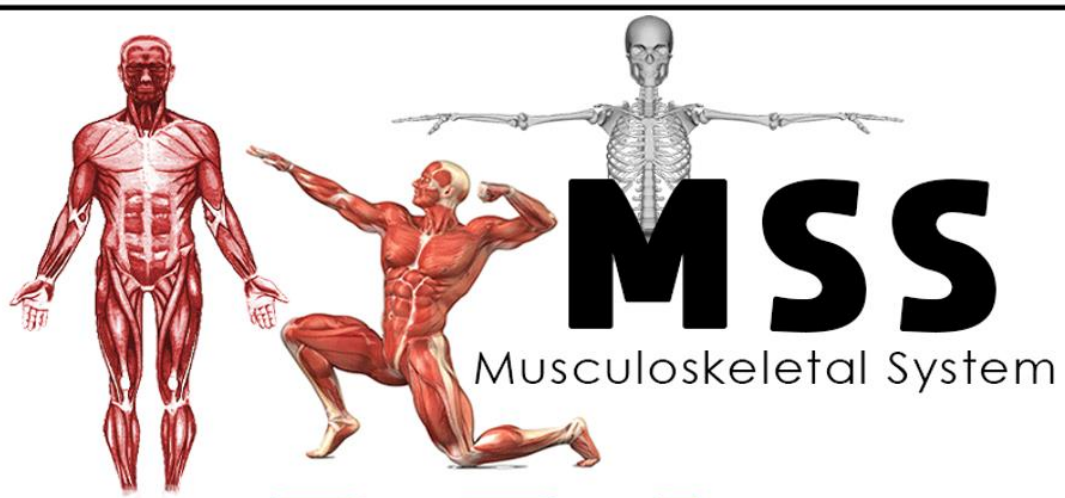

MSS

Musculoskeletal System

PBL

Problem Based Learning

Doctor 2018 | Medicine | JU

Done by

Sarah Basel

Contributed In The Scientific Correction

Luna Hussein

Contributed In The Grammatical Correction

Ibrahim N. Dbaybo

Doctor

Qussay Salih

In this sheet, we will go through clinically-oriented anatomy to get a practical perspective on gross anatomy, that will help you understand the importance of anatomic structures and function.

Head injuries

- **ANATOMY:**

  The head can be divided into the following layers:

  1. Scalp.
  2. Skull.
  3. Meninges.
  4. Brain.
  5. Cerebrospinal fluid.
  6. Tentorium.

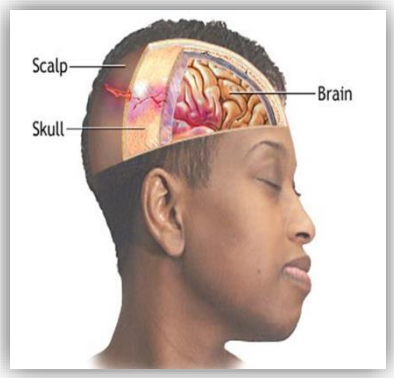

- **Scalp:**

  The scalp is a multilayered structure with layers that can be defined by the word itself:

  S: skin
  C: connective tissue
  A: aponeurosis (galea)
  L: loose areolar tissue
  P: pericranium

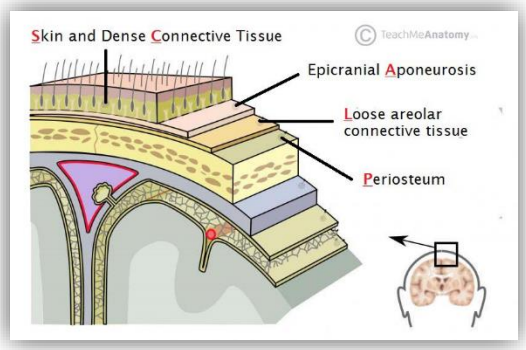

- Examining the layers of the scalp reveals that **the first three layers are tightly held together**. Forming a single unit, this unit is the tissue torn away during serious "scalping" injuries.
- **Bleeding from scalp laceration can result in major blood loss, especially in children:**

  The scalp has an extremely rich blood supply from the external carotid arteries, so lacerations of the scalp tend to bleed profusely.
- **REMEMBER:** scalp vessels do not retract when lacerated because the connective tissue in which they are found prevents retraction.

- **SKULL:**
  - It is composed of Cranial vault and a base.
  - The floor of the cranial cavity is divided into 3 parts:
    - Anterior cranial fossa → frontal lobe.
    - Middle cranial fossa → temporal lobe.
    - Posterior cranial fossa → brain stem and cerebellum.

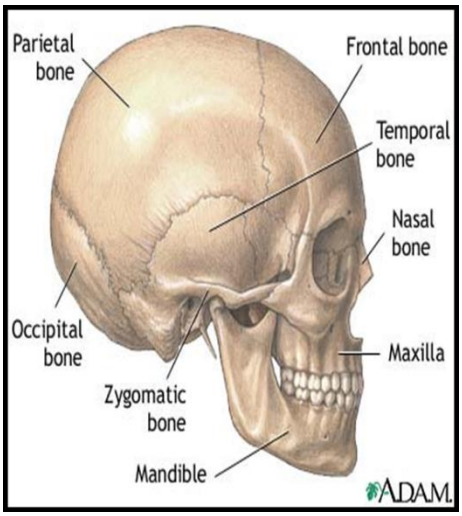

- **Skull base fractures:**
  - These are serious fractures. They are usually caused by substantial blunt trauma, involving at least one of the bones that compose the base of the skull.
  - Skull base fractures are associated with cranial nerves lesions and artery injuries.

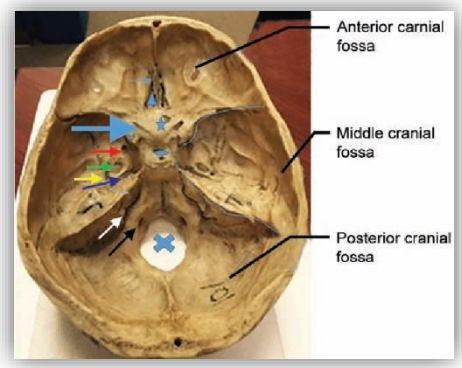

  - **EXAMPLES:**

OLFACTORY NERVE	**Loss of smell (anosmia)** Due to injury to the cribriform plate.
Facial nerve	Injury to petrous part of the temporal bone**.** **(Bell's palsy)**
Internal carotid artery	Carotid canal fractures are associated with internal carotid artery injury **(Traumatic ICA pseudoaneurysm)**.

  - **Pseudoaneurysm**: Known as a false aneurysm. A collection of blood that forms between the two outer layers of an artery. It is **usually caused by a penetrating injury to the vessel**, which then bleeds, but forms a space between the **two above layers, rather than exiting the vessel**. A true aneurysm involves all three layers of the blood vessel.

- **Meninges:**
  1. Dura: a tough inelastic covering that is continuous with the periosteum of the skull.
  2. Arachnoid: delicate richly vascularized layer (spider like appearance).
  3. Pia: the most fragile layer, this layer closely adheres to the surface of the brain and spinal cord.

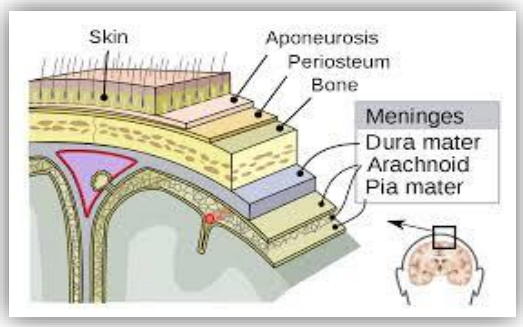

- **Subdural space** is a potential space in which hemorrhage can occur.
- **Cerebrospinal fluid circulates between the arachnoid and pia matter in the subarachnoid space**.

- **Tentorium:**

  Divides the head into:

  Supratentorial:
  - Anterior fossa.
  - Middle fossa.

  Infratentorial:
  - Posterior fossa.

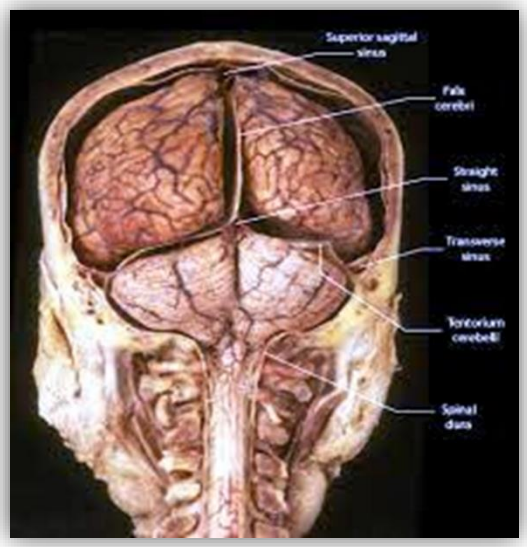

- **Cerebrospinal Fluid:**

  Cerebrospinal fluid is formed primarily by the choroid plexus, which is found in particular regions of the ventricles. Once the CSF is formed, it flows through the four interconnected ventricles of the brain and through the spinal cord's narrow canal. When the CSF reaches the upper regions of the brain, it is reabsorbed from the subarachnoid space into the venous blood through the arachnoid villi.
  - Through the ongoing processes of formation, circulating, and reabsorption, the entire CSF volume of about 150 cc is replaced three times a day. If any of these processes is defective, so that excess CSF accumulates, **hydrocephalus**

("water on the brain") (استسقاء الدماغ) occurs. This increase in CSF pressure can lead to brain damage. Treatment consists of surgically shunting the excess CSF to veins elsewhere in the body.

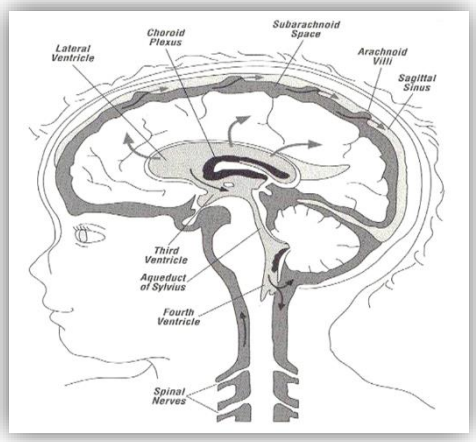

- **Intracranial pressure:**
  Swelling due to leakage from damaged blood vessels is one of our body's responses to trauma. The same happens when the brain gets traumatized. Just like any other tissue, it swells. Unfortunately, unlike other tissues, brain has no room for swelling. It is trapped inside the skull cage. The lack of space causes a rise in intracranial pressure, leading to a decrease in blood flow, which in turn impacts on the ability of brain cells to eliminate toxins.
  - **Cerebral perfusion pressure (CPP)**, the pressure of blood flowing to the brain is normally fairly constant due to autoregulation.
  - For abnormal ICP, the cerebral perfusion pressure is calculated by subtracting the mean arterial pressure from intracranial pressure:

$$CPP = MAP - ICP$$

  - One of the main problems of increased ICP is that it can cause ischemia by decreasing CPP. Once the ICP approaches the level of the mean systemic pressure, cerebral perfusion falls. This would result in brain damage because the brain depends on constant delivery of oxygen and glucose by the blood (neurons are sensitive to hypoxia and Hypoglycemia).
  - Several pathological processes that affect the brain can cause elevation of the intracranial pressure.
  - Elevated ICP not only indicate the presence of a problem but can often contribute to the problem.
    - 10 mm Hg - normal ICP (in adult).
    - 20 mm Hg - abnormal.
    - 40 mm Hg - severe elevation.
  - Cerebral perfusion pressure of less than 70 mm Hg is generally associated with poor outcome following a head injury.

♣ Classification of head injuries:

Head injuries are classified according to:

1. Mechanism of injury.
2. severity of the injury.
3. Morphology of the injury.

Mechanism	
Blunt injury	divided into: - High velocity(automobile). - Low velocity (fall, assault). 
Penetrating injury	gunshot wounds or other penetrating wounds. 
Severity	This is classified according to Glasgow coma Scale. There is a total score of 15 points, such 15/15 indicates that the patient is alert and fully oriented, whereas 3/15 indicates a severe and deep coma. The points score comprises a best motor response (total of 6 points), best verbal response (total of 5 points), and best eye movement response (total of 4 points). 1) Mild (GCS score 14-15). 2) Moderate (GCS score 9-13). 3) Severe (GCS score 3-8). 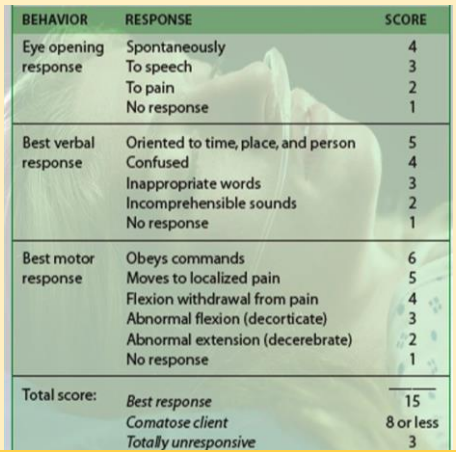

BEHAVIOR	RESPONSE	SCORE
Eye opening response	Spontaneously	4
	To speech	3
	To pain	2
	No response	1
Best verbal response	Oriented to time, place, and person	5
	Confused	4
	Inappropriate words	3
	Incomprehensible sounds	2
	No response	1
Best motor response	Obeys commands	6
	Moves to localized pain	5
	Flexion withdrawal from pain	4
	Abnormal flexion (decorticate)	3
	Abnormal extension (decerebrate)	2
	No response	1
Total score:	*Best response*	15
	Comatose client	8 or less
	Totally unresponsive	3

Morphology		
Skull fractures	○ Vault ○ Basilar	○ Linear vs stellate ○ Depressed / nondepressed ○ Open / closed ○ With/without CSF leakage ○ With/without nerve palsy
Intracranial lesions	○ Focal ○ Diffuse	○ Epidural ○ Subdural ○ Intracerebral ○ Mild concussion ○ Classic concussion ○ Diffuse axonal injury

♣ Skull fractures:

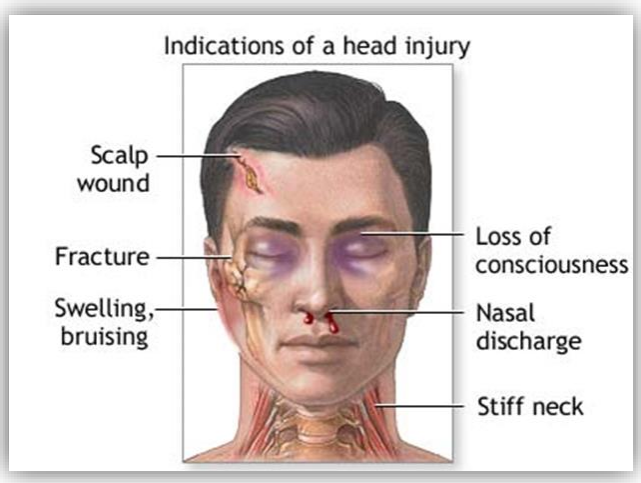

♣ Skull base (basilar) fractures:

Basilar fractures have characteristic signs:	
○ Clear fluid [cerebrospinal fluid (CSF)] leaking from the nose (rhinorrhea) or ears **(otorrhea).**	
○ Periorbital ecchymosis often called **'raccoon eyes'** (bruising of the orbit that result from blood collecting there as it leaks from the fracture site).	
○ Retroauricular ecchymosis known as **"Battle's sign"** (bruising over the mastoid process).	

- **Scalp wounds:**

  This is a case of a **Depressed skull fracture**. In a depressed skull fracture, a bony fragment is depressed below the normal skull convexity. This may lead to secondary arterial and venous damage with hematoma formation. Furthermore, brain injury can also result from this type of fractures.

  - **Surgical management:**

    Patients with depressed fractures should undergo early surgical intervention to reduce the incidence of infection.

    Method: debridement and **craniectomy** is performed if the underlying brain is damaged and swollen. In these instances, cranioplasty is required at a later date.

> **Craniectomy:** a procedure in which part of the skull is removed to allow a swelling brain room to expand without being squeezed.
>
> **Cranioplasty:** a procedure performed to restore a defect on the cranial vault after a previous craniectomy using titanium mesh or other artificial products that resemble bone structure.

- **Focal intracranial lesions:**
  - **Intracranial bleeding**
  - Venous bleeding:

    Slow, insidious onset.
  - Arterial bleeding:

    Signs and symptoms will be apparent within a few hours.
- **Computed tomography (CT):**

  Cerebral CT is the “workhouse” of neuroradiological examination. It is ideally used for head injuries because the brain, and its coverings, can be easily and quickly examined, and blood is easily detected.

- **Epidural hematoma (Also referred to as extradural):**

  Dural vessels, especially the middle meningeal artery in the pterion region, are vulnerable to traumatic injury. Once a vessel tears, blood accumulates between the periosteal layer and the meningeal layer of the dura. This will cause the dura to expand under the arterial pressure.

  Clinically, patients can be lucid for several hours after the traumatic event before neurologic signs appear (headache, confusion, vomiting, loss of consciousness and inability to move body parts).

  Treatment: usually by urgent surgery in the form of a craniotomy. Delayed surgery can result in permanent brain damage or death. Without prompt drainage, death usually follows due to enlargement of the hematoma thus increasing ICP that leads to brain **herniation and midline shift.**

  NOTE: Craniotomy is different from craniectomy. During craniotomy, the skull flap is immediately replaced, the surgeon creates a temporary flap in the skull. The hematoma is gently removed. After the procedure, the section of the skull is put back in place and secured using metal plates or screws.

  - **Surgical management=(cranio)(tomy)**

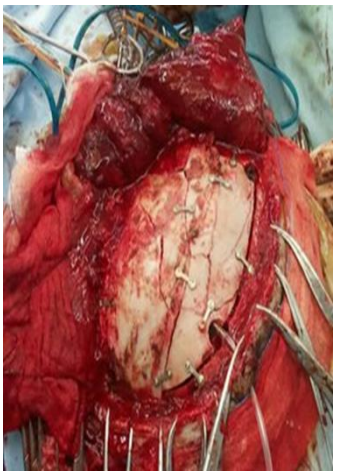

- **Subdural Hematoma:**
  - **Much more common than epidural**
  - A subdural hematoma develops between the dura mater and the arachnoid space. The hematoma results from venous bleeding, usually from torn cerebral veins, at the site of entrance to the superior sagittal sinus (bridging veins).
  - Can be associated with arterial laceration on the brain surface.
  - Subdural hematomas may cause an increase in the pressure inside the skull, which in turn, can cause compression and damage to delicate brain tissue.
  - **Treatment:** large symptomatic hematomas require a **craniotomy**.
  - **Prognosis:** acute subdural hematomas have one of the highest mortality rates (poor prognosis).
  - This kind of hematomas is not associated with skull fractures (no traumatic injury unlike epidural hematoma).
  - Usually associated with brain injury.

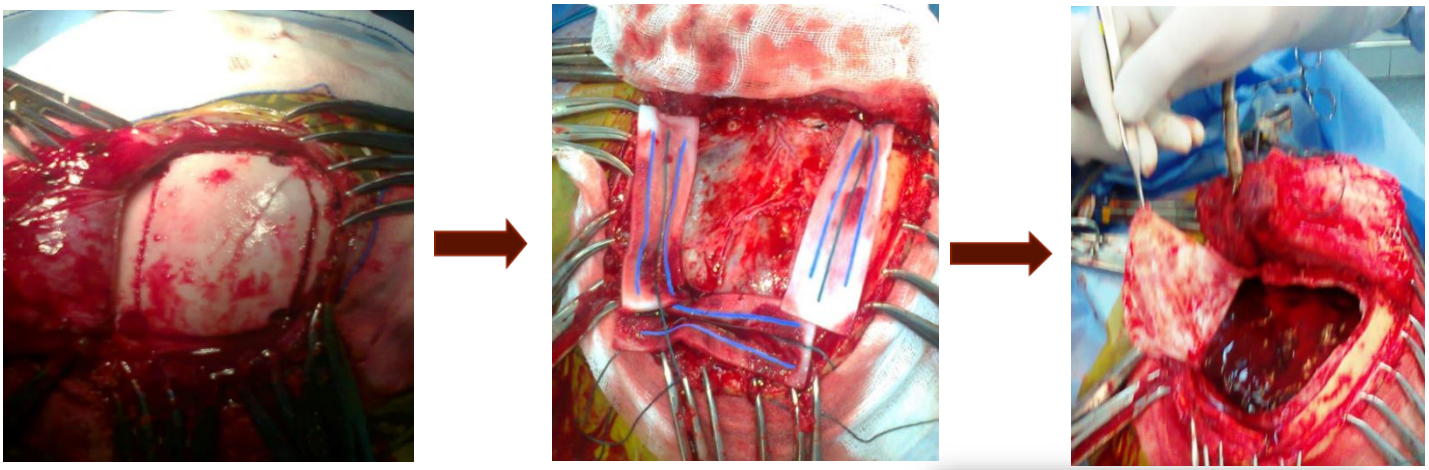

- **Contusions (bruise of the brain tissue):**
  - Almost always seen in association with subdural hematomas.
  - Majority occur in the frontal and temporal lobes, although it can occur in any part of the brain including the cerebellum and brainstem.

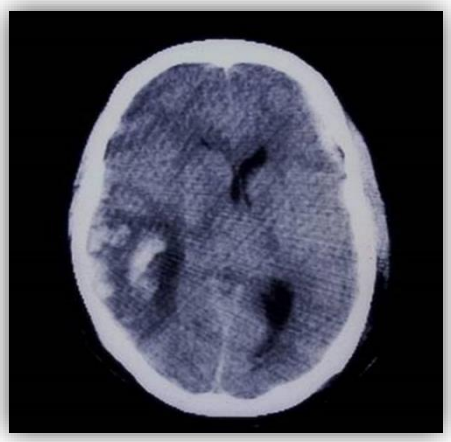

- Contusions can, in a period of hours or days, coalesce to form an intracerebral hematoma.
- Contusions differ from concussion (reversible altered brain function, recognized to occur in athletes participating in contact sport).
- "concussion" is a movie based on a true story, Dr.Qusai mentioned the story briefly during the lecture. It is a good movie to watch ☺

♣ Note: There is subarachnoid hemorrhage, but hematomas don't occur because antifibrogenic elements in the CSF prevent clot formation.

♣ **Comparison between epidural and subdural hematomas:**

Subdural	Epidural
Between dura and arachnoid mater.	Between the skull and dura mater (between the periosteal and meningeal layers of the dura mater).
Rapture to cerebral veins (bridging veins) while approaching venous sinuses, **mostly venous.**	Rupture to meningeal vessels (MMA). **Mostly arterial.**
Crescent shaped.	Lense shaped (biconvex): because its expansion stops at the skull sutures.
Poorly localized.	Well localized
	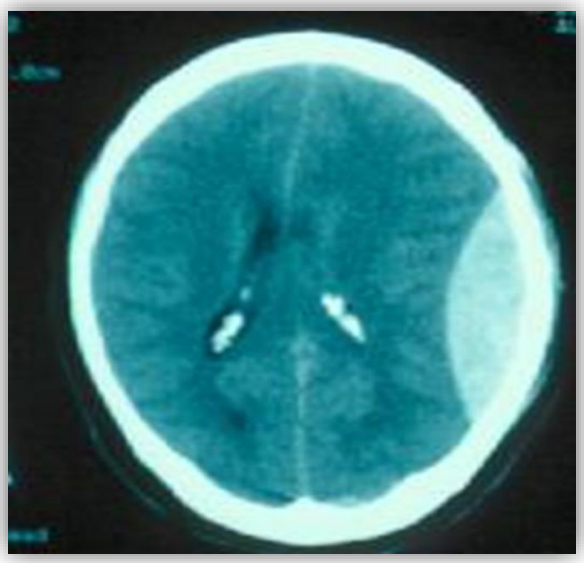

Use your mind, not just your regular brain lobes.

Best of luck…