



Medical Virology for 2nd Year M.D. Students

Polyomaviridae

University of Jordan

School of Medicine

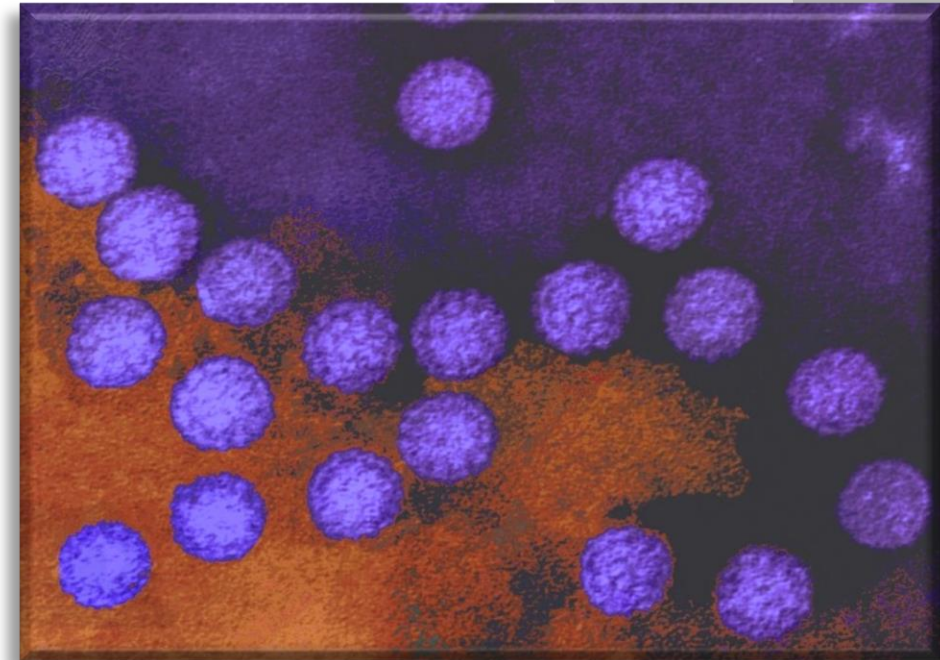
Section of Microbiology & Immunology

Malik Sallam, M.D., Ph.D.



Polyomaviridae-Introduction

- (Gk. Poly: many, multiple; Oma, tumors).
- Naked viruses.
- Icosahedral
- Contain double-stranded DNA genome.
- Able to establish latency.





Polyomaviridae-Taxonomy

➤ Family (*Polyomoviridae*)

➤ Genus (*Alphapolyomavirus*)

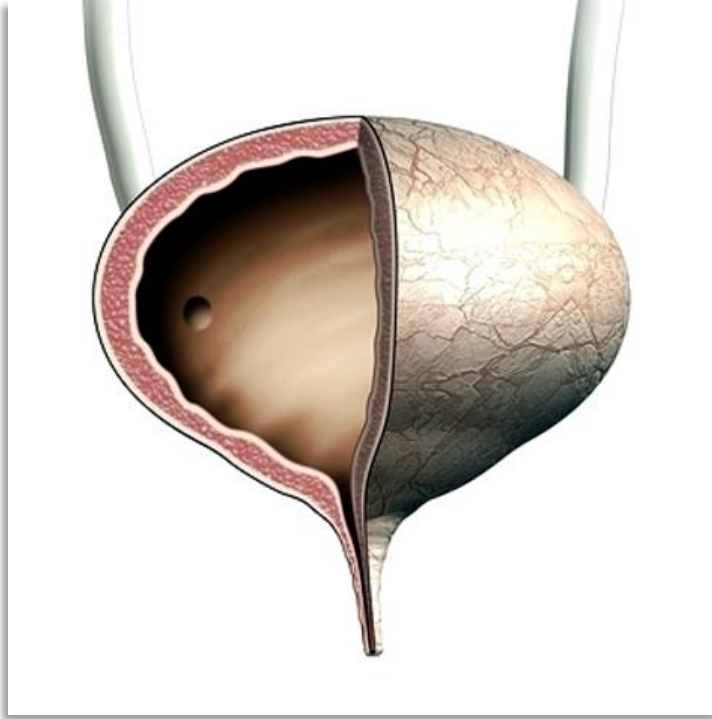
➤ Species (*BK virus (BKV)*).

➤ Species (*JC virus (JCV)*).

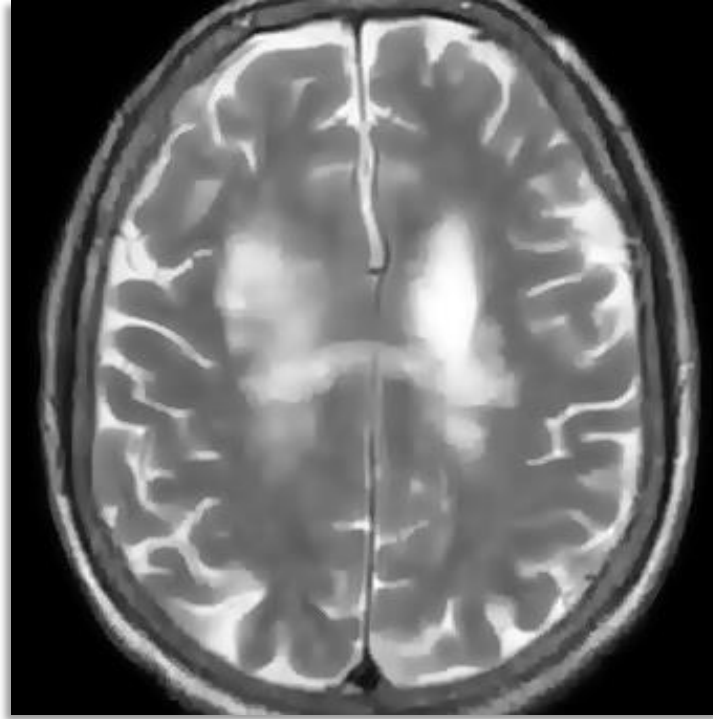
➤ Species (*Merkel cell polyomavirus (MCPyV)*).



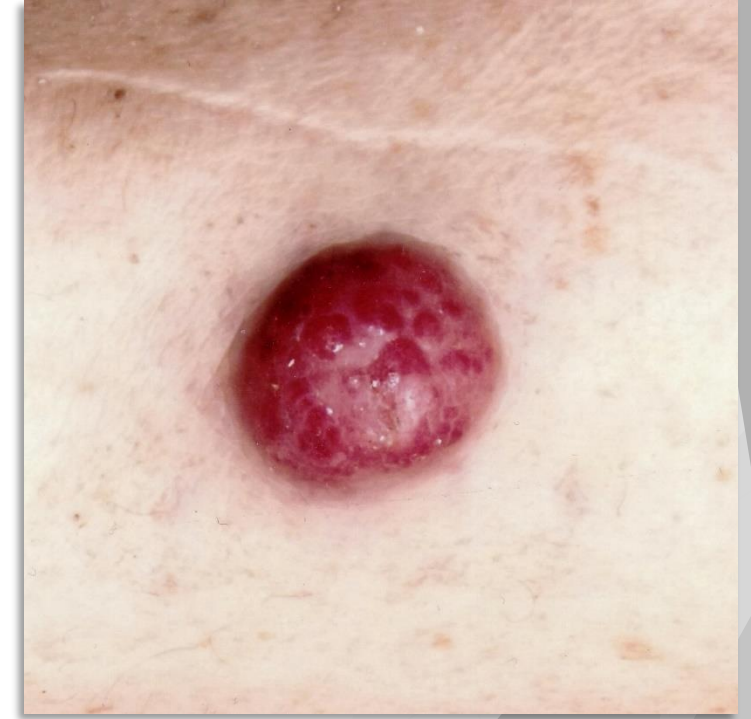Clinical Conditions



BK virus: Hemorrhagic
cystitis



JC virus: Progressive
multifocal
leukoencephalopathy
(PML)



MCPyV: Merkel cell
carcinoma



Transmission and Clinical Findings

- Routes of transmission has not been clarified.
- Primary polyomavirus infections are presumably subclinical.
- Contact is generally assumed as the portal of entry for the virus, but contaminated food and water have also been suggested as well.
- BKV and JCV are known to persist in the reno-urinary tract.
- Urinary shedding occurs asymptotically and intermittently in healthy individuals.



Clinical Findings

- ▶ Significant organ disease is observed only in patients with underlying immune dysfunction:
 - Allogenic stem cell transplantation for hemorrhagic cystitis (dysuria and hematuria).
 - HIV-AIDS or multiple sclerosis treated with immunomodulatory drugs for progressive multifocal leukoencephalopathy (cognitive impairment, visual deficit and motor dysfunction).
 - Merkel cell carcinoma, a rare neuroendocrine skin tumor is observed in elderly or immunosuppressed patients (**AEIOU**).



Epidemiology of Polyomaviruses

Seroprevalence of HPyVs in adults

HPyV	Seroprevalence in adults (%)	Country
BKV	82–99	USA, Australia, Italy
JCV	39–81	USA, Australia, Italy
MCPyV	60–81	Italy



**Karolinska
Institutet**



Dx, Rx and Prevention

- Definitive diagnosis of BKV requires a biopsy to be taken for histopathology, BKV-specific qPCR in plasma or urine.
- MRI is the imaging modality of choice if PML is suspected. The confirmatory test for suspected PML is the demonstration of JCV DNA in the CSF or brain by PCR.
- At present, there is no antiviral therapy specifically licensed for the treatment of either JCV or BKV infections.
- MCC: Surgery, radiotherapy and chemotherapy.